

(1930)

CASE REPORT

PULMONARY ASBESTOSIS: REPORT OF A CASE*

RALPH G. MILLS, M.D.,
Fond du Lac, Wisconsin

Interest in the injury to the lungs produced by the inhalation of asbestos dust has been aroused in the last six years, and several reports of cases have appeared in the medical literature of Great Britain. Aside from an occasional editorial or incidental mention, little has been written in this country about the condition. Apparently this is the first case reported from the United States. Nevertheless asbestos is mined or manufactured in many portions of this country. Undoubtedly injury to the lungs of some of these numerous workers has occurred, and may have been directly or indirectly responsible for death without the real condition being recognized. This case is reported in the hope of arousing more widespread interest in the disease and establishing it as an entity with which American physicians surely will have to deal.

REPORT OF CASE

A man, aged fifty-eight years, came to The Mayo Clinic May 26, 1929, in extremis, suffering from cardiac disease. He was taken to the hospital immediately on his arrival, and such studies were made of the disease as his condition permitted. Not a great deal was then known of his earlier history except that as a boy he had travelled the seven seas with his grandfather, who was a sea captain. He lived well and drank heavily during this period of his life. For a number of years he remained in the tropics, and finally, in 1898, contracted yellow fever. After recovery from this disease he returned to the United States and engaged in various enterprises, among others, the manufacture of brick. Subsequently, it was ascertained that the patient had been working in South America from 1911 to 1913; the significance of this fact will appear later. Aside from the illness due to yellow fever, he was thought to have been in good health until 1924, when he had an attack of dyspnea, with mild, but increasingly severe, congestive heart failure. Five distinct attacks, characterized by these same symptoms, had been experienced before the last seizure, which occurred in December, 1928, following a type of respiratory infection called influenza.

General examination revealed that there was dyspnea, cyanosis, and congestion of the lungs. The systolic blood pressure was recorded as 160 mm. of mercury, and the diastolic pressure, as 110 mm. The heart was enlarged, and there was a systolic murmur at the apex.

*Work done in the Section of Pathologic Anatomy, The Mayo Clinic, Rochester, Minnesota.
Submitted for publication May 29, 1930.

Ascites and edema of dependent portions were present, and the liver was large and tender. Examination of the ocular fundi disclosed sclerosis of the retinal arteries, of the hypertensive type, with two small hemorrhages in the retina. Roentgenologic examination of the thorax gave evidence of an enlarged heart, and of passive congestion of the lungs. This plate, however, was taken in the hospital and was not satisfactory for further analysis of the condition of the lungs. Electrocardiographic examination gave evidence of complete heart block.

During the patient's stay in the hospital he failed rapidly and dyspnea, cyanosis, and edema increased. The pulse became very irregular and manifested auricular fibrillation. There was venous congestion in the neck. Venesection was performed twice, and salyrgan, 1 c.c., was given intramuscularly once, and just before death by vein. The patient died two days after he entered the hospital. The clinical diagnosis was hypertensive cardiac disease of five years' duration, cardiac hypertrophy with congestive failure, of five months' duration, and complete heart block.

An abstract of observations at necropsy includes the following points of significance. The abdomen contained 4,000 c.c. of clear, straw-colored fluid. There were 300 c.c. of a similar fluid in each pleural cavity, and the pericardium contained 200 c.c. The heart weighed 600 gm.; the myocardium was yellowish pink, and beneath the epicardium were a few petechial hemorrhages. The consistence of the muscle was firm, and the surface presented a moderate amount of streaking. The coronary arteries were slightly sclerosed. The measurements of the heart were as follows: aortic valve ring, 7.0 cm.; mitral valve ring, 11.0 cm.; tricuspid valve ring, 14.0 cm.; pulmonic valve ring, 7.0 cm.; thickness of left ventricle, 1.8 cm.; depth of left ventricle, 6.0 cm.; thickness of right ventricle, 0.5 cm., and depth of right ventricle, 10.0 cm.

There were interlobar adhesions of the left lung, and the anterior surface of the lower lobe was covered with fibrinous adhesions. Both lobes were grayish-brown and mottled, with anthracosis, marginal emphysema, and apical scarring. The consistence of the tissue of the lung was markedly increased. On the cut surface the color was recorded as grayish-brown, and the froth and fluid that exuded were increased in amount. The upper lobe of the right lung was of the same color and general appearance as the left; it was partly covered with adhesions. Apical scarring was noted in this lung, and there was also subpleural edema. The condition of the middle and lower lobes was essentially of the same nature; the lobes were united by interpleural adhesions. A calcified node of the hilum was found.

The liver was purplish-brown, coarsely nodular, and the cut surface was finely granular. There were scat-

P. 34 L. 5

P. 35 L. 4

WAGONER
REP.

tered regions of thickening in the capsule. The cut surface was mottled yellow and red, and there was definite fatty change in the hepatic parenchyma.

The anatomic diagnosis that was given took account of the features just mentioned and included a notation of silicosis of the lungs. Microscopic examination of

hypertrophy and finally to dilatation of the right of the heart. The systolic pressure of the blood not greatly elevated when it was recorded, but diastolic pressure was relatively too high. The patient weighed as much as many hearts in cases in which hypertension was the underlying lethal factor.




Fig. 1. A large mass of asbestos, measuring more than 1 mm. in length, obtained from the lung by digesting a portion of the tissue with fuming nitric acid. Evidence of degeneration is the presence of the cross striations in the fibers. The darker portion of the fiber had a distinct yellowish-brown color (x75).

Fig. 2. A tangled mass of asbestos fibers in an unstained section of pulmonary tissue. From its distribution one would suspect that it had been dilodged by the microtome knife. Scattered black dots are "asbestos bodies," indicating that portions of the fibers, at least, had undergone change in tissues (x175).

the essential tissues was made. Numerous phagocytic cells that contained quantities of blood pigment were noted in the alveoli of the lungs. Special stains for iron demonstrated its presence in these cells and also in the walls of blood vessels and alveoli. There appeared to be some increase in the amount of readily visible elastic tissue in the lung. Fibrosis was very marked.

COMMENT

During the final survey of the sections in this case there were observed certain peculiar, brownish, fibrous structures, apparently foreign bodies, in the tissue from the lung, usually embedded in connective tissue, and often engulfed by large giant cells. They did not take the ordinary stains, and some of them were shown to contain iron by the Prussian blue reaction. There was much discussion as to the nature of these bodies, without any conclusion being reached. The possibility was considered that they might be asbestos fibers, but at that time there was little basis for such a contention. There was no history of exposure to asbestos dust, and certain apparent differences were observed between the reactions of these fibers and those shown by commercially prepared asbestos. However, further study strengthened rather than weakened the impression that the bodies were asbestos fibers. Evidently the fibrosis of the lungs was in some way connected with the presence of these foreign bodies. The idea was further entertained that the fibrosis of the lungs was responsible for progressive increase in resistance to the circulation through the organs, and may have led to

complete heart block was hardly to be explained on the basis of partial obstruction. There seemed to be no final answer to several questions connected with this case.

Shortly after the death of this patient, I corresponded with one of his business partners, and mentioned the fibrosis of the lungs. I also wrote that the fibers found looked more like bits of asbestos than anything I could think of, and asked if, fifteen years or more before his death, the patient could have been exposed for a considerable time to inhalation of inorganic dust such as asbestos, or any material that would give sharp angular particles as well as longer, irregular fibers.

More than eight months after this letter was written a business associate called on me, and stated that he had ascertained that the deceased had, as a young man, worked in an asbestos mine in South America. Later still, another business associate wrote that while the patient had been in South America he had drilled asbestos-bearing rock. The shot holes were clear by air. Presumably this was prior to 1898, when the patient left the tropics, or at least thirty-two years before death.

The study of the lungs and heart was resumed, insofar as material was available. This unfortunately was limited. A few small pieces of pulmonary tissue were subjected to the action of fuming nitric acid to oxidize all the organic matter, and to concentrate in the sediment any inorganic fibers or other particles that might have been embedded in the substance of the lung. The pulmonary tissue contained a surprisingly large amount

of fat which collected as fatty acid on the surface of the liquid. This was not a clear yellow, and a smear of it was made, with the idea that some of the fibers might have been caught in this material and thus prevented from settling to the bottom of the heavy fluid. The sediment collected from the bottom, after washing,

These asbestos fibers did not show more plainly by polarized light. The golden-brown color of the fibers was a distinguishing feature under the microscope.

Smaller fibers of asbestos, when lying separate, seemed to have undergone changes not observed in larger fragments. The butt end of one of these frag-




Fig. 3. A small fascicle of asbestos lying in a giant cell. A knob with a brownish envelope has developed on the butt end of the fiber; the frayed ends opposite have broken off as golden-brown oval bodies (x200).

Fig. 4. A group of asbestos fibers surrounded by giant cells. Their golden-brown color distinguished them from fibers of elastic tissue, which stained more of a lilac color with hematoxylin and eosin. The asbestos fibers were frequently thicker and more irregular in outline, and remained unchanged in color with the ordinary aniline dyes (x150).

was found to contain a few fibers, together with some small particles of silica. Such drastic treatment as boiling in fuming nitric acid would destroy most materials, even the finest fibers of asbestos, but would probably not affect appreciably the larger ones.

In the scum that collected on the surface of the solution of nitric acid were found several fragments that were certainly asbestos. The largest was more than 1 mm. in length (Fig. 1). This had the definite cross striations that are characteristic of altered asbestos fibers, as described by various observers.² When viewed under polarized light a portion of the mass was dark and there were brilliant streaks through it, thus duplicating the appearance given by a known sample of asbestos from commercial sources. A portion of the mass of asbestos had a yellowish-brown color of exactly the nature and shade presented by the control sample. The physical configuration also agreed with what one would expect of asbestos.

In Figure 2 are shown the asbestos fibers in a smear where they apparently had been spread through the tissues by the microtome knife. The section in which they were found had not been stained. A few golden-brown oval bodies were mixed with the fibers, suggesting that some alteration in their structure had taken place, but the condition of the main mass indicated that the center had been protected from this change in the tissues. Alteration apparently affected mostly the finer fibers, leaving the larger masses relatively unchanged for this long period of time. Search was made for the elastic tissue fibers about the blood vessels, and in the alveolar walls, but they could hardly be distinguished.

ments is shown in Figure 3. It had become enlarged and knobbed, and had a distinctly brownish color. There seemed to be an envelope of a lighter brownish color about a darker center; the latter was continuous with the fiber inside the giant cell. The frayed ends of the fiber gave place to the golden-brown oval bodies, whereas that portion within the giant cell was the least changed. The majority of asbestos fibers of small size lay in a confused mass of giant cells, which seemed to represent a foreign-body reaction. In Figure 4 is shown a scattered group of fibers, among which can be seen giant cells; the adjacent tissue of the lung has been undergoing interstitial fibrosis. The asbestos fibers were readily distinguished from elastic tissue fibers by their golden-brown color; the fibers of elastic tissue took a lilac-brown stain with hematoxylin. The former were unchanged by ordinary aniline dyes, whereas the latter were readily tinted by various methods usually applied to such tissues.

In certain areas the process was still more advanced and connective tissue of a more mature type was seen, sometimes in more or less circumscribed areas. Such a nodule of scar tissue is shown in Figure 5, but this is not entirely comparable to the so-called silicotic nodules found in cases of silicosis in which tuberculosis plays a part.

There seemed little doubt that many of the asbestos fibers had been almost completely removed from the tissues. The frequent association of partly absorbed fibers and the golden-brown oval bodies shown in Figure 6 leaves little doubt that the latter were derived from the former. They were often in the same giant cell,

or lay close to fibers in various stages of dissolution. There was a central, darker portion, which probably represented the remains of a fiber, and which was not dissolved by nitric acid.³ The outer, lighter brown covering, however, disappeared, and was thought to be a deposit of pigment of endogenous origin, probably

silica were detected in the tissues and in the residue after oxidation with the acid, but not enough to explain the fibrosis which was present. Apparently once asbestos dust enters the lung it continues to injure the tissues as long as the person lives. In short, asbestosis is an incurable disease, and one from which the pa-

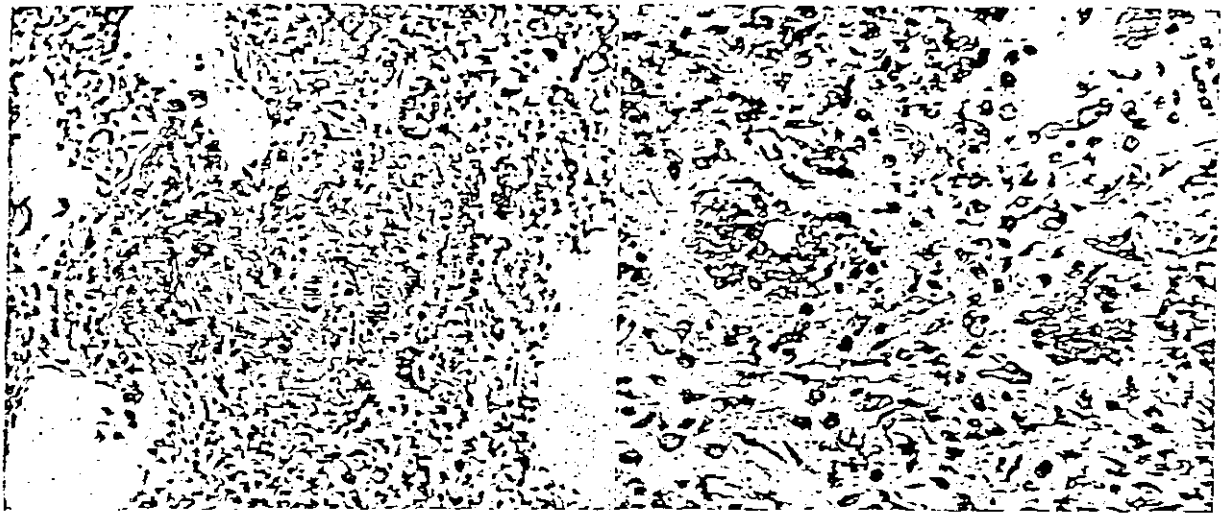


Fig. 5. A circumscribed nodule of fibrosis composed of fibrous tissue and giant cells in the midst of which lie partly degenerated asbestos fibers. The giant cell at the upper edge of the nodule contains several "asbestosis bodies" presumably in the stage of transition between a continuous fiber and the golden-brown oval bodies (x200).

Fig. 6. Two giant cells with inclusions. The one on the right contains a bit of golden-brown asbestos within it, and there is also one above and one below the cell. The cell on the left contains numerous golden-brown bodies and a large vacuole in which lie more of these bodies, together with granules of hemogenous pigment. The tissue is markedly fibrotic (x450).

derived from the blood. It did not take a Prussian blue stain, although there is reason to believe that it contained iron in the form of one of the higher oxides. These golden-brown oval bodies were not birefringent under polarized light. They were believed to represent the end stage of disintegration of fibers of which an intermediate stage has been described by Cooke,^{1,2} and by McDonald as "curious bodies" and by Stewart and Haddow as "asbestosis bodies." These men saw cases of more intense nature, and fibers that had not been exposed to the tissues for such a long period of time. The oval bodies did not stimulate the foreign-body reaction to such a marked extent as did the incompletely disintegrated fibers, but were scattered in clumps or singly through regions of mature connective tissue. This may be attributed to the cessation in the release of silicic acid in the colloidal form, a process that is believed to explain the fibrosis in cases of silicosis. Asbestos is a silicate, and hence presumably subject to the same dissolving process that affects particles of pure silica in the production of silicosis.

The ordinary "heart failure cells" presented the usual morphology and staining reactions. Occasional cells of the same general nature as the heart failure cell were found, measuring 100 to 150 microns in diameter. They contained only blood pigment, a few golden-brown oval bodies, bits of degenerated elastic fibers, or any combination of the three.

Perhaps the most valuable feature of this case is the extreme length of time that elapsed between the exposure to the dust and death. A few particles of

tient may or may not die. Intercurrent disease has been found in other reported cases to be unusually frequent, especially tuberculosis and bronchopneumonia. Neither were present in this instance, and death occurred from hypertensive heart disease, with complete heart block. This complication has not been mentioned before in this connection.

There is no reason to believe that the hypertension was directly connected with the pulmonary asbestosis, but the extreme dilatation of the right side of the heart is probably attributable to the fibrosis of the lungs. Passive congestion of the lungs is to be considered as a complicating factor, and may have operated in preventing a possible tuberculous infection. Auricular fibrillation was associated with the cardiac decompensation, and the heart block was probably of similar origin. Infarction of the heart was not found, and only the fatty changes in the myocardium were discovered which also involved the bundle of His. Colloidal silica has been found in previous studies⁴ to be injurious to other viscera, especially the kidneys, but in this instance such alterations were not marked. The heart block, then, can hardly be attributed to this toxic factor.

SUMMARY

A case of pulmonary asbestosis, found in the United States, and of at least seventeen years' duration, is described. Pertinent clinical and pathologic details are given. This report corresponds reasonably well with reports from Great Britain.

39 South Main Street.

BIBLIOGRAPHY

1. Cooke, W. E.: Fibrosis of the lungs due to the inhalation of asbestos dust. *Brit. Med. Jour.*, 2:147 (July 26) 1924.
2. Cooke, W. E.: Pulmonary asbestosis. *Brit. Med. Jour.*, 2:1024 (Dec. 3) 1927.
3. Gloyne, S. R.: Presence of asbestos fibre in lesions of asbestos workers. *Tubercle*, 10:404 (June) 1929.
4. Gye, W. E., and Purdy, W. J.: The poisonous properties of colloidal silica. I. The effects of the parenteral administration of large doses. *Brit. Jour.*

- Exper. Path.*, 3:75 (April) 1922. II. The effects of repeated intravenous injections on rabbits; fibrosis of the liver, 3:86 (April) 1922. III. 5:238 (Aug.) 1924.
5. McDonald, Stuart: Histology of pulmonary asbestosis. *Brit. Med. Jour.*, 2:1025 (Dec. 3) 1927.
6. Stewart, M. J., and Haddow, A. C.: Demonstration of the peculiar bodies of pulmonary asbestosis ("asbestosis bodies") in material obtained by lung puncture and in the sputum. *Jour. Path. and Bacteriol.*, 32:172 (Jan.) 1929.

METATONE NOT ACCEPTABLE FOR N. N. R.

Shotgun tonic mixtures were very popular a generation ago and some received more or less official recognition by being included in the National Pharmacopeia. In recent years these tonic mixtures have deservedly fallen into disuse, although included in the line of preparations of many manufacturers. Occasionally an effort is made to revive the use of such tonics by the addition of an ingredient the use of which has become a current fad. One of the recent attempts in this direction is the exploitation by Parke, Davis & Co. of a typical shotgun tonic mixture, modernized by the addition of "Vitamin B extract." This preparation, known as Metatone, is stated to have the following composition: alcohol, 1 per cent; Vitamin B extract per fluid ounce, 10 grs.; nucleic acid, 2 grs.; calcium glycerophosphate, 4 grs.; potassium glycerophosphate, 4 grs.; sodium glycerophosphate, 2 grs.; manganese glycerophosphate, ½ gr.; strychnine glycerophosphate, 8/200 gr. The statement as to the amount of "Vitamin B extract" is meaningless and gives no indication as to the actual amount of Vitamin B present, and there appears to be no good reason for giving it along with the other constituents of Metatone. Most of the other constituents of Metatone have long since been discredited as useful therapeutic agents. The Council on Pharmacy and Chemistry declared Metatone unacceptable for New and Non-official Remedies because it is an unscientific mixture, marketed under a proprietary name with unwarranted therapeutic claims. (*Jour. A. M. A.*, May 3, 1930, p. 1405.)

ELECTRIFIABLE PLATES

The Post Office Department reports that J. M. Hughes, his wife, Mrs. J. M. Hughes, and his daughter, Essie I. Hughes, all of Atlanta, Ga., have for some time been defrauding the public under the trade name "Electrifiable Company" in the sale of so-called heel plates. These plates were crudely cut from sheets of copper and zinc. They cost 25 cents a pair; they sold at \$5 a pair! It was claimed that, when worn in the shoes, the plates would cure hardening of the arteries, high blood pressure, enlargement of the heart, kidney trouble, hardening of the prostate gland, diabetes, rheumatism and dropsy! The Postmaster General issued a fraud order against the Electrifiable Company and J. M. Hughes. (*Jour. A. M. A.*, May 3, 1930, p. 1427.)

USE OF THYROID IN OBESITY

The use of thyroid in obesity should always be controlled by a previous basal metabolism test. If this is normal or subnormal, it is safe for a physician to use thyroid. The best practice is to start with small doses of desiccated thyroid (Thyroideum, U. S. P.) gradually increasing. The small dose would be approximately 0.03 Gm. (½ grain) twice a day. The physician must keep a sharp lookout for fast pulse, nervousness or other symptoms resulting from thyroid stimulation. An obese person should not expect reduction by thyroid unless his diet is restricted, and when dietary restrictions are followed thyroid is not needed as frequently. (*Jour. A. M. A.*, May 31, 1930, p. 1784.)