

Snake Bites

Jiann-Ruey Ong, MD; Hon-Ping Ma, MD; Tzong-Luen Wang, MD, PhD

Abstract

Snakebites are not uncommon in Taiwan. There are 23 venomous snake with 6 most common encountered here. Annual report of snakebites is about 300~600 with mortality of 10~20. Traditional classification of venom by hematoxin or neurotoxin is still useful in initial clinical management. Severe envenomation occurred in less than 5%. First aids in the field and prompt deliver to nearest capable facilities for medical care or administration of antivenom greatly reduce the morbidity and mortality. History of exposure, local effect and systemic syndromes of envenomation, progression of symptoms and signs, laboratory data obtained in emergency department should guide the decision for antivenom therapy. Coagulopathy with shock and respiratory failure is the main complications. Aggressive supportive treatment for possible complications of snakebites and allergic reaction of antivenom therapy is the mainstay of management. (*Ann Disaster Med.* 2004;2 Suppl 2:S80-S88)

Key words: Snakebites; Antivenom; Critical Care

Introduction

Snake bites are encountered worldwide. Of the 3000 species of snakes, about 10% to 15% are venomous. Of the 14 families of snakes, 5 contain venomous species. Taiwan has about 23 venomous snakes. Snakes are poikilotherms, which account for their distribution and activity, and mostly active around 25~35°C. They distributed throughout most of the earth's surface, including fresh and salt water with only few exceptions.

Epidemiology

Reported snakebites are about 6000 annually in American and 2000 events are venomous bites. There are 300 to 600 reported snake-

bites in Taiwan annually, causing death of 20~30 people. 97% of snakebites are on the extremities. Males are bitten more frequently than females. 85% snakebites are predominate hematoxin.

Classification

There are about 23 types of venomous snakes in Taiwan, and 9 of them are sea snakes. Russell's viper and *Agkistrodon acutus* are found over the southern and middle part of Taiwan. Others distributed throughout the island.

Among five venomous families are

1. Colubridae
2. Hydrophidae / sea snakes: *Hydrophis cyanocinctus* Daudin (青環海蛇),

From Department of Emergency Medicine, Shin-Kong Wu Ho-Su Memorial Hospital, Taipei, Taiwan
 Address for reprints: Dr. Tzong-Luen Wang, Department of Emergency Medicine, Shin Kong Wu Ho-Su Memorial Hospital,
 No 95, Wen Chang Road, Taipei, Taiwan
 Received: Feb 12 2004. Revised: Feb 27 2004. Accepted: Mar 12 2004.
 TEL: 886-2-28389425 FAX: 886-2-28353547 E-mail: M002183@ms.skh.org.tw

- Laticauda colubrina* (黃唇青斑海蛇)
3. Elapidae: *Bungarus multicinctus* (kraits, 雨傘蛇), *Naja Naja atra* (眼鏡蛇)
 4. Viperidae / true vipers: *Vipera russelli formosensis* (Russell's viper, 鎖鏈蛇), *Trimeresurus stejnegeri Schmidt* (青竹絲), *Trimeresurus mucrosquamatus* (Turtle-Designed Snake, 龜殼花)
 5. Crotalidae / pit viper: *Agkistrodon acutus* / *Deinagkistrodon acutus* (百步蛇).

Snake venom are classified as either neurotoxic or hematotoxic. Some of the snakes have compound toxin. Even this classification

is felt inadequate currently, it is useful in clinical management. Six of the most usually encountered snakebites in Taiwan are classified as below by venom toxicity.

1. Hematoxin: Crotalinae, Viperidae.
 - Hematoxin alter vessel permeability, and procagulant toxin may cause swelling, severe pain, ecchymosis and consumption coagulopathy.
 - *Agkistrodon acutus* (百步蛇 / 五步蛇)
 - *Trimeresurus stejnegeri stejnegeri* (赤尾鮎 / 赤尾青竹絲)

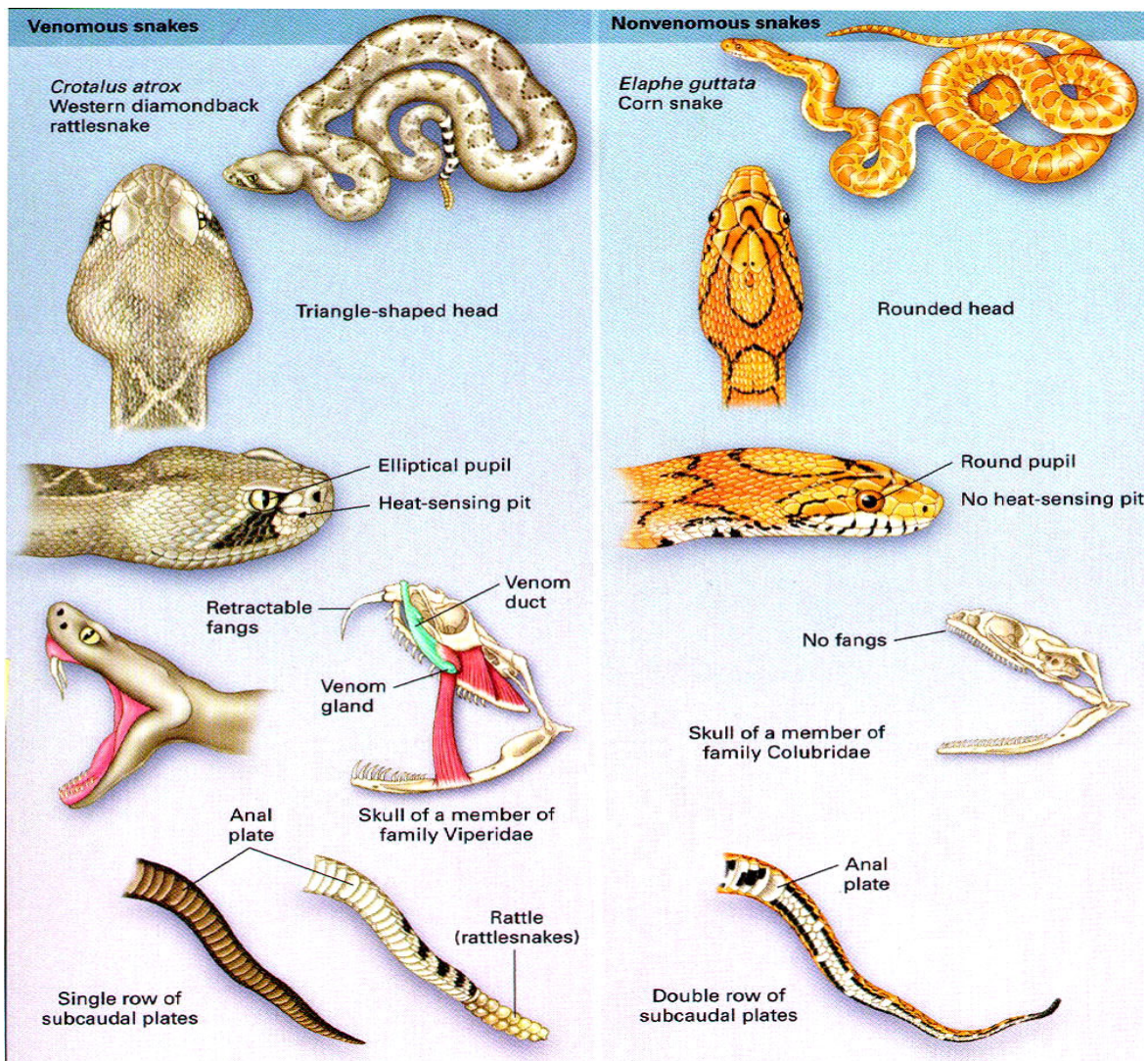


Figure. Differentiation between venomous and non-venomous snakes (adapted from Gold BS ed. Current Concepts: Bites of Venomous Snakes. NEJM 2002;347: 347-56)

- *Trimeresurus mucrosquamatus* (龜殼花)
2. Neurotoxin: Elapidae. Neurotoxin acts on neuromuscular junction and causes paralysis. Signs usually become within 2~4 hours or may be delayed after the bite, which include ptosis, partial ophthalmoplegia, dysarthria, loss of facial expression, loss of airway control and respiratory paralysis. ● *Naja naja atra* (眼鏡蛇)
 - *Bungarus multicinctus* (雨傘節)
 3. Mixed:
 - *Vipera russell Formosensis* (鎖鏈蛇)
 - *Sea snake* (海蛇)

Identifications: Venomous vs. non-venomous

Differentiation of between pit vipers and harmless snakes have several principles. In the assessment of a reported bite from a venomous snake, one must distinguish the bite from that of a nonvenomous snake or another animal and from puncture wounds caused by inanimate objects (Figure). In the absence of positive identification, objective signs and symptoms of envenomation become the primary focus of diagnosis.

Clinical Features

Observed snakebites is a straightforward diagnosis. Sometimes, highly suspicion of snakebites is required for vague bite mark or symptoms. Although suspected snakebite was common, severe envenoming occurred in less than 5% of cases. The signs and symptoms of a venomous snakebite vary considerably and depend on comorbidity, size, age of the victim; the age, health, size of the snake; relative toxic-

ity of the venom; condition of the fangs; whether the snake has recently fed or its injured.

Local envenomation, if left untreated, can cause serious systemic problems as the toxic products are absorbed. The victim's autopharmacologic response to the envenomation must also be taken into account. A wave of effects can occur over several days, ranging from minimal pain to multisystem failure and death.

From 30% to 50% of venomous snakebites result in little or no envenomation, less than 5% are severe envenomation.

Local effect. The fang mark from neurotoxin predominate snakebites, eg. Kraits or *Naja naja atra* usually are not remarkable with little pain or swelling and difficult to identify. Petechiae, edema, swelling and ecchymosis are remarkable from hematoxin predominate snakebites (i.e. pit viper). Severe localized pain and hemorrhagic bullae are also prominent. Oozing from fang marks usually is caused by Russell's viper. Necrosis of the skin and subcutaneous tissue is noted later. Numbness is the hallmark of neurotoxin snakebites. Duration from snakebites and accompanied soft tissue presentations are also useful in identifying snakebites. Progressive swelling of extremities may cause compartment syndrome and fasciotomy is usually required. Rhabdomyolysis and necrosis is inevitable.

Systemic effect. The most common reaction to snakebite is terror, which may cause nausea, vomiting, diarrhea, syncope, tachycardia, and cold, clammy skin. Many people believe that any bite from a venomous snake will result in envenomation; in fact, 25 percent of all pit-viper bites are "dry" and do not result in envenomation. Autonomic reactions related to

terror must be differentiated from systemic manifestations of envenomation.

Some of the neurotoxin snakebites rapidly progressed to neuromuscular symptoms with dysphagia, dysarthria, general weakness, cranial nerves palsy, and even respiratory failure. Others may have prodromal phase of dizziness, nausea, vomiting, perioral numbness and tingling, metallic taste in the mouth, muscle fasciculation, ptosis and then accompanied by acute respiratory failure, especially from *Naja naja atra*. The common cause of death is respiratory failure. Some of the systemic neuromuscular weakness may be delayed in onset, thus, close observation for at least 8 hours is required. Baseline and serial pulmonary function test are important.

Increased capillary membrane permeability and disruption of coagulation mechanism with bleeding are common in hematoxin predominating snakebites. Prolonged aPTT and PT, thrombocytopenia will not be reversed without antivenom therapy. Shock and massive pulmonary edema may be developed. Heart and kidney damage occurs secondarily to this mechanism. Some specific toxin may act directly on specific organ, such as heart, causing heart failure and even arrhythmias. Allergic reactions secondary to histamine and bradykinin release may aggravate systemic response.

Diagnosis

Snakebites are clinically suspected by history of exposure, clinical symptoms and laboratory tests. Snakes recognition may be assisted by pictures or specimen provided at emergency department. Fang marks, local or systemic symptoms are helpful.

(1) History of exposure (Snakes type, fang

marks, sites of accident, time, initial management.)

- (2) Physical examinations (local effects: fang marks, swelling, ecchymosis, pain; systemic symptoms)
- (3) Laboratory data (CBC, coagulation profile, chemistry, urinalysis)

Treatment

Medical management for snake bites includes first aids, emergency care, and antivenom therapy and monitoring possible complication.

First aids.

1. Try to recognize the snake by appearance, color and characteristics
2. Victim should be moved beyond striking distance to prevent second strike.
3. Placed at rest, kept calm and warm, as soon as possible. Keep physical activity minimal. Movement (i.e. walking) will facilitate venom absorption.
4. Rings, watches, and constrictive clothing should be removed on involved extremities, and stimulants (eg. alcohol) should be avoided. Immobilize extremities in a functional position below the level of the heart by compressive dressing and splint. Constriction bands (elastic bandage or penrose drain, rope, or piece of clothing) may be of some use, especially when immediate medical care is not available. For hematoxin predominant snakebite (i.e. marked swelling and ecchymosis) wrapped circumferentially above the bite, applied with enough tension to restrict superficial venous and lymphatic flow while maintaining distal pulses and capillary filling. The band should be snug but loose enough comfortably slide a finger underneath. For neurotoxin predominate

snakebite, the bitten extremities should wrap in a snug elastic bandage, elastic bandage are applied initially over the bite site and then extending to cover the entire limb.

5. Previously recommended first-aid measures such as tourniquets, incision and suction, cryotherapy (ice water immersion), and electric-shock therapy are strongly discouraged. If a tourniquet or constriction band has been placed as first aid, it should be left in place until the victim is evaluated in the hospital and, if appropriate, until infusion of antivenom is initiated.
6. Patients are transported immediately to the nearest medical facility regardless of whether overt signs of envenomation are quickly apparent. Signs and symptoms of snakebites may be delayed.
7. Paramedical personnel should focus on support of the airway and breathing, administration of oxygen, establishment of intravenous access in an unaffected extremity, and transportation of the victim to the nearest medical facility

Emergency management. Any suspected snakebites should prompt the initiation of first aid, investigation and observation. Early consultation is recommended due to complex presentations. The first priority is maintaining of vital signs and advanced life support. If snakebites has been confirmed or highly suspected, the next step is to identify dry bite to envenomation. Envenomation grading is helpful to determine the need for antivenom. Prompt antivenom therapy, aggressive supportive resuscitation and treatment of complications greatly reduce mortality of snakebites.

The time elapsed since the bite allows assessment of the temporal effects of the bite to

determine if the process is confined locally or if systemic signs have developed. Sign of envenomation should be aggressively sought, by clinical and laboratory evidence of venom effect. Assess the timing of events and onset of symptoms. Inquire about the time the bite occurred and details about the onset of pain. Early and intense pain implies significant envenomation

- Absent: removed elastic bandage, observed for at least 12h. Delayed envenomation after benign presentation has been documented, but most envenomation patients will develop clinical or laboratory evidence of envenomation within 2h of removing bandage. Coagulation studies should be repeated 2h after bandage removal and at interval thereafter, depending on patient's condition.
- Present: The bandage should be left in place until signs are absent or antivenom has been applied. If the patient's condition deteriorates immediately after bandage removal, the bandages may be re-applied while antivenom is given. Assess clinical severity for possible antivenom.

The wound should be cleansed with soap and water. Immunized with tetanus. Wound culture and antibiotic therapy should be initiated only if signs of infection are present. Prophylactic antibiotics are not indicated in the routine treatment of patients with snakebites from neither non-venomous nor venomous snakes if no necrosis is present. Use of antibiotics prophylactically will have little impact on further infection but may give rise to side effects. It is not cost effective and may select out more resistant organisms. The event rate for infection after snake bite from venomous

snakes is low.

Lab:

- CBC with manual differential and peripheral blood smear
- Prothrombin time and activated partial thromboplastin time
- Fibrinogen and split products
- Type and cross
- Blood chemistries, including electrolytes, BUN, creatinine, CK
- Urinalysis for myoglobinuria
- Arterial blood gas determinations for patients with systemic symptoms
- Baseline and serial pulmonary function parameter if suspect neurotoxin.

Antivenom. Antivenom is the mainstay of therapy for poisonous snakebites. Envenomation grading is helpful to determine the need for antivenom. Progression of signs and symptoms also indicated for antivenom therapy even after several days of snakebites. Antivenom is most effective if infusion within 4h, and less effective if more than 8 hours. Nevertheless, in severe envenomation, antivenom should be considered even after 3~4 days. Never use intramuscular or digital injection. Observation for progression of edema and systemic signs should be continued during and after antivenom infusion. Limb circumference should be measured at several sites above and below the bite. Repeat above exams every 4 hours.

There are four types of antivenom available currently in Taiwan.

1. Polyvalent hematropic antivenom;
2. Polyvalent Neurotropic antivenom;
3. Monovalent antivenom for *A. acutus*;
4. Monovalent antivenom for Russell viper.

Skin test Always remember skin test.

Diluted 1000u (1 vial) of antivenom with 10ml diluent to 100u/ml. Then use 0.1 ml of this solution and diluted to 1ml. Use 0.1ml (1u) of second solution for skin test. Wheal formation in 30min is positive.

- Negative skin test: Infusion in 15~30min, never more than 2h.
- Positive skin test: If antivenom therapy is mandatory, give premedication with antihistamine and steroid, and keep slow infusion for half to 2 hours. Epinephrine infusion should be readily available and used.

Progression of signs and symptoms:

- worsening of local injury: pain, ecchymosis, swelling
- laboratory abnormalities: worsening platelet counts, prolonged coagulation times, decreased fibrinogen
- systemic manifestations: unstable vital signs or abnormal mental status

According to Dr. Dart's data, envenomation can be validated by severity scoring. The scoring system depends upon minimal-moderate-severe score, grade I-IV score, and snake severity score. The total score interpretation is 1.3-2.8 for no risk, 2.1-2.3 for minimal risk, 3.2-3.5 for moderate risk, and 8.5-9.5 for severe risk.

Complications or side effects from antivenom therapy. Acute and delayed allergic reactions are fewer with new antivenom than conventional equine-derived antivenom. Acute reactions occurred in 19% of patients with isolated urticaria, cough, hives, dyspnea and wheezing. Infusion should be stopped immediately for all allergic reactions. Mild cases may resolve spontaneously without treatment or responded to antihistamine and steroid. In mod-

erate cases, continued antivenom infusion was given if the reaction response to antihistamine and steroid or the envenomation is very severe. Epinephrine infusion should be readily available depending on the severity of the reaction. Delayed serum sickness will be developed in 23% of patients usually begin from 2 to 10 days after antivenom administration and last for a week or more.. These include pruritis, rash, arthralgia, anorexia, and hives. But these are usually resolved with antihistamine (eg. Diphenhydramine, hydroxyzine, cimetidine) or steroid (methylprednisolone) according to the severity of allergic reactions. Serum sickness is the only indication for the use of steroids with snakebites.

Complications of Envenomation

- **Coagulopathy.** Antivenom is the best treatment for coagulopathy, but if active bleeding occurs, blood component replacement may be necessary.
- **Compartment syndrome.** Severe envenomations may be associated with increased compartment pressure. The local reaction to envenomation, manifested as marked swelling, tenderness, tenseness, hypesthesia, and pain, may mimic a true compartment syndrome. In cases of suspected compartment syndrome, clinical diagnosis requires objective evidence of elevation in compartment pressure to more than 30 mm Hg. If compartment pressure is elevated, we recommend elevation of the bitten body part in conjunction with the administration of mannitol 1~2g/kg IV over 30min and an additional four to six vials of FabAV over the course of one hour. Compartment syndrome

in patients with envenomation is thought to be caused by myonecrosis related to the action of the venom components rather than the elevated compartment pressure that causes vascular insufficiency. Thus, the most effective treatment is to neutralize the venom, which may reduce the compartment pressure. If these measures fail to reduce compartment pressure within four hours and the patient has circulatory compromise, fasciotomy may be required to lower the compartment pressure. There is some debate regarding the use of fasciotomy, and no firm evidence support its usage. It does not prevent the progression of envenomation, treat coagulopathy, or obviate the need for additional antivenom. Fasciotomy may substantially lengthen the course of treatment and may be associated with nerve damage, disfiguring scars, contractures, and loss of limb function.

- **Rhabdomyolysis.** May be a complication of compartment syndrome or caused by venom myolysins. Results in muscle pain, weakness, myoglobinuria, renal failure, and hyperkalemia. Alkalinization of urine and closely monitor urine output (ie hydration, mannitol or diuretics) is pertinent to prevent acute renal failure.

Summary

Suspected snakebites should prompt immediate first aid in field and early transportation to nearest medical facilities. Emergency physicians base on history, clinical manifestation and labo-

ratory data to confirm suspected snakebites. For dry bites or no envenomation, the patient should be observed for at least 6~12h before discharged. Extended period of observation to 12~24h is required for a coral snake. The EP should determine the severity of envenomation and predominate venom activity before decide what type of antivenin to administer, how much, and over what period. Allergic reaction is not rare in antivenin therapy.

References

1. Gold BS, ed. Current Concepts: Bites of Venomous Snakes. *NEJM* 2002;347: 347-56
2. Dart RC, ed. A Randomized Multicenter Trial of Crotalinae Polyvalent Immune Fab (Ovine) Antivenom for the Treatment for Crotaline Snakebite in the United States. *Arch Int Med* 2001;161:2030-36
3. Polly Terry. Antibiotics in non-venomous snakebite. *BMJ* 2002;19: 142
4. Polly Terry. The use of Antibiotics in venomous snakebite. *BMJ* 2002;19: 48-9
5. 毛壽先、殷鳳儀：台灣常見陸地 毒蛇簡介 台灣省立博物館印行，1990年
6. Judith E. Tintinalli. *Emergency Medicine: A Comprehensive Study Guide*. 6th edition 2004.
7. Marx, ed. *Rosen's Emergency Medicine*. 5th edition 2002.

毒蛇咬傷

翁健瑞 王宗倫

摘要

毒蛇咬傷在台灣並不少見。在台灣有23種毒蛇其中又以當中的6種最常見。一年約有300至600宗有報告的毒蛇咬傷，約有10~20的死亡個案。傳統將毒蛇的毒液區分成神經毒素及出血性毒素對臨床的診斷與處理有很大的幫助。只有少於5%發生嚴重的毒液作用。在現場的緊急處理及儘早將病人送到最近的合適醫院或有能力給予抗毒蛇血清的醫院可以大大的降低傷亡。在急診獲得的暴露史，毒液的局部及全身性症狀、表徵的進展、實驗室的數據決定了抗毒血清的使用。凝血障礙併發休克及呼吸衰竭是最常見的併發症。對可能出現的併發症及抗毒血清引發的過敏反應，予以積極的治療是治療的主要方向。(Ann Disaster Med. 2004;2 Suppl 2:S80-S88)

關鍵詞：毒蛇咬傷；抗毒蛇血清；加護治療

財團法人新光吳火獅紀念醫院急診科
抽印本索取：王宗倫 台北市士林區文昌路95號 財團法人新光吳火獅紀念醫院急診科
收件：93年2月12日 修正：93年2月27日 接受刊載：93年3月12日
電話：(02)28389425 傳真：(02)28353547 E-mail：M002183@ms.skh.org.tw