




# **USMLE Step 2**

## **Clinical Knowledge (CK)**

### *Sample Test Questions*

A Joint Program of the Federation of State Medical Boards of the United States, Inc.,  
and the National Board of Medical Examiners®



**This booklet updated July 2015.**

Copyright © 2015 by the Federation of State Medical Boards of the United States, Inc. (FSMB), and the National Board of Medical Examiners® (NBME®). All rights reserved. Printed in the United States of America. The United States Medical Licensing Examination (USMLE®) is a joint program of the FSMB and the NBME.

## CONTENTS

USMLE Step 2 CK Test Question Formats .....	3
Introduction to USMLE Step 2 CK Sample Test Questions .....	5
Normal Laboratory Values .....	6
USMLE Step 2 CK Sample Test Questions.....	8
Answer Sheet for USMLE Step 2 CK Sample Test Questions.....	52
Answer Key for USMLE Step 2 CK Sample Test Questions.....	53

# USMLE Step 2 CK Test Question Formats

## Single-Item Questions

This is the traditional, most frequently used multiple-choice format. It consists of a vignette and question followed by three to twenty-six options that are in alphabetical or logical order. The response options in this format are lettered (eg, A, B, C, D, E). You are required to select the one best answer to the question. Other options may be partially correct, but there is only ONE BEST answer.

Items with an associated abstract or pharmaceutical ad were introduced into the examination in August 2011. Each abstract or pharmaceutical ad appears as a 2- or 3-item set; there are no more than 5 of these item sets in each examination. Because item sets with an associated abstract or pharmaceutical ad may require more time to answer than traditional multiple-choice items, blocks that include these item sets contain fewer items.

### Strategies for Answering Single One-Best-Answer Questions

- Read each question carefully. It is important to understand what is being asked.
- Try to generate an answer and then look for it in the response option list.
- Alternatively, read each response option carefully, eliminating those that are clearly incorrect.
- Of the remaining response options, select the one that is most correct.
- If unsure about an answer, it is better to guess since unanswered questions are automatically counted as wrong answers.

### Example Item: Single Question

A 32-year-old woman with type 1 diabetes mellitus has had progressive renal failure over the past 2 years. She has not yet started dialysis. Examination shows no abnormalities. Her hemoglobin concentration is 9 g/dL, hematocrit is 28%, and mean corpuscular volume is 94  $\mu\text{m}^3$ . A blood smear shows normochromic, normocytic cells. Which of the following is the most likely cause?

- |                                   |                                |
|-----------------------------------|--------------------------------|
| (A) Acute blood loss              | (G) Polycythemia vera          |
| (B) Chronic lymphocytic leukemia  | (H) Sickle cell disease        |
| (C) Erythrocyte enzyme deficiency | (I) Sideroblastic anemia       |
| (D) Erythropoietin deficiency     | (J) $\beta$ -Thalassemia trait |
| (E) Immuno-hemolysis              |                                |
| (F) Microangiopathic hemolysis    |                                |

(Answer: D)

## Sequential Item Sets

A single patient-centered vignette may be associated with two or three consecutive questions about the information presented. Each question is associated with the initial patient vignette but is testing a different point. You are required to select the ONE BEST answer to each question. These questions are designed to be answered in sequential order. You must click “Proceed to Next Item” to view the next item in the set; once you click on this button, the next question will be displayed, and you will not be able to return to the previous question or change the answer to it.

### Example Items: Sequential Questions

A 35-year-old woman is brought to the emergency department because of worsening pain and swelling of her right knee for the past 2 days. She has been taking acetaminophen for the knee pain during the past 2 days, but the pain is worse today. She has not had any trauma to the knee or any previous problems with her joints. She is otherwise healthy and she currently takes an oral contraceptive. She is sexually active and has a 10-year-old son who lives with her. She is a receptionist at a local hotel and she tells you she must stand often while working. She is 160 cm (5 ft 3 in) tall and weighs 52 kg (115 lb); BMI is 20 kg/m<sup>2</sup>. Temperature is 37.9°C (98.9°F). The right knee is erythematous, swollen, and tender; there is pain on movement. No other joints are affected. X-ray of the knee shows an effusion but no structural abnormalities of the joint.

Which of the following is the most appropriate next step in diagnosis?

- (A) Arthrocentesis of the knee
- (B) Blood cultures
- (C) Complete blood count
- (D) MRI of the knee
- (E) Urine cultures

(Answer: A)

Arthrocentesis is done. The synovial fluid is cloudy. Gram stain is negative. Analysis of the synovial fluid shows a leukocyte count of 120,000/mm<sup>3</sup> and 90% neutrophils. Which of the following is the most appropriate additional test on the synovial fluid?

- (A) Culture for bacteria
- (B) Culture for fungus
- (C) Glucose measurement
- (D) Polarized light microscopy
- (E) Protein level

(Answer: A)

**NOTE:** When additional item formats are added to the examination, notice will be provided on the USMLE Web site (<http://www.usmle.org>). You must monitor the Web site to stay informed about the types of items that occur in the examination, and you must practice with the downloadable sample test items available on the USMLE Web site in order to be fully prepared for the examination.

## **Introduction to USMLE Step 2 CK Sample Test Questions**

The following pages include 141 sample test questions. Most of these questions are the same as those you can install on your computer from the USMLE Web site. Please note that reviewing the sample questions as they appear on pages 8-51 is not a substitute for practicing with the test software. You should download and run the Step 2 CK examination tutorial and practice test items that are provided on the USMLE Web site well before your test date. The sample materials available on the USMLE Web site include additional items and item formats that do not appear in this booklet, such as abstract and pharmaceutical ad item sets, items with associated audio or video findings, and sequential item sets. You should become familiar with all item formats that will be used in the actual examination.

Although the sample questions exemplify content on the examination, they may not reflect the content coverage on individual examinations. In the actual examination, questions will be presented in random order. The questions will be presented one at a time in a format designed for easy on-screen reading, including the use of exhibit buttons for some pictorials and a Normal Laboratory Values button (Table included here on pages 6–7). Photographs, charts, and x-rays in this booklet are not of the same quality as the pictorials used in the actual examination. In addition, you will be able to adjust the brightness and contrast of the computer screen.

To take the following sample test questions as they would be timed in the actual examination, you should allow a maximum of one hour for each block, for a total of four hours. Please be aware that most examinees perceive the time pressure to be greater during an actual examination. An answer form for recording answers is provided on page 52. An answer key is provided on page 53. In the actual examination, answers will be selected on the screen; no answer form will be provided.

## LABORATORY VALUES

\* Included in the Biochemical Profile (SMA-12)

	<u>REFERENCE RANGE</u>	<u>SI REFERENCE INTERVALS</u>
<b>BLOOD, PLASMA, SERUM</b>		
* Alanine aminotransferase (ALT), serum.....	8-20 U/L .....	8-20 U/L
Amylase, serum .....	25-125 U/L.....	25-125 U/L
* Aspartate aminotransferase (AST), serum .....	8-20 U/L.....	8-20 U/L
Bilirubin, serum (adult) Total // Direct .....	0.1-1.0 mg/dL // 0.0-0.3 mg/dL .....	2-17 µmol/L // 0-5 µmol/L
* Calcium, serum (Ca <sup>2+</sup> ) .....	8.4-10.2 mg/dL .....	2.1-2.8 mmol/L
* Cholesterol, serum .....	Rec:<200 mg/dL .....	<5.2 mmol/L
Cortisol, serum.....	0800 h: 5-23 µg/dL // 1600 h: 3-15 µg/dL .....	138-635 nmol/L // 82-413 nmol/L
	2000 h: ≤ 50% of 0800 h.....	Fraction of 0800 h: ≤ 0.50
Creatine kinase, serum .....	Male: 25-90 U/L .....	25-90 U/L
	Female: 10-70 U/L .....	10-70 U/L
* Creatinine, serum .....	0.6-1.2 mg/dL .....	53-106 µmol/L
Electrolytes, serum		
Sodium (Na <sup>+</sup> ) .....	136-145 mEq/L .....	136-145 mmol/L
* Potassium (K <sup>+</sup> ) .....	3.5-5.0 mEq/L .....	3.5-5.0 mmol/L
Chloride (Cl <sup>-</sup> ).....	95-105 mEq/L .....	95-105 mmol/L
Bicarbonate (HCO <sub>3</sub> <sup>-</sup> ).....	22-28 mEq/L .....	22-28 mmol/L
Magnesium (Mg <sup>2+</sup> ).....	1.5-2.0 mEq/L .....	0.75-1.0 mmol/L
Estril, total, serum (in pregnancy)		
24-28 wks // 32-36 wks.....	30-170 ng/mL // 60-280 ng/mL .....	104-590 nmol/L // 208-970 nmol/L
28-32 wks // 36-40 wks .....	40-220 ng/mL // 80-350 ng/mL .....	140-760 nmol/L // 280-1210 nmol/L
Ferritin, serum.....	Male: 15-200 ng/mL .....	15-200 µg/L
	Female: 12-150 ng/mL .....	12-150 µg/L
Follicle-stimulating hormone, serum/plasma .....	Male: 4-25 mIU/mL .....	4-25 U/L
	Female: premenopause 4-30 mIU/mL .....	4-30 U/L
	midcycle peak 10-90 mIU/mL .....	10-90 U/L
	postmenopause 40-250 mIU/mL .....	40-250 U/L
Gases, arterial blood (room air)		
pH .....	7.35-7.45 .....	[H <sup>+</sup> ] 36-44 nmol/L
PCO <sub>2</sub> .....	33-45 mm Hg .....	4.4-5.9 kPa
PO <sub>2</sub> .....	75-105 mm Hg .....	10.0-14.0 kPa
* Glucose, serum.....	Fasting: 70-110 mg/dL .....	3.8-6.1 mmol/L
	2-h postprandial: < 120 mg/dL .....	< 6.6 mmol/L
Growth hormone - arginine stimulation.....	Fasting: < 5 ng/mL .....	< 5 µg/L
	provocative stimuli: > 7 ng/mL .....	> 7 µg/L
Immunoglobulins, serum		
IgA .....	76-390 mg/dL .....	0.76-3.90 g/L
IgE .....	0-380 IU/mL .....	0-380 kIU/L
IgG .....	650-1500 mg/dL .....	6.5-15 g/L
IgM .....	40-345 mg/dL .....	0.4-3.45 g/L
Iron .....	50-170 µg/dL .....	9-30 µmol/L
Lactate dehydrogenase, serum.....	45-90 U/L.....	45-90 U/L
Luteinizing hormone, serum/plasma .....	Male: 6-23 mIU/mL .....	6-23 U/L
	Female: follicular phase 5-30 mIU/mL .....	5-30 U/L
	midcycle 75-150 mIU/mL.....	75-150 U/L
	postmenopause 30-200 mIU/mL .....	30-200 U/L
Osmolality, serum.....	275-295 mOsmol/kg H <sub>2</sub> O .....	275-295 mOsmol/kg H <sub>2</sub> O
Parathyroid hormone, serum, N-terminal .....	230-630 pg/mL .....	230-630 ng/L
* Phosphatase (alkaline), serum (p-NPP at 30°C) .....	20-70 U/L .....	20-70 U/L
* Phosphorus (inorganic), serum .....	3.0-4.5 mg/dL .....	1.0-1.5 mmol/L
Prolactin, serum (hPRL) .....	< 20 ng/mL .....	< 20 µg/L
* Proteins, serum		
Total (recumbent) .....	6.0-7.8 g/dL .....	60-78 g/L
Albumin .....	3.5-5.5 g/dL.....	35-55 g/L
Globulin .....	2.3-3.5 g/dL.....	23-35 g/L
Thyroid-stimulating hormone, serum or plasma.....	0.5-5.0 µU/mL .....	0.5-5.0 mU/L
Thyroidal iodine ( <sup>123</sup> I) uptake.....	8%-30% of administered dose/24 h .....	0.08-0.30/24 h
Thyroxine (T <sub>4</sub> ), serum.....	5-12 µg/dL .....	64-155 nmol/L
Triglycerides, serum .....	35-160 mg/dL .....	0.4-1.81 mmol/L
Triiodothyronine (T <sub>3</sub> ), serum (RIA) .....	115-190 ng/dL .....	1.8-2.9 nmol/L
Triiodothyronine (T <sub>3</sub> ) resin uptake.....	25%-35% .....	0.25-0.35
* Urea nitrogen, serum .....	7-18 mg/dL .....	1.2-3.0 mmol/L
* Uric acid, serum .....	3.0-8.2 mg/dL .....	0.18-0.48 mmol/L

LABORATORY VALUES (continued from previous page)

	<u>REFERENCE RANGE</u>	<u>SI REFERENCE INTERVALS</u>
<b>BODY MASS INDEX (BMI)</b>		
Body mass index .....	Adult: 19-25 kg/m <sup>2</sup>	
<b>CEREBROSPINAL FLUID</b>		
Cell count .....	0-5/mm <sup>3</sup>	0-5 x 10 <sup>6</sup> /L
Chloride .....	118-132 mEq/L	118-132 mmol/L
Gamma globulin .....	3%-12% total proteins	0.03-0.12
Glucose .....	40-70 mg/dL	2.2-3.9 mmol/L
Pressure .....	70-180 mm H <sub>2</sub> O	70-180 mm H <sub>2</sub> O
Proteins, total .....	<40 mg/dL	<0.40 g/L
<b>HEMATOLOGIC</b>		
Bleeding time (template) .....	2-7 minutes	2-7 minutes
Erythrocyte count .....	Male: 4.3-5.9 million/mm <sup>3</sup> Female: 3.5-5.5 million/mm <sup>3</sup>	4.3-5.9 x 10 <sup>12</sup> /L 3.5-5.5 x 10 <sup>12</sup> /L
Erythrocyte sedimentation rate (Westergren) .....	Male: 0-15 mm/h Female: 0-20 mm/h	0-15 mm/h 0-20 mm/h
Hematocrit .....	Male: 41%-53% Female: 36%-46%	0.41-0.53 0.36-0.46
Hemoglobin A <sub>1c</sub> .....	≤ 6%	≤ 0.06
Hemoglobin, blood .....	Male: 13.5-17.5 g/dL Female: 12.0-16.0 g/dL	2.09-2.71 mmol/L 1.86-2.48 mmol/L
Hemoglobin, plasma .....	1-4 mg/dL	0.16-0.62 mmol/L
Leukocyte count and differential		
Leukocyte count .....	4500-11,000/mm <sup>3</sup>	4.5-11.0 x 10 <sup>9</sup> /L
Segmented neutrophils .....	54%-62%	0.54-0.62
Bands .....	3%-5%	0.03-0.05
Eosinophils .....	1%-3%	0.01-0.03
Basophils .....	0%-0.75%	0-0.0075
Lymphocytes .....	25%-33%	0.25-0.33
Monocytes .....	3%-7%	0.03-0.07
Mean corpuscular hemoglobin .....	25.4-34.6 pg/cell	0.39-0.54 fmol/cell
Mean corpuscular hemoglobin concentration .....	31%-36% Hb/cell	4.81-5.58 mmol Hb/L
Mean corpuscular volume .....	80-100 μm <sup>3</sup>	80-100 fL
Partial thromboplastin time (activated) .....	25-40 seconds	25-40 seconds
Platelet count .....	150,000-400,000/mm <sup>3</sup>	150-400 x 10 <sup>9</sup> /L
Prothrombin time .....	11-15 seconds	11-15 seconds
Reticulocyte count .....	0.5%-1.5%	0.005-0.015
Thrombin time .....	<2 seconds deviation from control	<2 seconds deviation from control
Volume		
Plasma .....	Male: 25-43 mL/kg Female: 28-45 mL/kg	0.025-0.043 L/kg 0.028-0.045 L/kg
Red cell .....	Male: 20-36 mL/kg Female: 19-31 mL/kg	0.020-0.036 L/kg 0.019-0.031 L/kg
<b>SWEAT</b>		
Chloride .....	0-35 mmol/L	0-35 mmol/L
<b>URINE</b>		
Calcium .....	100-300 mg/24 h	2.5-7.5 mmol/24 h
Chloride .....	Varies with intake	Varies with intake
Creatinine clearance .....	Male: 97-137 mL/min Female: 88-128 mL/min	
Estriol, total (in pregnancy)		
30 wks .....	6-18 mg/24 h	21-62 μmol/24 h
35 wks .....	9-28 mg/24 h	31-97 μmol/24 h
40 wks .....	13-42 mg/24 h	45-146 μmol/24 h
17-Hydroxycorticosteroids .....	Male: 3.0-10.0 mg/24 h Female: 2.0-8.0 mg/24 h	8.2-27.6 μmol/24 h 5.5-22.0 μmol/24 h
17-Ketosteroids, total .....	Male: 8-20 mg/24 h Female: 6-15 mg/24 h	28-70 μmol/24 h 21-52 μmol/24 h
Osmolality .....	50-1400 mOsmol/kg H <sub>2</sub> O	
Oxalate .....	8-40 μg/mL	90-445 μmol/L
Potassium .....	Varies with diet	Varies with diet
Proteins, total .....	<150 mg/24 h	<0.15 g/24 h
Sodium .....	Varies with diet	Varies with diet
Uric acid .....	Varies with diet	Varies with diet



## Sample Questions

### Block 1 (Questions 1-44)

1. An 82-year-old woman with a 20-year history of urinary incontinence has had a mild exacerbation of her symptoms over the past 3 months. Urine loss generally occurs when she is carrying out daily activities such as shopping or driving and is not affected by coughing or sneezing. She underwent appendectomy at the age of 24 years. She has one daughter. She takes no medications. Pelvic examination shows an atrophic cervix without a palpable uterus or an adnexal mass. Laboratory studies show:

Hemoglobin	13 g/dL
Serum	
Na <sup>+</sup>	140 mEq/L
Cl <sup>-</sup>	105 mEq/L
K <sup>+</sup>	4.5 mEq/L
HCO <sub>3</sub> <sup>-</sup>	25 mEq/L
Urea nitrogen	15 mg/dL
Glucose	120 mg/dL
Creatinine	1.1 mg/dL
Urine	
Epithelial cells	5–10
Glucose	negative
WBC	0–1/hpf
Bacteria	occasional

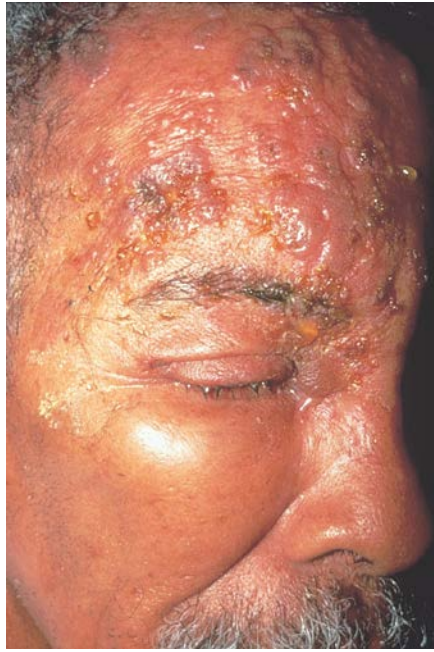Which of the following is the most likely cause of this patient's urinary incontinence?

- (A) Detrusor instability
  - (B) Hyperglycemia
  - (C) Neurogenic bladder
  - (D) Obstructive uropathy
  - (E) Urinary tract infection
2. A 30-year-old woman comes to the physician because of intermittent throbbing headaches, sweating, and pallor over the past 3 months. She has had several blood pressure measurements that fluctuate from 110/80 mm Hg to 160/108 mm Hg. Her pulse is 100/min, and blood pressure now is 138/88 mm Hg. Serum studies show:

Na <sup>+</sup>	140 mEq/L
Cl <sup>-</sup>	110 mEq/L
K <sup>+</sup>	4.5 mEq/L
HCO <sub>3</sub> <sup>-</sup>	26 mEq/L
Urea nitrogen	14 mg/dL
Creatinine	1 mg/dL

Which of the following is the most likely location of the abnormality?

- (A) Adrenal cortex
- (B) Adrenal medulla
- (C) Aorta
- (D) Renal arterioles
- (E) Renal glomeruli
- (F) Thyroid gland



3. A 56-year-old man has had the painful weeping rash shown for 2 days. He underwent chemotherapy for non-Hodgkin lymphoma 1 year ago. His temperature is 36.7°C (98°F), pulse is 80/min, and blood pressure is 138/76 mm Hg. Examination shows no other abnormalities. Which of the following is the most likely diagnosis?
- (A) Herpes zoster
  - (B) Impetigo
  - (C) Pyoderma gangrenosum
  - (D) Syphilis
  - (E) Systemic lupus erythematosus
- 
4. A 20-year-old man has had frequent upper respiratory tract infections over the past 4 years. He has daily purulent sputum and has noted decreased exercise tolerance over the past 2 years. He and his wife have been unable to conceive because of his low sperm count. Scattered expiratory wheezing and rhonchi are heard throughout both lung fields. An x-ray of the chest shows hyperinflation. Spirometry shows a decreased FEV<sub>1</sub>:FVC ratio. Which of the following is most likely to confirm the diagnosis?
- (A) Arterial blood gas analysis
  - (B) Examination of sputum for eosinophils
  - (C) Sweat chloride test
  - (D) Sputum cytology
  - (E) Bronchoscopy
5. A previously healthy 24-year-old woman comes to the physician because of a low-grade fever and a nonproductive cough for 7 days. She has been able to continue her daily activities. Her temperature is 37.7°C (99.9°F). A few scattered inspiratory crackles are heard in the thorax. An x-ray of the chest shows patchy infiltrates in both lungs. Which of the following is the most appropriate initial pharmacotherapy?
- (A) Amoxicillin
  - (B) Cefaclor
  - (C) Ciprofloxacin
  - (D) Erythromycin
  - (E) Trimethoprim-sulfamethoxazole

6. A 42-year-old woman comes to the physician for an annual pelvic examination and Pap smear. Over the past year, she has had increasing fatigue and difficulty sleeping. She has two children who both attend college. She is currently looking for part-time work outside the home. Her husband has been busy in a new start-up business. Examination shows no abnormalities. Laboratory studies show:

Hemoglobin	15 g/dL
Mean corpuscular volume	95 $\mu\text{m}^3$
Leukocyte count	6000/ $\text{mm}^3$ with a normal differential
Serum	
$\text{Na}^+$	145 mEq/L
$\text{Cl}^-$	102 mEq/L
$\text{K}^+$	4.5 mEq/L
$\text{HCO}_3^-$	25 mEq/L
Urea nitrogen	18 mg/dL
Creatinine	1.0 mg/dL
Alkaline phosphatase	70 U/L
Aspartate aminotransferase (AST, GOT)	22 U/L
Alanine aminotransferase (ALT, GPT)	19 U/L
$\gamma$ -Glutamyltransferase (GGT)	83 U/L (N=5–50 U/L)

Which of the following is the most likely explanation for this patient's laboratory abnormalities?

- (A) Acetaminophen
  - (B) Alcohol
  - (C) Diphenhydramine
  - (D) Estrogen effect
  - (E) Ibuprofen
7. A 42-year-old man comes to the physician because of malaise, muscle and joint pain, and temperatures to  $38.4^\circ\text{C}$  ( $101.1^\circ\text{F}$ ) for 3 days. Three months ago, he underwent cadaveric renal transplantation resulting in immediate kidney function. At the time of discharge, his serum creatinine concentration was 0.8 mg/dL. He is receiving cyclosporine and corticosteroids. Examination shows no abnormalities. His leukocyte count is  $2700/\text{mm}^3$ , and serum creatinine concentration is 1.6 mg/dL; serum cyclosporine concentration is in the therapeutic range. A biopsy of the transplanted kidney shows intracellular inclusion bodies. Which of the following is the most appropriate next step in management?
- (A) Increase the dosage of corticosteroids
  - (B) Increase the dosage of cyclosporine
  - (C) Begin amphotericin therapy
  - (D) Begin ganciclovir therapy
  - (E) Begin heparin therapy
8. A 62-year-old woman with ovarian cancer comes to the emergency department because of fever for 2 days. Ten days ago, she received chemotherapy with paclitaxel and carboplatin. She feels tired but has not had nausea or vomiting. Her temperature is  $39.5^\circ\text{C}$  ( $103.1^\circ\text{F}$ ), blood pressure is 100/60 mm Hg, and pulse is 115/min. The lungs are clear to auscultation. Examination shows a soft, nontender abdomen. Her hematocrit is 32%, leukocyte count is  $800/\text{mm}^3$ , and platelet count is  $105,000/\text{mm}^3$ . Serum electrolyte concentrations are within normal limits. Which of the following is the most appropriate next step in treatment?
- (A) Plasmapheresis
  - (B) Additional chemotherapy
  - (C) Intravenous antibiotic therapy
  - (D) Intravenous corticosteroid therapy
  - (E) Transfusion of 2 units of leukocytes
  - (F) Transfusion of 2 units of packed red blood cells

9. A previously healthy 34-year-old woman is brought to the physician because of fever and headache for 1 week. She has not been exposed to any disease. She takes no medications. Her temperature is 39.3°C (102.8°F), pulse is 104/min, respirations are 24/min, and blood pressure is 135/88 mm Hg. She is confused and oriented only to person. Examination shows jaundice of the skin and conjunctivae. There are a few scattered petechiae over the trunk and back. There is no lymphadenopathy. Physical and neurologic examinations show no other abnormalities. Test of the stool for occult blood is positive. Laboratory studies show:

Hematocrit	32% with fragmented and nucleated erythrocytes
Leukocyte count	12,500/mm <sup>3</sup>
Platelet count	20,000/mm <sup>3</sup>
Prothrombin time	10 sec
Partial thromboplastin time	30 sec
Fibrin split products	negative
Serum	
Urea nitrogen	35 mg/dL
Creatinine	3.0 mg/dL
Bilirubin	
Total	3.0 mg/dL
Direct	0.5 mg/dL
Lactate dehydrogenase	1000 U/L

Blood and urine cultures are negative. A CT scan of the head shows no abnormalities. Which of the following is the most likely diagnosis?

- (A) Disseminated intravascular coagulation
  - (B) Immune thrombocytopenic purpura
  - (C) Meningococcal meningitis
  - (D) Sarcoidosis
  - (E) Systemic lupus erythematosus
  - (F) Thrombotic thrombocytopenic purpura
10. A previously healthy 42-year-old man is brought to the emergency department 1 day after the sudden onset of shortness of breath and chest pain at rest; the pain is exacerbated by deep inspiration. His pulse is 100/min, respirations are 22/min, and blood pressure is 140/90 mm Hg. Breath sounds are normal. The remainder of the examination shows no abnormalities. Arterial blood gas analysis on room air shows:

pH	7.49
PCO <sub>2</sub>	30 mm Hg
PO <sub>2</sub>	64 mm Hg
O <sub>2</sub> saturation	91%

An x-ray of the chest shows no abnormalities. Which of the following is the most likely mechanism of these findings?

- (A) Carbon monoxide poisoning
- (B) Congenital heart disease
- (C) Depressed alveolar ventilation
- (D) Interstitial edema
- (E) Interstitial fibrosis
- (F) Low oxygen-carrying capacity of the blood
- (G) Ventilation-perfusion mismatch

11. A 64-year-old woman comes to the physician because of a 5-month history of increasing shortness of breath, sore throat, and a cough productive of a small amount of white phlegm. Over the past week, she has had nausea related to excess coughing. Over the past year, she has had a 3.2-kg (7-lb) weight loss. She has asthma treated with theophylline and inhaled  $\beta$ -adrenergic agonists and corticosteroids. She has smoked one pack of cigarettes daily for 44 years and drinks one alcoholic beverage daily. She appears thin. Examination shows a 2-cm, nontender lymph node in the right supraclavicular area. Examination shows no other abnormalities. An x-ray of the chest shows a large right lower lobe density. A CT scan of the chest shows a 7.5 x 7.5 x 6-cm right lower lobe mass with some scattered calcifications. The lesion abuts the posterior chest wall without clear invasion. There are right lower peritracheal, precarinal, right hilar, and subcarinal lymph nodes. There is a 1.5-cm mass in the right adrenal gland. A biopsy specimen of the lung mass is most likely to show which of the following?
- (A) B-cell lymphoma
  - (B) Lung abscess
  - (C) Mesothelioma
  - (D) Metastatic adenocarcinoma of the breast
  - (E) Multiple endocrine neoplasia
  - (F) Non-small cell lung carcinoma
  - (G) Sarcoidosis
  - (H) Tuberculosis
12. A previously healthy 20-year-old college student comes to the emergency department because she has been unable to urinate for 8 hours. She has a 2-day history of fever, fatigue, severe burning with urination, and pain in the genital area. She is sexually active and uses a diaphragm for contraception. She takes no medications. She appears uncomfortable. Her temperature is 38.7°C (101.7°F), pulse is 110/min, and blood pressure is 110/70 mm Hg. Abdominal examination shows a large, cystic, midline pelvic mass. The groin nodes are enlarged and tender. Pelvic examination shows erythematous external genitalia with extensive ulceration. The lesions extend into the vagina. Internal examination is not possible due to patient discomfort. Which of the following is the most appropriate initial step in management?
- (A) Measurement of serum urea nitrogen concentration
  - (B) Vaginal cultures
  - (C) Intravenous pyelography
  - (D) Renal ultrasonography
  - (E) Placement of a Foley catheter
13. A 9-year-old boy is brought to the physician because of progressive weakness and a purple-red discoloration over his cheeks and upper eyelids over the past 8 weeks. His symptoms began shortly after a camping trip, and he now is unable to climb stairs, walk long distances, comb his hair, or dress himself. His mother says that she was careful to apply his sunscreen on the trip and can recall no tick bites or exposure to poisonous plants. His only medication is a topical corticosteroid for several dry, scaly patches of the skin. He appears weak and lethargic. He is at the 75th percentile for height and 25th percentile for weight; he has had no change in his weight since his last examination 9 months ago. His temperature is 37.7°C (99.8°F), blood pressure is 110/68 mm Hg, pulse is 105/min, and respirations are 28/min. Examination of the skin shows a purple-red discoloration over the cheeks and eyelids, periorbital edema, erythematous plaques and scales over the elbows and knees, and flat-topped red papules over all knuckles. There is generalized weakness and atrophy of the proximal muscles. Which of the following is the most likely diagnosis?
- (A) Dermatomyositis
  - (B) Duchenne's muscular dystrophy
  - (C) Eczema
  - (D) Lyme disease
  - (E) Psoriasis
  - (F) Rocky Mountain spotted fever
  - (G) Seborrhea
  - (H) Systemic lupus erythematosus

14. A 37-year-old woman, gravida 5, para 4, at 34 weeks' gestation comes to the emergency department because of vaginal bleeding for 2 hours. She has had no prenatal care. Her second child was delivered by lower segment transverse cesarean section because of a nonreassuring fetal heart rate; her other three children were delivered vaginally. Her pulse is 92/min, respirations are 18/min, and blood pressure is 134/76 mm Hg. The abdomen is nontender, and no contractions are felt. There is blood on the vulva, the introitus, and on the medial aspect of each thigh. The fetus is in a transverse lie presentation. The fetal heart rate is 144/min. Which of the following is the most likely diagnosis?
- (A) Abruptio placentae
  - (B) Amniotic fluid embolism
  - (C) Latent phase of labor
  - (D) Placenta previa
  - (E) Ruptured uterus
  - (F) Ruptured vasa previa
15. A 4080-g (9-lb) male newborn is delivered at term to a 32-year-old woman, gravida 2, para 1. Apgar scores are 8 and 9 at 1 and 5 minutes, respectively. Examination in the delivery room shows fracture of the right clavicle. Which of the following is the most likely sequela of this condition?
- (A) Correction only with casting
  - (B) Correction only with physical therapy
  - (C) Left-hand dominance
  - (D) Permanent nerve damage
  - (E) Spontaneous healing without treatment
16. A healthy 4-year-old girl is brought for a well-child examination. A grade 2/6 systolic ejection murmur is heard along the upper left sternal border.  $S_2$  is widely split and does not vary with respiration. A soft mid-diastolic murmur is heard along the lower left sternal border. Examination shows no other abnormalities. Which of the following is the most likely diagnosis?
- (A) Aortic stenosis
  - (B) Atrial septal defect
  - (C) Coarctation of the aorta
  - (D) Mitral valve prolapse
  - (E) Patent ductus arteriosus
  - (F) Pulmonary stenosis
  - (G) Tetralogy of Fallot
  - (H) Transposition of the great arteries
  - (I) Ventricular septal defect
  - (J) Normal heart
17. A previously healthy 14-year-old girl is brought to the physician because of a 2-day history of fever and pain and swelling of the right knee. She remembers injuring the knee while playing soccer last week, but she was able to finish the game. She has no history of rash or joint pain. Her sister has inflammatory bowel disease. The patient's temperature is 39°C (102.2°F), blood pressure is 110/80 mm Hg, pulse is 95/min, and respirations are 20/min. Examination of the right knee shows swelling, tenderness, warmth, and erythema; range of motion is limited. Which of the following is the most appropriate next step in management?
- (A) X-ray of the right knee
  - (B) Gastrointestinal series with small-bowel follow-through
  - (C) Nuclear scan of the right knee
  - (D) MRI of the right knee
  - (E) Antibiotic therapy
  - (F) Arthrocentesis

18. A 3-year-old girl is brought to the physician because of fever and left ear pain for 3 days. She has been treated with amoxicillin for the past 5 days for left otitis media. Her temperature is 38.5°C (101.3°F), pulse is 100/min, respirations are 20/min, and blood pressure is 80/60 mm Hg. Examination shows the left ear displaced forward and laterally from the head. There is edema and tenderness behind the left ear. Otoscopic examination shows a red, dull, left tympanic membrane that does not move. Which of the following is the most likely diagnosis?
- (A) Acoustic neuroma
  - (B) Labyrinthitis
  - (C) Lateral sinus thrombosis
  - (D) Mastoiditis
  - (E) Rhabdomyosarcoma
19. A 15-year-old girl is brought to the physician 3 months after she had a blood pressure of 150/95 mm Hg at a routine examination prior to participation in school sports. She is asymptomatic and has no history of serious illness. Twelve months ago, she was diagnosed with a urinary tract infection and treated with oral trimethoprim-sulfamethoxazole. She currently takes no medications. Subsequent blood pressure measurements on three separate occasions since the last visit have been: 155/94 mm Hg, 145/90 mm Hg, and 150/92 mm Hg. She is at the 50th percentile for height and 95th percentile for weight. Her blood pressure today is 150/90 mm Hg confirmed by a second measurement, pulse is 80/min, and respirations are 12/min. Examination shows no other abnormalities. Her hematocrit is 40%. Urinalysis is within normal limits. Cardiac and renal ultrasonography shows no abnormalities. Which of the following is the most appropriate next step in management?
- (A) Exercise and weight reduction program
  - (B) Measurement of urine catecholamine concentrations
  - (C) Measurement of urine corticosteroid concentrations
  - (D) Captopril therapy
  - (E) Hydrochlorothiazide therapy
20. A 72-year-old woman with unresectable small cell carcinoma of the lung is brought to the emergency department after her family found her unresponsive. During the past week, she has become progressively confused. On arrival, she does not respond to command but withdraws all extremities to pain. Her temperature is 37°C (98.6°F), pulse is 80/min, respirations are 12/min, and blood pressure is 130/70 mm Hg. The pupils are equal and reactive to light, and corneal reflexes are brisk; there is spontaneous medial and lateral gaze. Laboratory studies show:

Hemoglobin	12.2 g/dL
Leukocyte count	6000/mm <sup>3</sup>
Serum	
Na <sup>+</sup>	118 mEq/L
Cl <sup>-</sup>	98 mEq/L
K <sup>+</sup>	4.5 mEq/L
HCO <sub>3</sub> <sup>-</sup>	26 mEq/L
Urea nitrogen	16 mg/dL
Glucose	95 mg/dL
Creatinine	0.8 mg/dL

Which of the following is the most likely mechanism of these findings?

- (A) Adrenal insufficiency
- (B) Inadequate renal blood flow
- (C) Injury to the renal tubules
- (D) Nonphysiologic ADH (vasopressin) secretion
- (E) Nonphysiologic aldosterone secretion
- (F) Physiologic ADH (vasopressin) secretion
- (G) Physiologic aldosterone secretion

21. A 52-year-old woman comes to the emergency department because of a 1-week history of low-grade fever and increasing abdominal cramps that are exacerbated by bowel movements. She began a course of amoxicillin-clavulanate and metronidazole 2 days ago but has had no relief of her symptoms. She has had intermittent constipation for the past 12 years. She has not had nausea, vomiting, urinary symptoms, or bloody stools. She has a 3-year history of hypertension. She underwent total abdominal hysterectomy and bilateral salpingo-oophorectomy 5 years ago because of leiomyomata uteri. She is 165 cm (5 ft 5 in) tall and weighs 86 kg (190 lb); BMI is 32 kg/m<sup>2</sup>. Her temperature is 38.1°C (100.6°F), pulse is 75/min, and blood pressure is 150/80 mm Hg. The lungs are clear to auscultation. Cardiac examination shows no abnormalities. The abdomen is soft, and there is tenderness to palpation of the left lower quadrant with guarding but no rebound. Bowel sounds are normal. The stool is brown, and test for occult blood is negative. Her hemoglobin concentration is 14.5 g/dL, leukocyte count is 15,000/mm<sup>3</sup>, and platelet count is 280,000/mm<sup>3</sup>; serum studies and urinalysis show no abnormalities. Which of the following is the most appropriate next step in diagnosis?
- (A) Examination of the stool for ova and parasites
  - (B) Test of the stool for *Clostridium difficile* toxin
  - (C) Endoscopic retrograde cholangiopancreatography
  - (D) Pelvic ultrasonography
  - (E) CT scan of the abdomen with contrast
  - (F) Colonoscopy
22. A 22-year-old man comes to the physician for a routine health maintenance examination. He feels well. He has had a painless left scrotal mass since childhood. Examination shows a 6-cm, soft, nontender left scrotal mass that transilluminates; there are no bowel sounds in the mass. Examination of the testis shows no abnormalities. Which of the following is the most likely cause of the mass?
- (A) Accumulation of scrotal adipose tissue
  - (B) Cryptorchidism of the left testis
  - (C) Dilation of the pampiniform plexus of veins around the testis
  - (D) Persistence of a patent processus vaginalis
  - (E) Torsion of the left testis
23. A 27-year-old nulligravid woman comes to the physician because of a 1-year history of irregular heavy menstrual bleeding. She has been otherwise healthy. Menses occur at irregular 15- to 45-day intervals and last 3 to 7 days; menses had previously occurred at regular 28-day intervals with moderate flow. Her last menstrual period was 4 weeks ago. She is sexually active and does not use contraception. Her temperature is 37°C (98.6°F), pulse is 80/min, respirations are 20/min, and blood pressure is 120/80 mm Hg. Physical examination shows no abnormalities. Pelvic examination shows clear cervical mucus. Serum studies show:
- |                              |  |
|------------------------------|--|
| Thyroid-stimulating hormone  | 3 µU/mL  |
| Follicle-stimulating hormone | 5 mIU/mL   |
| Prolactin                    | 18 ng/mL   |
| Progesterone                 | 0.5 ng/mL (menstrual cycle day 30: follicular N<3; luteal N>3–5) |
- Pelvic ultrasonography shows no abnormalities. Which of the following is the most likely diagnosis?
- (A) Adenomyosis
  - (B) Anovulation
  - (C) Endometrial polyp
  - (D) Leiomyoma uteri
  - (E) Pregnancy



24. A 47-year-old woman with end-stage renal disease comes to the physician because of increased shortness of breath since her last hemodialysis 2 days ago. Her pulse is 88/min and regular, respirations are 26/min and slightly labored, and blood pressure is 176/110 mm Hg. Examination shows jugular venous distention and pitting edema below the knees. Diffuse crackles are heard. Cardiac examination shows no murmurs, rubs, or gallops. Laboratory studies show:

Serum	
Na <sup>+</sup>	138 mEq/L
Cl <sup>-</sup>	100 mEq/L

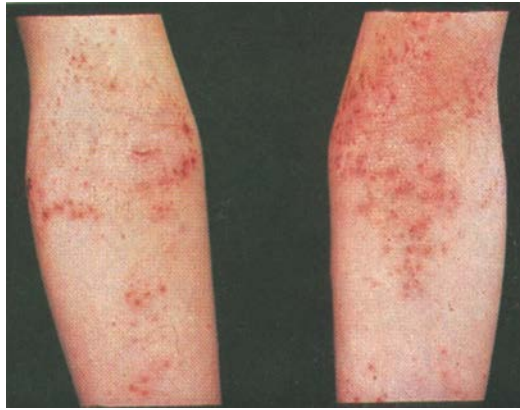Arterial blood gas analysis on room air:

pH	7.30
PCO <sub>2</sub>	28 mm Hg
PO <sub>2</sub>	88 mm Hg
HCO <sub>3</sub> <sup>-</sup>	14 mEq/L

Which of the following is the most likely acid-base status of this patient?

- (A) Metabolic acidosis, respiratory compensation
  - (B) Metabolic acidosis, uncompensated
  - (C) Metabolic alkalosis, respiratory compensation
  - (D) Metabolic alkalosis, uncompensated
  - (E) Respiratory acidosis, renal compensation
  - (F) Respiratory acidosis, uncompensated
  - (G) Respiratory alkalosis, renal compensation
  - (H) Respiratory alkalosis, uncompensated
  - (I) Normal acid-base balance
25. A 21-year-old woman comes to the physician for preconceptional advice. She is recently married and would like to conceive within the next year. She does not eat meat, fish, or dairy products and wishes to decrease the risks of her diet on her baby. Menses occur at regular 28-day intervals and last 5 days. She does not smoke or drink alcohol. She takes no medications. She is 157 cm (5 ft 2 in) tall and weighs 50 kg (110 lb); BMI is 20 kg/m<sup>2</sup>. Physical examination shows no abnormalities. Pelvic examination shows a normal appearing vagina, cervix, uterus, and adnexa. Which of the following is most likely to decrease the risk of fetal anomalies in this patient?
- (A) Adjusting diet to include more sources of protein during the first trimester
  - (B) Beginning folic acid supplementation prior to conception
  - (C) Calcium supplementation during the first trimester
  - (D) Iron supplementation during the first trimester
  - (E) Soy protein shakes throughout pregnancy and lactation
26. A previously healthy 15-year-old boy is brought to the emergency department in August 1 hour after the onset of headache, dizziness, nausea, and one episode of vomiting. His symptoms began during the first hour of full-contact football practice in full uniform. He reported feeling weak and faint but did not lose consciousness. He vomited once after drinking water. On arrival, he is diaphoretic. He is not oriented to person, place, or time. His temperature is 39.5°C (103.1°F), pulse is 120/min, respirations are 40/min, and blood pressure is 90/65 mm Hg. Examination, including neurologic examination, shows no other abnormalities. Which of the following is the most appropriate next step in management?
- (A) Obtain a CT scan of the head
  - (B) Administer sodium chloride tablets
  - (C) Administer intravenous fluids
  - (D) Immerse the patient in an ice water bath
  - (E) Obtain a lumbar puncture

27. A 27-year-old woman comes to the physician for a follow-up examination. She has a 10-week history of persistent nonproductive cough that is worse at night and a 1-month history of a hoarse voice. She otherwise feels well. She has not had loss of appetite or change in exercise tolerance. She has never smoked. Empiric treatment with an oral decongestant and albuterol inhaler has not improved her symptoms. She has no history of serious illness. Her temperature is 37°C (98.6°F), pulse is 68/min, respirations are 12/min, and blood pressure is 110/76 mm Hg. Cardiopulmonary examination and an x-ray of the chest show no abnormalities. Her FEV<sub>1</sub> is normal. Which of the following is the most appropriate next step in management?
- (A) 24-Hour monitoring of esophageal pH
  - (B) Echocardiography
  - (C) CT scan of the chest
  - (D) Inhaled corticosteroid therapy
  - (E) Nitroglycerin therapy
28. A 36-year-old nulligravid woman with primary infertility comes for a follow-up examination. She has been unable to conceive for 10 years; analysis of her husband's semen during this period has shown normal sperm counts. Menses occur at regular 28-day intervals and last 5 to 6 days. She is asymptomatic except for severe dysmenorrhea. An endometrial biopsy specimen 5 days before menses shows secretory endometrium. Hysterosalpingography 1 year ago showed normal findings. Pelvic examination shows a normal vagina and cervix. Bimanual examination shows a normal-sized uterus and no palpable adnexal masses. Rectal examination is unremarkable. Which of the following is the most likely diagnosis?
- (A) Anovulation
  - (B) Endometriosis
  - (C) Intrauterine synechiae
  - (D) Male factor
  - (E) Tubal obstruction
29. A 5-year-old boy is brought to the physician by his mother because of a 2-day history of a low-grade fever, cough, and runny nose. His temperature is 38°C (100.4°F). Examination findings are consistent with a diagnosis of a common cold. The physician refers to a randomized, double-blind, placebo-controlled clinical trial that evaluated the effectiveness of a new drug for the treatment of the common cold. The mean time for resolution of symptoms for patients receiving the new drug was 6.4 days, compared with a mean time of 6.7 days for patients receiving the placebo ( $p=0.04$ ). Which of the following is the most appropriate interpretation of these study results?
- (A) The findings are clinically and statistically significant
  - (B) The findings are clinically insignificant but statistically significant
  - (C) The findings are clinically significant but statistically insignificant
  - (D) The findings are neither clinically nor statistically significant
30. A 25-year-old woman comes to the physician because of a 2-month history of numbness in her right hand. During this period, she has had tingling in the right ring and small fingers most of the time. She has no history of serious illness and takes no medications. She is employed as a cashier and uses a computer at home. She played as a pitcher in a softball league for 5 years until she stopped 2 years ago. Vital signs are within normal limits. Examination shows full muscle strength. Palpation of the right elbow produces a jolt of severe pain in the right ring and small fingers. Sensation to pinprick and light touch is decreased over the medial half of the right ring finger and the entire small finger. The most likely cause of these findings is entrapment of which of the following on the right?
- (A) Brachial plexus at the axilla
  - (B) Median nerve at the wrist
  - (C) Musculocutaneous nerve at the forearm
  - (D) Radial nerve at the forearm
  - (E) Ulnar nerve at the elbow



31. A 6-year-old girl is brought to the physician because of a 1-month history of a recurrent pruritic rash on her arms. She was born at term and has been healthy except for an episode of bronchiolitis 6 months ago treated with albuterol. A photograph of the rash is shown. Which of the following is the most appropriate next step in management?
- (A) Coal tar therapy
  - (B) Oral antibiotic therapy
  - (C) Topical antibiotic therapy
  - (D) Topical corticosteroid therapy
  - (E) Vitamin supplementation
- 
32. A 37-year-old man with type 1 diabetes mellitus is admitted to the hospital because of inadequate control of his glucose concentrations for the past 2 months. Despite his poor control, he demands that he be discharged. He reports that he has had a 3-month history of fatigue, irritability, and feelings of hopelessness. He says that he has been noncompliant with his diabetic regimen, adding, "Sometimes I forget." He has been avoiding his family and friends because he is not in the mood to see them but admits that he is lonely. He did not get out of bed for 2 days, which prompted his wife to call an ambulance and have him admitted to the hospital. Prior to admission to the hospital, his only medication was insulin, although he often missed doses. He does not drink alcohol. He is 168 cm (5 ft 6 in) tall and weighs 100 kg (220 lb); BMI is 36 kg/m<sup>2</sup>. His temperature is 37°C (98.6°F), pulse is 68/min, respirations are 18/min, and blood pressure is 150/85 mm Hg. Physical examination shows no abnormalities. On mental status examination, he is tired and has a restricted affect. There is no evidence of suicidal ideation. Cognition is intact. His fasting serum glucose concentration is 120 mg/dL. Which of the following is the most appropriate next step in management?
- (A) Adhere to the patient's wishes and discuss home-care options
  - (B) Adhere to the patient's wishes on the condition that he agree to home nursing care
  - (C) Schedule neuropsychological testing
  - (D) Seek a court order to appoint a legal guardian
  - (E) Involuntarily hold the patient in the hospital
33. A previously healthy 37-year-old woman comes to the physician because of a 3-month history of episodes of severe anxiety, shortness of breath, palpitations, and numbness in her hands and feet. Her vital signs are within normal limits. Physical examination shows no abnormalities. Thyroid function studies and an ECG show no abnormalities. Which of the following is the most appropriate pharmacotherapy?
- (A) Lithium carbonate
  - (B) Methylphenidate
  - (C) Olanzapine
  - (D) Paroxetine
  - (E) Valproic acid

34. A study is conducted to assess the effectiveness of a new drug for the treatment of type 2 diabetes mellitus. A total of 1000 patients with type 2 diabetes mellitus are enrolled. Patients are randomly assigned to receive the new drug or standard treatment. The alpha and beta values for calculating probability are 0.05 and 0.20, respectively. Results show that the new drug is significantly better than standard treatment. If this study had been performed in a population of only 500 patients, which of the following would have been most likely to increase?
- (A) Chance of a type I error
  - (B) Chance of a type II error
  - (C) Power of the study
  - (D) Sensitivity of the study
  - (E) Specificity of the study
35. A 22-year-old man with a seizure disorder has had increasing cough and shortness of breath for 3 days and fever for 1 day. He has foul-smelling sputum. He had a generalized tonic-clonic seizure 1 week ago. His temperature is 39.4°C (103°F). Crackles are heard on auscultation of the chest. An x-ray of the chest shows a right upper-lobe infiltrate of the lung. Which of the following is the most likely cause?
- (A) Chemical pneumonitis
  - (B) Pneumonia secondary to anaerobes
  - (C) Pneumonia secondary to gram-negative aerobes
  - (D) Pneumonia secondary to gram-positive aerobes
  - (E) Pneumonia secondary to *Mycoplasma pneumoniae*
36. A 62-year-old man comes to the physician because of a 2-month history of progressive fatigue and ankle swelling. He had an anterior myocardial infarction 3 years ago and has had shortness of breath with mild exertion since then. Current medications include labetalol and daily aspirin. He has smoked one-half pack of cigarettes daily for 30 years. His pulse is 100/min and regular, respirations are 20/min, and blood pressure is 130/75 mm Hg. There are jugular venous pulsations 5 cm above the sternal angle. Crackles are heard at both lung bases. Cardiac examination shows an S<sub>3</sub> gallop. There is edema from the midtibia to the ankle bilaterally. Further evaluation of this patient is most likely to show which of the following findings?
- (A) Decreased pulmonary capillary wedge pressure
  - (B) Impaired contractility of the left ventricle
  - (C) Prolapse of the mitral valve
  - (D) Thrombosis of the superior vena cava
  - (E) Ventricular septal defect
37. A 72-year-old woman with advanced ovarian cancer metastatic to the liver is brought to the physician by her son because she cries all the time and will not get out of bed. On a 10-point scale, she rates the pain as a 1 to 2. She also has hypertension and major depressive disorder. She has received chemotherapy for 2 years. Current medications also include oxycodone (10 mg twice daily), hydrochlorothiazide (25 mg/d), and fluoxetine (20 mg/d). She is 165 cm (5 ft 5 in) tall and weighs 66 kg (145 lb); BMI is 24 kg/m<sup>2</sup>. Her temperature is 37°C (98.6°F), pulse is 110/min, respirations are 12/min, and blood pressure is 120/80 mm Hg. Examination shows a firm, distended abdomen with moderate tenderness over the liver. On mental status examination, she is oriented to person, place, and time. She has good eye contact but appears sad and cries easily. Which of the following is the most appropriate next step in management?
- (A) Reassurance
  - (B) Assess for suicidal ideation
  - (C) Begin dextroamphetamine therapy
  - (D) Increase oxycodone dosage
  - (E) Restart chemotherapy

38. A 42-year-old woman comes to the physician because of a 1-year history of vaginal bleeding for 2 to 5 days every 2 weeks. The flow varies from light to heavy with passage of clots. Menses previously occurred at regular 25- to 29-day intervals and lasted for 5 days with normal flow. She has no history of serious illness and takes no medications. She is sexually active with one male partner, and they use condoms inconsistently. Her mother died of colon cancer, and her maternal grandmother died of breast cancer. She is 163 cm (5 ft 4 in) tall and weighs 77 kg (170 lb); BMI is 29 kg/m<sup>2</sup>. Her temperature is 36.6°C (97.8°F), pulse is 90/min, respirations are 12/min, and blood pressure is 100/60 mm Hg. The uterus is normal sized. The ovaries cannot be palpated. The remainder of the examination shows no abnormalities. Test of the stool for occult blood is negative. Which of the following is the most appropriate next step in diagnosis?
- (A) Barium enema
  - (B) Progesterone challenge test
  - (C) Colposcopy
  - (D) Cystoscopy
  - (E) Endometrial biopsy
39. A 5-year-old girl is brought to the physician by her parents for evaluation of recurrent injuries. Her parents say that she started walking at the age of 14 months and since then has always seemed clumsier and had more injuries than other children. She has had increasingly frequent chest pain with exertion since starting a soccer program 3 months ago. She usually has pain or swelling of her knees or ankles after practice. She has been wearing glasses for 2 years. Her 16-year-old brother has required two operations for a severe rotator cuff injury he sustained while taking a shower, and she has a maternal cousin who died of a ruptured aortic aneurysm at the age of 26 years. Today, the patient walks with a limp. She is at the 99th percentile for height and 50th percentile for weight. A midsystolic click is heard at the apex. The left ankle is swollen and tender; range of motion is limited by pain. The joints of the upper and lower extremities are hypermobile, including 25 degrees of genu recurvatum, thumbs that may be extended to touch the forearms, and flexibility at the waist, with palms easily touching the floor with straight knees. Which of the following is the most appropriate next step in diagnosis?
- (A) Skeletal survey
  - (B) Echocardiography
  - (C) Bone scan
  - (D) MRI of the shoulder
  - (E) Aortic angiography
40. A 47-year-old man comes to the physician 12 hours after the sudden onset of a severe occipital headache and stiff neck. He has not had any other symptoms and has no history of severe headache. He has hypertension and gastroesophageal reflux disease. Current medications include hydrochlorothiazide and ranitidine. He is oriented to person, place, and time. His temperature is 36.7°C (98.1°F), pulse is 100/min, and blood pressure is 160/90 mm Hg. Range of motion of the neck is decreased due to pain. Neurologic examination shows no focal findings. Which of the following is the most likely diagnosis?
- (A) Cluster headache
  - (B) Meningitis
  - (C) Migraine
  - (D) Subarachnoid hemorrhage
  - (E) Tension-type headache
41. A 19-year-old woman noticed a mass in her left breast 2 weeks ago while doing monthly breast self-examination. Her mother died of metastatic breast cancer at the age of 40 years. Examination shows large dense breasts; a 2-cm, firm, mobile mass is palpated in the upper outer quadrant of the left breast. There are no changes in the skin or nipple, and there is no palpable axillary adenopathy. Which of the following is the most likely diagnosis?
- (A) Fibroadenoma
  - (B) Fibrocystic changes of the breast
  - (C) Infiltrating ductal carcinoma
  - (D) Intraductal papilloma
  - (E) Lobular carcinoma

42. A 22-year-old woman comes to the physician in October for a follow-up examination. She feels well. She has a 2-year history of type 1 diabetes mellitus controlled with insulin. She had a normal Pap smear 3 months ago and saw her ophthalmologist 6 months ago. Her 67-year-old grandmother has breast cancer. She is 168 cm (5 ft 6 in) tall and weighs 57 kg (125 lb); BMI is 20 kg/m<sup>2</sup>. Her hemoglobin A<sub>1c</sub> is 6.2%, and fingerstick blood glucose concentration is 118 mg/dL. Which of the following health maintenance recommendations is most appropriate at this time?
- (A) Begin running for exercise
  - (B) Dietary modification for weight loss
  - (C) Human papillomavirus testing
  - (D) Mammography
  - (E) Influenza virus vaccine
  - (F) Supplementation with vitamins C and D
43. A 27-year-old woman, gravida 2, para 1, at 12 weeks' gestation comes to the physician for a prenatal visit. She feels well. Pregnancy and delivery of her first child were uncomplicated. Medications include folic acid and a multivitamin. Her temperature is 37.2°C (99°F), and blood pressure is 108/60 mm Hg. Pelvic examination shows a uterus consistent in size with a 12-week gestation. Urine dipstick shows leukocyte esterase; urinalysis shows WBCs and rare gram-negative rods. Which of the following is the most appropriate next step in management?
- (A) Recommend drinking 8 oz of cranberry juice daily
  - (B) Oral amoxicillin therapy
  - (C) Oral metronidazole therapy
  - (D) Intravenous cefazolin therapy
  - (E) Intravenous pyelography
  - (F) Cystoscopy
44. An 18-year-old man with a 12-year history of type 1 diabetes mellitus comes to the physician for a follow-up examination. Medications include 25 U of NPH insulin and 10 U of regular insulin in the morning and 10 U of NPH insulin and 10 U of regular insulin before dinner. His hemoglobin A<sub>1c</sub> was 14.5% 12 weeks ago. His current pulse is 80/min, respirations are 20/min, and blood pressure is 145/95 mm Hg. Examination shows scattered retinal microaneurysms bilaterally. The remainder of the examination shows no other abnormalities. Laboratory studies show:

Hemoglobin A <sub>1c</sub>	13%
Serum	
Na <sup>+</sup>	130 mEq/L
K <sup>+</sup>	3.2 mEq/L
Cl <sup>-</sup>	101 mEq/L
HCO <sub>3</sub> <sup>-</sup>	23 mEq/L
Glucose	325 mg/dL
Creatinine	1.5 mg/dL
Cholesterol	350 mg/dL
Urine	
Blood	negative
Glucose	4+
Protein	1+
Ketones	negative

Which of the following is the most likely renal diagnosis?

- (A) Cholesterol renal emboli
- (B) Diabetic nephropathy
- (C) Hypertensive glomerulosclerosis
- (D) Hypokalemic nephropathy
- (E) Sodium-losing nephropathy

## Sample Questions

### Block 2 (Questions 45-86)

45. An 18-year-old primigravid woman comes for her initial prenatal visit at 16 weeks' gestation. She is not sure about the date of her last menstrual period but says that the pregnancy probably occurred immediately after she stopped taking oral contraceptives 5 months ago. Maternal serum  $\alpha$ -fetoprotein (MSAFP) concentration is increased to 3 multiples of the median. Which of the following is the most appropriate next step in management?

- (A) Repeat measurement of MSAFP concentration
- (B) Triple screening for MSAFP, serum  $\beta$ -hCG, and serum estriol concentrations
- (C) Ultrasonography
- (D) Amniocentesis for measurement of  $\alpha$ -fetoprotein concentration
- (E) Amniocentesis for chromosomal analysis

46. A 19-year-old man comes to the physician because of a 3-week history of malaise, generalized fatigue, swelling of his legs, and dark urine. He has no known sick contacts. There is no personal or family history of serious illness. He takes no medications. His temperature is 37°C (98.6°F), pulse is 82/min, respirations are 14/min, and blood pressure is 152/91 mm Hg. Examination shows 2+ pretibial edema bilaterally. The remainder of the examination shows no abnormalities. Laboratory studies show:

Hemoglobin	10.4 g/dL
Leukocyte count	5000/mm <sup>3</sup>
Platelet count	250,000/mm <sup>3</sup>
Serum	
Na <sup>+</sup>	135 mEq/L
K <sup>+</sup>	4.9 mEq/L
Cl <sup>-</sup>	101 mEq/L
HCO <sub>3</sub> <sup>-</sup>	19 mEq/L
Urea nitrogen	68 mg/dL
Creatinine	4.6 mg/dL
Urine	
Blood	3+
Protein	3+
RBC	5–7/hpf with dysmorphic features
RBC casts	numerous

Serum complement concentrations are within the reference ranges. Renal ultrasonography shows no abnormalities. A renal biopsy specimen shows a crescent formation in the glomeruli and immune complex deposition along the basement membrane. The most appropriate next step in management is administration of which of the following?

- (A) Oral azathioprine
- (B) Oral lisinopril
- (C) Intravenous fluids
- (D) Intravenous furosemide
- (E) Intravenous methylprednisolone

47. A sexually active 20-year-old woman has had fever, chills, malaise, and pain of the vulva for 2 days. Examination shows a vulvar pustule that has ulcerated and formed multiple satellite lesions. Nodes are palpated in the inguinal and femoral areas. A smear of fluid from the lesions establishes the diagnosis. Which of the following is the most likely causal organism?

- (A) *Chlamydia trachomatis*
- (B) *Haemophilus ducreyi*
- (C) *Neisseria gonorrhoeae*
- (D) *Streptococcus pyogenes* (group A)
- (E) *Treponema pallidum*

48. A 17-year-old girl comes to the physician for an examination prior to entering college. She reports that she feels well but is nervous about leaving home for the first time. She states that she has tried to diet to improve her appearance but that food restriction often "backfires" because she becomes hungry and then engages in episodes of binge eating. She reports a loss of control during these episodes, saying "It's like I stop thinking at all and before I know it, I have eaten two pizzas." She induces vomiting several times during each binge and has developed a pattern of bingeing and purging every evening. She has no history of serious illness and takes no medications. She is 165 cm (5 ft 5 in) tall and weighs 57 kg (125 lb); BMI is 21 kg/m<sup>2</sup>. Vital signs are within normal limits. Physical examination shows dry mucous membranes, erosion of enamel on the lingual surface of the front teeth, and hypertrophy of the parotid gland. Serum studies are most likely to show which of the following sets of findings in this patient?

	Potassium	Bicarbonate
(A)	Decreased	decreased
(B)	Decreased	increased
(C)	Increased	decreased
(D)	Increased	increased
(E)	Normal	decreased
(F)	Normal	increased

49. A 52-year-old woman has had dyspnea and hemoptysis for 1 month. She has a history of rheumatic fever as a child and has had a cardiac murmur since early adulthood. Her temperature is 36.7°C (98°F), pulse is 130/min and irregularly irregular, respirations are 20/min, and blood pressure is 98/60 mm Hg. Jugular venous pressure is not increased. Bilateral crackles are heard at the lung bases. There is an opening snap followed by a low-pitched diastolic murmur at the third left intercostal space. An x-ray of the chest shows left atrial enlargement, a straight left cardiac border, and pulmonary venous engorgement. Which of the following is the most likely explanation for these findings?

- (A) Aortic valve insufficiency
- (B) Aortic valve stenosis
- (C) Mitral valve insufficiency
- (D) Mitral valve stenosis
- (E) Tricuspid valve insufficiency

50. A 2-month-old boy is brought to the physician because of a 6-week history of persistent diarrhea and vomiting, most pronounced after formula feedings. He has had a 113-g (4-oz) weight loss since birth. He currently weighs 3100 g (6 lb 13 oz) and is 51 cm (20 in) in length. He appears irritable. Examination shows jaundice. The lungs are clear to auscultation. No murmurs are heard. The liver is palpated 2 to 3 cm below the right costal margin, and the spleen is palpated 1 to 2 cm below the left costal margin. Laboratory studies show:

Serum	
Glucose	35 mg/dL
Bilirubin (total)	2.3 mg/dL
Urine	
Glucose	negative
Reducing substances	3+

Which of the following is the most likely mechanism of these findings?

- (A) Decreased gluconeogenesis
- (B) Decreased insulin secretion
- (C) Increased glucagon secretion
- (D) Increased gluconeogenesis
- (E) Increased insulin secretion
- (F) Insulin resistance



51. A 25-year-old man is brought to the emergency department after being discovered semiconscious and incoherent at home. On arrival, he is stuporous. His blood pressure is 105/70 mm Hg, pulse is 80/min, and respirations are 12/min. Examination shows cool, damp skin. The pupils are pinpoint and react sluggishly to light. Which of the following is the most likely substance taken?

- (A) Alcohol
- (B) Barbiturates
- (C) Cocaine
- (D) Heroin
- (E) LSD

52. For 8 weeks, a 52-year-old man with a 5-year history of type 2 diabetes mellitus has had deep burning pain in the ball of his right foot and big toe when the foot is raised above chest concentration. He also has cramping in his right calf when he walks more than 50 feet. He has smoked two packs of cigarettes daily for 30 years. Femoral pulses are palpable; pedal pulses are absent. Which of the following is the most likely diagnosis?

- (A) Aortoiliac stenosis
- (B) Femoral popliteal stenosis
- (C) Mononeuropathy
- (D) Vasculitis
- (E) Venous stasis

53. A 16-year-old girl is brought to the physician because of intermittent pain and swelling of both ankles over the past month. She is currently not in pain. When the pain occurs, it is so severe that she is unable to walk. There is no associated fever or chills. She is sexually active and has had one sexual partner for 12 months. Her temperature is 37°C (98.6°F), pulse is 80/min, and blood pressure is 145/87 mm Hg. Examination shows no abnormalities or tenderness of the ankle joints. There is a nonpainful ulcer on the oral buccal mucosa. The lungs are clear to auscultation. Cardiac examination shows no abnormalities. Laboratory studies show:

Leukocyte count	4000/mm <sup>3</sup>
Segmented neutrophils	65%
Eosinophils	3%
Lymphocytes	25%
Monocytes	7%
Platelet count	60,000/mm <sup>3</sup>
Erythrocyte sedimentation rate	100 mm/h
Serum	
Antinuclear antibodies	1:320
Anti-DNA antibodies	positive
Rapid plasma reagin	1:16
Rheumatoid factor	negative
Urine	
Protein	3+
RBC casts	negative
RBC	none
WBC	10–20/hpf

X-rays of the ankles show no abnormalities other than tissue swelling. Which of the following is the most likely diagnosis?

- (A) Disseminated gonococcal disease
- (B) Polyarticular arthritis
- (C) Reactive arthritis
- (D) Secondary syphilis
- (E) Systemic lupus erythematosus

54. A 65-year-old man who is quadriplegic as a result of multiple sclerosis is hospitalized for treatment of left lower lobe pneumonia. His temperature is 38.1°C (100.5°F), pulse is 95/min, respirations are 12/min, and blood pressure is 120/80 mm Hg. He appears malnourished. Rhonchi are heard at the left lower lobe of the lung on auscultation. Examination of the heart, lymph nodes, abdomen, and extremities shows no abnormalities. There is a 1-cm area of erythema over the sacrum with intact skin and no induration. Neurologic examination shows quadriparesis. Test of the stool for occult blood is negative. Which of the following is the most effective intervention for this patient's skin lesion?
- (A) Frequent turning
  - (B) Use of wet to dry dressings
  - (C) Whirlpool therapy
  - (D) Broad-spectrum antibiotic therapy
  - (E) Surgical debridement
55. A 67-year-old woman comes to the physician because of dizziness for 6 weeks. When she stands up suddenly, she becomes light-headed and has to steady herself for approximately 1 to 2 minutes before she is able to walk. She has hypertension and type 2 diabetes mellitus. Current medications include glyburide, a diuretic, a  $\beta$ -adrenergic blocking agent, and an angiotensin-converting enzyme (ACE) inhibitor. Her pulse is 55/min. Her blood pressure is 110/70 mm Hg in the right arm and 70/50 mm Hg in the left arm while supine; her blood pressure is 70/50 mm Hg in the right arm and 50/30 mm Hg in the left arm immediately after standing. Neurologic examination shows no focal findings. An ECG shows sinus bradycardia with no evidence of ischemia. Carotid duplex ultrasonography shows reverse flow in the left vertebral artery with no evidence of occlusion. Which of the following is the most appropriate next step in management?
- (A) Cardiac stress scintigraphy
  - (B) Adjusting her medication regimen
  - (C) Warfarin therapy
  - (D) Transesophageal echocardiography
  - (E) Coronary arteriography
56. A 65-year-old woman has a 6-month history of progressive irritability, palpitations, heat intolerance, frequent bowel movements, and a 6.8-kg (15-lb) weight loss. She has had a neck mass for more than 10 years.  $^{131}\text{I}$  scan shows an enlarged thyroid gland with multiple areas of increased and decreased uptake. Which of the following is the most likely diagnosis?
- (A) Defect in thyroxine ( $\text{T}_4$ ) biosynthesis
  - (B) Graves' disease
  - (C) Multinodular goiter
  - (D) Riedel's thyroiditis
  - (E) Thyroid carcinoma
  - (F) Thyroiditis
  - (G) Toxic adenoma
  - (H) Triiodothyronine ( $\text{T}_3$ ) thyrotoxicosis
57. A 4-year-old boy is brought to the physician because of temperatures to 39.4°C (102.9°F) for 8 days. Examination shows anterior cervical lymphadenopathy, nonexudative conjunctivitis bilaterally, a strawberry tongue, an erythematous truncal rash, and edema of the hands and feet. Which of the following is the most appropriate pharmacotherapy to prevent complications of this illness?
- (A) Intravenous immune globulin
  - (B) Intravenous penicillin
  - (C) Intravenous prednisone
  - (D) Oral isoniazid
  - (E) Oral rifampin

58. A 32-year-old woman comes to the physician because of weakness of the lower extremities for 2 days. Three years ago, she had pain and partial loss of vision of the right eye; the vision returned to normal after 6 weeks. There is mild pallor of the right optic disc. She has impaired tandem gait. Babinski's sign is present bilaterally. There is mild spasticity of the lower extremities and mild weakness of the iliopsoas and hamstring muscles. Serum creatine kinase activity is 50 U/L. Which of the following is the most likely diagnosis?

- (A) Amyotrophic lateral sclerosis
- (B) Becker's muscular dystrophy
- (C) Diffuse sensorimotor peripheral neuropathy
- (D) Duchenne's muscular dystrophy
- (E) Hyperkalemic periodic paralysis
- (F) Hypokalemic periodic paralysis
- (G) Multiple sclerosis
- (H) Myasthenia gravis
- (I) Myasthenic (Lambert-Eaton) syndrome
- (J) Myotonic muscular dystrophy
- (K) Polymyositis
- (L) Pontine astrocytoma
- (M) Pontine infarction
- (N) Spinal cord tumor
- (O) Transverse myelitis

59. A previously healthy 18-year-old man is brought to the emergency department because of abdominal pain and nausea for 6 hours. He has had decreased appetite for the past week. He takes no medications. He drinks one to two beers daily and occasionally more on weekends. He does not use illicit drugs. His temperature is 37.8°C (100°F), pulse is 120/min, respirations are 24/min, and blood pressure is 105/60 mm Hg. Abdominal examination shows diffuse tenderness with no guarding or rebound. Bowel sounds are normal. Laboratory studies show:

Serum	
Na <sup>+</sup>	135 mEq/L
Cl <sup>-</sup>	98 mEq/L
K <sup>+</sup>	3.8 mEq/L
HCO <sub>3</sub> <sup>-</sup>	16 mEq/L
Glucose	360 mg/dL
Ketones	present
Urine ketones	present

Arterial blood gas analysis on room air shows a pH of 7.30. Which of the following is the most likely diagnosis?

- (A) Acute appendicitis
- (B) Acute pancreatitis
- (C) Alcoholic ketoacidosis
- (D) Diabetic ketoacidosis
- (E) Lactic acidosis

60. A previously healthy 2-year-old boy is brought to the physician 20 minutes after an episode of cyanosis and loss of consciousness that lasted 3 minutes. The symptoms occurred after his mother scolded him for climbing onto the dining room table. The mother says that the child began to cry, let out a deep sigh, stopped breathing, and jerked his arms and legs back and forth. On arrival, he is alert and active. Neurologic examination shows no focal findings. Which of the following is the most appropriate next step in management?

- (A) Reassurance
- (B) EEG
- (C) CT scan of the head
- (D) Anticonvulsant therapy
- (E) Lumbar puncture

61. A 72-year-old man comes to the physician because of a 7-month history of leg weakness and dry eyes and mouth. He also has had a 10.4-kg (23-lb) weight loss over the past 4 months despite no change in appetite. He has smoked one and a half packs of cigarettes daily for 50 years. He drinks 4 oz of alcohol daily. He has peptic ulcer disease and emphysema. Medications include cimetidine, theophylline, and low-dose prednisone. Examination shows mild ptosis. He has a barrel-shaped chest. Breath sounds are distant. There is moderate weakness of proximal muscles of the lower extremities. Reflexes are absent. He has difficulty rising from a chair. Sensory examination shows no abnormalities. An x-ray shows a hyperinflated chest and a 3 x 4-cm mass in the right hilum. His neurologic findings are most likely due to a lesion involving which of the following?
- (A) Muscle membrane
  - (B) Parasympathetic nervous system
  - (C) Peripheral nerve
  - (D) Presynaptic neuromuscular junction
  - (E) Sympathetic nervous system
62. A 5-year-old boy is brought to the physician because of a 2-day history of fever and painful swelling of the left ankle. He has had recurrent cervical lymphadenitis and pneumonia since infancy. Two years ago, a culture from an abscess in the cervical region grew *Staphylococcus aureus*. His temperature is 38°C (100.4°F). Examination shows a tender, erythematous, edematous left ankle; there is point tenderness over the medial malleolus. A bone scan shows increased uptake in the left lower tibial metaphysis. Culture of bone aspirate grows *Serratia marcescens*. Nitroblue tetrazolium test shows no color change. Which of the following is the most likely mechanism for these findings?
- (A) Adenosine deaminase deficiency
  - (B) Consumption of complement
  - (C) Defective opsonization
  - (D) Destruction of CD4+ T lymphocytes
  - (E) Developmental arrest of maturation of B lymphocytes
  - (F) Dysmorphogenesis of the third and fourth pharyngeal pouches
  - (G) Impaired chemotaxis
  - (H) Impaired phagocytic oxidative metabolism
63. A previously healthy 47-year-old man comes to the physician because of a 6.8-kg (15-lb) weight loss over the past 6 months. He spent 2 weeks in Mexico 3 months ago. Since returning, he has noticed that his stools have changed in size and consistency. He has not had fever, night sweats, or change in appetite. He takes no medications. He has smoked one pack of cigarettes daily for 20 years. He appears healthy and well nourished. His temperature is 37°C (98.6°F), pulse is 105/min, respirations are 16/min, and blood pressure is 130/78 mm Hg. Examination shows pale conjunctivae. The abdomen is soft with no organomegaly. Rectal examination shows a normal prostate with no masses. Test of the stool for occult blood is positive. Laboratory studies show:

Hemoglobin	11 g/dL
Mean corpuscular volume	72 $\mu\text{m}^3$
Platelet count	300,000/mm <sup>3</sup>
Red cell distribution width	16% (N=13%–15%)

Which of the following is the most appropriate next step in diagnosis?

- (A) Second complete blood count in 3 months
- (B) CT scan of the abdomen
- (C) Colonoscopy
- (D) Esophagogastroduodenoscopy
- (E) Sigmoidoscopy

64. A 62-year-old white man comes to the physician because of an 8-month history of progressive pain and stiffness of his hands. The stiffness is worse at the end of the day. He has a 1-year history of fatigue and increased urination. He has no history of serious illness and takes no medications. His last visit to a physician was 10 years ago. He does not smoke or drink alcohol. He is 185 cm (6 ft 1 in) tall and weighs 82 kg (180 lb); BMI is 24 kg/m<sup>2</sup>. His pulse is 84/min, and blood pressure is 136/82 mm Hg. Examination shows dark brown skin. S<sub>1</sub> and S<sub>2</sub> are normal. An S<sub>3</sub> is heard at the apex. There is mild tenderness over the second and third metacarpophalangeal joints bilaterally without synovial thickening. Heberden nodes are present over the distal interphalangeal joints of the index and ring fingers bilaterally. Laboratory studies show:

Hemoglobin	16 g/dL
Leukocyte count	7700/mm <sup>3</sup>
Platelet count	332,000/mm <sup>3</sup>
Serum	
Glucose	182 mg/dL
Albumin	3.4 g/dL
Total bilirubin	1.1 mg/dL
Alkaline phosphatase	52 U/L
AST	55 U/L
ALT	68 U/L
Hepatitis B surface antigen	negative
Hepatitis C antibody	negative
Rheumatoid factor	negative

Which of the following is most likely to have prevented this patient's condition?

- (A) Calcium supplementation
  - (B) Enalapril therapy
  - (C) Metformin therapy
  - (D) Methotrexate therapy
  - (E) Phlebotomy
65. A 57-year-old woman is brought to the emergency department 45 minutes after she fell after an episode of light-headedness. She has a 6-month history of progressive fatigue, tingling sensations in her fingers and toes, and loss of balance. She underwent a partial gastrectomy for peptic ulcer disease 10 years ago. She has type 2 diabetes mellitus. She has smoked one pack of cigarettes daily for 40 years. Her only medication is insulin. She appears pale. Her temperature is 37°C (98.6°F), pulse is 105/min, respirations are 20/min, and blood pressure is 124/76 mm Hg. The abdomen is soft with a well-healed surgical scar. Sensation to vibration and position is absent over the upper and lower extremities. She has a broad-based gait. Laboratory studies show:

Hemoglobin	8.3 g/dL
Mean corpuscular volume	105 µm <sup>3</sup>
Leukocyte count	4800/mm <sup>3</sup>
Platelet count	100,000/mm <sup>3</sup>
Serum	
Bilirubin, total	2.1 mg/dL
Direct	0.2 mg/dL
Lactate dehydrogenase	320 U/L

Which of the following is the most likely explanation for these findings?

- (A) Amyotrophic lateral sclerosis
- (B) Diabetes mellitus
- (C) History of gastrectomy
- (D) Meniere disease
- (E) Multiple sclerosis
- (F) Vertebrobasilar deficiency

66. A 62-year-old man comes to the physician because of a 3-month history of progressive fatigue and joint pain, a 2-month history of sinus congestion, a 3-week history of cough, and a 1-week history of blood-tinged sputum. He has not had fever, nausea, vomiting, or diarrhea. He has hypercholesterolemia, stable angina pectoris, and hypertension. Medications include atorvastatin, labetalol, isosorbide, and aspirin. Over the past 3 weeks, he has been taking over-the-counter ibuprofen as needed for the joint pain. His pulse is 84/min, respirations are 12/min, and blood pressure is 132/76 mm Hg. Examination shows clear nasal discharge with no nasal or oral lesions. The joints are diffusely tender with no warmth or erythema; range of motion is full. Laboratory studies show:

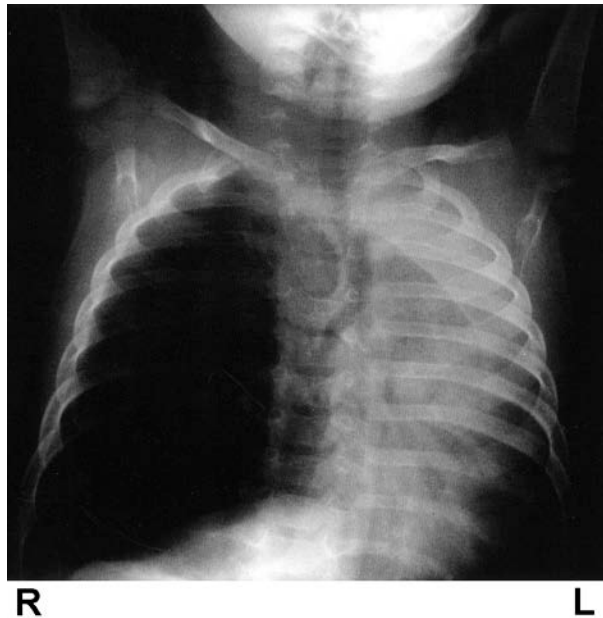
Hematocrit	36%
Mean corpuscular volume	83 $\mu\text{m}^3$
Leukocyte count	14,000/mm <sup>3</sup>
Segmented neutrophils	74%
Eosinophils	1%
Lymphocytes	14%
Monocytes	11%
Platelet count	275,000/mm <sup>3</sup>
Serum	
Urea nitrogen	28 mg/dL
Creatinine	3.2 mg/dL
Antinuclear antibodies	1:256
Rheumatoid factor	negative
Antineutrophil cytoplasmic antibodies	positive
Urine	
Blood	3+
Protein	3+
RBC	15–17/hpf
WBC	1–2/hpf
RBC casts	rare

Which of the following is the most likely underlying mechanism of this patient's renal failure?

- (A) Atheroembolic disease
  - (B) Cold agglutinins
  - (C) Interstitial nephritis
  - (D) Lyme disease
  - (E) Septic arthritis
  - (F) Vasculitis
67. Two days after admission to the hospital for congestive heart failure, an 82-year-old man is unable to walk because of severe, throbbing pain in his left foot. He has no history of similar episodes or recent trauma. He also has coronary artery disease and hypertension. Current medications include atenolol, lisinopril, furosemide, and aspirin. He does not smoke or drink alcohol. He is in moderate distress. His temperature is 38°C (100.4°F), pulse is 68/min and regular, respirations are 12/min, and blood pressure is 138/88 mm Hg. Jugular venous pulsations are present 3 cm above the sternal angle. Crackles are heard at both lung bases. A grade 2/6 systolic murmur is heard best at the left sternal border and second intercostal space. Examination of the lower extremities shows pitting pedal edema. There is tenderness, erythema, and edema of the left great toe. Active and passive range of motion of the first metacarpophalangeal joint produces pain; arthrocentesis of the joint is performed. Analysis of joint fluid aspirate is most likely to show which of the following?

	<b>WBC (/mm<sup>3</sup>)</b>	<b>Microscopic Examination for Crystals</b>	<b>Gram Stain</b>
(A)	100	needle-shaped	no organisms
(B)	100	none	gram-positive cocci
(C)	100	none	no organisms
(D)	100	rhomboid	no organisms
(E)	20,000	needle-shaped	no organisms
(F)	20,000	none	gram-positive cocci

68. A 42-year-old woman comes to the physician because of an 8-week history of intermittent nausea and abdominal pain that occurs 20 to 30 minutes after eating. The pain extends from the epigastrium to the right upper quadrant and is sometimes felt in the right scapula; it lasts about 30 minutes and is not relieved by antacids. The last episode occurred after she ate a hamburger and french fries. She has not had vomiting. She is currently asymptomatic. She is 165 cm (5 ft 5 in) tall and weighs 104 kg (230 lb); BMI is 38 kg/m<sup>2</sup>. Examination shows no other abnormalities. Which of the following is the most appropriate next step in management?
- (A) Abdominal ultrasonography of the right upper quadrant
  - (B) Upper gastrointestinal series with small bowel follow-through
  - (C) CT scan of the abdomen
  - (D) Endoscopic retrograde cholangiopancreatography
  - (E) Elective cholecystectomy
  - (F) Immediate cholecystectomy
69. A 52-year-old man comes to the physician with his wife because of a 1-year history of excessive daytime sleepiness. He does not think the symptoms are problematic, but his wife is concerned because he sometimes falls asleep on the sofa early in the evening when guests are present. He also once fell asleep while driving at night and drove off the road, narrowly avoiding injury. His wife says that he has always snored loudly, and over the past year, he has had episodes of choking or gasping for breath while sleeping. He is 178 cm (5 ft 10 in) tall and weighs 105 kg (231 lb); BMI is 33 kg/m<sup>2</sup>. His pulse is 76/min, respirations are 14/min, and blood pressure is 150/76 mm Hg. Physical and neurologic examinations show no other abnormalities. Which of the following is most likely to confirm the diagnosis?
- (A) 24-Hour ambulatory ECG monitoring
  - (B) Multiple sleep latency test
  - (C) Polysomnography
  - (D) CT scan of the head
  - (E) Laryngoscopy
70. A 47-year-old man is brought to the emergency department 2 hours after the sudden onset of shortness of breath, severe chest pain, and sweating. He has no history of similar symptoms. He has hypertension treated with hydrochlorothiazide. He has smoked one pack of cigarettes daily for 30 years. His pulse is 110/min, respirations are 24/min, and blood pressure is 110/50 mm Hg. A grade 3/6, diastolic blowing murmur is heard over the left sternal border and radiates to the right sternal border. Femoral pulses are decreased bilaterally. An ECG shows left ventricular hypertrophy. Which of the following is the most likely diagnosis?
- (A) Acute myocardial infarction
  - (B) Aortic dissection
  - (C) Esophageal rupture
  - (D) Mitral valve prolapse
  - (E) Pulmonary embolism
71. A 22-year-old man is brought to the emergency department 30 minutes after he sustained a gunshot wound to the abdomen. His pulse is 120/min, respirations are 28/min, and blood pressure is 70/40 mm Hg. Breath sounds are normal on the right and decreased on the left. Abdominal examination shows an entrance wound in the left upper quadrant at the midclavicular line below the left costal margin. There is an exit wound laterally in the left axillary line at the 4th rib. Intravenous fluid resuscitation is begun. Which of the following is the most appropriate next step in management?
- (A) Upright x-ray of the chest
  - (B) CT scan of the chest
  - (C) Intubation and mechanical ventilation
  - (D) Peritoneal lavage
  - (E) Left tube thoracostomy



72. A 4-year-old boy with asthma becomes limp during treatment with inhaled albuterol in the emergency department. Ten minutes ago, he received intravenous methylprednisolone for an acute exacerbation, and he was alert and oriented at that time. He received the diagnosis of asthma 2 years ago and has been admitted to the hospital for acute exacerbations eight times since then. Current medications include albuterol and montelukast. He appears pale and gasps and moans as he attempts to breathe. He responds to voice. His temperature is 36°C (96.8°F), pulse is 160/min and thready, respirations are 18/min, and blood pressure is 50/20 mm Hg. The skin is cold to the touch. Pulmonary examination shows poor air movement, especially on the left. No wheezes are heard. The point of maximal impulse is 2 cm to the left of the midclavicular line in the sixth intercostal space. A chest x-ray is shown. Which of the following is the most likely underlying cause of this patient's hypotension?
- (A) Adverse effect of albuterol
  - (B) Adverse effect of methylprednisolone
  - (C) Atelectasis of the left lung
  - (D) Decrease in cardiac output
  - (E) Severe bronchospasm
- 
73. A previously healthy 22-year-old college student is brought to the emergency department by her parents 20 minutes after they observed her having a seizure. After the seizure, she was confused and had difficulty thinking of some words. She has had a headache, cough, and fever for 3 days treated with acetaminophen and dextromethorphan. Her temperature is 38.9°C (102°F). Neurologic examination shows diffuse hyperreflexia. On mental status examination, she is confused and has short-term memory deficits. She has difficulty naming objects and makes literal paraphasic errors. An MRI of the brain shows bitemporal hyperintensities. A lumbar puncture is done; cerebrospinal fluid analysis shows an erythrocyte count of 340/mm<sup>3</sup>, a leukocyte count of 121/mm<sup>3</sup> (88% monocytes), and a protein concentration of 78 mg/dL. Which of the following is the most likely diagnosis?
- (A) Bacterial meningitis
  - (B) Dextromethorphan intoxication
  - (C) Herpes simplex encephalitis
  - (D) HIV encephalopathy
  - (E) Reye syndrome
  - (F) Syphilis



74. A 67-year-old woman comes to the physician because of easy bruising for 4 months. She has a history of lung cancer treated with radiation therapy 6 months ago. She has a 2-year history of hypertension treated with a thiazide diuretic and an angiotensin-converting enzyme (ACE) inhibitor. Examination, including neurologic examination, shows no abnormalities except for multiple ecchymoses. Her hemoglobin concentration is 13 g/dL, leukocyte count is  $5000/\text{mm}^3$ , and platelet count is  $35,000/\text{mm}^3$ . A serum antiplatelet antibody assay is negative. Which of the following is the most appropriate next step in diagnosis?
- (A) Bone scan
  - (B) CT scan of the abdomen
  - (C) CT scan of the chest
  - (D) Bronchoscopy
  - (E) Bone marrow aspiration
75. A 57-year-old woman comes to the physician because of an 8-week history of difficulty sleeping, fatigue, and muscle tension. During this period, she also has had memory lapses, difficulty concentrating, and has been reprimanded at work for arriving late. Over the past 2 weeks, she has had three episodes of palpitations and shortness of breath that have awakened her from sleep. Her pulse is 80/min, and blood pressure is 110/90 mm Hg. Physical examination shows no abnormalities. Mental status examination shows a depressed mood and constricted affect. She says that she is no longer interested in activities that she used to enjoy. She has suicidal ideation without a plan. Her hemoglobin concentration is 11 g/dL, and serum ferritin concentration is 140 ng/mL. Which of the following is the most appropriate initial step in treatment?
- (A) Acupuncture
  - (B) Diazepam therapy
  - (C) Donepezil therapy
  - (D) Ferrous sulfate therapy
  - (E) Ginkgo biloba extract therapy
  - (F) Paroxetine therapy
76. A 60-year-old man has had painful skin with exfoliation of the skin and mucous membranes for 1 day. He has been taking allopurinol and probenecid for 2 weeks because of gouty arthritis. There is diffuse exfoliation of the skin with oozing of serous fluid. The mucous membranes of the mouth are erythematous and exfoliated. There are no target lesions. Which of the following is the most likely diagnosis?
- (A) Bullous pemphigoid
  - (B) Erythema multiforme
  - (C) Pemphigus erythematosus
  - (D) Staphylococcal scalded-skin syndrome
  - (E) Toxic epidermal necrolysis
77. A 27-year-old man is brought to the emergency department by his sister because of increasing confusion for 10 hours. He is unable to answer questions. His sister states that he recently saw a psychiatrist for the first time because of hearing voices; he was prescribed a medication, but she is not sure what it is. She says that he has a history of excessive drinking, and she thinks that he has also experimented with illicit drugs. He appears acutely ill. His temperature is  $39.1^\circ\text{C}$  ( $102.3^\circ\text{F}$ ), pulse is 124/min, and blood pressure is 160/102 mm Hg. Examination shows profuse diaphoresis and muscle rigidity. His neck is supple. The abdomen is soft and nontender. Mental status examination shows psychomotor agitation alternating with lethargy. His leukocyte count is  $15,600/\text{mm}^3$ , and serum creatine kinase activity is 943 U/L. Which of the following is the most likely explanation for this patient's symptoms?
- (A) Amphetamine intoxication
  - (B) Bacterial meningitis
  - (C) Delirium tremens
  - (D) Neuroleptic malignant syndrome
  - (E) Sepsis

78. A previously healthy 17-year-old girl comes to the physician because of a 2-month history of exercise-induced cough and nasal congestion. She plays field hockey and has noticed she coughs when running up and down the field. The cough is nonproductive and resolves with rest. She has not had chest pain or palpitations. She takes no medications and does not smoke. Her sister has asthma. The patient appears well. Her pulse is 68/min, respirations are 16/min, and blood pressure is 100/75 mm Hg. Pulse oximetry on room air shows an oxygen saturation of 99%. Cardiopulmonary examination shows no abnormalities. An x-ray of the chest shows no abnormalities. Spirometry shows an FEV<sub>1</sub>:FVC ratio of 90% and an FEV<sub>1</sub> of 90% of predicted. Which of the following is the most likely diagnosis?
- (A) Asthma
  - (B) Chronic bronchitis
  - (C) Gastroesophageal reflux disease
  - (D) Postnasal drip syndrome
  - (E) Variable endobronchial upper airway obstruction
79. An 18-year-old man is brought to the emergency department 45 minutes after his car slid off an icy road into a telephone pole at approximately 35 miles per hour. He was the restrained driver, and the air bag inflated. Examination shows multiple contusions over the chest bilaterally; there is tenderness to palpation over the right lower chest wall. The abdomen is flat, soft, and nontender. A complete blood count and serum concentrations of electrolytes, urea nitrogen, and creatinine are within the reference range. Toxicology screening is negative. His urine is pink; urinalysis shows 80 RBC/hpf but no WBCs. Which of the following is the most appropriate next step in management?
- (A) CT scan of the abdomen and pelvis with contrast
  - (B) Magnetic resonance arteriography of the renal arteries
  - (C) Intravenous administration of antibiotics
  - (D) Exploratory laparotomy
  - (E) No further studies are indicated
80. A 15-year-old boy is brought to the physician because of fatigue since starting his freshman year of high school 3 months ago. He often falls asleep during class. He urinates four to five times nightly and often has difficulty falling asleep again. He has no history of serious illness and takes no medications. He is at the 20th percentile for height and above the 95th percentile for weight and BMI. Vital signs are within normal limits. Examination shows a velvety, hyperpigmented, macular rash over the neck and axillae. The remainder of the examination shows no abnormalities. Results of a complete blood count and serum electrolyte concentrations show no abnormalities. Additional laboratory studies show:

Serum glucose	134 mg/dL
Urine	
pH	5.5
Specific gravity	1.028
Glucose	1+
Ketones	negative

In addition to dietary counseling, which of the following is the most appropriate initial treatment?

- (A) Exercise program
- (B) Increased fluid intake
- (C) Cyclosporine therapy
- (D) Insulin therapy
- (E) Oral hypoglycemic agent

81. A previously healthy 32-year-old man is brought to the emergency department after being found unconscious on the floor at his workplace. On arrival, he is obtunded. He is intubated and mechanical ventilation is begun. Examination shows flaccid paralysis on the right. A CT scan of the head shows a large evolving cerebral infarction on the left. Carotid duplex ultrasonography shows dissection of the left carotid artery. After receiving intensive medical care for 6 hours, the patient develops decerebrate posturing and becomes hemodynamically unstable. Vasopressor therapy is begun. A second CT scan of the head shows a massive left hemispheric cerebral infarction with severe edema and herniation. The physician determines that surgical intervention is not indicated because of the patient's poor prognosis. The patient's driver's license indicates that he wishes to be an organ donor. The physician meets with the patient's family and informs them about the patient's prognosis, and they are devastated. During the meeting, they say that they were unaware of his willingness to be an organ donor and agree that he should not receive cardiopulmonary resuscitation. Which of the following is the most appropriate next step with respect to organ donation?

- (A) Arrange for the regional organ procurement organization to address the issue with the patient's family
- (B) Delay further consideration of the issue until after 24 hours of aggressive care
- (C) Delay further consideration of the issue until the family seems ready
- (D) Initiate organ donation at this time

82. A 77-year-old man is brought to the physician because of a 12-hour history of word-finding difficulty and weakness and sensory loss of the right arm and leg. He has no history of similar symptoms. He has type 2 diabetes mellitus, hypertension, and atrial fibrillation. Current medications include metformin, lisinopril, and aspirin. He is alert. His pulse is 80/min and irregular, respirations are 16/min, and blood pressure is 170/90 mm Hg. He follows commands but has nonfluent aphasia. There is moderate weakness and decreased sensation of the right upper and lower extremities. Deep tendon reflexes are 2+ bilaterally. Babinski sign is present on the right. His serum glucose concentration is 162 mg/dL. Which of the following is the most appropriate next step in diagnosis?

- (A) Carotid duplex ultrasonography
- (B) CT scan of the head
- (C) EEG
- (D) Lumbar puncture
- (E) Cerebral angiography

83. A 67-year-old man is brought to the emergency department because of a 1-week history of nausea, generalized weakness, and malaise. He has congestive heart failure, hypertension, and coronary artery disease. Current medications include lisinopril, digoxin, isosorbide, spironolactone, and metoprolol. His temperature is 37.2°C (99°F), pulse is 88/min, and blood pressure is 140/90 mm Hg. Examination shows a soft abdomen. There is 2+ edema in the lower extremities. Laboratory studies show:

Hematocrit	36%
Leukocyte count	10,000/mm <sup>3</sup>
Serum	
Na <sup>+</sup>	140 mEq/L
K <sup>+</sup>	7.3 mEq/L
HCO <sub>3</sub> <sup>-</sup>	18 mEq/L
Urea nitrogen	40 mg/dL
Creatinine	1.8 mg/dL
AST	20 U/L

Urinalysis shows no abnormalities. Which of the following is the most likely explanation for this patient's hyperkalemia?

- (A) Adverse effect of medications
- (B) Laboratory error
- (C) Metabolic acidosis
- (D) Renal failure
- (E) Rhabdomyolysis

84. A 19-year-old college student comes to the physician because of progressive hair growth over her face and body since the age of 16 years. She also has acne and oily skin. Menses have occurred at 30- to 90-day intervals since menarche at the age of 14 years. She has no history of serious illness and takes no medications. She is 168 cm (5 ft 6 in) tall and weighs 88 kg (193 lb); BMI is 31 kg/m<sup>2</sup>. Her temperature is 37.2°C (99°F), pulse is 72/min, respirations are 16/min, and blood pressure is 120/80 mm Hg. Physical examination shows coarse, pigmented hair over the chin and upper lip, around both nipples, and along the midline of the lower abdomen. The remainder of the examination, including pelvic examination, shows no abnormalities. Serum studies show:

Fasting glucose	95 mg/dL
Fasting insulin	7.5 µU/mL (N=11–240)
Dehydroepiandrosterone sulfate	3 µg/mL (N=0.5–5.4)
Follicle-stimulating hormone	8 mIU/mL
17α-Hydroxyprogesterone	160 ng/dL (N=20–300)
Luteinizing hormone	10 mIU/mL
Testosterone	4.2 nmol/L (N<3.5)

Which of the following is the most appropriate pharmacotherapy?

- (A) Bromocriptine
  - (B) Clomiphene
  - (C) Combination oral contraceptive
  - (D) Dexamethasone
  - (E) Gonadotropin-releasing hormone agonist
85. A 27-year-old woman comes to the physician because she has been unable to move the left side of her face for the past 2 days. Two weeks ago, she had a 3-day episode of flu-like symptoms that resolved without treatment. She has a history of impaired glucose tolerance. She is sexually active with one male partner and uses an oral contraceptive; they do not use condoms. She says she sometimes eats too much and occasionally consumes raw shellfish. She lives in Minnesota and hikes a wooded path with her dog daily to go swimming in a lake. She is 157 cm (5 ft 2 in) tall and weighs 77 kg (170 lb); BMI is 31 kg/m<sup>2</sup>. Examination shows an inability to wrinkle the left side of the forehead and an asymmetric smile. The remainder of the examination shows no abnormalities. Which of the following is the strongest predisposing factor for this patient's condition?
- (A) Hiking
  - (B) Oral contraceptive use
  - (C) Overeating
  - (D) Shellfish ingestion
  - (E) Swimming in a lake
  - (F) Unprotected sexual intercourse
86. A 67-year-old woman comes to the physician for a follow-up examination. She had a pulmonary embolism and required treatment in the hospital for 3 weeks. She had a retroperitoneal hemorrhage; anticoagulant therapy was temporarily discontinued, and she underwent placement of an inferior vena cava (IVC) filter. She had a hematoma that was resolving on discharge from the hospital 2 weeks ago. Today, she says she has had a persistent sensation of tingling and numbness of her left thigh that she did not report in the hospital because she thought it would go away; the sensation has improved somewhat during the past week. Her only medication is warfarin. Vital signs are within normal limits. Examination of the skin shows no abnormalities. Muscle strength is normal. Sensation to light touch is decreased over a 5 x 5-cm area on the lateral aspect of the left anterior thigh. Which of the following is the most likely cause of this patient's decreased sensation?
- (A) Cerebral infarction during the hospitalization
  - (B) Complication of the IVC filter placement
  - (C) Compression of the lateral femoral cutaneous nerve
  - (D) Hematoma of the left thigh
  - (E) Spinal cord infarct
  - (F) Vitamin B<sub>12</sub> (cobalamin) deficiency

## Sample Questions

### Block 3 (Questions 87-123)

87. A 27-year-old woman, gravida 3, para 2, at 25 weeks' gestation is admitted to the hospital 30 minutes after spontaneous rupture of membranes. She reports that after walking a 5-km course 24 hours ago, she began to have muscle aches and chills. Her temperature prior to going to bed last night was 38.9°C (102°F). She took 800 mg of ibuprofen and awoke 8 hours later with severe abdominal pain and shaking chills. She began to vomit, then noted a gush of blood-tinged fluid from her vagina. Her pregnancy had been uncomplicated. On admission, she appears ill. Her temperature is 39.1°C (102.3°F), pulse is 110/min, respirations are 18/min, and blood pressure is 110/60 mm Hg. Abdominal examination shows severe, diffuse tenderness throughout the lower quadrants. Pelvic examination shows exquisite cervical motion and uterine tenderness. Speculum examination confirms rupture of membranes. Ultrasonography shows the fetus in a vertex presentation. There is anhydramnios. Which of the following is the greatest predisposing factor for this patient's premature rupture of membranes?
- (A) Emesis
  - (B) Exercise
  - (C) Ibuprofen use
  - (D) Intra-amniotic infection
  - (E) Multiparity
88. A previously healthy 27-year-old nulligravid woman comes to the emergency department because of a 2-day history of moderate-to-severe pain and swelling of the left labia. She is sexually active and uses condoms inconsistently. Her temperature is 37.2°C (99°F), pulse is 92/min, respirations are 18/min, and blood pressure is 115/75 mm Hg. Pelvic examination shows a 4 x 3-cm, tender, fluctuant mass medial to the left labium majus compromising the introital opening. Which of the following is the most appropriate next step in management?
- (A) Administration of intravenous metronidazole
  - (B) Administration of intravenous penicillin G
  - (C) Ultrasound-guided needle aspiration of the mass
  - (D) Incision and drainage
  - (E) Vulvectomy
89. A 57-year-old man comes to the emergency department because of cramping in his hands and feet and numbness and tingling around his lips and in his fingers; these symptoms occurred intermittently for 6 months but have been progressively severe during the past 2 weeks. He also has had a 13-kg (30-lb) weight loss and bulky, foul-smelling stools that do not flush easily. He has a 10-year history of drinking 8 to 10 beers daily. He has been hospitalized twice for severe abdominal pain 4 and 6 years ago. His pulse is 80/min, and blood pressure is 105/65 mm Hg. He appears cachectic and chronically ill. The abdomen is nontender. Deep tendon reflexes are 4+ bilaterally. Chvostek and Trousseau signs are present. His serum calcium concentration is 6.5 mg/dL. Which of the following is the most likely diagnosis?
- (A) Hypomagnesemia
  - (B) Hypoparathyroidism
  - (C) Osteomalacia
  - (D) Vitamin D deficiency
90. An obese 33-year-old woman has had four 12-hour episodes of severe, sharp, penetrating pain in the right upper quadrant of the abdomen associated with vomiting but no fever. She has no diarrhea, dysuria, or jaundice and is asymptomatic between episodes. There is slight tenderness to deep palpation in the right upper quadrant. Which of the following is the most appropriate next step in diagnosis?
- (A) Supine and erect x-rays of the abdomen
  - (B) Upper gastrointestinal series
  - (C) Ultrasonography of the upper abdomen
  - (D) CT scan of the abdomen
  - (E) HIDA scan of the biliary tract

91. Five years after being shot in the right thigh, a 21-year-old man comes to the emergency department because of a buzzing sensation adjacent to the scar. At the time of the initial wound, he was discharged after 6 hours of observation with no fractures or soft-tissue swelling. A loud murmur is heard on auscultation; there is a thrill. He has dilated varicose veins with incompetent valves in the lower leg. Which of the following is the most likely diagnosis?
- (A) Arterial spasm
  - (B) Arteriovenous fistula
  - (C) Deep venous thrombosis
  - (D) Occlusion of the superficial femoral artery
  - (E) Pseudoaneurysm
92. A 35-year-old woman comes to the physician because of two 12-hour episodes of dizziness over the past 3 months. During episodes, she experiences the acute onset of rotatory vertigo and imbalance, decreased hearing, tinnitus, a sense of fullness of the right ear, and vomiting. Examination shows a mild hearing loss of the right ear. Which of the following is the most likely diagnosis?
- (A) Acoustic neuroma
  - (B) Benign positional vertigo
  - (C) Brain stem transient ischemic attacks
  - (D) Meniere disease
  - (E) Viral labyrinthitis
93. A 45-year-old woman has a 2-week history of increased anxiety, abdominal discomfort, irritability, and difficulty concentrating; she was robbed at knifepoint in a parking lot 3 weeks ago. She takes levothyroxine for hypothyroidism and uses an over-the-counter inhaler as needed for exercise-induced asthma. Her blood pressure is 140/80 mm Hg, and pulse is 100/min. Examination shows dry skin and hair. She is cooperative but appears anxious, glancing around quickly when a loud noise is heard outside the office. Leukocyte count is  $12,000/\text{mm}^3$ , and serum thyroid-stimulating hormone concentration is  $5.0 \mu\text{U/mL}$ . An ECG shows sinus tachycardia. Which of the following is the most likely diagnosis?
- (A) Acute stress disorder
  - (B) Agoraphobia
  - (C) Generalized anxiety disorder
  - (D) Hypothyroidism
  - (E) Panic disorder
94. A 2-week-old newborn is brought to the physician because his lips have turned blue on three occasions during feeding; he also sweats during feeding. He was born at 38 weeks' gestation and weighed 2466 g (5 lb 7 oz); he currently weighs 2778 g (6 lb 2 oz). His temperature is  $37.8^\circ\text{C}$  ( $100^\circ\text{F}$ ), pulse is 170/min, respirations are 44/min, and blood pressure is 75/45 mm Hg. A grade 3/6 harsh systolic ejection murmur is heard at the left upper sternal border. An x-ray of the chest shows a small boot-shaped heart and decreased pulmonary vascular markings. Which of the following is the most likely diagnosis?
- (A) Anomalous coronary vessels
  - (B) Atrial septal defect
  - (C) Endocardial fibroelastosis
  - (D) Tetralogy of Fallot
  - (E) Total anomalous pulmonary venous return

95. A 38-year-old woman comes to the physician because of a low-grade fever and generalized rash for 4 days. She is currently receiving cefazolin therapy for chronic osteomyelitis. Her temperature is 38.2°C (100.8°F), blood pressure is 150/108 mm Hg, and pulse is 100/min. There is a faint diffuse maculopapular rash. Examination of the back shows no costovertebral angle tenderness. Cardiac and pulmonary examinations show no abnormalities. Laboratory studies show:

Leukocyte count	10,800/mm <sup>3</sup>
Segmented neutrophils	60%
Bands	8%
Eosinophils	4%
Lymphocytes	20%
Monocytes	8%
Serum	
Urea nitrogen	20 mg/dL
Creatinine	1.6 mg/dL
Urine	
WBC	12/hpf
RBC	8/hpf
RBC casts	none
WBC casts	rare

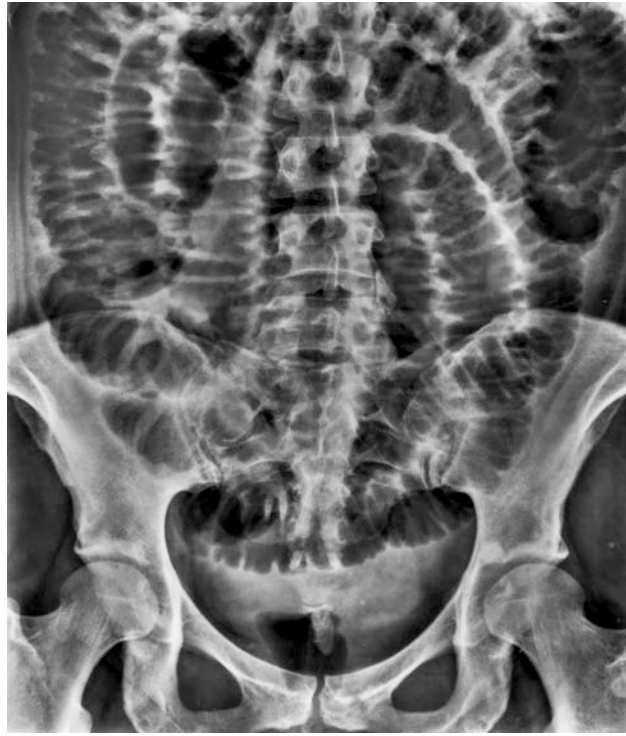Eosinophils are found in the urine sediment. Which of the following is the most likely explanation for these findings?

- (A) Acute tubular necrosis
  - (B) Fibromuscular dysplasia
  - (C) Interstitial nephropathy
  - (D) Polyarteritis nodosa
  - (E) Pyelonephritis
  - (F) Wegener's granulomatosis
96. A 62-year-old woman comes to the physician for a routine health maintenance examination. On questioning, she has had fatigue, constipation, and a 9-kg (20-lb) weight gain during the past year. She receives estrogen replacement therapy. Serum lipid studies were within the reference range 5 years ago. She is 157 cm (5 ft 2 in) tall and weighs 77 kg (170 lb); BMI is 31 kg/m<sup>2</sup>. Physical examination shows no other abnormalities. Serum lipid studies today show:

Total cholesterol	269 mg/dL
HDL-cholesterol	48 mg/dL
LDL-cholesterol	185 mg/dL
Triglycerides	180 mg/dL

Which of the following is the most likely cause?

- (A) Alcohol
- (B) Diabetes mellitus
- (C) Estrogen deficiency
- (D) Estrogen replacement therapy
- (E) Hypothyroidism
- (F) Thiazide diuretic therapy



97. A 37-year-old woman comes to the emergency department because of a 3-day history of increasingly severe abdominal pain, nausea, and vomiting. Twelve years ago, she had a hysterectomy because of severe dysfunctional uterine bleeding. Her temperature is 37°C (98.6°F), blood pressure is 106/70 mm Hg, pulse is 110/min, and respirations are 12/min. Examination shows a distended, tympanic abdomen with diffuse tenderness but no guarding; bowel sounds are hypoactive. Her leukocyte count is 10,000/mm<sup>3</sup>, and hematocrit is 44%. An x-ray of the abdomen is shown. Which of the following is the most appropriate initial step in management?
- (A) CT scan of the abdomen
  - (B) Intravenous neostigmine therapy
  - (C) Esophagogastroduodenoscopy
  - (D) Nasogastric intubation
  - (E) Laparotomy

98. Six hours after delivery, a 1200-g (2-lb 11-oz) newborn develops respiratory distress. She was born at 32 weeks' gestation. Her pulse is 136/min, respirations are 60/min, and blood pressure is 60/30 mm Hg. Examination shows grunting and moderate intercostal and subcostal retractions. The lungs are clear to auscultation. Umbilical artery blood gas analysis on 60% oxygen shows:

pH	7.32
PCO <sub>2</sub>	32 mm Hg
PO <sub>2</sub>	60 mm Hg

An x-ray of the chest shows diffuse reticulogranular densities with an air bronchogram. Which of the following is the most likely underlying mechanism?

- (A) Abnormality of mucociliary function
- (B) Aspiration of meconium into the lungs
- (C) Blockage of airways with mucus
- (D) Increased pulmonary capillary permeability
- (E) Infection with group B streptococcus
- (F) Pulmonary surfactant deficiency



99. A 70-year-old man comes to the physician because of fever, productive cough, and pleuritic chest pain for 1 day. Over the past 2 years, he has had two similar episodes. He also has had persistent pain in the thoracic spine for 1 month. His temperature is 39.2°C (102.6°F), pulse is 94/min, respirations are 22/min, and blood pressure is 110/60 mm Hg. There is dullness to percussion and decreased breath sounds over the right base. Examination shows tenderness of the midthoracic spine. Laboratory studies show:

Hematocrit	34%
Leukocyte count	15,000/mm <sup>3</sup>
Segmented neutrophils	81%
Bands	4%
Lymphocytes	15%
Serum calcium	10.9 mg/dL

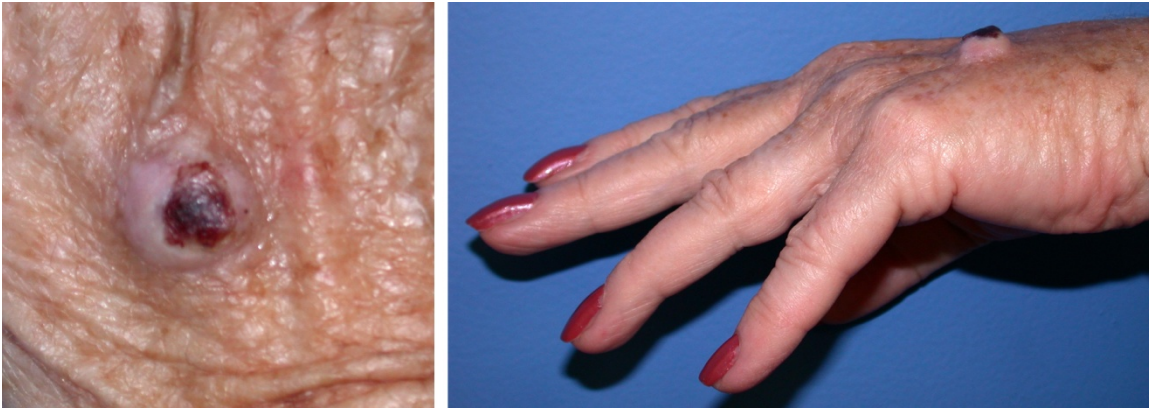X-rays of the chest show consolidation of the right lower lobe, lytic lesions at T8 and T10, and diffuse osteopenia. Which of the following is the most likely diagnosis of this patient's back condition?

- (A) HIV infection
  - (B) Multiple myeloma
  - (C) Prostate cancer
  - (D) Staphylococcal osteomyelitis
  - (E) Tuberculosis osteomyelitis
100. A previously healthy 17-year-old girl comes to the physician because of a 1-week history of itching and progressive rash. She has no history of skin problems or associated symptoms. She takes no medications. Her sister with whom she shares a room had similar symptoms during the previous week. The patient's temperature is 36.8°C (98.2°F). There are multiple 2- to 5-mm erythematous papules over the trunk, especially at the waistline, and over the forearms, hands, and fingers. There is no lymphadenopathy or hepatosplenomegaly. Which of the following is the most likely causal organism?
- (A) Epstein-Barr virus
  - (B) Group A streptococcus
  - (C) Measles virus
  - (D) *Sarcoptes scabiei*
  - (E) Varicella-zoster virus
101. A hospitalized 57-year-old man has had severe progressive pain in his left knee since awakening 2 hours ago. He was admitted to the hospital 2 days ago for an acute myocardial infarction. Cardiac catheterization showed occlusion of the left anterior descending artery, and he underwent placement of a stent. Current medications include aspirin, metoprolol, lisinopril, simvastatin, clopidogrel, and heparin. Vital signs are within normal limits. Examination of the knee shows a large effusion. The knee is hot to touch and erythematous. He holds the knee in 30 degrees of flexion; the pain is exacerbated with further flexion or extension. Laboratory studies show:

Hematocrit	40%
Leukocyte count	13,000/mm <sup>3</sup>
Serum	
Ca <sup>2+</sup>	9.2 mg/dL
Urea nitrogen	15 mg/dL
Creatinine	1.0 mg/dL
Albumin	3.6 g/dL

An x-ray of the left knee shows calcification of the synovium. Which of the following is the most likely diagnosis?

- (A) Deep venous thrombosis
- (B) Gonorrhea
- (C) Gout
- (D) Hemarthrosis
- (E) Pseudogout
- (F) Septic arthritis



102. A 67-year-old woman comes to the physician 1 month after noticing a nontender nodule on the back of her left hand. She initially thought it was an insect bite, but it has grown in size over the past week. It bleeds when she picks at it. She has no history of serious illness. She lives in a retirement community in Florida and frequently plays golf and tennis. Examination of the dorsum of the left hand shows a 2.5-cm lesion. Photographs of the lesion are shown. Which of the following is the most appropriate next step in management?
- (A) Observation
  - (B) Topical application of fluorouracil
  - (C) Sentinel lymph node biopsy
  - (D) Cryosurgery
  - (E) Excision of the lesion
- 
103. A 6-year-old boy is brought to the emergency department 2 hours after injuring his arm when he fell out of a tree. His mother says that he is extremely active and likes to climb. During the past year, he fractured his right tibia after falling off a trampoline and sustained a concussion after falling off his bicycle. She says that his teachers reprimand him frequently for running wildly in the classroom, talking excessively, and getting out of his seat; he often forgets to turn in his homework. His parents are currently divorcing. His father has a history of illicit drug use. The patient is at the 50th percentile for height and weight. His pulse is 80/min, and blood pressure is 100/80 mm Hg. Physical examination shows a dislocated left shoulder, healing abrasions over the elbows, and ecchymoses in various stages of healing over the knees. Mental status examination shows a neutral affect. He says that he likes to run and climb trees. Which of the following is the most likely explanation for these findings?
- (A) Attention-deficit/hyperactivity disorder
  - (B) Conduct disorder
  - (C) Learning disorder
  - (D) Seizure disorder
  - (E) Age-appropriate behavior
104. A 9-month-old boy is brought to the physician because of discharge from the left ear for 1 day. He has had frequent infections since the age of 4 months. He had *Streptococcus pneumoniae* bacteremia at 4 months of age, *Haemophilus influenzae* meningitis at 5½ months of age, and *S. pneumoniae* pneumonia at 7 months of age. He also has had two episodes of otitis media during this period. He is an only child, and there is no family history of frequent infections. His immunizations are up-to-date. He is at the 20th percentile for length and 3rd percentile for weight. He is not in acute distress. Examination shows no abnormalities other than a purulent drainage from the left ear canal. Which of the following is the most likely diagnosis?
- (A) Chronic granulomatous disease of childhood
  - (B) Severe combined immunodeficiency
  - (C) Thymic-parathyroid dysplasia (DiGeorge syndrome)
  - (D) Transient hypogammaglobulinemia of infancy
  - (E) X-linked agammaglobulinemia

105. Four days after undergoing open reduction and internal fixation of a fracture of the right femur sustained in a motor vehicle collision, a 47-year-old man continues to have agitation and confusion despite treatment with haloperidol. He has mild hypertension. Other medications include acetaminophen, atenolol, and prophylactic subcutaneous heparin. His temperature is 37.2°C (99°F), pulse is 98/min, respirations are 24/min, and blood pressure is 168/98 mm Hg. During the examination, he is uncooperative and refuses to answer questions. Neurologic examination shows tremulousness and no focal findings. He is oriented to person but not to place or time. A CT scan of the head shows no abnormalities. Which of the following is the most likely cause of these findings?
- (A) Adverse effect of medication
  - (B) Alcohol withdrawal
  - (C) Fat emboli
  - (D) Sepsis
  - (E) Subdural hematoma
106. A 4-year-old girl is brought to the physician because of pallor and jaundice for 2 days. She had previously been well, although she was treated for jaundice with phototherapy for 2 weeks while a newborn. Her mother and two additional maternal relatives underwent splenectomy during childhood for unknown reasons. Examination of the patient shows jaundice. The spleen tip is palpated 4 cm below the left costal margin. Which of the following blood smear findings is most likely to explain this family's condition?
- (A) Elliptocytes
  - (B) Howell-Jolly bodies
  - (C) Schistocytes
  - (D) Sick cells
  - (E) Spherocytes
107. A 4-year-old boy is brought for a follow-up examination. He has a history of chronic recurrent otitis media and recently completed a 10-day course of antibiotics. His vital signs are within normal limits. Examination shows clear ear canals and intact tympanic membranes; a brown, irregular mass is visualized behind the tympanic membrane. Which of the following is the most likely explanation for these findings?
- (A) Epithelial tissue proliferation
  - (B) Lingual papillae loss
  - (C) Middle ear effusion
  - (D) Midface hypoplasia
  - (E) Nerve entrapment
  - (F) Olfactory hair cell degeneration
  - (G) Semicircular canal edema
  - (H) Tympanic membrane rupture
108. An 87-year-old woman is brought to the physician by her son because of progressive memory loss over the past 2 years. Her son says that she repeats herself frequently and has been forgetting to take her routine medications. She takes hydrochlorothiazide for mild systolic hypertension and levothyroxine for hypothyroidism. She had vulvar cancer 10 years ago treated with wide excision. Her blood pressure is 138/78 mm Hg. Physical examination is within normal limits for her age. Mini-Mental State Examination score is 23/30. Laboratory studies, including serum vitamin B<sub>12</sub> (cyanocobalamin), thyroxine (T<sub>4</sub>), and thyroid-stimulating hormone concentrations, are within normal limits. A CT scan of the head shows mild volume loss. Which of the following is the most appropriate pharmacotherapy?
- (A)  $\beta$ -Adrenergic agonist
  - (B) Cholinesterase inhibitor
  - (C) Dopamine agonist
  - (D) Prednisone
  - (E) Selective serotonin reuptake inhibitor

109. A 19-year-old college student comes to the physician because of vaginal irritation and pain with urination for 5 days. Two weeks ago, she had streptococcal pharyngitis treated with amoxicillin. She has been sexually active with two partners over the past year; she uses condoms for contraception. Her last menstrual period was 1 week ago. Her temperature is 37.2°C (99°F), and blood pressure is 90/60 mm Hg. Pelvic examination shows erythema of the vulva and vagina and a thick white vaginal discharge. The pH of the discharge is 4. Which of the following is the most likely cause of these findings?
- (A) Bacterial vaginosis
  - (B) Candidiasis
  - (C) *Chlamydia trachomatis* infection
  - (D) *Escherichia coli* infection
  - (E) *Neisseria gonorrhoeae* infection
  - (F) Trichomoniasis
110. A 10-year-old boy is brought for a follow-up examination 2 days after he was seen in the emergency department because of hives, hoarseness, and light-headedness. His symptoms began 15 minutes after he was stung by a bee and lasted approximately 60 minutes; they resolved before he was treated. He has been stung by bees three times over the past year, and each reaction has been more severe. Examination shows no abnormalities. Which of the following is the most appropriate recommendation to prevent future morbidity and mortality from this condition?
- (A) Avoid areas known to have bees
  - (B) Avoid wearing colorful clothing outside
  - (C) Carrying diphenhydramine tablets
  - (D) Carrying self-injectable epinephrine
  - (E) Seek immediate medical attention following any future sting
111. A 37-year-old woman comes to the physician because of a 1-day history of throbbing facial pain. She describes the pain as 7 out of 10 in intensity. Over the past 9 days, she has had nasal congestion, purulent nasal discharge, sore throat, and a nonproductive cough. She does not smoke. Her husband and children have had no recent illness. Her temperature is 38.5°C (101.3°F). Examination shows congested nasal mucosa and purulent discharge on the left. There is tenderness to palpation over the left cheek and no transillumination over the left maxillary sinus. The tympanic membranes are normal, and there is no erythema of the throat. Examination shows no cervical adenopathy. The lungs are clear to auscultation. Which of the following is the most likely causal organism?
- (A) *Haemophilus influenzae* type b
  - (B) *Moraxella catarrhalis*
  - (C) *Staphylococcus aureus*
  - (D) *Streptococcus pneumoniae*
  - (E) *Streptococcus pyogenes* (group A)
112. A previously healthy 19-year-old college student comes to student health services 24 hours after the onset of headache, stiff neck, and sensitivity to light. She does not recall any sick contacts. She had chickenpox at the age of 7 years. Her most recent examination 1 year ago included PPD skin testing and showed no abnormalities. She takes a daily multivitamin and an herbal weight-loss preparation. She received all appropriate immunizations during childhood but has not received any since then. She does not smoke, drink alcohol, or use illicit drugs. There is no family history of serious illness. She appears lethargic. Her temperature is 39.1°C (102.4°F), pulse is 112/min, respirations are 20/min, and blood pressure is 100/68 mm Hg. Examination shows diffuse petechiae. Kernig and Brudzinski signs are present. The remainder of the examination shows no abnormalities. A lumbar puncture is performed. Cerebrospinal fluid (CSF) analysis shows numerous segmented neutrophils and a decreased glucose concentration. A Gram stain of the CSF shows gram-negative cocci. Which of the following is the most appropriate pharmacotherapy?
- (A) Ceftriaxone
  - (B) Clindamycin
  - (C) Erythromycin
  - (D) Metronidazole
  - (E) Vancomycin

113. An asymptomatic 52-year-old man comes for a follow-up examination 1 month after he passed renal calculi. He has a history of renal calculi 2 years ago. Serum uric acid and calcium concentrations and urinary oxalate excretion are within normal limits. Urinary calcium excretion is increased. In order to avoid recurrence of renal calculi, which of the following is the most appropriate pharmacotherapy for this patient?

- (A) Bicarbonate
- (B) Calcium lactate
- (C) Methenamine mandelate
- (D) Probenecid
- (E) Thiazide diuretic

114. A 27-year-old man comes to the physician for a routine health maintenance examination. He says he feels well and has not had any problems. He has no history of serious illness. He occasionally takes acetaminophen for headaches. His brother had kidney failure at the age of 32 years. There is no family history of liver disease. The patient does not smoke. He occasionally drinks a beer or a glass of wine. He has never used intravenous illicit drugs. He has had 10 lifetime male sexual partners and uses condoms consistently. He has been in a monogamous relationship for the past 3 years. His temperature is 37°C (98.6°F), pulse is 72/min, and blood pressure is 118/70 mm Hg. Examination shows no abnormalities except for mild scleral icterus. Laboratory studies show:

Hematocrit	44%
Leukocyte count	5000/mm <sup>3</sup>
Prothrombin time	11 sec (INR=1)
Serum	
Na <sup>+</sup>	141 mEq/L
K <sup>+</sup>	4.2 mEq/L
Cl <sup>-</sup>	104 mEq/L
HCO <sub>3</sub> <sup>-</sup>	24 mEq/L
Urea nitrogen	14 mg/dL
Creatinine	0.8 mg/dL
Bilirubin, total	3.0 mg/dL
Direct	0.2 mg/dL
AST	14 U/L
ALT	15 U/L

Serologic testing for hepatitis A and B is negative. Abdominal ultrasonography shows no abnormalities. Which of the following is the most likely cause of these findings?

- (A) Decreased conjugation of bilirubin
- (B) Decreased excretion of bilirubin by hepatocytes
- (C) Decreased intracellular storage of bilirubin
- (D) Delayed uptake of bilirubin
- (E) Hemolysis

115. A 32-year-old woman, gravida 2, para 1, at 8 weeks' gestation comes to the physician for her first prenatal visit. She delivered her first child spontaneously at 34 weeks' gestation; pregnancy was complicated by iron deficiency anemia. She has no other history of serious illness. Her blood pressure is 100/70 mm Hg. Examination shows no abnormalities. Ultrasonography shows a dichorionic-diamniotic twin intrauterine pregnancy consistent in size with an 8-week gestation. This patient is at increased risk for which of the following complications?

- (A) Abruptio placentae
- (B) Fetal chromosome abnormality
- (C) Hyperthyroidism
- (D) Preterm labor and delivery
- (E) Twin transfusion syndrome

116. A 37-year-old man comes to the physician because of nonradiating low back pain for 3 days. The pain began after he worked in his yard. He has not had any change in bowel movements or urination. He had one similar episode 3 years ago that resolved spontaneously. Vital signs are within normal limits. Examination of the back shows bilateral paravertebral muscle spasm. Range of motion is limited by pain. Straight-leg raising is negative. In addition to analgesia, which of the following is the most appropriate next step in management?
- (A) Bed rest
  - (B) Regular activity
  - (C) X-rays of the spine
  - (D) MRI of the spine
  - (E) Lumbar spine traction
117. A 27-year-old nurse comes to the emergency department because of nervousness, dizziness, palpitations, and excess perspiration for the past 3 hours. She has had similar episodes over the past 6 months. The symptoms improve following ingestion of orange juice or soft drinks. She says that she has had a great deal of stress. She has been drinking two alcoholic beverages daily for the past month; before this time, she seldom drank alcohol. Examination shows no abnormalities. Her serum glucose concentration is 30 mg/dL. Intravenous glucose is administered, and the patient's symptoms improve. Which of the following is the most appropriate next step in diagnosis?
- (A) Liver tests
  - (B) Measurement of serum proinsulin and insulin antibodies
  - (C) Measurement of serum cortisol and ACTH concentrations
  - (D) Measurement of serum growth hormone and plasma somatomedin-C concentrations
  - (E) Measurement of serum insulin and C-peptide concentrations
118. Three days after hospitalization for diabetic ketoacidosis, an 87-year-old woman refuses insulin injections. She says that her medical condition has declined so much that she no longer wishes to go on living; she is nearly blind and will likely require bilateral leg amputations. She reports that she has always been an active person and does not see how her life will be of value anymore. She has no family and most of her friends are sick or deceased. On mental status examination, she is alert and cooperative. She accurately describes her medical history and understands the consequences of refusing insulin. There is no evidence of depression. She dismisses any attempts by the physician to change her mind, saying that the physician is too young to understand her situation. She says, "I know I will die, and this is what I want." Which of the following is the most appropriate next step in management?
- (A) Discharge the patient after she has signed an "against medical advice" form
  - (B) Seek a court order to appoint a legal guardian
  - (C) Offer insulin but allow the patient to refuse it
  - (D) Admit to the psychiatric unit
  - (E) Administer insulin against the patient's wishes
119. A 37-year-old woman with AIDS comes to the physician because of a 1-month history of progressive diarrhea and a 1.8-kg (4-lb) weight loss. During the past week, she has had six large watery stools daily. She is currently receiving triple antiretroviral therapy. She is employed as a flight attendant and works regularly on domestic flights throughout the USA. She also flies to Asia at least once monthly. She is 163 cm (5 ft 4 in) tall and weighs 59 kg (130 lb); BMI is 22 kg/m<sup>2</sup>. Her temperature is 37°C (98.6°F), pulse is 88/min, and blood pressure is 112/64 mm Hg. The abdomen is scaphoid. The remainder of the examination shows no abnormalities. Her CD4+ T-lymphocyte count is 400/mm<sup>3</sup> (Normal ≥500). Which of the following is the most likely causal organism?
- (A) *Cryptosporidium parvum*
  - (B) Cytomegalovirus
  - (C) *Mycobacterium avium-intracellulare* complex
  - (D) *Salmonella enteritidis*
  - (E) *Strongyloides stercoralis*

120. A previously healthy 17-year-old girl comes to the emergency department because of a 5-day history of progressive lower abdominal pain, fever, and malodorous vaginal discharge. Menarche was at the age of 12 years, and her last menstrual period was 2 weeks ago. She is sexually active with one male partner and uses a combination contraceptive patch. Her temperature is 37.8°C (100°F), pulse is 90/min, respirations are 22/min, and blood pressure is 110/70 mm Hg. Abdominal examination shows severe lower quadrant tenderness bilaterally. Pelvic examination shows a purulent cervical discharge, cervical motion tenderness, and bilateral adnexal tenderness. Her hemoglobin concentration is 10.5 g/dL, leukocyte count is 13,000/mm<sup>3</sup>, and platelet count is 345,000/mm<sup>3</sup>. A urine pregnancy test is negative. Which of the following is the most appropriate pharmacotherapy?

- (A) Oral azithromycin
- (B) Vaginal clindamycin
- (C) Intravenous penicillin and vancomycin
- (D) Intramuscular ceftriaxone and oral doxycycline
- (E) Intravenous oxacillin and metronidazole

121. During the past month, a 37-year-old woman has had epigastric pain 2 to 3 hours after eating and at night; she has a feeling of fullness and bloating even when she eats small amounts. For 2 days, she has been unable to keep any food "down" and has had repetitive vomiting between meals. Six months ago, she was diagnosed with a peptic ulcer and was treated with a proton pump inhibitor and antibiotics. After 2 weeks of treatment, her symptoms were alleviated, and she discontinued the medication due to the quantity of pills she had to take. Placement of a Foley catheter yields no urine. This patient is most likely to have which of the following electrolyte profiles?

	Na <sup>+</sup> (mEq/L)	K <sup>+</sup> (mEq/L)	Cl <sup>-</sup> (mEq/L)	HCO <sub>3</sub> <sup>-</sup> (mEq/L)
(A)	130	2.8	88	32
(B)	130	4.2	100	24
(C)	130	4.4	100	14
(D)	148	2.3	96	24
(E)	148	4.8	110	24

122. A 42-year-old woman is brought to the emergency department 10 minutes after being involved in a high-speed motor vehicle collision in which she was a restrained passenger. On arrival, she has shortness of breath and abdominal pain. Her pulse is 135/min, respirations are 30/min, and blood pressure is 80/40 mm Hg. Breath sounds are decreased at the left lung base. An x-ray of the chest shows opacification of the left lower lung field with loss of the diaphragmatic shadow. Placement of a chest tube yields a small amount of air followed by greenish fluid. Which of the following is the most appropriate next step in management?

- (A) CT scan of the abdomen
- (B) CT scan of the chest
- (C) Thoracoscopy
- (D) Laparotomy
- (E) Thoracotomy

123. A previously healthy 27-year-old man comes to the physician 4 weeks after noticing three nontender lesions on his penis. He says they have not changed in size. He is sexually active with multiple male and female partners and uses condoms inconsistently. He takes no medications. He drinks two to five beers on social occasions. He occasionally smokes marijuana. His temperature is 36.9°C (98.4°F). There is no lymphadenopathy. Examination shows three sessile, flesh-colored lesions on the shaft of the penis that are 10 mm in diameter. On application of a dilute solution of acetic acid, the lesions turn white. The remainder of the examination shows no abnormalities. Which of the following is the most appropriate next step in management?

- (A) Topical ganciclovir therapy
- (B) Oral acyclovir therapy
- (C) Oral doxycycline therapy
- (D) Intramuscular penicillin therapy
- (E) Cryotherapy

## Sample Questions

### Block 4 (Questions 124-141)

124. A 52-year-old woman with alcoholism comes to the physician after a serum cholesterol concentration of 290 mg/dL was found on a routine screening. She drinks a pint of vodka daily. She takes captopril for hypertension and glyburide for type 2 diabetes mellitus. She also has intermittent episodes of gout. Fasting serum studies show:

Total cholesterol	252 mg/dL
HDL-cholesterol	80 mg/dL
Triglycerides	300 mg/dL
Glucose	118 mg/dL
Thyroid-stimulating hormone	4.5 $\mu$ U/mL

Which of the following is the most appropriate next step in management?

- (A) Alcohol cessation
  - (B) Better control of diabetes
  - (C) Switch from captopril to calcium-channel blocking agent therapy
  - (D) Gemfibrozil therapy
  - (E) Thyroid replacement therapy
125. A 32-year-old man who is a jackhammer operator comes to the physician because of pain and swelling of his right arm for 3 days. The symptoms are moderately exacerbated by exertion. Examination of the right upper extremity shows erythema and moderate edema. Capillary refill time is less than 3 seconds. Which of the following is the most likely diagnosis?
- (A) Axillary-subclavian venous thrombosis
  - (B) Deep venous valvular insufficiency
  - (C) Superficial thrombophlebitis of the basilic vein
  - (D) Superior vena cava syndrome
  - (E) Thoracic outlet syndrome
126. A healthy 7-year-old boy is brought to the physician 1 week after he was exposed for several hours to a child with chickenpox. The patient and his healthy sister have not had chickenpox. They have not received varicella vaccine. Which of the following is the most appropriate management for the patient and his sister at this time?
- (A) Administer acyclovir as prophylaxis
  - (B) Administer immune globulin, intravenously
  - (C) Administer aspirin therapy if vesicles appear
  - (D) Advise the parents to keep the siblings home from school to prevent exposing their classmates
  - (E) Inform the parents that a vesicular rash may appear at any time over the next 2 weeks
127. An 18-year-old man is brought to the emergency department 10 minutes after he sustained a stab wound to his chest. On arrival, he is unresponsive to painful stimuli. His pulse is 130/min, respirations are 8/min and shallow, and palpable systolic blood pressure is 60 mm Hg. He is intubated and mechanically ventilated, and infusion of 0.9% saline is begun. After 5 minutes, his pulse is 130/min, and blood pressure is 70/40 mm Hg. Examination shows a 2-cm wound at the left sixth intercostal space at the midclavicular line. There is jugular venous distention. Breath sounds are normal. The trachea is at the midline. Heart sounds are not audible. Which of the following is the most appropriate next step in management?
- (A) Chest x-ray
  - (B) Echocardiography
  - (C) Bronchoscopy
  - (D) Pericardiocentesis
  - (E) Placement of a right chest tube



128. A 32-year-old woman comes to the physician because of fatigue for 6 months. She has had progressively severe dyspnea on exertion for 6 weeks. She had an extensive abdominal operation 5 years ago for Crohn disease. She does not take any medications. Her temperature is 37°C (98.6°F), pulse is 62/min, respirations are 18/min, and blood pressure is 110/65 mm Hg. Examination of the thyroid gland, lungs, heart, abdomen, and extremities shows no abnormalities. Test of the stool for occult blood is negative. Laboratory studies show:

Hemoglobin	8 g/dL
Mean corpuscular volume	70 $\mu\text{m}^3$
Leukocyte count	9000/mm <sup>3</sup>
Platelet count	500,000/mm <sup>3</sup>

Which of the following is the most likely diagnosis?

- (A) Acute leukemia
  - (B) Anemia of chronic disease
  - (C) Folic acid deficiency
  - (D) Iron deficiency
  - (E) Lyme disease
  - (F) Microangiopathic hemolytic anemia
  - (G) Pernicious anemia
  - (H) Sleep apnea
129. A 37-year-old woman is brought to the emergency department 45 minutes after she was found unconscious on her apartment floor. Her coworkers became concerned when she did not arrive for work. On arrival, she is unable to provide a history. Her pulse is 96/min, respirations are 12/min, and blood pressure is 124/58 mm Hg. Examination shows erythema, warmth, and induration of the upper back, buttocks, and posterior thighs. Her serum creatine kinase activity is 10,300 U/L. Urine toxicology screening is positive for opiates and cocaine. Urine dipstick is strongly positive for blood. Microscopic examination of the urine shows pigmented granular casts and rare erythrocytes. This patient is at increased risk for which of the following conditions over the next 24 hours?
- (A) Acute respiratory distress syndrome
  - (B) Acute tubular necrosis
  - (C) Cerebral edema
  - (D) Cerebral hemorrhage
  - (E) Cocaine-induced cardiomyopathy
130. A 77-year-old woman is brought to the emergency department after collapsing at home. Six hours ago, she had the sudden onset of massive bright red rectal bleeding. On arrival, her blood pressure is 90/60 mm Hg, and pulse is 120/min. Abdominal examination shows no abnormalities. Insertion of a nasogastric tube yields clear aspirate. Her hematocrit is 28%. Which of the following is the most likely diagnosis?
- (A) Colon cancer
  - (B) Diverticulosis
  - (C) Duodenal ulcer
  - (D) Hemorrhoids
  - (E) Inflammatory bowel disease
131. A 55-year-old man has had crushing substernal chest pain on exertion over the past 6 weeks. He had a myocardial infarction 2 months ago. He takes nitroglycerin as needed and one aspirin daily. He has smoked two packs of cigarettes daily for 30 years. Examination shows normal heart sounds and no carotid or femoral bruits. Treatment with a  $\beta$ -adrenergic blocking agent is most likely to improve his symptoms due to which of the following mechanisms?
- (A) Decreasing diastolic relaxation
  - (B) Decreasing myocardial contractility
  - (C) Dilating the coronary arteries
  - (D) Peripheral vasodilation
  - (E) Preventing fibrin and platelet plugs

132. A 32-year-old woman, gravida 3, para 2, at 41 weeks' gestation is admitted to the hospital in active labor. Pregnancy has been complicated by mild asthma treated with inhaled bronchodilators. At the beginning of the second stage of labor, the cervix is 100% effaced and 10 cm dilated; the vertex is at -1 station. The fetal heart rate is reactive with no decelerations. After 10 minutes of pushing, there is a prolonged deceleration to 60/min. The patient has the acute onset of shortness of breath, rapidly develops cyanosis, and becomes unresponsive. Her pulse and blood pressure cannot be detected. Immediate resuscitation is started. Five minutes later, there is bleeding from the nose, mouth, and intravenous sites. Which of the following is the most likely diagnosis?
- (A) Amniotic fluid embolism
  - (B) Intracerebral hemorrhage
  - (C) Myocardial infarction
  - (D) Status asthmaticus
  - (E) Toxic shock syndrome
133. A 37-year-old woman comes to the physician because of shortness of breath for 3 months. Her symptoms increase with exertion. She also has had difficulty walking because of ankle pain. Two months ago, she had painful red spots on her legs for several weeks. She has not had a sore throat. She takes acetaminophen for aches and pains. Her temperature is 37.4°C (99.3°F), pulse is 90/min, respirations are 18/min, and blood pressure is 140/90 mm Hg. The lungs are clear to auscultation, and cardiac examination shows no abnormalities. An x-ray of the chest shows bilateral hilar adenopathy. Which of the following is the most likely diagnosis?
- (A) Cat-scratch disease
  - (B) Chronic lymphocytic leukemia
  - (C) Hodgkin disease
  - (D) Rubella
  - (E) Sarcoidosis
  - (F) Syphilis
  - (G) Systemic lupus erythematosus
  - (H) Tuberculosis
134. A 67-year-old woman has had fatigue, dry skin, brittle hair, swelling of the ankles, and cold intolerance for 1 year; she has gained 9 kg (20 lb) during this period. Her pulse is 55/min, and blood pressure is 150/90 mm Hg. She appears lethargic. Examination shows dry skin and a nontender thyroid gland that is enlarged to two times its normal size. There is mild edema of the ankles bilaterally. The relaxation phase of the Achilles reflex is greatly prolonged. Which of the following is the most likely diagnosis?
- (A) Chronic lymphocytic thyroiditis (Hashimoto disease)
  - (B) Defect in thyroxine ( $T_4$ ) biosynthesis
  - (C) Graves disease
  - (D) Multinodular goiter
  - (E) Riedel thyroiditis
  - (F) Thyroid cyst
  - (G) Thyroid lymphoma
  - (H) Thyroiditis
135. A 47-year-old woman comes to the physician because of persistent nonproductive cough for 6 weeks. She has not had fever or weight loss. She has hypertension treated with enalapril for the past 3 months. She does not smoke. There is no history of lung disease. She weighs 54 kg (120 lb) and is 163 cm (64 in) tall. Her temperature is 37°C (98.6°F), blood pressure is 130/80 mm Hg, pulse is 70/min, and respirations are 12/min. Examination and an x-ray of the chest show no abnormalities. Which of the following is the most likely mechanism of this patient's cough?
- (A) Decreased plasma renin activity
  - (B) Decreased serum angiotensin II concentrations
  - (C) Increased serum angiotensin I concentrations
  - (D) Increased serum bradykinin concentrations
  - (E) Increased serum histamine concentrations

136. A 32-year-old man comes to the physician because he has had difficulty focusing on tasks at work and at home during the past 2 months. He works as an automobile mechanic. He has had a lot of energy for work but often is distracted to the point that he does not complete assigned tasks. He frequently stops working on his own tasks to attempt to develop greater efficiency in his shop. He states that he is delighted with his newfound energy and reports that he now needs only 4 hours of sleep nightly. He has no history of psychiatric illness. He always performed well in school. He has a history of drinking alcohol excessively and using methamphetamines and cocaine during his 20s, but he has not consumed alcohol or used illicit drugs for the past 3 years. His temperature is 37°C (98.6°F), pulse is 60/min, and blood pressure is 125/80 mm Hg. Physical examination shows no abnormalities. On mental status examination, he describes his mood as "good." He has a labile affect. His speech is rapid in rate but normal in rhythm, and his thought process is organized. Short- and long-term memory are intact. Attention and concentration are fair; he makes no errors when performing serial sevens, and he can repeat seven digits forward and five in reverse sequence. He has had no delusions or hallucinations. Which of the following is the most likely diagnosis?

- (A) Antisocial personality disorder
- (B) Attention-deficit/hyperactivity disorder
- (C) Bipolar disorder
- (D) Borderline personality disorder
- (E) Major depressive disorder

137. A previously healthy 15-year-old boy is brought to the physician because of a 5-day history of fever, intractable nausea and vomiting, sore throat, and muscle pain. His mother has been giving him ibuprofen and amoxicillin that was remaining from a previous streptococcal throat infection. He appears ill, and his lips are parched. His temperature is 38.9°C (102°F), blood pressure is 120/74 mm Hg while supine and 100/70 mm Hg while standing, and pulse is 92/min while supine and 120/min while standing. Examination shows dry mucous membranes. The oropharynx is erythematous without exudate. There is shotty cervical adenopathy. The abdomen is soft without organomegaly. Laboratory studies show:

Serum	
Na <sup>+</sup>	138 mEq/L
Cl <sup>-</sup>	98 mEq/L
K <sup>+</sup>	3.4 mEq/L
HCO <sub>3</sub> <sup>-</sup>	21 mEq/L
Urea nitrogen	55 mg/dL
Glucose	105 mg/dL
Creatinine	1.3 mg/dL
Amylase	40 U/L
Urine	
Ketones	moderate
WBC	negative
RBC	negative
Na <sup>+</sup>	8 mEq/L
Protein	negative

Which of the following is the most likely explanation for this patient's renal insufficiency?

- (A) Acute tubular necrosis
- (B) Amoxicillin-induced acute interstitial nephritis
- (C) Ibuprofen-induced renal failure
- (D) Post-streptococcal glomerulonephritis
- (E) Severe volume depletion

138. A 6-year-old boy with cystic fibrosis is brought to the physician by his mother because his skin has been cool and clammy for 30 minutes. Earlier in the day, he had been playing outdoors, and the temperature was 99°F. When returning indoors, he was thirsty and restless. His blood pressure is 70/40 mm Hg, and pulse is 120/min. Examination shows dry mucous membranes. Serum sodium concentration is 128 mEq/L, and serum chloride concentration is 87 mEq/L. Which of the following is the most likely explanation for these findings?

(A) Excessive sweat electrolyte concentration  
(B) Excessive sweat volume  
(C) Excessive urinary output  
(D) Excessive vasopressor secretion  
(E) Inadequate sweat production

139. A 4-month-old boy is brought to the physician because of a 2-day history of fever and progressive redness around his right eye. He has had persistent diarrhea and oral candidiasis since birth and was treated for pneumococcal pneumonia at the age of 2 months. He appears ill. His temperature is 39°C (102.2°F), pulse is 130/min, and respirations are 25/min. Examination shows violaceous preseptal (periorbital) cellulitis and oral candidiasis. Laboratory studies show:

Hemoglobin	10 g/dL
Leukocyte count	3000/mm <sup>3</sup>
Segmented neutrophils	85%
Lymphocytes	15%
Platelet count	350,000/mm <sup>3</sup>
Serum	
IgA	<5 mg/dL
IgG	300 mg/dL
IgM	<5 mg/dL

Which of the following is the most likely diagnosis?

(A) AIDS  
(B) Chronic granulomatous disease  
(C) Severe combined immunodeficiency  
(D) Thymic-parathyroid dysplasia (DiGeorge syndrome)  
(E) X-linked agammaglobulinemia

140. A 67-year-old woman comes to the physician for her first influenza virus vaccination. She has a history of untreated hypertension. Her blood pressure is 160/100 mm Hg, and pulse is 100/min. Shortly after administration of the influenza virus vaccine, she develops shortness of breath, hives, and angioedema. Which of the following is most likely to have prevented this reaction?

(A) Inquiry about an egg allergy  
(B) Heterophile agglutination test  
(C) Skin test with histamine reagent  
(D)  $\beta$ -Adrenergic blocking agent therapy  
(E) Amantadine therapy  
(F) Insulin therapy  
(G) Rimantadine therapy

141. During a routine examination, a 32-year-old man has a blood pressure of 120/80 mm Hg. He is concerned because his father, grandfather, and two uncles have hypertension. He works as a systems programmer for a large computer company and frequently has to meet tight deadlines. He has smoked one pack of cigarettes daily for 10 years. He is 4.5 kg (10 lb) overweight and drinks three cups of coffee daily. Which of the following measures is most likely to reduce this patient's risk for hypertension over the next 5 years?

(A) Increase intake of dietary fiber  
(B) Restrict caffeine  
(C) Stress management  
(D) Weight loss

## Answer Sheet for Step 2 CK Sample Questions

### Block 1 (Questions 1-44)

1.____	10.____	19.____	28.____	37.____
2.____	11.____	20.____	29.____	38.____
3.____	12.____	21.____	30.____	39.____
4.____	13.____	22.____	31.____	40.____
5.____	14.____	23.____	32.____	41.____
6.____	15.____	24.____	33.____	42.____
7.____	16.____	25.____	34.____	43.____
8.____	17.____	26.____	35.____	44.____
9.____	18.____	27.____	36.____	

---

### Block 2 (Questions 45-86)

45.____	54.____	63.____	72.____	81.____
46.____	55.____	64.____	73.____	82.____
47.____	56.____	65.____	74.____	83.____
48.____	57.____	66.____	75.____	84.____
49.____	58.____	67.____	76.____	85.____
50.____	59.____	68.____	77.____	86.____
51.____	60.____	69.____	78.____	
52.____	61.____	70.____	79.____	
53.____	62.____	71.____	80.____	

---

### Block 3 (Questions 87-123)

87.____	95.____	103.____	111.____	119.____
88.____	96.____	104.____	112.____	120.____
89.____	97.____	105.____	113.____	121.____
90.____	98.____	106.____	114.____	122.____
91.____	99.____	107.____	115.____	123.____
92.____	100.____	108.____	116.____	
93.____	101.____	109.____	117.____	
94.____	102.____	110.____	118.____	

---

### Block 4 (Questions 124-141)

124.____	128.____	132.____	136.____	140.____
125.____	129.____	133.____	137.____	141.____
126.____	130.____	134.____	138.____	
127.____	131.____	135.____	139.____	

## Answer Key for Step 2 CK Sample Questions

### Block 1 (Questions 1-44)

1. A	10. G	19. A	28. B	37. B
2. B	11. F	20. D	29. B	38. E
3. A	12. E	21. E	30. E	39. B
4. C	13. A	22. D	31. D	40. D
5. D	14. D	23. B	32. A	41. A
6. B	15. E	24. A	33. D	42. E
7. D	16. B	25. B	34. B	43. B
8. C	17. F	26. C	35. B	44. B
9. F	18. D	27. A	36. B	

---

### Block 2 (Questions 45-86)

45. C	54. A	63. C	72. D	81. A
46. E	55. B	64. E	73. C	82. B
47. B	56. C	65. C	74. E	83. A
48. B	57. A	66. F	75. F	84. C
49. D	58. G	67. E	76. E	85. A
50. A	59. D	68. A	77. D	86. C
51. D	60. A	69. C	78. A	
52. B	61. D	70. B	79. A	
53. E	62. H	71. E	80. A	

---

### Block 3 (Questions 87-123)

87. D	95. C	103. A	111. D	119. A
88. D	96. E	104. E	112. A	120. D
89. D	97. D	105. B	113. E	121. A
90. C	98. F	106. E	114. A	122. D
91. B	99. B	107. A	115. D	123. E
92. D	100. D	108. B	116. B	
93. A	101. E	109. B	117. E	
94. D	102. E	110. D	118. C	

---

### Block 4 (Questions 124-141)

124. A	128. D	132. A	136. C	140. A
125. A	129. B	133. E	137. E	141. D
126. E	130. B	134. A	138. A	
127. D	131. B	135. D	139. C	