

USE OF CARBON FIBERS FOR THE REPAIR OF BOWED TENDONS: A PRELIMINARY REPORT*

S.S. van den Berg, DVM¹; K. P. Reed, DVM²; and A. Marino, PhD¹

Carbon implanted in the body in the form of thin fibers (8 microns in diameter), stimulated formation of highly cellular tissue that appeared to reinforce injured tendons and ligaments).^{1,2,5,6} A typical implant consisting of 40,000 fibers (overall diameter about 2 mm) induces tissue that results in a combined structure of carbon fibers and new tissue 8 mm in diameter.^{3,4} Our purpose was to determine whether the induced tissue conferred any clinical benefits in cases of bowed tendon in horses.

The implant operation was performed under general anesthesia with the horse in lateral recumbancy. The area between the carpus and the pastern joint was shaved, and the limb was fixed in extension to obtain the correct angle for the introduction of the instruments. After the usual pre-surgical preparations, a stab wound was made through the skin and tendon sheath to the center of the superficial flexor tendon. In the case of the deep flexor tendon, the stab wound penetrated to its center through the superficial tendon. A specially designed trocar and cannula were inserted up the center of the tendon to the level of the carpometacarpal joint. The trocar was removed and the implant (a bundle of 40,000 fibers) was placed into the tendon through the cannula. The cannula was then removed, and the tendon sheath and skin were sutured. Since the carbon fibers themselves were not intended to carry any mechanical load, they were not attached to the tendon at either end. The entire procedure was completed in 5-10 minutes.

A support bandage was applied immediately after surgery and changed every 3-4 days as needed, and the horse was confined to a stall for 6 weeks. The horse was confined in a small paddock for the next 6 weeks and then pastured during the next 6 months where it was permitted unlimited exercise. At 9 months after surgery, the horse began a 6-month training period in which it was slowly returned to its previous functional level. This study was independently performed at Pretoria, South Africa and Bossier City, Louisiana. At both study locations, the injuries treated ranged from mild to severe.

To compare the histological response to carbon fibers in the horse with the results obtained in other animals, carbon fibers were implanted bilaterally in one uninjured horse (the superficial flexor on the left side, the **deep** flexor on the right side). The horse was sacrificed 6 months after implantation and the tendons were removed, fixed in formalin, and prepared for viewing by scanning electron microscopy (SEM).

Authors addresses- 1 Abe Baily Professorship for Equine Medicine and Surgery Faculty of Africa. 2 Equine Medicine & Surgery Highway 3, Benton, LA. 3 Department of Orthopaedic Surgery LSU School of Medicine, Shreveport, LA

*Presented at the annual meeting of the Louisiana Veterinary Medical Association, Bossier City, Louisiana, September, 1987.

TABLE 1

Interim results regarding use of carbon fibers for treatment of bowed tendon.*

	<u>Study 1</u>	<u>Study 2</u>
Number of Horses	49 (35)	33 (33)
Number of Implants	49	42
Lost to Follow-Up	6	0
Status:		
In training	20	22
Success	15	8
Failure	8	3

*Study 1 was performed in Pretoria, South Africa and Study 2 was performed in Bossier City, Louisiana. The number of Thoroughbreds is listed in parentheses.

Preliminary results from both study locations are presented in Table I. In Study 1, success was defined as return to previous functional level. In Study 2, success was defined as a return to racing (one or more races). In Study 1, which mostly involved racing horses but also included some cross-country horses and jumpers, 49 horses (35 Thoroughbreds) were entered into the study. Of this group, 15 horses completed the training period and were clinically rated as successes; 8 animals failed to return to their previous functional level. Of the latter group, 2 exhibited failures at the site of the previous lesion and 6 animals failed either at another site on the same limb or on the other limb. In Study 2, 8 horses completed the training period and returned to racing. Five of the horses won races (a total of 17 races won), and one horse failed when racing. Three horses failed during the training period. Of the 4 failures, 1 occurred at the site of the implant.

The SEM appearance of the implant from the deep flexor tendon is shown in Figure 2. Connective tissue and cells were found throughout the implant. The nature and extent of the tissue ingrowth is similar to that seen in rabbits and goats.²⁻⁶

The aim of this study was to determine whether the tissue growth that occurs inside an implanted carbon-fiber bundle can add mechanical strength to a bowed tendon. Many previous studies have reported the tissue-induction phenomenon, and we have confirmed this observation in the horse. The question of the clinical significance of the phenomenon has been judged by its ability to permit horses to return to their previous activities. Fifteen horses have achieved this plateau in Study 1 and 8 in Study 2. These results, however are preliminary, and a final judgment regarding the efficacy of carbon fibers for treating bowed tendon can be made only after further studies.

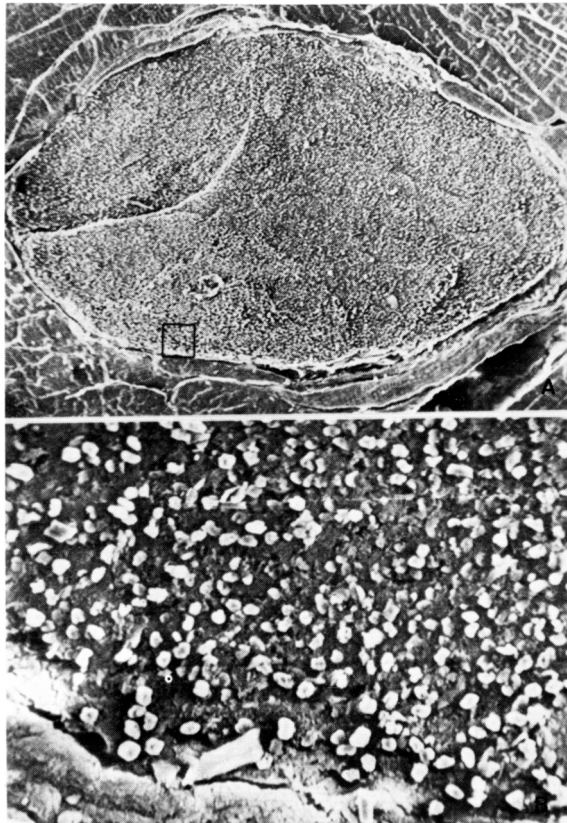


Figure 1. A SEM cross-sectional view of carbon-fiber bundle in the horse deep flexor tendon. A, cross-sectional view of the entire bundle; B, magnification of the area indicated in A. The individual carbon fibers are about 8 microns in diameter.

REFERENCES

1. Jenkins DIIR, ForsteriW, McKibbin B, Rails ZA: Induction of tendon and ligament formation by carbon implants. *J. Bone Joint Surg.* 59:53-57, 1977.
2. Marino AA, Anglin EL, Misra RP, Boudreaux, C: Biological reaction to high-strength polyethylene implants. *Trans. 32nd Ann. ORS* 11:105, 1986.
3. Marino AA, Fronczak SJ: Long-term tissue reaction to carbon fibers. In: *Biomedical Engineering V: Recent Developments, Proc. 5th Southern Biomedical Engineering Conference* pp 530-533, 1986.
4. Marino AA, Fronczak S, Boudreaux C, Lyles DN, Keating EM, Albright JA: Orthopaedic applications of carbon fibers. *IEEE, Eng. Med. & Biol.* 5:31-34, 1986.
5. Marino AA, Malakanok V, Albright J, Specian B, Keating M: Carbon-fiber reconstruction of Achilles tendons in rabbits. *Trans. 30th Ann. ORS Meeting* 9:367, 1984.
6. Specian RD, Marino AA, Albright JA: Regrowth of rabbit Achilles tendons around carbon-fiber implants. *Anal. Rev.* 211:A182-A183, 1985.