

## Herbal does not mean innocuous: Ten cases of severe hepatotoxicity associated with dietary supplements from Herbalife® products<sup>☆</sup>

Alain M. Schoepfer<sup>1</sup>, Antoinette Engel<sup>2</sup>, Karin Fattinger<sup>3</sup>, Urs A. Marbet<sup>4</sup>,  
Dominique Criblez<sup>5</sup>, Juerg Reichen<sup>6,\*</sup>, Arthur Zimmermann<sup>7</sup>, Carl M. Oneta<sup>8</sup>

<sup>1</sup>University Hospital of Bern, Gastroenterology Clinic, Bern, Switzerland

<sup>2</sup>University Hospital, Department of Medicine, Zurich, Switzerland

<sup>3</sup>Department of General Internal Medicine, Inselspital – University Hospital Bern, Bern, Switzerland

<sup>4</sup>Kantonsspital, Altdorf, Switzerland

<sup>5</sup>Department of Gastroenterology, Hospital of Luzern, Switzerland

<sup>6</sup>Department of Clinical Pharmacology, University of Bern, Murtenstrasse 35, CH301 Bern, Switzerland

<sup>7</sup>Department of Pathology, University Hospital of Bern, Switzerland

<sup>8</sup>Medical Office, Winterthur, Switzerland

See Editorial, pages 444–446

**Background/Aims:** Herbal agents are popular and perceived as safe because they are supposedly ‘natural’. We report 10 cases of toxic hepatitis implicating Herbalife® products.

**Methods:** To determine the prevalence and outcome of hepatotoxicity due to Herbalife® products. A questionnaire was sent to all public Swiss hospitals. Reported cases were subjected to causality assessment using the CIOMS criteria.

**Results:** Twelve cases of toxic hepatitis implicating Herbalife® preparations (1998–2004) were retrieved, 10 sufficiently documented to permit causality analysis. Median age of patients was 51 years (range 30–69) and latency to onset was 5 months (0.5–144). Liver biopsy (7/10) showed hepatic necrosis, marked lymphocytic/eosinophilic infiltration and cholestasis in five patients. One patient with fulminant liver failure was successfully transplanted; the explant showed giant cell hepatitis. Sinusoidal obstruction syndrome was observed in one case. Three patients without liver biopsy presented with hepatocellular (2) or mixed (1) liver injury. Causality assessment of adverse drug reaction was classified as certain in two, probable in seven and possible in one case(s), respectively.

**Conclusions:** We present a case series of toxic hepatitis implicating Herbalife® products. Liver toxicity may be severe. A more detailed declaration of components and pro-active role of regulatory agencies would be desirable.

© 2007 European Association for the Study of the Liver. Published by Elsevier B.V. All rights reserved.

**Keywords:** Herbal; Hepatotoxicity; Causality assessment; Fulminant liver failure; Cholestatic pattern; Veno-occlusive disease

Received 19 April 2007; received in revised form 4 June 2007; accepted 7 June 2007; available online 24 July 2007

Associate Editor: C.P. Day

<sup>☆</sup> The authors who have taken part in this study declared that they do not have anything to disclose regarding funding or conflict of interest with respect to this manuscript.

\* Corresponding author. Tel.: +41 31 632 31 91; fax: +41 31 632 49 97.

E-mail address: reichen@ikp.unibe.ch (J. Reichen).

### 1. Introduction

Herbal remedies and dietary supplements based on ‘natural’ ingredients are popular, over 60% of patients in the U.S. reporting such use [1]. Patients perceive them as natural and therefore safe. However, the literature abounds with reports of hepatotoxicity and other toxic effects of herbal remedies [2]. Herbal remedies are

considered dietary supplements in many countries including the U.S.; therefore, proof of neither efficacy nor safety has to be provided by the manufacturer.

Herbalife® is a product sold for promoting ‘wellness’ and weight reduction; the company reports sales of 1.6 billion \$ in 60 countries (<http://ir.herbalife.com/phoenix.zhtml?c=183888&p=irool-irhome>). We observed an index case implicating Herbalife® as a cause for fulminant hepatic failure. After observing a case of fulminant hepatic failure and reading about a second case [3] we tried to ascertain the potential for Herbalife® to cause hepatotoxicity. Therefore, we conducted a systematic survey in public Swiss hospitals, pathology departments and the Swiss pharmacovigilance database; thereby we could identify 10 well-documented cases implicating Herbalife® in potentially severe hepatotoxicity.

## 2. Materials, patients and methods

A short questionnaire was sent to all heads of the departments of medicine of Swiss public hospitals ( $n = 121$ ), divisions of gastroenterology/hepatology ( $n = 12$ ), of pathology ( $n = 16$ ) and to the Swiss pharmacovigilance database. The return rate was 75%. In the questionnaire, the following questions were asked

- Did/do you treat patients with toxic hepatitis due to herbal remedies, in particular of Herbalife?
- If so, were other causes of hepatitis excluded?
- What kind of herbal remedy do you think was the offending agent?

Based upon this questionnaire, we could identify 12 cases of potential hepatotoxicity attributable to Herbalife® products occurring between 1998 and 2004. We then requested additional information from the treating physician; patients were included if concomitant liver disease or concomitant intake of other potentially hepatotoxic drugs could be ruled out by the following criteria:

- no co-medication with known hepatotoxic potential,
- absence of the metabolic syndrome as defined by Eckel et al. [4],
- Exclusion of other metabolic ( $\alpha_1$ -antitrypsin deficiency, Wilson’s disease, hemochromatosis), viral (Hepatitis A, B, C) and autoimmune liver disease (IgG, ANA, Anti-LKM1, ASMA, SLA, ANCA, AMA).
- Exclusion of obstructive or tumorous liver disease by appropriate imaging techniques which was ultrasound in most cases.

Ten out of twelve patients met these criteria; two cases were excluded, one either because our stringent criteria were not met or another herbal product was found to be the offending agent. In the 10 remaining cases, data were rendered anonymous and assessed independently by two teams (AS and CO; KF) according to the CIOMS criteria [5]. The causality was graded by KF according to the WHO criteria for Causality Assessment of Suspected Adverse Reactions (<http://www.who-umc.org/DynPage.aspx?id=22682>).

In seven out of ten patients a liver biopsy was obtained. The liver biopsies were reviewed by an expert hepatopathologist (AZ) blinded to question(s) asked and laboratory results.

## 3. Results

Our systematic survey of public hospitals, departments of pathology and the regulatory authority

yielded 10 cases of hepatotoxicity potentially involving Herbalife® (Table 1). The median age was 51 years (range 30–69), six were female and four male. Case no. 2 has been published as a case report in a journal not referenced in Pubmed [3]. None of them were severely obese (Table 1). There was no significant co-morbidity and no apparent pre-existing liver disease except for patient no. 9 who had serological evidence of past hepatitis A and B, patient no. 1 who had evidence of hepatitis E (IgG) and patient no. 8 who consumed about 50 g of alcohol/day. Concomitant drug use was modest as reported in Table 1; none of the drugs taken are known for significant hepatotoxic potential and had been instituted in all cases at least 1 year before presentation.

Median time of onset of symptoms was 5 months (range 0.5–144 months). Prevailing clinical symptoms were fatigue, loss of appetite and jaundice. No patient exhibited signs of either allergy or extra-hepatic disease. Three patients had a complicated clinical course as described below. Liver enzymes and bilirubin levels at presentation are reported in Table 2. Seven of the 10 patients had marked hyperbilirubinemia but prothrombin time was normal in nine of the ten patients with the exception of case no. 9 with fulminant hepatic failure (see below).

All patients took Herbalife® dietary supplements for weight reduction reportedly taking the manufacturer’s recommended dose. Almost all patients were taking several Herbalife® products at the same time (Table 3). Two patients were married to a Herbalife® distributor.

In seven out of ten patients a liver biopsy was performed. Hepatic necrosis, marked lymphocytic and eosinophilic infiltration and mild to moderate cholestasis were noticed in five patients. A histological picture of this type of toxic liver injury is shown in Fig. 1. There was one case each of giant cell hepatitis and sinusoidal obstruction syndrome.

All patients are alive but one (no. 9) required liver transplantation. One patient (no. 1) presumably continues to consume Herbalife® products and has histologically proven cirrhosis but remains asymptomatic up to now.

### 3.1. Patient no. 1

This 30-year-old man experienced a first episode of painless jaundice in July 2000 from which he spontaneously recovered. A second episode of jaundice occurred in September 2000. At this time, work-up revealed positive antibodies (IgG) against hepatitis E. Liver biopsy showed acute hepatitis with dense neutrophilic and lymphocytic infiltration, multiple apoptotic bodies and discrete endophlebitis of central veins. These findings were considered to be compatible with acute hepatitis E by the local pathologist. A third episode of painless

**Table 1**  
**Patient characteristics**

No	Sex	Age	BMI (kg/m <sup>2</sup> )	Latency (months)	Co-medication	Type of liver injury according to CIOMS [5]	Histology	Re-challenge	Causality
1	M	30	33.0	26	None	Hepatocellular	Acute and chronic lobular and portal hepatitis, fibrosis of portal tracts with partially complete septa and focal nodular remodeling	Positive	Certain
2	F	63	29.7	3.5	Amiloride/HCTZ	Hepatocellular	Severe sub-acute cholestatic lobular and portal/periportal hepatitis, confluent necroses, partial portocentral bridging	Positive	Certain
3	F	52	23.3	7	None	Hepatocellular	Acute cholestatic, mixed lobular and portal hepatitis with zone 3 lobular necrosis and portocentral bridging	ND	Probable
4	F	47	28.3	4	Cyproterone/ethinyl estradiol <sup>a</sup>	Hepatocellular	Sub-acute lobular and portal hepatitis, cholestasis, minor interface activity, no fibrosis	ND	Probable
5	F	42	30.2	3	None	Hepatocellular	Acute lobular and portal hepatitis, few bile duct lesions, no fibrosis	ND	Probable
6	M	35	29.2	6	None	Hepatocellular	ND	ND	Probable
7	F	57	n/a	2	None	Mixed	ND	ND	Probable
8	M	60	n/a	17	ASA, diphenhydramine	Hepatocellular	Cholestatic hepatitis, central endophlebitis, interface lesions, ductular proliferations, septal fibrosis	± <sup>b</sup>	Probable
9	F	41	28.1	144	None	Hepatocellular	Necrotising cholestatic syncytial giant cell hepatitis, nodular regenerates	± <sup>c</sup>	Probable
10	F	69	n/a	4	Losartan	Hepatocellular	ND	ND	Possible

n/a stands for not available, ND for not done.

<sup>a</sup> The oral contraceptive (OCP) was stopped together with Herbalife products; a rechallenge with the same OCP preparation 6 weeks later was negative.

<sup>b</sup> Acetylsalicylic acid (ASA) and diphenhydramine were discontinued without any change in liver enzymes (negative dechallenge) and were therefore exculpated. For further details see narrative.

<sup>c</sup> No formal rechallenge was performed but an increase in transaminases was associated with suspected re-intake of Herbalife® products; for further details see text.

jaundice occurred in December 2001; work-up was unrevealing and a second liver biopsy showed markedly expanded portal tracts with a mixed infiltrate with numerous eosinophils and prominent interface lesions. Furthermore, there was portal and septal fibrosis with incomplete cirrhosis. An extended history revealed that the patient had been consuming various Herbalife® products since 1999 for weight loss; the products were provided by his wife, a distributor of Herbalife®. He was advised to stop his intake of Herbalife® products; thereafter, liver tests markedly decreased. In 2002, the patient resumed taking Herbalife® products with a prompt increase in liver enzymes.

### 3.2. Patient no. 8

This 60-year-old man was referred for work-up of elevated liver enzymes and jaundice. Actual medication consisted of diphenhydramine and aspirin; hepatological work-up was negative. Alcohol consumption and diphenhydramine were discontinued but liver enzymes did not normalize after 3 months off alcohol and diphenhydramine. Therefore, a liver biopsy was performed and revealed perivenular necrosis, endophlebitis and fibrotic alterations of central and sub-lobular veins consistent with sinusoidal obstruction syndrome. In addition, there was cholestasis and portal tract inflammation with

**Table 2**  
**Bilirubin and liver enzymes at presentation**

No.	Bilirubin	AST	ALT	Alkaline phosphatase	$\gamma$ -Glutamyl transpeptidase	ALT/AP
1	482	19	50	1.8	4	29
2	408	60	54	2.0	5	27
3	410	30	20	2.6	17	7
4	164	17	31	1.8	3	17
5	140	14	37	1.1	2	34
6	40	19	57	1.9	n/a	3
7	5	1	4	1.6	3	2
8	332	31	31	3.1	23	10
9	382	27	16	1.8	n/a	9
10	51	17	49	6.5	n/a	8

Bilirubin is given in  $\mu\text{mol/l}$ , the liver enzymes as fold upper limit of normal. ALT/AP ratio is given for the application of the CIOMS criteria [5].

ductular proliferation. The patient was questioned again with respect to alternative medications; he then confessed to having consumed Herbalife® products for the previous 17 months. The patient discontinued Herbalife® and liver enzymes normalized over several months. He was last seen in 2005 with an increase in liver enzymes; Herbalife® consumption was denied. A proposed liver biopsy and further follow-up were refused.

### 3.3. Patient no. 9

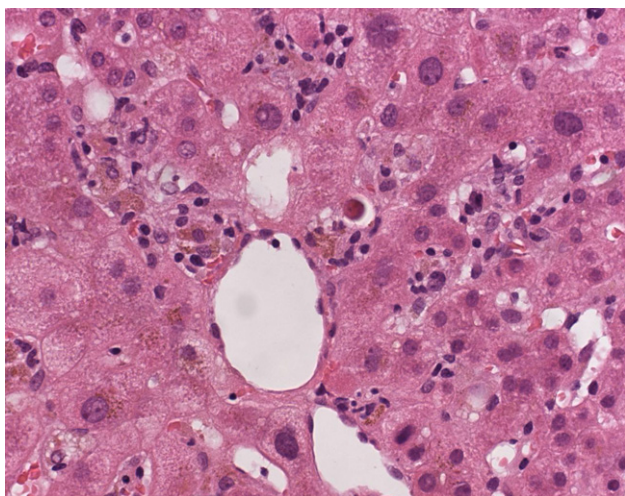
This was the index case; this 41-year-old female patient – born in Laos but living for 12 years in Switzerland – developed jaundice, fatigue and hepatic encephalopathy. Work-up revealed no cause of acute liver disease. She had antibodies against hepatitis A and B. IgG were normal, auto-antibodies negative. Because of deteriorating mental state and factor

$V < 20\%$  she was listed for super-urgent liver transplantation and successfully transplanted 7 days after admission. She was married to a distributor of Herbalife® who encouraged her to take the compound for weight control. Liver biopsy obtained shortly after admission showed sub-acute cholestatic and necrotizing hepatitis with a few giant cells (Fig. 2a). The explant showed similar changes but now nodular regenerative nodules and clear-cut cholestatic syncytial giant cells were evident (Fig. 2b). One year post transplant, there was one episode of slightly elevated liver enzymes. At that time, she was vague on Herbalife® use but was advised again to refrain from taking Herbalife®. Since then, she is doing well with normal liver enzymes 7 years after liver transplantation.

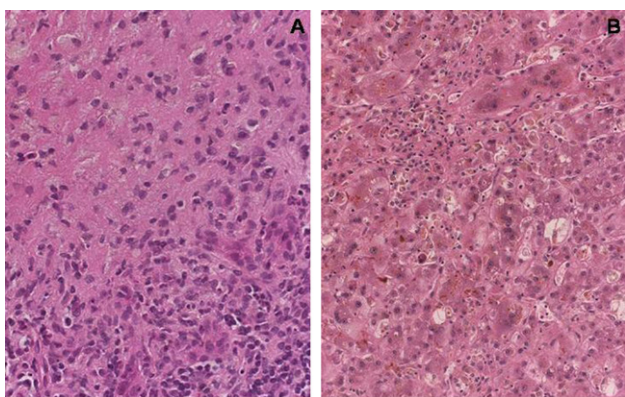
Assessment of causality performed according to WHO criteria revealed 2, 7 and 1 case(s) as certain, probable and possible, respectively (Table 1).

**Table 3**  
**Herbalife products used. No specific information could be gathered on patients no. 7 and 9**

Patient no.	1	2	3	4	5	6	8	10
Herbalife product consumed								
Shape works formula 1	X		X		X	X		
Shape works formula 2	X		X					
Shape works formula 3	X	X	X			X		X
Vitamin C capsules (herbal extract)			X					
Guarana capsules	X		X		X	X	X	
Green and beige capsules (herbal extract)		X		X	X			
Instant drink with plant extracts				X				
Protein snack			X					
RoseOx (herbal extract)	X		X				X	X
AloeMAX drink			X					
Tang Kuei Plus	X			X		X	X	X
Aloe concentrate			X					X
Shake mix Gold								
Thermojetics tea		X	X				X	X
Thermojetics green and beige			X					
Herbalifeline (fish oil concentrate)			X					X
Thermojetics protein bar			X					
Formula 5 Cell-U-Loss	X							



**Fig. 1.** Histologically, the needle biopsy shows a moderate degree of sub-acute lobular and portal hepatitis. The lobular component is characterized by hepatocyte damage, with frequent apoptotic bodies, a focal mixed, lymphocyte-predominant infiltrate, spotty necroses with pigment-laden macrophage accumulations and cholestasis.



**Fig. 2.** The needle biopsy shows sub-acute cholestatic and necrotizing hepatitis with marked hepatocyte damage, apoptotic bodies. A few syncytial giant cells are found. The large parenchymal necroses are in part already fibrosed (a). The explant shows similar changes, but the fibrotic response is now associated with cholestatic nodular regenerates, and a prominent cholestatic syncytial giant cell hepatitis is observed (b).

#### 4. Discussion

We report 10 well-documented cases implicating Herbalife® products in clinically significant hepatotoxicity. Another 12 cases are reported from Israel in another article in this issue of the journal. In three of our ten patients, potentially life-threatening liver disease occurred namely liver failure requiring urgent liver transplantation, sinusoidal obstruction syndrome and cirrhosis.

Revealing the cause of suspected hepatotoxicity in our case series was particularly difficult since Herbalife® is sold as a food supplement and our patients did not report it on conventional history taking. Only insistent questioning – often after liver biopsy raised the suspi-

cion of hepatotoxicity – revealed the cause of the underlying liver disease. Two patients continued to put themselves at risk even after conceding that Herbalife® was the cause of their liver disease.

The question arises whether Herbalife® is a threat to public health. We have uncovered 10 convincing cases over a period of 7 years in a small country (population of ~7,500,000). The company itself estimates that about 80,000 customers in Switzerland consume one or more of their products. This would lead to an estimated incidence of  $1.8/10^6$ /year, a rather low incidence. An alternative explanation is that Herbalife® products are mostly safe but that there are some products with considerable potential for hepatotoxicity. Evaluation is rendered extremely difficult by the reticence of the company to reveal the composition of its different products. Moreover, it appears that the company prepares its products in a different fashion in each country. A report from Israel in another article in this issue of the journal suggests that inadvertent contamination and/or overdose of a component can lead to clusters of hepatotoxicity.

The liver enzyme pattern was hepatocellular in nine and mixed hepatocellular/cholestatic in one patient according to International criteria [5]. Histologically, five out of seven patients in whom a biopsy was available showed cholestatic hepatitis with prominent eosinophilic infiltration. Of the others, one each showed giant cell hepatitis with massive sub-acute necrosis and sinusoidal obstruction syndrome, respectively. Giant cell hepatitis in the adult is most often due to autoimmune disease [6]; this appears rather unlikely in our patient since IgG and auto-antibodies were negative. Similarly, paramyxovirus [7] and herpes family viruses, other known causes of giant cell hepatitis, were excluded serologically. In support of her liver disease being due to Herbalife® is the suspected rechallenge after transplantation and the fact that giant cell hepatitis has been described with another herbal remedy, Isabgol, used to treat chronic constipation [8]. Another case not fitting the general pattern is case no. 8 with sinusoidal obstruction syndrome, a well-known effect of pyrrolizidine alkaloids [9]. Typically, such alkaloids are found in herbal medicines containing *Heliotropium*, *Senecio*, *Symphytum* and *Crotalaria* species [10].

Some patients developed slight to moderate fibrosis; this was severe in patient no. 1 after 1 year of intake. Rapidly progressive fibrosis has repeatedly been observed with other herbal remedies such as Jin Bu Huan [11,12].

In our series, prognosis seems to be favorable if the offending agent is identified and its intake stopped. However, severe life-threatening disease including liver failure may occur during long-term intake in particular when the patient fails to acknowledge intake of the offending agent(s). This is emphasized by a report where

10 out of 12 cases of fulminant hepatic failure, herbal medicines or dietary supplements were implicated as offending agents [13].

Herbalife® preparations are products made of ‘specially selected plants and herbs, enriched with different nutrients, oligo-elements, minerals as well as vitamins’. Usually, the exact number of admixed products as well as their exact composition is unknown. Furthermore, search for a specific hepatotoxin was complicated by the fact that all of our patients consumed at least three, but up to 12 different Herbalife® products at the same time (Table 3).

Finally, due to the retrospective manner of our study, none of the incriminated preparations were available for analysis. We can only offer the following speculations: all our patients used Herbalife® products for weight reduction. Attractive candidates include *ephedra sinica* – an ingredient of *ma huang* which has been used for centuries to induce weight loss and is reported to be present in many agents including Herbalife® [14,15]. Its active ingredient is ephedrine, a hepatotoxin known to induce lesions similar to those observed by us [14,15]. Reportedly, the company took care of removing ephedrine containing herbs some time after 2000; efforts to substantiate this with the company failed.

Another promising candidate is *N-nitroso-fenfluramine* contained in traditional Chinese herbs ‘Chaso’ or ‘Onshido’ used for weight reduction [16]. Two herbs can be identified by the text on Herbalife® bottles, namely guarana (*Paullinia cupana*) and green tea (*Camellia sinensis*). Guarana is a psychostimulans acting via liberation of caffeine with neurological and cardiologic side effects [17,18] but hepatotoxicity has not been reported. Ten cases of hepatotoxicity implicating *Camellia sinensis* have been reported of which three were certain based on a positive rechallenge [19].

Intake of herbal products is consistently underreported by patients as evidenced by some of our cases. Even worse, in our and in other case series [19,20] it is often difficult to convince the patient of the toxicity of the incriminated herbal product. This has at least the advantage that often such cases can be classified as certain based on rechallenge initiated by the patient.

In summary, we report 10 cases of hepatotoxicity associated with the intake of Herbalife® dietary supplements. The lack of labeling of contents of these products renders causality assessment impossible; regulatory agencies and lawmakers are urged, therefore, to impose such labeling in particular for products with the potential for significant toxicity of products such as Herbalife®. A high degree of suspicion and appropriate history taking is mandatory to reveal the potential for hepatotoxicity of ‘innocuous’ dietary supplements. A better declaration of the composition of these products should be mandatory and reporting of adverse events improved.

## Acknowledgments

We give our sincerest thanks to Dr Leonard Seeff, NIH, NIDDK, US, who went to extraordinary lengths to critically review our manuscript and who made many invaluable suggestions to improve the manuscript.

## References

- [1] Harnack LJ, Rydell SA, Stang J. Prevalence of use of herbal products by adults in the Minneapolis/St Paul, Minn, metropolitan area. *Mayo Clin Proc* 2001;76:688–694.
- [2] Stickel F, Patsenker E, Schuppan D. Herbal hepatotoxicity. *J Hepatol* 2005;43:901–910.
- [3] Hofmann M, Marbet UA, Hurni A, Bianchi L, Göldi H. Rezidiv einer medikamentös-toxischen Hepatitis. *Schweiz Med Forum* 2006;5:147–148.
- [4] Eckel RH, Grundy SM, Zimmet PZ. The metabolic syndrome. *Lancet* 2005;365:1415–1428.
- [5] Benichou C, Uclaf R. Criteria of drug-induced liver disorders: report of an international consensus meeting. *J Hepatol* 1990;11:272–276.
- [6] Johnson SJ, Mathew J, MacSween RNM, Bennett MK, Burt AD. Post-infantile giant cell hepatitis: histological and immunohistochemical study. *J Clin Pathol* 1994;47:1022–1027.
- [7] Phillips MJ, Blendis LM, Poucell S, Patterson J, Petric M, Roberts E, et al. Syncytial giant-cell hepatitis. Sporadic hepatitis with distinctive pathological features – a severe clinical course – and paramyxoviral features. *N Engl J Med* 1991;324:455–460.
- [8] Fraquelli M, Colli A, Cocciolo M, Conte D. Adult syncytial giant cell, chronic hepatitis due to herbal remedy. *J Hepatol* 2000;33:505–508.
- [9] Chojkier M. Hepatic sinusoidal-obstruction syndrome: toxicity of pyrrolizidine alkaloids. *J Hepatol* 2003;39:437–446.
- [10] Stedman C. Herbal hepatotoxicity. *Semin Liver Dis* 2002;22:195–206.
- [11] Picciotto A, Campo N, Brizzolaro R, Giusto R, Guido G, Sinelli N, et al. Chronic hepatitis induced by Jin Bu Huan. *J Hepatol* 1998;28:165–167.
- [12] Chitturi S, Farrell GC. Herbal hepatotoxicity: an expanding but poorly defined problem. *J Gastroenterol Hepatol* 2000;15:1093–1099.
- [13] Estes JD, Stolpman D, Olyaei A, Corless CL, Ham JM, Schwartz JM, et al. High prevalence of potentially hepatotoxic herbal supplement use in patients with fulminant hepatic failure. *Arch Surg* 2003;138:852–856.
- [14] Nadir A, Agrawal S, King PD, Marshall JB. Acute hepatitis associated with the use of a Chinese herbal product, ma-huang. *Am J Gastroenterol* 1996;91:1436–1438.
- [15] Neff GW, Reddy KR, Durazo FA, Meyer D, Marrero R, Kaplowitz N. Severe hepatotoxicity associated with the use of weight loss diet supplements containing ma huang or usnic acid. *J Hepatol* 2004;41:1062–1064.
- [16] Adachi M, Saito H, Kobayashi H, Horie Y, Kato S, Yoshioka M, et al. Hepatic injury in 12 patients taking the herbal weight loss AIDS Chaso or Onshido. *Ann Intern Med* 2003;139: 488–492.
- [17] Cuzzolin L, Zaffani S, Benoni G. Safety implications regarding use of phytomedicines. *Eur J Clin Pharmacol* 2006;62:37–42.
- [18] Haller CA, Jacob III P, Benowitz NL. Pharmacology of ephedra alkaloids and caffeine after single-dose dietary supplement use. *Clin Pharmacol Ther* 2002;71:421–432.
- [19] Bonkovsky HL. Hepatotoxicity associated with supplements containing Chinese green tea (*Camellia sinensis*). *Ann Intern Med* 2006;144:68–71.
- [20] Stickel F, Baumuller HM, Seitz K, Vasilakis D, Seitz G, Seitz HK, et al. Hepatitis induced by Kava (*Piper methysticum rhizoma*). *J Hepatol* 2003;39:62–67.