



Government of South Australia
Department of Health

SNAKEBITE & SPIDERBITE

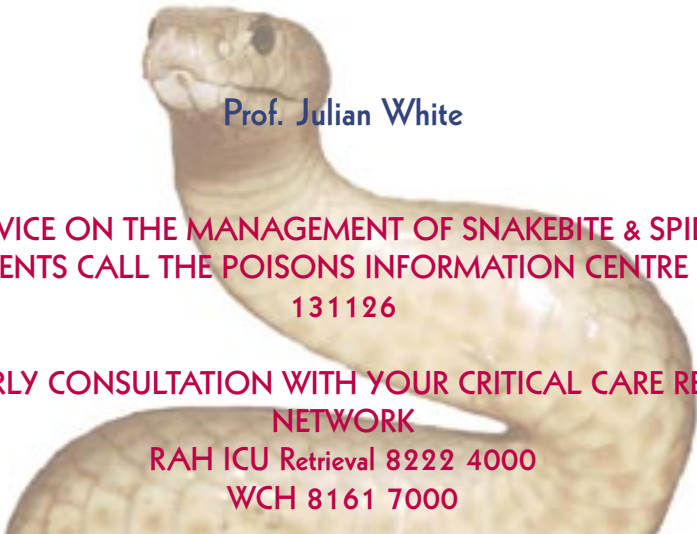Management Guidelines South Australia

Prof. Julian White

FOR ADVICE ON THE MANAGEMENT OF SNAKEBITE & SPIDERBITE
PATIENTS CALL THE POISONS INFORMATION CENTRE ON
131126

SEEK EARLY CONSULTATION WITH YOUR CRITICAL CARE REFERRAL
NETWORK

RAH ICU Retrieval 8222 4000
WCH 8161 7000



ACKNOWLEDGEMENTS

I would like to thank the many colleagues, both in SA and NSW, whose comments on the drafts and earlier versions of this document have helped improve it and also those colleagues who have shared cases of envenoming with me over the last twentyfive plus years. That shared experience, combined with the many cases I have managed personally, has formed the background knowledge on which this document is based. It is hard to single out a few from so many, but Ian Whyte, Henry Kilham and Lynda Smart all made special contributions to the realisation of the first NSW version of this project in 1998-1999, as has the NSW Critical Care Advisory Committee and it's Chair, Tony O'Connell, without whose support the project would not have eventuated. This updated revised version has had important input from Dr. Geoff Isbister and Dr. Lindsay Murray to whom I am most grateful. The support of colleagues here in SA has, and will remain, crucial in realising projects such as this. These new SA guidelines are based on the new NSW guidelines, the two being produced in tandem. However, I have added some special extras for the SA version. I am particularly grateful to the following colleagues in SA whose help has enabled me to undertake this project; Dr. Chris Baggoley, Sue Glen, Dr. Jeremy Raftos, Alan Staples, Dr. Mark Hutchinson (who also supplied some photos), Dr. Bill Giriggs.

A number of naturalist, herpetologist and arachnologist colleagues also assisted in the first version, by providing personal perspectives on distribution and abundance of venomous animals. Harrold Ehmman and Mike Gray were especially important in this process.

Lastly I would like to thank those in Adelaide whose forbearance about the time spent producing this document was crucial; my colleagues in the Division of Paediatric Medicine, Women's and Children's Hospital and my family, who have missed me most during this process.

Julian White
November 2006

Published by the Department of Health, Adelaide 2006

**Copyright © Children, Youth and Women's Health Service & Department of Health (SA)
Prof. Julian White asserts his moral right to be recognised as the author of this publication.**

**National Library of Australia Cataloguing-in-Publication:
White, Julian.**

**Snakebite & spiderbite : management guidelines South
Australia.**

ISBN 0 7308 9551 3.

- 1. Poisonous snakes - Venom - Toxicology - South Australia.**
- 2. Poisonous spiders - Venom - Toxicology - South
Australia. 3. Bites and stings - South Australia. 4.
Snakebites - South Australia. I. South Australia.
Department of Health. II. Title.**

615.942099423

**This document may be copied within Australia by medical
and paramedical staff for the purposes of patient care and
medical education.**

**DEPARTMENT OF HEALTH, GOVERNMENT OF SOUTH AUSTRALIA
December 2006**

Except where noted, all illustrations, including photos are copyright © Prof. Julian White

HOW TO USE THIS BOOK

EMERGENCY INFORMATION

This section is designed to provide brief information for rapid assimilation and use.

Brief information on the following topics may be found on the following pages:

Snakebite overview:	Page	5
Snakebite flow chart:	Page	9
Methods for determining type of snake if no venom detection result:	Page	10
Major patterns of clinical and laboratory findings after snakebite:	Page	11
Redback Spiderbite overview:	Page	14
Redback spider flowchart:	Page	15
Funnel web spiderbite overview:	Page	16
Funnel web spider flowchart:	Page	17
Marine stings/poisonings overview:	Page	18
List of recommended antivenom stocks for each hospital:	Page	71
List of venomous animals for each hospital hinterland:	Page	71

SEEK EARLY CONSULTATION WITH YOUR CRITICAL CARE REFERRAL NETWORK

RAH 8222 4000

WCH 8161 7000

Prof. White 0419-825029

Poisons Information Centre 131126

DETAILED INFORMATION

This section is designed to provide more comprehensive information, including management guidelines and details on animals of particular importance.

A detailed listing is provided in the Contents page (next page). An overview of major topics is listed below:

Snakes and snakebite:	Page	19
Management guidelines:	Page	19
Details of snakes:	Page	32
Spiders and spiderbite:	Page	58
Redback spiders:	Page	58
Funnel web spiders:	Page	60
Other arthropods:	Page	65
Marine envenoming & poisoning:	Page	18
Reading List:	Page	70

TABLE OF CONTENTS

SECTION 1 - EMERGENCY INFORMATION	3
SECTION 2 - SNAKEBITE (detailed information)	19
Protocol for Managing a Case of Snakebite in a hospital with antivenom available	19
Treatment of the envenomed or possibly envenomed patient	19
Criteria for systemic envenoming	20
Snake venom detection kit	21
Antivenom therapy	24
Antivenom dose	24
Management of anaphylaxis	25
Management of the patient who initially appears well	26
Management of the severely ill patient where the diagnosis is obscure	27
Snakebite coagulopathy - defibrination	28
Snakebite coagulopathy - anticoagulation	29
Snakebite myolysis	29
Snakebite neurotoxic paralysis	30
Follow up of snakebite patients	30
Protocol for Managing a Case of Snakebite in a Hospital Without Antivenom Available	31
Details of Major Venomous Snakes	32
Identifying snakes	32
Brown Snakes	35
Tiger Snakes	38
Rough-scaled Snake	39
Copperheads	40
Broad-headed snakes (includes Stephen's Banded Snake & Pale-headed Snake)	41
Mulga Snake or King Brown	43
Red-bellied Black Snake	44
Blue-bellied or Spotted Black Snake	45
Collett's snake	46
Death Adders	47
Taipans	48
Eastern Small-eyed Snake	50
Yellow-faced Whip Snake	50
Other Elapid Snakes	51
Scalation Comparison Table	53
SECTION 3 - SPIDERBITE & OTHER ARTHROPODS	58
Red Back Spider	58
Funnel Web Spiders	60
Protocol for managing funnel web spiderbite	60
Miscellaneous Spiders and Other Arthropods	65
Scorpions	68
SECTION 4 - RECOMMENDED READING	70
SECTION 5 - RECOMMENDED ANTIVENOM STOCKS	71

AN OVERVIEW OF SNAKEBITE MANAGEMENT

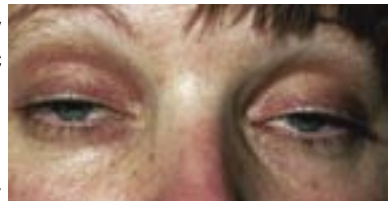Snakebite is a potential medical emergency and should always receive high priority assessment and treatment, even if the patient appears initially well. The **majority of snakebites** will not result in significant envenoming and **will not require antivenom**.

- **Beware** the patient with a history of **multiple bites**; in most such cases major envenoming will occur, requiring increased amounts of antivenom.
- **Admit all cases** of probable snakebite at least for 12 hours after the bite or after removal of effective first aid, or overnight, preferably to a high dependency ward; insert IV line, give IV fluids. No patient with suspected snakebite should be discharged in the evening or during the night or to a situation where no other adult is able to observe them over the following 24hrs.
- **Manage cases only in hospitals fully equipped to do so**, including laboratory facilities on-site, adequate stocks of appropriate antivenom.

Major problems may include one or more of the following effects of the venom (note these are principally systemic rather than local effects):

- **Paralysis**; block transmission at the neuromuscular junction causing skeletal and respiratory muscle flaccid paralysis, either presynaptic and/or postsynaptic.

SIGNS: ptosis (drooping of upper eyelids), diplopia (double vision), ophthalmoplegia (partial or complete paralysis of eye movements), fixed dilated pupils, muscle weakness, respiratory problems.



Ptosis following tiger snake bite.

- **Coagulopathy**; cause either defibrination with low fibrinogen, unclottable blood but usually normal platelet count, or direct anticoagulation, with normal fibrinogen and platelet count. Both types cause elevated prothrombin ratio (INR).

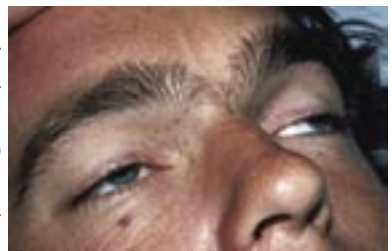SIGNS: bleeding from bite wound, venepunctures, rarely haematemesis etc; haematuria.

- **Myolysis**; cause generalised destruction of skeletal muscle with high serum CK (creatinine kinase) and myoglobinuria (red to brown urine testing positive for blood; can be confused with true haematuria), occasionally severe hyperkalaemia.

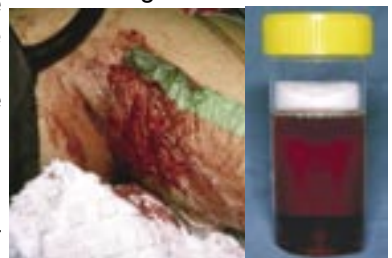SIGNS: muscle movement pain or weakness, red or brown urine.

- **Renal Damage**: primary or secondary (myolysis, coagulopathy) acute renal failure.

SIGNS: oliguria (decreased urine output), anuria (no urine output) etc.



Ptosis and partial gaze paralysis following death adder bite



Oozing from venepuncture site and dark red urine of myoglobinuria.

General symptoms include; headache, nausea, vomiting, abdominal pain, collapse, convulsions. Beware anxiety as a cause of general symptoms.

Local symptoms vary from minimal to obvious bite marks, local pain, swelling, or bruising. **A trivial looking bite site does not mean a trivial bite.** Punctures or scratches may occur.

FIRST AID - Pressure Immobilisation Bandage & Splint (PIB):

Maintain airway/breathing if impaired. Immediately apply a broad compressive bandage to the bite site at same pressure as for a sprain. Extend the bandage to cover the whole of the bitten limb including fingers/toes. Splint limb. Keep patient still; bring transport to patient. **DO NOT** give alcohol, food, stimulants, or cut the wound, or use a tourniquet. **DO NOT WASH OR CLEAN THE WOUND.** Leave PIB in place until patient arrives at a place of definitive care (hospital with appropriate antivenom etc).



IN HOSPITAL:

- **Maintain airway/breathing if impaired.**
- **Establish IV line, give IV fluid load.**
- **Admit for serial clinical observations and serial laboratory testing.** If clinical (including antivenom stocks) or laboratory facilities are inadequate, maintain PIB and arrange transfer or retrieval to an appropriate hospital.
- **Antivenom therapy** is indicated in most cases if there is any evidence of systemic envenoming detected by clinical observation or on laboratory testing. Always **consult early with the local Critical Care Referral Network and clinical toxinology/toxicology experts** if in any doubt, preferably before commencing antivenom (**Prof. White, 0419-825029; Poisons Information Centre, 131126**).
- **Removal of PIB first aid:** The bandage should not be removed until the patient is fully assessed (clinical history, examination, laboratory tests performed and results assessed, venom detection performed and result obtained), stabilised (ABC, IV line in situ, IV fluid load) and if envenomed, treatment commenced (appropriate type and dose of IV antivenom given). In a significant number of patients, initial clinical and laboratory examination will be normal, with no indication of systemic envenoming. Such patients do not require antivenom at this time and the PIB first aid should be removed. 1-2 hours later they should be fully re-evaluated, including repeat laboratory testing, or earlier if symptoms develop. Do not leave PIB in place for long periods of time, especially in a well patient. **NEVER** remove PIB first aid prior to assessing the patient, stabilising the patient, or if unable or unwilling to commence appropriate antivenom therapy.

Clinical evidence of envenoming:

- Any degree of **paralysis** (e.g. ptosis, ophthalmoplegia, limb weakness, respiratory effects).
- **Excessive bleeding** (bleeding gums, prolonged bleeding from venepuncture sites or other wounds, including the bite site).
- Period of **unconsciousness** or fitting.
- Oliguria, anuria, or myoglobinuria.
- General symptoms such as headache, vomiting, abdominal pain, but beware of these in isolation (i.e. anxiety reaction only). If all other clinical and laboratory indicators are normal, such general symptoms alone are not usually sufficient reason to commence antivenom therapy.

Laboratory evidence of envenoming:

- Laboratory tests to monitor for envenoming should include coagulation studies (INR, aPTT, fibrinogen, d-dimer), FBC/CBP, EUC and CK.
- If initial tests are normal, repeat testing at least twice, usually about 2-3 hours apart, is required, or more urgently if the patient develops clinical evidence suggestive of envenoming.
- Where laboratory testing is not rapidly accessible a whole blood clotting time (WBCT) may be performed but should not delay arrangements for transfer of the patient. (WBCT; put 10 mls venous blood into a **glass** test tube and measure time taken to clot; normal less than 10 mins).
- An INR>2 indicates a coagulopathy (unless patient is on warfarin).
- Myoglobinuria or a significantly raised CK indicates myolysis.
- Abnormally raised creatinine or urea indicates renal damage.
- Cut away bandage over bite site and swab for venom detection (**CSL Snake Venom Detection Kit**). Best sample for venom detection is bite site swab.

Snake Venom Detection Kit (SVDK):

- **Only use the SVDK** to choose which antivenom is appropriate. NEVER use it to determine if there is envenoming, or exclude snakebite.
- **Best sample is bite site swab** (moistened) - Cut away bandage over bite site and swab for venom detection. Collect at earliest opportunity after presentation to hospital; ONLY if systemic envenoming, may alternatively use urine; blood unreliable. Test takes up to 25mins, best performed in a laboratory (see page 19 for method).
- **A positive result in an envenomed patient indicates;** definite snakebite, type of antivenom to use (if required), BUT is not a sole indication to give antivenom. Give antivenom if there is clinical &/or laboratory evidence of significant systemic envenoming (see above).

NOTE: positive venom detection from the bite site does not imply systemic

envenoming and is not in itself an indication for antivenom.

- **A negative result** does not exclude either a snakebite or systemic envenoming.
- Always confirm SVDK result by comparing with result from diagnostic algorithms (see page 10) combined with knowledge of snakes in region.

ANTIVENOM (AV) THERAPY: Treatment of choice for systemic envenoming. Use monovalent in preference to polyvalent if the identity of snake is known (use snake venom detection kit, with confirmation using diagnostic algorithms combined with knowledge of snakes found in region, plus expert advice if unsure or if conflict between SVDK and diagnostic algorithm results). Do not overlook polyvalent antivenom as backup if insufficient monovalent antivenom available.

- **Always give IV, diluted** up to 1:10, depending on size of patient and volume of antivenom. Always have **adrenaline ready** drawn up or in syringe pump, in case of anaphylaxis. Commence antivenom infusion slowly, increasing rate if no adverse reactions, aiming to give whole initial dose over 15-20mins.
- Dosage varies with type of antivenom, type of snake, number of bites, but **children require same dose as adults**.
- Starting dose for major **brown snake bite** is 2-5 vials§ of CSL Brown Snake AV. For some smaller rural hospitals, the recommended stock level is only 3 vials, to be given in life threatening situations, whilst supplementation of stocks from another hospital, plus retrieval are being arranged.
- Starting dose for major **tiger snake bite** is 2-4 vials of CSL Tiger Snake AV. For some smaller rural hospitals, the recommended stock level is only 2 vials, to be given in life threatening situations, whilst supplementation of stocks from another hospital, plus retrieval are being arranged.
- Starting dose for major **taipan bite** is 1-3 vials of CSL Polyvalent or Taipan AV.
- Starting dose for major **mulga snake bite** is 1 vial of CSL Black Snake AV.
- Starting dose for major **red bellied black snake bite** is 1 vial of CSL Tiger Snake AV.
- Starting dose for major **death adder bite** is 1 vial of CSL Death Adder AV.
- One vial of CSL Polyvalent Snake AV is equivalent to 1 vial of relevant monovalent AV, as above.
- Further doses of antivenom may be required in major cases.
- If the patient has had 25mls or more AV, consider a 7 day course of prophylactic oral steroids.

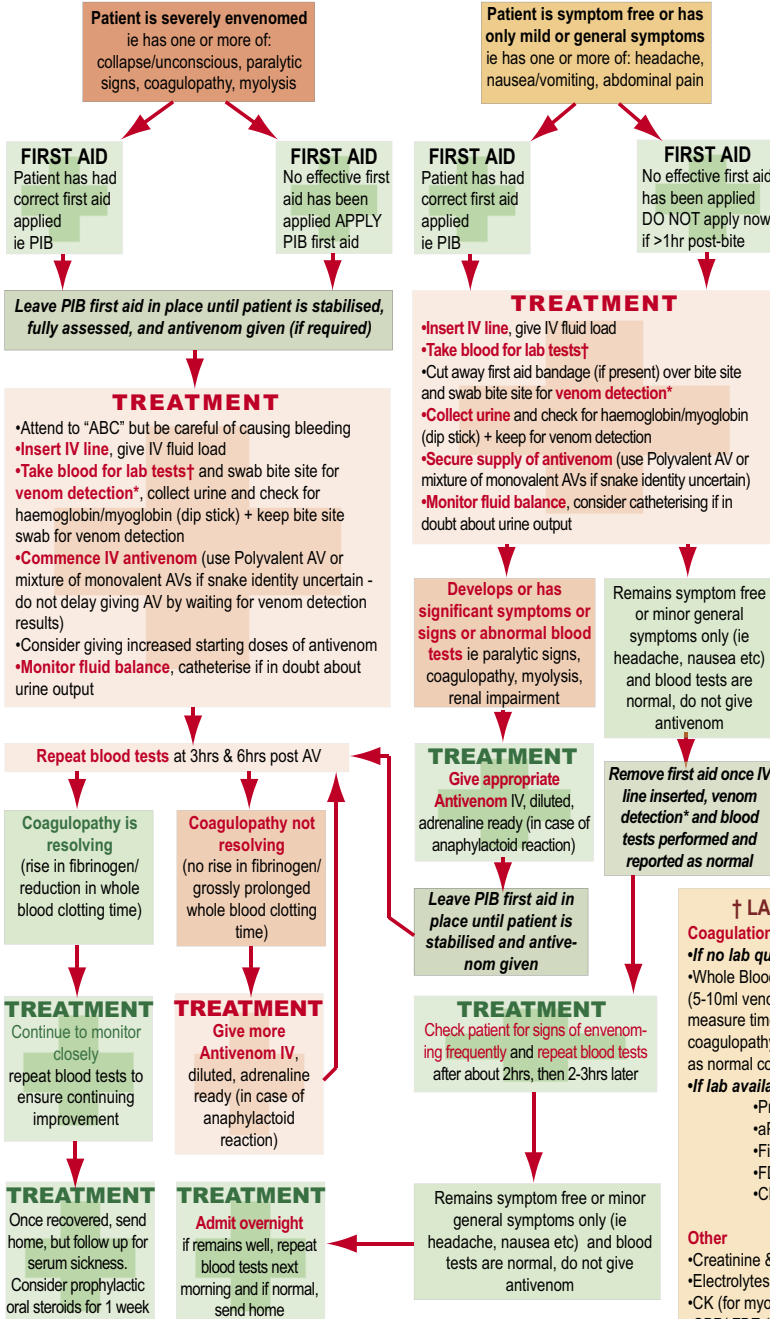
FOLLOW UP: Always ensure snakebite patients are followed up adequately, particularly if given AV, watching especially for serum sickness.

§An ongoing prospective study of Australian snakebite (ASP Study) is generating information that may allow changes in recommended initial doses of antivenom, particularly Brown Snake AV. Initial results indicate that a lower starting dose of 2 vials may be sufficient in most cases. Further research is required to define a safe initial dose if less than 5 vials are used.


SNAKEBITE MANAGEMENT CHART

Patient presents with possible snakebite

PLEASE NOTE: This chart cannot cover all possible situations and assumes an understanding of the symptoms and signs of local, general and specific envenoming by Australian venomous snakes (see Snakebite section and preceding pages). If in doubt, seek advice from the **Poisons Information Centre** (131126) and from your local **Critical Care Referral Network**



FIRST AID FOR SNAKEBITE
PIB = Broad bandage over bite site, then rest of bitten limb, including toes/fingers, at same pressure as for ankle sprain, then splint limb, keep immobile

SVDK SNAKE VENOM DETECTION KIT

 * Cut away first aid bandage over bite site only, to allow visual access and swab for venom detection
NOTE: bite site swab is best sample
 Only test urine if no bite site available AND patient has systemic envenoming
DO NOT use SVDK to determine if patient has snakebite

↑ LABORATORY TESTS

Coagulation

- If no lab quickly available
 - Whole Blood Clotting Time (WBCT) (5-10ml venous blood in glass test tube, measure time to clot; >10mins suggests coagulopathy, but test staff member's blood as normal control)
- If lab available request
 - Prothrombin time/INR
 - aPTT
 - Fibrinogen
 - FDP/ XDP (d-dimer)
 - CBP/ FBE (platelet count)

Other

- Creatinine & urea
- Electrolytes (especially K+)
- CK (for myolysis)
- CBP/ FBE (WCC for leukocytosis ± lymphopenia)

Patient Discharged Home

METHODS FOR DETERMINING TYPE OF SNAKE IF VENOM DETECTION IS NOT AVAILABLE OR HAS FAILED
DETERMINING THE MOST LIKELY SNAKE BASED ON CLINICAL FINDINGS

START HERE →

LOCAL EFFECTS OF BITE

Examine the bite site

Minimal local effects, no significant redness, swelling, bruising

Obvious redness, swelling, ± bruising

Moderate to severe local pain

Minimal or no local pain

Marked swelling after 3+ hours

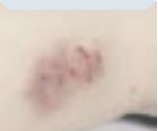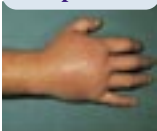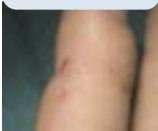Only mild swelling after 3+ hours

- ?death adder

- brown snake
- ?taipan

- mulga snake
- red bellied black snake
- yellow faced whip snake

- tiger snake
- rough scaled snake
- ?taipan



PLEASE NOTE:
 This chart cannot cover all possible situations and assumes an understanding of the symptoms and signs of local, general and specific envenoming by Australian snakes. If in doubt, seek advice from the **Poisons Information Centre (131126)** and from your local **Critical Care Referral Network**

Combine this information with the result of the systemic effects key (below) to give a best guess for the type of snake most likely to have caused the bite. Accuracy can be improved by matching this with known snake fauna for the region where the bite occurred.

SYSTEMIC EFFECTS OF BITE

Is there a coagulopathy?

Yes

No

Defibrination coagulopathy
 low fibrinogen
 raised FDP/XDP

Anti-coagulation
 normal fibrinogen & FDP/XDP

Is there paralysis?

Yes

No

Is there paralysis ± myolysis?

Yes

No

Is there paralysis?

No

Yes

Is there major myolysis?

No

Yes

Is there major myolysis?

No

- tiger snake
- rough scaled snake
- ?taipan

- brown snake
- broad headed snake or Stephen's banded snake

- mulga snake
- spotted black snake
- Collett's snake

- ?death adder
- ?copperhead

- mulga snake
- spotted black snake
- Collett's snake
- ± small eyed snake

- red bellied black snake
- yellow faced whip snake

© 1998 Dr. Julian White

§ consider possibility this is a tiger snake bite with early envenoming showing initial coagulopathy only

MAJOR PATTERNS OF CLINICAL AND LABORATORY FINDINGS AFTER AUSTRALIAN SNAKEBITE

1. Defibrination coagulopathy.

No paralysis or myolysis. Bite site usually minimal or no pain, no significant swelling, bruising or redness, but there may be ooze of blood.

Likely snakes: Brown snakes (all species except ringed brown snake) (genus *Pseudonaja*).

Broad headed snakes, including Stephen's banded snake and pale headed snake (genus *Hoplocephalus*).

2. Defibrination coagulopathy + paralysis ± mild myolysis.

Bite site variable; there may be an ooze of blood.

Likely snakes: Taipan & inland taipan (genus *Oxyuranus*).

3. Defibrination coagulopathy + paralysis + moderate to severe myolysis.

Bite site usually painful, with mild swelling, bruising, redness, there may also be an ooze of blood.

Likely snakes: Tiger snakes (genus *Notechis*).

Rough scaled snake (genus *Tropidechis*).

4. Moderate to marked myolysis + anticoagulant coagulopathy (fibrinogen normal, no raised FDP/XDP).

No paralysis (beware major myolysis mimicing paralysis). Bite site usually painful, often marked swelling, sometimes bruising. Persistent blood ooze not common.

Likely snakes: Mulga snake, Collett's snake, spotted black snake (genus *Pseudechis*).

5. Moderate to marked myolysis.

No paralysis (beware major myolysis mimicing paralysis) or coagulopathy. Bite site usually painful, often marked swelling, sometimes bruising. Persistent blood ooze not common.

Likely snakes: Mulga snake, Collett's snake, spotted black snake (genus *Pseudechis*).

Eastern small eyed snake (*Rhinoplocephalus nigrescens*).

6. Paralysis (postsynaptic; reverses with antivenom therapy) ± mild anticoagulant coagulopathy.

No myolysis. Renal damage unlikely. Bite site often painful, but with little swelling, redness or bruising. Persistent blood ooze unlikely.

Likely snakes: Death adders (genus *Acanthophis*).

7. General symptoms of envenoming (some or all of; headache, nausea, vomiting, diarrhoea, abdominal pain, dizziness, collapse).

No paralysis or coagulopathy; no or generally mild myolysis. Bite site usually painful, often marked swelling, sometimes bruising. Persistent blood ooze not common.

Likely snakes: Red bellied black snake and mild bites by spotted black snake and Collett's snake (genus *Pseudechis*).

Yellow faced whip snake and other large whip snakes (genus *Demansia*).

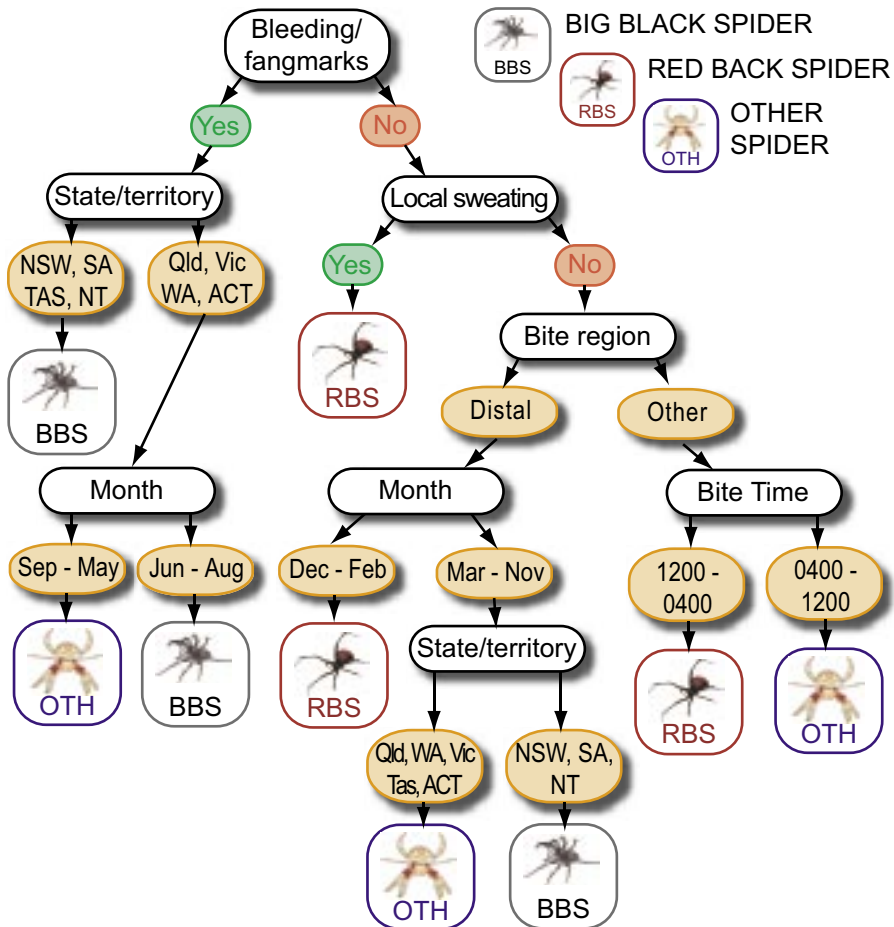
MANAGING SPIDERBITE CASES AND DECIDING ON THE LIKELY TYPE OF SPIDER OR COURSE OF MANAGEMENT

Spiders are very common. Spiderbite is common, far more frequent than snakebite, but most spiderbites are trivial and require no treatment. Two groups of spiders have the potential to cause significant envenoming; red back spiders and their kin, and funnel web spiders and their kin. It follows that the most important decision in managing a spiderbite is to decide if the spider is a possible funnel web spider (“big black spider”), a red back spider, or something else.

A diagnostic algorithm has been developed to assist in making this decision. Like all such algorithms, it cannot cover all situations and is meant as a guide only, not an absolute indicator in every situation.

To further assist in determining the type of spider, the diagrams opposite illustrate some key features that distinguish mygalomorph spiders (such as funnel web spiders and trapdoor spiders) from araneomorph spiders (most other types of spiders, including the red back spider).

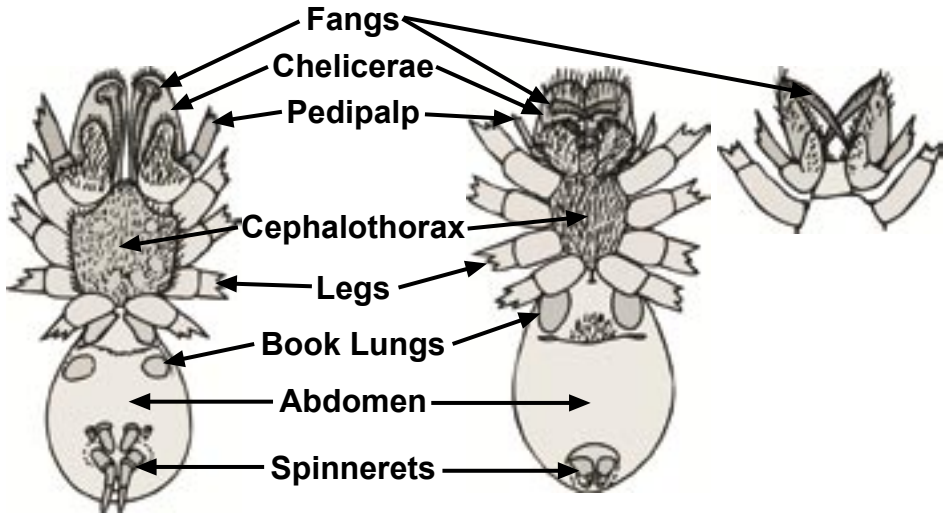
SPIDERBITE DECISION TREE (after Isbister & Sibbritt 2004)



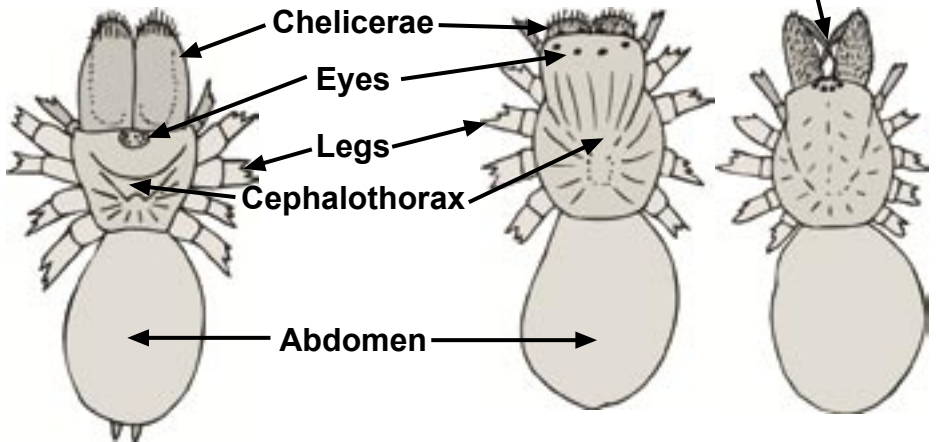
MYGALOMORPH SPIDERS

ARANEOMORPH SPIDERS

Ventral Surface (underside)



Dorsal Surface (topside)



RED BACK SPIDER

EMERGENCY OVERVIEW OF Red Back Spider Bite

Red back spider bite is common but very unlikely to prove lethal, even if untreated.

- **Significant envenoming occurs in less than 20% of cases**, but if left untreated, will result in several days of distress for the patient.
- **Only those patients who develop symptoms need assessment in hospital.** Those patients who present to hospital with no or minimal symptoms may be allowed home, but asked to ring or return if pain or other symptoms develop. Symptomatic patients should be fully assessed in hospital.
- **In those patients who do develop significant envenoming:**
 - The **bite is often felt**, usually as a mild sting.
 - A variable time later they **develop local pain** which becomes severe and is sometimes associated with local sweating.
 - The bite site is quite variable in appearance and there may be nothing to see.
 - The **pain becomes more severe and spreads** proximally, often causing pain/swelling of draining lymph nodes.
 - They **develop** regional or generalised pain, usually severe, often with **sweating** and hypertension and malaise. There may be nausea.
 - The **pain may mimic** acute abdomen or cardiac chest pain.
 - Left **untreated** with antivenom, the **symptoms may persist** for days or longer.
 - **In delayed presentation**, the pain sometimes alters to become more prominent in the legs and feet, often described as burning (even if the bite was elsewhere).
- There are **no** useful or diagnostic **laboratory tests** for red back spider bite.
- **In all cases with significant envenoming, antivenom should be considered** and in most cases will be justified.
- **Antivenom treatment**
 - **Give 2 vials IM or IV.** For IV administration dilute the antivenom in 100ml of normal saline and administer over 20mins using a pump. Always have adrenaline and full resuscitation available in case of anaphylaxis, but premedication is not required.
 - Wait 2 hours. If incomplete resolution of symptoms, give a further 2 vials IM or IV.
 - Wait 2 hours. If incomplete resolution of symptoms seek expert advice.
- **If antivenom therapy is unsuccessful** for red back bite, it is usually because not enough has been given.
- **Antivenom is effective days after the bite** (possibly longer but unproven), but the greater the delay, usually the greater amount of antivenom required.
- **If the symptoms suggest red back bite**, but there is no spider identified or uncertain history of a bite, still consider giving antivenom. It may both clinch the diagnosis and treat the patient.
- **If in any doubt ring for advice; Prof. White, 0419-825029; Poisons Information Centre, 131126.**



SIMPLIFIED FLOW CHART FOR MANAGING RED BACK SPIDERBITE

Please refer to the initial spiderbite diagnostic algorithm on page 12 to help determine if a red back spider bite is likely, before proceeding to use the chart below.

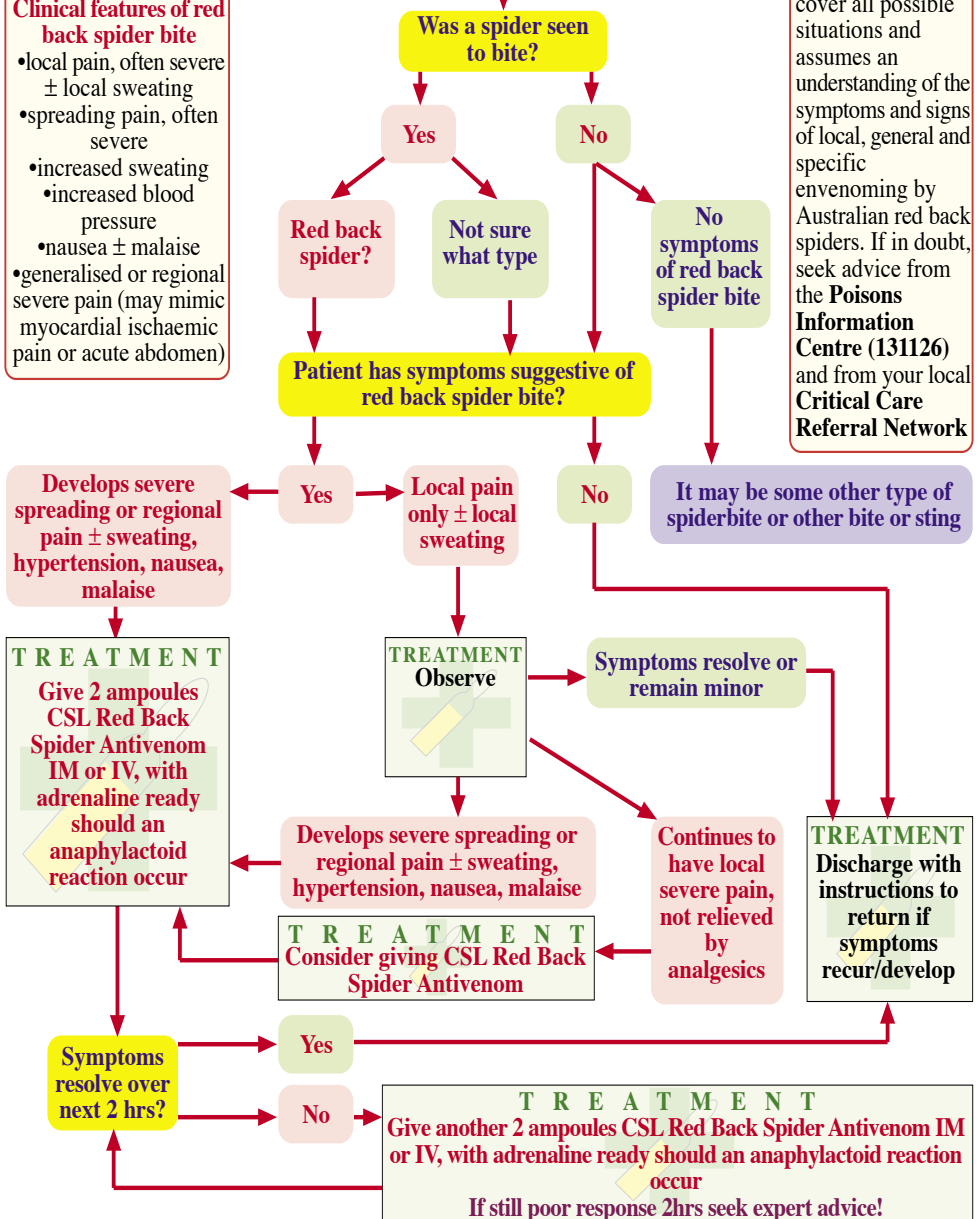
START HERE →

Patient presents with possible red back spiderbite

PLEASE NOTE:

This chart cannot cover all possible situations and assumes an understanding of the symptoms and signs of local, general and specific envenoming by Australian red back spiders. If in doubt, seek advice from the **Poisons Information Centre (131126)** and from your local **Critical Care Referral Network**

- Clinical features of red back spider bite**
- local pain, often severe ± local sweating
 - spreading pain, often severe
 - increased sweating
 - increased blood pressure
 - nausea ± malaise
 - generalised or regional severe pain (may mimic myocardial ischaemic pain or acute abdomen)



TREATMENT
Give 2 ampoules CSL Red Back Spider Antivenom IM or IV, with adrenaline ready should an anaphylactoid reaction occur

TREATMENT
Observe

TREATMENT
Consider giving CSL Red Back Spider Antivenom

TREATMENT
Discharge with instructions to return if symptoms recur/develop

TREATMENT
Give another 2 ampoules CSL Red Back Spider Antivenom IM or IV, with adrenaline ready should an anaphylactoid reaction occur
If still poor response 2hrs seek expert advice!

FUNNEL WEB SPIDERS

EMERGENCY OVERVIEW of FUNNEL WEB SPIDER BITE



Sydney funnel web spider, *Atrax robustus* - male on left, female on right

There are three species of funnel web spider found in SA, all restricted to a distribution from the southern Mount Lofty ranges to the southern Flinders Ranges. All are rarely encountered. None have caused significant bites so far, but experience with related species in eastern Australia suggests the SA species might be capable of causing major envenoming.

- **Funnel web spider bite is potentially, rapidly lethal.**
- All possible funnel web spider bites (including “big black spiders” that could be funnel web spiders) should be **managed as a medical emergency**.
- However, the **majority of bites will be minor**, not requiring antivenom.
- If the patient has presented within 3 hours of the bite or has effective first aid in place, **insert an IV line**.
- **Do not remove first aid until ready to treat with antivenom.**
- **Bite is usually painful** and fang marks are present in most cases.
- **Symptoms and signs of systemic envenoming**
 - Perioral tingling and tongue fasciculation.
 - Increased salivation, lachrymation, piloerection, sweating.
 - Nausea, vomiting, headache.
 - Hypertension, tachycardia.
 - Dyspnoea, pulmonary oedema (may occur early or be delayed several hours).
 - Irritability, decreased conscious state, coma.
- There are **no diagnostic tests** for funnel web envenoming.
- **If there are any symptoms of systemic envenoming give 2 vials of CSL Funnel Web Spider Antivenom IV** (in SA this antivenom is held at the WCH).
- **If the envenoming is severe**, with dyspnoea, pulmonary oedema or altered conscious state, **give 4 vials** of CSL Funnel Web Spider Antivenom IV.
- **Be prepared to give more antivenom** until major symptoms resolved. 8 vials is common in severe bites.
- **If in any doubt ring for advice;** Prof. White, 0419-825029; Poisons Information Centre, 131126.

SIMPLIFIED FLOW CHART FOR MANAGING FUNNEL WEB SPIDER BITE

Please refer to the initial spiderbite diagnostic algorithm on page 12 to help determine if a red back spider bite is likely, before proceeding to use the chart below.

START HERE →

Patient presents with possible funnel web spiderbite

PLEASE NOTE:
This chart cannot cover all possible situations and assumes an understanding of the symptoms and signs of local, general and specific envenoming by funnel web spiders. If in doubt, seek advice from the **Poisons Information Centre (131126)** and from your local **Critical Care Referral Network**

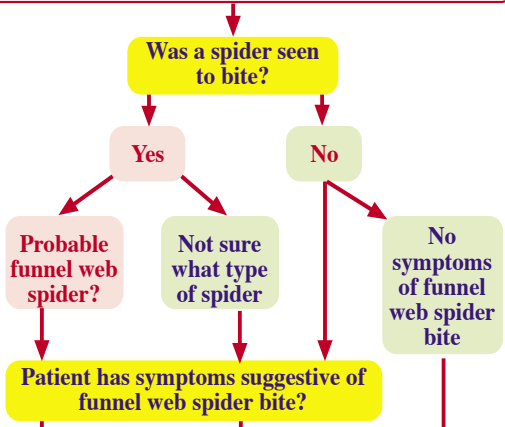
Clinical features of funnel web spider bite
LOCAL: usually have painful bite site
SYSTEMIC:
 • perioral tingling & tongue twitching
 • increased sweating, lachrymation, salivation
 • piloerection
 • hypertension
 • nausea ± malaise
 • dyspnoea - pulmonary oedema
 • decreased conscious state/coma

Develops systemic envenoming (as noted above) even if only to minor degree

TREATMENT
Apply pressure immobilisation first aid to bitten limb

TREATMENT
Give 2 ampoules (4 if severe envenoming) CSL Funnel Web Spider Antivenom IV, with adrenaline ready should an anaphylactoid reaction occur

Symptoms resolve over next 30-60 mins?



Yes
Develops systemic envenoming (as noted above) even if only to minor degree

Local pain only ± local sweating

Develops systemic envenoming (as noted above), even if only minor

TREATMENT
Observe at least 4 hrs from time of bite

IMPORTANT NOTE
If patient initially responds to antivenom, but later has relapse, especially pulmonary oedema, suspect re-envenoming and consider giving more antivenom

TREATMENT
Give more CSL Funnel Web Spider Antivenom IV, with adrenaline ready should an anaphylactoid reaction occur. Up to 8 ampoules is common for severe envenoming. If poor response or severe envenoming seek expert advice early!

TREATMENT
Discharge with instructions to return if symptoms recur/develop

MARINE VENOMOUS ANIMALS

EMERGENCY OVERVIEW OF MARINE ENVENOMING

Marine envenoming and poisoning is common.

Stingrays.

Cause both local tissue injury and local envenoming (pain).
Local tissue injury may be severe and take precedence in management.
Hot water immersion helps reduce pain.
Persistent pain may require local anaesthetic or regional nerve block.
Ensure tetanus prophylaxis.
Consider prophylactic antibiotics in cases with significant local tissue injury.
There is no antivenom available.

Spiny venomous fish (stonefish, bullrout etc.).

Local pain predominates.
Hot water immersion helps reduce pain.
Persistent pain may require local anaesthetic or regional nerve block.
Ensure tetanus prophylaxis.
Consider prophylactic antibiotics in cases with significant local tissue injury.
There is no antivenom available, except for stonefish stings.

Blue ringed octopus.

Most bites are minor, but potentially lethal.
Bite may be painless.
In significant cases, rapid development of systemic envenoming which may include: Perioral tingling. Progressive generalised weakness/paralysis. Respiratory paralysis. Hypotension.
Maintain airway, respiration (intubate, ventilate), give IV fluids \pm pressors to control hypotension. No antivenom is available.

Major jellyfish stings

Sting is usually painful. There may be weals, erythema or even blistering.
Severe allergic reactions possible.
Hot water immersion at 45 degrees Celsius or equivalent hot shower is the best method of pain relief. Treat symptomatically.
Antivenom is only available for stings by major box jellyfish species, which do not occur in SA waters. Irrigating the sting with copious vinegar is the preferred first aid; do not use PIB.

Blue bottle stings (Physalia spp.)

Sting is usually painful. Linear raised erythematous mark.
Hot water immersion at 45 degrees Celsius or equivalent hot shower is the best method of pain relief.
Occasionally rashes may last for a few days and bullous reactions occur rarely.
No antivenom is available.

If in any doubt ring for advice, Prof. White, 0419-825029; Poisons Information Centre, 131126 .

PROTOCOL FOR MANAGING A CASE OF SNAKEBITE

BASIC INFORMATION

Venomous snakebite is a medical emergency, potentially life threatening, and is NOT a simple matter of just giving antivenom. **EXPERT ADVICE** is available on **131126 (PIC) and through your local Critical Care Referral Network**.

A considerable number of snakebites do not result in significant illness, and do not require Antivenom, but **ALL probable snakebites should be admitted** for observation at least for 12+ hrs or overnight, as some serious effects may be delayed. Followup review and tests should be performed at 1-2 days post-bite.

PROTOCOL FOR MANAGING A CASE OF SNAKEBITE IN A HOSPITAL WITH ANTIVENOM AVAILABLE

[1] [a] **Possible or definite snakebite: GO TO Section [2].**

OR

[b] **The patient presents unwell, diagnosis uncertain.** There is a history of possible exposure to snakes (i.e. walking in long grass etc), and the patient has any of the following; loss of consciousness, convulsions, headache, vomiting, weakness or paralysis (initially ptosis, diplopia, slurred speech), dark urine, bleeding, renal failure; consider snakebite: **GO TO Section [7]** for advice on confirming snakebite as a diagnosis.

[2] [a] **The patient is unwell, possibly envenomed. GO TO Section [3] (below).**

OR

[b] **The patient is well, no apparent envenoming. GO TO Section [6].**

[3] **Management of the envenomed or possibly envenomed patient:**

[i] **Urgent Treatment:**

Respiratory failure: artificial ventilation; mouth to mask; bag/mask; bag/endo-tracheal tube as needed.

Circulatory failure: if cardiac arrest, cardiopulmonary resuscitation.

Insert an IV line (normal saline, give initial IV fluid load, about 500-1,000ml over 2hrs in adults, less for children, then run at maintenance, keep the patient fasted). If possible insert long line in cubital fossa or similar, to allow frequent blood sampling and avoid the need for further venepunctures. Avoid subclavian, femoral and jugular vessels, as uncontrollable haemorrhage may occur if there is a coagulopathy.

If profound hypotension, IV volume restoration/electrolyte solution. A degree of hypertension may be encountered which usually resolves.

If patient already has severe envenoming, apply pressure bandage/ immobilisation first aid (remove when initial antivenom therapy is completed).

Blood samples:

- whole blood clotting time (in glass test tube).
- coagulation studies (PT/INR, aPTT, Fibrinogen, XDP/d-dimerFDP)
- complete blood picture (CBP/FBE)

- electrolytes, renal function, CK

Avoid venepuncture in sites where bleeding may be difficult to control (i.e. femoral, neck, subclavian).

Anaphylaxis due to allergy to venom is occasionally seen: (i.e. in reptile keepers). Treat with IV adrenaline infusion (see section 5) or IM adrenaline (initial dose 0.25-0.5 mg.). For paediatric dosages see section [5] [vi].

[ii] **History:**

- was a snake seen to bite (?multiple bites) OR were the circumstances such that a bite might have occurred?
- when did the patient get bitten (elapsed time)?
- description of snake if possible (colour, length)
- geographic place that the incident occurred (snakes in area)
- timing and type of first aid and activity after the bite
- type and timing of symptoms; specifically ask about headache, nausea, vomiting, abdominal pain, blurred or double vision, slurring of speech, muscle weakness, respiratory distress, bleeding from the bite site or elsewhere, passing dark or red urine, local pain or swelling at the bite site, pain in lymph nodes draining the bite area (axilla, or groin), loss of consciousness, convulsions.
- relevant past history; specifically ask about allergy or past exposure to antivenom, atopic (allergy) history, renal, cardiac, or respiratory disease and medications (eg. anticoagulants etc).

[iii] **Examination:**

- assess patient status looking for:
- evidence of a bite (if an adequate first aid bandage is in place cut first aid bandage away from over bite site, keeping bandage from area adjacent to skin, DO NOT WASH WOUND, but SWAB FOR VENOM DETECTION; see Section [4] for technique of venom detection), and look for evidence of multiple bites, or venom movement (swollen or tender draining lymph nodes),
- neurotoxic paralysis (ptosis, diplopia, dysarthria, limb weakness, respiratory distress),
- coagulopathy (bleeding from bite site or elsewhere),
- muscle damage (muscle tenderness, pain on movement, weakness, brown or red urine indicating myoglobinuria).

[iv] **Determine if there is systemic envenoming.**

If there is then ANTIVENOM therapy will probably be needed.

Systemic envenoming is present if there is one or more of the following:

- neurotoxic paralysis (e.g. ptosis, ophthalmoplegia, limb weakness, respiratory effects)
- significant coagulopathy (e.g. unclottable blood, INR>2, prolonged bleeding from wounds, venepunctures etc.; see Section [8] for details on coagulopathy and its management)
- significant myolysis (myoglobinuria (see section [7] [ii]), significantly raised CK)
- unconsciousness or convulsions if definite snakebite

- early non-specific symptoms such as headache, vomiting, abdominal pain may indicate developing envenoming, BUT beware of these as purely manifestations of anxiety rather than envenoming. If these are the only evidence of envenoming then be cautious in deciding if antivenom is required.

If systemic envenoming is present, consider ANTIVENOM therapy; see Section [5] for guide-lines on use and techniques of administration.

[vi] **Ongoing care:**

Should include; constant nursing care, with specific instructions to look for evidence of developing paralysis (ptosis, diplopia); monitor urine output, and if in doubt then catheterise; serial respiratory function (FVC, O₂ saturation or expired CO₂); check and update tetanus immunisation status (once coagulopathy resolved); avoid unnecessary venepunctures.

- [vii] **Once situation is stabilised** it may be possible to remove all first aid. However, if the patient has severe envenoming and will require transfer to another hospital, or if there will be a delay in obtaining further supplies of antivenom, consider leaving first aid in place longer.

[4] **Venom Detection using the C.S.L. Venom Detection Kit (SVDK):**

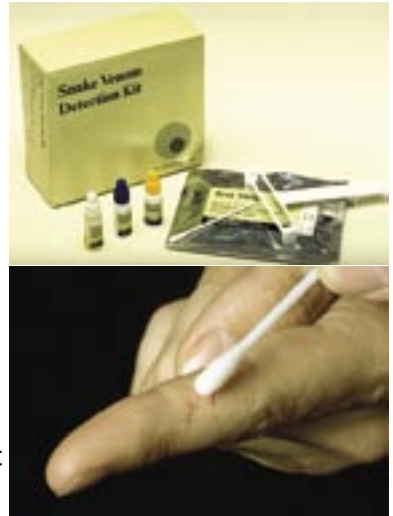- [i] The SVDK is designed to detect very small amounts of snake venom, and indicate which type of venom is present, corresponding to one of the 5 monovalent antivenoms. It does not necessarily indicate if envenoming has occurred. **A positive SVDK does not necessarily indicate that the patient needs antivenom therapy.**

- [ii] The SVDK comes in a kit including three separate test well strips, each in protective foil, but only one set of instructions, reagents and accessories. It must be kept refrigerated, though if in a lab at 22°C, it can be left out of the fridge for the 20-25mins required to perform the test.

[iii] ***The best sample is a swab from the bite site.***

Take an unused sample diluent bottle (currently yellow top) and use finger nail to lever off the dropper cap. Moisten the swab stick provided, in the solution in the bottle. Rub the swab firmly over the bite site and adjacent skin. Place the end of the swab back in the solution in the bottle and twirl around for a few moments to get venom into solution. Then proceed to use the kit as indicated in the instructions.

A positive result is indicated by a colour change (to blue) in one of the first five wells plus the positive control well (well 7), within 10



minutes in the last stage of the test, so watch all tubes carefully throughout this last 10 min. period. If one tube changes colour, all will do so eventually, but only the first tube to change is relevant.

If you get a positive result this usually indicates;

- (i) that venom was present on the skin,
- (ii) the type of snake involved,
- (iii) the appropriate monovalent antivenom to use should this be needed.

IT DOES NOT INDICATE SYSTEMIC Envenoming HAS OCCURRED AND IS NOT AN INDICATION FOR ANTIVENOM THERAPY. EQUALLY A NEGATIVE RESULT DOES NOT EXCLUDE SNAKEBITE. See notes on each type of snake for further guidance on interpretation.

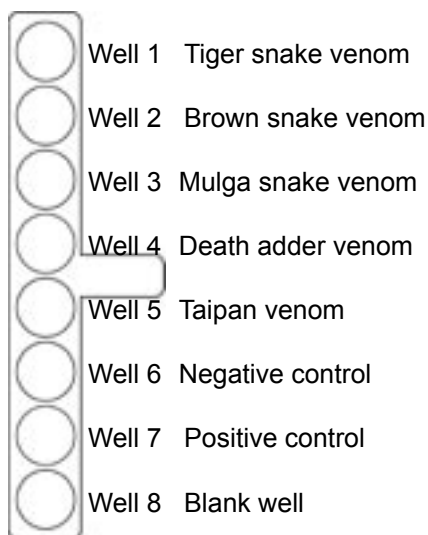
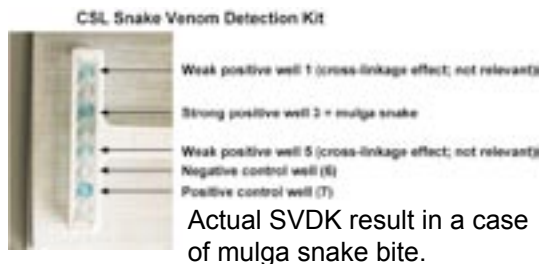Be aware that false positives from bite site swabs, though rare, are possible.



- [iv] **If the patient has evidence of systemic envenoming and the bite site is not available** for testing (i.e. been washed, or not apparent), then URINE is worth testing for venom. See kit instructions for dilutions, if necessary. Do not test urine unless the patient has evidence of systemic envenoming. Do not try and use the SVDK test on urine as a method of proving or excluding snakebite. Urine can give false positives for venom, especially brown snake venom. A positive SVDK for brown snake venom, in the absence of clinical or laboratory evidence of envenoming, such as coagulopathy, in nearly all cases should be considered a false positive and therefore of no diagnostic value.

- [v] **Blood has proved an unreliable** sample for venom testing with the SVDK, giving both false positives and false negatives. It is not recommended for use with the SVDK.

- [vi] The SVDK should not be used to determine if a snakebite is a likely diagnosis. The only purpose of the SVDK is to determine best choice of antivenom, should antivenom be indicated on clinical or laboratory grounds.

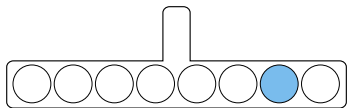


COMMON PATTERNS of SVDK VENOM DETECTION RESULTS

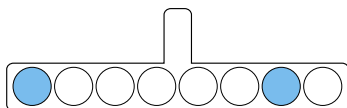
WELL NUMBER:

1 2 3 4 5 6 7 8

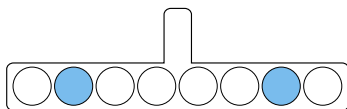
DIAGNOSTIC PATTERN:



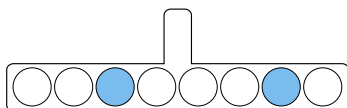
Only well 7 positive: No snake venom detected. This result does not exclude snakebite.



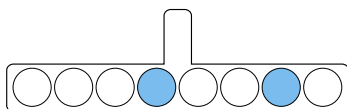
Wells 7 & 1 positive: If systemic effects include defibrination, paralysis \pm myolysis, suggests *tiger snake* or *rough scaled snake* bite. If systemic effects defibrination only, consider bite by *broad-headed*, *pale-headed* or *Stephen s banded snake*. If systemic effects are confined to paralysis, without defibrination, consider possibility of *copperhead* bite.



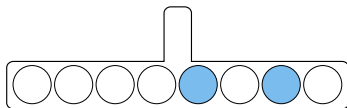
Wells 7 & 2 positive: Most likely a *brown snake* bite. If systemic envenoming develops, expect defibrination coagulopathy, \pm renal damage. Paralysis is unlikely and myolysis should not occur.



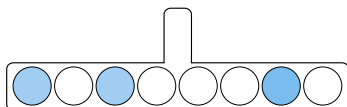
Wells 7 & 3 positive: Most likely a bite by a *mulga snake* (*king brown*) or *Collett s snake*; if systemic envenoming, expect myolysis, extensive swelling of bitten limb, \pm anticoagulant coagulopathy, \pm renal damage. **OR** Possibly a bite by a *red-bellied* or *blue-bellied (spotted) black snake*; if systemic envenoming, expect only mild myolysis, nocoagulopathy, paralysis or renal damage.



Wells 7 & 4 positive: *Death adder* bite; if systemic envenoming, expect post-synaptic paralysis, no coagulopathy, significant myolysis or renal damage.



Wells 7 & 5 positive: *Taipan* or *inland taipan* bite; systemic envenoming very likely. Expect defibrination coagulopathy, paralysis, \pm myolysis, \pm renal damage.



Wells 7, 1 & 3 positive: This pattern is sometimes seen with bites by several species. If a *copperhead* bite, if there is systemic envenoming, expect paralysis, without coagulopathy. If a *red-bellied* or *blue-bellied (spotted) black snake* bite, if there is systemic envenoming, expect only mild myolysis, no coagulopathy, paralysis or renal damage. If a *Collett s snake* bite, if there is systemic envenoming, expect myolysis, possibly anticoagulant coagulopathy, \pm renal damage.

[5] Antivenom Therapy:

[i] **Antivenom is the definitive treatment of envenoming**, and is potentially life saving but as it is currently refined horse serum, it is also potentially allergenic and therefore its use is not without risk. Therefore, **antivenom should only be used if there is systemic envenoming**. Overall less than 1 in 4 patients require antivenom therapy.

[ii] **See guide-lines in Section [3] [iv] for determining if systemic envenoming has occurred.**

IF THE TYPE OF SNAKE IS KNOWN then Monovalent Antivenom is preferred to Polyvalent (less hazardous, less side effects, less expensive). See section [4] for information on the use of Venom Detection to determine which type of antivenom to use. Check data sheet for the type of snake re particular guide-lines on use of antivenom (bites by some snakes may not need antivenom even if there is mild to moderate envenoming).

IF THE TYPE OF SNAKE IS NOT KNOWN (SVDK not available, or failed, or the patient requires Antivenom before a SVDK result is possible) then either Polyvalent Antivenom or an appropriate mixture of Monovalent Antivenoms should be used. The diagnostic algorithms in this document (page 10) may also assist in choice of antivenom. Please refer to advice sheet for your hospital to determine if there is an appropriate mix of two monovalent antivenoms for your area. In general terms, in eastern NSW, a mixture of CSL Tiger Snake Antivenom and CSL Brown Snake Antivenom will often be appropriate, providing a bite from a death adder can be excluded on grounds of description of the snake. However, there are areas where such a mix will not be sufficient, such as far north-eastern NSW where there is a chance of taipans being present.

[iii] **Antivenom administration:**

- Antivenom for snakebite should **always be given IV**, with all facilities **ready to hand to treat anaphylaxis** in the rare event that it should occur (see section [5] [vi] for a suggested regime).
- Have an IV line set up and running. Dilute the antivenom about 1:10 (1:5 or less may be needed if volume is a problem, i.e. polyvalent antivenom, paediatric patient), in IV fluid (e.g. normal saline, or Hartmans). Start infusion very slowly carefully observing patient for reaction (look for rash, hypotension, bronchospasm; in children warning signs also include nasal, palatal, or ocular pruritis, coughing, sneezing, profuse sweating, faecal or urinary urgency or incontinence, abdominal pain, and a sense of impending doom), and increase rate aiming to give whole dose over 15 to 20 minutes.

[iv] **Antivenom dose:**

- The minimum dose is one vial of the appropriate antivenom. For some antivenoms, the initial dose is higher.
- Starting dose for major **brown snake bite** is 5 vials of CSL Brown Snake Antivenom. For some smaller rural hospitals, the recommended stock level is only 3 vials, to be given in life threatening situations, whilst supplementation of

stocks from another hospital, plus retrieval are being arranged.

- Starting dose for major **tiger snake bite** is 4 vials of CSL Tiger Snake Antivenom. For some smaller rural hospitals, the recommended stock level is only 2 vials, to be given in life threatening situations, whilst supplementation of stocks from another hospital, plus retrieval are being arranged.
- Starting dose for major **taipan bite** is 3 vials of CSL Polyvalent or Taipan Antivenom.
- Starting dose for major **mulga snake bite or Collett's snake bite** is 1 vial of CSL Black Snake Antivenom.
- Starting dose for major **red bellied black snake or blue bellied black snake** bite is 1 vial of CSL Tiger Snake Antivenom.
- Starting dose for major **death adder bite** is 1 vial of CSL Death Adder Antivenom.
- One vial of CSL Polyvalent Snake Antivenom is equivalent to 1 vial of relevant monovalent antivenom, as above.
- Children require the same dose as adults.
- Multiple bites or severe envenoming mandate higher doses; increase the dose by 1-3 vials, depending on the type of antivenom, and be prepared to give more. 4 to 6 or more vials is not unusual in a severe snakebite.
- If there is a coagulopathy then the dose can be titrated against serial coagulation results (see Section [8] for guide-lines on managing coagulopathy).

[vi] **Management of anaphylaxis or anaphylactoid reaction to antivenom:**

(i) *Preparation prior to commencing antivenom.*

1. Dedicate one small bore (18-20 G in adults) IV line to antivenom administration, and one large bore IV line (16-14 G in adults) for emergency resuscitation.
2. Prepare 1L Normal Saline (20 ml/kg in children) ready to give under pressure.
3. Prepare adrenaline 1:1000 (1mg in 1 mL) drawn up to a dose of 0.01 mg/kg (max. 0.3 mg, i.e. max 0.3 mL) and label "adrenaline for i.m. injection only (dose in mg)".
4. Prepare an i.v. infusion of adrenaline 1mg in 100 mL (controlled by infusion pump or syringe driver) ready to attach by a side arm to the resuscitation line. Anti-reflux valves must be attached above the side arm on any other infusions using this i.v., to prevent adrenaline going back up into the other fluid bags. To prevent erroneous administration, do not attach the adrenaline infusion unless it is needed.
5. Record blood pressures on the other side to the fluid/adrenaline infusion, to avoid pronged cuff inflations and thus extravasation of infusion fluids.

(ii) **Management of a reaction**

Most reactions are related to the rate of antivenom infusion, and cause flushing, hypotension and bronchospasm. Some mild reactions resolve with temporary cessation of the antivenom infusion and recommencing it at a slower rate. *Envenomed patients may be severely coagulopathic*, so it is important to be cautious when giving adrenaline to avoid blood pressure surges, which might lead to intracerebral haemorrhage.

Initial management of severe reactions (sudden hypotension, bronchospasm):

- Suspend the antivenom infusion
- Lie the patient flat (if not already), commence high flow/100% oxygen and support airway/ventilation as required
- Rapid infusion of 1L N Saline (20 mL/kg in children) over 2-3 minutes
- Adrenaline i.m. into the lateral thigh, 0.01 mg/kg to maximum of 0.3 mg (alternatively, those experienced with i.v. adrenaline infusions may proceed directly to this, as below)
- Liaise with toxicology service regarding ongoing management

For reactions that do not respond to initial management:

- If hypotensive, repeat Normal Saline bolus as above (up to 50 mL/kg may be required)
- Commence i.v. infusion of adrenaline (0.5-1 mL/kg/hour, of 1 mg in 100 mL) and titrate according to response; monitor BP every 3-5 minutes (using the arm opposite to the infusion); beware that as the reaction resolves adrenaline requirements will fall, the blood pressure will rise and the infusion rate will need to be reduced
- Consider nebulised salbutamol for bronchospasm, nebulised adrenaline for upper airway obstruction, and i.v. atropine for severe bradycardia
- Seek advice urgently from the local/regional ED Consultant &/or ICU Consultant

[6] The patient appears well, no apparent evidence of envenoming.**[i] Quickly ascertain:****History:**

- was a snake seen to bite (?multiple bites) OR were the circumstances such that a bite might have occurred?
- when did the patient get bitten (elapsed time)?
- description of snake if possible (colour, length)
- geographic place that the incident occurred (snakes in area)
- timing and type of first aid and activity after the bite
- determine if there has been any evidence of envenoming; specifically ask about headache, nausea, vomiting, abdominal pain, blurred or double vision, slurring of speech, muscle weakness, respiratory distress, bleeding from the bite site or elsewhere, passing dark or red urine, local pain or swelling at the bite site, pain in lymph nodes draining the bite area (axilla, or groin), loss of consciousness, convulsions.
- relevant past history; specifically ask about allergy or past exposure to antivenom, atopic history, renal, cardiac, or respiratory disease.

Examination: - assess patient status looking for:

- evidence of a bite (if there is an adequate first aid bandage in place, cut it away from over the bite site, keeping bandage from area adjacent to skin, DO NOT WASH WOUND, but SWAB FOR VENOM DETECTION; see Section [4] (page 27) for technique of venom detection), looking for evidence of multiple bites, or venom movement (swollen or tender draining lymph nodes),
- neurotoxic paralysis (ptosis or drooping eyelids, diplopia or double vision, dysar-

- thria or slurred speech, limb weakness, respiratory distress),
- coagulopathy (bleeding from bite site or elsewhere),
- muscle damage (muscle tenderness, pain on movement, weakness, urine).

Investigations:

- whole blood clotting time in a glass tube OR
- complete blood picture (CBP/FBE/FBC)
- coagulation studies (PT/INR, aPTT, Fibrinogen, d-dimer/XDP/FDP)
- electrolytes (especially K⁺⁺), renal function, CK (for myolysis)

[ii] If after performing the above there is evidence of envenoming then proceed as for Section [3] above.

[iii] If after performing the above there is no clinical evidence of envenoming then the patient will still need admission to hospital for observation overnight, preferably to a high intensity nursing area, ensuring that nursing staff are instructed to regularly check for signs of developing envenoming, especially early signs of paralysis (e.g. ptosis, diplopia etc). If there is clear evidence of a snakebite (e.g. bite site) then insert an IV line (normal saline, run at maintenance, fast patient for first 8 hours post bite). Monitor urine output and colour, check for blood. Ensure that the duty doctor will be notified of any changes immediately, and will then personally reassess the patient.

NOTE: There is no point in leaving first aid in place if the patient is well and in hospital and the hospital is able to treat snakebite (i.e.. has the appropriate antivenom available). The first aid bandage and splint merely delays venom absorption, it does not inactivate venom, and delay in removing first aid will delay onset of definitive treatment of snakebite.

[7] Management of the severely ill patient, where diagnosis of snakebite is obscure:

[i] If the patient presents with unexplained onset of collapse, convulsions, bleeding, paralysis, rhabdomyolysis (e.g. muscle breakdown, myoglobinuria), or renal failure, in a setting where snakebite might have occurred (e.g. in rural areas, or gardens, paddocks, long grass in urban areas), and particularly in children who may give no history of exposure to snakes, then include snakebite in the differential diagnosis.

[ii] Useful tests to establish if there has been a snakebite include:

- Examine patient on exposed areas for bite marks or scratches.
- whole blood clotting time or coagulation studies to establish if there is a coagulopathy. (refer Section [8] for details of snakebite coagulopathy).
- check for myolysis; dark or red urine indicative of myoglobinuria (positive for "blood" and so may be mistaken for haematuria), elevated CK (>1000).
- test for venom in urine using SVDK (see Section [4]; page 27).
- if in doubt discuss with Clinical Toxinologist or Toxicologist at the Poisons Information Centre on 131126 or your local Critical Care Network.

- [ii] If there is clear evidence that a snakebite is the cause of the patient's illness following the above, then **GO TO Section [3]**.

If there is equivocal evidence of snakebite, seek advice as above.

[8] Snakebite Coagulopathy - Defibrination

- [i] Some snakes may cause a significant coagulopathy as part of envenoming (e.g. brown snakes, tiger snakes, rough scaled snakes, broad-headed snakes, Stephen's banded snakes, taipans). This is due to potent procoagulants in the venom, which *in vivo* cause consumption of fibrinogen and fibrinolysis; the **DEFIBRATION SYNDROME**. This may occur rapidly after onset of envenoming, and renders the blood UNCLOTTABLE, sometimes within 30 to 60 minutes of the bite. Platelets are usually unaffected. Snakebite coagulopathy can prove complex to manage, and it is preferable to treat the patient in a major hospital, with full coagulation laboratory facilities on site.

[ii] Tests for coagulopathy:

- **If there is no laboratory in your hospital**, perform a whole blood clotting time (5 to 10 ml venous blood in a glass tube, e.g. test tube, and observe time to clot; normal is less than 10 mins., if there is a coagulopathy there will be no clot at 15 mins or only a very weak clot). However, performing a WBCT is not a substitute for laboratory coagulation tests and should only be used as initial assessment while transfer to a hospital with laboratory facilities is being organised.
- At the same time take blood for later laboratory tests; most useful tests are; prothrombin ratio (INR), aPTT, fibrinogen level, and fibrin(ogen) degradation products (XDP/d-dimer or FDP). In some laboratories a thrombin clotting time (TCT) may be useful to assess fibrinogen level. A complete blood picture (CBP/FBE) should be performed for platelet count.
- In most cases a single batch of tests will not be sufficient, and serial studies will be needed.

[iii] Expected results in coagulopathy:

- Whole blood clotting time will be greater than 15 mins. or there may be only a weak clot in less severe cases (usually will not clot even after 1 hour). {normal= less than 10 mins.}
- INR (prothrombin time) grossly prolonged (>4, usually infinity). {normal= 1.0 }
- aPTT grossly prolonged (>150 secs). {normal= less than 40 secs}
- Thrombin clotting time (TCT) grossly prolonged (>150 secs). {normal 15 secs}
- NOTE: TCT may be the first parameter to show improvement as a result of antivenom therapy, dropping from >150 secs to less than 100 secs. If this occurs it probably indicates that enough antivenom has been given, despite the lack of improvement in other parameters, and so at this stage cease further antivenom therapy and repeat tests in 1 hour to confirm trend of improvement.
- **Fibrinogen level very low** (<0.1 g/l). {normal= 1.5 to 4.0 g/l}. This is the key diagnostic finding in defibrination coagulopathy.
- Fibrin(ogen) degradation products grossly elevated (XDP/d-dimer > 16). {normal=<0.25}. This is another key diagnostic finding.
- NOTE: Degradation products are in themselves anticoagulant, and at such high levels may interfere with some clotting tests, giving falsely high levels of abnor-

mality, particularly INR and aPTT on some automated coagulation machines. This may obscure the first signs of recovery.

[iv] Management principles:

- If initial studies are normal, remove PIB first aid and repeat studies after 2 hours, or sooner if the patient appears envenomed. If the second set of tests are also normal, repeat a third time, a further 3 hours later.
- If there is a significant coagulopathy (unclottable blood, or $\text{INR} > 2$ + low fibrinogen), then this must be treated. Antivenom is the treatment of choice. Replacement therapy with clotting factors (e.g. whole blood, FFP, cryoprecipitate) should be avoided as it is liable to make the coagulopathy worse if there is still active venom. Once active venom is all neutralised by antivenom normal homeostasis rapidly (sometimes within 3 hours) rectifies the problem, placing the patient out of danger (i.e. $\text{INR} < 4$), usually without need of any other treatment.
- Antivenom therapy can be titrated against the resolution of the coagulopathy, in particular, the fibrinogen level. After the initial dose of antivenom retest clotting studies at 3 and 6 hours after completion of antivenom dose. If still showing a non-resolving coagulopathy at 6 hours (ie. no significant rise in fibrinogen level), it is usually necessary to give more antivenom and repeat tests as above, continuing this process until there is evidence of resolution, but if there is no resolution after an adequate initial dose, then expert advice should be sought to determine further dosing, rather than giving ever increasing amounts of antivenom.
- NOTE that even if enough antivenom has been given, many coagulation parameters will remain abnormal for hours or days, especially fibrin(ogen) degradation products, which may remain elevated for 48hrs, longer if there is renal failure. A rise in fibrinogen level from zero to detectable is the key indicator of resolution of the defibrination coagulopathy, not a return to normal fibrinogen levels, which may take many hours. In some laboratories, the first evidence of such a rise may be a fall in the aPTT or INR, rather than a change in detectable fibrinogen titres.

[9] Snakebite Coagulopathy - Anticoagulation

- This occurs after some severe bites by mulga snakes, Collett's snakes and possibly spotted/blue bellied black snakes and is due to direct anticoagulants in the venom, which interfere with the extrinsic and, to a lesser extent, the intrinsic clotting pathways.
- This can result in a prolonged clotting time, elevated INR and aPTT, but fibrinogen levels and fibrin(ogen) degradation products are within the normal range. The INR, in particular, may be grossly elevated, occasionally > 12 . However, without a full clotting laboratory, this may be hard to ascertain, and the whole blood clotting time might be prolonged in these patients, though a clot should eventually form, unlike true defibrination coagulopathy, as discussed earlier.
- Experience has shown that persistent ooze from the bite site or elsewhere is not likely as a result of venom induced direct anticoagulation, again, different to defibrination coagulopathy. Brown snakes, tiger snakes, taipans and other species causing defibrination do not cause this direct anticoagulation, as discussed earlier.
- Antivenom is very effective at rapidly reversing direct anticoagulation

coagulopathy. Usually one vial of antivenom will suffice.

[10] Snakebite Myolysis

- This occurs most commonly after bites by tiger snakes, rough-scaled snakes and mulga snakes/king browns, but may also occur occasionally after taipan bites, while bites by red-bellied black snakes and spotted/blue-bellied black snakes may result in low level myolysis (CK 500-3,000IU).
- It is the result of widespread direct damage to striated muscle cells, resulting in complete muscle cell breakdown within 1-3 days, though damage probably commences within 1-3 hrs of venom reaching the muscle. Full recovery is possible, but will take 4+ weeks.
- The key diagnostic indicators are myoglobinuria (easily mistaken for haematuria) and a dramatic rise in plasma CK. The latter may reach figures much greater than 100,000IU. In addition, patients complain of generalised muscle pain, with tender muscles.
- The secondary effects of myolysis are renal failure and massive hyperkalaemia, which can be very difficult to control and has proven lethal.
- Once myolysis is established it is uncertain if antivenom will reverse damage, but in severe cases it may be worth trying further large doses of specific antivenom.

[11] Snakebite Neurotoxic Paralysis

- Presynaptic neurotoxic flaccid paralysis may occur after bites by tiger snakes, rough-scaled snakes, copperheads, taipans, rarely brown snakes.
- It usually first manifests as ptosis, 1-3+ hours after the bite, with potential progression to partial ophthalmoplegia, complete ophthalmoplegia, fixed dilated pupils, dysarthria, dysphagia, peripheral weakness, culminating in respiratory paralysis, though it may take 24+ hours to reach this final stage. Once complete paralysis is established it may take days, weeks or longer to reverse sufficiently for the patient to survive off a ventilator.
- Antivenom will not reverse well established presynaptic paralysis.
- Pure postsynaptic neurotoxic flaccid paralysis may occur after bites by death adders, resulting in similar, but often more rapid progression of symptoms and signs. This form of paralysis is usually reversible if sufficient antivenom is given. Neostigmine may also reduce the degree of paralysis.

[12] Followup of Snakebite Patients

- All patients with systemic envenoming should be followed up over 6 months, with particular concern for serum sickness over the first 14 days. Consider giving a 7 day course of oral steroids as prophylaxis if more than 25mls of antivenom has been given.

It is important to follow up all patients with initially trivial or no apparent envenoming, especially if discharged less than 24hrs post-bite, to ensure late onset envenoming is not missed. In particular, look for late onset neurotoxic envenoming, myolysis (not if proven brown snake bite) and renal damage.

PROTOCOL FOR MANAGING A CASE OF SNAKEBITE IN A HOSPITAL WITHOUT ANTIVENOM AVAILABLE

[1] The patient presents with a definite or possible snakebite.

- If not already applied, immediately apply correct first aid, namely a *broad compressive bandage* bound first over the bite site, at the *same pressure as for a sprain* (i.e. not so tight that it occludes the blood supply), then bind the bandage over as much of the bitten limb as possible, going over the top of clothing, and keeping the limb as still as possible. Once the limb is bandaged, *immobilise it using a splint*.
- Do NOT wash the wound, but if a venom detection kit is available then swab the wound as directed (see page 21 for details on SVDK) prior to applying first aid, but do not delay first aid significantly just to swab for venom, unless the patient appears well and greater than 20mins has elapsed since the bite.
- Keep the patient as still and quiet as possible.
- Fast the patient, and be prepared for vomiting.
- Carefully watch for evidence of envenoming, and if there is respiratory embarrassment, give respiratory support.
- Monitor urine output and colour.
- If the snake was brought with the patient, place it in alcohol (if practical), and ensure it goes with the patient when evacuation occurs.

[2] As soon as possible after applying first aid as above, notify the relevant doctor or hospital, to organise medical evacuation.

- It will help the retrieval team if you can give the following patient status report:
- Name, sex, age of patient.
- Brief history of the suspected bite. Was a snake seen? What type of snake? Was it a multiple bite? Are there any symptoms or signs of envenoming? (namely; headache, nausea, vomiting, abdominal pain, collapse, convulsions, early paralysis such as drooping upper eyelids, double vision, slurred speech, limb weakness, evidence of bleeding problem such as persistent ooze from the bite site, evidence of muscle damage such as dark or red urine, muscle pain).
- Patient's past history, particularly past snakebites with antivenom therapy, allergic disease, renal or heart disease, or use of anticoagulant drugs (e.g. warfarin) or antiplatelet drugs (e.g. aspirin or NSAIDS).

COMPARING HEAD SCALATION AND APPEARANCE TO DETERMINE THE MOST LIKELY TYPE OF SNAKE

Head shape and scalation can be very useful in determining the type of snake. When a dead snake, with head intact, is brought in with the patient, examination of the head should be performed. Once used to looking at the heads of the three major dangerous snakes in SA it is often possible to distinguish between them. The Photos shown here are of reasonably typical specimens.

The shape of the head; is it broad and triangular (eg mulga snake), broad and square (eg tiger snake), or narrow with brow ridges (eg brown snake) is of particular relevance. Refer to the diagram on page 34 and the colour key opposite for matching scale names to individual scales.

If you consult a clinical toxicologist for assistance they will ask you about the head appearance. If you are able to take digital photos and send them (eg by email or similar), then close ups of the head from above and the side will be most useful.



MULGA SNAKE (*Pseudechis australis*)

The head is broad and triangular. The parietal scales are triangular and at their neck edge, there are several rows of smaller scales visible, before the side of the head is reached.



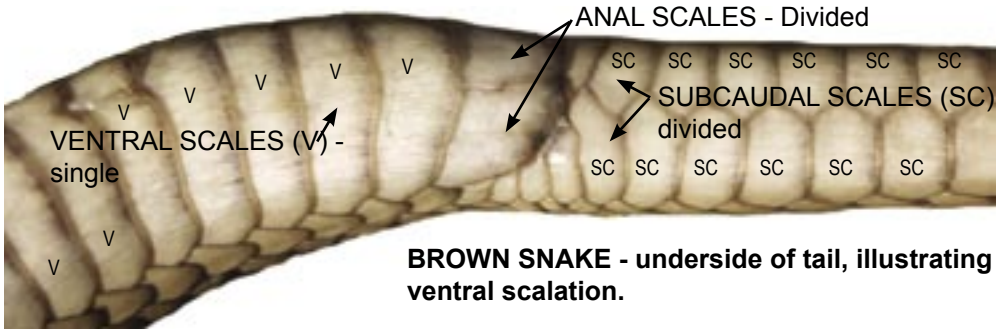
TIGER SNAKE (*Notechis scutatus/ater*)

The head is broad and more square in shape. The parietal scales are less triangular and broader, with fewer rows of scales leading to the side of the head and these scales are larger in proportion to the parietals, than in the mulga snake.



BROWN SNAKE (*Pseudonaja textilis/nuchalis*)

The head is more narrow and elongated than in either the tiger snake or mulga snake. There is a prominent scale ridge, or brow, above the eye, noticeably different to the mulga snake. The parietals are triangular, but less acutely so than the mulga snake. The frontal scale is much more elongate than either the mulga snake or tiger snake.



BROWN SNAKE - underside of tail, illustrating ventral scalation.

- Parietal scales
- Frontal scale
- Supraocular scales
- "side scales" to rear of head

- Temporal scale
- Post-temporal scales
- Supralabial scales

Patterns based on head shape and parietal and frontal scales.

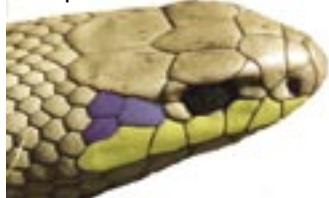Classic taxonomic differentiation using temporal and post temporal scales.



MULGA SNAKE - temporal scale + 3 post temporal scales. Note scale below touches lip and is therefore a supralabial scale.



TIGER SNAKE - temporal + 2 post temporal scales. Note scale below does not fully touch the lip.

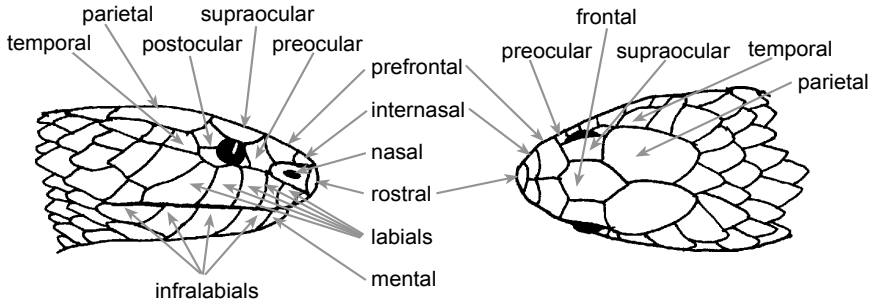


BROWN SNAKE - temporal + 2 post temporal scales. Note scale below touches lip and is therefore a supralabial scale.

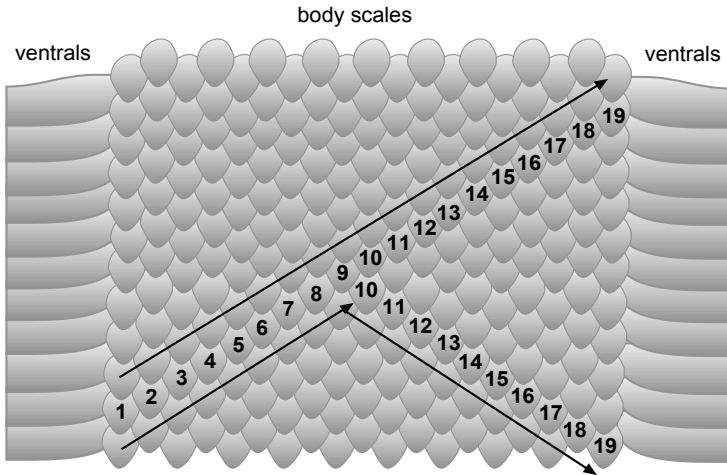
DETAILS OF MAJOR VENOMOUS SNAKES

DETAILS OF SCALE NAMES AND COUNTS

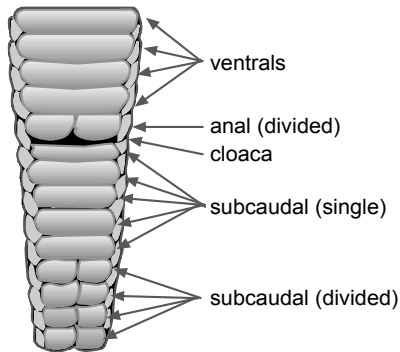
HEAD SCALATION OF AN ELAPID SNAKE



MIDBODY SCALE COUNT



VENTRAL, ANAL & SUBCAUDAL SCALES



BROWN SNAKES

Genus *Pseudonaja*

[1] EPIDEMIOLOGY

Brown snakes cause the majority of snakebites in Australia. However because of the small amount of venom available (average only 5 mg.) and the small fang size (average length only 2.8 mm.), many bites do not result in significant envenoming. On average only 1 in 5 or less brown snake bites is severe enough to require antivenom therapy. Nevertheless, when a significant amount of venom is injected, it can cause major and life threatening envenoming very rapidly. All brown snake bites should be treated as potentially lethal.

[2] TAXONOMY

Snake	Scientific name	Mid body scale count	Ventral scale count	Anal scale count	Subcaudal scale count
Common brown snake	<i>P. textilis</i>	17 rows	185-235	divided	45-75
Western brown snake	<i>P. nuchalis</i>	17-19 rows	180-230	divided	50-70
Ringed brown snake	<i>P. modesta</i>	17 rows	145-175	divided	35-55
Peninsular brown snake	<i>P. inframacula</i>	17 rows	190-205	divided	52-62
Spotted brown snake	<i>P. guttata</i>	19 rows	190-220	divided	45-70
Dugite	<i>P. affinis</i>	19 rows	190-230	divided	50-70

The ringed brown snake is smaller than its cousins, and although it can cause envenoming, there is no evidence that it can cause severe or life threatening envenoming, and unlike all its cousins, the venom lacks a procoagulant and therefore cannot cause a coagulopathy.

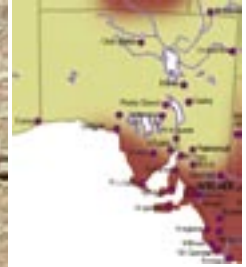The colour of brown snakes is very variable and misleading for identification purposes. They may be brown, red brown, grey, very dark brown and may be plain in colour, have speckling, stripes or bands, or have a dark or black head. Length is variable, but can occasionally reach 2m.

[3] DISTRIBUTION

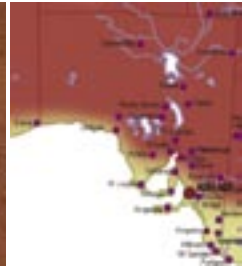
Widely distributed throughout Australia including both arid areas and wetter areas. Adapt well to human land use and are the most common snake in urban areas and farmlands. The maps show approximate theoretical distribution only.

[4] CLINICAL VENOM EFFECTS

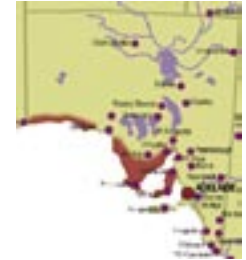Powerfully toxic venom, with potential to cause coagulopathy, renal failure and paralysis. In practice the dominant feature of brown snake envenoming is coagulopathy (defibrination type). Paralysis is only very rarely seen, usually in bites where there has been a long delay in giving antivenom therapy. Renal failure is a moderately common feature of brown snake envenoming in adults and is usually



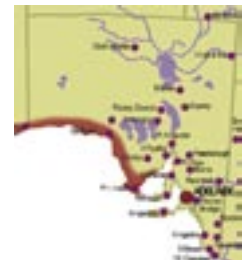The common brown snake - *Pseudonaja textilis* and it's approximate distribution in SA. The right hand specimen is a juvenile showing the classic black markings on top of the head and black band on the neck.



The western brown snake - *Pseudonaja nuchalis* and it's approximate distribution in SA. Note the varied colour patterns present within this species, including black headed varieties.



The peninsular brown snake - *Pseudonaja inframacula* and it's approximate distribution in SA.



The dugite - *Pseudonaja affinis* and it's approximate distribution in SA.



The spotted brown snake - *Pseudonaja guttata* and its approximate distribution in SA (just in the far north east corner).



The ringed brown snake - *Pseudonaja modesta* and its approximate distribution in SA. Note the 5 pale rings located at intervals along the body.

an acute tubular necrosis, which may require a period of haemodialysis. The risk seems increased if the patient has also had alcohol near the time of the bite. If renal failure is present then the coagulopathy is usually of the true DIC type, with thrombocytopenia.

The ringed brown snake does not appear to cause coagulopathy or severe envenoming.

[5] ANTIVENOM

Preferred antivenom is CSL Brown Snake Antivenom. If there is a coagulopathy, expect to use at least 2-5 vials, often 6+ are needed. The initial dose if there is defibrination coagulopathy is 2-5§ vials.

[6] VENOM DETECTION

The expected pattern if brown snake venom is present is positive in well 2 + well 7 (positive control). It is unclear what pattern may result with ringed brown snake venom.

§ An ongoing prospective study of Australian snakebite (ASP Study) is generating information that may allow changes in recommended initial doses of antivenom, particularly Brown Snake AV. Initial results indicate that a lower starting dose of 2 vials may be sufficient in most cases. Further research is required to define a safe initial dose if less than 5 vials are used.

TIGER SNAKES

Genus *Notechis*

[1] EPIDEMIOLOGY

Tiger snakes are the second most important cause of snake bites and fatalities. In general they are wetlands snakes, with a more restricted distribution, usually in association with creeks and rivers or water storage areas and lakes. Historically, untreated tiger snake bites have resulted in nearly 50% mortality and they are much more likely to inflict a severe bite than brown snakes. They have small fangs (average length 3.5mm) and produce a moderate amount of highly toxic venom (average 35mg.).

[2] TAXONOMY

There are only two species, the common tiger snake *Notechis scutatus* and the black tiger snake *Notechis ater*, the latter having numerous subspecies, several of which occur in SA. They have body scales in 17-19 rows, with 140-190 ventral scales, a single (undivided) anal scale and 35-65 undivided subcaudal scales and may reach 1.2 metres in length.

[3] DISTRIBUTION

Largely restricted to wetter areas of south east SA and along the River Murray (*N. scutatus*), and on Kangaroo Island and isolated populations (*N. ater*).

[4] CLINICAL VENOM EFFECTS

Powerfully toxic venom, with potential to cause defibrination type coagulopathy, paralysis, myolysis, and secondary renal failure. Coagulopathy may be severe with



Common banded form, and unbanded brown form of mainland tiger snake (*Notechis scutatus*).



Common black form and copper brown form (from Kangaroo Island) of black tiger snake (*Notechis ater*).

lethal haemorrhages reported, but untreated, tends to spontaneously resolve in about 12-18 hours. Paralysis is principally presynaptic and is common in moderate to severe cases of envenoming. Once full paralysis is established it will not usually be reversible with antivenom. Myolysis may be very severe, often with secondary renal failure and hyperkalaemia.

[5] ANTIVENOM

Preferred antivenom is CSL Tiger Snake Antivenom. One vial is rarely sufficient. If there is evidence of coagulopathy, paralysis or myolysis, initial dose should be at least 2-4 vials, with further doses often necessary.

[6] VENOM DETECTION

The expected pattern if tiger snake venom is present is positive in well 1 + well 7 (positive control), but in addition, occasionally there may be a weak positive in wells 3 and 4.

ROUGH SCALED SNAKE

Tropidechis carinatus

[1] EPIDEMIOLOGY

The rough scaled snake is similar in many ways to the tiger snake, frequenting mostly wetter areas. Though technically considerably less dangerous than the tiger snake, clinical experience has shown it to be almost identical in effects in humans and it should be considered lethal. Within its range it is probably causing bites more frequently than tiger snakes. Fang length and venom quantity is less than for tiger snakes.

[2] TAXONOMY

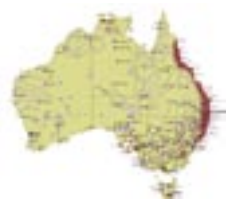There is a single species. It has strongly keeled body scales, 23 rows mid-body, 160-185 ventral scales, anal scale undivided, 50-60 undivided subcaudals. It may reach 1 metre in length. Colouration is variable, but most specimens have an overall olive colour above, with irregular darker cross bands, while the belly scales are mostly cream or yellow, sometimes with darker areas.

[3] DISTRIBUTION

Rough scaled snakes are mainly found near watercourses or in sclerophyll forests in eastern Australia. They are not native to SA.

[4] CLINICAL VENOM EFFECTS

Despite the major clinical effects of rough scaled snake bites, comparative testing shows the venom as much less toxic than tiger snake venom. Clinically, however, all the major problems seen with tiger snake bites occur; namely defibrination coagulopathy, presynaptic paralysis and major myolysis, with possible secondary renal failure.



[5] ANTIVENOM

The preferred antivenom is CSL Tiger Snake Antivenom. In cases with severe envenoming multiple vials will be needed, with a starting dose of at least 2-4 vials.

[6] VENOM DETECTION

The expected pattern if rough scaled snake venom is present is positive in well 1 + well 7 (positive control).

COPPERHEADS

Genus *Austrelaps*

[1] EPIDEMIOLOGY

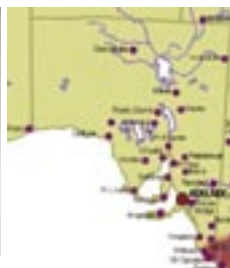Copperheads are also snakes that prefer wetter, cooler areas, right up into alpine regions. Though probably not rare, bites are rarely reported and there is comparatively little known about envenoming by these snakes. Based on venom and animal studies and a few case reports, bites are potentially lethal and likely to be similar to tiger snake bites. Fangs and venom quantities are also comparable, though venom toxicity is less.

[2] TAXONOMY

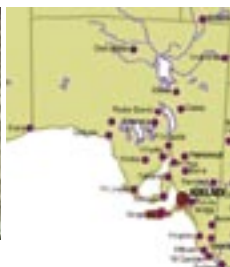Copperheads are restricted to south east Australia. Colouration is quite variable, often with russet tinge to upper surface, blending to yellow or cream on belly scales. As with other copperheads, they typically have pale or white markings on the edge of lip scales. Midbody scales in 15 rows, 150 ventrals, anal undivided, 35-55 undivided subcaudals, length to 1.2 metres.

[3] DISTRIBUTION

In SA all specimens are either lowland copperheads, *Austrelaps superbus* in the South East, or pygmy copperheads, *A. labialis* in the Mount Lofty Ranges and on Kangaroo Island.



Common or lowlands copperhead (*Austrelaps superbus*).



Pygmy copperhead (*Austrelaps labialis*).

[4] CLINICAL VENOM EFFECTS

The principal clinical effect of copperhead bites appears to be paralysis, while neither myolysis nor coagulopathy are well documented in humans envenomed by these snakes. Based on experimental work there may be myolysis, but coagulopathy, if present at all, seems more likely to be direct anticoagulant rather than defibrination.

[5] ANTIVENOM

Current recommendations are to use CSL Tiger Snake Antivenom, but dosage is uncertain. In severe cases, use several vials.

[6] VENOM DETECTION

Copperheads tested for venom detection have been principally *Austrelaps superbus*, not *A. labialis*. The expected pattern if copperhead venom is present is positive in well 1 + well 7 (positive control), but there may also be a weak positive in well 3.

BROAD HEADED SNAKES

Genus *Hoplocephalus*

[1] EPIDEMIOLOGY

The three members of this genus are the broad headed snake, *Hoplocephalus bungaroides*, Stephen's banded snake, *Hoplocephalus stephensii* and the pale headed snake, *Hoplocephalus bitorquatus*, none of which are frequent causes of envenoming. Most cases are in researchers or reptile keepers, but accidental cases doubtless occur occasionally in the general population living in the ranges of these snakes. Fangs are small, venom quantity equally small, but recent clinical experience suggests these snakes could cause lethal envenoming.

[2] TAXONOMY

All three species are small to medium sized thin snakes, with distinctive colouration for each species. The broad headed snake is typically black above with yellow scales forming irregular narrow bands, with a cream belly. There are 21 rows of midbody scales, 200-230 ventral scales, an undivided anal scale and 40-65 undivided subcaudals, with length to 0.9 metres. Stephen's banded snake is typically dark grey to almost black, with wide cross bands of a slightly lighter hue, often with pale or white markings around the lips or side of the head. Midbody scales in 21 rows, with 220-250 ventrals, an undivided anal scale, 50-70 undivided subcaudals and length to 0.6 metres. The pale headed snake is typically uniform grey or light brown in body colour, with a broad pale band on the nape of the neck, often bordered by narrow black markings. The top of the head is usually grey, sometimes with spots. Midbody scales in 21 rows, 190-225 ventrals, undivided anal scale, 40-65 undivided subcaudals, length to 0.6 metres.

[3] DISTRIBUTION

None of these snakes are native to SA. The broad headed snake is restricted to ranges in south and central eastern NSW, where it favours sandstone rock areas, sheltering under rocks, venturing forth at night in search of prey. Stephen's banded snake is found in north eastern coastal NSW and adjacent Queensland and is



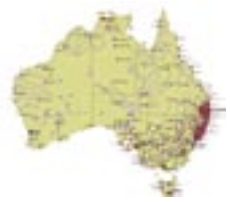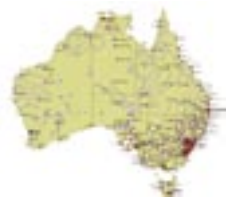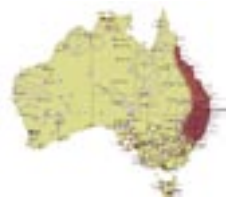Pale headed snake



Broad headed snake



Stephen's banded snake



nocturnal and partly arboreal. The pale headed snake is more broadly distributed in north eastern NSW and Queensland and is also nocturnal and partly arboreal in habit.

[4] CLINICAL VENOM EFFECTS

Few bites from any of these snakes are reported, but recent experience with bites by both the broad headed snake and Stephen's banded snake indicate that severe envenoming can occur in humans, with defibrination coagulopathy. Paralysis, myolysis and renal failure have not been reported so far. Though no deaths are reported, complete defibrination can potentially result in lethal haemorrhage, so these snakes are considered as possibly deadly.

[5] ANTIVENOM

While not formally tested, CSL Tiger Snake Antivenom has been used in several cases with apparent success. 2-4+ vials may be required to reverse the defibrination.

[6] VENOM DETECTION

Tests at CSL on Stephen's banded snake venom failed to show reactivity in the SVDK, but clinically it appears that at least the broad headed snake may give a weak positive in well 1 + well 7 (positive control). If in the range of these snakes, consider them as a cause of envenoming if the patient has defibrination without paralysis or myolysis, but the SVDK is negative or weakly positive for tiger snake venom.

MULGA SNAKES

Pseudechis australis

[1] EPIDEMIOLOGY

Mulga snakes are probably the second most common cause of significant snakebite in arid areas of Australia. Few cases are recorded in the medical literature, but they are known to cause fatalities and severe envenoming. While their venom is less potent than some other species (e.g. browns, tiger snakes, taipans), they produce large quantities (up to 180 mg.), and have quite large fangs (up to 6 mm.). The majority of mulga snake bites will result in significant envenoming, requiring antivenom therapy.

[2] TAXONOMY

The mulga snake, or king brown, *Pseudechis australis*, is a member of the black snake group, but far more dangerous than its cousins. It has 17 scale rows, 185-225 ventral scales, a divided anal scale, and 50-75 subcaudals, some or all of which may be divided. It is a large snake, usually brown in colour, with a slight yellow tinge to the edge of each scale, giving a distinctive appearance. The head is triangular, flattened, and broad.

[3] DISTRIBUTION

Widely distributed in the more arid parts of Australia, but generally less common than brown snakes. The map shows approximate theoretical distribution only.

[4] CLINICAL VENOM EFFECTS

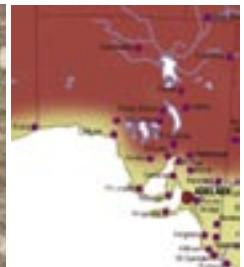Moderately powerful venom, principal effect being myolysis of skeletal muscle, with the potential for secondary renal failure and hyperkalaemia. True paralysis does not seem to occur with mulga snake bites, but the muscle damage may be severe enough to cause direct muscle weakness, which might mimic paralysis. The venom does not contain procoagulants, but rather direct anticoagulants. Defibrination coagulopathy is not seen, but there may be slight (occasionally marked) prolongation of clotting times, INR, APTT, due to the anticoagulants. Mulga snake bites are usually associated with significant local swelling and pain at the bite site. The swelling may take several hours to fully develop, but many days to fully subside.

[5] ANTIVENOM

Preferred antivenom is CSL Black Snake Antivenom. Usually one vial is sufficient. Bites by Collett's snake, *P. colletti*, should be treated as for mulga snakes.

[6] VENOM DETECTION

The expected pattern if mulga snake venom is present is positive in well 3 + well 7 (positive control), but there may also be weak positive in well 1.



RED BELLIED BLACK SNAKE

Pseudechis porphyriacus

[1] EPIDEMIOLOGY

Black snakes are found principally in wetter areas, typically near creeks. In eastern Australia they are common in areas frequented by man, and many bites have been recorded. It is clear that this snake is not particularly dangerous, and very few fatalities are recorded. While its bite may often cause a local and even mild systemic reaction, potentially lethal bites are rare and most cases, even with envenoming, probably do not warrant antivenom therapy.

[2] TAXONOMY

The black snake is of moderate size, usually over 1 metre in length, typically with a jet black body and an underside (ventral scales) which is deep red in colour, extending a short way up the sides of the snake. It has scales in 17 rows, with 180-210 ventral scales, a divided anal scale and 40-65 subcaudal scales, divided anteriorly.

[3] DISTRIBUTION

Wetlands snake, common near creeks and water. The map shows approximate theoretical distribution only and in much of this range it may be uncommon.

[4] CLINICAL VENOM EFFECTS

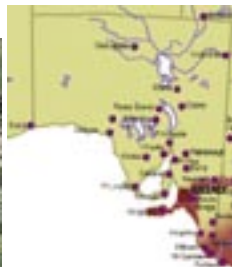The venom is neither particularly potent, nor in very large quantity. It does not appear to cause any of the major complications of Australian snake venoms; that is it does not cause paralysis, coagulopathy, significant myolysis, or renal failure in man, according to currently available information. However envenoming is associated with systemic symptoms, including headache, severe abdominal pain, nausea and vomiting, possibly syncope and the bite site is often painful and swollen and may become infected.

[5] ANTIVENOM

Few cases require antivenom. If it is needed the preferred antivenom is CSL Tiger Snake Antivenom (not Black Snake Antivenom). In reptile keepers, where there is a risk of repeated exposure to antivenom and the attendant possibility of developing hypersensitivity to antivenom, it is particularly important to avoid unnecessary exposure. Therefore reptile keepers bitten by black snakes should only be given antivenom therapy as a last resort in very severe envenoming.

[6] VENOM DETECTION

The expected result is positive in well 3 + well 7 (positive control), but there may also be a weak positive in well 1 (see mulga snake).



SPOTTED OR BLUE BELLIED BLACK SNAKE

Pseudechis guttatus

[1] EPIDEMIOLOGY

Little is known about bites by this snake, but it is usually considered similar to the red bellied black snake, so bites are unlikely to prove lethal. However, the related Collett's snake has now caused severe envenoming, so that the clinical status of this snake is uncertain.

[2] TAXONOMY

The spotted or blue bellied black snake is of moderate size, usually over 1 m. in length, typically with a black or deep brown body, the latter usually with black or dark spots, and an underside (ventral scales) which is blue grey in colour, extending a short way up the sides of the snake. It has mid body scales in 19 rows, with 175-205 ventral scales, a divided anal scale and 45-65 subcaudal scales.

[3] DISTRIBUTION

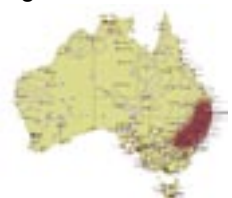Found in both dry and moist habitats in eastern Australia, not native to SA. The map shows approximate theoretical distribution only. There are verbal reports that this snake is increasingly common within parts of its range, at the expense of the red bellied black snake.

[4] CLINICAL VENOM EFFECTS

The venom is neither particularly potent, nor in very large quantity. It does not appear to cause any of the major complications of Australian snake venoms; that is it does not cause paralysis, defibrination coagulopathy, significant myolysis, or renal failure in man, according to currently available information. However envenoming, based on very limited case material, is associated with systemic symptoms, including headache, severe abdominal pain, nausea and vomiting, possibly syncope and the bite site is often painful and swollen and may become infected. Though not documented, a direct anticoagulant may be present, causing anticoagulant type coagulopathy (see mulga snake).

[5] ANTIVENOM

Few cases require antivenom. If it is needed the preferred antivenom is CSL Tiger Snake Antivenom (not Black Snake Antivenom). In reptile keepers, where there is a risk of repeated exposure to antivenom and the attendant possibility of developing hypersensitivity to antivenom, it is particularly important to avoid unnecessary exposure. Therefore reptile keepers bitten by black snakes should only be given antivenom therapy as a last resort in very severe envenoming.



[6] VENOM DETECTION

Expected result is positive in well 3 + well 7 (positive control), but there may also be a weak positive in well 1 (see mulga snake).

COLLETT'S SNAKE

Pseudechis colletti

[1] EPIDEMIOLOGY

Collett's snakes cause few bites, mostly in reptile keepers. Few cases are recorded in the medical literature, but they are known to severe envenoming, with the potential for lethality. While their venom is less potent than some other species (e.g. browns, tiger snakes, taipans), they produce large quantities, and have quite large fangs. The majority of Collett's snake bites will result in significant envenoming, requiring antivenom therapy. They should be considered similar to mulga snakes clinically.

[2] TAXONOMY

The Collett's snake, *Pseudechis colletti*, is a member of the black snake group, but far more dangerous than it's cousins, the red-bellied and blue-bellied black snakes. It has 19 scale rows, 215-235 ventral scales, a divided anal scale, and 50-70 subcaudals, some or all of which may be divided. It is a large snake, usually pink-brown in colour, with pinkish markings along the body, giving a distinctive appearance. The head is triangular, flattened, and broad.

[3] DISTRIBUTION

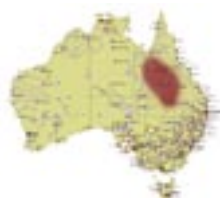Restricted to parts of inland arid Queensland. Not native to SA. The map shows approximate theoretical distribution only.

[4] CLINICAL VENOM EFFECTS

Moderately powerful venom, principal effect being myolysis of skeletal muscle, with the potential for secondary renal failure and hyperkalaemia. True paralysis does not seem to occur with Collett's snake bites, but the muscle damage may be severe enough to cause direct muscle weakness, which might mimic paralysis. The venom does not contain procoagulants, but rather direct anticoagulants. Defibrination coagulopathy is not seen, but there may be slight (occasionally marked) prolongation of clotting times, INR, APTT, due to the anticoagulants. Collett's snake bites are usually associated with significant local swelling and pain at the bite site. The swelling may take several hours to fully develop, but many days to fully subside.

[5] ANTIVENOM

Preferred antivenom is CSL Black Snake Antivenom. Usually one vial is sufficient.



[6] VENOM DETECTION

The expected pattern if Collett's snake venom is present is positive in well 3 + well 7 (positive control), but there may also be weak positive in well 1.

DEATH ADDERS

Genus *Acanthophis*

[1] EPIDEMIOLOGY

Death adders are now relatively rare in the wild in much of settled Australia, although there are a few areas where they are locally common. They do not appear to adapt well to human land use. As a result bites by death adders in the wild are extremely rare. In contrast they are common in captivity and bites to reptile keepers are moderately common. They have a potent venom and prior to antivenom, used to kill 50% of all people bitten. Death from death adder bite is now very rare.

[2] TAXONOMY

The death adders are squat snakes with a distinctive triangular head, narrow neck, and relatively short, dumpy body, compared to other dangerous snakes in Australia. Mid body scales are in 21-23 rows, with 110-160 ventral scales, an undivided anal scale, and 40-60 undivided subcaudal scales.

[3] DISTRIBUTION

Formerly far more widely distributed than now, they prefer habitats with leaf litter or other ground debris in which to hide, usually, but not exclusively, in sandy soils, including coastal dune country. The map shows approximate theoretical distribution only. The death adder is the only Australian dangerous venomous snake which is commonly active at night, and it is often reluctant to move away if humans approach; relying on being hidden in leaf litter. It is therefore possible to step on a death adder hidden in this way.

[4] VENOM EFFECTS

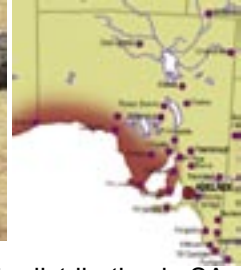Death adder venom is powerful, but limited in action. In man its effects are principally those of paralysis due to post synaptic neurotoxins. This raises an interesting possibility in therapy, as post synaptic paralysis is often reversible with either antivenom or anticholinesterases. Death adders do not cause a defibrination type coagulopathy or myolysis, and renal failure is not reported. Death adder bites are usually quite painful at the bite site, though swelling is usually only slight, and there is a tendency to local secondary infection.

[5] ANTIVENOM

The preferred antivenom is CSL Death Adder Antivenom, but at least in reptile keepers, where exposure to antivenom should be minimised, it is worth trying other therapies to reverse paralysis if present, reserving antivenom for those severe cases where such therapies fail. The suggested therapy is iv anticholinesterase (e.g. neostigmine + atropine) but beware of convulsions secondary to neostigmine therapy. A single vial is the usual initial antivenom dose.

[6] VENOM DETECTION

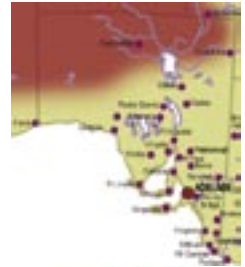
The expected result is positive in well 4 + well 7 (positive control), but occasionally there may also be a weak positive in well 1.



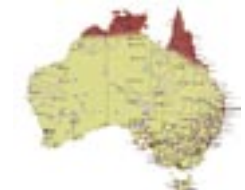Common death adder, *Acanthophis antarcticus*, and approximate distribution in SA.



Desert death adder, *Acanthophis pyrrhus*, and approximate distribution in SA.



Northern death adder, *Acanthophis praelongus*, not native to SA.



TAIPANS

Genus *Oxyuranus*

[1] EPIDEMIOLOGY

Both taipans are popular amongst reptile keepers, and quite a few exist both in reptile parks, and in private collections, and bites do occur. The taipan is one of the world's most dangerous snakes, and prior to the development of an antivenom, nearly all cases were fatal. All taipan bites should be considered as potentially fatal, and require the most urgent attention. Because the problems they cause are complex, all cases should be managed in major hospitals, with full ICU, full laboratory facilities, and expert help from a Clinical Toxinologist/Toxicologist should always be sought.

[2] TAXONOMY

Taipans are large snakes, sometimes exceeding 2m in length, with mid body scales in 23 rows, 220-250 ventral scales, a divided anal scale, and 55-70 divided subcaudal scales. The inland taipan *Oxyuranus microlepidotus* often has a dark coloured head, and a speckled brown body. It is easily mistaken for a western brown snake. The common taipan *Oxyuranus scutellatus* is generally of brown colour, with pale belly and often a paler coloured angular head.

[3] DISTRIBUTION

The common taipan, *Oxyuranus scutellatus*, is not native to SA. The inland

taipan, *Oxyuranus microlepidotus*, is restricted to the far north west of the State, if present at all, in the black soil plains country. Neither species is likely to be common.

[4] CLINICAL VENOM EFFECTS

Taipans have very powerful venom in large amounts, and delivered by large fangs (up to 12 mm. for the common taipan). The venom has a wide spectrum of activity, including potent neurotoxins and procoagulants. Envenoming is usually accompanied by rapid onset of defibrination type coagulopathy, early or delayed onset of paralysis, and myolysis and renal failure may develop in some cases. The patient may be so severely envenomed that intubation is needed within 1-2 hours of the bite. Bites by taipans are the only Australian snakebites where it may sometimes be justified to commence antivenom therapy before systemic envenoming is established.

[5] ANTIVENOM

Preferred antivenom is CSL Taipan Antivenom. However taipan antivenom is of similar volume and cost to polyvalent antivenom and therefore it is often more practical to stock and use polyvalent rather than taipan antivenom if the number of expected taipan bites is low (e.g. country hospital servicing a reptile park). In a metropolitan hospital where access to taipan antivenom directly from CSL after hours is possible, it is best to use the specific antivenom for therapy. Initial dose is 1-3 vials.

[6] VENOM DETECTION

The expected result is positive in well 5 + well 7 (positive control), but for common taipan venom, there may also be weak positives in wells 1,3 and 4, while for the inland taipan there may be weak positives in wells 1 to 4, especially well 2.



Inland taipan *Oxyuranus microlepidotus*.



Common taipan *Oxyuranus scutellatus*.

EASTERN SMALL EYED SNAKE

Rhinoplocephalus (previously Cryptophis) nigrescens

[1] EPIDEMIOLOGY

In much of its range this snake is common, but few bites are recorded, though this does not imply actual bites are rare. There is one recorded fatality, from delayed effects of myolysis.

[2] TAXONOMY

This snake shares the genus with 5 other species, none of which are known to be of medical significance. It is a steel grey colour above, with a cream belly. The sides of the head may be yellowish to red brown. Midbody scales 15 rows, ventrals 145-190, anal undivided, 20-35 undivided subcaudals, length to 0.45 metres.

[3] DISTRIBUTION

Restricted to eastern Australia. Not native to SA. Nocturnal.

[4] CLINICAL VENOM EFFECTS

The single reported severe case occurred in 1968, the young man concerned dying more than a week after the bite with effects of severe myolysis. The venom does not appear neurotoxic, nor does it cause coagulopathy experimentally.

[5] ANTIVENOM

Antivenom is unlikely to be required for most bites by this snake, but should major envenoming occur, with myolysis, use CSL Tiger Snake Antivenom which has been shown effective in envenomed animals.

[6] VENOM DETECTION

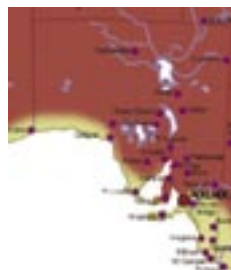There is currently no information on the reactivity of this venom with the SVDK, but because the principal toxin is similar to one of the major toxins in tiger snake venom, it is possible that it may cross react and bind to antibody in well 1, giving a positive result.

YELLOW FACED WHIP SNAKE

Demansia psammophis

[1] EPIDEMIOLOGY

This snake is included not because it is dangerous, but because it frequently causes bites. Envenoming by this snake may result in both local and general symptoms, but there is no evidence that it is potentially lethal, and therefore bites do not require antivenom therapy.



[2] TAXONOMY

The yellow faced whip snake grows to about 60 cms. long, and is thin of build, the average adult having a diameter approximating that of a standard biro. This is considerably smaller than most of the potentially lethal snakes. The colour is usually green to grey anteriorly, shading to a russet brown towards the tail, and with a distinctive pale ring around the eye. Mid body scales are in 15 rows, with 165-230 ventrals, a divided anal scale, and 60-105 undivided subcaudal scales.

[3] DISTRIBUTION

Common across much of Australia, including much of SA.

[4] CLINICAL VENOM EFFECTS

Few formal studies on the venom of this snake have been published, but it is not considered lethal to man. Bites usually cause local pain and swelling, sometimes with a mild systemic illness, but there is no evidence of paralysis, coagulopathy, myolysis, or renal failure.

[5] ANTIVENOM

Yellow faced whip snake bites do not need antivenom therapy, but may warrant admission overnight if there is significant local swelling, for elevation of the bite site.

[6] VENOM DETECTION

Venom of this snake may give positive results in the SVDK, either as "brown snake" (well 2), or as "tiger snake" (well 1), and this may cause confusion in interpretation of the SVDK results. Be aware of this in interpretation of SVDK results and in deciding on the need for antivenom therapy.

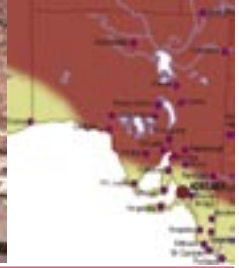OTHER ELAPID SNAKES

There are a variety of other species of elapid (cobra) type snakes in SA, in addition to the above mentioned dangerous species. Some, such as the curl snake, are of moderate size and may cause local pain and swelling, while others live most of their life burrowing, are small, and bites should only be trivial. A full discussion of all species is not appropriate in this document, however some brief information on species is listed.

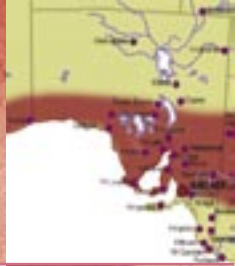
None of these snakes are likely to cause medically significant bites requiring hospitalisation and antivenom treatment is not appropriate. However, it should be noted that very few of these snakes have had their venom investigated and for most there are few, if any records of bites. Should someone present following a bite by one of these snakes, it is most uncertain if the SVDK will produce a positive result. There is a possibility that venom might be detected, in an unpredictable manner, that might cause confusion with a dangerous species. The chance of such an event is not high, because bites by most of these snakes are unlikely. For many, their small size and cryptic lifestyle make encounters with humans rare and fang penetration would usually be difficult, even if a bite did occur, almost certainly in association with picking up and handling the snake.

curl snake, *Suta suta*

Curl snakes can cause mild local envenoming, with both swelling and pain, occasionally general symptoms such as headache and nausea, but do not cause life threatening envenoming. There is no evidence they can cause coagulopathy, paralysis or myolysis.

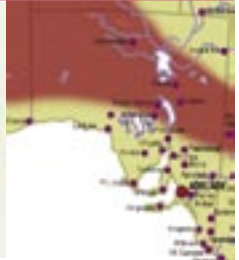
**black headed snake, *Suta spectabilis***

There is no significant experience with bites by these snakes, but they are unlikely to cause more than local pain and swelling.

**hooded snake, *Suta monachus***

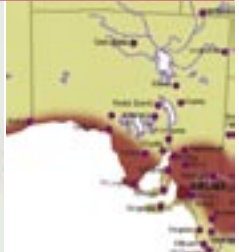There is no significant experience with bites by these snakes, but they are unlikely to cause more than local pain and swelling.

Photo copyright © Dr. Mark Hutchinson, S.A. Museum

**mallee back-headed snake, *Suta nigriceps***

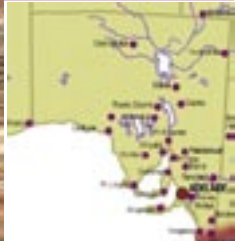There is no significant experience with bites by these snakes, but they are unlikely to cause more than local pain and swelling.

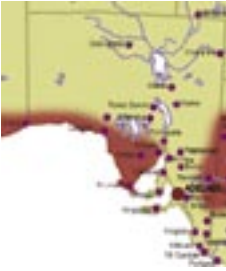Photo copyright © Dr. Mark Hutchinson, S.A. Museum

**little whip snake, *Suta flagellum***

There is no significant experience with bites by these snakes, but they are unlikely to cause more than local pain and swelling.

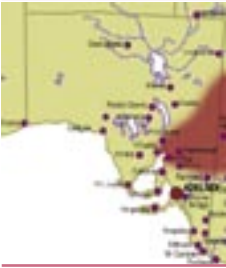Photo copyright © Dr. Mark Hutchinson, S.A. Museum





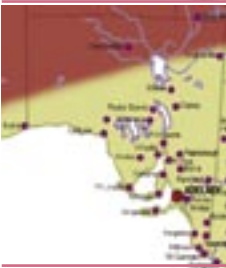**bardick,
*Echiopsis curta***

Their small size makes effective envenoming of humans unlikely, other than perhaps mild local pain and swelling. There is no evidence they can cause coagulopathy, paralysis or myolysis. However, there is some evidence their venom may be detected in SVDK as death adder.



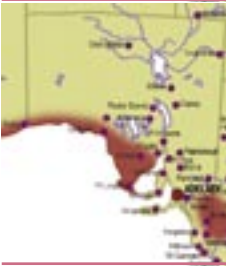**red naped snake,
*Furina diadema***

A small snake, unlikely to effectively bite humans or cause more than mild local pain or minimal swelling. However, another member of this genus has been reported to cause general symptoms, such as headache, vomiting and abdominal pain.



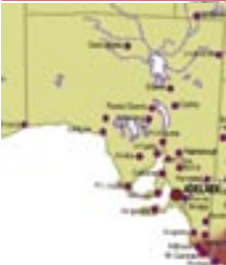**orange naped snake,
*Furina ornata***

A small snake, unlikely to effectively bite humans or cause more than mild local pain or minimal swelling. However, another member of this genus has been reported to cause general symptoms, such as headache, vomiting and abdominal pain.



**Master's snake,
*Dysdalia mastersii***

Their small size makes effective envenoming of humans unlikely, other than perhaps mild local pain and swelling. There is no evidence they can cause coagulopathy, paralysis or myolysis.



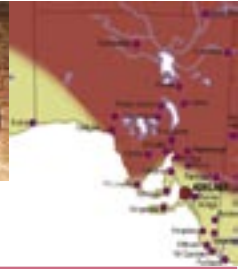
**white lipped snake,
*Drysalia coronoides***

Their small size makes effective envenoming of humans unlikely, other than perhaps mild local pain and swelling. There is no evidence they can cause coagulopathy, paralysis or myolysis.

Photo copyright © Dr. Mark Hutchinson, S.A. Museum

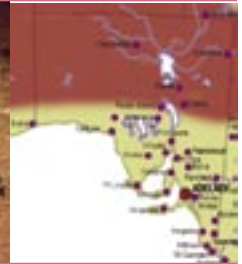**desert banded snake,
*Simoselaps bertholdi***

One of several species of small, harmless burrowing elapid snakes, most commonly encountered at night or in pits or hollows in which they have become trapped. Harmless.



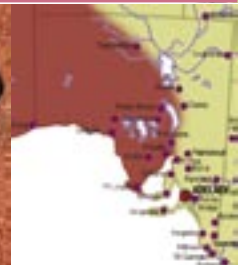**narrow banded burrowing snake,
*Simoselaps fasciolatus***

Similar to the desert banded snake in habits. Harmless.



**half girdled snake,
*Simoselaps semifasciatus***

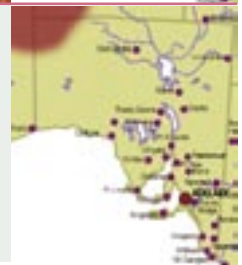

Similar to the desert banded snake in habits. Harmless.



**northern desert banded snake,
*Simoselaps anomalus***

Similar to the desert banded snake in habits. Harmless.

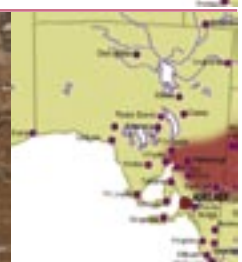Photo copyright © Dr. Mark Hutchinson,
S.A. Museum



**coral snake,
*Simoselaps australis***

Similar to the desert banded snake in habits. Harmless.

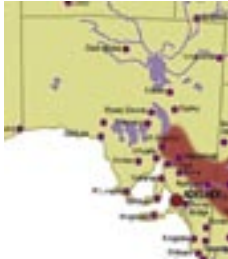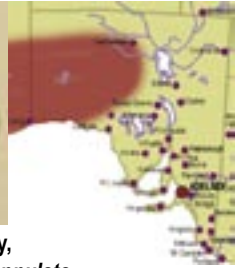Photo copyright © Dr. Mark Hutchinson,
S.A. Museum



western black-naped snake, →
Simoselaps bimaculatus

Similar to the desert banded snake in habits. Harmless.

Photo copyright © Dr. Mark Hutchinson, S.A. Museum



← bandy bandy,
Vermicella annulata

There is no evidence bandy bandys are likely to cause significant bites in humans. Indeed, the small head size may make it difficult for the snake to effectively bite in most cases.

PYTHONS

Several python species occur in S.A.. All are non-venomous, but have numerous long teeth and can cause significant local effects at a bite site. Because of the large number of teeth, the pattern of bite marks is likely to be quite distinct from a venomous snake bite. Secondary infection requiring antibiotic treatment may occur following python bites, and all patients should have their tetanus immunisation brought up to date. They are easily distinguished from venomous snakes by their high mid-body scale count.



woma python
Aspidites ramsayi



carpet python
Morelia spilotes



head showing heat sensing pits on lower lip & front of snout

BLIND SNAKES

There are numerous species of blind snakes; small burrowing snakes which are non-venomous and cannot bite humans. Their head shape has evolved for burrowing and is distinctive, as is the long, thin, cylindrical body. The tail ends in a sharp spine, which is not venomous and is used by the snake for leverage. All blind snakes are harmless to humans. They may be encountered in trenches or pits which they may fall into at night.



typical blind snake (above)
 distinctive head of a blind snake with scales over the eyes (below), and the pointed spine on the end of the tail (bottom)



SCALE COUNT DETAILS

Snake	Scientific name	MidBody	Ventral
Eastern brown snake	<i>Pseudonaja textilis</i>	17	185-235
Western brown snake	<i>Pseudonaja nuchalis</i>	17-19	180-230
Dugite	<i>Pseudonaja affinis</i>	19	190-230
Peninsular brown snake	<i>Pseudonaja inframacula</i>	17	190-205
Speckled brown snake	<i>Pseudonaja guttata</i>	19-21	190-220
Ringed brown snake	<i>Pseudonaja modesta</i>	17	145-175
Mulga snake	<i>Pseudechis australis</i>	17	185-225
Collett's snake	<i>Pseudechis colletti</i>	19	215-235
Red bellied black snake	<i>Pseudechis porphyriacus</i>	17	170-215
Blue bellied black snake	<i>Pseudechis guttatus</i>	19	175-205
Inland taipan	<i>Oxyuranus microlepidotus</i>	23	220-250
Common death adder	<i>Acanthophis antarcticus</i>	21	110-135
Desert death adder	<i>Acanthophis pyrrhus</i>	19-21	120-160
Yellow faced whip snake	<i>Demansia psammophis</i>	15	165-230
White lipped snake	<i>Drysdalia coronoides</i>	15	120-160
Masters's snake	<i>Drysdalia mastersii</i>	15	134-160
Bardick	<i>Echiopsis curta</i>	19	130-145
Red naped snake	<i>Furina diadema</i>	15	160-210
Orange naped snake	<i>Furina ornata</i>	15-17	160-240
Northern desert banded snake	<i>Simoselaps anomalus</i>	15	115-130
Coral snake	<i>Simoselaps australis</i>	17	140-170
Desert banded snake	<i>Simoselaps bertholdi</i>	15	110-135
Western black-naped snake	<i>Simoselaps bimaculatus</i>	15	175-235
Narrow banded snake	<i>Simoselaps fasciolatus</i>	17	140-175
Half girdled snake	<i>Simoselaps semifasciatus</i>	15-17	140-190
Little whip snake	<i>Suta flagellum</i>	17	125-150
Hooded snake	<i>Suta monachus</i>	15	150-175
Mallee black-headed snake	<i>Suta nigriceps</i>	15	145-175
Black headed snake	<i>Suta spectabilis</i>	15	135-170
Curl snake	<i>Suta suta</i>	19-21	150-170
Bandy bandy	<i>Vermicella annulata</i>	15	180-320
NON-VENOMOUS			
Pythons (various species)		>35	-
Blind snakes	<i>Ramphotyphlops</i> species	Very distinctive head, body (see photos)	

SCALE COUNT DETAILS

Snake	Anal	Subcaudals	Adult length
Eastern brown snake	divided	45-75; divided	1.5m
Western brown snake	divided	50-70; divided	1.5m
Dugite	divided	50-70; divided	1.2m
Peninsular brown snake	divided	52-62; divided	1.1m
Speckled brown snake	divided	45-70; divided	0.8m
Ringed brown snake	divided	35-55; divided	0.5m
Mulga snake	divided	50-75; first few single	2.3m
Collett's snake	divided	50-70; first few single	2.0m
Red bellied black snake	divided	40-65; single to divided	1.4m
Blue bellied black snake	divided	45-65; first few single	1.5m
Inland taipan	single	55-70; divided	2.5m
Common death adder	single	35-60; mostly single	0.5m
Desert death adder	single	40-65; first few single	0.5m
Yellow faced whip snake	divided	60-105; divided	1.0m
White lipped snake	single	35-70; single	0.3m
Masters's snake	single	32-55; single	0.25m
Bardick	single	30-40; single	0.4m
Red naped snake	divided	35-70; divided	0.4m
Orange naped snake	divided	35-70; divided	0.7m
Northern desert banded snake	divided	15-30; divided	0.2m
Coral snake	divided	15-30; divided	0.3m
Desert banded snake	divided	15-30; divided	0.3m
Western black-naped snake	divided	15-35; divided	0.3m
Narrow banded snake	divided	15-30; divided	0.3m
Half girdled snake	divided	14-30; divided	0.3m
Little whip snake	single	20-40; single	0.3m
Hooded snake	single	20-35; single	0.4m
Mallee black-headed snake	single	18-35; single	0.4m
Black headed snake	single	20-40; single	0.4m
Curl snake	single	20-35; single	0.5m
Bandy bandy	divided	12-30; divided	0.6m
NON-VENOMOUS			
Pythons (various species)	-	-	-

GENERAL INFORMATION ON RED BACK SPIDER BITE

The Australian red back spider, *Latrodectus hasselti*, is a member of the world-wide widow spider group, envenoming by these spiders being known as "latrodectism". The venom contains excitatory neurotoxins which stimulate the nervous system rather than cause paralysis.

Clinical Features

Possibly 50% of red back spider bites are minor, resulting in either minimal or no symptoms and do not require treatment with antivenom. In cases where significant envenoming occurs, antivenom therapy is usually indicated, though death is extremely unlikely in untreated cases of latrodectism. The value of CSL Red Back Spider Antivenom is its ability to dramatically improve the symptoms of latrodectism and allow a rapid return to work.

In a typical case of significant latrodectism, the patient will usually feel the bite as a minor sting only and may not see the spider. After a brief period of 10-50 mins the bite area becomes painful. The pain increases to become severe and then spreads proximally, involving draining lymph nodes, which become swollen and tender, eventually causing generalised pain, localised or generalised sweating, hypertension and malaise. Many other symptoms may also occur, but are uncommon or less consistent. The generalised truncal pain may be chest pain, abdominal pain or neck or head pain, and may mimic the pain of myocardial infarction or acute abdomen. The progression from local to generalised pain may take from 1 to 24 hours, though less than 6 hours for progression is seen in most cases. There is often little to see at the bite site.

First Aid

There is no definitive first aid for latrodectism. Cold packs on the bite area sometimes help diminish pain. A snake bite type bandage will make pain worse and is not recommended.

Treatment

All suspected or definite cases of red back spider bite with evidence of envenoming should be assessed in a hospital, but asymptomatic cases do not require hospital assessment and should be advised to seek medical care only if they become symptomatic. Antivenom should be given only if there is a pattern of symptoms and signs consistent with significant envenoming, including severe local pain unresponsive to analgesics if it is a confirmed red back bite. Full systemic envenoming is not a requirement to justify antivenom treatment for red back spider bite, unlike snakebite.

Criteria for significant envenoming are:

History of local pain becoming severe, or spreading proximally, becoming regional or even truncal and severe in nature.

± Local or regional or generalised profuse sweating.



- ± Headache, malaise, nausea.
- ± Hypertension.

Antivenom

CSL Red Back Spider Antivenom is refined horse IgG Fab2, averaging 1.5mL per vial. It should be given IM (intramuscularly) or IV with all facilities ready to treat anaphylactic type reaction, including adrenaline 1:1,000 drawn up ready to use IM or SC. Anaphylaxis to this antivenom is rare. The initial dose is 2 vials. While the recommended route is still IM, there is an increasing trend to using IV. While initial research is encouraging that IV may be a better route, this has yet to be confirmed by definitive research. For IV administration dilute the antivenom in 100ml of normal saline and administer over 20mins using a pump. This method is to reduce the risk of allergic reaction. If the patient has been bitten by a red back spider, within 2 hours of administration of antivenom, often within 30mins, there should be some resolution of symptoms of envenoming. This may be a complete and permanent resolution, a partial resolution, or resolution with subsequent relapse. In the latter two situations, another 2 vials of antivenom should be given. Occasionally even a further antivenom is required, but rarely more than this. A case of suspected red back spider bite in which there is no discernible response to 4 vials of antivenom is most likely not a case of latrodectism. If in doubt ring **Prof. White, 0419-825029; Poisons Information Centre, 131126.**

Is it a red back spider bite or some other type of spider bite?

Often it is clear that the spider was, most likely, a red back spider, but this may not always be the case. A useful algorithm for deciding on the most likely type of spider has been developed (Isbister & Sibbritt 2004), with particular reference to “big black spiders” that might be a funnel web spider. This algorithm is shown on page 12. Like all such algorithms, it cannot cover all situations, but is a useful guide for clinicians. It has been designed to indicate the most likely spider group, based on circumstances of the bite (location, time of year, time of day) and early local clinical effects (specifically local diaphoresis or increased sweating). It then classifies the spider into one of three groups; (i) big black spiders, which includes funnel web spiders, (ii) red back spiders, (iii) all other spiders, which are, in general, unlikely to cause significant effects and are therefore of no great medical concern.

PROTOCOL FOR MANAGING FUNNEL WEB SPIDER BITE

BASIC INFORMATION

Funnel web spider bite is a medical emergency, potentially life threatening, and is NOT a simple matter of just giving antivenom. **EXPERT ADVICE** is available;

Prof. White, 0419-825029; Poisons Information Centre, 131126.

A considerable number of funnel web spider bites do not result in significant illness, and do not require Antivenom, but **ALL suspected or confirmed funnel web spider bites must be observed** for at least 4 hours.

As noted earlier in this document, funnel web spiders have a limited distribution in South Australia and bites are very rare, with none causing envenoming so far. The following information, based on guidelines for N.S.W., is included here for completeness, in the unlikely event that a significant funnel web spider bite occurred in S.A..

PROTOCOL

[1] [a] Possible or definite funnel web spider bite: GO TO Section [2].

OR

[b] The patient presents unwell, diagnosis uncertain. There is a history of possible exposure to funnel web spiders (i.e. in an area within the range of these spiders etc), and the patient has any of the following; tingling around lips, tongue fasciculation, excessive lachrymation, salivation, piloerection, hypertension, nausea, dyspnoea (pulmonary oedema), impaired conscious state: If after consideration it appears funnel web spider bite is a likely diagnosis, urgently consider antivenom therapy GO TO Section [3] for advice on management.

[2] [a] The patient is unwell, possibly envenomed. GO TO Section [3] (below).

OR

[b] The patient is well, no apparent envenoming. GO TO Section [6].

[3] Management of the envenomed or possibly envenomed patient:

[i] Urgent Treatment:

- Respiratory failure due to pulmonary oedema: artificial ventilation; mouth to mouth; bag/mask; bag/endotracheal tube as needed. Intubation and PEEP may assist in severe cases.
- Circulatory failure: if cardiac arrest, cardiopulmonary resuscitation.
- Insert an IV line (normal saline, run at maintenance, keep the patient fasted).
- If profound hypotension, IV volume restoration/electrolyte solution. A degree of hypertension is more commonly encountered.
- CSL Funnel Web Spider Antivenom is vital in treating systemic envenoming and is clearly an essential part of emergency management (see section [5] for details on administration).
- Apply pressure bandage/ immobilisation first aid, (remove when initial antivenom therapy is completed).
- Blood samples:
 - complete blood picture
 - electrolytes, renal function, CK

[ii] History:

- was a spider seen to bite (?multiple bites) OR were the circumstances such that a bite might have occurred?
- when did the patient get bitten (elapsed time)?
- description of spider if possible (colour,size, shape)
- geographic place that the incident occurred
- timing and type of first aid and activity after the bite
- type and timing of symptoms; specifically ask about tingling around lips, tongue fasciculation, excessive lachrymation, salivation, piloerection, hypertension, nausea, dyspnoea (pulmonary oedema), impaired conscious state.
- relevant past history; specifically ask about allergy or past exposure to funnel web spider antivenom, atopic (allergy) history, renal, cardiac, or respiratory disease.

[iii] Examination:

- assess patient status looking for:
 - local piloerection at bite site (if unbandaged)
 - tongue fasciculation
 - increased lachrymation, salivation
 - piloerection
 - tachycardia, hypertension
 - pulmonary oedema

[iv] Determine if there is systemic envenoming.

If there is then ANTIVENOM therapy will probably be needed.

Systemic envenoming is present if there is:

- tongue fasciculation
- increased lachrymation, salivation
- piloerection distant from bite site
- tachycardia, hypertension
- pulmonary oedema

If systemic envenoming is present, urgently consider ANTIVENOM therapy as this may be life saving; see Section [5] for guide-lines on use and techniques of administration.

[vi] Ongoing care:

Should include; constant nursing care, with specific instructions to look for evidence of developing systemic envenoming; monitor urine output; check and update tetanus immunisation status.

[vii] Once situation is stabilised it may be possible to remove all first aid, but this may be left on for several hours if there is severe systemic envenoming, as there is evidence that it may increase local destruction of venom (not seen with snake venoms).

[4] Venom Detection:

[i] There is no venom detection available for spider bites.

[5] Antivenom Therapy:

[i] Antivenom is the definitive treatment of envenoming, and is potentially life saving. Antivenom should only be used if there is systemic envenoming. Only a minority of patients bitten by funnel web spiders will require antivenom therapy.

[ii] See guide-lines in Section [3] [iv] for determining if systemic envenoming has occurred.

[iii] Antivenom administration:

- Antivenom for funnel web spider bite should *always be given IV*, with all facilities ready to hand to treat anaphylaxis in the rare event that it should occur (see section [5] [vi] for a suggested regime) (because of the nature of envenoming by funnel web spiders, with catecholamine storm, anaphylaxis is very unlikely).

- Have an IV line set up and running. Start infusion very slowly carefully observing patient for reaction (look for rash, hypotension, bronchospasm; in children warning signs also include nasal, palatal, or ocular pruritis, coughing, sneezing, profuse sweating, faecal or urinary urgency or incontinence, abdominal pain and a sense of impending doom), and increase rate aiming to give whole dose over 15 to 20 minutes.

[iv] Antivenom dose:

- The minimum dose is two vials of the CSL Funnel Web Spider Antivenom.

- Children require the same dose as adults.

- Multiple bites or severe envenoming mandate higher doses; commence with at least 4 vials, and be prepared to give more. Eight vials is not unusual in a severe bite.

- If there is incomplete response to initial antivenom, give further doses until all significant symptoms and signs have resolved. Be aware that relapse may occur greater than 6 hours after initial response to therapy, requiring further doses of antivenom. If the only residual problem is pulmonary oedema this may well be an effect of envenoming, but consider the possibility of IV fluid overload as an alternative, especially in children who have received large amounts of IV fluid.

[v] Premedication prior to antivenom therapy:

- This is unnecessary for CSL Funnel Web Spider Antivenom. **Be fully prepared to treat anaphylaxis if it occurs** with adrenaline (see section [5] [vi] below for guidelines on use of adrenaline), volume load with SPPS, and such other measures as may be indicated.

[vi] Management of anaphylaxis:

(i) *Preparation prior to commencing antivenom.*

1. Dedicate one small bore (18-20 G in adults) IV line to antivenom administration, and one large bore IV line (16-14 G in adults) for emergency resuscitation.
2. Prepare 1L Normal Saline (20 ml/kg in children) ready to give under pressure.
3. Prepare adrenaline 1:1000 (1mg in 1 mL) drawn up to a dose of 0.01 mg/kg (max. 0.3 mg, i.e. max 0.3 mL) and label "adrenaline for i.m. injection only (dose in mg)".

4. Prepare an i.v. infusion of adrenaline 1mg in 100 mL (controlled by infusion pump or syringe driver) ready to attach by a side arm to the resuscitation line. Anti-reflux valves must be attached above the side arm on any other infusions using this i.v., to prevent adrenaline going back up into the other fluid bags. To prevent erroneous administration, do not attach the adrenaline infusion unless it is needed.
5. Record blood pressures on the other side to the fluid/adrenaline infusion, to avoid pronged cuff inflations and thus extravasation of infusion fluids.

(ii) Management of a reaction

Most reactions are related to the rate of antivenom infusion, and cause flushing, hypotension and bronchospasm. Some mild reactions resolve with temporary cessation of the antivenom infusion and recommencing it at a slower rate. *Envenomed patients may be severely coagulopathic*, so it is important to be cautious when giving adrenaline to avoid blood pressure surges, which might lead to intracerebral haemorrhage.

Initial management of severe reactions (sudden hypotension, bronchospasm):

- Suspend the antivenom infusion
- Lie the patient flat (if not already), commence high flow/100% oxygen and support airway/ventilation as required
- Rapid infusion of 1L N Saline (20 mL/kg in children) over 2-3 minutes
- Adrenaline i.m. into the lateral thigh, 0.01 mg/kg to maximum of 0.3 mg (alternatively, those experienced with i.v. adrenaline infusions may proceed directly to this, as below)
- Liaise with toxicology service regarding ongoing management

For reactions that do not respond to initial management:

- If hypotensive, repeat Normal Saline bolus as above (up to 50 mL/kg may be required)
- Commence i.v. infusion of adrenaline (0.5-1 mL/kg/hour, of 1 mg in 100 mL) and titrate according to response; monitor BP every 3-5 minutes (using the arm opposite to the infusion); beware that as the reaction resolves adrenaline requirements will fall, the blood pressure will rise and the infusion rate will need to be reduced
- Consider nebulised salbutamol for bronchospasm, nebulised adrenaline for upper airway obstruction, and i.v. atropine for severe bradycardia
- Seek advice urgently from the local/regional ED Consultant &/or ICU Consultant

[6] The patient appears well, no apparent evidence of envenoming.

[i] Quickly ascertain:

History:

- was a spider seen to bite (?multiple bites) OR were the circumstances such that a bite might have occurred?
- when did the patient get bitten (elapsed time)?
- description of spider if possible (colour, size, shape)
- geographic place that the incident occurred
- timing and type of first aid and activity after the bite

- type and timing of symptoms; specifically ask about tingling around lips, tongue fasciculation, excessive lachrymation, salivation, piloerection, hypertension, nausea, dyspnoea (pulmonary oedema), impaired conscious state.
- relevant past history; specifically ask about allergy or past exposure to antivenom, atopic (allergy) history, renal, cardiac, or respiratory disease.

Examination:

- assess patient status looking for:
- local piloerection at bite site (if unbandaged)
- tongue fasciculation
- increased lachrymation, salivation
- piloerection
- tachycardia, hypertension
- pulmonary oedema

Investigations: There are no investigations specific for funnel web spider envenoming.

- [ii] If after performing the above there is evidence of systemic envenoming then proceed as for Section [3] above.
- [iii] If after performing the above there is no clinical evidence of envenoming then observe the patient for a minimum of 4 hours after removal of first aid.

MOUSE SPIDERS

The mouse spiders of the genus *Missulena* are possibly of medical significance, as there is a single report of significant envenoming in a child bitten in SE Queensland. In this case, symptoms were similar to those seen in funnel web spider bite and there was some improvement following administration of funnel web spider antivenom. However, there are a considerable number of recorded bites from these spiders without any significant medical effects. This may just indicate a low rate of effective bites.



Venom research has demonstrated strong similarities in actions and toxicity between mouse spider and funnel web spider venoms. Similarly, research has indicated that mouse spider venom is neutralised by CSL Funnel Web Spider Antivenom. Therefore, in the unlikely event of major envenoming by a mouse spider, CSL Funnel Web Spider Antivenom is a recommended therapeutic option, with dosage as for funnel web spider envenoming.

MISCELLANEOUS SPIDERS AND OTHER ARTHROPODS

BLACK HOUSE SPIDER

This common black spider is often found in and around buildings. It is more hairy and robust of body and legs than the red back spider. Bites often cause local pain, redness and sometimes a mild general malaise, but not the severe, spreading pain of *latrodectism*.

Treatment is symptomatic, with analgesics as necessary, updating tetanus immune status and antibiotics if there is clear evidence of secondary infection.



WHITE TAILED SPIDER

This common house hunting spider has gained a formidable reputation for causing skin damage, essentially unsubstantiated by case reports from mainland Australia. There are numerous cases of bites reported without any significant local injury or effects, with only mild local discomfort and a small red lump, settling after about 24 hours. In a major series of 130 confirmed cases, none developed either infection or skin damage.

Most cases of bites by this spider will probably not require any treatment. Should the bite area become red and painful over the first 24-48 hours, consider secondary infection as a cause and treat with antibiotics.



NECROTIC ARACHNIDISM

Most patients are either unaware of a bite or cannot adequately describe the spider, particularly since most cases occur at night or while gardening. Though the white-tailed spider is often blamed, there is now strong evidence that it does not cause skin injury and it should not be invoked as a cause of skin damage. There are other types of spider, particularly outside Australia, which can cause primary skin necrosis. Foremost amongst these is the recluse spider group (*Loxoscelis*), including the fiddleback spider, *Loxosceles rufescens*, now clearly implicated in some South Australian cases of "necrotic arachnidism".

If there is initial pain, then blistering and dusky colouration of the skin, developing over 2-7 days, with later darkening of the skin suggestive of developing skin necrosis, consider necrotic arachnidism, but only after all other causes have been excluded. Though the Americans have lived with *Loxoscelism* for many years, treatment remains controversial. Early surgical excision, steroids and antibiotics do not appear generally helpful, though secondary infection clearly requires treatment.

AN APPROACH TO THE INVESTIGATION AND DIAGNOSIS OF NECROTIC SKIN ULCERS PRESENTING AS SUSPECTED SPIDER BITES

(Adapted from: Isbister GK, Whyte IM. Suspected white-tail spider bite and necrotic ulcers. *Internal Medicine Journal* 2004; 34(1-2):38-44).

Establish whether or not there is a history of spider bite

Clear history of spider bite (better if spider is caught):

- Refer to information on definite spider bites

No history of spider bite:

- Investigation should focus on the clinical findings: ulcer or skin lesion
- Provisional diagnosis of a suspected spider bite is inappropriate

Clinical history and examination

Important considerations:

- Features suggestive of infection, malignant processes or vasculitis
- Underlying disease processes: diabetes, vascular disease
- Environmental exposure: soil, chemical, infective
- Prescription medications
- History of minor trauma

Specific historical information about the ulcer can assist in differentiating some conditions:

- Painful or painless
- Duration and time of progression
- Preceding lesion

Investigations

Skin biopsy:

- Microbiology: contact microbiology laboratory before collecting specimens so that appropriate material and transport conditions are used for fungi, *Mycobacterium* spp, and unusual bacteria
- Histopathology

Laboratory Investigations: may be important for underlying conditions (autoimmune conditions, vasculitis), including, but not be limited, to:

- Biochemistry (including liver and renal function tests)
- FBC and coagulation studies
- Autoimmune screening tests, cryoglobulins

Imaging:

- Chest radiography
- Colonoscopy
- Vascular function studies of lower limbs

Treatment

Local wound management

Treatment based on definite diagnosis or established pathology

Investigation and treatment of underlying conditions may be important, (eg, pyoderma gangrenosum or diabetes mellitus)

Follow-up and monitoring

The diagnosis may take weeks or months to be established, so patients must have ongoing follow-up.

Continuing management: co-ordinated with multiple specialities involved

if present. Hyperbaric oxygen therapy has been suggested and anecdotal cases suggest it may be beneficial if there is significant necrosis developing. It has not yet been proved by clinical trial and is clearly impractical as routine treatment of every case. Good wound care appears to be fundamental in treatment, along with elevation and rest of the affected area.

HUNTSMAN SPIDER

There are many species of huntsman spiders. Most are reluctant to bite, but can cause local pain and redness, usually of short duration only. Occasionally the pain is more severe and the patient may feel generally unwell for about 24 hours.

Most cases of bites by this spider will probably not require any treatment. Should the bite area become red and painful over the first 24-48 hours, consider secondary infection as a cause and treat with antibiotics.



STEATODA SPIDER

This common relative of the red back spider looks similar to the red back, except it never has the red markings, being a uniform black. Its bites can cause local pain and redness, but usually not the spreading severe pain of latrodectism.

Most cases of bites by this spider will probably not require any treatment. Should the bite area become red and painful over the first 24-48 hours, consider secondary infection as a cause and treat with antibiotics. For rare cases showing features of latrodectism, CSL Red Back Spider Antivenom should be considered.



ORB WEAVING SPIDERS

There are a vast number of species, sizes and shapes of these common spiders, all characterised by the use of orb shaped webs to catch their prey. Most species are too small to bite humans effectively, but a few of the larger species may cause mild to moderate local pain and redness of usually short duration, without significant systemic effects.

Most cases of bites by this spider will probably not require any treatment. Should the bite area become red and painful over the first 24-48 hours, consider secondary infection as a cause and treat with antibiotics.



WOLF SPIDERS

These common ground hunters are well represented in arid areas, often living in burrows in the ground, sometimes with a palisade at the entrance, or even a trapdoor. Their big eyes give eyeshine at night when spotlighting. Few bites are recorded in Australia and they are unlikely to cause more than mild local pain and redness of short duration. Given their commonness, they are reluctant to bite.

Most cases of bites by this spider will probably not require any treatment. Should the bite area become red and painful over the first 24-48 hours, consider secondary infection as a cause and treat with antibiotics.



MITTURGID SPIDERS

These often large spiders are superficially similar to wolf spiders, but with less prominent eyes. Little is known about their bites, but local pain and redness might be expected.

Most cases of bites by this spider will probably not require any treatment. Should the bite area become red and painful over the first 24-48 hours, consider secondary infection as a cause and treat with antibiotics.



SCORPIONS

Many scorpions are found in Australia, but none are dangerous. Most live either under rocks or debris or in deep twisting burrows they dig in the sand. All are active at night. Their sting, in the tail, usually causes intense local pain lasting 15-45 mins, occasionally longer, but only rarely are there any systemic symptoms.

Most cases of scorpion stings will probably not require any treatment. If pain is very severe and prolonged then analgesics may be required.

Should the sting area become red and painful over the first 24-48 hours, consider secondary infection as a cause and treat with antibiotics.



CENTIPEDES

The larger centipedes can bite humans, using the fangs at the front of the head, not the harmless tail appendages. The venom can cause intense local pain, similar to scorpion sting, but also some mild local skin damage, and secondary infection is always possible and not rare.

Most cases of centipede bites will probably not require any treatment. If pain is very severe and prolonged then analgesics may be required. Should the bite area become red and painful over the first 24-48 hours, consider secondary infection as a cause and treat with antibiotics.



INSECTS

Many insects can either sting or bite humans, but few cause more than minor local irritation, except in hypersensitive individuals. Some Hymenoptera, such as bees, wasps and primitive ants such as inch or bulldog ants, have a sting in their abdomen/tail attached to a venom gland. Stings can be quite painful and may result in allergic reactions, up to and including anaphylaxis. Secondary infection, though uncommon, may occur. Honey bees leave their sting in the wound, but wasps and ants do not, so may sting more than once.

Application of a local cold pack may help reduce pain and swelling. If there is a history of increasingly severe local reactions to stings, or any form of systemic reaction, the patient should be referred to an immunologist or allergist for consideration of desensitisation therapy and instructed on what to do if there is an anaphylactic reaction. In selected cases it may be justified to give the patient an adrenaline inhaler or injection set, together with comprehensive instructions on use.



RECOMMENDED FURTHER READING

The following books are useful sources of further information and are not listed in order of importance. There are many papers published on aspects on envenoming, relevant to Australia, which may be found in a variety of journals or via Index Medicus. Of particular note is *The Medical Journal of Australia* for clinical information and *Toxicon* for venom research.

COGGER, H.G. (2000) *Reptiles and Amphibians of Australia*, 6th edition. Sydney: Reed New Holland. The most comprehensive textbook on the taxonomy of Australian venomous snakes (and other reptiles). Contains comprehensive identification keys.

COVACEVICH, J., DAVIE, P., PEARN, J. Eds. (1987) *Toxic Plants and Animals: A Guide for Australia*. Brisbane:Queensland Museum. A detailed textbook on many of Australia's venomous animals, with especially detailed sections on venomous snakes and snakebite.

EHMANN, H. (1992) *Encyclopedia of Australian Animals: Reptiles*. Sydney:Angus & Robertson. A comprehensive book on the biology and taxonomy of venomous snakes (and other reptiles).

ISBISTER, G.K., WHITE, J. (2004) Clinical consequences of spider bites: recent advances in our understanding. *Toxicon*, 43(5):477-492.

ISBISTER, G.K. (2004) Marine envenomation and poisoning. In ed. Dart, R. *Medical Toxicology*, Lippincott, Williams & Wilkins, pps 1621-1644.

ISBISTER, G.K. (2004) Other arthropods. In ed. Dart, R. *Medical Toxicology*, Lippincott, Williams & Wilkins, pps 1606-1620.

MEIER, J., WHITE, J. Eds. (1995) *Handbook of Clinical Toxicology of Animal Venoms and Poisons*. Boca Raton: CRC Press. Classic textbook of clinical toxinology from global perspective, including detailed information on Australian venomous animals and their effects.

PEARN, J., COVACEVICH, J. (1988) *Venoms and Victims*. Brisbane:Queensland Museum & Amphion Press. A small book detailing some interesting aspects of envenoming, with a clinical viewpoint.

SHINE, R. (1991) *Australian Snakes: A Natural History*. Sydney:Reed Books. A detailed account of the biology and ecology of Australian snakes.

SUTHERLAND, S.K., TIBBALLS J. (2001) *Australian Animal Toxins*. Melbourne: Oxford University Press. The classic work on Australian venomous animals and their clinical effects. 2nd edition.

WHITE, J. (2002) *CSL Antivenom Handbook*. Melbourne: CSL Ltd. Standard work on Australian antivenoms. 2nd edition.

WHITE, J. (2005) *Australian and Pacific Snakes*. In eds. Brent, J. et al, *Critical Care Toxicology*. Mosby.

WHITE, J. (2004) Elapid snakes. In ed. Dart, R. *Medical Toxicology*, Lippincott, Williams & Wilkins, pps 1566-1578.

WHITE, J. (2005) Snake venoms and coagulopathy. *Toxicon*, 45:951-967.

WHITE, J. (2002) Venomous Australian snakes. *Current Therapeutics*, 43(2):19-27.

WHITE, J. (2002) Terrestrial animals. *Current Therapeutics*, 43(2):28-34.

WHITE, J. (2002) Marine animals. *Current Therapeutics*, 43(2):37-45.

HOSPITAL SPECIFIC INFORMATION

The table on the following pages lists each SA hospital, with occurrence of major venomous snakes in the hinterland for each hospital (shown as “+” if present or possibly present; “-” if absent or unlikely to be present). Such a listing is approximate, because detailed information on precise point by point distribution for each species is not available. It is meant as a guide, not an absolute statement of what may be found in the area.

On the opposite page the table lists recommended antivenom stocks for each listed hospital. These recommendations are based on a review of risks, facilities, past usage and other practical considerations. Few hospitals will hold optimal stocks to fully treat one, let alone two cases of major envenoming by a given type of snake. What is important is that stocks are sufficient to at least start treatment, while further stocks and/or retrieval are being sought. For those hospitals with stock levels below the ideal starting dose for brown snake or tiger snake type envenoming, it is expected that available stocks will only be used where there is an immediate threat to life, while awaiting supplemental stocks from another hospital and a retrieval.

For small country hospitals with limited resources and no access to on-site laboratory testing, the decision to stock any antivenom must be based on distance to a more major hospital versus risk and local resources. Each hospital has been evaluated separately as each has its own unique characteristics. Thus one hospital with very limited resources may be recommended to stock antivenom, while a similarly resourced hospital elsewhere may not be recommended to stock any antivenom at all. Such differences will reflect degree of isolation and risk.

It is critically important in assessing a case of suspected snakebite to be able to determine degree of systemic envenoming in all four major risk areas; neurotoxic flaccid paralysis; coagulopathy; myolysis; renal damage. While the first, paralysis, is principally assessed clinically, the other three rely on laboratory testing. Because of this, it is always preferable to manage snakebite cases in hospitals with full laboratory facilities. This will exclude most country hospitals. However, the use of a glass test tube to conduct whole blood clotting time testing will allow even small country hospitals to commence meaningful initial assessment.

HOSPITAL SPECIFIC INFORMATION

Major dangerous snake groups found in approximate hospital hinterland.

<i>Hospital</i>	<i>Brown snakes</i>	<i>Tiger snakes</i>	<i>Copper-heads</i>	<i>Mulga snake</i>	<i>Red bellied black snake</i>	<i>Inland taipan</i>	<i>Death adders</i>	<i>Yellow faced whip snake</i>
Angaston Hospital	+	-	-	-	+	-	-	+
Balaklava Hospital	+	-	-	-	+	-	-	+
Barmera Hospital	+	+	-	+	-	-	-	+
Berri Hospital	+	+	-	+	-	-	-	+
Booleroo Centre Hospital	+	-	-	+	-	-	-	+
Bordertown Hospital	+	+	-	-	-	-	-	-
Burra Hospital	+	-	-	+	-	-	-	+
Ceduna Health Service	+	+	-	+	-	-	+	+
Central Yorke Peninsula Hospital, Maitland	+	-	-	-	-	-	-	+
Clare Hospital	+	-	-	-	-	-	-	+
Cleve Hospital	+	-	-	+	-	-	+	+
Coober Pedy Hospital	+	-	-	+	-	+	+	+
Cowell Hospital	+	-	-	+	-	-	+	+
Crystal Brook Hospital	+	-	-	-	-	-	-	+
Cummins Hospital	+	-	-	+	-	-	+	+
Elliston Hospital	+	-	-	+	-	-	+	+
Eudunda Hospital	+	-	-	-	+	-	-	+
Flinders Medical Centre	+	+	+	-	+	-	-	-
Gawler Health Service	+	-	-	-	-	-	-	-
Gumeracha Hospital	+	-	+	-	+	-	-	+
Hawker Hospital	+	-	-	+	-	-	-	+
Jamestown Hospital	+	-	-	-	-	-	-	+
Kangaroo Island Hospital	-	+	+	-	-	-	-	-
Kapunda Hospital	+	-	-	-	+	-	-	+
Karoonda Hospital	+	-	-	-	-	-	-	+
Kimba Hospital	+	-	-	+	-	-	+	+
Kingston Hospital	+	+	-	-	-	-	-	-
Lameroo Hospital	+	-	-	-	-	-	-	+

HOSPITAL SPECIFIC INFORMATION

Recommended antivenom stocks for each hospital.

<i>Hospital</i>	<i>Brown snake AV</i>	<i>Tiger snake AV</i>	<i>Black snake AV</i>	<i>Death adder AV</i>	<i>Taipan AV</i>	<i>Poly-valent AV</i>	<i>Red back spider AV</i>	<i>Funnel web spider AV</i>	<i>SVDC</i>
Angaston Hospital	0	0	0	0	0	0	0	0	0
Balaklava Hospital	2	0	0	0	0	0	2	0	1
Barmera Hospital	0	0	0	0	0	0	0	0	0
Berri Hospital	5	4	1	0	0	2	3	0	3
Booleeroo Centre Hospital	3	0	0	0	0	0	1	0	1
Bordertown Hospital	3	1	0	0	0	0	2	0	1
Burra Hospital	0	0	0	0	0	0	2	0	0
Ceduna Health Service	3	2	0	0	0	1	2	0	1
Central Yorke Peninsula Hospital, Maitland	0	0	0	0	0	0	0	0	0
Clare Hospital	3	0	0	0	0	0	2	0	1
Cleve Hospital	3	0	1	0	0	0	2	0	1
Cooper Pedy Hospital	3	0	0	0	0	1	3	0	1
Cowell Hospital	0	0	0	0	0	0	0	0	0
Crystal Brook Hospital	0	0	0	0	0	0	0	0	0
Cummins Hospital	3	0	0	0	0	1	0	0	1
Elliston Hospital	3	0	0	0	0	1	2	0	1
Eudunda Hospital	0	0	0	0	0	0	0	0	0
Flinders Medical Centre	8	5	1	1	0	4	5	0	2
Gawler Health Service	0	0	0	0	0	0	2	0	0
Gumeracha Hospital	0	0	0	0	0	0	0	0	0
Hawker Hospital	3	0	1	0	0	0	2	0	1
Jamestown Hospital	3	0	0	0	0	0	2	0	1
Kangaroo Island Hospital	0	3	0	0	0	0	2	0	0
Kapunda Hospital	0	0	0	0	0	0	0	0	0
Karoonda Hospital	0	0	0	0	0	0	0	0	0
Kimba Hospital	0	0	0	0	0	0	0	0	0
Kingston Hospital	3	3	0	0	0	0	2	0	1
Lameroo Hospital	3	0	0	0	0	0	2	0	1

Major dangerous snake groups found in approximate hospital hinterland.

<i>Hospital</i>	<i>Brown snakes</i>	<i>Tiger snakes</i>	<i>Copper-heads</i>	<i>Mulga snake</i>	<i>Red bellied black snake</i>	<i>Inland taipan</i>	<i>Death adders</i>	<i>Yellow faced whip snake</i>
Leigh Creek Hospital	+	-	-	+	-	-	-	+
Loxton Hospital	+	+	-	-	-	-	-	+
Lyell McEwin Hospital	+	-	-	-	+	-	-	-
Mannum Hospital	+	+	-	-	+	-	-	+
Meningie Hospital	+	+	-	-	+	-	-	-
Mid-West Health, Wudinna	+	-	-	+	-	-	+	+
Millicent Hospital	+	+	+	-	-	-	-	-
Modbury Hospital	+	-	+	-	+	-	-	+
Mount Barker Hospital	+	+	+	-	+	-	-	+
Mount Gambier Hospital	+	+	+	-	-	-	-	-
Mount Pleasant Hospital	+	+	-	-	+	-	-	+
Murray Bridge Hospital	+	+	-	-	+	-	-	+
Naracoorte Health Service	+	+	+	-	-	-	-	-
Noarlunga Health Service	+	+	-	-	+	-	-	-
Orroroo Health Service	+	-	-	+	-	-	-	+
Penola Hospital	+	+	+	-	-	-	-	-
Peterborough Hospital	+	-	-	+	-	-	-	+
Pinnaroo Hospital	+	-	-	-	-	-	-	+
Port Augusta Hospital	+	+	-	+	-	-	+	+
Port Broughton Hospital	+	-	-	-	-	-	+	+
Port Lincoln Hospital	+	+	-	+	-	-	+	+
Port Pirie Hospital	+	+	-	+	-	-	+	+
Quorn Health Service	+	+	-	+	-	-	-	+
Renmark Hospital	+	+	-	+	-	-	-	+
Repatriation Hospital	+	-	-	-	-	-	-	-
Riverton Hospital	+	-	-	-	+	-	-	+
Rocky River Health Service	+	-	-	-	-	-	-	+
Roxby Downs Health Service	+	-	-	+	-	+	+	+

Recommended antivenom stocks for each hospital.

<i>Hospital</i>	<i>Brown snake AV</i>	<i>Tiger snake AV</i>	<i>Black snake AV</i>	<i>Death adder AV</i>	<i>Taipan AV</i>	<i>Poly-valent AV</i>	<i>Red back spider AV</i>	<i>Funnel web spider AV</i>	<i>SVDK</i>
Leigh Creek Hospital	3	0	1	0	0	0	2	0	1
Loxton Hospital	3	3	0	0	0	0	2	0	1
Lyell McEwin Hospital	5	4	0	0	0	2	5	0	2
Mannum Hospital	3	3	0	0	0	0	0	0	1
Meningie Hospital	3	3	0	0	0	0	0	0	1
Mid-West Health, Wudinna	3	0	0	0	0	1	2	0	1
Millicent Hospital	3	3	0	0	0	0	2	0	1
Modbury Hospital	3	0	0	0	0	1	3	0	1
Mount Barker Hospital	3	2	0	0	0	0	2	0	1
Mount Gambier Hospital	5	8	0	0	0	0	3	0	2
Mount Pleasant Hospital	3	0	0	0	0	0	2	0	1
Murray Bridge Hospital	5	4	0	0	0	0	3	0	2
Naracoorte Health Service	3	3	0	0	0	0	2	0	1
Noarlunga Health Service	0	0	0	0	0	0	2	0	0
Orroroo Health Service	3	0	0	0	0	1	2	0	1
Penola Hospital	0	0	0	0	0	0	2	0	0
Peterborough Hospital	0	0	0	0	0	0	0	0	0
Pinnaroo Hospital	3	0	0	0	0	0	2	0	1
Port Augusta Hospital	8	4	1	0	0	2	3	0	2
Port Broughton Hospital	0	0	0	0	0	0	2	0	0
Port Lincoln Hospital	5	4	0	0	0	1	3	0	2
Port Pirie Hospital	5	4	0	0	0	1	6	0	2
Quorn Health Service	0	0	0	0	0	0	0	0	0
Renmark Hospital	3	3	0	0	0	2	2	0	1
Repatriation Hospital	0	0	0	0	0	0	0	0	0
Riverton Hospital	0	0	0	0	0	0	0	0	0
Rocky River Health Service	0	0	0	0	0	0	0	0	0
Roxby Downs Health Service	3	0	0	0	0	1	3	0	1

Major dangerous snake groups found in approximate hospital hinterland.

<i>Hospital</i>	<i>Brown snakes</i>	<i>Tiger snakes</i>	<i>Copper-heads</i>	<i>Mulga snake</i>	<i>Red bellied black snake</i>	<i>Inland taipan</i>	<i>Death adders</i>	<i>Yellow faced whip snake</i>
Royal Adelaide Hospital	+	+	+	-	+	-	-	-
SA Ambulance Service								
Snowtown Hospital	+	-	-	-	-	-	-	+
South Coast District Hospital, Victor Harbor	+	+	-	-	+	-	-	-
Strathalbyn Health Service	+	+	+	-	+	-	-	+
Streaky Bay Hospital	+	+	-	+	-	-	+	+
Tailem Bend Hospital	+	+	-	-	+	-	-	+
Tanunda Hospital	+	-	-	-	+	-	-	+
The Queen Elizabeth Hospital	+	-	-	-	-	-	-	-
Tumby Bay Hospital	+	+	-	+	-	-	+	+
Waikerie Health Service	+	+	-	+	+	-	+	+
Walleroo Hospital	+	-	-	-	-	-	+	+
Whyalla Hospital	+	-	-	+	-	-	+	+
Women's & Children's Hospital	+	+	+	-	+	-	-	-
Woomera Hospital	+	-	-	+	-	-	+	+
Yorke town Hospital	+	+	-	-	-	-	-	+

Recommended antivenom stocks for each hospital.

<i>Hospital</i>	<i>Brown snake AV</i>	<i>Tiger snake AV</i>	<i>Black snake AV</i>	<i>Death adder AV</i>	<i>Taipan AV</i>	<i>Poly-valent AV</i>	<i>Red back spider AV</i>	<i>Funnel web spider AV</i>	<i>SVDK</i>
Royal Adelaide Hospital	10	6	1	1	0	4	5	0	3
SA Ambulance Service	0	0	0	0	0	0	0	0	0
Snowtown Hospital	0	0	0	0	0	0	0	0	0
South Coast District Hospital, Victor Harbor	3	3	0	0	0	0	2	0	1
Strathalbyn Health Service	0	0	0	0	0	0	0	0	0
Streaky Bay Hospital	3	0	0	0	0	1	2	0	1
Tallem Bend Hospital	0	0	0	0	0	0	0	0	0
Tanunda Hospital	2	0	0	0	0	1	2	0	1
The Queen Elizabeth Hospital	0	0	0	0	0	0	5	0	0
Tumby Bay Hospital	3	2	0	0	0	1	2	0	1
Waikerie Health Service	3	2	0	0	0	0	2	0	1
Walleroo Hospital	3	0	0	0	0	0	3	0	1
Whyalla Hospital	5	4	1	0	0	1	4	0	3
Women's & Children's Hospital	5	4	1	1	0	1	3	1	3
Woomera Hospital	3	0	1	0	0	0	2	0	1
Yorketown Hospital	3	1	0	0	0	0	2	0	1