

Sarcoptic mange in wildlife

D.B. Pence⁽¹⁾ & E. Ueckermann⁽²⁾

(1) Department of Pathology, Texas Tech University Health Sciences Center, 3601 4th Street, Lubbock, Texas 79430, United States of America

(2) Agricultural Research Council-Plant Protection Research Institute, Biosystematic Division: Arachnology, Private Bag X134, Pretoria 0001, South Africa

Summary

Sarcoptic mange caused by *Sarcoptes scabiei* is responsible for epizootic disease in populations of wild canids in North America, Europe and Australia, wild cats in Europe and Africa, wild ungulates and wild boars in Europe, wombats and koalas in Australia, and great apes and various wild bovids in Africa. Although short-term mortality may appear devastating, in a self-sustaining population, mortality is non-compensatory and a mange epizootic generally does not affect long-term population dynamics. Alternatively, the net effect of a mange epizootic can have serious consequences in remnant or fragmented populations of CITES-listed, threatened, or endangered species where loss of even a few individuals can be critical to the survival or restoration of a species (CITES: Convention on International Trade in Endangered Species of Wild Fauna and Flora). The pathogenesis and concordant clinical symptoms of mange depends on the immune status of the respective host. Naïve, immunocompromised or anergic animals that are unable to evoke hypersensitivity responses develop an extensive epidermal hyperkeratosis usually without marked alopecia, but with an underlying chronic dermal inflammation and an abundance of mites in the skin. Immunocompetent hosts are able to develop strong types I and IV hypersensitivity responses that result in a marked decrease and eventual loss of mites in the skin. However, there are dramatic structural and functional changes in the skin; it becomes extensively thickened, greyish in colour and there is a marked eosinophilia throughout the epidermis and dermis. There is often almost complete alopecia. Isolation and treatment of infected individuals may be warranted, and has met with some success in small remaining populations of certain highly endangered species.

Keywords

Anergia – Epizootics – Hypersensitivity – *Sarcoptes scabiei* – Sarcoptic mange – Wildlife.

Introduction

Sarcoptic mange is a highly contagious mite infection caused by *Sarcoptes scabiei* in the skin of domestic and wild mammals. Scabies is a human infection with the same mite. The entire subject of sarcoptic mange in wildlife has been discussed in a recent review (10). The purpose of this paper is not to duplicate, but rather to supplement, that work. Herein, the authors emphasise the dual nature of the pathogenesis of sarcoptic mange and provide greater detail on certain clinical aspects of the disease in some of the more important wildlife species.

Distribution

Sarcoptic mange has been reported from 10 orders, 27 families and 104 species of domestic, free-ranging and wild mammals. A complete list of these hosts has been published (10).

While isolated cases of mange are reported from many different hosts, the disease may reach epizootic proportions in certain wildlife populations. These include coyotes (*Canis latrans*), red foxes (*Vulpes vulpes*) and grey wolves (*Canis lupus*) in North America (31, 43, 45, 46, 51, 56, 58, 59), arctic foxes (*Alopex lagopus*), red foxes, and grey wolves in Europe (18, 23, 36), red

foxes and dingoes (*Canis familiaris dingo*) in Australia (19, 32, 33), lynx (*Lynx lynx*) in Europe (21, 36, 49), lions (*Panthera leo*) and cheetahs (*Acinonyx jubatus*) in Africa (39, 62), chamois (*Rupicapra rupicapra*), ibex (*Capra ibex*), and Iberian ibex (*Capra pyrenaica*) in Europe (15, 23, 40, 42, 48), wild boars (*Sus scrofa*) in Europe (23), wombats (*Vombatus ursinus*) and koalas (*Phascolarctos cinereus*) in Australia (7, 11, 19, 34, 53), mountain gorillas (*Gorilla gorilla berengei*) and possibly chimpanzees (*Pan spp.*) in Africa (13, 24) and impala (*Aepyceros melampus*), hartebeest (*Alcelaphus buselaphus*), springbok (*Antidorcas marsupialis*), wildebeest (*Connochaetes taurinus*), buffalo (*Syncerus caffer*), eland (*Taurotragus oryx*), kudu (*Tragelaphus strepsiceros*), Grant's and Thompson's gazelle (*Gazella gazella* and *G. thompsoni*, respectively) and sable antelope (*Hippotragus niger*) in Africa (50, 62, 64).

Aetiology

Epizootic sarcoptic mange is caused by *Sarcoptes scabiei* (L., 1758, Latrille, 1802) (Acari: Astigmata, Sarcoptidae), a submacroscopic burrowing mite (Fig. 1) in which male and female adults, larvae, protonymphs, tritonymphs, and eggs occur in the epidermis to the level of the stratum granulosum (Fig. 2) (4). The burrowing mites consume living cells and tissue fluid (3). The developmental cycle and life history stages of *S. scabiei* have been discussed in detail (4, 13). The morphology, intraspecific variation and taxonomic implications

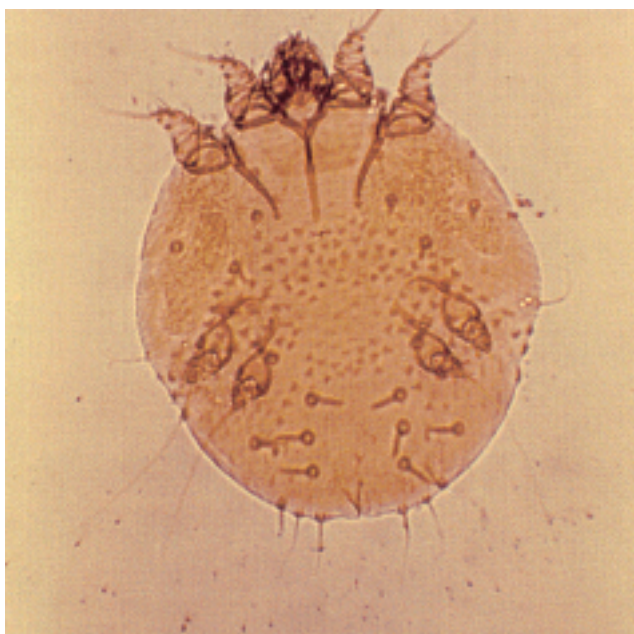

Fig. 1
Photomicrograph of the ventral view of an unstained adult female *Sarcoptes scabiei*

Diagnostic features include the tooth-like denticles in the mid-dorsal idiosoma and the clublike setae on the posterior idiosoma
Photo: courtesy of D.B. Pence

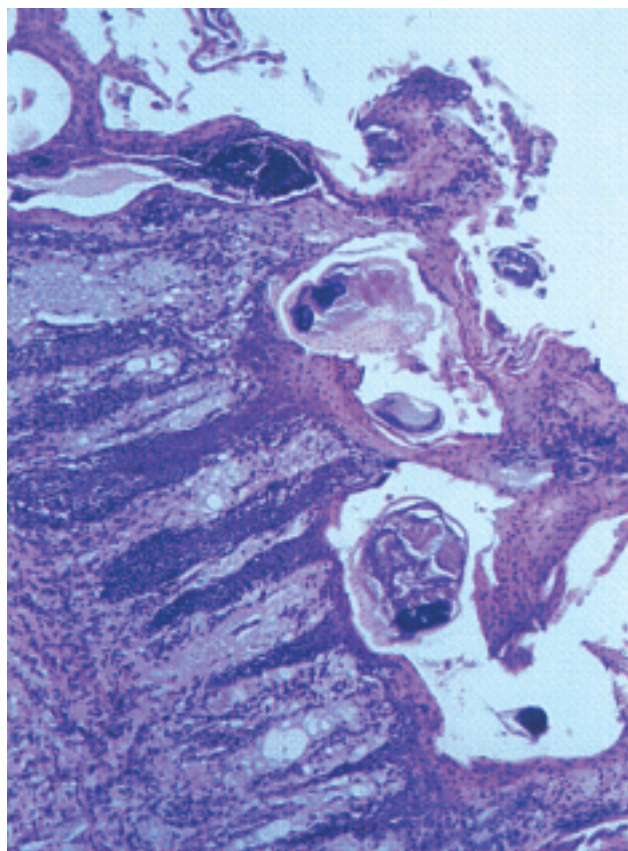


Fig. 2
Histological section of skin from a coyote that has developed hypersensitivity to class II sarcoptic mange

Sections of a few mites and extensive hyperkeratosis are seen in the stratum corneum while an inflammatory infiltration and hyperplasia is evident in the stratum granulosum

Haematoxylin and eosin

Photo: courtesy of D.B. Pence

of the species also are discussed in detail elsewhere (13, 43). There are no definitive means to taxonomically distinguish the various strains that manifest a fairly high degree of host specificity for their respective host species. It has been proposed that the mite causing mange in wild and domestic animals is a single highly variable species manifesting physiological specificity across a wide range of different hosts (13, 43). Thus, *S. scabiei* as a species is divided into morphologically indistinguishable varieties that have a high degree of host specificity and low degree of cross infectivity. The varieties are named for their predominant host species, such as *S. scabiei* var. *canis*, *S. scabiei* var. *suis*, etc.

Epizootiology

Probably *S. scabiei* originated as a human parasite and man spread the infection to domestic animals (14). Various wildlife species in turn were infected, often from contact with their domestic counterparts.

All the life history stages of *S. scabiei* can be found in the same host individual. Transmission between hosts can be by direct contact of infected with uninfected animals since larvae and nymphs leave their burrows and wander on the skin surface (4). Alternatively, transmission may be by indirect contact since mites can apparently survive for some time off their hosts and still remain infective for a new host individual (2). For example, uninfected foxes occupying the former dens of mange foxes can become infected (16).

Since transmission is by direct or indirect contact it tends to be density-dependent. For example, mange is more prevalent when coyote population densities in Texas are high (46). The same is true for common wombat populations in Australia and mange is also more prevalent in times of higher environmental stress, such as during droughts or winter (53, 55).

The important epizootics of sarcoptic mange in wildlife species have been reviewed recently (10). The epizootiology of sarcoptic mange seems to differ across different geographic areas and host populations. The short-term effects of a mange epizootic can appear to have a dramatic effect on an affected wildlife population. However, appearances can sometimes be deceiving in terms of the ultimate effects of a mange epizootic in wildlife species, the numbers of which are sufficient to sustain the population over what appears to be devastatingly high losses. Pence and Windberg (46) showed that, while a southern Texas (USA) coyote population experienced approximately 70% mortality at the peak of a mange epizootic which lasted several years, the epizootic had no long-term effect on coyote abundance. Likewise, despite the apparent short-term devastating effects of the many recently reported epizootics in red foxes, coyotes, and grey wolves across many different areas of North America (31, 43, 45, 46, 51, 56, 58, 59), these populations remain stable or are increasing in most areas. Apparently, these epizootics seem to cycle every 30 to 45 years in some areas (46). Indeed, there is evidence that while mange can severely effect the short-term population levels of naïve hosts, the populations will recover over a longer period. Such was the apparent case with the introduction of sarcoptic mange into the naïve red fox population in Fennoscandia in the 1960s and 1970s. Although the fox population experienced an overall decline of 50% and up to 90% mortality in some areas (36), it had begun to recover during the late 1980s (29). Likewise, sarcoptic mange does not seem to have had any severe long-term effects on other red fox populations in Europe where epizootics have been reported in the Ukraine (16), Germany (23) and Spain (18). This also seems to be the case for red fox and dingo populations experiencing sarcoptic mange epizootics in Australia (19, 32, 33). Unfortunately, the long-term healthy prognosis for a mange furbearer population does little to allay the immediate concerns of the conservationists or the fur trappers who witness the extensive morbidity and mortality.

Despite the outcries of concerned hunters, the authors likewise conjecture that sarcoptic mange epizootics in other common

and ecologically stable host species will have little or no long-term ramifications at the population level. Small epizootic outbreaks of sarcoptic mange have been reported from many wild hosts. Examples include wild boar populations in central and southern Europe (23), red deer (*Cervus elaphus*) and roe deer (*Capreolus capreolus*) in central Europe (23, 26), several of the larger bovid ungulates in South Africa (64), llamas (*Llama glama*) and other camelids in South America (26), dingo and red fox populations in Queensland (32, 33), and perhaps many of the other potential wild hosts that have stable populations.

Alternatively, sarcoptic mange in remnant or isolated populations, even in species that are not listed by the Convention on International Trade in Endangered Species of Wild Fauna and Flora (CITES), can have a much more serious long-term effect. An example of this is the red fox population on the island of Bornholm in Denmark. After sarcoptic mange was introduced into the naïve fox population, an epizootic ensued, and foxes disappeared from the island (20).

Mange can seriously affect populations of CITES-listed species that are not yet considered 'endangered'. A mange epizootic has been reported in the common chimpanzee (*Pan troglodytes*) in central Africa (13). Although about 200,000 individuals remain over Africa, this species is in a precarious situation because its population is highly fragmented with limited exchange. Here, the loss of a few individuals from a disease such as mange sometimes becomes critical. As is the case with the common chimpanzee, apparently approximately 200,000 lions remain in Africa. Their population is also somewhat fragmented. More importantly, the lion population in parts of South Africa is experiencing a serious tuberculosis (TB) epizootic due to the consumption of TB-infected buffalo and kudu carcasses. Many of these lions also are sero-positive for feline immunodeficiency virus (FIV), although to date, no clinical feline AIDS syndrome has been recognised, and no link has been confirmed between FIV and TB infection in lions. Sarcoptic mange has been reported in these free-ranging lions (62), but it occurs sporadically and is density-dependent, usually affecting cubs. In these large and relatively pristine ecosystems, mange appears to be a natural regulatory mechanism of populations.

Epizootics of sarcoptic mange that occur periodically in Australia have the potential to threaten the survival of some of the remaining small remnant populations of the common wombat (*Vombatus ursinus*), and perhaps the less abundant and more ecologically restricted southern hairy-nosed wombat (*Lasiorchinus latifrons*) (34).

The remnant populations of endangered species may be unable to tolerate even a few cases of a disease such as sarcoptic mange. In Africa, endangered species at risk where sarcoptic mange has been reported, but with unknown consequences, include the Bonobo chimpanzee (*Pan paniscus*) (13), cheetah (39), and the wild dog (*Lycaon pictus*) (39). In addition, an outbreak of mange has been reported in the highly endangered mountain

gorilla in Uganda (24). In mountainous areas across southern Europe, sarcoptic mange is the most common cause of mortality in the small fragmented populations of the highly endangered chamois and Iberian Ibex (15, 48). In these areas, sarcoptic mange also has been reported in the remnant populations of the highly endangered European mouflon (*Ovis orientalis musimon*) (25, 26).

Pathogenesis and pathology

Sarcoptes scabiei burrows into the skin, usually to the level of the stratum germinativum (Fig. 2). Part of the burrowing is accomplished by the action of the cutting mouthparts, chelicerae and gnathosoma (3), and cutting hooks on the legs (61). However, little is known concerning the substances secreted by the mite that might aid in the digestion of host tissue to facilitate burrowing and feeding. It has been suggested (45) and partially substantiated (46) that the epizootics in many wildlife populations that recur every 30 to 40 years may result from the appearance of a new virulent strain of *S. scabiei*. Perhaps these new strains have developed mutant forms of keratinases or similar proteolytic enzymes that make it easier for them to invade and burrow through the skin of an antigenically naïve host.

Certainly the mechanical disruption and ingestion of cells and tissue fluid by the mites in the skin contribute to the pathogenesis of sarcoptic mange. The excretions and secretions of living mites may have an irritant and allergenic effect. A massive amount of antigenic material is released in the skin, including dead mites, molted skins of living adult and immature mites, and eggshells. Thus, a large part of the pathogenesis of sarcoptic mange is undoubtedly a manifestation of hypersensitivity to the mites. Both types I and type IV hypersensitivity have been demonstrated in some domestic animals such as the dog (10) and pig (12). However, only immediate (type I) hypersensitivity was demonstrated in experimentally infected red foxes (30). This also seemed to occur in coyotes; even those with advanced cases of class III mange (45). In the thickened, hyperkeratotic and hyperpigmented skin of these animals (Figs 3 and 4), the cellular reaction is more reflective of the eosinophilic inflammation observed in immediate hypersensitivity than the chronic granulomatous inflammation seen in delayed hypersensitivity. As the hypersensitivity reaction progresses, mites decrease in the lesions (Fig. 2). As pruritis increases, so also do the number and severity of traumatic lesions (Fig. 4).

The pathogenesis of experimental sarcoptic mange infections in swine seems to be reflective of those of most other hosts that have been critically examined (61). Initial lesions of sarcoptic mange in many hosts are localised and non-pruritic. After a period of several weeks there is a generalised urticarial eruption with severe pruritis. This is the hallmark of the development of



Fig. 3
An advanced case of severe class III sarcoptic mange in a juvenile coyote from Texas

Note the almost complete alopecia except the hair along the back of the neck and along the back and the thickened slate-grey to bluish appearing skin over most of the body

Photo: courtesy of D.B. Pence

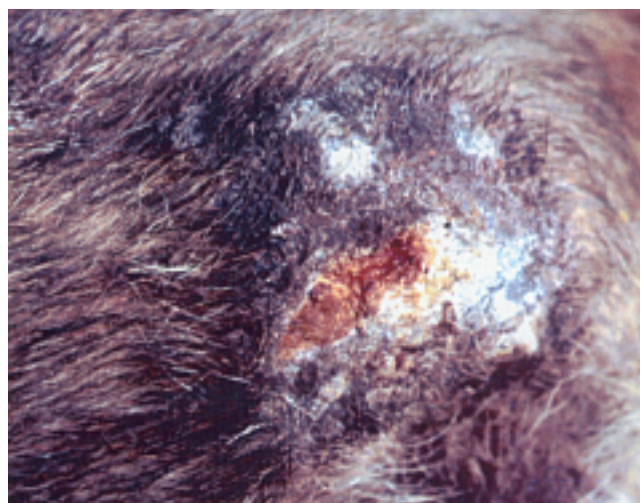


Fig. 4
Skin of coyote with class III sarcoptic mange showing detail of changes indicative of a severe hypersensitivity response

Note the self-inflicted traumatic lesion in response to the intense pruritis

Photo: courtesy of D.B. Pence

an allergic response in the host. Depending on the host, this may or may not be accompanied by a delayed hypersensitivity response. Usually there are few or no mites associated with these later lesions. As emphasised for domestic animals (61), it appears that many sarcoptic mange-related diseases in wildlife are caused principally by the allergic response and the lesions are from self-inflicted trauma induced by the intense pruritis (Fig. 4). However, recently exposed, previously naïve new hosts as well as otherwise anergic and malnourished animals may develop non-pruritic, severe crusting dermatitis. These lesions characteristically have severe hyperkeratosis, a serosanguineous exudate and large numbers of mites (Fig. 5). These are the kinds of lesions sometimes seen in winter in ibex, chamois and red deer (malnourished?) in the Austrian Alps (see Figs. 1.35 and 1.37 in 57) and Spain (Figs 6 and 7), in lynx (anergic?) in Sweden and Switzerland (Figs 8 and 9) and in common wombats (recently exposed naïve or anergic?) in Australia (Figs 10 and 11).

Histologically, initial skin lesions are notably those of hyperkeratosis with accumulations of serum exudate and

extravasated erythrocytes in the stratum corneum, acanthosis, parakeratosis, hyperplasia of the stratum germinativum, plugged, hyperplastic and inflamed sebaceous glands and hair follicles, and a generalised inflammatory infiltration of neutrophils, lymphocytes and plasma cells (Fig. 2) (45). Initially, there is dermal oedema and an inflammatory infiltration of lymphocytes and plasma cells. In immunologically competent hosts that evoke a hypersensitivity response to *S. scabiei*, there are epidermal and dermal infiltrations of large numbers of eosinophils. As the allergic response progresses, mites become rare or absent and there is

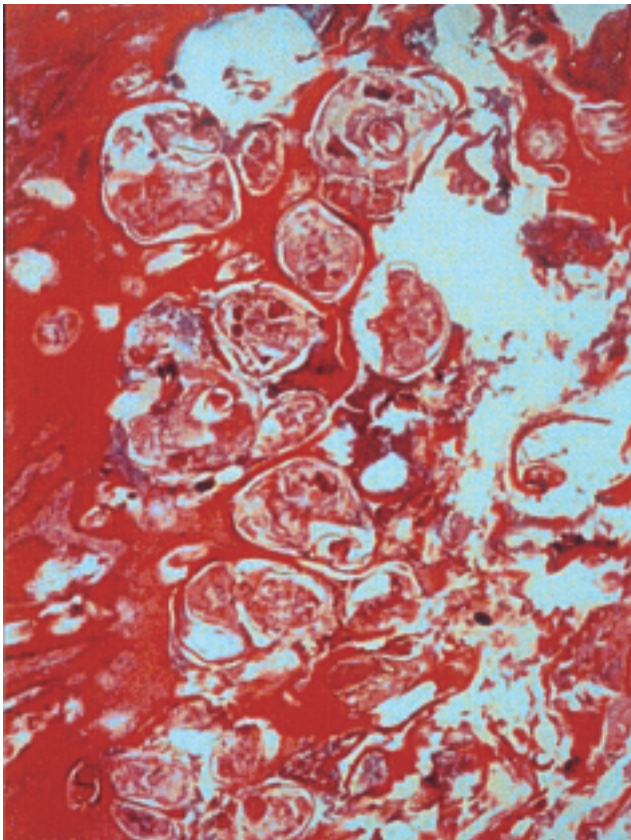


Fig. 5
Histological section of skin from a European lynx that has advanced sarcoptic mange
 Sections of many mites and extensive hyperkeratosis are seen in the stratum corium, and there is no evidence of a hypersensitivity response Best's Carmine
 Photo: courtesy of M.-P. Ryser-Degiorgis



Fig. 6
Spanish ibex from Spain with severe chronic stage sarcoptic mange
 A mixed clinical picture is presented, showing lesions that seem indicative of having developed some level of hypersensitivity with pruritis, but mites are still abundant in the skin
 The lesions on the face, ears, around the nostrils, trunk, abdomen and limbs are dry encrustations with fissuring, but in some areas such as around the eye the skin has become somewhat thickened and wrinkled with alopecia from rubbing that is indicative of pruritis
 Photo: courtesy of L. León-Vizcaíno

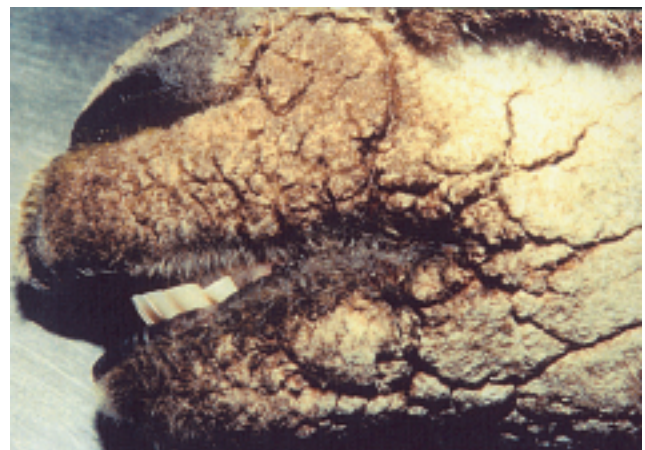

Fig. 7
Spanish ibex with hyperkeratotic and parakeratotic lesions on the muzzle manifested as heavy encrustations with fissuring
 Such lesions are usually indicative of lack of a hypersensitivity response due to anergia or malnourishment
 Photo: courtesy of L. León-Vizcaíno



Fig. 8
European lynx from Sweden with the anergic form of severe sarcoptic mange

The fur is shabby and the carcass is emaciated. There is some evidence of encrustations on the head, ears, and legs. While there are severe lesions over most of the body of this animal, they are not very evident because of the thick fur

Photo: courtesy of M.-P. Ryser-Degiorgis



Fig. 9
Typical lesions of sarcoptic mange on the ear of a European lynx

The heavy encrustations with fissuring are indicative of a lack of a hypersensitivity response. Large numbers of mites are present in these lesions

Photo: courtesy of M.-P. Ryser-Degiorgis



Fig. 10
Common wombat from Australia with an advanced stage of sarcoptic mange

Lack of hypersensitivity response results in lesions manifesting as severe encrustations with fissuring of the skin over most areas of the body. Extensive alopecia is evident on the head and anterior torso

Photo: courtesy of L.F. Skerratt

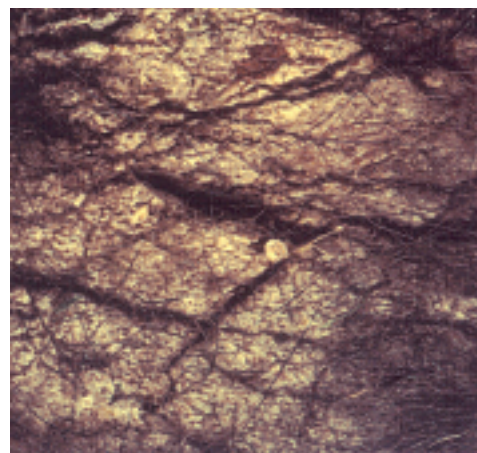


Fig. 11
Skin of a common wombat with skin lesions usually typical of anergia

There is alopecia. Thick dry crusts on the skin surface may become fissured and haemorrhage or become pyodermic. Many mites occur in the skin

Photo: courtesy of L.F. Skerratt

extensive fibroplasia and chronic inflammation of the dermis. In immunologically compromised animals that do not initiate a hypersensitivity response, eosinophils are scarce and there is little evidence of a chronically inflamed or fibroplastic dermis. Many mites may be seen in tissue sections for the duration of these infections (Fig. 5).

Clinical signs

The initial lesions, their subsequent progression, and the concordant clinical signs of sarcoptic mange varies considerably among the many different host species that may be infected. The course of the disease and the concordant clinical symptoms is determined by the immunological state of the host. Specifically, this depends on whether or not the host species is immunologically naïve, or, if it has been previously exposed to the mite, whether or not it is anergic or can evoke hypersensitivity responses. Whether the host is immunologically compromised or not, the lesions initially consist of non-pruritic patches of erythematous papules grading into seborrheic dermatitis. Mites may not be particularly abundant in the skin at this point.

After several weeks, as a hypersensitivity response eventually develops in immunologically competent hosts, the lesions become intensely pruritic and there is extensive hyperkeratosis, alopecia, and dermal inflammation. Mites may be isolated in large numbers from the skin during this time. Finally, after many weeks to months, the end result is a highly dysfunctional skin covering much of the body of the animal. The skin becomes greatly thickened, wrinkled, hairless, and often discoloured to a slate grey colour. Mites are rarely seen in these advanced lesions. Eventually, infected animals become listless, dehydrated, and emaciated. Most eventually die from the infection.

There are varying degrees of alopecia in the naïve or immunologically compromised host. The skin lesions are those of an encrusting dermatitis without pruritis. The dermatitis becomes extensive, often covering most of the body. The thickened dry crusts on the skin surface fissure and haemorrhage or are pyodermic. Mites are present in large numbers. The debilitated host becomes emaciated and often succumbs to the infection.

Three classes of progression of lesions of sarcoptic mange are described in coyotes in Texas (Fig. 12) (45). This seems to be the pattern of progression of the disease in wild canids elsewhere, including other species such as red foxes, red wolves (*Canis rufus*), grey wolves and probably jackals (*Canis aureus*) (see Fig. 5.5 in 10) (9, 36, 37, 44, 58, 59). Animals with class I infections had initial lesions of small dry scabby encrustations with or without alopecia and without suppuration or thickening of the skin. Lesions were always

found on the lower fore and hind limbs and a small spot on the ischium (Fig. 12). These are often most pronounced on the elbows, hocks and at the base of the tail (35). Rarely, small lesions appear on the ears. Class II mange was described as an active progressive infection with larger lesions on the elbows, hocks and knees, and ischial region (Fig. 12). There was usually alopecia, some suppurative encrustations, and greatly hyperkeratotic darkly pigmented and wrinkled skin. In these animals there were also class I lesions over much of the fore and hind limbs and ischial region becoming confluent on the ventral surface, flanks and shoulders. The back of the head, ears and muzzle were usually affected. However, less than a half of the body was involved. Coyotes with advanced cases of active mange were considered as class III if more than a half of the body was covered (Fig. 12). Frequently, in coyotes and

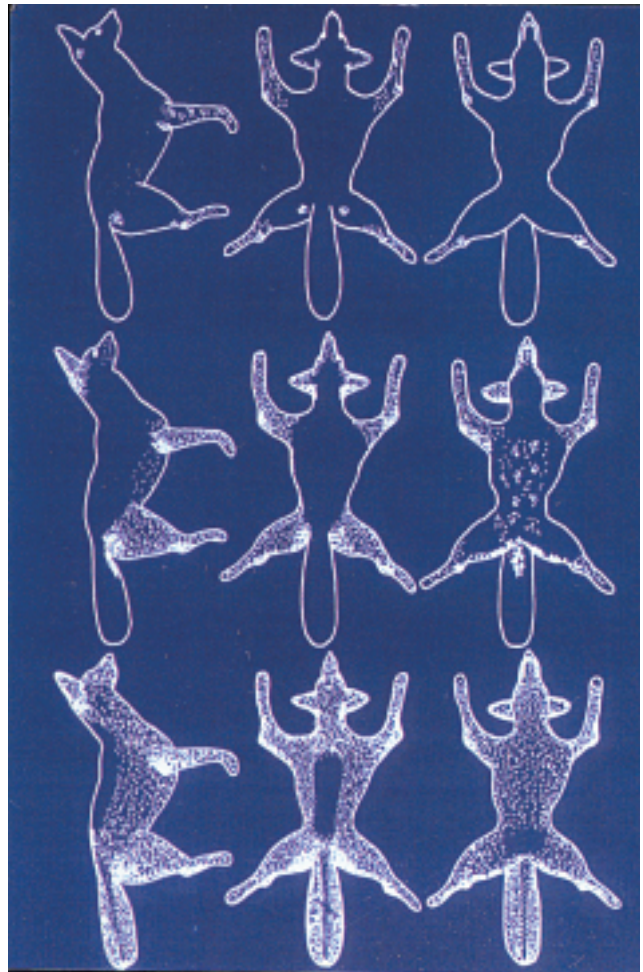


Fig. 12

Classes of mange in coyotes

Class I (top) is the initial infection with lesions on the fore and hind limbs, ischium and base of the ears

Class II (middle) has more advanced lesions covering up to a half of the body surface

Class III (bottom) involves greater than a half of the total body surface and may leave the animal essentially hairless except for the back

Photo: courtesy of D.B. Pence (redrawn from Pence *et al.* [45])

other canids with advanced mange, almost all the body is involved with partial to almost total alopecia of the legs, flanks, abdomen, chest, shoulders, tail (rat-tail), and head (Figs 3 and 13). The skin over much of the affected area is thickened, wrinkled and slate-grey in colour (Fig. 4). Except in the most advanced cases, there are numerous suppurative encrustations. There is an additional class, class IV, in which a very small number of animals (3% of all the animals examined) had healing and partial regrowth of hair at the periphery of lesions that would otherwise be classed as class I or II. These animals were apparently recovering from the infection.

The distribution of lesions seems to be slightly different in domestic dogs and in the closely related dingo in Australia (22, 32, 33). The preferred sites in both are the elbows, hocks, ventral thorax, and margin of the pinna (61). In addition, these lesions and alopecia may become generalised in untreated animals covering the entire body, including the back that usually remains unaffected in wild canids (Figs 3 and 13).



Fig. 13
A case of advanced sarcoptic mange in a jackal from South Africa

The lesions are similar to those of other wild canids and indicative of a severe hypersensitivity response with traumatic lesions from rubbing and scratching

Photo: courtesy of R.G. Bengis

Based on the heavy intensities of mites reported in one pup (22), the immune response of the dingo may not control the infection to the same extent as in dogs. There is now good evidence that *S. scabiei* was introduced into Australia since the arrival of Europeans (L. Skerratt, personal communication). Thus, it is reasonable that the dingo would be a somewhat more naïve host than the dog. Dingoes lived in a mange-free environment for a long period of time.

Clinical manifestations of sarcoptic mange in the lynx from Scandinavia and the Swiss Alps seem to be those usually associated with the lack of a hypersensitivity response (M.-P. Ryser-Degiorgis, personal communication). Lesions are those of an extensive encrusting dermatitis that covers the entire body but are usually more prominent on the head, ears, feet and tail (Fig. 8). Typical changes are thick crusts with deep fissures (Fig. 9). Self-trauma as a consequence of pruritis is rarely observed, alopecia is spotty and never generalised, and mites are very numerous in scrapings and in histological sections (Fig. 5) (M.-P. Ryser-Degiorgis, personal communication) (49).

It is unclear from the description as to the exact nature and distribution of sarcoptic mange lesions in the cheetah in Africa (39). Apparently, there were areas of alopecia and encrustations, with *S. scabiei* isolated from nine of twelve cheetahs. Some level of hypersensitivity response in this host was confirmed as there was a dermal mixed inflammatory infiltration with many eosinophils, but the epithelial surface of the skin was covered by a thick serosanguineous exudate with mites in cross section (39). Most of the mange seen in cheetah in Southern Africa is caused by *Notoedres cati*, and the lesions are generally localised to the pinnae, head, neck and shoulders. Many of these diminutive mites are present in skin scrapings, and a mixed inflammatory reaction is present in the dermis (R.G. Bengis, personal communication). Mange caused by *S. scabiei* also has been seen in the leopard (Fig. 14) (R.G. Bengis, personal



Fig. 14
A case of sarcoptic mange in a leopard from South Africa

Alopecia and encrustations on the head and anterior body are evident, but the nature of the lesions are undescribed

Photo: courtesy of R.G. Bengis

communication), and the nature of the disease process falls into the hypersensitivity category, with severe pruritis, alopecia, hyperkeratosis and thickened lead-coloured skin.

Sarcoptic mange was known to occur in lions in South Africa at least thirty years ago (64), which suggests a fairly long host-parasite association with the concomitant development of hypersensitivity responses. However, cubs are more frequently affected clinically than adults, with mixed inflammatory responses. Certainly, the lesions sometimes observed in lion cubs (Fig. 15) are suggestive of those seen in the European lynx, but vary considerably, probably related to social and hence nutritional stress, due to their low ranking in the social hierarchical structure.



Fig. 15
A case of sarcoptic mange in a lion cub from South Africa

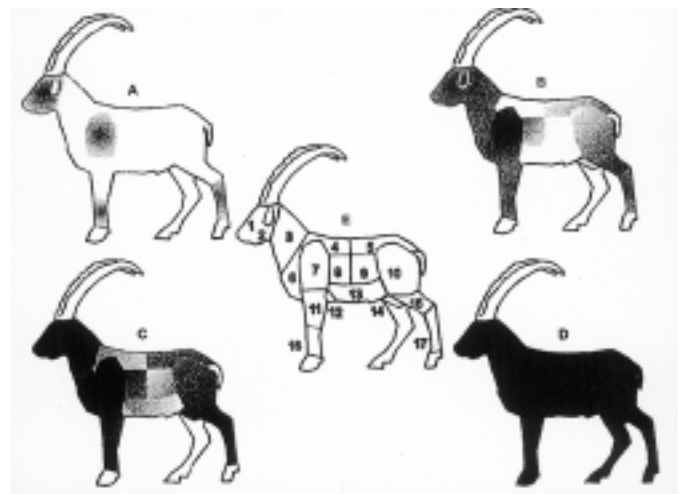
The lesions have not been adequately described, but are reminiscent of those observed in the European lynx suggesting a lack of hypersensitivity response

Photo: courtesy of R.G. Bengis

Common wombats with sarcoptic mange are severely debilitated. They become emaciated and have skin lesions usually typical of anergia (52). These lesions, suggestive of anergia, are also reported in koalas infected with *S. scabiei* (11). In infected wombats, there is alopecia in addition to thick dry crusts on the skin surface that may become fissured and haemorrhagic or become pyodermic, and many mites occur in the skin (Figs 10 and 11) (52). The crust appears similar to that in humans with 'Norwegian itch' or super-scabies, or in domestic animals with hyperkeratotic sarcoptic mange (52). Lesions may occur over the entire body, but the head, neck, shoulders and limbs are most often involved (52). Vision is affected in some animals with infected eyelids. The usual skin lesions are epidermal thickening with numerous mites present and a mild predominantly mononuclear dermal infiltrate (53, 55). However, while most wombats manifest signs of anergia,

there is evidence that a hypersensitivity response may occur in some wombats that manifest an intense pruritis and have few mites in the skin (38, 47).

Lesions of sarcoptic mange in ibex, chamois and red deer across Europe appear similar. They seem to be indicative of hosts that have been exposed fairly recently to the sarcoptic mange mite, but that have already developed some level of hypersensitivity response. There are hyperkeratotic and parakeratotic lesions on the face, ears, around the nostrils (Figs 6 and 7) and these subsequently extend to the trunk, abdomen and limbs (Fig. 6). The lesions are dry encrustations with fissuring, or the skin may become somewhat thickened and wrinkled (8, 15, 27, 41). A similar clinical picture is described for the Siberian ibex (*Capra siberica*) in central Asia (60). The progression of the disease is best documented in the Spanish ibex (Fig. 16) (27). In the



A. Initial stage when mites are isolated from the face¹, shoulder⁷, carpus¹⁶ and tarsus¹⁷
B. Developmental stage when mites advanced to the neck², elbow¹¹, ear², and knee¹⁵, and could be found in the pelvis¹⁰, costal area³, chest⁵, groin¹⁴ and lumbar-sacra¹⁵ areas
C. Consolidation stage when mites invaded the back⁴, axilla¹², abdomen¹³ and flanks⁹
D. Chronic stage when the entire body is infected with mites

Fig. 16
Progression of sarcoptic mange lesions in the Spanish ibex

Photo: courtesy of *Journal of Wildlife Diseases*

(reprinted from León-Vizcaíno *et al.* [27])

initial stage, the disease commences on the face, shoulders, carpus and tarsus. During the developmental stage, the mite spreads to the neck, elbows, ears, and knees; prevalence is higher in the costal, lumbar-sacral, and groin areas. In the initial and developmental stages, there is evidence of pruritis with rubbing, with numerous mites present in the skin. The initial normal appearance of the skin becomes reddened as infection progresses. In the consolidation stage *S. scabiei* was found in all corporal areas, but less frequently on the back, axilla or flanks. Pruritis is more intense, there are bald spots on the skin from rubbing, and over most of the body there is evidence of mange lesions. The skin is lusterless, inelastic and thickened and often

becomes scabby and cracked (Fig. 7). In the chronic stage, more severe lesions and mites were found on all parts of the body; a greater degree of hyperkeratosis and alopecia is seen than in the consolidation phase. Mites are still abundant. The disease may follow a similar pattern in some of the other wild ungulates, such as Barbary sheep (17) and the African ungulates (64). Certainly photographic documentation in some hosts such as the wildebeest (Fig. 17) and impala (Fig. 18) indicates this, but the nature and progression of the lesions in these hosts have not been fully documented.




Fig. 17
A case of sarcoptic mange in a wildebeest from South Africa
 The fissured heavy encrustations are reminiscent of those seen in animals that fail to evoke a sustained hypersensitivity response
 Photo: courtesy of R.G. Bengis



Fig. 18
A case of sarcoptic mange in an impala from South Africa
 The appearance and distribution of lesions are similar to those seen during winter in malnourished red deer in Europe. The heavy encrustations on the head and neck indicate the lack of a hypersensitivity response
 Photo: courtesy of R.G. Bengis

Diagnosis

Sarcoptic mange is often difficult to diagnose because of the submacroscopic size of *S. scabiei* and the plethora of associated clinical lesions they can cause, especially in hypersensitised hosts where the mites have largely disappeared. Deep skin scrapings examined in 10% potassium hydroxide (KOH) is very helpful in hosts where mites are still abundant in the skin. *Sarcoptes scabiei* is easily identified based on the presence of idiosomal denticles and club-shaped setae (Fig. 1) (43). A diagnostic enzyme-linked immunosorbent assay (ELISA) has been developed for a number of host species (10) that can be used to confirm the presence of *S. scabiei* in suspect lesions without mites or for serological surveys.

Immunity

The immune response in sarcoptic mange is a complex, poorly understood subject. Certainly, there is evidence of the protective effect to reinfection in some animals (5, 6), but not in others (30). When present, this appears to be linked more to a cell-mediated immune response than to a humoral response (5), although the latter have been demonstrated in several hosts following infection (10). As previously indicated, whether or not the host can evoke hypersensitivity responses largely determines the pathogenesis and subsequent clinical course of infection.

Public health concerns

Human scabies acquired from a captive wombat was first reported in the early 19th Century (54). Since then, numerous human infections acquired from a number of wild and domestic species have been reported (2, 10). Human infections of animal origin differ from typical human scabies in duration of infection, distribution of lesions, and other symptoms. Infections are usually short-term and self-limited. Lesions often begin on exposed parts of the body where mites enter a hair follicle. A small pustule or erythematous papule develops and is intensely pruritic. Mites do not burrow extensively as in human scabies and the infection often wanes after a few weeks. Otherwise, there are no public health problems associated with sarcoptic mange in wild mammals.

Veterinary public health concerns

Although it is generally recognised to be a single heterogeneous species (63), host specificity varies somewhat among the different strains of *S. scabiei*. Cross-transmission is possible between certain hosts with some strains (9). Thus, cross-transmission of some strains of *S. scabiei* is possible between their wild and domestic hosts (33, 47, 52). Just how frequently this actually occurs and its relative importance to companion animals and domestic livestock remain to be elucidated. For

instance, how frequently domestic canids infect their wild counterparts such as foxes, coyotes, jackals or wolves is unknown. Alternatively, domestic dogs could acquire mange from wild canids, especially during epizootics.

Management of sarcoptic mange

In stable populations, mange epizootics are generally allowed to run their course and seem to have no long-term effect on population abundance (45, 46). Alternatively, as stated above, mange can have devastating effects on small remnant populations, genetically compromised populations, or fragmented populations of threatened or endangered species. In such cases, capture and treatment of individual cases may be

warranted. In social species, it is essential to treat the entire group, family or pride, because if one individual is overlooked, that individual will re-infect the treated individuals after the residual effects of the ivermectin have worn off. Ivermectin has been used to treat individual animals and to establish a pool of mange-free animals in the ongoing restoration programme for the endangered Spanish ibex in Spain (28). The avermectins, especially ivermectin, have been used to treat many different domestic and wild species with success (1), and are the drugs of choice for treatment of sarcoptic mange. In cheetah with notoedric mange, multiple treatments spaced a month apart are necessary to sterilise the infection. ■

La gale sarcoptique chez les animaux sauvages

D.B. Pence & E. Ueckermann

Résumé

La gale sarcoptique, due à *Sarcoptes scabiei*, provoque des épizooties chez de nombreuses espèces d'animaux sauvages, notamment des canidés sauvages en Amérique du Nord, en Europe et en Australie, des chats sauvages en Europe et en Afrique, des ongulés et des sangliers en Europe, les wombats et les koalas en Australie, ainsi que des grands singes et plusieurs types de bovidés en Afrique. Quoique les taux de mortalité puissent paraître dévastateurs à court terme, en réalité dans une population autonome la mortalité n'est pas compensatoire et par conséquent une épizootie de gale n'affecte généralement pas la dynamique des populations à long terme. En revanche, un foyer de gale peut avoir un impact très grave sur les populations survivantes ou dispersées inscrites sur les listes CITES (Convention sur le commerce international des espèces de faune et de flore sauvages menacées d'extinction), ou sur les espèces menacées pour lesquelles chaque animal mort peut signifier un risque d'extinction. La pathogénie de la gale et les signes cliniques correspondants dépendent du degré d'immunité de l'hôte. Chez les animaux exposés pour la première fois, immunodéprimés ou anergiques, et incapables de présenter une réaction d'hypersensibilité, on observe une hyperkératose épidermique extensive, habituellement sans alopecie marquée, mais avec une inflammation dermique chronique sous-jacente et la présence dans la peau de nombreux acariens. En revanche, les hôtes immunocompétents développeront de fortes réactions d'hypersensibilité de types I et IV se traduisant par une diminution sensible du nombre d'acariens dans la peau puis leur élimination. Toutefois, la peau est soumise à d'importantes modifications structurelles et fonctionnelles ; elle s'épaissit, devient grisâtre et l'on observe une hyperéosinophilie de l'épiderme et du derme. Dans la plupart des cas, l'alopecie est quasi intégrale. L'isolement et le traitement des animaux infectés peuvent être d'un grand secours ; ils ont donné de bons résultats chez les populations survivantes de certaines espèces particulièrement menacées.

Mots-clés

Anergie – Épizootie – Gale sarcoptique – Faune sauvage – Hypersensibilité – *Sarcoptes scabiei*. ■

Sarna sarcóptica en los animales salvajes

D.B. Pence & E. Ueckermann

Resumen

La sarna sarcóptica causada por *Sarcoptes scabiei* es responsable de epizootias en poblaciones de cánidos salvajes norteamericanos, europeos y australianos, gatos salvajes europeos y africanos, ungulados salvajes y jabalíes europeos, wombats y koalas australianos y grandes simios y diversos bóvidos salvajes africanos. Aunque las mortandades a corto plazo puedan parecer devastadoras, en poblaciones autosuficientes la mortalidad no es compensatoria, por lo que la sarna sarcóptica no suele incidir en la dinámica demográfica a largo plazo. En cambio, una epizootia de sarna puede tener graves consecuencias si afecta a poblaciones residuales o fragmentadas de especies amenazadas o en peligro de extinción, como las que figuran en la convención CITES (Convención sobre el Comercio Internacional de Especies Amenazadas de Fauna y Flora Silvestres), en cuyo caso la supervivencia o recuperación de la especie puede llegar a depender de la salvación o pérdida de unos pocos individuos. La patogénesis y los correspondientes síntomas clínicos de la sarna dependen del estado inmunitario en que se encuentre el huésped. Un ejemplar no expuesto previamente, en deficientes condiciones inmunitarias o que padezca de anergia, incapaz de generar respuestas de hipersensibilidad, sufrirá una hiperqueratosis epidérmica muy extendida, en general sin alopecia muy marcada pero con inflamación dérmica subyacente de carácter crónico y abundancia de ácaros en la piel. Los ejemplares inmunocompetentes podrán generar una intensa respuesta de hipersensibilidad de tipo I y IV que induzca un sensible decremento del número de ácaros presentes en la piel hasta su total desaparición. No obstante, la piel experimenta una serie de impresionantes cambios estructurales y funcionales: engrosamiento generalizado, color grisáceo y pronunciada eosinofilia en toda la epidermis y la dermis. A menudo se produce una alopecia casi completa. Es posible aislar y tratar a los ejemplares infectados, como se ha hecho con cierto éxito en el caso de pequeñas poblaciones residuales de algunas especies en grave peligro de extinción.

Palabras clave

Anergia – Epizootia – Fauna salvaje – Hipersensibilidad – *Sarcoptes scabiei* – Sarna sarcóptica.



References

1. Arends J.J., Skogerboe T. & Ritzhaupt L.K. (1999). – Persistent efficacy of doramectin and ivermectin against experimental infestations of *Sarcoptes scabiei* var. *suis* in swine. *Vet. Parasitol.*, **82**, 71-79.
2. Arlian L.G. (1989). – Biology, host relations, and epidemiology of *Sarcoptes scabiei*. *Annu. Rev. Entomol.*, **34**, 139-161.
3. Arlian L.G., Runyan R.A. & Vyszenski-Moher D.L. (1988). – Water balance and nutrient procurement of *Sarcoptes scabiei* var. *canis* (Acari: Sarcoptidae). *J. med. Entomol.*, **25**, 64-68.
4. Arlian L.G. & Vyszenski-Moher D.L. (1988). – Life cycle of *Sarcoptes scabiei* var. *canis*. *J. Parasitol.* **74**, 427-430.
5. Arlian L.G., Morgan M.S., Vyszenski-Moher D.L. & Stemmer B.L. (1994). – *Sarcoptes scabiei*: the circulating antibody response and induced immunity to scabies. *Experim. Parasitol.*, **78**, 37-50.
6. Arlian L.G., Morgan M.S. & Arends J.J. (1996). – Immunologic cross-reactivity among various strains of *Sarcoptes scabiei*. *J. Parasitol.*, **82**, 66-72.

7. Arundel J.H., Barker I.K. & Beveridge I. (1977). – Diseases of marsupials. In *The biology of marsupials* (B. Stonehouse & D. Gilmore, eds). University Park Press, Baltimore, 148-149.
8. Bidovec A., Zakrajsek B., Kusej M., Bavdek S., Pogaenik A., Rode B., Breznik B. & Steineck T. (1993). – Chamois (*Rupicapra rupicapra* L.) scabies. In *Proc. First Slovenian Veterinary Congress* (V. Cestnik, ed.), Vol. 2. Slovenian Veterinary Association, Ljubljana, 473-480.
9. Bornstein S., Thebo P. & Zakrisson G. (1995). – Clinical picture and antibody response to experimental *Sarcoptes scabiei* var. *vulpes* infection in red fox (*Vulpes vulpes*). *Acta vet. scand.*, **36**, 509-519.
10. Bornstein S., Mörner T. & Samuel W.M. (2001). – *Sarcoptes scabiei* and sarcoptic mange. In *Parasitic diseases of wild mammals*, 2nd Ed. (W.M. Samuel, M.J. Pybus & A.A. Kocan, eds). Iowa State University Press, Ames, 107-119.
11. Brown A.S., Seawright A.A. & Wilkinson G.T. (1981). – An outbreak of sarcoptic mange in a colony of koalas. In *Wildlife diseases of the Pacific Basin and other countries* (M.E. Fowler, ed.). Fruitridge, Sacramento, 111.
12. Davis D.P. & Moon R.D. (1990). – Dynamics of swine mange: a critical review of the literature. *J. med. Entomol.*, **27**, 727-737.
13. Fain A. (1968). – Étude de la variabilité de *Sarcoptes scabiei* avec une révision des Sarcoptidae. *Acta zool. pathol. antverp.*, **47**, 1-196.
14. Fain A. (1978). – Epidemiological problems of scabies. *Inter. J. Dermatol.*, **17**, 20-30.
15. Fernández-Morán J., Gómez S., Ballesteros F., Quirós P., Benito J.L., Feliu C. & Nieto J.M. (1997). – Epizootiology of sarcoptic mange in a population of cantabrian chamois (*Rupicapra pyrenaica parva*) in northwestern Spain. *Vet. Parasitol.*, **73**, 163-171.
16. Gerasimov Y. (1958). – Mange in wild foxes. Translation of Russian game reports. Canadian Department of Northern Affairs National Resources, Ottawa, 1-5.
17. González-Candela M. & León-Vizcaíno L. (1999). – Sarna sarcóptica en la población de arruí (*Ammotragus lervia*) del parque regional de Sierra Espuña (Murcia). *Galemys*, **11**, 43-58.
18. Gortazar C., Villafuerte R., Blanco J.C. & Fernandez-de-Luco D. (1998). – Enzootic sarcoptic mange in red foxes in Spain. *Zeitschr. Jagdwissenschaft.*, **44**, 251-256.
19. Gray D.F. (1937). – Sarcoptic mange affecting wild fauna in New South Wales. *Aust. vet. J.*, **13**, 154-155.
20. Henriksen P., Dietz H.H., Henriksen S.A. & Gjelstrup P. (1993). – Sarcoptic mange in red fox in Denmark. A short report. *Dansk Vettidsskr.*, **76**, 12-13.
21. Holt G. & Berg C. (1990). – Sarcoptic mange in red fox and other wild mammals in Norway. *Nord. Veterinaertidsskr.*, **102**, 427-432.
22. Hoyte H.M.D. & Mason R.S. (1961). – *Sarcoptes scabiei* in the dingo (*Canis antarcticus*). *Aust. vet. J.*, **37**, 53-54.
23. Ippen R., Nickel S. & Schröder H.-D. (1995). – Krankheiten des Jagdbaren Wildes. Deutscher Land-wirtschaftsverlag, Berlin, 189-195.
24. Kalema G., Koch R.A. & Macfie E. (1998). – An outbreak of sarcoptic mange in free-ranging mountain gorillas (*Gorilla gorilla berengei*) in Bwindi Impenetrable National Park, South Western Uganda. In *Proc. American Association of Zoo Veterinarians and American Association of Wildlife Veterinarians Joint Conference*, Omaha, 438.
25. Kerschagl W. (1938). – Gamsräude und ihre Übertragung auf andere Wiltarten. *Dtsch. Illust. Süddeutsche Jagdzeit.*, **59**, 711-712.
26. Kutzer E. (1970). – *Sarcoptes*-Milben und *Sarcoptes*raude der Haustiere. Merkblätter über angewandte Parasitenkunde und Schädlingskämpfung. *Angew. Parasitol.*, **11**, 1-22.
27. León-Vizcaíno L., Ruíz de Ybáñez M., Cubero M.J., Ortíz J.M., Espinosa J., Pérez L., Simón M.A. & Alonso F. (1999). – Sarcoptic mange from Spanish ibex from Spain. *J. Wildl. Dis.*, **35**, 647-659.
28. León-Vizcaíno L., Cubero M.J., González-Capitel E., Simón M.A., Pérez L., Ruíz de Ybáñez M., Ortíz J.M., González-Candela M. & Alonso F. (2002). – Experimental ivermectin treatment of sarcoptic mange and establishment of a mange-free population of Spanish ibex. *J. Wildl. Dis.*, **37**, 775-785.
29. Lindström E.R., Andrén H., Anglstrom P., Cederlund G., Hörnfeldt B., Jäderberg L., Lemnell P.-A., Martinsson B., Sköld K. & Swensson J.E. (1994). – Disease reveals the predator: sarcoptic mange, red fox predation, and prey populations. *Ecology*, **75**, 1042-1049.
30. Little S.E., Davidson W.R., Rakich P.M., Nixon T.L., Bounous D.I. & Nettles V.F. (1998). – Responses of red foxes to first and second infection with *Sarcoptes scabiei*. *J. Wildl. Dis.*, **34**, 600-611.
31. Little S.E., Davidson W.R., Howerth E.W., Rakich P.M. & Nettles V.F. (1998). – Diseases diagnosed in red foxes from Southeastern United States. *J. Wildl. Dis.*, **34**, 620-624.
32. McCarthy P.H. (1960). – The presence of sarcoptic mange in the wild fox (*Vulpes vulpes*) in central Queensland. *Aust. vet. J.*, **36**, 359-360.
33. McCarthy P.H. (1960). – The transmission of sarcoptic mange from the wild fox (*Vulpes vulpes*) to man and other species in central Queensland. *Aust. vet. J.*, **36**, 479-480.
34. Martin R.W., Handasyde K.A. & Skerratt L. (1998). – Current distribution of sarcoptic mange in wombats. *Aust. vet. J.*, **76**, 411-414.
35. Mörner T. (1981). – The epizootic outbreak of sarcoptic mange in Swedish red foxes. In *Wildlife diseases of the Pacific Basin and other countries* (M.E. Fowler, ed.). Fruitridge, Sacramento, 124-130.
36. Mörner T. (1992). – Sarcoptic mange in Swedish wildlife. In *Health and management of free-ranging mammals, Part One* (M. Artois, ed.). *Rev. sci. tech. Off. int. Epiz.*, **11** (4), 1115-1121.
37. Mörner T. & Christensson D. (1984). – Experimental infection of red foxes (*Vulpes vulpes*) with *Sarcoptes scabiei* var. *vulpes*. *Vet. Parasitol.*, **15**, 159-164.

38. Munday B.L. (1978). – Marsupial disease. In Fauna course B. Postgraduate Committee for Veterinary Science, University of Sydney, Sydney, 335-385.
39. Mwanzia J.M., Kock R., Wambua J.M., Kock N. & Jarret O. (1995). – An outbreak of sarcoptic mange in the free-living cheetah (*Acinonyx jubatus*) in the Mara region of Kenya In Proc. American Association of Zoo Veterinarians and American Association of Wildlife Veterinarians Joint Conference, Omaha, 105-112.
40. Onderscheka K., Kutzer E. & Richter H.E. (1968). – Die Räude der Gemse und ihre Bekämpfung. *Zeitschr. Jagdwissensch.*, **14**, 12-27.
41. Onderscheka K., Steineck T. & Tataruch F. (1989). – Der klinische Verlauf der Gamsräude. Tagungsbericht CIC-Gamswildsymposium, Ljubjana (S. Linn, ed). GWI Duick, München, 331-349.
42. Palomares F. & Ruíz-Martínez I. (1993). – Status und Aussichten für den Schutz der Population der Spanischen Steinbocks (*Capra pyrenaica* Schinz, 1938) im Sierra Mágina Naturpark in Spanien. *Zeitschr. Jagdwissensch.*, **38**, 87-94.
43. Pence D.B., Casto S.D. & Samuel W.M. (1975). – Variation in the chaetotaxy and denticulation of *Sarcoptes scabiei* (Acarina: Sarcoptidae) from wild canids. *Acarologia*, **17**, 160-165.
44. Pence D.B., Custer J.W. & Carley C.J. (1981). – Ectoparasites of wild canids from the Gulf Coastal Prairies of Texas and Louisiana. *J. med. Entomol.*, **18**, 409-412.
45. Pence D.B., Windberg L.A. & Sprowls R. (1983). – The epizootiology and pathology of sarcoptic mange in coyotes, *Canis latrans*, from south Texas. *J. Parasitol.*, **69**, 1110-1115.
46. Pence D.B. & Windberg L.A. (1994). – Impact of a sarcoptic mange epizootic on a coyote population. *J. Wildl. Manag.*, **58**, 624-633.
47. Perry R.A. (1983). – Successful treatment of sarcoptic mange in the common wombat (*Vombatus ursinus*). *Aust. vet. Pract.*, **13**, 169.
48. Rossi L., Meneguz P.G., de Martin P. & Rodolfi M. (1995). – The epizootiology of sarcoptic mange in chamois, *Rupicapra rupicapra*, from the Italian Eastern Alps. *Parassitol. (Roma)*, **37**, 233-240.
49. Ryser-Degiorgis M.-P., Ryser A., Bacciarini L.N., Angst C., Gottstein B., Janovsky M. & Breitenmoser U. (2002). – Notoedric and sarcoptic mange in free-ranging lynx from Switzerland. *J. Wildl. Dis.*, **38** (in press).
50. Sachs R. & Sachs C. (1968). – A survey of parasitic infestation of wild herbivores in the Serengeti region in northern Tanzania and the Lake Rukwa region in southern Tanzania. *Bull. epiz. Dis. Afr.*, **16**, 455-472.
51. Samuel W.M. (1981). – Attempted experimental transfer of sarcoptic mange (*Sarcoptes scabiei*, Acarina: Sarcoptidae) among red fox, coyote, wolf and dog. *J. Wildl. Dis.*, **17**, 343-347.
52. Skerratt L.F. (1998). – Diseases and parasites of the common wombat *Vombatus ursinus* in the Healesville area of Victoria. In Wombats (R.T. Wells & P.A. Pridmore, eds). Surrey Beatty & Sons, Chipping Norton, 317-328.
53. Skerratt L.F., Martin R.W. & Handasyde K.A. (1998). – Sarcoptic mange in wombats. *Aus. vet. J.*, **76**, 408-410.
54. Skerratt L.F. & Beveridge I. (1999). – Human scabies of wombat origin. *Aust. vet. J.*, **77**, 607.
55. Skerratt L.F., Middleton D. & Beveridge I. (1999). – Distribution of life cycle stages of *Sarcoptes scabiei* var. *wombati* and effects of severe mange on common wombats in Victoria. *J. Wildl. Dis.*, **35**, 633-646.
56. Stone W.M., Parks E., Weber B.L. & Parks F.J. (1972). – Experimental transfer of sarcoptic mange from red foxes and wild canids to captive wildlife and domestic animals. *N.Y. Fish Game J.*, **29**, 102-103.
57. Sweatman G.T. (1971). – Mites and pentastomes. In Parasitic diseases of wild mammals, 1st Ed. (J.W. Davis & R.C. Anderson, eds). Iowa State University Press, Ames, 3-64.
58. Todd A.W., Gunson J.R. & Samuel W.M. (1981). – Sarcoptic mange: an important disease of coyotes and wolves of Alberta, Canada. In Proc. Worldwide Furbearer Conference (J.A. Chapman & D. Pursley, eds). R. Donnelly and Sons Publishers, Falls Church, 730-759.
59. Trainer D.O. & Hale J.B. (1969). – Sarcoptic mange in red foxes and coyotes in Wisconsin. *Bull. Wildl. Dis. Assoc.*, **5**, 387-391.
60. Vyrypaev V.A. (1985). – Efecto de la infestación epizootica de *Sarcoptes scabiei* sobre una población de ibex siberiano (*Capra siberica*) en Asia Central (Tien-Shan). *Parazitologiya*, **19**, 190-194.
61. Yager J.A. & Scott D.W. (1985). – The skin and appendages. In Pathology of domestic animals, 4th Ed. (K.V.F. Jubb, P.C. Kennedy & N. Palmer, eds), Vol. 1. Academic Press, St Louis, 408-549.
62. Young E. (1975). – Some important parasitic and other diseases of lion, *Panthera leo*, in the Kruger National Park. *J. S. Afr. vet. Assoc.*, **46**, 181-183.
63. Zahler M., Essig A., Gothe R. & Rinder H. (1999). – Molecular analysis suggests monospecificity of the genus *Sarcoptes* (Acar: Sarcoptidae). *Int. J. Parasitol.*, **29**, 759-766.
64. Zumpt F. & Ledger J.A. (1973). – Present epidemiological problems of sarcoptic mange in wild and domestic animals. *J. S. Afr. Wildl. Manag. Assoc.*, **3**, 119-120.