

# Common Diseases of Urban Wildlife

## BIRDS

### PART 1

#### **The Australian Registry of Wildlife Health**

##### MISSION STATEMENT:

The Australian Registry of Wildlife Health is committed to contributing to the preservation of Australia's biodiversity through increased understanding of the interactions among animals, the environment, and disease causing agents.

## 1 Common Diseases of Birds

### 1.1 Introduction

A wide variety of diseases have been documented within free ranging Australian birds. The following segment focuses on those diseases that occur often within a particular species or taxonomic group of birds.

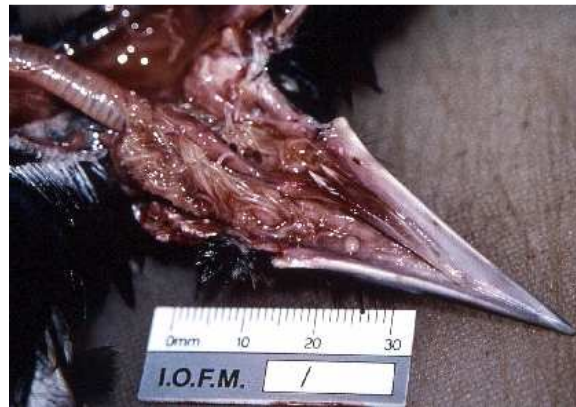### 1.2 Parasitic Disease

For additional information see also: (Bain and Mawson, 1981).

#### 1.2.1 *Cheilospirura gymnorhinis*

*Cheilospirura gymnorhinis* is also referred to as the throat worm of juvenile magpies.

The same parasite, or a similar parasite, occurs in the oral cavity and pharynx of currawongs, butcherbirds, magpie larks, and black-faced cuckoo shrikes. *C. gymnorhinis* burrows its head into the mucosa of the oral cavity and pharynx. The host then responds by creating a fibrous nodule around



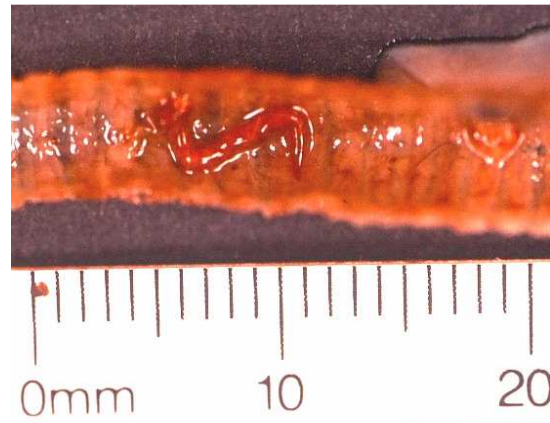*Cheilospirura gymnorhinis*, oropharynx, Magpie

the parasite. Although small numbers of parasites result in self-limiting infections, large numbers can impair prehension of food, or partially obstruct the glottis. Treatment trials using a variety of anti-helminthic agents have not been successful in eliminating the parasites (Larry Vogelnest, personal communication). Repeated manual removal of the parasites with haemostats is recommended and this is assisted by application of moxidectin directly to the nematodes. Euthanasia may be the most humane option for severely debilitated young birds with heavy burdens of *C. gymnorhinis*.

#### 1.2.2 *Syngamus trachea*

*Syngamus trachea* is commonly found in the trachea of a variety of birds.

Occasionally magpies that die suddenly are found to have complete tracheal obstruction with masses of these parasites.



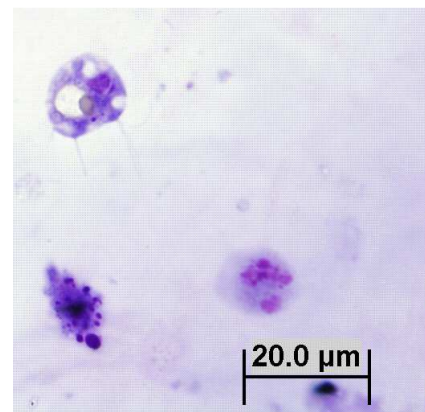
*Syngamus trachea*

### 1.2.3 Trichomoniasis

Oral trichomoniasis has been observed in debilitated free ranging birds, but is most common in captive

wildlife that are undergoing treatment for various injuries. Birds of prey, columbiforms, little penguins, and psittacines are sporadically affected by trichomoniasis. Trichomonads are common commensal agents within the avian alimentary tract. Trichomonads are ovoid protozoa that have four anterior flagella and an undulating membrane. These organisms are spread through either direct or indirect contact. The factors that predispose a bird to develop trichomoniasis are unknown.

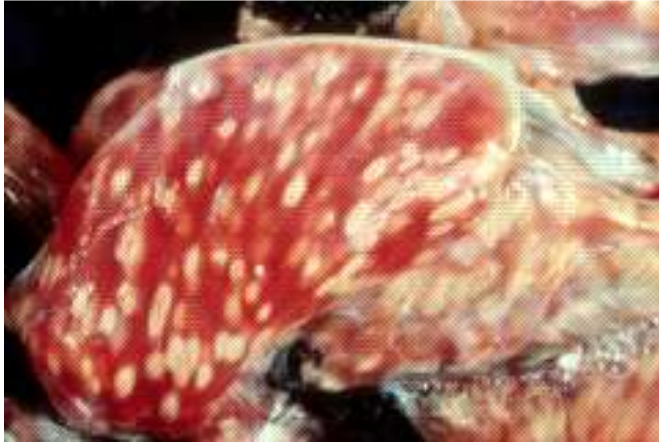Caseous oral plaques are created when the organisms cause tissue necrosis. Lesions are often subject to secondary bacterial infections. A diagnosis of trichomoniasis is best made by examining a wet mount preparation of the caseous debris. Flagellates can be seen moving within the wet preparations under light microscopy. The organisms are much more difficult (often impossible) to see within cytologic and histologic preparations of affected tissues.



*Trichomonas* spp.

Treatment of trichomoniasis includes debridement of the caseous plaques, supportive care and administration of antiprotozoal agents.

#### 1.2.4 *Haemoproteus*



Lesions due to *Haemoproteus* sp, pectoral muscle, Pied Currawong.

Megaloschizonts of *Haemoproteus* cause clinically significant myopathy in pied currawongs within the Sydney region of New South Wales. This organism was initially reported as *Leucocytozoon* sp. *Haemoproteus* spp.

infection occurred in juvenile, sub-adult and adult birds of both sexes, at any time of year, but it has not been seen in recent years. Infection in some birds may have been incidental; however, heavy parasite burdens in some birds resulted in lethargy, weakness and debility. If the breast feathers are parted, pale oval foci were evident throughout the pectoral musculature in affected birds. There is no known treatment for this protozoal infection and birds often die shortly after initial examination. The lifecycle of this protozoal agent is unknown.

Upon post mortem examination of affected birds, discrete, pale oval foci measuring up to 1.5 cm long and 0.5 cm wide are scattered throughout the skeletal muscles, tongue, myocardium and ventricular muscularis externa. Histopathologic examination demonstrates that pale foci consist of central megaloschizonts, surrounded by necrotic muscle and an intense inflammatory response. Haemorrhage, necrosis, and inflammation are most severe around ruptured megaloschizonts. Pigmented oval *Haemoproteus* gamonts may or may not be evident within circulating erythrocytes of affected birds.

#### 1.2.5 *Toxoplasma gondii*

Toxoplasmosis is a potentially fatal disease in native birds (Hartley and Dubey 1990, ARWH). Birds with toxoplasmosis are depressed, fluffed, or are found dead. Gross

post mortem findings consist of pulmonary oedema, pulmonary congestion, and pale foci within the liver, spleen and intestinal mucosa. Histologic examination reveals pulmonary oedema and congestion, fibrin within the distal airways, and non-suppurative inflammation or necrosis within the liver, spleen, brain, skeletal muscle, ventriculus, adrenal gland, and intestine. Numerous protozoa, morphologically consistent with *T. gondii* may be observed in the interstitium of the lung or within foci of necrosis in other tissues. Definitive diagnosis of *T. gondii* protozoal encephalitis has been established in some native birds using immunohistochemistry (Hartley and Dubey, 1991).

Protozoal cysts resembling those of *T. gondii* are observed in the absence of inflammation during routine histologic examination of nervous tissue of a variety of native birds, especially the tawny frogmouth. These cysts are consistent morphologically with *T. gondii* and they appear to be a common incidental finding (ARWH).

#### 1.2.6 Other Parasites

##### **Ectoparasites**

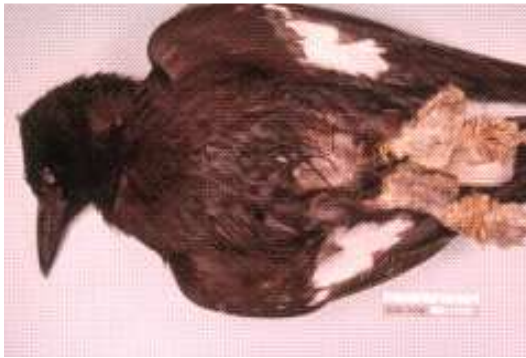Birds can be parasitised by ticks. *Ixodes holocyclus*, the paralysis tick, is found occasionally on birds. Anecdotal reports of tick paralysis in birds have been documented. Three species of the genus *Ornithodoros* are known in Australia, *O. macmillani* on wild birds, *O. capensis* on sea birds and *O. gurneyi* primarily on kangaroos (David Spratt, personal communication).

Lice commonly infest wild birds, but rarely cause disease, such as anaemia. Heavy infestations may be treated with topical antiparasitic powders.

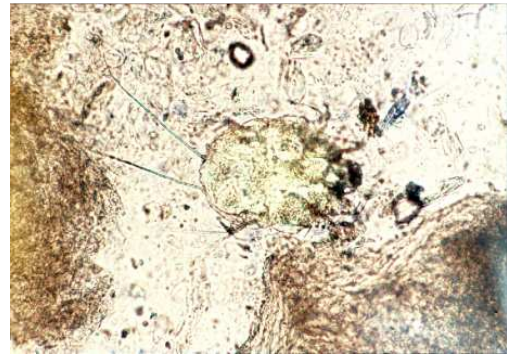*Cnemidocoptes* sp. infestations are capable of causing severe debility in pied currawongs. Infestations are associated with significant epidermal hyperplasia, primarily involving the skin of the toes. Mites can be demonstrated by microscopic examination of scrapings of the thickened skin. Oral or subcutaneous administration



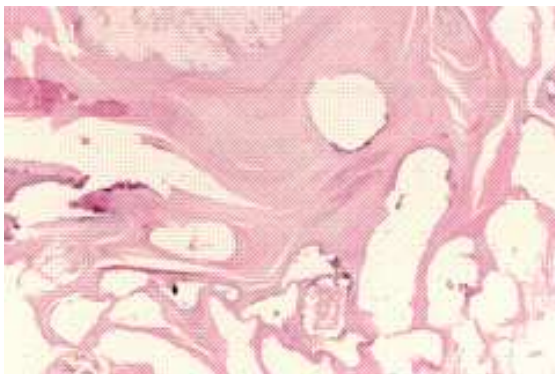
of ivermectin-like drugs will control *Cnemidocoptes* sp. infestation, but more severe infestations are often associated with foot deformation and general debility, which may not be amenable to treatment.



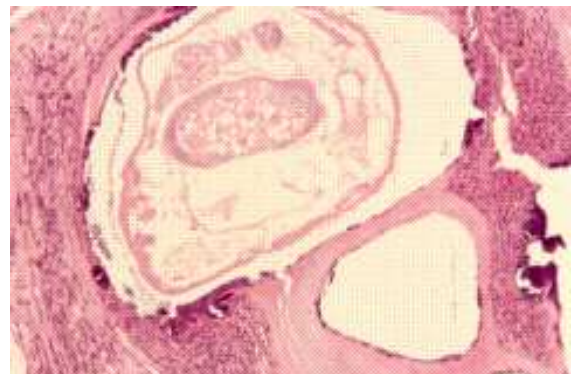
a) Pedal hyperkeratosis from *Cnemidocoptes* sp, pied currawong.



b) *Cnemidocoptes* sp, whole mount.



Hyperkeratosis, *Cnemidocoptes* spp. H & E.



*Cnemidocoptes* spp. Note internal organs surrounded by hyaline exoskeleton. H & E.

Hippobosca are a genus of fly that occurs commonly within the plumage of birds of

prey, especially the tawny frogmouth. Hippoboscids can bite and are capable of acting as a vector in the transmission of disease. These flies will infest and bite humans, but do not seem to remain on human hosts for prolonged periods.



*Sternostoma tracheacolum* is the tracheal and air sac mite of Gouldian finches. Heavy burdens of these mites are capable of causing coughing, sneezing, and open mouth breathing. Disease associated with this parasite is most common in captive finches. Ivermectin-like drugs can be used to treat affected birds.

Hippoboscids fly

### Trematodes

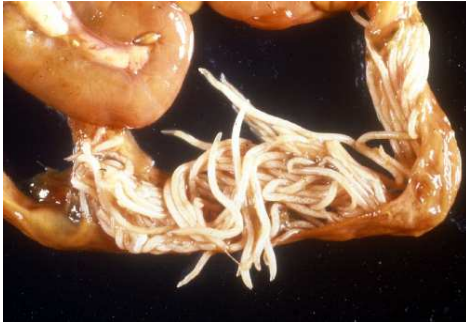*Australobilharzia* spp. are schistosome parasites that live in the blood vessels of water birds. These parasites are most commonly reported in silver gulls. The parasites have an affinity for the blood vessels of the gastrointestinal tract and kidney. The presence of adult trematodes and trematode eggs may result in the formation of multiple granulomas within the intestine and liver. *Australobilharzia* sp. infection, however, is most often an incidental finding in birds. The cercaria of *Australobilharzia* sp. penetrate the skin of humans and are the cause of “swimmer’s itch”.

*Mawsontrema eudyptulae* is a trematode that lives in the bile ducts of little penguins. Infection with this parasite may be incidental, or may be associated with liver enlargement, necrosis, and possibly haemorrhage from the liver (Harrigan 1992, Norman et al., 1992). For the population of little penguins in Bass Strait in southeastern Australia to remain stable, the scale of annual, natural mortality is astonishing and has been estimated at 100,000 birds (Norman et al., 1992). In addition, large numbers of immature birds also perish and many become beach washed (loc. cit.). In these so-called “wrecks”, adult mortality generally occurs in winter due mainly to starvation. Wrecks involving immature birds occur

mainly in late summer and early autumn and are directly or indirectly the result of parasitic infection (Obendorf and McColl, 1980; Harrigan, 1992).

## Nematodes

Gastrointestinal nematodiasis is usually an incidental finding in wild birds. Parasite

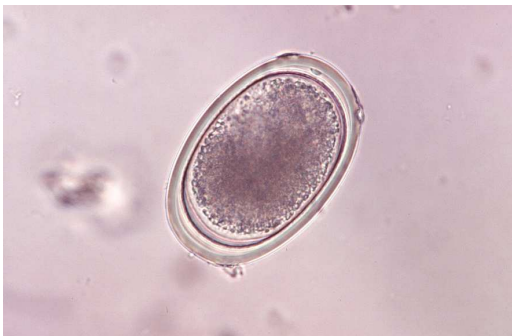

Heavy ascarid burden, captive long-billed corella

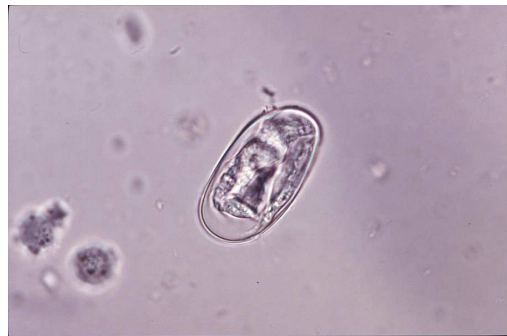burdens in wild birds are usually mild. Captive birds, however, may experience excessive parasite burdens that can contribute to debility.

*Capillaria* spp. are often evident within serpiginous tracts created as the nematode burrows through the mucosa and lamina

propria of the oesophagus, proventriculus and liver. Capillariasis occurs primarily in captive birds. Infected birds may suffer from extensive hyperplasia of the oesophageal mucosa and marked inflammation surrounding the parasites in the mucosa and lamina propria. Emaciation and dehydration can result from these infections. *Capillaria* sp. infections in wild birds are primarily an incidental finding during post mortem examination.

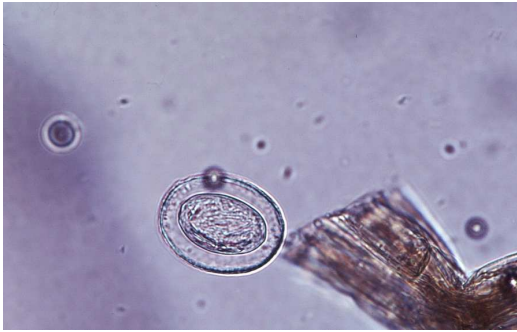

Ascarid ovum

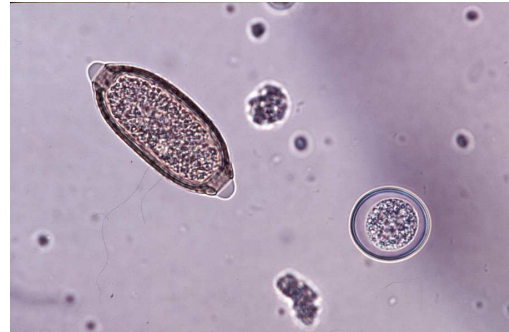

Strongyle ovum





Cestode ovum



Capillaria ovum and Coccidial oocyst

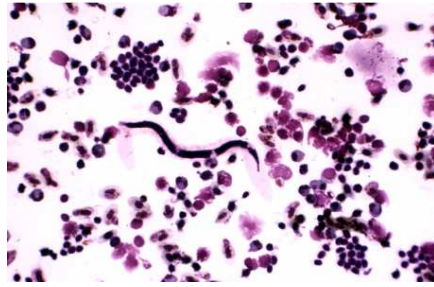
*Contracaecum* spp. are nematodes that parasitise the oesophagus and proventriculus of piscivorous birds. Small numbers of parasites pose no threat to the host. There are reports of large parasite burdens of *C. spiculigerum* being associated with proventricular ulceration, haemorrhage, emaciation and death in little penguins in Victoria (loc. cit.).

*Dispharynx nasuta* is a nematode parasite that burrows into the mucosa of the proventriculus in a variety of birds. Infection with this parasite can result in either granulomatous inflammation or the development of fibrous nodules surrounding the parasites within the wall of the proventriculus. *Echinuria uncinata* is a parasite that is capable of causing similar lesions in waterfowl.

*Serratospiculum anaculata* resides within the airsacs of birds of prey, and infection is most common in falcons. Two species are known in Australia: *S. guttatum* from *Falco longipennis* and *F. peregrinus* and *S. tendo* from *F. peregrinus*. Overseas, *S. anaculata* occurs primarily as an unapparent infection. Clinical respiratory disease has been described in Australian birds infected with *S. anaculata* that are subject to stress or concurrent disease. Diagnosis of *S. anaculata* requires endoscopic examination of the air sacs. Ivermectin-like drugs can be used to treat affected birds.

Microfilariae are occasionally found during examination of peripheral blood smears of

wild birds. Adult filarial nematodes may reside within the air sacs, coelomic cavity, subcutaneous tissues, heart, greater vessels, or lungs. Infection is diagnosed during microscopic examination of peripheral blood smears or buffy coat smears. Microfilariae are transmitted by haematophagous arthropods. Microfilarial infections are incidental to the host.



Microfilaria, peripheral blood smear, barking owl.

*Oxyspirirura* spp. are nematode parasites that can be found within the conjunctiva and nictitating membrane of a number of species. Infection with this parasite is usually asymptomatic, but may be associated with conjunctivitis in a small proportion of birds (Pass, 1993).

*Angiostrongylus cantonensis*, the rat lungworm has been found to neurological dysfunction associated with eosinophilic or non-suppurative encephalomyelitis in yellow-tailed black cockatoos, and more commonly in tawny frogmouths. Infection in tawny frogmouths is now a very common occurrence and seems to have a seasonal prevalence (Monks et al., in press, Montali et al., 2004, Prociv, 1999). Birds become infected with the parasite by eating snails and slugs, the intermediate host. Diagnosis of the infection can be very difficult, since birds do not usually develop eosinophilia. Cerebrospinal fluid taps collected from infected animals are also often non-suppurative rather than eosinophilic, making it difficult to differentiate angiostrongylosis from viral or protozoal infection. Treatment of the infection in birds is also difficult. The parasite's cuticle retains many antigens and killing the worms can result in release of antigens with subsequent severe host immune response.

### Cestodes


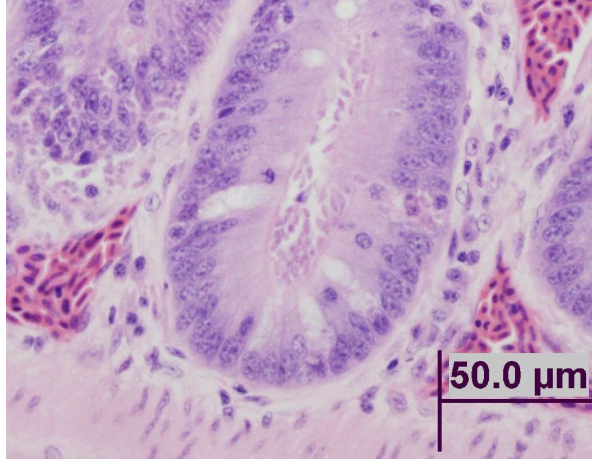
Birds are parasitised by many species of cestode. None of these is considered to be highly pathogenic in free-living birds. It is possible, however, that large burdens of cestodes will add to the debility of a captive or compromised bird. If

necessary, cestodiasis is treated with praziquantel. The treatment is usually repeated 10 days after the first dosage.

**Protozoa**

A wide variety of protozoa have been reported within the gastrointestinal tract, cardiovascular system, musculature and renal tissues of free-flying birds. The following discussions regarding protozoa are limited to those protozoal infections known to be clinically significant.

*Spironucleus* (formerly Hexamita) -like organisms have been associated with numerous outbreaks and individual cases of emaciation, diarrhoea and fatal enteritis in Australian king parrots (Philbey et al., 2002, Vogelnest, 1994). Similar parasites have been identified in an emaciated, wild sulphur crested cockatoo from western NSW (ARWH). These birds become emaciated and have very thin walled intestinal tracts, often filled with fetid brown fluid. The intestinal tissues of affected birds seem to decompose very rapidly making it very difficult to identify organisms within tissues on histologic examination. Saline wet-mount preparations can be used to demonstrate the organism within the gastrointestinal tract during gross post mortem examination.

	
Protozoal enteritis, king parrot	Protozoa (arrows) in the intestinal crypts and along the mucosal basement membrane of a sulfur crested cockatoo

Gastrointestinal *Giardia* spp. infections have been documented in a variety of wild and aviary birds in Australia. *Giardia* spp. have been recovered from the intestinal

lumen of straw-necked ibis in Western Australia, and a sulphur-crested cockatoo in Victoria (Foreshaw et al., 1992, Gallagher et al., 1995). Giardiasis in captive young budgerigars can result in decreased growth rates, dehydration, and diarrhoea (Filippich, 1998). Diagnosis of giardiasis is based upon direct microscopic examination of faeces or intestinal content. *Giardia* sp. trophozoites are pear shaped, binucleate, and have eight flagella. A cyst form, with four nuclei is occasionally shed in the faeces. Treatment of budgerigars with metronidazole decreased shedding of these protozoa in the faeces (Filippich, 1998). Treatment for giardiasis is the same as for trichomoniasis. Careful attention to hygiene will prevent clinical infection in most captive birds.

*Cryptosporidia* spp. have been observed within the intestinal brush border of wild Pacific black ducks, a red-tailed black cockatoo, an Australian magpie, and a rock parrot (ARWH). The significance of this parasite as an avian pathogen is poorly understood.

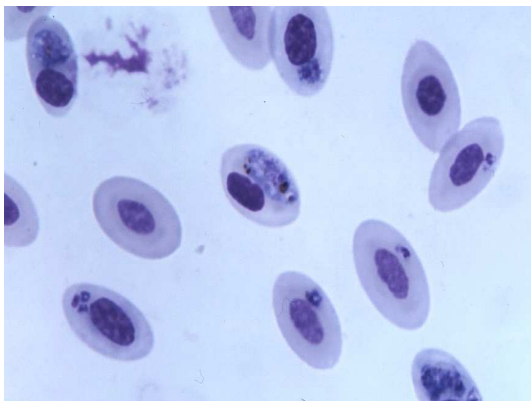
Eimerian and isosporan coccidial oocysts are commonly identified within the faeces of healthy captive and free-flying birds. Coccidiosis may cause necrotising enteritis in young captive birds of a variety of species. Disease associated with coccidial infection in free ranging birds is rare. When large numbers of faecal oocysts accompany diarrhoea, treatment of coccidiosis is advisable.

Renal coccidiosis is a common incidental finding within little penguins, Australian gannets, and short-tailed shearwater (also known as the Tasmanian mutton bird). Limey disease is the term used to describe clinically apparent renal coccidiosis in nestling short-tailed shearwater. Chicks with limey disease are thin and have urate and faecal soiling of the pericloacal feathers (Munday et al., 1971). Renal enlargement and multiple pale foci throughout the kidney are evident on gross post mortem examination. The ureter and cloaca may also be distended with urates. Microscopic examination of the affected renal tissue reveals inflammation within the interstitium surrounding the large collecting ducts. Coccidial oocysts are often

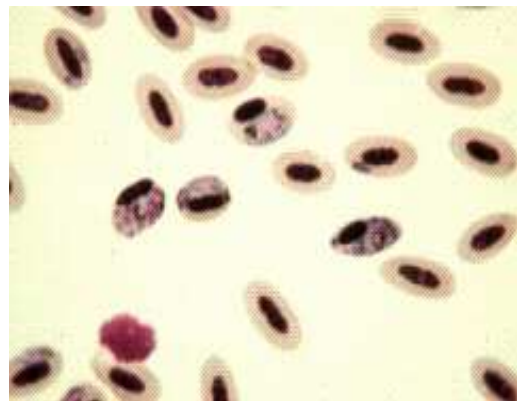
evident within multiloculated granulomas within the collecting duct mucosa and in the surrounding interstitium.

*Caryospora* spp are coccidian parasites that can be found within the intestinal lamina propria and mucosa of carnivorous birds of prey, but these are generally incidental findings. *Caryospora* spp. can be found infecting reptiles, birds and rodents and can have a single host, or two host (predator-prey) lifecycle. The intestinal forms of *Caryospora* spp. are characterised by a single sporocyst containing eight elliptical sporozoites.

*Haemoproteus*, *Leucocytozoon*, *Plasmodium*, *Atoxoplasma*, and a *Babesia*-like organism are genera of the family Plasmodiidae that are commonly found within the peripheral blood of wild Australian birds. Each of these organisms is arthropod borne. A bird may be infected with two or more of these organisms concurrently without any clinical signs. Young or debilitated birds may develop anaemia, anorexia, and depression as a result of large parasite burdens.



Avian malaria, Albatross (Blood smear)



Avian malaria, Blue Faced Parrot Finch (Blood smear)

Trypanosomes are occasionally found within the peripheral blood of native birds. These parasites are extracellular flagellates that are transmitted by biting midges. Trypanosomes are reported most commonly in little penguins, and they do not appear to be pathogenic.

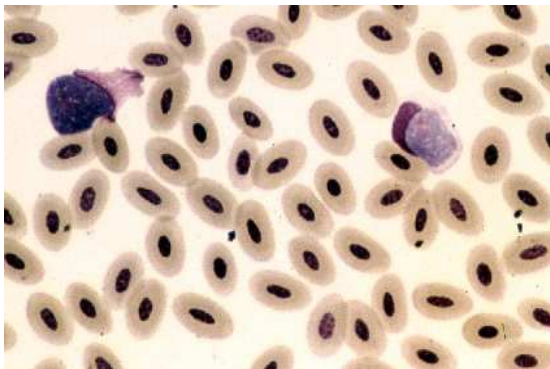
Systemic coccidiosis associated with *Lankestrella* spp. and *Isospora serin* have been



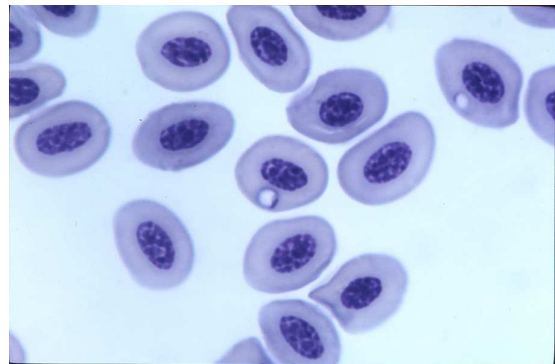
identified within circulating monocytes of the brown treecreeper, house sparrows, and aviary birds within NSW. O'Donoghue and Adlard (2000) in the "Catalogue of Protozoan Parasites Recorded in Australia" employ the generic name *Lankesterella* rather than *Atoxoplasma*. Of Australian *Lankesterella* spp, one species occurs in tree-creepers and one in white eyes and sparrows (David Spratt, personal communication).

These systemic coccidian parasites undergo sexual reproduction (gametogony) within the mucosa of the gastrointestinal tract, and asexual reproduction (schizogony) within extra-intestinal tissues such as the liver and spleen. Sporozoites of this organism are evidently transported among these sites within mononuclear cells. Sporozoites are round basophilic organisms that have a small basophilic nucleus. These sporozoites are visible, usually as individual organisms, within the cytoplasm of mononuclear cells, which have an indented nucleus.

A *Babesia*-like piroplasm is occasionally evident within the erythrocytes of little penguins. The organism is most likely transmitted by ticks, and infection has been associated with regenerative anaemia (ARWH).



Leukocytozoon, pied currawong..



Ring form, Babesia spp, little penguin.

### 1.3 Bacterial Disease

Sporadic outbreaks of mortality in native birds have been attributed to infection with *E. coli*, *Salmonella* spp., *Pasteurella* spp., *Mycobacterium* spp., *Erysipelothrix rhusiopathiae*, *Listeria monocytogenes*, *Streptococcus* spp., *Staphylococcus aureus*, *Haemophilus* spp., *Mycoplasma* spp., and *Clostridium* spp (ARWH). Ideally

treatment of bacterial infection is based upon isolation of the organism within lesions, and antimicrobial sensitivity testing.

### 1.3.1 Yersiniosis

*Yersinia pseudotuberculosis* infections can result in either acute enteritis and septicaemia, or multisystemic abscesses.

### 1.3.2 Necrotic Enteritis

#### **Aetiology**

Wild rainbow lorikeets, scaly-breasted lorikeets, and king parrots in coastal eastern Australia are seasonally affected with necrotising enteritis. A variety of organisms, primarily coliforms, have been isolated within the necrotic intestinal tissue. *Clostridium perfringens* and *E. coli*, however, are most commonly isolated within the intestine and other tissues of birds with necrotic enteritis.

Carbohydrate overload has been suggested as a means of causing intestinal overgrowth with *Clostridium perfringens*, and subsequent necrotic enteritis (Pass, 1993, McOrist and Reece, 1992). Numerous artificial feeding stations are established for lorikeets in urban areas. Unfortunately, many of these stations provide only sugar water. The presence of an underlying viral infection in birds suffering from necrotic enteritis, however, has not been thoroughly investigated.

Necrotic enteritis occurs in male and female birds, juvenile animals and adults. Free-ranging birds are most commonly diagnosed with necrotic enteritis; however, the disease has been observed in captive lorikeets. Necrotic enteritis is most often observed in July and August (ARWH).

An investigation into the occurrence of necrotic enteritis identified 58 dead rainbow lorikeets, red-collared lorikeets, and scaly-breasted lorikeets originating from 18 different flocks in eastern Australia over a ten year period (McOrist and Reece, 1992). *Cl. perfringens* was isolated from the intestinal tissues of many birds, and beta toxin was demonstrated within the bacterial colonies and within intestinal content using gas

liquid chromatography (McOrist and Reece, 1992).

In 1998, eight birds were presented to the ARWH with necrotic enteritis. *E. coli* was isolated in pure culture from the necrotic segments of intestine, and in the lung and liver of seven of these birds. These tissues were also submitted for anaerobic culture; however, *Cl. perfringens* was not identified. Thus, necrotic enteritis may be caused by a variety of bacteria and its pathogenesis may be multifactorial.

### **Clinical Signs**

Birds with necrotic enteritis exhibit a variety of clinical signs. Most of these birds are in good body condition, but are weak, depressed, dehydrated, regurgitate clear fluid, and have soiled vent feathers as a result of watery diarrhoea. The bird's abdomen may be palpably distended. Alternatively, birds with necrotic enteritis are found dead or moribund. The species affected by necrotic enteritis normally have wet faeces, and the detection of diarrhoea may be difficult.

### **Pathology**

During the gross post mortem examination of these birds, the intestinal tract is distended by gas or reddish-brown fluid. A diphtheritic membrane coats the mucosa, or the mucosa is found to be friable and haemorrhagic. Microscopic examination of affected segments of intestine reveals the following lesions: mucosal to transmural necrosis, intense mononuclear cell infiltration, oedema and congestion throughout the lamina propria and submucosa, and colonies of bacteria scattered throughout a superficial layer of necrotic debris and fibrinous exudate.

### **Diagnosis**

Necrotic enteritis is identified based upon the clinical signs and microbial culture of faeces. Many birds with necrotic enteritis are found dead. Post mortem examination and microbial culture of segments of intestine are used to establish a diagnosis.

### **Treatment**

Although sensitivity testing of the *E. coli* isolated within the intestine of birds with necrotic enteritis indicates that the organism is sensitive to a variety of commonly used antibiotics, treatment of these birds is rarely successful. Presumably, the birds are suffering from either enterotoxaemia, or bacteraemia by the time they demonstrate clinical signs.

### 1.3.3 Chlamydiosis

#### **Aetiology**

*Chlamydophila psittaci* is a bacterium of the family Chlamydiaceae. These bacteria are obligate intracellular parasites that are capable of causing severe disease in free-living birds, aviary birds and humans.

Outside of the body *C. psittaci* take the form of elementary bodies, which have a rigid cell wall. Elementary bodies are weakly gram-negative, non-motile bacteria, which are phagocytosed by host cells. Once enveloped within a phagosome, elementary bodies expand to become reticulate bodies, which have a more flexible cell wall and are capable of growth and multiplication. After a period of division, these revert to elementary bodies, which are released with the death of the host cell.

*C. psittaci* is endemic throughout Australia. It is a notifiable disease. Psittacine and columbiform birds are most susceptible to *C. psittaci* infection. Chlamydiosis is a common disease of lorikeets, cockatoos, budgerigars, rosellas, and aviary psittacines. *C. psittaci* is transmitted either through the faecal-oral route or through respiratory secretions. Elementary bodies may remain infective within dried faeces for several months. Chlamydiosis should be considered among the differential diagnoses in any emaciated wild bird, and barrier methods should be employed to prevent potential spread of infection to other wildlife or humans.

#### **Clinical Signs**

Birds with active chlamydiosis may exhibit a broad range of symptoms associated with either acute or chronic disease. Many birds will function as asymptomatic

carriers of the organism, while others may suffer severe or fatal infection. Chlamydiosis is most often manifested as respiratory or gastrointestinal illness. Clinical signs associated with *C. psittaci* infection include: weight loss, depression, lethargy, anorexia, diarrhoea, bile stained faeces, ocular or nasal discharge, and dyspnoea.

### **Pathology**

Post mortem findings can be highly variable in birds suffering from chlamydiosis. Some birds may die acutely with very few morphologic lesions, while some will merely have splenomegaly and hepatomegaly, and others may have fibrinous air sacculitis, pericarditis and enteritis.

### **Diagnosis**

Definitive diagnosis of chlamydiosis relies upon isolation of the organism within cell culture or embryonated chicken eggs. Marked leucocytosis, monocytosis, and an elevated AST may be suggestive of *C. psittaci* infection, however, there is significant species and individual variability in the haemogram of birds with chlamydiosis. Antigen can be detected within conjunctival, nasal, or faecal swabs using antigen capture ELISA tests or direct immunofluorescence testing. Diagnostic tests based upon antigen capture are highly sensitive, but may not be highly specific. Some gram negative bacteria will cross react with the antibody used in the ELISA test, thus, conjunctival and choanal swabs will provide far fewer false positive reactions compared with faecal swabs. ELISA based antigen capture test kits are commercially available for in-house identification of *Chlamydia* sp. antigen (Clearview® test kits). These kits are marketed for the detection of human *C. trachomatis* within urine samples, but they are effective in the identification of *C. psittaci*.

Post mortem diagnosis of chlamydiosis is usually based on finding multisystemic histiocytic inflammation on histologic examination and identification of the organism within lesions. Impression smears of spleen, lung, and liver can be stained using modified Machiavello's staining protocols. This protocol can also be used to identify the organism within paraffin embedded tissue. Fresh tissues, such as



liver, spleen and lung may be submitted to a microbiology laboratory for culture, or swabs from fresh tissues can be tested with antigen capture ELISA tests or PCR. Immunohistochemical demonstration of the organism is possible in fixed tissues.

## **1.4 Viral Disease**

### **1.4.1 Psittacine Beak & Feather Disease (PBFD)**

#### **Aetiology**

Psittacine beak and feather disease is a common disease in wild and aviary psittacines throughout Australia. The disease is caused by psittacine circovirus, and is manifested by lesions in the feathers, beak and occasionally the claws.

Psittacine circovirus is an icosahedral, non-enveloped virus, which has a single, round strand of DNA. Presence of the virus can be demonstrated with feather epithelium, follicular epithelium, macrophages within the feather pulp and dermis, macrophages in the bursa of Fabricius, Kupffer cells in the liver, and within faeces. Psittacine circovirus has an affinity for epithelial cells and lymphoid cells.



Galah with severe PBFD infection.

#### **Clinical Signs**

Clinical signs of infection with psittacine circovirus are highly variable depending on the age and species of the bird, and the quantity of virus in the infective exposure. The progression of disease is also highly variable, ranging from acute to chronic. Young birds most often exhibit the acute form of infection. Clinical signs of acute psittacine circovirus infection include diarrhoea, weight loss, anorexia, depression and either death or residual feather damage. The chronic form of psittacine circovirus infection in

cockatoos begins with loss of the powder keratin in the plumage, and the production of dystrophic down feathers over the hips. Powder down feathers become short and lose the plumaceous barbs. The loss of powder down feathers results in a dull and

dirty look of contour and flight feathers, and imparts a glossy black appearance to the beak.

When damaged by psittacine circovirus, the beak may become elongated, softened, broken, cracked, or it may have uneven wear. These changes are most commonly seen in cockatoos in the late stages of infection. If the germinal epithelium of the beak is exposed by fractures or cracks in the keratin the bird will often stop eating due to pain.

Young lorikeets of the genus *Trichoglossus* that are infected with psittacine circovirus will often present with the last two to four primary feathers of the wings missing. If pulled from their follicles, the calamus of the remaining tail feathers and flight feathers will often exhibit characteristic morphologic lesions. These lorikeets are called “runners” since they are unable to fly, yet healthy enough to forage and run on the ground. Young lorikeets are identified by their dark brown beaks. Occasionally, these young lorikeets will have a blotchy yellow pattern on the tail feathers that are usually green.



Rainbow lorikeet “runner”. Loss of primary feathers from psittacine circovirus infection..

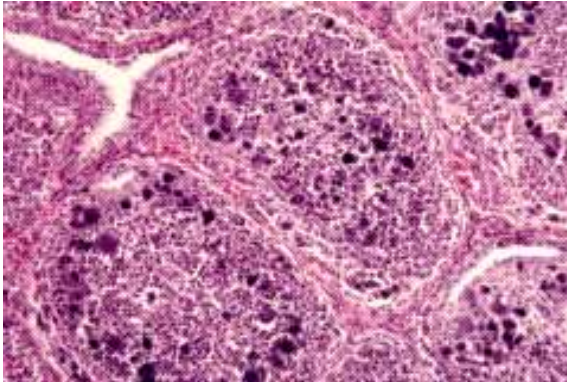
Beak lesions rarely occur in lorikeets infected with psittacine circovirus.

Feathers damaged by psittacine circovirus are curled, clubbed, easily broken, or they have retained feather sheaths, haemorrhages within the calamus (shaft), or annular constrictions of the calamus. Replacement feathers grow slowly, or fail to regrow.

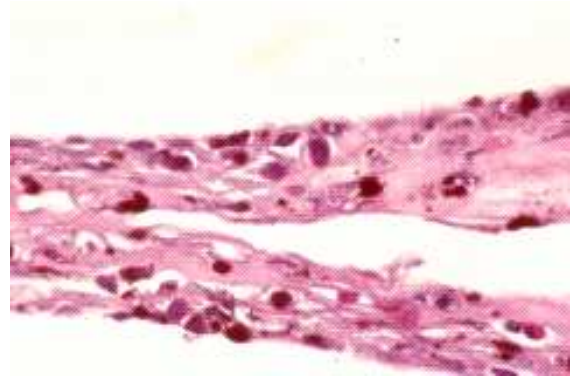
### Pathology

Histologic lesions associated with psittacine circovirus infection occur primarily in the growing feather, but may also be evident within the follicle. Necrosis occurs in the germinal layer of the follicular and feather epithelium, and basophilic

cytoplasmic inclusion bodies may be evident within the epithelium, and in reticuloendothelial cells in the dermis, feather pulp, and bursa of Fabricius.



Psittacine circovirus, large intracytoplasmic inclusions



Psittacine circovirus, large intracytoplasmic inclusions

Psittacine circovirus infects the thymus and bursa of Fabricius and is associated with lymphoid necrosis and premature atrophy of these tissues. Birds with psittacine beak and feather disease often succumb to secondary viral, bacterial or fungal infections.

### Diagnosis

The presumptive diagnosis of psittacine beak and feather disease is based upon gross and microscopic lesions in the feather and feather follicle.



Crest feathers, Major Mitchell cockatoo, PBFD. Note pinching of shaft, retained sheaths.

Psittacine circovirus is very difficult to isolate in culture. Definitive diagnosis of

infection with this virus can be established through serological testing, which is available through commercial laboratories. Haemagglutination inhibition (HI) testing detects antibodies to psittacine circovirus in blood, serum and yolk, while haemagglutination (HA) testing detects the virus in faecal samples or feathers. Birds that suffer from severe psittacine beak and feather disease may not mount an effective immune response to the virus and their titres measured via HI tests may not be elevated.

Elevated HI titres merely indicate that antibodies have been formed in response to exposure to psittacine circovirus. Birds with either the acute or chronic form of circovirus infection often have low titres. Budgerigars, lorikeets, and king parrots, however, usually have high psittacine circovirus titres and continue to shed the virus.

Immunohistochemistry, PCR, and DNA *in-situ* hybridisation tests for psittacine circovirus are available overseas.

### **Treatment**

Some species of psittacine can spontaneously recover from the acute form of beak and feather disease. Rainbow lorikeets, budgerigars, eclectus parrots and king parrots may recover from this infection with only mild residual feather changes. Birds with the chronic form of psittacine circovirus infection rarely recover. The cause of death most often relates to secondary infection with other viral, bacterial or fungal agents as a result of immunosuppression.

There is no known cure for psittacine beak and feather disease. Nursing care to keep the bird warm and eating will prolong the life of cockatoos. Lorikeets may spontaneously recover from psittacine beak and feather disease, but can shed the virus for a prolonged period.

### **Prevention**

Since there is no effective treatment for birds suffering from psittacine beak and feather disease, controlling the spread of the virus relies on strict hygiene

and euthanasia of affected birds. Birds that have clinically apparent psittacine beak and feather disease can shed psittacine circovirus for extended periods, functioning as a source of infection for other birds. If euthanasia is not an option, these birds should be maintained under strict quarantine. Viracidal disinfectants used to kill parvovirus should inactivate psittacine circovirus. A killed vaccine for the prevention of psittacine beak and feather disease is currently under investigation.

#### 1.4.2 Poxvirus

##### **Aetiology**

Australian magpies, native pigeons and raptors are occasionally clinically affected by poxvirus infection.

Poxvirus is a member of the genus Avipox, which has a worldwide distribution. Poxvirus is shed in saliva, nasal secretions, faeces and wound exudates or scabs. The virus is transmitted primarily by haematophagous arthropods, such as mosquitos; however, other vectors and fighting can also result in transmission. Infection results in viraemia and then localisation within the skin or mucosa.

##### **Clinical signs**

Clinical signs of poxvirus infection vary from blistering and small nodules in the skin to large dermal nodules with markedly hyperplastic epithelium, which may have foci of ulceration. These lesions primarily occur on the skin of the feet, legs and head, and around the eyes, mouth and cloaca. Secondary bacterial infection is a common finding in poxvirus lesions. Some birds will recover spontaneously, while others will become debilitated due to difficulty walking or obtaining food.

##### **Pathology**

The microscopic lesions associated with poxvirus infection include marked epidermal thickening. Hyperplastic epithelial cells may contain cytoplasmic vacuoles that house large, eosinophilic inclusion bodies. These inclusion bodies are called Bollinger bodies.



## **Diagnosis**

A diagnosis of poxvirus infection is based on finding the characteristic intracytoplasmic eosinophilic inclusion bodies within epithelial cells upon microscopic examination of formalin fixed tissue sections. Some diagnosticians can use Diff Quik® stained scrapings of the proliferative lesions to identify intracellular inclusions, but this is very difficult. Alternatively, biopsies of the proliferative wounds can be submitted for electron microscopy to look for viral particles.

## **Treatment**

Many birds will respond to cage rest and nursing care. Surgical debulking of large lesions may provide relief for some birds. Nutritional support and prevention of secondary infections will aid in the recovery of many birds suffering from poxvirus infection.

### **1.4.3 Adenovirus**

Adenovirus associated hepatic necrosis is a fairly common finding in tawny frogmouths along coastal eastern Australia. Tawny frogmouths with adenovirus hepatitis may have evidence of traumatic injury, or may be depressed and weak. Diagnosis of adenovirus infection is based on post mortem examination. The liver is mottled, friable, enlarged and has rounded margins upon gross post mortem examination. Foci of acute hepatocellular necrosis are scattered throughout the parenchyma of the liver on histological examination. Individual hepatocytes at the margins of the necrotic foci will have peripheralisation of nuclear chromatin and contain intranuclear eosinophilic to basophilic inclusion bodies (Reece et al., 1985). Inclusion body hepatitis associated with adenovirus infection has also been described in a cockatiel (Scott et al., 1986).

### **1.4.4 Other Viruses**

An enterovirus-like agent has been identified within the faeces and enterocytes of galahs and sulphur-crested cockatoos that were depressed, anorexic, and had profuse, green, mucoid diarrhoea. Over a period of approximately three weeks affected birds

became dehydrated, emaciated and died. Dilation of the intestinal tract with mucoid fluid, gas, and a thickened mucosa were evident during gross post mortem examination. Histological examination of affected segments of intestine demonstrated atrophy of villi, and hyperplasia of the crypts of Lieberkuhn. Concurrent psittacine circovirus infection was evident within some of the ill birds (Wylie and Pass, 1989).

## 2 Animals mentioned in text

### 2.1 Aves

Little penguin (*Eudyptula minor*)

Short-tailed shearwater (*Puffinus tenuirostris*)

Australian gannet (*Morus serrator*)

Straw-necked ibis (*Threskiornis spinicollis*)

Pacific black duck (*Anas superciliosa*)

Silver gull (*Larus novaehollandiae*)

Sulphur-crested cockatoo (*Cacatus galerita*)

Galah (*Cacatua roseicapilla*)

Red-tailed black cockatoo (*Calyptorhynchus magnificus*)

Yellow-tailed black cockatoo (*Calyptorhynchus funereus*)

Rainbow lorikeet (*Trichoglossus haematodus*)

Scaly-breasted lorikeet (*Trichoglossus chlorolepidotus*)

Red-collared lorikeet (*Trichoglossus haematodus rubritorquis*)

Australian king parrot (*Alisterus scapularis*)

Cockatiel (*Nymphicus hollandicus*)

Budgerigar (*Melopsittacus undulatus*)

Laughing kookaburra (*Dacelo novaeguineae*)

Tawny frogmouth (*Podargus strigoides*)

Black-faced cuckoo-shrike (*Coracina novaehollandiae*)

Brown treecreeper (*Climacteris picumnus*)

Red wattlebird (*Anthochaera carunculata*)

Gouldian finch (*Erythrura gouldiae*)

House sparrow (*Passer domesticus*)  
Magpie-lark (*Grallina cyanoleuca*)  
Pied butcherbird (*Cracticus nigrogularis*)  
Pied currawong (*Strepera graculina*)  
Australian magpie (*Gymnorhina tibicen*)  
Long-billed corella (*Cacatua tenuirostris*)  
Peregrine falcon (*Falco peregrinus*)  
Australian hobby (*Falco longipennis*)  
Barking owl (*Ninox connivens*)  
Rock parrot (*Neophema petrophila*)  
Shy albatross (*Diomedea cauta*)  
Blue-faced parrot finch (*Erythrura trichroa*)  
White-eyes (*Zosteropidae*)  
Eclectus parrot (*Eclectus roratus*)

### 3 References

- Bain O and Mawson PM (1981) On some oviparous nematodes mainly from Australian birds. Rec. S. Aust. Mus. 18: 265-284.
- Blus LJ, Wiemyer SN, Henny CJ (1996) Organochlorine pesticides. . In: Fairbrother A, Locke LN, Hogg GL (eds). Non-infectious diseases of wildlife. Iowa State University Press, Ames, Iowa. Pp. 61 - 70.
- Charles JA (1995) Organochlorine toxicity in tawny frogmouths. In: Proceedings of the Australian Committee of the Association of Avian Veterinarians, Dubbo. Pp. 135 - 141.
- Cooke-Yarborough CM, Kornberg AJ, Hogg GG, Spratt DM, Forsyth JRL (1999) A fatal case of angiostrongyliasis in an 11-month-old infant. Medical Journal of Australia 170: 541-543.
- Fairbrother A (1996) Cholinesterase inhibiting pesticides. In: Fairbrother A, Locke LN, Hogg GL (eds). Non-infectious diseases of wildlife. Iowa State University Press,

Ames, Iowa. Pp. 52 - 60.

Filippich LJ, McDonnell PA, Munoz E, Upcroft JA (1998) *Giardia* infection in budgerigars. Aust. Vet. J. 76(4): 246 - 251.

Fleay P (1981) Looking at animals. Boolarong Publications, Brisbane, Queensland. Pp 38 - 41.

Foreshaw D, Palmer DG, Halse SA, et al. (1992) *Giardia* in a straw-necked ibis (*Theskiornis spiricollis*) in Western Australia. Vet. Rec. 131: 267 - 268.

Gallagher AN, Gartrell BD, Upcroft JA (1995) Pathogenic *Giardia* isolated from a wild trapped sulphur-crested cockatoo (*Cacatua galerita*). In: Proceedings of the Australian Committee of the Association of Avian Veterinarians, Dubbo. Pp. 23 - 27.

Harrigan KE (1992) Cause of mortality of little penguins *Eudyptula minor* in Victoria. Emu 91, 273 – 277.

Hartley W (1999) Personal communication.

Hartley WJ, Dubey JP (1990) Fatal toxoplasmosis in some native Australian birds. J. Vet. Diag. Invest. 3: 167 - 169.

Hartley WJ, Reece RL (1997) Nervous diseases of Australian native and aviary birds. Aust. Vet. Prac. 27(2): 91 - 96.

Locke LN, Thomas NJ (1996) Lead poisoning of waterfowl and raptors. In: Fairbrother A, Locke LN, Hoff GL (eds) Non-infectious diseases of wildlife. Iowa State University Press, Ames, Iowa. Pp. 52 - 60.

McOrist S, Penny RA (1986) Encephalomyelitis in free-living Rainbow lorikeets (*Trichoglossus haematodus*). Avian Pathology. 15: 783 - 789.

McOrist S, Reece RL (1992) Clostridial enteritis in free living lorikeets

(*Trichoglossus* spp.). Avian Pathology 21: 503 - 507.

Monks DJ, Carlisle MS, Carrigan M, Rose K, Spratt D, Gallagher A, Prociv P (in press) *Angiostrongylus cantonensis* infection in birds: cerebrospinal disease in a yellow-tailed black cockatoo (*Calyptorhynchus funereus*) and two tawny frogmouths (*Podargus strigoides*). In press: J Avian Medicine and Surgery.

Montali R, Spratt D, Rose K (2004) *Angiostrongylus cantonensis* in tawny frogmouths in Sydney. Presented at the Wildlife Disease Association, Australasia, Conference 2004 – Kinchega.

Munday BL, Mason RW, Wells RJH et al. (1971) Further studies on “Limey-disease” of Tasmanian mutton birds (*Puffinus tenuirostris*). J. Wildlife Disease. 7: 126.

Norman FI, DU Guesclin PB, Dann P (1992) The 1986 “Wreck” of little penguins *Eudyptula minor* in western Victoria. Emu 91, 369 – 376.

Obendorf DL and McColl K (1980) Mortality in little penguins (*Eudyptula minor*) along the coast of Victoria, Australia. J. Wildlife Disease. 16: 2, 251 – 259.

O’Donoghue PJ and Adlard RD (2000) Catalogue of protozoan parasites recorded in Australia. In: Memoirs of the Queensland Museum. Queensland Museum, South Brisbane, Australia: 2000. 45: 1, 1 – 163. 1285 ref.

Pass DA (1993) Diseases of free-ranging birds in Australia. In: Fowler ME (ed). Zoo and wild animal medicine. Current therapy 3. W.B. Saunders Company, Philadelphia. Pp. 172 - 177.

Paton DC, Dorward DF, Fell P (1983) Thiamine deficiency and winter mortality in red wattlebirds, *Anthochaera carunculata* (Aves: Melphagidae) in suburban Melbourne. Aust. J. Zool. 31: 147.



Philbey AW, Andrew AL, Gestier AW, Reece RL, Arzey KE (2002) Spironucleosis in Australian king parrots (*Alisterus scapularis*). Aust. Vet. J. 80: 3, 154 – 160.

Prociv P (1999) Parasitic meningitis (editorial) Medical Journal of Australia. 170: 517-518.

Reece RL, Pass DA, Butler R (1985) Inclusion body hepatitis in a tawny frogmouth (*Podargus strigoides*: Carimulgifformes). Aust. Vet. J. 62: 426.

Reiss AE, Badcock NR (1998) Itraconazole levels in serum, skin and feathers of gouldian finches (*Chloebia gouldiae*) following in seed medication. Proceedings of the American Association of Zoological Medicine, Omaha.

Scott PC, Condrón RJ, Reece RL (1981) Inclusion body hepatitis associated with adeno-like particles in a cockatiel (*Psittaciformes*; *Nymphicus hollandicus*). Aust. Vet. J. 63(10): 337.

Slatter P, Slater P, Slatter R (1994) The Slater field guide to Australian birds. Landsdowne Printing Pty. Ltd., Sydney.

Vogelnest L (1999) Personal communication.

Vogelnest L (1994) Veterinary care of wild Australian Native birds - medicine. Proc 233. The Post Graduate Committee in Veterinary Science. Pp. 141 - 190.

Wylie SL, Pass DA (1989) An entero-like virus infection of cockatoos. Aust. Vet. J. 66: 321.