

Kernohan's Notch

J.M.S. Pearce

Emeritus Consultant Neurologist, Department of Neurology, Hull Royal Infirmary, Hull, UK

Key Words

Tonsillar herniation • Tentorial pressure cone • Temporal lobe herniation • Uncus • False localizing signs

Abstract

James Collier, in 1904, gave one of the best early accounts of tonsillar herniation as a terminal event caused by raised intracranial pressure. He also observed false localizing signs. Adolf Meyer added to the picture, describing detailed pathology of tentorial and subfalcial herniation, and hemianopia as a false localizing sign. In 1929, Kernohan and Woltman published their important work on ipsilateral hemiplegia accompanying expanding brain lesions. They demonstrated grooving of the crus cerebri on the side opposite to a tumour. Jefferson devised the term 'the tentorial pressure cone.' The current debate about the mechanisms is indicated in this short review.

Copyright © 2006 S. Karger AG, Basel

The clinical signs of imminent death seen in terminal brain tumours, abscesses and haematomata had been variably recognised though not understood from the time of Wepfer's account of cerebral haemorrhage [1]. The consequences of raised pressure within the skull were however only appreciated in the early 20th century. One of the first references to the causal brain herniation was that of James Collier [2], who clearly described cerebellar tonsillar herniation in 1904. He observed accom-

panying false localizing signs in 20 of 161 (12.4%) consecutive cases of intracranial tumour examined clinically and pathologically. Supratentorial lesions were the commonest cause. He commented:

'In many cases of intracranial tumour of long duration, it was found postmortem that the posterior inferior part of the cerebellum had been pushed down and backwards into the foramen magnum and the medulla itself somewhat caudally displaced, the 2 structures together forming a cone-shaped plug tightly filling up the foramen magnum.'

Adolf Meyer deserves credit for confirming the pathological brain herniation in a significant series in 1920 [3]. He wrote:

'The falx and tentorium constitute an important protection against any sudden impacts of pressure by keeping apart heavy portions of the brain, but they also provide an opportunity for trouble in case of swelling or need of displacement.'

He described hemianopia as a false localizing sign of uncal herniation caused by strangulation of the posterior cerebral artery.

Kernohan's notch is a groove in the cerebral peduncle caused by displacement of the brainstem against the incisura of the tentorium in some cases of transtentorial herniation. The resulting ipsilateral hemiparesis, a false localizing sign, despite Collier's and Meyer's earlier findings, became known as the Kernohan-Woltman syndrome.

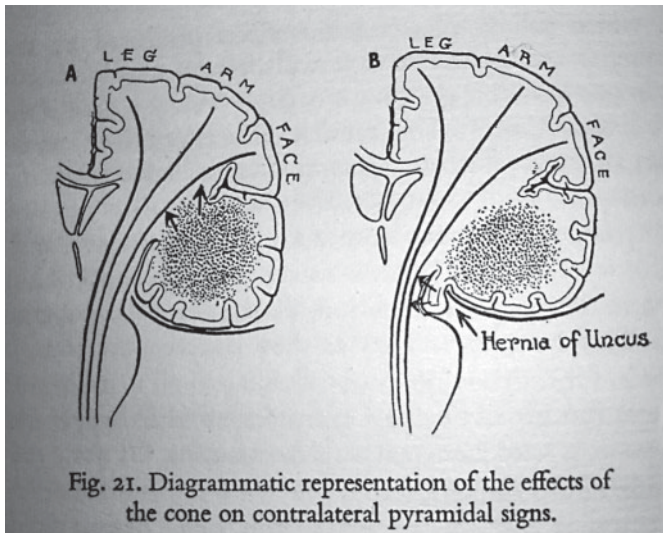


Fig. 1. Illustration from Jefferson's *The tentorial pressure cone* [7].

Kernohan-Woltman Syndrome

Another early, brief case report by Groeneveld and Schaltenbrand described [4] a case of tumour of the cerebral hemisphere with a 'remarkable complication: lesion of the crossed pes pedunculi with pressure on the tentorial edge.' In 1929, Kernohan and Woltman published their important work [5] on ipsilateral hemiplegia accompanying expanding brain lesions. They, too, showed grooving of the crus cerebri on the side opposite to a tumour:

'The tumour was often large enough to displace the brain toward the opposite side and also to cause herniation through the tentorium. Such herniation and displacement may be evidenced by a groove sweeping over the uncinate gyrus on the side of the tumour. On the opposite side the groove may be absent...' (p. 282)

They concluded, 'Notching of the crus cerebri by the free margin of the tentorium could, we believe, explain the homolateral signs of the pyramidal tract noted in most of our cases.'

In 1931, Kaplan [6] noted in eight chronic subdural haematomas that:

'Misleading pyramidal tract signs have been noted frequently in cases with chronic subdural hematoma. A dilated and fixed pupil on one side, even in the presence of homolateral paresis or bleeding from the opposite ear, points to a lesion on the same side. (...) The mechanism by which this notch is produced, whether by

displacement of the brainstem at a diencephalic level or by the herniating uncus, remains unclear.

There the matter rested until 1938, when Sir Geoffrey Jefferson [7] described in four cases the mechanism of temporal lobe herniation:

'The temporal lobes lie on the tentorium, which slopes away laterally as a gently inclined plane, so that pressure from above will tend to make them slide away from the midline. However, if one lobe is enlarged it cannot escape overhanging the free edge. For this reason, a tumour of the temporal lobe will be the surest way of bringing it more firmly into contact with the midbrain and squeezing its inner border over the sharp edge of the falx, into a situation in which it can herniate downward into the posterior fossa. The free edge of the tentorium now cuts deeply into it (...) The crowding of the temporal lobe into the incisura must have an effect on the crus.'

Jefferson applied the term 'the tentorial pressure cone.' From autopsies he deduced that 'death results from interference with the subthalamic autonomic vegetative centres or with the pathways from them.' He emphasized the selective compression of the posterior cerebral artery. Figure 1 shows an uncal herniation from Jefferson's 1938 article [7].

A year later Read and Cone [8] induced raised pressure in 10 macaques, showing:

'A lesion in the form of a herniated hippocampal gyrus pressing on the third nerve. In some of our cases, the nerve was flattened or stretched and in one instance discolored (...) The amount of pressure necessary to produce the herniation in the normal animal may give some idea of the pressures in cases in human beings. (...) In some of the animals, it was almost as high as systolic blood pressure and this may aid in the explanation of the infarctions that occur in man.'

The Kernohan-Woltman notch and midbrain haemorrhages seen in humans were not found in the macaques. It is clear that until Jefferson's paper, the temporal or uncal herniation was not always distinguished from the 'tonsillar' or 'central' herniation of the cerebellum and brainstem. Plum and Posner [9] visualized a rostro-caudal stepwise progression: a more continuous process of brain displacement. This found general acceptance.

Recent observations on cerebellar pressure coning have raised doubts about its mechanism. Ropper [10] regards uncal herniation as a passive rather than an active process as the mesencephalon is twisted and the ipsilateral space of Bichat is widened by the expanding cerebral mass. Contrary to traditional concepts, early stupor or coma correspond to distortion of the brain by lateral displacement rather than vertical transtentorial herniation

with brain stem compression. Pineal displacement >6 mm correlates with stupor, and >8.5 mm with coma [10]. Fisher [11], combining clinical, pathologic, and imaging data, concludes that temporal lobe herniation is not the means by which the midbrain sustains irreversible damage in acute cases, but rather lateral displacement of the brain at the tentorium is the prime mover and herniation a harmless accompaniment. Transtentorial herniation and descent through the tentorial opening could not be documented. Bilateral brain stem compression in acute bilateral cases must be distinguished from herniation [11]. Upward cerebellar herniation indicates an overflow posterior fossa, and subfalcial herniation is tolerated unless lateral displacement is excessive. Brain stem ischaemia is a recently suggested mechanism for third nerve and brain stem signs [12].

James Watson Kernohan (1896–1981) was born in County Antrim, Ireland, and died in 1981. Kernohan graduated from Queen's University, Ireland, moving in 1931 to become a pathologist at the Mayo Clinic until his retirement in 1962. He focussed his attention on neuropathology, especially on tumours (together with Alfred Uihlein, Kernohan published *Sarcomas of the Brain* [13]) and vascular lesions of the cord, and brain abscesses. He developed a widely used classification system for brain tumours [14]. Only little is recorded about Henry William Woltman (1889–1964) [15], who was associate professor at the Mayo clinic. He also worked with Kernohan on periarteritis nodosa.

References

- 1 Pearce JMS: Johann Jakob Wepfer (1620–1695) and cerebral haemorrhage. *J Neurol Neurosurg Psychiatry* 1997;62:387.
- 2 Collier J: The false localizing signs of intracranial tumour. *Brain* 1904;27:490–508.
- 3 Meyer A: Herniation of the brain. *Arch Neurol Psychiatry* 1920;4:387–400.
- 4 Groeneveld A, Schaltenbrand G: Ein Fall von du raendothelium über der Grosshirnhemisphäre mit einer bemerkenswerten Komplikation: Läsion des gekreuzten pes pedunculi durch Druck auf den Rand des Tentoriums. *Dtsch Z Nervenheilkd* 1927;117:32–50.
- 5 Kernohan JW, Woltman HW: Incisura of the crus due to contralateral brain tumor. *Arch Neurol Psychiatry* 1929;21:274–287.
- 6 Kaplan A: Chronic subdural hematoma: a study of eight cases with special reference to the state of the pupil. *Brain* 1931;54:430–459.
- 7 Jefferson G: The tentorial pressure cone. *Arch Neurol Psychiatry* 1938;40:857–876.
- 8 Reid WL, Cone WV: The mechanism of fixed dilatation of the pupil. *JAMA* 1939;112:2030–2034.
- 9 Plum F, Posner J: *The Diagnosis of Stupor and Coma*, ed 3. Philadelphia, Davis, 1980.
- 10 Ropper AH: Lateral displacement of the brain and level of consciousness in patients with an acute hemispherical mass. *New Engl J Med* 1986;314:953–958.
- 11 Fisher CM: Brain herniation: a revision of classical concepts. *Can J Neurol Sci* 1995;22:83–91.
- 12 Ritter AM, Muizelaar JP, Barnes T, et al: Brain stem blood flow, pupillary response, and outcome in patients with severe head injuries. *Neurosurgery* 1999;44:941–948.
- 13 Kernohan JW, Uihlein A: *Sarcomas of the Brain*. Springfield, Charles Thomas, 1962.
- 14 Kernohan JW, Mabon RF, Svien HJ, et al: A simplified classification of gliomas. *Proc Staff Meet Mayo Clin* 1949;24:71–75.
- 15 Corbin KB, Kernohan JW: Henry William Woltman, MD, 1889–1964. *Neurology* 1965;15:413–414.