

6

Preoperative Assessment in Hallux Valgus

DAVID M. LAPORTA
THOMAS V. MELILLO
VINCENT J. HETHERINGTON

The goal of any bunion surgery is the elimination of pain, restoration of a congruous metatarsophalangeal joint, realignment of the hallux into a rectus position, and preservation of joint motion. The best method for predicting a successful surgical result in hallux valgus reconstruction is thorough preoperative planning. This helps ensure selection of the appropriate procedure to attain these goals. Preoperative planning should include a thorough history as to the progression of the deformity and an adequate clinical and radiographic examination. In addition, addressing the deformity by the choice of surgical procedures requires identifying its etiology and pathomechanics. This chapter reviews and details pertinent features of the preoperative clinical and radiographic examination.

ETIOLOGY

The hallux abducto valgus deformity may result from a variety of contributing factors. Proper historical and clinical assessment of the patient in both a non-weight-bearing and weight-bearing manner and a thorough biomechanical evaluation, as well as an understanding of the microscopic pathologies occurring in and around the first metatarsophalangeal joint, will ensure a more predictable surgical result by selection of the appropriate procedure or procedures.

A historical review of the various etiologies shows that some still believe that shoe choice, excessive ac-

tivity, and external environmental factors play a significant role in the development of hallux abducto valgus deformities. This belief persists despite historical studies that demonstrate these are aggravating factors, not primary pathologies. Hereditary factors are known to be causative only in that it is the foot type with its associated biomechanical abnormalities that is inherited, not necessarily the resulting pathologic condition known as hallux abducto valgus.

Biomechanical Etiology

The biomechanical etiology of hallux abducto valgus has its origin in the rearfoot. The subtalar joint range of motion when excessive will most often lead to a pronated foot. External factors such as limb rotations and equinus conditions tend to accelerate the pathologic processes associated with hallux abducto valgus. The sequence of events usually commences when the calcaneus everts beyond the vertical in an excessively pronated foot. The resultant eversion unlocks the midtarsal joint, allowing the axes of the talonavicular and calcaneocuboid joints to become parallel to each other and resulting in an unstable midtarsal joint. This instability, which persists during stance, allows for hypermobility of the first ray at the time it should be most stable for propulsion.¹⁻³

At the same time, the soft tissue musculature around the rearfoot and first ray become altered in the pronated foot. With calcaneal eversion, the pull of the flexor

hallucis brevis and longus are altered. In addition, with an unstable midtarsal joint the route of the peroneus longus muscle tendon is altered, thereby affecting the motion about the first ray. The peroneus longus muscle, coursing around the cuboid, normally inserts into the base of the first metatarsal and the medial cuneiform and stabilizes the complex at toe-off. In a pronated foot, the peroneus longus cannot perform this function, and the resultant muscular and biomechanical alteration results in a hypermobile first ray.^{4,9}

With the preceding definition and an understanding of the mechanics of hypermobility of the first ray as an etiology in hallux abducto valgus deformity, the first-ray axis and biomechanics of the subtalar and midtarsal joints can be discussed. The first ray possesses a triplane axis that courses in an anterior, lateral, and dorsal direction.^{3,10} Therefore, dorsiflexion of the first metatarsal will be accompanied by adduction and plantar flexion will be accompanied by abduction.

Motion about the first ray is dependent on the peroneus longus muscle. As was previously discussed, the peroneus longus muscle in turn is dependent on the stability of the midtarsal joint because it uses the cuboid as its fulcrum. From the cuboid this muscle courses anterior and dorsal to exert its stability on the first ray. The triplane stability exerted on the first ray in normal biomechanics is one of plantarflexion, abduction, and a posterior pull. In normal gait therefore as the foot progresses from midstance into propulsion, the supinating subtalar joint also locks the midtarsal joint; this ensures a stable lateral column of the foot and provides the peroneus longus muscle with an efficient fulcrum at the cuboid to exert a plantar, lateral, and posterior pull on the first ray. Consequently, any pronatory influence that causes an unlocking of the midtarsal joint may result in metatarsus primus adductus over a period of time.^{3,5}

Finally, it should be remembered that the first metatarsal head is firmly bound to the sesamoids by the tibial and fibular sesamoidal ligaments.^{11,12} In the early stage of hallux abducto valgus deformity, these two ligaments firmly hold the sesamoids to the metatarsal head. Therefore, the early radiographic view of the deformity is actually dorsiflexion, adduction, and inversion of the first metatarsal. As the deformity progresses over time, the tibial sesamoidal ligament becomes functionally elongated as it adapts to stress

placed on the medial side of the first metatarsophalangeal joint. The fibular sesamoidal ligament, conversely, functionally shortens along with the other lateral soft tissue structures. The first metatarsal rotates slightly at the metatarsal cuneiform articulation. In a pronated foot, this slight rotation of the metatarsal allows for an inversion or varus rotation of the first metatarsal head relative to the sesamoids. The hallux now moves in the opposite direction of the first metatarsal head, which accounts for the valgus or rotational component of the deformity. As the amount of hallux eversion increases over time, the tibial, intersesamoidal, and fibular sesamoidal ligaments continue to adapt functionally to the deformity. The surgical importance of the soft tissue adaptation lies in the fact that if valgus rotation of the hallux is a component of the deformity and if transection of the fibular sesamoidal ligament is not accomplished, there will still be some degree of valgus rotation left in the great toe. With the advent of biomechanics and a more detailed radiographic evaluation of the deformity, the etiology in hallux abducto valgus deformity has become more refined and may be categorized as follows³:

1. Hypermobility of the first ray
2. Instability of the midtarsal joint
3. Calcaneal eversion beyond vertical
4. Instability of the peroneus longus

Metatarsus Primus Varus

The first metatarsal articulates proximally with the first cuneiform via their articular surfaces and strong ligamentous support. As a result, any deviation or abnormality in this articulation can give rise to deformity. Some of the terms used to describe this relationship between the first metatarsal and the cuneiform, as well as the relationship between the first metatarsal and the second metatarsal, are *metatarsus primus varus*, *metatarsus primus adductus*, and an *increased intermetatarsal angle*. Quite often, and erroneously, these terms are used interchangeably. In reality, the term *metatarsus primus varus* classically is used to describe a condition in which both medial and lateral cortices of the metatarsal are of equal length, but there is an increase in the measurable angle between the first and

second metatarsal that is secondary to a deviation at the first metatarsocuneiform joint.

Additionally, there exists a difference in the margins or sides of the cuneiform such that the lateral margin as compared to the medial margin of the first cuneiform is longer, causing an oblique angulation of the first metatarsocuneiform joint.^{13,14} The clinical and radiographic effect is an increased intermetatarsal angle measurement on radiographs, and a pronounced first metatarsal medially on palpation. This type of cuneiform has often been termed *atavistic* and was originally discussed by Lapidus¹⁵ in the surgical correction of hallux abductor valgus deformity. Klienberg in 1932¹⁶ believed that such obliquity at the first metatarsophalangeal joint represented a medial cuneiform that was an atavistic remnant of a period when the hallux had a prehensile thumb-like function.

The alternative concept of an os intermetatarsum as the proximate cause of a true metatarsus primus varus was a poor attempt to explain its occurrence. Objective studies by Wheeler¹⁷ failed to demonstrate the correlation between the presence or absence of an os intermetatarsum and the development of metatarsus primus varus.

The radiographic diagnosis of metatarsus primus varus may be demonstrated by comparing the longitudinal bisection of the first metatarsal with the longitudinal bisection of the medial cuneiform. If the angle formed between this intersection is greater than 25°, a metatarsus primus varus deformity is said to exist within the first ray.¹⁸ However, it should be emphasized that the obliquity seen on radiographic images may quite possibly represent a positional alteration produced by the imaging technique. In short, metatarsal primus varus is a true structural deformity that lies within the first metatarsal cuneiform relationship. Metatarsus primus adductus or increased intermetatarsal angle are indeed the same entity, and represent a deformity characterized by an increased angulation from a long axis bisection of the first and second metatarsals. The presence of metatarsus primus adductus is an important consideration in understanding the osseous pathologies associated with hallux abductor valgus. This change may be the result of long-standing biomechanical pathologies as opposed to inherent structural deformity, but in either event if any of the deformities of metatarsus primus varus or metatarsus primus adductus are pathologic, they must be corrected. In fact,

Hardy and Clapman⁹ were the first to demonstrate that in younger patients it is an increase in the metatarsus primus adductus of the first ray that initiates the transverse plane rotation of the great toe. Of 78 patients who developed adult hallux valgus deformity, it was a consistent finding that the initiating factor in the osseous structure was an increased intermetatarsal angle, which was later followed by the hallux moving away from the midline of the body.

CLINICAL EVALUATION

The podiatric surgeon should never base the selection of a surgical procedure solely on any one set of findings or evaluations. It is only after a thorough history and clinical examination in conjunction with assessment of standardized radiographs that one may consider the appropriate surgical procedure that will yield the best long-term result. All too often the preoperative clinical examination of the deformity is limited to the patient seated in the chair. It should be remembered that hallux abductor valgus is a dynamic propulsive phase deformity that obligates both non-weight-bearing and weight-bearing examination, as well as palpation and gait analysis.

The practitioner should first obtain a thorough history of the patient's chief complaint. One should note the exact location of the pain as being deep within the first metatarsophalangeal joint or solely confined at the medial eminence, and if there is coexisting second metatarsal pain. One should inquire as to the duration of the pain. A long-standing deformity that has only recently worsened may be indicative of erosion of the plantar crista, which has now allowed the sesamoids to drift laterally unimpeded. It is equally important to establish any functional limitations resulting from the deformity. The practitioner should inquire if there is pain at rest, only in shoe gear, or on vigorous activity.

Another important consideration in the preoperative assessment in hallux abductor valgus reconstruction is the age of the patient. The practitioner should select the procedure that will yield a functional and cosmetic long-lasting result. In addition, associated deformities such as ankle joint equinus may also be addressed at this time in the younger patient. Finally, the podiatric history is no different from the standard format utilized in the medical arena. A thorough systemic

history should be obtained on every patient contemplating any surgical procedure.

As mentioned previously, the clinical examination should be performed in both the non-weight-bearing and weight-bearing attitudes. It should be remembered that the physical examination should include a thorough assessment of vascular, dermatologic, neurologic, and musculoskeletal systems.

The examination of the bunion deformity should begin with thorough palpation of the bunion and first metatarsophalangeal joint to localize the exact area of tenderness. This preferably is done while placing the joint through an entire range of motion. Pain throughout range of motion at extreme dorsiflexion or plantar flexion may indicate synovial or cartilaginous changes. Although there is often a dorsomedial prominence, the presence of a bursal swelling should be noted. In addition, many patients exhibiting hallux valgus deformity may actually present with a chief complaint of a paronychia of the fibular nail border, which results from the abutment of the hallux against the second toe. The sesamoids and plantar crista should also be palpated for localized tenderness.

Examination of the first metatarsophalangeal joint range of motion is vital for a successful surgical outcome. First, the quantity of the range of motion should be noted. The normal first metatarsophalangeal joint should exhibit at least 65° of dorsiflexion and 15° of plantar flexion. Any decrease in the quantity of motion may be indicative of arthritic changes predisposing the joint to a hallux limitus deformity. Severe arthritic changes with cartilaginous erosions would make any attempt at osseous and soft tissue realignment futile in hallux valgus reconstruction.

The quality of motion within the first metatarsophalangeal joint should likewise be carefully evaluated. This evaluation should be performed with the joint in both the deviated and rectus position. Again, it should be noted if pain is elicited at the endpoint of the range of motion or throughout range of motion. Any crepitation should be noted as this may indicate articular damage or structural adaptation within the joint.

In addition to the first metatarsophalangeal joint, the entire first-ray range of motion should be evaluated. The first ray normally has an axis of motion approximately 5 mm toward dorsiflexion and plantar flexion. An increase in motion around the first-ray axis

may indicate hypermobility, which may affect the selection of the appropriate surgical procedure.

Any callous formation should be noted as to its location around the bunion deformity. The callous pattern should be noted as plantar first metatarsal, plantar medial interphalangeal joint, or underneath the second metatarsal.¹⁸⁻²⁰

RADIOGRAPHIC EVALUATION

Proper radiographic evaluation of the hallux abducto valgus deformity requires standard preoperative weight-bearing views taken in the angle and base of gait.²¹ It cannot be overemphasized that hallux valgus represents a dynamic deformity on which ground reactive forces exert a direct pronounced effect.

Standard preoperative views should consist of weight-bearing dorsiplantar, lateral, forefoot axial, and medial oblique projections. Dorsiplantar and lateral views together will allow the practitioner to accurately measure traditional relationships and identify positional and structural components of the deformity. A 45° medial oblique projection demonstrates hypermobility from lack of parallelity between the first and second metatarsals. The medial oblique projection will also act as a standard for assessment of pre- and postoperative correction of the deformity. The forefoot axial projection will aid in evaluating degenerative changes noted within the sesamoid apparatus. The plantar crista of the first metatarsal head may also be viewed and evaluated for erosive changes that may accelerate the deformity. We do not recommend evaluating the tibial sesamoid position on the forefoot axial view, because it should be remembered that activation of the "windless mechanism" will cause the deformity to appear less severe than it actually is.³

Finally, the preoperative radiographic evaluation must be combined with a thorough history of the patient's chief complaint and proper clinical examination in both the non-weight-bearing and weight-bearing stance.

Intermetatarsal Angle

The intermetatarsal angle is formed by the angle produced at the intersection of the longitudinal bisection

of the shafts of the first and second metatarsal (Fig. 6-1). A normal range for the intermetatarsal angle in the rectus foot is considered to be 0° - 14° . In the adducted foot type, 0° - 12° may be considered normal. An abnormally increased intermetatarsal angle may be termed *metatarsus primus adductus*.²² This transverse plane relationship is one of the most important in selecting the appropriate surgical procedure. As the intermetatarsal angle approaches values greater than 15° , one may wish to consider a more proximally based osteotomy for greater correction. A metatarsal head or neck osteotomy may be considered when the intermetatarsal angle is mild to moderately increased.²³ Scott et al.²⁴ reported that when comparing the intermetatarsal angle, metatarsus primus varus, the metatarsal cuneiform angle, and the metatarsus omnis varus angle in patients with hallux valgus, medial deviation of the first metatarsal was measured differently by all four angles. Therefore, it appears the best measure of deviation of the first metatarsal is the intermetatarsal angle.²⁴

Hallux Abductus Angle

The hallux abductus angle or hallux valgus angle is formed by the intersection of a line drawn through the long axis of the first metatarsal and the long axis of the proximal phalanx (see Fig. 6-1). A normal hallux abductus angle is one that measures less than 16° in the rectus foot type. Mild deformity is present when this angle measures between 17° and 25° . The deformity is categorized as severe when the angle measures up to 35° . Finally, a subluxed joint is usually apparent when this relationship measures more than 35° .²⁴

Proximal Articular Set Angle

The proximal articular set angle (PASA) is another valuable measurement of structural deformity within the metatarsal head. This angle is formed by a line representing the effective articular cartilage of the first metatarsal head and a perpendicular line to the bisection of the shaft of the first metatarsal¹⁸ (Fig. 6-2A). An abnormal increase in PASA may demonstrate the loca-

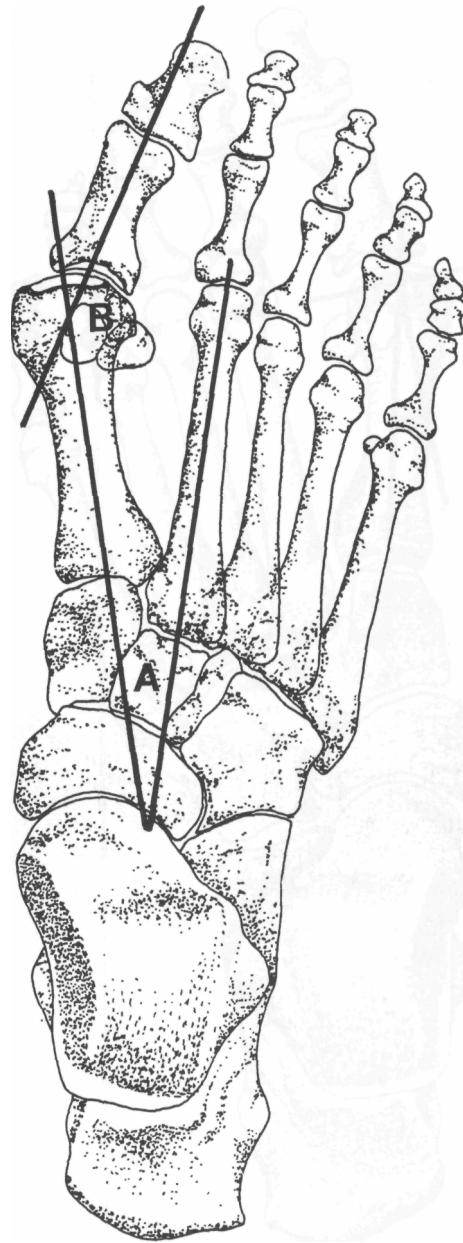
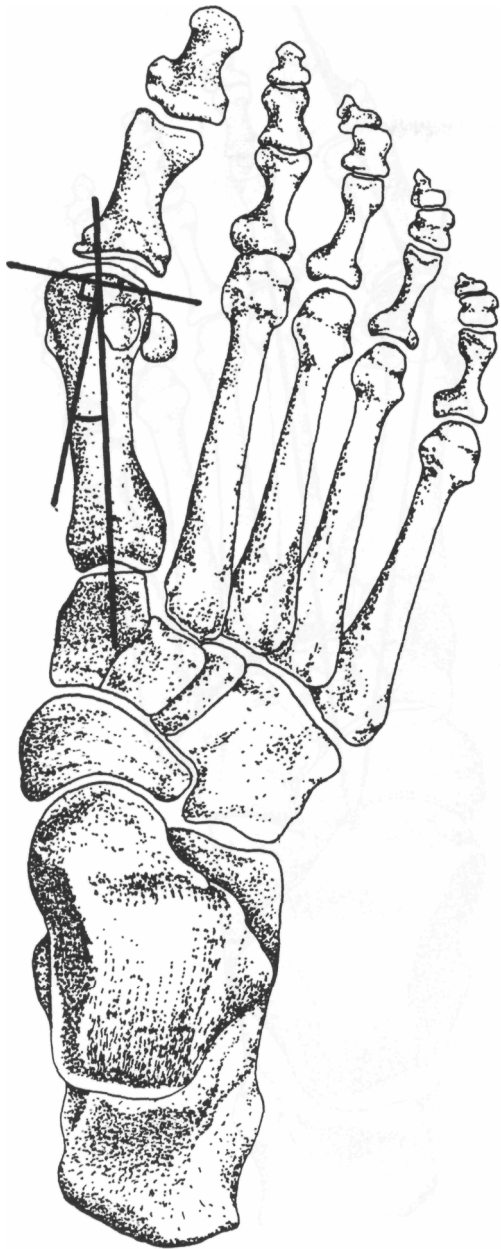
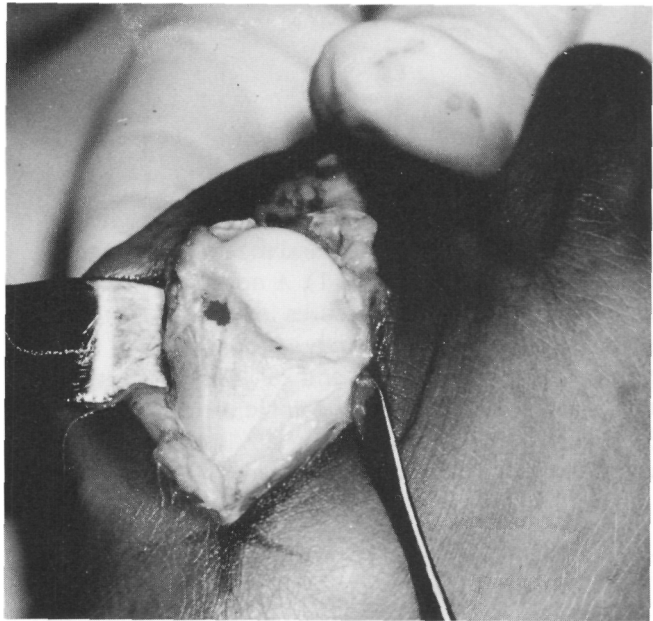


Fig. 6-1. A. Intermetatarsal angle; B. hallux abductus angle.

tion of a structural deformity in the head of the metatarsal, and it may progressively increase secondarily to structural adaptation of the articular cartilage surface as the deformity progresses. A normal PASA is one that measures less than 8° in the rectus foot. However, our



A



B

Fig. 6-2. (A) Proximal articular set angle. (B) Intraoperative photograph shows deviation of effective articular cartilage in a patient with hallux abducto valgus.

experience has led to the belief that the most reliable indicator of an abnormal PASA is to visualize the articular cartilage of the first metatarsal intraoperatively (Fig. 6-2B). Also, one should recognize that when performing an osteotomy at the base of the first metatarsal

to correct an abnormal intermetatarsal angle, the PASA may be relatively increased to a point that the first metatarsal phalangeal joint is no longer congruous, necessitating a second distal osteotomy to connect for the relative increase in the PASA.

Tangential Angle to the Second Axis

The tangential angle to the second metatarsal axis (TASA) is formed by the bisection of the effective articular surface of the first metatarsal and its perpendicular to the longitudinal axis of the second metatarsal²⁵ (Fig. 6-3). TASA is helpful in determining the angulation of a transverse V osteotomy when performing an Austin-type procedure. In fact, TASA actually redefines a rectus hallux because it compares the position of the hallux to the second toe angle and not to the shaft of the first metatarsal. Ideally, TASA should equal 0°, but an acceptable range is $\pm 5^\circ$. A useful equation that may be employed preoperatively when assessing TASA is $TASA = PASA - IM$ angle. Therefore, the only time it is indicated to reduce PASA to 0° is when the intermetatarsal angle is 0°. Utilizing this formula, one can see that TASA concomitantly reflects changes that occur in both the proximal articular set and the intermetatarsal angle in any given foot.²⁵

Distal Articular Set Angle

The distal articular set angle (DASA) represents the angle formed by the bisection of the shaft of the proximal phalanx and the line representing the effective articular cartilage of the base of the proximal phalanx (Fig. 6-4). A normal DASA is considered to be less than 8°. Historically, an abnormal DASA may be corrected by employing a proximal osteotomy near the base of the proximal phalanx. It should be remembered, however, that whenever hallux valgus deformity is present clinically and radiographically the proximal phalanx will also present with some degree of rotation on x-ray examination. This means that one is not viewing the true structural medial and lateral borders of the proximal phalanx. Therefore, preoperative assessment of DASA should be fully compared with the clinical amount of valgus deformity if correction at the base of the proximal phalanx via osteotomy is to be addressed.^{26,27} Another factor to consider in measuring the DASA is the length of the proximal phalanx, or the presence of a distal angulational abnormality.

Hallux Abductus Interphalangeus

The hallux abductus interphalangeus (HAI) angle is a comparison of the longitudinal bisection of the proxi-

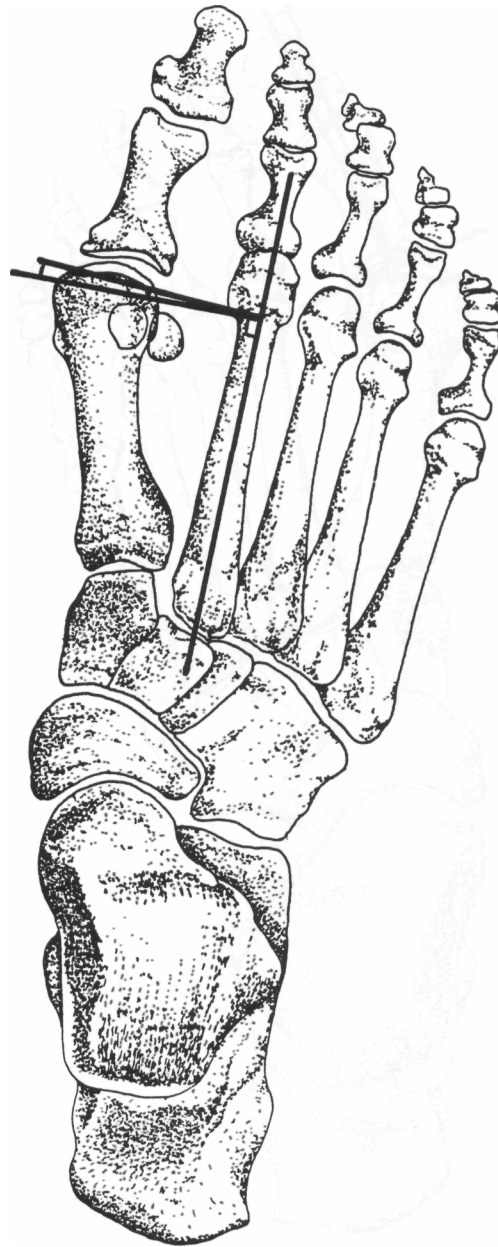


Fig. 6-3. Tangential articular set angle.

mal phalanx with the longitudinal bisection of the distal phalanx (Fig. 6-5). The HAI angle is usually considered normal when it measures within a range of 0°-10°. An increase in this angle indicates that the level of deformity is present at the interphalangeal

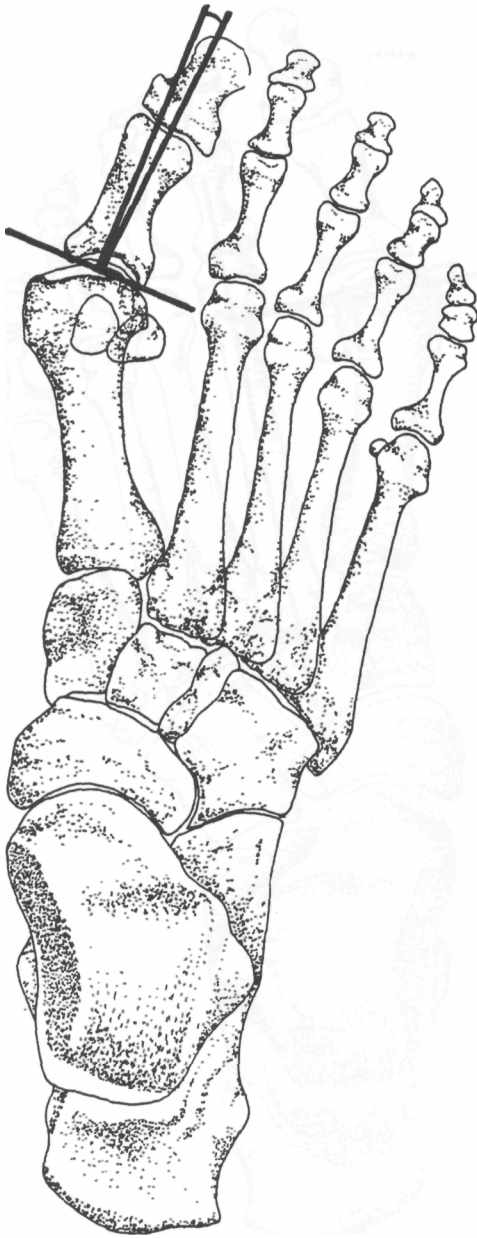


Fig. 6-4. Distal articular set angle.

joint of the hallux. Correction of this deformity is usually addressed at the head of the proximal phalanx.²⁸ Although osteotomies at the base of the proximal phalanx to correct for an abnormal DASA or hallux interphalangeus angle (HIA) have long been used as an adjunct procedure in the surgical management of

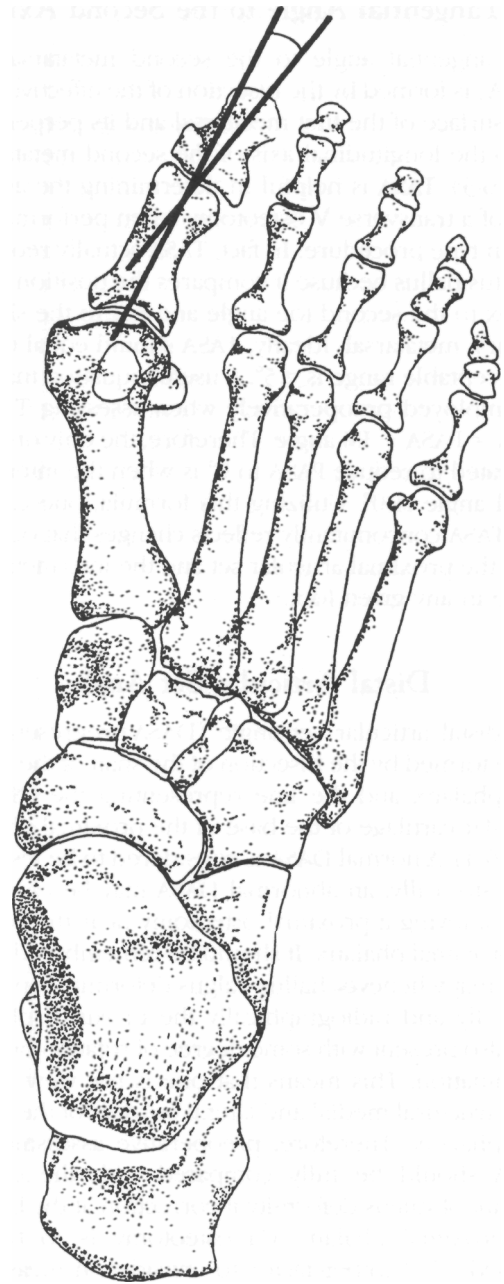


Fig. 6-5. Hallux abductus interphalangeus angle.

hallux abducto valgus deformity, it is our experience that the surgeon will get a more satisfactory functional and cosmetic result when performing an osteotomy at the head of the proximal phalanx if the HIA angle is abnormal.

Tibial Sesamoid Position

The tibial sesamoid position describes the relationship of the tibial sesamoid to the bisection of the first metatarsal shaft on a weight-bearing dorsiplantar view. A numerical sequence of one to seven is described with increasing deformity¹⁸ (Fig. 6-6). A tibial sesamoid position of four or greater represents a significant contraction of the fibular sesamoidal ligament and corresponding sesamoid apparatus. Many practitioners have advocated a fibular sesamoidectomy when the tibial sesamoid position is four or greater.²⁹ However, with adequate soft tissue release it is often possible to realign the fibular sesamoid under the head of the first metatarsal. Therefore our criteria for performing a fibular sesamoidectomy is when the sesamoid presents with severe arthritic changes or is fused to the lateral aspect of the first metatarsal head. Also, a fibular sesamoidectomy should be considered when one simply cannot relocate the tibial sesamoid under the metatarsal head.

Smith et al.³⁰ have recommended a simplified method of measuring the tibial sesamoid position us-

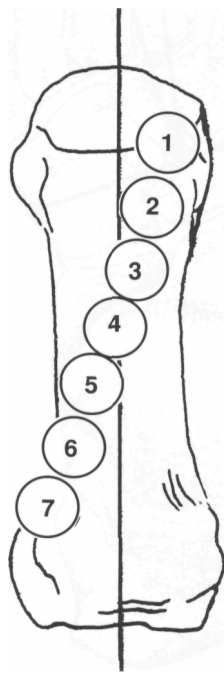


Fig. 6-6. Tibial sesamoid position.

ing gradations 0, 1, 2, and 3 rather than the traditional seven. They found the four-grade system was adequate and easier to apply than the seven-grade system in the literature.

Finally, as mentioned previously, one should not use a forefoot axial radiograph to assess the tibial sesamoid position. It should be remembered that when the metatarsal phalangeal joint is dorsiflexed to obtain the forefoot axial view, the windlass mechanism is activated, which allows the position to appear less severe than the deformity actually is.

Relative Lengths of the First and Second Metatarsal

Metatarsal protrusion is the comparison of the first and second metatarsal lengths. A normal protrusion is +2 to -2 mm. The first and second metatarsal shafts are first bisected and extended proximally to their point of intersection. From this point a compass may be used to construct an arc to the most distal point of the first and second metatarsals. The distance between the arcs is now measured in millimeters (Fig. 6-7). If the first metatarsal is longer, a positive value is assigned; if shorter, a negative value.¹⁸ There exists a strong correlation between a long first metatarsal and a hallux valgus or hallux limitus deformity. Therefore, the practitioner may wish to employ an osteotomy that will shorten the first metatarsal as well as correct for valgus deformity. In the case of a short first metatarsal, we do not recommend a lengthening procedure, because jamming may occur at the first metatarsal phalangeal joint and thus cause a limitus deformity.

Metatarsus Adductus Angle

An accurate measurement of the metatarsus adductus angle should be made, especially in the preoperative planning of correction of juvenile hallux abducto valgus deformity. The midway point of both the medial aspect of the metatarsocuneiform joint and the talonavicular joint is first found. Similarly, the midway point of the lateral aspect of both the calcaneocuboid joint and fourth metatarsocuboid joint is found. These medial and lateral midway points when connected represent the perpendicular to the long axis of the lesser tarsus. A line perpendicular to the long axis of the lesser metatarsus is now drawn and compared to its bisection of the longitudinal axis of the second

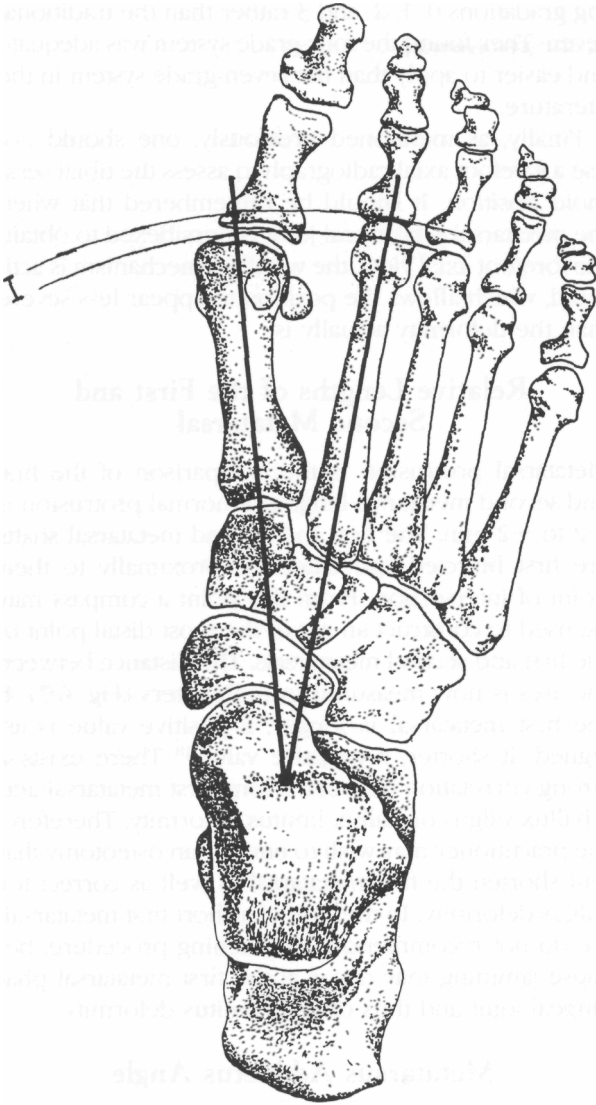


Fig. 6-7. Relative metatarsal protrusion.

metatarsal. The angle formed represents the metatarsus abductus angle¹⁸ (Fig. 6-8). The metatarsus adductus angle is considered normal when it is less than 15° in the rectus foot type. It has great clinical implications in the selection of a bunion procedure. As a general rule, it should be remembered that the greater the metatarsus adductus angle, the greater the hallux abductus angle and the smaller the intermetatarsal angle.³¹

The following formula is quite useful to assess the true intermetatarsal angle (IMAp):

$$\text{IMAp} = \text{M 1} - 2 + (\text{MAA} - 15^\circ)$$

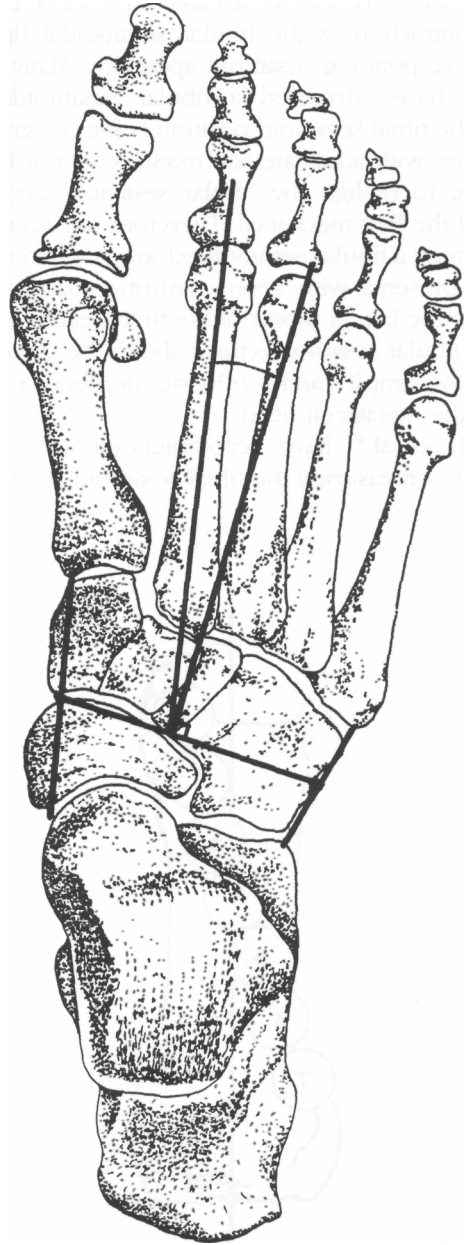


Fig. 6-8. Metatarsus adductus angle.

First Metatarsophalangeal Joint Articulations

The articulating surface between the head of the first metatarsal and base of the proximal phalanx in hallux abducto valgus deformity may be described as congruous, deviated, or subluxed. A congruous joint is one in which lines representing the effective articular surfaces of the metatarsal head and base of the proximal phalanx are parallel; to 3° divergence is considered normal. The normal first metatarsal phalangeal joint should be congruous. However, a congruous joint can be found in hallux abducto valgus deformity and may represent a structurally adapted articulation (Fig. 6-9A).

The metatarsophalangeal joint is deviated when the lines representing the effective articular surface of the head of the first metatarsal and base of the proximal phalanx intersect at a point outside the joint (Fig. 6-9B). A normal range of deviated first metatarsophalangeal articulation is 4 percent to 25 percent. In the subluxed joint, effective articular lines of the first metatarsophalangeal joint intersect within the joint itself (Fig. 6-9C). The angle formed is usually greater than 25 percent. The subluxed first metatarsophalangeal articulation represents a stage of deformity

with rapid progression. A common example would be in the patient with rheumatoid arthritis.

Shape of the First Metatarsal Head

The shape of the first metatarsal head when viewed on an anteroposterior (AP) radiograph may be described as round, square, or square with a central ridge. A normal first metatarsal head demonstrates a smooth, continuous, circular pattern (Fig. 6-10A). It is often considered as the least stable of first metatarsophalangeal joint articulations. In the younger patient with a flexible deformity, the round first metatarsal head is the most amenable to soft tissue procedures.³²

The square first metatarsal head is rarely found in hallux abducto valgus deformity (Fig. 6-10B). It is visually indicative of a hallux limitus or hallux rigidus deformity. The metatarsal head that is square with a central ridge is perhaps the most stable of the metatarsal head shapes (Fig. 6-10C). The central ridge is probably the plantar crista, which becomes more important when the first metatarsal is dorsiflexed (Fig. 6-10B). In a study of 6,000 school children, Kilmartin and Wallace³³ did not find statistical evidence to validate these beliefs. They concluded that "while the shape of the

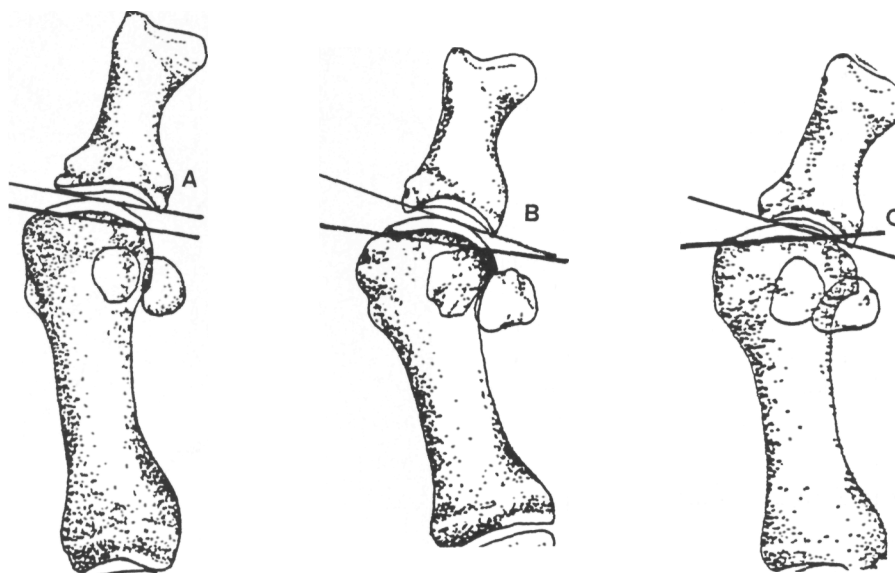


Fig. 6-9. Metatarsal joint articulation. (A) Congruous; (B) deviated; (C) subluxed.

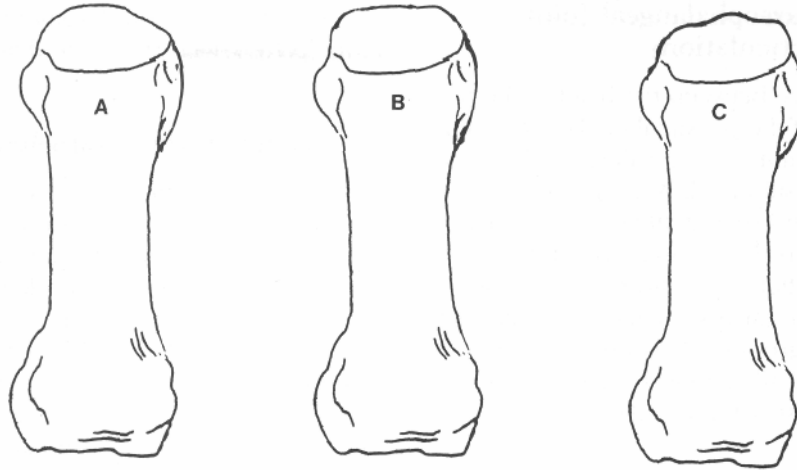


Fig. 6-10. Metatarsal head shape. (A) Round; (B) square; (C) square with central ridge.

metatarsal head may be an interesting radiological observation, it has little to contribute to the scientific assessment of first metatarsophalangeal joint pathology.¹³³

Metatarsocuneiform Joint

The metatarsocuneiform joint should also be assessed in hallux abducto valgus deformity. This articulation may be described as square, oblique, or round. As with the first metatarsal head, a rounded first metatarsocuneiform joint may be considered the most flexible and it is also most amenable to soft tissue correction. The most commonly observed shape in hallux abducto valgus deformity. A flat articulation is probably most clinically significant in the preoperative assessment of the deformity. An oblique metatarsocuneiform joint may represent an etiologic factor in the metatarsus primus varus deformity of the first metatarsal. In this instance, the practitioner may wish to select a basal osteotomy to reduce the intermetatarsal angle. An articulation between the first and second metatarsals may also exist blocking reduction of the intermetatarsal angle without metatarsal osteotomy (Fig. 6-11).

Radiographic Angular Relationships

After the practitioner has assessed all the pertinent traditional angular values, certain angular relationships may be gathered to aid one in the selection of the surgical procedures.

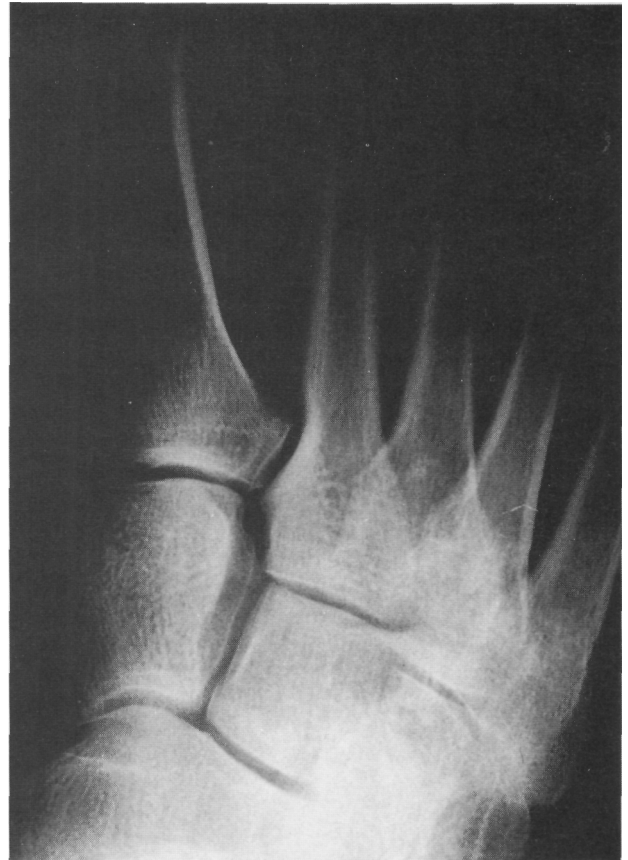

Fig. 6-11. Articulation between the first and second metatarsals that would resist a positional change in the intermetatarsal angle by soft tissue procedure alone.

A structural deformity is present when $PASA + DASA = HA$ with $PASA$ or $DASA$ exhibiting an abnormal value. Joint evaluation will reveal a congruent joint. It should be remembered that it is not the absolute numbers that are important but their relationship to each other. In this situation, an osteotomy is indicated as part of the corrective procedure.

A positional deformity exists when $PASA + DASA < HA$ with $PASA$ and $DASA$ both being normal. This is a soft tissue deformity and the joint position will be deviated or subluxed. Finally, a combined deformity is present when elements of both soft tissue and osseous structure contribute to the deformity.

JUVENILE HALLUX VALGUS

Hallux valgus as it occurs in the juvenile is a deformity of the first metatarsophalangeal joint that may present with pain, is progressive in nature, and may lead to future degenerative changes and serve as source of embarrassment to the older child and young adult. The incidence of juvenile hallux valgus has been addressed by several authors. Craigmile¹ in 1953 studied children in the 12- to 15-year-old group; 22 percent of female and 4 percent of male children exhibited some degree of bunion deformity. Cole³⁴ in 1959 found that 39 percent of female and 21 percent of male school children between the ages of 8 and 18 displayed mild to severe hallux valgus. Gould and others³⁵ reported in 1980 the incidence of bunions in the 4- to 14-year-old group to be rare; however, they found it to be five times more frequent in blacks. The male to female ratio was reported as approximately 1:1. Hardy and Clapman³⁶ in 1951 and Piggott³⁷ in 1960 reported a history of onset of the deformity before the age of 20 in adult patients with hallux valgus. Johnston³⁸ reported on a family with a seven-generation pedigree of hallux valgus and felt that it was attributable to an autosomal dominant trait with incomplete penetrance of the gene.

The etiology of juvenile hallux valgus is multifactorial with both genetic and environmental components. There is no doubt that the biomechanics of the child's foot contribute to the development of hallux valgus. The pathomechanical problems most often associated with juvenile hallux valgus are abnormal pronation associated with flexible flatfoot deformity. Juvenile hallux valgus may also be the presenting complaint of

a child or adolescent with metatarsus adductus.¹⁵ In this situation, the intermetatarsal angle will not be as large when compared with a juvenile hallux valgus, but will present with a prominent bunion deformity. In this deformity, there is an increase in adduction of all the metatarsals as opposed only to the first in juvenile hallux valgus. Serious consideration must be given to the management of the metatarsus adductus deformity in conjunction with the hallux valgus deformity.

Neurologic disorders such as cerebral palsy and Down syndrome have also been associated with the development of hallux valgus in the juvenile. In Down syndrome, the primary foot deformity has been reported to be hypermobile flatfoot with laxity of the soft tissues, which readily leads to the development of the juvenile hallux valgus deformity.

Inflammatory arthritis, of which juvenile rheumatoid arthritis is an example, may also result in this deformity. Goldner and Gaines³⁹ described a congenital hallux valgus with a short first ray, skin contracture, and severe deviation of the toe. They considered that this should be treated early, and that soft tissue releases and skin grafting may be necessary as well as osteotomy and bone graft to elongate the first ray.

First-ray deformity in juvenile hallux valgus may be considered as dynamic or static. Dynamic hallux valgus is a result of first-ray hypermobility with development of metatarsus primus abductus secondary to deviation of the great toe. It may also be associated with an abnormally long first metatarsal and hallux interphalangeus. Hardy and Clapman³⁶ suggested that some factors caused a lateral displacement of the distal phalanx of the great toe. They proposed that the pull of the extensor hallucis longus tendon is transferred laterally to the axis of the great toe in a bowstring effect, and that once this process has started lateral displacement of the first digit must increase. They stressed that the deformity was caused primarily by displacement of the great toe and widening of the intermetatarsal angle secondarily. Lundberg and Sulja⁴⁰ found increased relative protrusion of the first metatarsal was positively correlated with the development of hallux valgus.

Hardy and Clapman⁹ in 1951 found the first metatarsal, in cases of hallux valgus, to have a greater relative metatarsal protrusion than that of the controls. They noted that with a high degree of valgus of the hallux

and a low intermetatarsal angle, the first metatarsal tended to have a greater protrusion relative to the second metatarsal as opposed to cases with a low degree of valgus and a high intermetatarsal angle in which the second had the greater relative protrusion. Static hallux valgus is associated with deformity of the medial cuneiform, possibly a congenital defect that results in metatarsus primus varus as the primary deformity. It may also be caused by a metatarsal deviation or widening of the epiphysis of the first metatarsal proximally on its lateral aspect.

Jones⁴¹ though the primary deforming force in adolescent hallux valgus is adduction of the first metatarsal. He stated that a deformity of considerable severity may develop concurrently with the quick growth of the foot, and is associated with an adducted first metatarsal that was present at birth. He suggested that the metatarsal adduction was atavistic and related to evolutionary development. Bohm⁴² described the early stages of embryologic development of the first metatarsal. Early in normal development, the first metatarsal is at the medial border of the first cuneiform and forms an angle of 50° with the long axis of the foot, obviously being in marked adduction. This adduction is seen in the fetus and up to fourth month of gestation, gradually reducing until birth.

Hawkins and Mitchell⁴³ believed that there was a tendency to underestimate the significance of a congenital metatarsus primus varus in the development of a juvenile hallux valgus deformity. Shoe deformity forces were felt to be secondary to the congenital metatarsus primus varus. Simmonds and Menelaus¹⁴ also associated metatarsus primus varus with juvenile hallux valgus. They noted, as did Bonney and MacNab,⁴⁵ that metatarsus primus varus was the most important aspect needing correction in the adolescent if recurrence of the deformity was to be avoided, and believed it was a major factor contributing to the breakdown of the forefoot. Lapidus¹⁵ classified hallux valgus into three groups with the most predominant group showing a congenital predisposition to metatarsus primus varus. Truslow⁴⁶ thought the primary deformity was a wedging of the medial cuneiform or the proximal end of the metatarsal. The outward deviation of the toe was secondary to this primary deformity.

As alluded to earlier, Piggott³⁷ in his studies on adolescent hallux valgus classified the metatarsophalangeal joint into three groups. These classes were con-

gruous, deviated, or subluxed. In his study he could produce little or no evidence that metatarsus primus varus was the underlying cause of hallux valgus. He concluded that the structural prognosis of hallux valgus in the adolescent is as follows: Congruity of the joint surfaces can be considered as normal and indicates that a progressive deformity will not occur, but subluxation indicates that deterioration is likely; the deviation may or may not progress to subluxation. He noted subluxation of the first metatarsophalangeal joint was seen before closure of the metatarsal and phalangeal epiphysis. However, in support of metatarsus primus varus, Durman¹⁴ found a significant variation in shape of the first cuneiform. In his study, cuneiform deformity was present in 47 percent of patients with hallux valgus.

Thus we see that juvenile hallux valgus can be dynamic in nature, with deviation of the great toe resulting in an increase in the intermetatarsal angle, or a static deformity in which the primary etiology is more proximal, or a congenital effect, such as deformity of the medial cuneiform or base of the metatarsal. It is interesting to note that Luba and Rossman⁴⁷ show that preoperative compression and tension forces may act to perpetuate or stimulate active deformity by applying compression force to the epiphyseal plate medially and a tension force laterally, which may result in an asymmetric growth of the first metatarsal (Fig. 6-12). One could only speculate how this relationship interplays with the development of a structural metatarsus primus varus. In a study of 6,000 school children, Kilmartin et al.⁴⁸ failed to provide significant correlations between adduction of the first metatarsocuneiform joint, intercuneiform angle (an estimation of the alignment of the medial and intermediate cuneiforms), metatarsus adductus angle, or differentiation of growth patterns of the first metatarsal.³⁴

Clinical evaluation of the juvenile patient with hallux valgus deformity should be complete and thorough, including integrity of the soft tissue, examination for ligamentous laxity, joint status, and mobility, complete neuromuscular evaluation, and biomechanical evaluation.

When considering surgery in the child with juvenile hallux valgus, several areas are important. As with the adult hallux abducto valgus deformity, the correct procedure is chosen after careful examination, both clini-

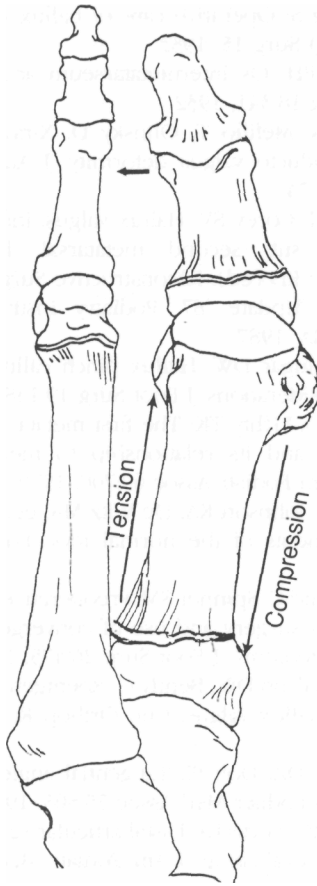


Fig. 6-12. Compressive and tension forces applied to the first metatarsal epiphysis as theorized by Luba and Rossman.

cally and radiographically. The growing foot, however, adds another dimension to this surgical correction. It appears that a slightly elevated intermetatarsal angle, at the time of examination in the child, may need greater reduction because of its tendency to increase with age. The timing of surgery should be related to the severity of symptoms, the estimation of progression of deformity based on radiographic criteria, and the skeletal age of the child. Estimation of skeletal age is important especially with regards to procedures around or involving the epiphyseal plate.

The goals of surgery in juvenile hallux valgus are primarily to correct the deformity, to reduce the intermetatarsal angle, to reduce the hallux abductus angle, to obtain and maintain a congruous metatarsophalangeal joint with realignment of the sesamoids, and to

have a pain-free range of motion. All this is predicated on the choice of the correct procedure.

A number of surgical procedures that may be used in the management of juvenile hallux valgus include soft tissue tendon-balancing procedures, whose main aim is to realign the osseous structures by correcting abnormality of soft tissue ligamentous and capsular structures. However, these procedures are infrequently done in the patient with juvenile hallux valgus as the primary procedure but are often used in conjunction with distal or proximal osteotomies that correct structural deformities. Distal metatarsal osteotomies can decrease the intermetatarsal angle and realign structural abnormalities in the transverse plane such as abnormal proximal articular set angles. They can shorten or maintain the length of the metatarsal. Distal osteotomies of use in juvenile hallux valgus include the Mitchell, Wilson, Austin, Reverdin, or Hohman types. Reduction of the intermetatarsal angle is accomplished by lateral displacement of those osteotomies. The degree of reduction will be less than that obtained with proximal osteotomies, and therefore lateral displacement osteotomy is used with intermetatarsal angles ranging from 12° to 16° . Proximal osteotomies include osteotomies of the metatarsal base, of the metatarsocuneiform joint in combination with a fusion, or cuneiform osteotomies. These osteotomies are used to correct hallux valgus deformities with increased intermetatarsal angles greater than 16° . Phalangeal osteotomy is limited to those cases in which structural deformity of the phalanx exist such as a transverse plane clinodactyly. Epiphysiodesis has been reported to be successful in the management of juvenile hallux valgus, and is best used in the child that is approaching skeletal maturity.⁴⁹

Complications following surgery for juvenile hallux valgus include recurrence of the deformity, Scranton and Zuckerman⁵⁰ reported a failure rate of 50 percent in patients with long first metatarsals and a 56 percent failure rate associated with collapsing pes valgo planus. Drennan,⁵¹ at an American Academy of Orthopedic Surgeons meeting in 1990, reported 30 to 50 percent recurrence of deformity after an initial procedure requiring secondary intervention. Metatarsalgia may occur postoperatively with excessive elevation or shortening of distal or proximal osteotomies. Excessive dorsiflexion may also lead to joint stiffness and secondary hallux rigidus. Total or partial premature

epiphyseal plate closure may occur and result in shortening or angular deformity of the metatarsal, undercorrection, or overcorrection. Epiphyseal plate closure may result secondary to osteotomy or arthrodesis of the metatarsal cuneiform articulation.

Juvenile hallux valgus is a complex deformity that needs careful preoperative clinical and radiographic evaluation. Consideration should be given to the appropriate timing of the procedure relative to the skeletal growth of the child. It is important to remember that no one procedure is appropriate for all juvenile or adolescent hallux valgus deformities.

REFERENCES

1. Craigmile DA: Incidence, origin and prevention of certain foot defects. *Br Med J* 2:749, 1953
2. Clough JG, Marshall HJ: The etiology of hallux abducto valgus. A review of the literature. *J Am Podiatr Med Assoc* 75:238, 1985
3. Root ML, Orien WP, Weed JH: Normal and Abnormal Function of the Foot. Los Angeles. Clinical Biomechanics Corp., 1977
4. Duke H, Newman LM, Bruskoff BL, et al: Relative metatarsal length patterns in hallux abducto valgus. *J Am Podiatr Assoc* 72:1, 1982
5. Gerbert J: Textbook of Bunion Surgery. 2nd Ed. Futura Publishing, New York, 1991
6. Harris RI, Beath T: The short first metatarsal: its incidence and clinical significance. *J Bone Joint Surg Am* 31:553, 1949
7. Robinson HA: Bunion: its cause and cure. *J Surg Gynecol Obstet* 27:343, 1918
8. Kalen V, Brecher A: Relationship between adolescent bunions and flatfeet. *Foot Ankle* 8:331, 1988
9. Hardy RH, Clapham JCR: Observations on hallux valgus. *J Bone Joint Surg* 33B:376, 1951
10. D'Amico JC, Schuster RO: Motion of the first ray. *J Am Podiatr Assoc* 69:17, 1979
11. DeBritto SR: The first metatarso-sesamoid joint. *Int Orthop* 6:67, 1984
12. Jahss MH (ed): The sesamoids of the hallux. *Clin Orthop* 157:88, 1981
13. Durman DC: Metatarsus primus varus and hallux valgus. *Arch Surg* 74:128, 1957
14. Durman DC: Metatarsus primus varus and hallux valgus. *J Bone Joint Surg* 39A:221, 1957
15. Lapidus PW: Operative correction of metatarsus primus varus in hallux valgus. *Surg Gynecol Obstet* 58:183, 1934
16. Kleinberg S: Operative care of hallux valgus and bunions. *Am J Surg* 15, 1932
17. Wheeler PH: Os intermetatarsium and hallux valgus. *Am J Surg* 18:341, 1932
18. LaPorta G, Melillo T, Olinsky D: X-ray evaluations of hallux abducto valgus deformity. *J Am Podiatr Assoc* 64:544, 1974
19. Jiminez AJ, Corey SV: Hallux valgus, intractable plantar keratosis sub second metatarsal, hammertoe. In McGlamry ED (ed): *Reconstructive Surgery of the Foot and Leg, Update '87*. Podiatry Institute Publishing, Tucker, GA, 1987
20. Sage RA, Jugar DW: Hallux pinch calluses: some etiologic considerations. *J Foot Surg* 19:148, 1980
21. McCrear JD, Lichty TK: The first metatarsocuneiform articulation and its relationship to metatarsus primus varus. *J Am Podiatr Assoc* 69:700, 1979
22. Steel MW, Johnson KA, De Witz MA, et al: Radiographic measurements of the normal foot. *Foot Ankle* 1:151, 1980
23. Southerland C, Spinner SM: Preoperative criteria for hallux valgus surgery and use of convergent angled base wedge osteotomy. *J Foot Surg* 26:475, 1987
24. Scott G, Wilson DW, Bently G: Roentgenographic assessment in hallux valgus. *Clin Orthop Relat Res* 267:143, 1991
25. Schechter DZ, Doll PJ: Tangential angle to the second axis. *J Am Podiatr Med Assoc* 75:505, 1985
26. Balding MG, Sorto LA: Distal articular set angle. Etiology and x-ray evaluation. *J Am Podiatr Med Assoc* 75:648, 1985
27. Barnett CH: Valgus deviation of the distal phalanx of the great toe. *J Anat* 96:171, 1962
28. Duke H, Newman LM, Bruskoff BL, et al: Hallux abductus interphalangeus and its relationship to hallux valgus surgery. *J Am Podiatr Med Assoc* 72:625, 1982
29. McGlamry ED: Hallucal sesamoids. *J Am Podiatry Assoc* 55:693, 1965
30. Smith RW, Reynolds JC, Stewart MJ: Hallux valgus assessment: report of research committee of the American Orthopedic Foot and Ankle Society. *Foot Ankle* 5:92, 1984
31. Yu GV, DiNapoli R: Surgical management of hallux abducto valgus with concomitant metatarsus adductus. In McGlamry ED (ed): *Reconstructive surgery of the foot and leg, Update '87*. Podiatry Institute Publishing, Tucker, GA, 1987
32. Jahss MH: Hallux valgus: further considerations, the first metatarsal head. *Foot Ankle* 2:1, 1981
33. Kilmartin TE, Wallace WA: First metatarsal head shape in juvenile hallux abducto valgus. *J Foot Surg* 30:506, 1991

34. Cole AE: Foot inspection of the school child. *J Am Podiatr Med Assoc* 49:446, 1959
35. Gould N, Schneider W, Ashikaga T: Epidemiological survey of foot problems in the continental United States. 1978-1979. *Foot Ankle* 1:8, 1980
36. Hardy RH, Clapman JCR: Hallux valgus; predisposing anatomical causes. *Lancet* ii:1180, 1952
37. Piggott H: The natural history of hallux valgus in adolescence and early adult life. *J Bone Joint Surg* 42:749, 1960
38. Johnston O: Further studies on the inheritance of hand and foot anomalies. *Clin Orthop Relat Res*
39. Goldner JL, Gaines RW: Adult and juvenile hallux valgus: analysis and treatment. *Orthop Clin North Am* 7:863, 1976
40. Lundberg BJ, Sulja T: Skeletal parameters on the hallux valgus foot. *Acta Orthop Scand* 43:749, 1960
41. Jones RA: Hallux valgus in the adolescent. *Proc R Soc Med* 41:391, 1948
42. Bohm M: The embryonic origin of clubfoot. *J Bone Joint Surg* 27:229, 1945
43. Hawkins FB, Mitchell CL, Hedrick DW: Correction of hallux valgus by metatarsal osteotomy. *J Bone Joint Surg* 27:387, 1945
44. Simmonds FA, Menelaus MB: Hallux valgus in adolescent. *J Bone Joint Surg* 42B:761, 1960
45. Bonney G, McNab, L: Hallux valgus and hallux rigidus—a critical survey. *J Bone Joint Surg* 34B:366, 1952
46. Truslow W: Metatarsus primus varus or hallux valgus. *J Bone Joint Surg* 7:98, 1925
47. Luba R, Rosman M: Bunions treatment with a modified Mitchell osteotomy. *J Pediatr Orthop* 4:44, 1984
48. Kilmartin TE, Barrington RL, Wallace WA: Metatarsus primus varus. *J Bone Joint Surg* 73B:937, 1991
49. Fox IM, Smith SD: Juvenile bunion correction by epiphyseodesis of the first metatarsal. *J Am Podiatr Med Assoc* 73(9):448, 1983
50. Scranton PE, Zuckerman JD: Bunion surgery in adolescents: results of surgical treatment. *J Pediatr Orthop* 4:39, 1984
51. Drennan JC: Instructional Course Lectures, The Childs Foot I. In *Proceedings, Annual Meeting AAOS, New Orleans, LA, February 1990*