

Office of the Chief Medical Examiner

CB # 7580 Chapel Hill, NC 27599-7580

Telephone 9199662253

REPORT OF AUTOPSY EXAMINATION

DECEDENT

Document Identifier B200801036

Autopsy Type ME Autopsy

Name Eve Marie Carson

Age 22 yrs

Race White

Sex F

AUTHORIZATION

Authorized By Steven D. Dubner MD

Received From Orange

ENVIRONMENT

Date of Exam 03/05/2008

Time of Exam 10:00

Autopsy Facility Office of the Chief Medical Examiner **Persons Present** Mr. Kevin Gerity, Dr. Steven Dubner, Ms. Molly Hupp

CERTIFICATION

Cause of Death

Multiple gunshot wounds

The facts stated herein are correct to the best of my knowledge and belief.

Digitally signed by

Cynthia Gardner MD 07 May 2008 12:26

DIAGNOSES

Gunshot wound of right cheek with injury to teeth # 5 and 6, alveolar ridge, maxilla, maxillary sinus and recovery of small caliber, deformed, full yellow metal jacketed bullet

Gunshot wound to right shoulder with injury of right posterior-lateral 4th rib, upper lobe of right lung, lower lobe of right lung, right hemidiaphragm and small intestine and recovery of small caliber, non-deformed, full yellow metal jacketed bullet

Perforating gunshot wound of right upper arm with injury to soft tissue

Perforating gunshot wound of right buttocks with injury to soft tissue

Shotgun wound of right hand with injury to soft tissues, bones, ligaments and vessels of the hand and recovery of birdshot pellets

Shotgun wound of head with injury to right temporal scalp, right temporal bone, right inferior frontal lobe of brain, right temporal pole of brain, pons, and cerebellum and recovery of plastic shot cup and birdshot pellets

Pale, anemic viscera

Aspiration of blood

Right hemothorax

IDENTIFICATION

Body Identified By

Visual

EXTERNAL DESCRIPTION

Length 65.5 inches

Weight 138 pounds

Body Condition Intact

Rigor Full

Livor Posterior, purple, unfixed

Hair Light brown, long and straight, 15" in length at the crown

Eyes Brown, cornea are clear, sclerae and conjunctivae are unremarkable, petechiae are not present

Teeth Natural, good repair

The body is that of a well developed, well nourished adult white female appearing compatible with the stated age of 22 years. The body is clad in a light gray tee shirt with the logo "X Civilización" (size large, brand "Roly"), dark blue sweatpants (size medium, brand "Gap") and light blue/gray/white athletic shoes (size 6 1/2, brand "Starbury"). About the neck is a yellow metal necklace with a small yellow metal locket. About the left wrist is a white paper wristband printed with "Be True" and "Nike." On the dorsum of the right hand are numerous long, straight, light-colored hairs. There is a small raised brown mole below the left eye. There is no evidence of medical intervention.

INJURIES

HEAD AND NECK:

1. On the right cheek, 59 1/2" above the heel, 2" to the right of midline, is an oval gunshot wound of entrance (gunshot wound A) measuring 0.3" x 0.15" and associated with a full concentric abrasion collar that measures 0.1" in width. There is no stippling, there is no soot. The wound track perforates skin, soft tissue, skeletal muscle, tooth #5, tooth #6, alveolar ridge, the palatine portion of the maxillary bone, and maxillary sinus. A small caliber, deformed, full yellow metal jacketed bullet is recovered from the maxillary sinuses, 60 1/2" above the heel, 1/2" to the left of midline. Direction is anterior to posterior, right to left, inferior to superior.

2. On the right temporal scalp, 62" above the heel, 2 1/2" to the right of midline, is an irregular shotgun wound of entrance measuring 2.5" x 1.8" with individual pellet entry sites at the wound margin at the 6 o'clock position ranging in diameter from 0.05" to 0.1". There is an irregular abrasion on the skin surface about the wound from the 9 o'clock to the 12 o'clock position that measures 1.6" x 1.3". There is no stippling, there is no soot, there is no white granular packing material. The wound track perforates skin, soft tissue, skeletal muscle, right temporal bone of skull, right inferior frontal lobe of brain, right temporal pole of brain, pons and cerebellum. Numerous birdshot pellets and a plastic shot cup are recovered from the wound track. Associated injuries include thin bilateral subdural hematomas, global subarachnoid hemorrhage, fractures of the bilateral anterior and middle cranial fossa, and linear fractures extending from the internally beveled entrance wound of the temporal bone involving the right temporal bone, right parietal bone and occipital bone. There are diastatic fractures of the lambdoid suture. Direction is right to left, anterior to posterior, superior to inferior.

TORSO:

1. On the right shoulder, 55 1/2" above the heel, 8" to the right of midline, is round gunshot wound of entrance (gunshot wound D) measuring 0.2" in diameter and associated with a full concentric abrasion collar that measures 0.05" in width. There is no stippling, there is no soot. The wound track perforates skin, soft tissue, skeletal muscle, right posterior-lateral 4th rib, upper lobe of right lung, lower lobe of right lung, right hemidiaphragm and small intestine. A small caliber, non-deformed, full yellow metal jacketed bullet is recovered 46 1/2" above the heel at the midline. Associated injuries include right hemothorax, 250 ml, and aspiration of blood. Direction is superior to inferior, posterior to anterior, right to left.

2. On the right buttock, 31" above the heel, 4" to the right of midline, is round gunshot wound of entrance (gunshot wound E) measuring 0.1" in diameter and associated with a full concentric abrasion collar measuring 0.1" in width. There is no stippling, there is no soot. The wound track perforates skin, soft tissue, and skeletal muscle to exit at the right posterior wall of the vagina at the vestibule at the 7 o'clock position where there is a 0.3" x 0.1" irregular gunshot wound of exit (gunshot wound F) located 32" above the heel, 1/2" to the right of midline. Direction is posterior to anterior, inferior to superior and right to left.

UPPER AND LOWER EXTREMITIES:

1. On the posterior right upper arm, 7" distal to the point of the shoulder, is an oval gunshot wound of entrance (gunshot wound B) measuring 0.3" x 0.2" and associated with an eccentric abrasion collar that measures up to 0.1" in width at the 9 o'clock position. There is no stippling, there is no soot. The wound track perforates skin and soft tissue to exit on the anterior right upper arm, 6 1/2" distal to the point of the shoulder, where there is an irregular gunshot wound of exit (gunshot wound C) measuring 0.4" x 0.3". Direction is posterior to anterior, distal to proximal.
2. On the dorsum of the right hand, 2 1/2" distal to the wrist, is an irregular shotgun wound of entrance (shotgun wound H) measuring 3.3" x 3" with an incomplete abrasion collar and few, scattered individual pellet entries at the wound margins individually measuring 0.1" in diameter. There is no stippling, there is no soot, there is no white granular packing material. The wound track perforates skin, soft tissue, skeletal muscle, vessels and bones of the hand to exit on the palmar surface of the right hand, 1 1/2" distal to the wrist, where there is an irregular shotgun wound of exit (shotgun wound I) measuring 4.4" x 1.9". Direction is posterior to anterior, distal to proximal.
3. On the right heel is a yellow-tan abrasion, 0.5".

DISPOSITION OF CLOTHING AND PERSONAL EFFECTS

The following items are preserved as evidence

Tee shirt, sweatpants, athletic shoes, wristband on left wrist, necklace, pellets and plastic shot cup from head, pellets from right hand, bullet from torso, bullet from head, hair from right hand, blood card and a sexual assault kit containing oral smears and swabs, pubic hair combings, vaginal smears and swabs, rectal smears and swabs, pulled pubic hair, pulled head hair, known blood sample and known cheek scrapings are submitted to Johnnie Britt of the Chapel Hill Police Dept. on March 5, 2008 at 1:47 pm.

PROCEDURES

Radiographs

Obtained

Chemistry

Aortic blood, inferior vena cava blood, liver and gastric contents are retained for toxicologic analysis.

Identification

The body is identified by comparison of antemortem photographs and known medical conditions including scoliosis.

Special Evidence Collection

Sexual assault kit and fingerprints are collected.

INTERNAL EXAMINATION

Body Cavities

There is 250 ml of blood within the right pleural cavity. The left pleural cavity, peritoneal cavity and pericardium contain no significant fluid. There are no adhesions. All body organs are present and in their usual anatomic position.

Cardiovascular System

Heart Weight 270 grams

The pericardial sac is free of significant fluid and adhesions. The coronary arteries arise normally, follow the usual distribution and are widely patent without evidence of significant atherosclerosis or thrombosis. The chambers and valves bear the usual size-position relationships and are unremarkable. The myocardium shows no evidence of infarction, scarring or focal lesions. The aorta and its major branches are intact without significant atherosclerosis.

Respiratory System

Right Lung Weight 190 grams

Left Lung Weight 260 grams

The upper and lower airways are free of debris and foreign material. There is a gunshot wound injury of the right lung as described previously in the evidence of injury section of this report. The right lung displays atelectasis, the left lung displays minimal edema. There is mild to moderate aspiration of blood bilaterally. There is no obvious consolidation or focal lesions. The pulmonary arteries are free of thrombi or emboli.

Gastrointestinal System

There is gunshot wound injury of the proximal small intestine as described previously in the evidence of injury section of this report. Otherwise, the GI tract is intact throughout its length. There is a small Meckel's diverticulum. The appendix is present. The stomach contains approximately 100 ml of partially digested food including kidney beans.

Liver

Liver Weight 1060 grams

The capsule is intact and the parenchyma is unremarkable. The gallbladder contains approximately 10 ml of yellow, slightly mucoid bile and the extrahepatic biliary tree is patent.

Spleen

Spleen Weight 90 grams

The spleen is normally formed. No focal lesions are present.

Pancreas

Normal size, shape and consistency without focal lesions.

Urinary

Right Kidney Weight 100 grams

Left Kidney Weight 100 grams

The kidneys are of normal size and shape. The capsules strip with ease from the underlying smooth pale tan firm cortical surfaces. The renal architecture is intact without focal lesions. The ureters are intact. The urinary bladder is empty.

Reproductive

The uterus, cervix, fallopian tubes and ovaries are unremarkable. There is an exit gunshot wound injury of the vagina at the vestibule as described previously in the evidence of injury section of this report.

Endocrine

The thyroid gland and adrenal glands are grossly unremarkable.

Neurologic

Brain Weight 1360 grams

There is a shotgun wound injury of the brain as described previously in the evidence of injury section of this report associated with thin bilateral subdural hematomas, subarachnoid hemorrhage and a lacerated hemorrhagic wound track involving the right inferior frontal lobe, right temporal lobe, pons and cerebellum. Aside from these injuries the brain is grossly unremarkable.

Skin

Grossly unremarkable.

Immunologic System

Grossly unremarkable.

Musculoskeletal System

There is moderate scoliosis of the thoracic and lumbar spine. There are gunshot wound and shotgun wound injuries as described previously in the evidence of injury section of this report.

MICROSCOPIC EXAMINATION

Cardiovascular

The epicardium and endocardium, where seen, are architecturally unremarkable. The myocytes are robust and uniform in size and nuclear staining quality. There is no inflammation. There is no increased fibrosis.

Respiratory

Sections of right and left lung are similar and display patchy areas of intra-alveolar hemorrhage.

Liver

The hepatic architecture is unremarkable. The portal triads contain the usual complement of bile duct, artery and vein and a mild mixed inflammatory infiltrate that focally extends beyond the limiting plate and is not associated with hepatocyte necrosis.

Hematologic

The subcapsular area and cortex are unremarkable. The glomeruli are intact overall. The proximal tubules are patent. The vasculature is unremarkable.

Neurologic

A section of cortex displays contusions and subarachnoid hemorrhage.

SUMMARY AND INTERPRETATION

The decedent was a 22-year-old woman who was shot multiple times.

Significant findings at autopsy include multiple gunshot wounds. There is a perforating shotgun wound of the right hand and an irregularly abraded shotgun wound of the head with injury to the skull and brain and recovery of birdshot pellets and a plastic shot cup. These wounds most likely represent a single shot with the hand acting as an intermediate target. There is a gunshot wound of the head with injury to the teeth, maxilla and maxillary sinus and recovery of a bullet. There is a gunshot wound of the right shoulder with injury to a rib, right lung, diaphragm and small intestine and recovery of a bullet. There is a perforating gunshot wound of the buttocks. There is a perforating gunshot wound of the right upper arm and there is an abrasion on the right ankle.

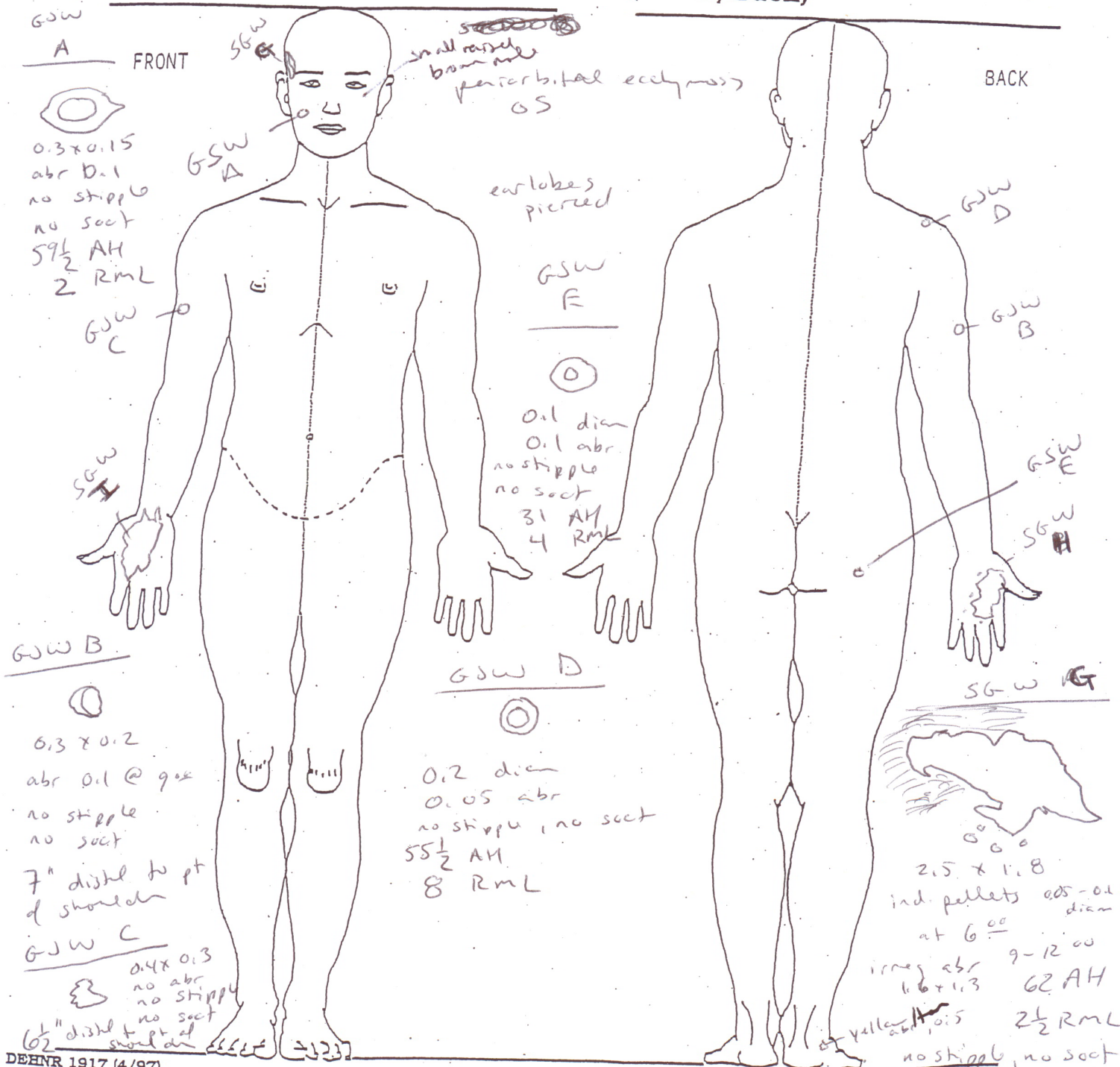
Postmortem toxicology studies revealed no alcohol in aortic blood.

Given the investigative and autopsy findings it is my opinion that the cause of death for Eve Marie Carson was due to multiple gunshot wounds.

DIAGRAMS

1. Adult (front/back)
2. Skull & scalp
3. Female perineum
4. Hands

BODY DIAGRAM: ADULT (Front/Back)



DEENR 1917 (4/97)
Medical Examiner

This form may be photocopied.

State of North Carolina

Name of Decedent: _____

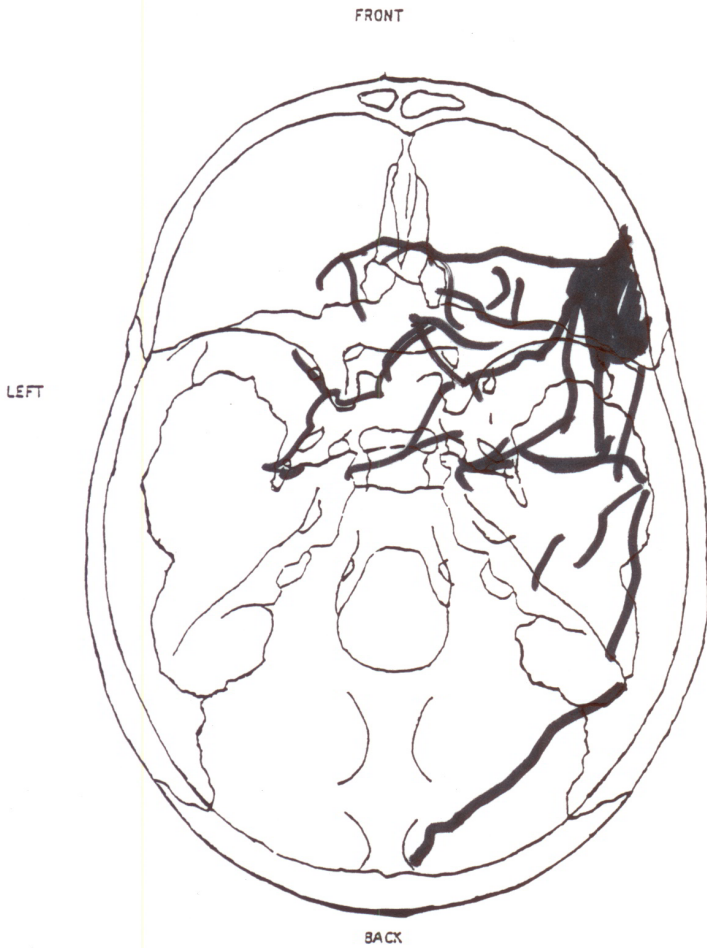
Office of the Chief Medical Examiner

Autopsy # B08-1036

Chapel Hill, North Carolina 27599-7580

Examined By: Gard Date: 5mar08

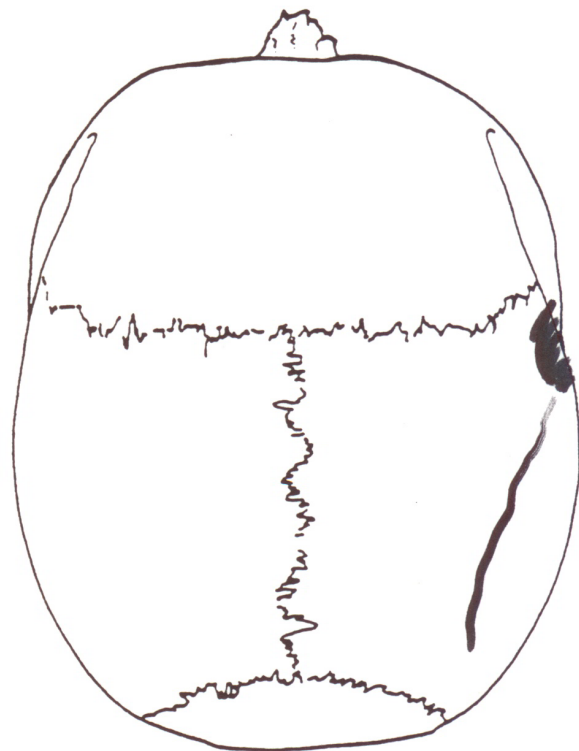
BODY DIAGRAM: SKULL & SCALP (top)



*Internal bevel fracture
R temporal*

*diastotic fx
lamboid suture*

RIGHT



DHHS 1922 (4/97)
Medical Examiner

This form may be photocopied.

PAGE ___ OF ___

State of North Carolina

Name of Decedent: _____

Office of the Chief Medical Examiner

Autopsy # BOB-1036

Chapel Hill, North Carolina 27599-7580

Examined By: Gardner Date: 5 Mar 08

BODY DIAGRAM: FEMALE PERINEUM

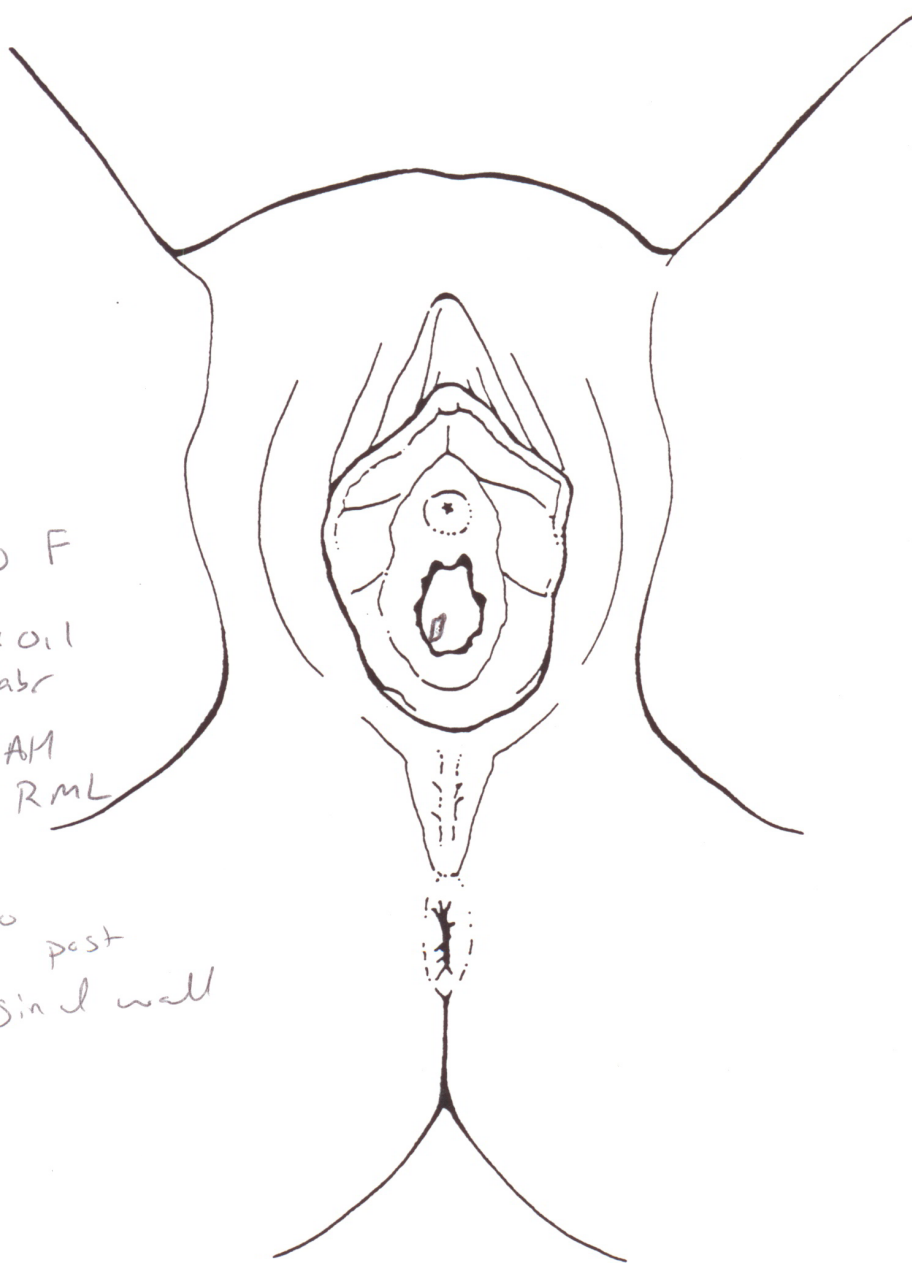
GJW F

6.3 x 0.1
no abr

32 AM

1/2 RML

@ 700 post
vaginal wall

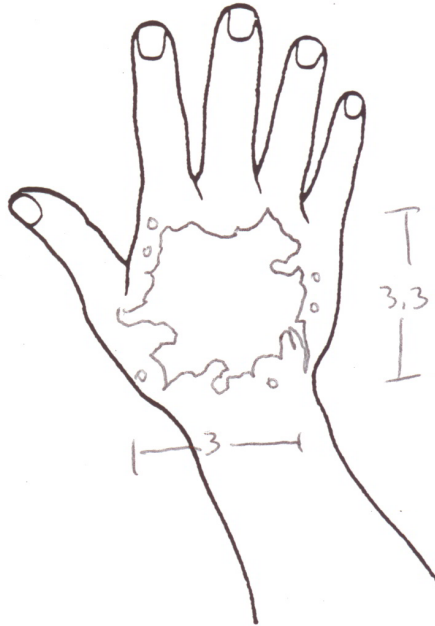
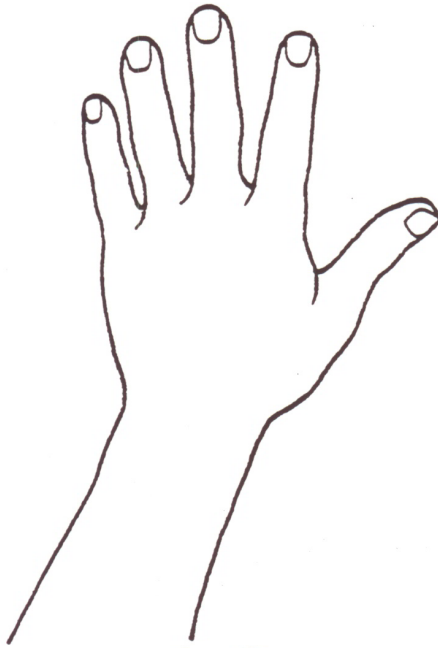


OCME-006 (4/97)
Medical Examiner

This form may be photocopied.

PAGE ____ OF ____

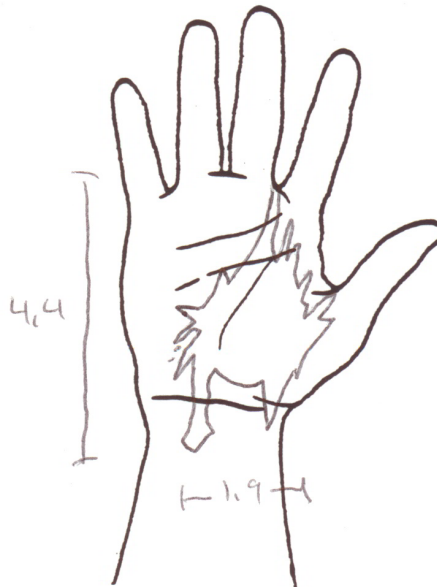
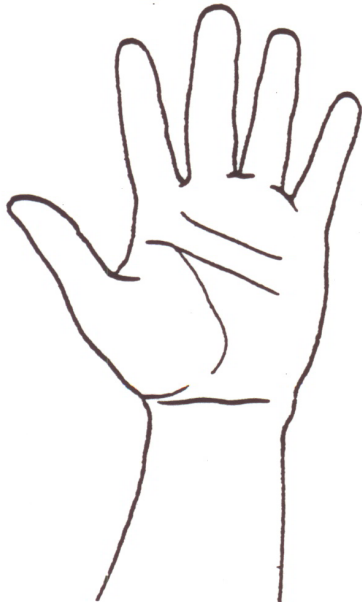
BODY DIAGRAM: HANDS



SGW I

no stibble
no soot
incomplete
abr
md. pellet
entres
at di-
at margin

2 1/2 dist to
wrist



SGW II

no stibble
no soot
no abr

1 1/2 dist to
wrist