

Focal autobiographical amnesia in association with transient epileptic amnesia

Facundo Manes,^{1,2} John R. Hodges,^{1,2} Kim S. Graham² and Adam Zeman³

¹University of Cambridge Neurology Unit, Addenbrooke's Hospital, ²MRC Cognition and Brain Sciences Unit, Cambridge and ³Department of Clinical Neurosciences, University of Edinburgh, Western General Hospital, Edinburgh, UK

Correspondence to: Professor John R. Hodges, MRC Cognition and Brain Sciences Unit, 15 Chaucer Road, Cambridge CB2 2EF, UK
E-mail: john.hodges@mrc-cbu.cam.ac.uk

Summary

Although problems with remembering significant events from the past (e.g. holidays, weddings, etc.) have been reported previously in patients with transient epileptic amnesia (TEA), to date there have been no detailed studies of autobiographical memory in patients with this disorder. To investigate this issue, a 68-year-old right-handed man (R.G.) who suffered from TEA and reported significant autobiographical memory problems was tested on a battery of neuropsychological tests of anterograde and remote memory. Tests of autobiographical memory revealed that R.G. was unable to evoke detailed autobiographical recollections from a substantial part of

his life. By contrast, he performed well on tests of new learning and general knowledge and possessed good personal semantic information about his past. In summary, a distinct form of autobiographical amnesia, which is characterized by loss of experiential remembering of significant events, may be associated with TEA. It is proposed that the autobiographical memory deficit seen in the disorder may result from the progressive erasure of cortically based memory representations. This case adds to growing evidence for a dissociation between mechanisms subserving anterograde memory and those required to evoke remote episodic memories.

Keywords: transient epileptic amnesia; autobiographical memory

Abbreviations: TEA = transient epileptic amnesia; WAIS-R = Wechsler Adult Intelligence Scale—Revised

Introduction

Transient epileptic amnesia (TEA) is a recently described condition in which temporal lobe epilepsy manifests as episodes of amnesia, often without other cognitive or ictal phenomena (Kapur, 1993a; Kopelman *et al.*, 1994; Zeman *et al.*, 1998). The main characteristics of TEA are as follows: (i) recurrent episodes of sudden memory loss which are usually brief in duration (typically <1 h); (ii) the occurrence of amnesic episodes on waking from a period of sleep; (iii) a disproportionately severe retrograde component of some attacks, so that patients may 'remember not being able to remember'; (iv) evidence of inter-ictal EEG abnormality in the temporal lobe; and (v) the reduction or cessation of amnesic episodes by the introduction of antiepileptic medication.

In a recent study, seven out of 10 patients with TEA complained of a distinctive and unusual variety of persistent amnesia for salient life events. This amnesia amounted to a partial, but substantial, depletion of the patients' stock of autobiographical recollections (Zeman *et al.*, 1998). In five of these patients the retrograde amnesia affected their recall

for periods of their lives preceding the clinical onset of epilepsy, sometimes by as much as 30 years. Their amnesia often became evident when looking at holiday albums or discussing other highly salient life events with family members. These difficulties with remote memory contrasted with the patients' normal performance on standard anterograde memory tests. Despite the symptoms of remote memory loss, the patients performed well on tests of famous faces and events, suggesting that the deficit might selectively affect autobiographical memory.

Although Zeman and colleagues' study strongly suggested that patients with TEA may show evidence of a 'focal retrograde amnesia' (Zeman *et al.*, 1998), to date there have been no detailed investigations focusing on autobiographical memory in patients with TEA. The aim of this study, therefore, was to redress this imbalance in the literature and to investigate the following questions: (i) could our patient's complaints of poor autobiographical memory be substantiated using various standard and tailor-made tests of personal memory; and (ii) would any deficit in remote memory extend beyond the domain of autobiographical memory?

Case report

Background

The patient, R.G., a 68-year-old right-handed man (Patient 3 in Zeman *et al.*, 1998), was referred in 1994 after several amnesic attacks. He had left school at the age of 14 years without qualifications and trained as an engineer in the Royal Air Force during the Second World War. Subsequently, he spent most of his working life as a maintenance engineer for a roller bearing manufacturer. He married in 1946 and had four sons and three daughters over the next 20 years. For many years, the family lived in a house belonging to R.G.'s employer, although R.G. and his family moved to a new home in the same area a few months before R.G.'s referral to the clinic. Holidays and celebrations of anniversaries, etc. were well represented in the family photograph album.

R.G.'s medical history included myocardial infarctions in 1985 and 1987, from which he had made a good recovery. At the time of referral he was taking aspirin and isosorbide mononitrate. He smoked occasionally and drank little alcohol. He could give some account of the events detailed below, but his wife had recorded them in her diary, and we therefore relied mainly on her record of her husband's symptoms. His wife and family confirmed that they had noticed no problems with R.G.'s anterograde and remote memory until the onset of amnesic episodes in 1994.

Clinical history

Four months before his first attendance at the clinic, R.G. had appeared abnormally 'detached' one morning. He was unsure where he was, and unable to recognize a visitor to the house, who was in fact his 45-year-old son. R.G. recovered over the course of a few hours, but has never been able to recall the events of the 3 days preceding this event, which included a dance and a trip to a town nearby. A month later he told his wife one morning that he did not know who she was or where they were. She walked him round their house and into the conservatory, which he had built recently but which he found unfamiliar. He continued to treat his wife as a stranger during most of that day. They paid a visit to another nearby town on the following day. Although R.G. behaved normally during the trip, he has never been able to recall any details relating to this day out. A few days later he had a further amnesic episode, again failing to recognize his son. His wife found him in tears shortly afterwards, saying 'I can't remember anything, it feels horrible'. On this occasion he was able to recognize her, but unable to recognize their new bungalow or the events of the previous day. After negative routine investigations, a diagnosis of transient ischaemic attacks was proposed and R.G. was treated with warfarin.

R.G. had two further attacks 3 and 5 months later. The first was principally amnesic, with failure to recognize a number of family members, including his wife. In the second episode he had more widespread cognitive difficulties. On

waking he complained that he 'could not remember anything'. A few minutes later his wife found him in his pyjamas in the living room, unsure what he was doing. He was unable to dress himself when his wife gave him his clothes. Soon after this he slept for a number of hours, and woke fully recovered. In addition to these amnesic attacks, he had complained on several occasions of a 'smell or taste', familiar from his work as an engineer, which was present almost constantly for several months. His wife also reported that on a number of occasions he had appeared very distant, 'as if he switches off' and 'as if he is looking from somewhere else'.

A detailed psychiatric interview by a consultant psychiatrist on October 5, 1995 revealed no evidence of psychiatric illness. The patient had no family history of psychiatric disorders.

On the basis of the clinical history, which was suggestive of TEA and complex partial amnesic seizures, and taking into account the EEG findings (described below) R.G.'s diagnosis was revised to epilepsy. He was treated with sodium valproate, which abolished the episodes for 2 years. Latterly, however, his amnesic episodes and complex partial seizures recurred, necessitating the addition of topiramate. He died suddenly on November 2, 1999 from rupture of an abdominal aortic aneurysm. Post-mortem brain examination was not performed.

Since the onset of his attacks, R.G. had become aware of persistent gaps in his memory, extending many years into his past. His wife had been particularly struck by these as R.G.'s memory had previously been very reliable. As she said, 'he would always correct me'. Some of these gaps had come to light when they looked at old photographs together. The family had made annual expeditions to Portugal, Spain or Yugoslavia for about 30 years. R.G. had lost all recollection of many of the places they had visited together, and had forgotten a number of salient holiday episodes that he and his wife had commemorated with photographs and had reminisced about together in the past. His memory for more recent trips was also affected. He had, for example, made three visits to Lincoln in recent years, but when he and his wife travelled to Lincoln market, at around the time of the fourth attack described above, R.G. failed to recall any previous trips. Finally, before he was banned from driving, R.G. had noticed that it was more difficult than he would have expected to find his way on familiar routes, and he had failed to recognize landmarks that had previously been well known to him.

A CT scan of the brain performed in 1994 was normal. A high-resolution 3D acquisition MRI scan in 1997 showed a number of peripheral high-signal lesions in the white matter that were likely to be of ischaemic origin, but the temporal lobes, including the hippocampi, appeared normal. EEG investigations found evidence of abnormal activity: an awake standard 12-lead EEG revealed sharpened theta activity in both temporal lobes, and a drug-induced sleep EEG showed undoubted independent bilateral sharp-wave abnormalities,

Table 1 Neuropsychological test results for R.G. from September 1994, April 1995 and February 1999

Test	Date of test		
	September 1994	April 1995	February 1999
Full-scale IQ (WAIS-R)	120	112	112
Age-scaled score			
Verbal subtests			
Digit span	13	13	12
Vocabulary	10	9	–
Arithmetic		12	10
Similarities	14	10	12
Performance subtests			
Block design	15	16	11
Picture completion	–	–	14
Digit symbol	–	–	9
GNT (30)	23	–	22
VOSP Unusual Views (20)	19	–	19
WCST Categories (6)	6	–	6

WAIS-R = Wechsler Adult Intelligence Scale—Revised (Wechsler, 1981); GNT = Graded Naming Test (McKenna and Warrington, 1983), VOSP = Visual Object and Space Perception Battery (Warrington and James, 1991); WCST = Wisconsin Card Sorting Test (Nelson, 1976); – = not tested.

referable to the anterior or mid-temporal lobes. A 24 h EEG, undertaken while R.G. was on treatment, was normal.

In summary, R.G. presented with two distinct varieties of amnesia: transient episodes of predominantly retrograde amnesia and a patchy but persistent amnesia for many salient events from his personal past (and for some details of local geography). The clinical features, EEG findings and R.G.'s positive response to anticonvulsants supported a diagnosis of TEA.

Results

Neuropsychological assessment

A standard psychometric assessment was performed in September 1994, April 1995, and February 1999. The results are summarized in Table 1. On all three occasions, R.G. performed normally on tests of general intelligence, perception and frontal lobe function. The level of measured IQ was commensurate with his estimated premorbid level, as judged by the National Adult Reading Test (Nelson, 1982). Performance on the difficult Graded Naming Test (McKenna and Warrington, 1983) was in keeping with his estimated intellectual level. The scores on the Wechsler Adult Intelligence Scale—Revised (Wechsler, 1987) performance subtests demonstrated that R.G. had normal spatial and constructional capacity [as did his performance on the Unusual Views subtest of the Visual Object and Space Perception Battery (Warrington and James, 1991)]. R.G. also showed above average performance on most of the verbal subtests of the Wechsler Adult Intelligence Scale—Revised (WAIS-R). On the Wisconsin Card Sorting Test (Nelson,

Table 2 R.G.'s performance and that of 24 control subjects (from Hodges and Patterson, 1995) on a battery of semantic memory tests

Test	R.G.	Control mean (SD)
Category fluency		
Living things	45	58.3 (12.3)
Man-made items	52	55.4 (8.6)
Picture naming (48)	46	43.6 (2.3)
Naming to description (24)	22	22.4 (1.3)
Word-picture matching (48)	48	47.4 (1.1)
Pyramids and palm trees (52)	52	51.2 (1.4)

1976), R.G. achieved six categories in both assessments and made five perseverative errors in 1994 and seven in 1999.

The following subtests from the Hodges and Patterson's semantic battery (Hodges and Patterson, 1995) were also administered to R.G.: category fluency for four categories of living and non-living things; naming of highly familiar black-and-white line drawings; naming to description (e.g. 'What do you call the small green animal which leaps around ponds?'); word-picture matching (indicating the zebra out of eight foreign animals); category sorting (sorting pictures and words according to prespecified criteria, such as electrical/non-electrical); a semantic features test (e.g. 'Does an elephant have a trunk?'); and the picture version of the Pyramid and Palm Trees Test (Howard and Patterson, 1992) of semantic association [which of palm tree (target) and fir tree (foil) are most closely associated with pyramid]. R.G. performed normally on all these tests compared with age-matched control subjects (Table 2).

In October 1994 and February 1995, R.G. was tested on a neuropsychological battery designed to assess verbal and non-verbal anterograde recall and recognition memory, and retrograde memory for public and personal events. These tests had been selected for use with a group of patients with TEA to which R.G. belonged (Zeman *et al.*, 1998). The tests used were immediate and delayed story recall from the Wechsler Memory Scale—Revised (Wechsler, 1987), reproduction and delayed recall of the Rey Complex Figure (Osterrieth, 1944), the Recognition Memory Test for words and faces (Warrington, 1984), the 50-item Famous Faces Test and Famous Names Test (Greene and Hodges, 1996), and the Autobiographical Memory Interview (Kopelman *et al.*, 1990). R.G.'s performance was compared with that of 25 control subjects matched for age and education (Zeman *et al.*, 1998).

R.G.'s performance on this battery was entirely normal, apart from a mild but significant degree of verbal recognition memory impairment on the second occasion of testing (Table 3). Given R.G.'s complaints about his autobiographical memory, amply confirmed by the tests described below, it is noteworthy that his scores on the Autobiographical Memory Interview were normal compared with the control group.

Table 3 Performance of R.G. and 25 control subjects (from Zeman et al., 1998) on a battery of anterograde and retrograde memory tests

Test	R.G.			Control mean (SD)
	October 1994	February 1995	February 1999	
Anterograde memory tests				
Story Recall (WMS-R)				
Immediate (21)	14	12	11	12 (4)
Delayed (21)	11	8	8.5	9 (3)
Rey Figure				
Immediate (36)	35	36	30	34 (3)
Delayed (36)	26	26	19	15 (8)
Recognition Memory				
Words (50)	41	37	40	47 (3)
Faces (50)	45	41	41	44 (4)
Retrograde memory tests				
Famous Faces				
Recognition (50)	49	49	—	43 (7)
Naming (50)	36	29	—	31 (4)
Identification (50)	47	45	—	39 (9)
Famous Names				
Recognition (50)	50	50	—	50 (1)
Identification (50)	49	49	—	49 (1)
AMI Personal Semantic				
Childhood (21)	21	21	—	20 (2)
Early adulthood (21)	21	20.5	—	20 (2)
Recent life (21)	20	17	—	20 (2)
AMI Personal Incident				
Childhood (9)	8	9	—	7 (2)
Early adulthood (9)	9	5	—	8 (2)
Recent life (9)	8	6	—	7 (2)

WMS-R = Wechsler Memory Scale—Revised (Wechsler, 1987); Rey Figure (Osterrieth, 1944); Recognition Memory Test (Warrington, 1984); Famous Faces and Names Test (Greene and Hodges, 1996); AMI = Autobiographical Memory Interview (Kopelman *et al.*, 1990).

Further autobiographical memory tests

As R.G. complained particularly of loss of autobiographical information, we used a number of methods to investigate his self-report of autobiographical amnesia.

Free recall

During an extended interview on October 2, 1995, R.G. was asked to give an unconstrained outline of his autobiography, with the opportunity to reminisce freely as he did so. During a 90 min interview (which was recorded and transcribed), R.G. sketched the key events of his past life. He had no difficulty in providing an outline of the main events of his first decade, with detailed information about the houses in which he had lived and the schools he had attended. He had an apparently vivid recollection of falling onto a fire and burning his hands at the age of 5 years. He gave equally vivid accounts of events from his teens, twenties and early thirties, including episodes from his first jobs, National Service, his marriage and the birth of his first five children. He described these years as falling in the 'area which I can recognize and remember'. He felt that there were 'no memory

gaps' in this period. As R.G. recalled the events of his forties (from the mid-1960s), he experienced increasing difficulty in evoking memories of the time. Thus, although he knew that his first holiday abroad and the weddings of three of his children fell in this decade, he could not remember any details of the foreign trip or imagine himself at the weddings. He had noticed this himself, as he often passed the buildings in which two of the wedding receptions had taken place, and had realized that he had lost his previous recollection of the events. He had even greater difficulty in recalling events from his fifties. He knew that he had visited Portugal and Yugoslavia repeatedly during this decade but said that he could remember no details of these trips: 'they are basically blanks'. Although his memory for events of the most recent decade prior to the onset of his illness was by no means normal, he was able to recall a few episodes from this period with the normal experiential quality of autobiographical memory, e.g. he could remember his glasses being taped on his nose so that he could watch his cardiac catheterization 7 years before. His recall of events from the previous few months was especially patchy. He could, for example, recall deciding that the ceiling of his new bungalow required a

particular type of treatment, but had no recollection of the treatment being applied.

In summary, R.G.'s free recall suggested a severely depleted stock of episodic memories from the past 25 years. Many earlier recollections were preserved, and he retained a grasp of the broad outline of his subsequent life history and of the details of occasional salient events from the past 25 years, especially recent ones.

Family tree

On this same occasion, we asked R.G. to construct a family tree, including the names and ages of his children and grandchildren. Independently, we asked R.G.'s wife to corroborate his account. He has six living children, 11 grandchildren and two great-grandchildren. R.G. could name all his children, nine of the 11 grandchildren and one of the two great-grandchildren. He knew the occupations of his children and their spouses, and gave accurate estimates of his grandchildren's ages. He supplied substantial amounts of accurate information about the families of his own brother and sister and of his wife's siblings. This information had clearly been updated regularly in recent times, suggesting that R.G.'s 'personal semantics' were better preserved than his stock of episodic memories for the past 25 years.

Family photographs

In April 1995 we tested R.G. using 31 family photographs obtained from his wife. The photographs depicted events and people from three periods of his life (1940–69, $n = 9$; 1970–89, $n = 11$; 1990s, $n = 11$). We presented these photographs one at a time in random order and asked R.G. to tell us who was shown in the photograph, and where and when it had been taken. 'Who' responses were scored as correct if R.G. could correctly name at least one person in the photograph in addition to his wife and himself, 'where' responses if he could name the correct location, and 'when' responses if he gave the correct date ± 5 years. On several occasions during this test session, R.G. spontaneously commented that certain photographs aroused absolutely no recollection whatsoever: we pursued this observation systematically in the follow-up study as described below.

Family photographs: follow-up study

In October 1995 we re-presented the same series of photographs, repeating the 'who', 'where' and 'when' questions that we had asked previously. In addition, following up R.G.'s spontaneous remarks in April 1995, we asked him to tell us whether he could specifically remember the occasion on which the photograph had been taken or whether he was using clues embedded in the photo to infer information about it (e.g. if someone was wearing morning dress, the occasion must have been a wedding). To gain more insight into this aspect of R.G.'s autobiographical recall, we asked him to

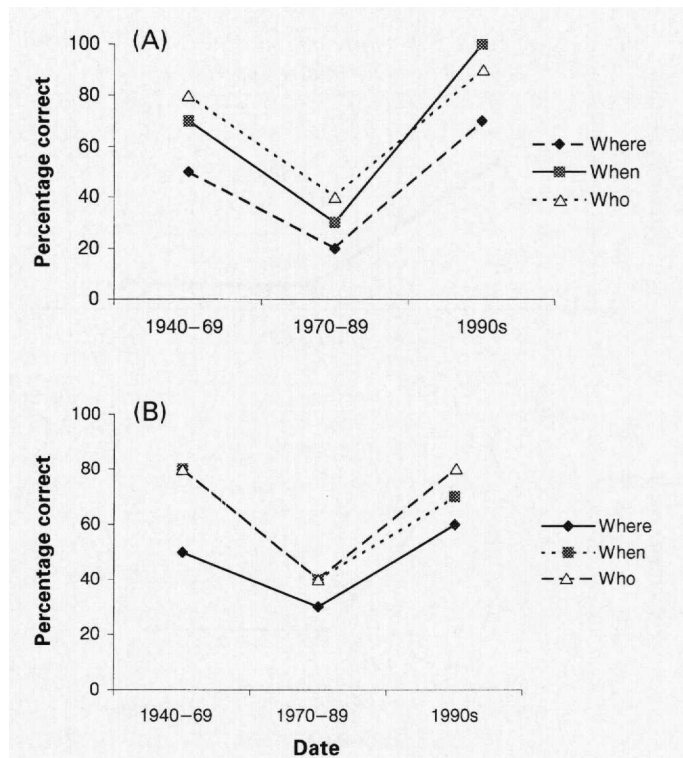


Fig. 1 R.G.'s performance on the family photographs test in (A) April 1995 and (B) October 1995. R.G. was asked to produce information about who was shown in the photograph and where and when it had been taken. Responses were scored as correct for 'who' information if he could name one person in the photograph other than himself and his wife, for 'where' information if he could produce information about the location of the photograph, and for 'when' information if he produced the correct date of the photograph ± 5 years.

recall a distinctive episode associated with the photographs for which he could give at least two correct items of 'who', 'where' and 'when' information (e.g. 'Can you tell us a little story about something that happened at the wedding?'). These episodes were scored out of 3 for specificity and richness of detail [as in the Autobiographical Memory Interview (Kopelman *et al.*, 1990)]. A score of 3 indicated a detailed episode specific in time and place, a score of 2 a less detailed time-specific episode or one in which the exact time and place were not recalled, and a score of 1 a vague memory, specific in neither time nor detail.

R.G.'s responses in these family photograph tests were consistent across the two testing sessions (Fig. 1A, April 1995; Fig. 1B, October 1995) and bore out his view that his memory for episodes from his middle years (1970–89) had been particularly severely affected. In this middle period, his responses were especially poor for photographs of foreign holidays.

The follow-up study revealed that R.G. was inferring information from the photos, rather than remembering the occasions depicted, and that he was unable to supply rich, associated episodic detail for the photos that he could accurately locate in terms of time, place and the identities of those present (Fig. 2A). Verbal descriptions of the

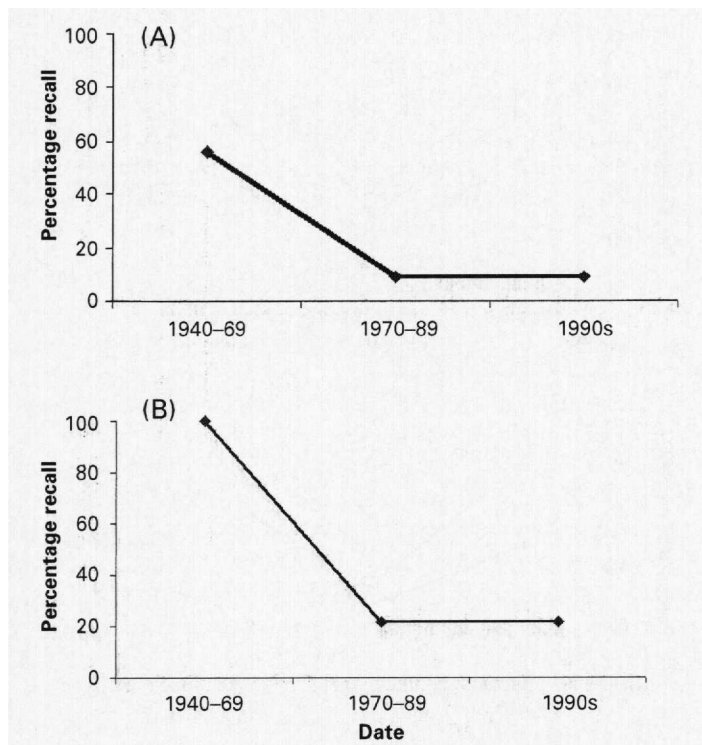


Fig. 2 (A) R.G.'s performance on the recall component of the family photographs test, in which he was asked to retrieve specific details associated with the portrayed event in October 1995. R.G.'s responses were scored out of 3 for specificity and detail. (B) R.G.'s performance on recall of details of his autobiographical history when given a verbal description (e.g. 'the aircraft recovery team'). R.G.'s responses were scored as correct if he recognized and supplied some details about the episode.

photographs that he failed to recognize did not (with one exception) help him to recover memories of the relevant occasions. Figure 2A also shows that R.G.'s difficulties extended to his most recent memories (from the 1990s), despite the fact that he performed as well with respect to this period as with respect to the 1940-69 period when asked to produce two pieces of 'where', 'when' and 'who' information. R.G. was virtually unable to produce any detailed episodic information for any of the photographs taken in the 1990s or for the period 1970-89. In summary, therefore, R.G. showed problems with autobiographical retrieval from the 1970s onwards and some impairment, albeit milder, of his memories from 1940-69.

Personal events

With the help of R.G.'s wife, we identified 12 further personal episodes (1940-69, $n = 4$; 1970-89, $n = 4$; 1990s, $n = 4$) that were not depicted in the photographs, and prompted R.G. with a succinct description of each (e.g. 'the aircraft recovery team' was the prompt for R.G.'s work in the late 1940s when he travelled the country salvaging parts from wrecked aircraft). R.G.'s responses were scored as correct (score 1) if he could recognize and supply some details about the episode and 0 if he could not. If he could come up with

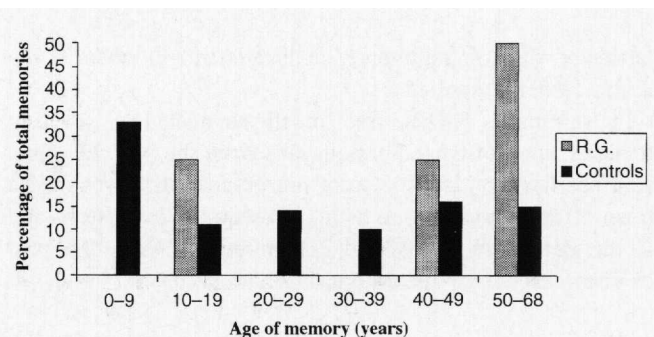


Fig. 3 Comparison of the memories produced by R.G. and controls (Evans *et al.*, 1996) on the modified Crovitz test. The figure shows the age of memories by decades as a proportion of the total memories produced.

some information about the event in question, he was asked to date the episode. This test was administered in October 1995. The results are shown in Fig. 2B. R.G. showed good recall of events from the period 1940-69 but poor recall for events from 1970 onwards. He was able to date all the events he recognized to the correct decade.

The modified Galton-Crovitz test (Galton, 1879; Crovitz, 1974)

A modified version of the Galton-Crovitz technique (Crovitz and Schiffman, 1974), based on that described by Hodges and Ward (Hodges and Ward, 1989), was used with R.G. in April 1995. The patient was given 10 high-frequency nouns (e.g. bird, boy, car, tree, clock) and asked to produce a detailed and specific autobiographical memory from any period in response to each word. Once he had recalled a memory, he was asked to estimate the date of the episode he had described. A practice item was given before the test list. R.G. was given up to 4 min to respond. During the first 2 min the experimenter provided non-specific prompts (e.g. 'Tell me more'). If after 2 min no episode was produced by R.G., the experimenter cued him by suggesting more concrete possibilities involving the target word (e.g. 'Have you ever been in a boat?'). The autobiographical episodes produced by the patient were scored for both detail and episodic specificity using a 0-3 rating scale described previously by Hodges and Ward (Hodges and Ward, 1989). R.G. was able to provide memories in response to eight of the 10 cue-words, and he scored a total of 21 out of 30 [control score ($n = 41$) = 28.3, SD = 1.9 (Evans *et al.* 1996)]. R.G.'s score, therefore, placed him more than 3 SD from the control mean. Although this score is not indicative of a severe autobiographical memory deficit—in general, R.G. received a good score for most of the eight memories he produced—Fig. 3 [which shows the age of memories by decade as a proportion of the total memories produced for both R.G. and control subjects (Evans *et al.*, 1996)] reveals that R.G. showed patchy recall of memories from the last 40 years. The only memories he produced during this time were from when he was aged 50-59 years: an incident at the age of

55 years when he injured his arm with a hydraulic jack and a memory from a year earlier when he watched the progress of a satellite in the night sky. The pattern on this test, therefore, replicates that demonstrated in the family photograph study: poor experiential recall of personal episodes for ~30 years prior to testing, with good retrieval of autobiographical events from earlier in R.G.'s life.

Further retrograde memory tests

Famous events

We supplemented the Famous Faces Test and Famous Names Test, which we had administered previously as part of the memory battery, with two further tests of knowledge about current events. The first Famous Events Test (for details and control data see Hodges and Ward, 1989; Evans *et al.*, 1996) consisted of a list of 50 famous events from the 1930s to the 1970s, randomly interspersed with 50 false event names. R.G. was asked to indicate whether each item was a real event and, for those events that he reported to be real, to say in which decade he thought the event took place. The second event test, the Famous Events Photographs test, required the identification and dating of a series of 25 photographs of very famous events (e.g. Queen Elizabeth II's coronation, Neil Armstrong on the moon) that had occurred every 2 years between 1945 and 1994 (Kitchener *et al.*, 1999).

In the Famous Events test, R.G. correctly identified 77% of the real events [control mean = 82%, SD = 14.9 (Evans *et al.*, 1996)] and mistakenly endorsed 14% of the false events. Although he was less accurate than control subjects, at least as measured by his hits minus false alarm score (R.G. = 62%; control mean = 76.4%, SD = 13.3), this performance was not impaired (i.e. it was not 2 SDs or more below the control mean). Thirty-three per cent of the events were placed in the correct decade [control subjects = 50.28, SD = 16.8 (Evans *et al.*, 1996)].

In the Famous Events Photographs test (Kitchener *et al.*, 1999), R.G. provided accurate or approximately accurate information for 19 out of 25 of the photographs, although he was only able to date 8 out of 25 of these to within 5 years. Control subjects identified 22 ± 1.6 events correctly (for details, see Kitchener *et al.*, 1999). Overall, therefore, R.G. showed no significant impairment in knowledge of famous events, although his performance was at the lower end of the control mean on both tests. He also exhibited a mild problem with the dating of events (e.g. dating President Kennedy's assassination to 1978 and the release of the hostage John McCarthy to 1976), although it is unclear whether this was to a greater extent than we would see in control subjects.

Current events

R.G. was asked informally about his knowledge of some recent current events. R.G. took an interest in current events

and would often discuss these. His recall for recent events was impressive. For example, he said of the O. J. Simpson trial, for which the verdict had been announced recently: 'found not guilty, everyone says that he was guilty of murdering wife and boyfriend and there is lots of shouting about American justice. The jury contained nine blacks, two whites, one Hispanic, the case ran for 280 days on television. O.J. is a footballer, a national hero'.

Famous places

In October 1995 we also administered verbal and visual versions of the Famous Buildings and Landmarks Test. The verbal version of the test requires the subject to give as much information as possible about a series of famous buildings and landmarks, including where in the world the famous building is found ('location') when given the verbal label (e.g. Eiffel Tower). In the visual version, the subject is asked to name the building or landmark from a photograph and then to describe the location.

On the verbal version of the test, R.G. correctly located 21 out of 25 of the buildings in their town and/or country. Further accurate information was supplied for 20 out of 21 of these buildings, and about one further building that he had located incorrectly. Visual details were supplied for 17 of these (e.g. the Eiffel Tower is 'very high, square at the base and tapering to a pinnacle'; Sydney Opera House is 'a modern construction, with a series of faces off the bay's edge'). In the visual version of the test, R.G. named 14 out of 25 correctly, identifying the correct country for 20 out of 25 buildings. These results are within the normal range (Evans *et al.*, 1995).

Discussion

The nature of R.G.'s amnesia

R.G. complained spontaneously that he had 'lost' his memory for most of the events of his middle and recent life. Like other TEA patients (Kapur, 1993a; Zeman *et al.*, 1998), R.G.'s retrograde amnesia came to light when discussing past holidays. This, presumably, does not reflect any selective vulnerability of memory for holidays, but rather the fact that holidays provide, for many people, a major source of recurrent yet unique events. On a range of more stringent tests of autobiographical memory, there was clear evidence that R.G.'s description of the problem was accurate. In free recall he was able to supply a rich account of the chronology and events of his first 30 years, but no more than an outline of the major events of his subsequent life: he could retrieve very few truly episodic memories from this latter period. Accordingly, with rare exceptions, family photographs from these years failed to evoke any recollection of the episodes depicted. R.G. tended to identify these episodes on the basis of clues such as dress, and his knowledge of the 'bare bones' of events that had affected his family. Verbal descriptions of

events from this period also failed to trigger normal episodic recollection. On the Crovitz test of cued autobiographical recall, he produced specific memories from his early life until age 30 years, but few from his later adult years.

Personalized tests like those used in this study cannot, by their nature, be compared with normative data on conventional lines. Our interpretation of them is bound to rely partly on the testimony of R.G. and his wife that he was previously familiar with these photographs and events, and that they would once have evoked normal 'experiential' memories. Accepting this limitation, several lines of evidence converge on the conclusion that R.G. suffered from severe but time-limited amnesia for autobiographical episodes. In contrast, R.G.'s outline knowledge of the major events in his life, often described as 'personal semantics', appeared relatively intact. He also performed normally on standard tests of anterograde memory, with one minor exception, and he showed no significant deficit on tests tapping retrograde memory for people and public events.

In conclusion, the core of R.G.'s amnesic syndrome appears to have been an inability to evoke autobiographical recollections from a substantial part of his life, in particular from his forties onwards. This inability was not absolute, as occasional episodes from his more recent life remained accessible, and R.G. reported that episodic memories from his earlier life retained a normal experiential quality. These difficulties contrast with the relative preservation of R.G.'s anterograde memory, of personal semantic knowledge about his past life and of general knowledge about the world.

The mechanism of R.G.'s focal autobiographical amnesia

There is converging evidence from neuropsychological and neuroimaging studies that areas in the temporal and frontal lobes are involved critically in the retrieval of long-term memories (Kapur, 1993b; Markowitsch *et al.*, 1993; Hunkin *et al.*, 1995; Calabrese *et al.*, 1996; Fink *et al.*, 1996; Parkin, 1996; Reinvang and Gjerstad, 1998; Conway *et al.*, 1999; Maguire and Mummery, 1999; Tanaka *et al.*, 1999). More specifically, medial temporal lobe structures (e.g. the hippocampus, subiculum and parahippocampal complex) are thought to play a critical role in both new learning and the storage of recent experiences, while neocortical regions are considered the permanent repository for autobiographical and semantic memories (Alvarez and Squire, 1994; McClelland *et al.*, 1995; Murre, 1996; Graham and Hodges, 1997). Thus, patients with lesions confined to the hippocampal complex show impairments in new learning, both for recently experienced events and for factual information, yet are able to retrieve memories acquired many years (i.e. 20–30 years) before (Scoville and Milner, 1957; Zola-Morgan *et al.*, 1990; Kapur and Brooks, 1999; but see Nadel and Moscovitch, 1997). By contrast, patients with selective neocortical damage (to either temporal lobe regions or frontal areas) show

deficits in the retrieval of semantic and/or autobiographical information, but may be capable of new learning (Kapur, 1993b; Graham and Hodges, 1997; Levine *et al.*, 1998; Rubin and Greenberg, 1998; Graham *et al.*, 1999; Evans *et al.*, 2001).

There is a range of cognitive explanations, therefore, that can be proposed for acquired autobiographical amnesia, including a generalized failure of retrieval, which would be expected to affect all autobiographical recall regardless of the age of a memory (Levine *et al.*, 1998), and the selective erasure of components of individual memories, which could explain partial forms of autobiographical amnesia (Rubin and Greenberg, 1998). Differences in the patterns of deficit in reported cases of focal retrograde amnesia support the idea that different mechanisms can be involved. For example, R.G. (described here), unlike J.M. (Evans *et al.*, 1996, 2001) and M.L. (Levine *et al.*, 1998), remained able to summon up some of his early autobiographical memories, whereas both J.M. and R.G., unlike M.L., retained the sense of vivid recollection or experiential 'immediacy' in at least some autobiographical recollections.

Against the background of these observations, can we define the likely basis of R.G.'s autobiographical amnesia? Several considerations argue against an explanation in terms of defective encoding: these include the temporal extent of the amnesia for information that R.G. had previously been quick to recall, and his normal anterograde memory performance on standard tests. A generalized retrieval deficit is also rendered unlikely by R.G.'s ability to retrieve a range of established and novel memories, and by the failure of cues to improve his performance.

An explanation in terms of disrupted long-term consolidation caused by hippocampally based seizures also seems implausible, regardless of which model of memory consolidation one considers. The temporal extent of R.G.'s retrograde amnesia (extending back in time for almost 30 years) is contrary to the standard account of memory consolidation (described previously), in which the hippocampal complex plays a temporary role in episodic retrieval. An alternative model of memory consolidation, the multiple trace theory, in which the hippocampal formation remains necessary for the retrieval of autobiographical memories throughout life, also fails to explain this pattern, given that R.G. showed normal experiential recall of many childhood and adulthood memories (Nadel and Moscovitch, 1997).

A more compelling alternative is that R.G.'s time-limited retrograde amnesia was due to degradation or erasure of the relevant neocortically based representations. If this hypothesis is correct, how could such a process occur? It could be argued that R.G.'s autobiographical memory difficulties were a consequence of underlying cerebrovascular disease. Roman and colleagues have recently published research diagnostic criteria for vascular dementia, which require 'the presence of focal signs on neurological examination such as hemiparesis, lower facial weakness, Babinski's sign, sensory deficits, hemianopia and dysarthria consistent with stroke', and a

clear relationship between the cognitive deficits (dementia) and the pathological process (stroke) (Roman *et al.*, 1993). R.G.'s neurological examination was normal and there was not a clear relationship between his performance on the neuropsychological tests and the mild degree of cerebrovascular disease evident on brain imaging. Furthermore, a very considerable literature on vascular dementia suggests that the most prominent deficits in the disease are in executive function and anterograde memory, and not typically in the retrieval of autobiographical memories (Hodges and Graham, 2001). It seems unlikely, therefore, that cerebrovascular disease was the predominant cause of R.G.'s severe and relatively isolated retrograde amnesia.

A more plausible explanation, and the one that we prefer, is that R.G.'s extensive retrograde memory deficit was the cumulative effect of recurrent temporal lobe epilepsy. Focal retrograde amnesia has been described previously in a patient with recurrent episodes of amnesia and, occasionally, of altered awareness, both attributed to epilepsy (Kapur *et al.*, 1989). The patient's memory for public events, both before and after onset of the illness, was particularly severely affected, with a milder, patchy impairment of memory for autobiographical episodes. Kapur (1993a) suggested that recurrent episodes of epileptic activity in the temporal lobes might give rise to a cumulative retrograde deficit (see also O'Connor *et al.*, 1997). We propose that R.G.'s amnesia may have had a similar basis, in the bitemporal epileptic activity demonstrated on EEG. While we cannot offer conclusive evidence for this hypothesis, it is more plausible than the suggestion that the mild degree of cerebrovascular disease demonstrated on MRI was the primary cause of his amnesia. It is also consistent with the common subjective complaint of autobiographical amnesia noted previously among patients with TEA (Zeman *et al.*, 1998).

Given this view of R.G.'s autobiographical memory deficit, how do we explain why his loss of memories affected only half of his life (e.g. the last 30 years), but that his retrieval of memories from before this time, while not entirely normal, was substantially better? The best account for R.G.'s pattern of performance is that older autobiographical material is simply less vulnerable to the process of fragmentation, either because it is more semantized (i.e. more akin to general semantic knowledge, which was clearly preserved in R.G.) and/or more strongly represented cortically. Cermak (1984) proposed that autobiographical episodes gradually take on the properties of semantic memory over a period of many years, becoming independent of their temporal and spatial context. More recent episodes, which require temporal and spatial context for recall, could be more vulnerable to repeated temporal lobe seizures than the older, semantized memories. In addition, it is likely that older memories are more frequently recalled during a patient's lifetime and, therefore, may have stronger neocortical links than younger memories, which have been retrieved less often. These older memories would be less vulnerable to erosion, resulting in an effect of time

in autobiographical recall. A number of recent investigations confirm the likelihood of this explanation.

O'Connor and colleagues describe a patient (J.T.) who showed increasingly temporally extensive loss of semantic information on a Famous Faces Test over a 3-year period during which he suffered frequent seizures (20–30 a day even on medication) (O'Connor *et al.*, 1997; see also Ahern *et al.*, 1994). As in the case of R.G., it was the most recently acquired information that was most susceptible to loss. J.T. showed a further link between seizure activity and memory ability: when he was prescribed the anticonvulsant paraldehyde, his verbal memory improved significantly. It is notable that J.T.'s autobiographical memory was particularly poor and he showed little autobiographical retrieval for most of his life, a pattern that supports the view that autobiographical events, which are multimodal and highly distributed in the brain, may be more vulnerable to repeated epileptic activity than semantic memories.

A group study by Blake and colleagues also found support for disrupted long-term memory consolidation, at least of verbal material, in patients with epileptic foci in the left temporal lobe (Blake *et al.*, 2000). Blake and colleagues note that 'it seems likely that the disruption of memory consolidation in epilepsy lies on a continuum (affecting all types of material), TEA patients occupying an intermediate position (with some autobiographical and event knowledge impairment) and patients with left temporal lobe epilepsy manifesting a material-specific profile of focal memory dysfunction' (p. 480).

Another investigation extends the results from Blake and colleagues to remote memory. Bergin and colleagues (Bergin *et al.*, 2000) found that a group of patients with temporal lobe epilepsy (TLE) performed significantly less well on a questionnaire of past public events than two other epileptic groups (patients with extratemporal epilepsy and those with primary generalized epilepsy). Patients in the TLE group were also significantly impaired on the test compared with control subjects, but there were no significant differences between the control participants, the patients with extratemporal epilepsy and the patients with primary generalized epilepsy. Further analyses of the data of Bergin and colleagues provided some evidence that performance on the public event questionnaire was associated with seizure frequency: the greater the number of convulsions experienced by a patient the more likely it was that they would exhibit a deficit on the questionnaire.

These studies demonstrate that systematic study of retrograde memory in patients with subtypes of focal and generalized epilepsy can clarify the relationship between focal retrograde amnesia and epileptic foci in the temporal lobes. Further research is clearly needed, however, if we are to fully understand the mechanisms by which recurrent epilepsy disrupts long-term consolidation, and how the extent of memory impairment is related to the severity and loci of epileptic activity.

Conclusion

We have described a patient, R.G., with temporal lobe epilepsy, who developed a focal amnesia for salient autobiographical events for a substantial portion of his life. Although anecdotal reports have hinted at the existence of disproportionately severe retrograde amnesia in TEA, this is the first clear empirical documentation of this phenomenon. This finding also adds to the evidence for dissociation between the mechanisms subserving anterograde memory and those required to evoke remote episodic memories, and strengthens the evidence for a dissociation between knowledge of public and of personal events. The consistency of R.G.'s amnesia over time, its stability across varying types of test and the preservation of some episodic memories suggest that R.G.'s amnesia may have been due to erasure of representations rather than to a defective retrieval mechanism. Whether epileptic activity per se is responsible for this phenomenon requires further investigation.

Acknowledgements

We wish to thank Professor Narinder Kapur for helpful discussion. F.M. was supported by the Raul Carrea Institute of Neurological Research, Buenos Aires, Argentina and by the Medical Research Council, UK. J.R.H. and K.S.G. were supported by the Medical Research Council, UK.

References

- Ahern GL, O'Connor M, Dalmau J, Coleman A, Posner JB, Schomer DL, et al. Paraneoplastic temporal lobe epilepsy with testicular neoplasm and atypical amnesia. *Neurology* 1994;44: 1270-4.
- Alvarez P, Squire LR. Memory consolidation and the medial temporal lobe: a simple network model. [Review]. *Proc Natl Acad Sci USA* 1994; 91: 7041-5.
- Bergin PS, Thompson PJ, Baxendale SA, Fish DR, Shorvon SD. Remote memory in epilepsy. *Epilepsia* 2000; 41: 231-9.
- Blake RV, Wroe SJ, Breen EK, McCarthy RA. Accelerated forgetting in patients with epilepsy. Evidence for an impairment in memory consolidation. *Brain* 2000; 123: 472-83.
- Calabrese P, Markowitsch HJ, Durwen HF, Widlitzek H, Haupts M, Holinka B, et al. Right temporofrontal cortex as critical locus for the ephory of old episodic memories. *J Neurol Neurosurg Psychiatry* 1996; 61: 304-10.
- Cermak, LS. The episodic/semantic distinction in amnesia. In: Butters N, Squire LR, editors. *The neuropsychology of memory*. New York: Guildford Press; 1984. p. 55-62.
- Conway MA, Turk DJ, Miller SL, Logan J, Nebes RD, Meltzer CC, et al. A positron emission tomography (PET) study of autobiographical memory retrieval. *Memory* 1999; 7: 679-702.
- Crovitz HF, Schiffman H. Frequency of episodic memories as a function of their age. *Bull Psychonom Soc* 1974; 4: 517-8.
- Evans JJ, Heggs AJ, Antoun N, Hodges JR. Progressive prosopagnosia associated with selective right temporal lobe atrophy. A new syndrome? *Brain* 1995; 118: 1-13.
- Evans JJ, Breen EK, Antoun N, Hodges JR. Focal retrograde amnesia for autobiographical events following cerebral vasculitis: a connectionist account. *Neurocase* 1996; 2: 1-12.
- Evans JJ, Graham KS, Pratt KH, Hodges JR. A long-term follow up of focal retrograde amnesia. In press 2001.
- Fink GR, Markowitsch HJ, Reinkemeier M, Bruckbauer T, Kessler J, Heiss W-D. Cerebral representation of one's own past: neural networks involved in autobiographical memory. *J Neurosci* 1996; 16: 4275-82.
- Galton F. Psychometric experiments. *Brain* 1879; 2: 149-62.
- Graham KS, Hodges JR. Differentiating the roles of the hippocampal complex and the neocortex in long-term memory storage: evidence from the study of semantic dementia and Alzheimer's disease. *Neuropsychology* 1997; 11: 77-89.
- Graham KS, Patterson K, Hodges JR. Episodic memory: new insights from the study of semantic dementia. [Review]. *Curr Opin Neurobiol* 1999; 9: 245-50.
- Greene JD, Hodges JR. Identification of famous faces and famous names in early Alzheimer's disease. *Brain* 1996; 119: 111-28.
- Hodges JR, Graham NL. In: Hodges JR, editor. *Vascular dementias. Early onset dementia*. Oxford: Oxford University Press. In press 2001.
- Hodges JR, Patterson K. Is semantic memory consistently impaired early in the course of Alzheimer's disease? Neuroanatomical and diagnostic implications. *Neuropsychologia* 1995; 33: 441-59.
- Hodges JR, Ward CD. Observations during transient global amnesia. *Brain* 1989; 112: 595-620.
- Howard D, Patterson K. *The pyramids and palm trees test: a test of semantic access from pictures and words*. Bury St. Edmunds (UK): Thames Valley Test Company; 1992.
- Hunkin NM, Parkin AJ, Bradley VA, Burrows EH, Aldrich FK, Jansari A, et al. Focal retrograde amnesia following closed head injury: a case study and theoretical account. *Neuropsychologia* 1995; 33: 509-23.
- Kapur N. Transient epileptic amnesia—a clinical update and a reformulation. *J Neurol Neurosurg Psychiatry* 1993a; 56: 1184-90.
- Kapur N. Focal retrograde amnesia in neurological disease: a critical review. [Review]. *Cortex* 1993b; 29: 217-34.
- Kapur N. Syndromes of retrograde amnesia: a conceptual and empirical synthesis. [Review]. *Psychol Bull* 1999; 125: 800-25.
- Kapur N, Brooks DJ. Temporally-specific retrograde amnesia in two cases of discrete bilateral hippocampal pathology. *Hippocampus* 1999; 9: 247-54.
- Kapur N, Young A, Bateman D, Kennedy P. Focal retrograde amnesia: a long term clinical and neuropsychological follow-up. *Cortex* 1989; 25: 387-402.
- Kitchener EG, Hodges JR. Impaired knowledge of famous people and events with intact autobiographical memory in a case of progressive right temporal lobe degeneration: implications for the

- organisation of remote memory. *Cogn Neuropsychol* 1999; 16: 589–607.
- Kopelman M, Panayiotopoulos CP, Lewis P. Transient epileptic amnesia differentiated from psychogenic 'fugue': neuropsychological, EEG, and PET findings. *J Neurol Neurosurg Psychiatry* 1994; 57: 1002–4.
- Kopelman MD, Wilson BA, Baddeley AD. The autobiographical memory interview. Bury St. Edmunds (UK): Thames Valley Test Company; 1990.
- Levine B, Black SE, Cabeza R, Sinden M, McIntosh AR, Toth JP, et al. Episodic memory and the self in a case of isolated retrograde amnesia. *Brain* 1998; 121: 1951–73.
- Maguire EA, Mummery CJ. Differential modulation of a common memory retrieval network revealed by positron emission tomography. *Hippocampus* 1999; 9: 54–61.
- Markowitsch HJ, Calabrese P, Liess J, Haupts M, Durwen HF, Gehlen W. Retrograde amnesia after traumatic injury of the fronto-temporal cortex. *J Neurol Neurosurg Psychiatry* 1993; 56: 988–92.
- McClelland JL, McNaughton BL, O'Reilly RC. Why there are complementary learning systems in the hippocampus and neocortex: insights from the successes and failures of connectionist models of learning and memory. [Review]. *Psychol Rev* 1995; 102: 419–57.
- McKenna P, Warrington EK. The Graded Naming Test. Windsor (UK): NFER-Nelson; 1993.
- Murre JM. TraceLink: a model of amnesia and consolidation of memory. *Hippocampus* 1996; 675–84.
- Nadel L, Moscovitch M. Memory consolidation, retrograde amnesia and the hippocampal complex. [Review]. *Curr Opin Neurobiol* 1997; 7: 217–27.
- Nelson HE. A modified card sorting test sensitive to frontal lobe defects. *Cortex* 1976; 12: 313–24.
- Nelson HE. National Adult Reading Test Manual. Windsor (UK): NFER-Nelson; 1982.
- O'Connor M, Sieggreen MA, Ahern G, Schomer D, Mesulam M. Accelerated forgetting in association with temporal lobe epilepsy and paraneoplastic encephalitis. *Brain Cogn* 1997; 35: 71–84.
- Osterrieth, PA. Le test de copie d'une figure complexe. *Arch Psychol* 1944; 30: 206–356. [translated by J. Corwin and F.W. Bylsma. *Clin Neuropsychol* 1993; 7: 9–15].
- Parkin AJ. Focal retrograde amnesia: a multi-faceted disorder? [Review]. *Acta Neurol Belg* 1996; 96: 43–50.
- Reinvang I, Gjerstad L. Focal retrograde amnesia associated with vascular headache. *Neuropsychologia* 1998; 36: 1335–41.
- Roman GC, Tatemichi TK, Erkinjuntti T, Cummings JL, Masdeu JC, Garcia JH, et al. Vascular dementia: diagnostic criteria for research studies. Report of the NINDS-AIREN International Workshop. *Neurology* 1993; 43: 250–60.
- Rubin DO, Greenberg DL. Visual memory-deficit amnesia: a distinct amnesic presentation and etiology. *Proc Natl Acad Sci USA* 1998; 95: 5413–6.
- Scoville WB, Milner B. Loss of recent memory after bilateral hippocampal lesions. *J Neurol Neurosurg Psychiatry* 1957; 20: 11–21.
- Tanaka Y, Miyazawa Y, Hashimoto R, Nakano I, Obayashi T. Postencephalitic focal retrograde amnesia after bilateral anterior temporal lobe damage. *Neurology* 1999; 53: 344–50.
- Warrington EK. Recognition Memory Test. Windsor (UK): NFER-Nelson; 1984.
- Warrington EK, James M. Visual Object and Space Perception Battery. Bury St. Edmunds (UK): Thames Valley Test Company; 1991.
- Wechsler D. Wechsler Memory Scale—Revised. San Antonio (TX): Psychological Corporation; 1987.
- Zeman AZ, Boniface SJ, Hodges JR. Transient epileptic amnesia: a description of the clinical and neuropsychological features in 10 cases and a review of the literature. [Review]. *J Neurol Neurosurg Psychiatry* 1998; 64: 435–43.
- Zola-Morgan SM, Squire LR. The primate hippocampal formation: evidence for a time-limited role in memory storage. *Science* 1990; 250: 288–90.

Received July 4, 2000. Revised November 15, 2000.

Accepted November 20, 2000