

# Dual Plane Breast Augmentation: Optimizing Implant–Soft-Tissue Relationships in a Wide Range of Breast Types

**John B. Tebbetts, M.D.**

*Dallas, Texas*

In breast augmentation, surgeons usually choose a pocket location for the implant behind breast parenchyma (retromammary), partially behind the pectoralis major muscle (partial retropectoral), or totally behind pectoralis major and serratus (total submuscular). Each of these implant pocket locations has specific indications, but each also has a unique set of tradeoffs. When applied to a wide range of breast types, each pocket location has limitations. Glandular ptotic and constricted lower pole breasts offer unique challenges that often are not solved without tradeoffs when using a strictly retromammary, partial retropectoral, or total submuscular pocket. This article describes specific indications and techniques for a dual plane approach to breast augmentation in several different breast types, introducing techniques that combine retromammary and partial retropectoral pocket locations in a single patient to optimize the benefits of each pocket location while limiting the tradeoffs and risks of a single pocket location. A total of 468 patients had dual plane augmentation between January of 1992 and March of 1998 using the specific techniques of dual plane augmentation described in this article. All patients were treated as outpatients and received general anesthesia. Indications, operative techniques, results, and complications for this series of patients are presented. Dual plane augmentation mammoplasty adjusts implant and tissue relationships to ensure adequate soft-tissue coverage while optimizing implant–soft-tissue dynamics to offer increased benefits and fewer tradeoffs compared with a single pocket location in a wide range of breast types. (*Plast. Reconstr. Surg.* 107: 1255, 2001.)

Three implant pocket locations are commonly used in augmentation mammoplasty: (1) behind breast parenchyma (retromammary),<sup>1</sup> (2) partially behind the pectoralis major muscle (partial retropectoral,<sup>2–9</sup> or (3) totally behind pectoralis major and serratus (total submuscular).<sup>10–12</sup> Other authors<sup>13–17</sup>

have addressed the relative benefits and tradeoffs of implant pocket location with respect to capsular contracture rates. This article presents techniques that allow two pocket planes (dual plane) to be developed in a single patient, adjusting the implant and tissue relationships to ensure adequate soft-tissue coverage while optimizing implant–soft-tissue dynamics, to offer increased benefits and fewer tradeoffs compared with a single pocket location in a wide range of breast types.

Each of the previously listed implant pocket locations has specific benefits and indications, but each also has unique tradeoffs in specific breast types. For example, in a glandular ptotic breast with thin soft tissues in the superior pole of the breast, a partial retropectoral or total submuscular pocket location provides the necessary additional soft-tissue coverage superiorly but risks a “double-bubble” deformity resulting from parenchyma sliding inferiorly off the pectoralis and implant. A constricted lower pole breast in a thin patient needs additional coverage superiorly, but muscle coverage inferiorly restricts optimal expansion of the constricted lower pole.

Because each pocket location has unique advantages and tradeoffs, applying a single pocket location to every primary augmentation may risk unnecessary compromises. Patients vary widely in soft-tissue characteristics, breast tissue, and their willingness to accept specific tradeoffs. When a surgeon uses only one pocket location for all primary breast augmen-

Received for publication August 4, 2000.

Dr. Tebbetts is a consultant to McGhan Medical Corporation, manufacturer of one of the types of saline-filled breast implants used in this study.

tations, it is logical that compromises, complications, or less-than-optimal results will occur, because a single pocket location does not completely address the range of anatomic variations and implant–soft-tissue dynamics that occur in a wide range of breast types. Even if a surgeon chooses the most appropriate of the three pocket locations (retromammary, partial retropectoral, total submuscular) for a given patient, tradeoffs can still occur. For example, none of the three common pocket locations is optimal for the glandular ptotic breast or a constricted lower pole breast in a thin patient. Even in routine breast types without specific deformities, a surgically controlled combination of pocket locations can potentially maximize the benefits and minimize the tradeoffs of a single pocket location.

This article addresses two questions:

1. Can a combination of pocket locations in the same breast (dual plane; combination of retromammary and partial retropectoral) increase the benefits and decrease the tradeoffs of a single pocket location, increase surgical control and predictability of the result, and minimize the tradeoffs, risks, and complications?
2. When additional muscle coverage is indicated, can the surgeon adjust the anatomic position of the pectoralis major muscle relative to the implant to better control the implant–soft-tissue dynamics for an optimal result?

#### DEFINITION OF DUAL PLANE AUGMENTATION

Dual plane augmentation is defined as any augmentation that meets the following three criteria:

1. The implant lies partially behind the pectoralis major muscle and partially behind the breast parenchyma (in dual planes simultaneously).
2. A specific group of pectoralis major muscle origins are totally divided in a specific area to alter implant–soft-tissue dynamics by anatomically repositioning portions of the pectoralis major relative to the implant (this criterion distinguishes dual plane from partial retropectoral augmentation).
3. The parenchyma-muscle interface is specifically altered to change the soft-tissue relationships between pectoralis major

and parenchyma and to change the implant-parenchyma dynamics.

Two anatomic entities largely control the position of the pectoralis major muscle relative to a breast implant: (1) the origins of the muscle along the inframammary fold inferiorly and the sternum medially, and (2) the attachments of the pectoralis to the breast parenchyma at the parenchyma-muscle interface. To alter the position of the pectoralis major muscle relative to the implant, the surgeon divides origins of the pectoralis along the inframammary fold. The muscle then retracts superiorly until its superior retraction is stopped by attachments at the parenchyma-muscle interface or by remaining muscle origin attachments along the sternum.

In dual plane augmentation, the surgeon alters the position of portions of the pectoralis major muscle by (a) selectively dividing the inferior origins of the pectoralis along the inframammary fold only, with no muscle division along the sternum; and (b) freeing the attachments of parenchyma to muscle at the parenchyma-muscle interface by dissecting in the retromammary plane between the parenchyma and the pectoralis. These two maneuvers are performed at different times and to different degrees, depending on incisional approach, breast type, tissue characteristics, implant–soft-tissue dynamics, and the surgeon's preferences.

#### CLINICAL CRITERIA AND METHODS

Each patient's preoperative breast-envelope characteristics were clinically characterized as tight, normal, or excessively compliant (genetically or postpregnancy). Areola-to-inframammary-fold distance, sternal-notch-to-nipple distance, base width of the breast, and intermammary distance were measured and recorded preoperatively and at each postoperative visit. Soft-tissue pinch thicknesses of the upper pole and at the inframammary fold was measured with calipers. The position of the lower border of the pectoralis was noted preoperatively and postoperatively by palpation and visualization while the patient contracted the pectoralis. The pocket location for the implant was chosen based on the criteria described below in order of priority.

#### *Adequacy of Soft-Tissue Cover*

Adequate soft-tissue cover over an implant is mandatory in both primary and reoperation

cases. In primary cases, adequacy of soft-tissue cover in the upper breast was assessed clinically by isolating the breast parenchyma inferiorly and firmly pinching the soft tissues superior to the parenchyma (Fig. 1, *left*) to quantitate soft-tissue pinch thickness of the upper pole. *If this pinch thickness was 2 cm or greater*, the patient was offered a *retromammary* pocket location, provided that an adequately filled, textured, anatomic implant was used. Soft-tissue pinch thickness was also measured immediately inferior to the inframammary fold (Fig. 1, *right*). *If this pinch thickness was less than 0.4 cm*, pectoralis major origins along the inframammary fold were *left intact* for additional soft-tissue coverage, and the patient was excluded from this study.

If the patient preferred a *round* implant, smooth or textured, the potential upper pole collapse of the round implant filled to the manufacturer's recommendations necessitated a partial retropectoral pocket to minimize risks of visible underfill rippling. If the patient requested a markedly bulging upper breast with a step-off (the "Baywatch" breast), she was encouraged to select either an overfilled round implant, a larger round implant filled to the manufacturer's recommendations, or a larger anatomic implant. Tradeoffs that all patients were required to accept by informed consent included the possibility of an increased (a) risk of a visible or palpable implant edge, (b) capsular contracture rate resulting from increased implant exposure to parenchyma, and (c) interference with mammographic interpretation as implant contact with parenchyma increased.

#### Patient Preference

If a patient preferred one pocket location over another, the tradeoffs and risks of that pocket location were discussed with the pa-

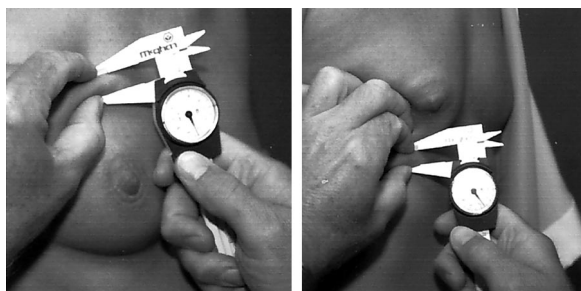


FIG. 1. Soft-tissue pinch thickness of the upper pole (*left*) and immediately inferior to the inframammary fold (*right*) is caliper-measured with a firm pinch of the skin and subcutaneous tissue.

tient, and the patient's wishes were honored provided that adequate soft-tissue cover was present. If  $<2$  cm of pinch thickness was present superior to the breast parenchyma, the patient was required to accept muscle coverage in the upper breast to ensure adequate coverage with any type of implant, or the patient was not operated on. Pocket locations with potential benefits and tradeoffs included in the information materials and discussed with each patient are listed in Table I.

Table II lists the potential benefits and tradeoffs of the dual plane pocket location compared with strict retromammary or partial retropectoral pocket locations described in Table I.

In this series of patients, when inadequate soft-tissue coverage ( $<2$  cm pinch thickness) was present superior to the breast parenchyma, upper pole muscle coverage was mandatory. When muscle coverage was indicated or preferred by the patient, three options were discussed: (1) partial retropectoral (with pectoralis origins intact along the inframammary fold and sternum), (2) total submuscular (adding serratus laterally for total muscle coverage), and (3) dual plane (with complete division of pectoralis origins along the inframammary fold, not along the sternum). The goal of the dual plane approach was to optimize the benefits while limiting the tradeoffs of the retromammary, partial retropectoral, and total submuscular approaches. Patients who elected the dual plane pocket location after considering all alternatives were included in this study. Preoperatively, all patients, *regardless of tissue thickness*, were advised of the following in informed-consent documents:

1. If you can feel your ribs with your finger, beneath the breast or at the side of your breast, you *will* be able to feel the edge of your implant beneath your breast and at the side of your breast.
2. Currently manufactured implants that strive to achieve durability of the shell have a thicker shell to prolong the life of your implant, and a thicker shell may be easier for you to feel.
3. If feeling an edge of an implant shell could be a problem for you, do not have an augmentation.
4. We cannot change the quality or thickness of your tissues. If you are thin or have

TABLE I  
Alternative Pocket Locations with Potential Tradeoffs

Pocket	Tradeoffs	Potential Benefits
Retromammary	<ol style="list-style-type: none"> <li>1. Increased risk of edge visibility or palpability.</li> <li>2. Possible increased interference with mammography.</li> <li>3. Possible increased incidence of capsular contracture.</li> </ol>	<ol style="list-style-type: none"> <li>1. Increased control of breast shape.</li> <li>2. Usually a more rapid postoperative recovery.</li> <li>3. Minimal or no distortion with pectoralis contraction.</li> <li>4. Increased control of inframammary fold position and shape.</li> </ol>
Partial retropectoral ( <i>without</i> dividing pectoralis origins along the inframammary fold)	<ol style="list-style-type: none"> <li>1. Lateral implant displacement over time, widening the space between the breasts.</li> <li>2. Less control of upper medial fill.</li> <li>3. More postoperative tenderness and a more prolonged recovery.</li> <li>4. Distortion of breast shape with pectoralis contraction.</li> <li>5. Less precise control of inframammary fold position, depth, and configuration. This potential tradeoff is minimized or eliminated by division of pectoralis origins along the inframammary fold in patients who have adequate soft-tissue coverage.</li> <li>6. Increased risk of superior implant malposition or displacement (when inferior pectoralis origins across inframammary fold are <i>not</i> divided).</li> <li>7. Longer time required for deepening of the inframammary fold (when pectoralis origins along the inframammary fold are <i>not</i> divided).</li> </ol>	<ol style="list-style-type: none"> <li>1. Muscle coverage mandatory if pinch thickness &lt; 2 cm above breast parenchyma.</li> <li>2. Possibly more accurate mammograms.</li> <li>3. Less risk of palpable or visible implant edges.</li> <li>4. Possible decreased risk of capsular contracture (small difference with saline-filled implants, greater difference with silicone gel-filled implants).</li> </ol>
Total submuscular	<ol style="list-style-type: none"> <li>1. All tradeoffs listed above for partial retropectoral, plus:</li> <li>2. Highest risk of superior implant displacement or malposition.</li> <li>3. Longer operative time.</li> <li>4. Longest postoperative recovery and morbidity.</li> <li>5. Least accurate and predictable inframammary fold and longest to achieve depth.</li> <li>6. Greatest risk of inframammary fold irregularities, lateral flattening, and fold level inaccuracies.</li> </ol>	<ol style="list-style-type: none"> <li>1. Possible increased coverage inferolaterally but clinically no significant additional cover long-term.</li> </ol>

very little breast tissue, you will be more likely to feel your implant.

5. The larger your implant, the worse your breast will look over time. A larger implant will stretch your tissues over time and will cause more tissue-thinning and sagging than a smaller implant. Your tissues do not improve with age, and they will be less able to support the additional weight of any implant, especially a larger implant.
6. Any implant, if filled adequately to prevent collapse and possible folding of the shell when you stand, will feel firmer than a normal breast, regardless of the filler material. If the implant shell folds, it could fail sooner and require you to have a reoperation sooner<sup>18</sup> (most patients accept a firmer breast in exchange for a possibly longer life of the implant shell).
7. If you want a totally natural breast, you should not have a breast augmentation.

### Three Types of Dual Plane Augmentation

Three variations of muscle division and parenchyma-muscle interface dissection were used in this study:

1. Type I dual plane: complete division of pectoralis origins across the inframammary fold, stopping at the medial aspect of the inframammary fold, with *no dissection in the retromammary plane to free the parenchyma-muscle interface* (Fig. 2, *above*).
2. Type II dual plane: complete division of pectoralis origins across the inframammary fold, stopping at the medial aspect of the inframammary fold (Fig. 2, *center*), followed by *dissection in the retromammary plane to approximately the inferior border of the areola*.
3. Type III dual plane: complete division of pectoralis origins across the inframammary fold, stopping at the medial aspect of the inframammary fold (Fig. 2, *below*),

TABLE II  
Potential Benefits and Tradeoffs of the Dual Plane Pocket Location

Pocket	Tradeoffs	Potential Benefits
Dual plane (compared with retromammary)		<ol style="list-style-type: none"> <li>1. Preserves the potential increased control of lower breast shape with retromammary.</li> <li>2. With proper techniques can have similar recovery as with retromammary.</li> <li>3. Reduced risk of edge visibility or palpability of retromammary by providing more upper pole coverage.</li> <li>4. Reduced interference with mammography by retromammary.</li> <li>5. Reduced possibility of capsular contracture of retromammary by reducing contact with parenchyma compared with retromammary.</li> </ol>
Dual plane (compared with partial retropectoral)	1. Possible increased risk of palpable or visible implant edges inferiorly	<ol style="list-style-type: none"> <li>1. Provides same mandatory muscle coverage if pinch thickness &lt; 2 cm above breast parenchyma.</li> <li>2. Reduced risk of lateral implant displacement over time; dividing inferior origins decreases pectoralis pressure on implant.</li> <li>3. Better control of upper medial fill with division of inferior origins to decrease pectoralis tension and pressure on upper pole of implant.</li> <li>4. Reduced postoperative tenderness and recovery period with proper technique.</li> <li>5. Reduced distortion of breast shape with pectoralis contraction.</li> <li>6. Decreased risk of superior implant malposition or displacement by decreasing pressure of pectoralis on lower pole of implant by dividing lower pectoralis origins.</li> <li>7. Increased control of inframammary fold position, depth, and configuration by decreasing pressure of pectoralis on lower pole of implant along inframammary fold.</li> <li>8. Retains possibility of more accurate mammograms, depending on position of muscle.</li> <li>9. Possible decreased risk of capsular contracture (small).</li> </ol>

followed by *dissection in the retromammary plane to approximately the superior border of the areola.*

*The medial origins of the pectoralis along the sternum were not completely divided in any patient to avoid four potential problems: (1) visible deformities that can occur along the sternum from cut muscle edges adhering to subcutaneous fat and excessive risk of visible implant edges beneath thin parasternal skin; (2) visible implant edges beneath thin skin and subcutaneous tissue in the intermammary space; (3) visible traction-rippling medially that can occur with any implant when the implant places traction on a capsule attached to thin, overlying tissue; and (4) possible synmastia. The distinct, isolated, white, tendinous-looking medial origins of the pectoralis that are located lateral to the main body of parasternal origins along the sternum in some patients were divided to max-*

*imally enlarge the medial pocket without risking the tradeoffs of complete division along the sternum. Complete division of the medial origins of pectoralis along the sternum allows slightly greater narrowing of the intermammary distance but greatly increases the risks described previously, and the risks far outweigh the potential benefits.*

#### *Selection of Technique by Breast Type*

One of the three dual plane techniques was selected for each patient, according to the requirements dictated by the patient's anatomy and desired implant-soft-tissue dynamics required for an optimal result. The goal was to match the surgical technique to the needs of the breast to (1) maximize soft-tissue coverage and minimize forces that could cause undesirable implant displacement, (2) avoid restricting optimal expansion of the lower pole,

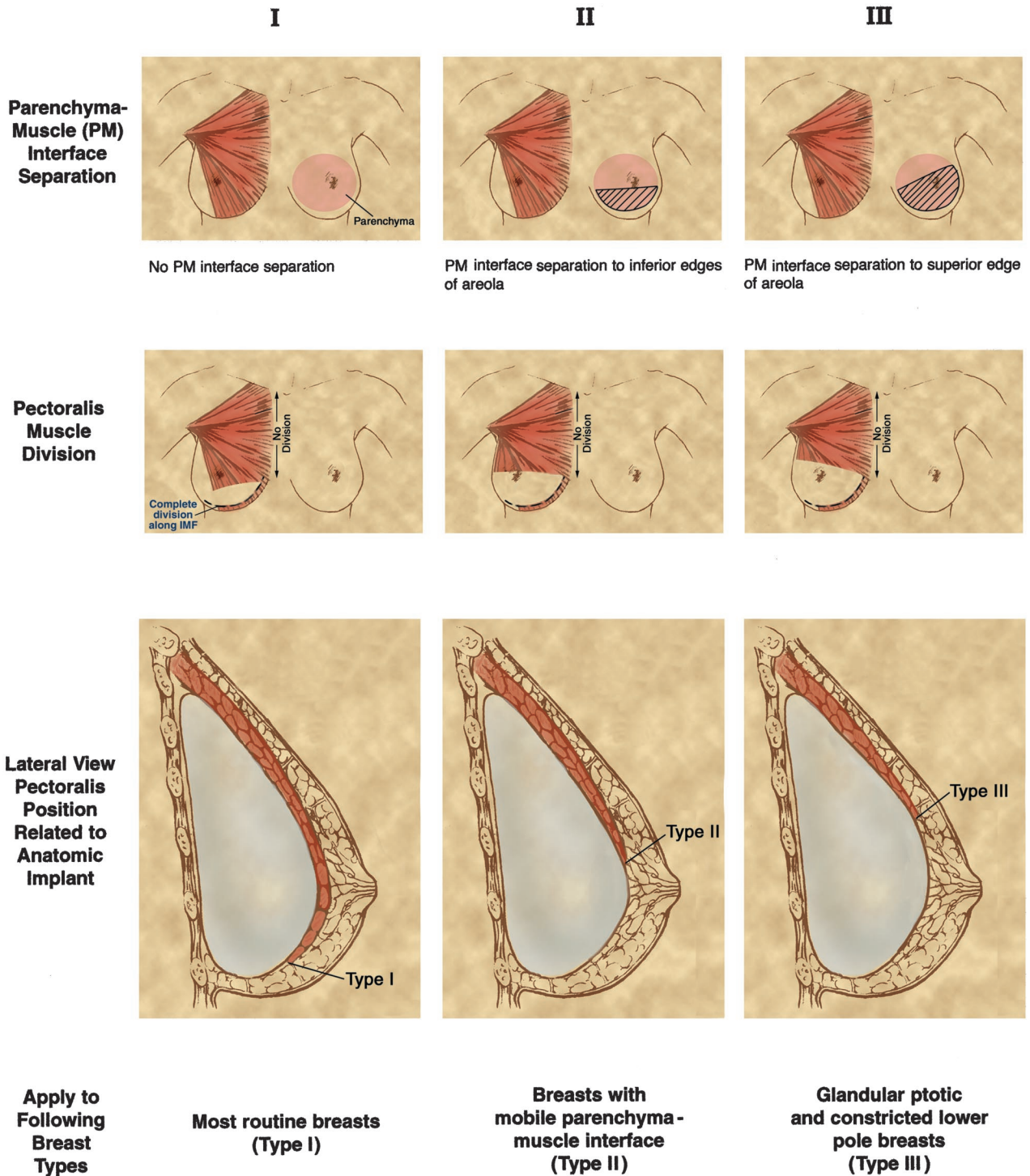


FIG. 2. Extent of dissection at the parenchyma-muscle interface (*above*), the position of the inferior edge of divided pectoralis origins (*center*), and pectoralis position relative to the implant (*below*) for types I, II, and III dual plane augmentation techniques.

and/or (3) reduce the risks of inferior displacement of breast parenchyma sliding off the pectoralis.

A type I dual plane technique was selected for most *routine breasts* that fit the following three criteria (Fig. 3):

1. all of the breast parenchyma located above the inframammary fold
2. tight attachments at the parenchyma-muscle interface
3. minimally stretched lower pole envelope, with an areola-to-inframammary fold dis-

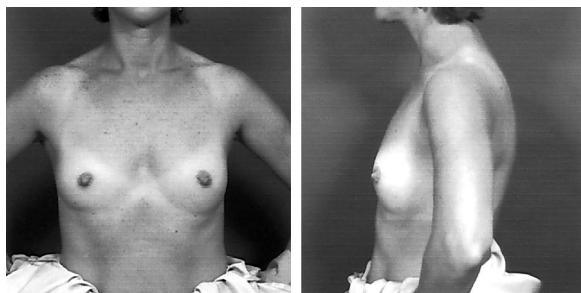


FIG. 3. A type I dual plane technique is selected for most routine breasts with the following characteristics: all breast parenchyma located above the inframammary fold, tight attachments at the parenchyma-muscle interface, and a minimally stretched lower pole envelope with an areola-to-inframammary fold distance under maximal stretch between 4.0 and 6.0 cm.

tance under stretch between 4.0 and 6.0 cm.

The goal in this type of breast was to minimize dissection at the parenchyma-muscle interface and divide the inferior pectoralis origins to optimize inframammary fold accuracy while preserving maximal muscle cover over the implant.

A type II dual plane technique was selected for breasts that had *highly mobile parenchyma* and fit the following criteria (Fig. 4):

1. most of the breast parenchyma located above the inframammary fold, but
2. looser attachments at the parenchyma-muscle interface (breast tissue much more mobile relative to the anterior surface of the pectoralis major)
3. lower pole envelope more stretched with an areola-to-inframammary fold distance under stretch between 5.5 and 6.5 cm.

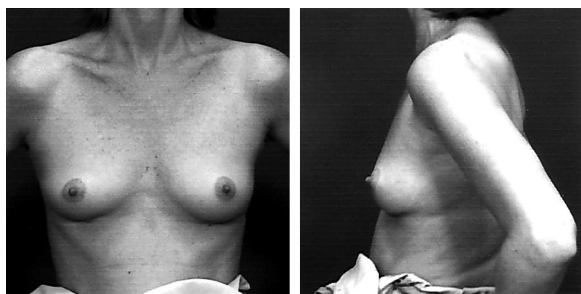


FIG. 4. A type II dual plane technique is selected for breasts with the following characteristics: most breast parenchyma located above the inframammary fold but looser attachments at the parenchyma-muscle interface (the breast tissue is much more mobile relative to the anterior surface of the pectoralis major), and a more stretched lower pole envelope with an areola-to-inframammary fold distance under stretch between 5.5 and 6.5 cm.

The goal in this type of breast was to perform more dissection at the parenchyma-muscle interface to allow the muscle to retract more superiorly, reducing the risks of highly mobile parenchyma sliding off the anterior surface of the pectoralis postoperatively.

A type III dual plane technique was selected for *glandular ptotic* and *constricted lower pole breasts* that fit criteria 1, 2, and 3 or criterion 4, below (Fig. 5):

1. breasts with *glandular ptosis* or *true ptosis* when one-third or more of the breast parenchyma lies below the level of the projected inframammary fold with the patient standing
2. very loose attachments at the parenchyma-muscle interface (breast parenchyma readily slides off the surface of the pectoralis)
3. markedly stretched lower pole envelope with an areola-to-inframammary fold distance under stretch of 7.0 to 8.0 cm
4. *constricted lower pole breasts* (Fig. 6) of all degrees, from mild to marked, including tuberous breasts, characterized by any combination of a (a) tight, constricted lower-breast envelope with a transversely short, tight inframammary fold; (b) parenchymal maldistribution, with parenchyma tightly concentrated centrally, producing a narrow base width; or (c) short areola-to-inframammary fold distance under stretch of 2.0 to 5.0 cm.

The goal in both glandular ptotic and constricted lower pole breasts was to maximally free the pectoralis inferiorly and to incremen-

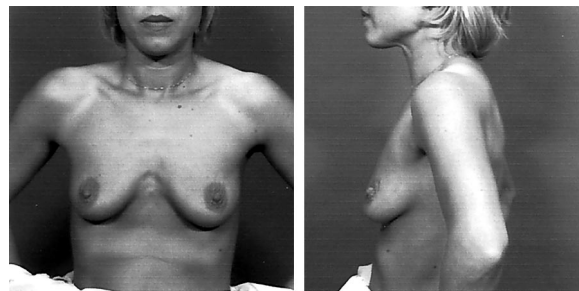


FIG. 5. A type III dual plane technique is selected for glandular ptotic breasts with the following characteristics: one-third or more of the breast parenchyma lying below the level of the projected inframammary fold with the patient standing, very loose attachments at the parenchyma-muscle interface (the breast parenchyma readily slides off the surface of the pectoralis), and a markedly stretched lower pole envelope with an areola-to-inframammary fold distance under stretch of 7.0 to 8.0 cm.

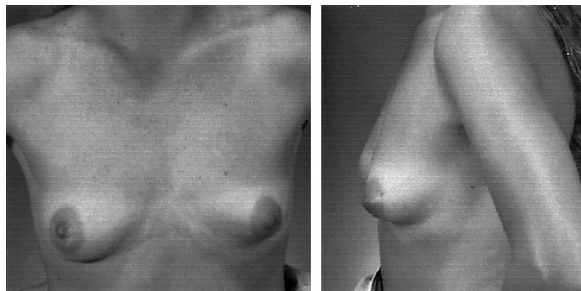


FIG. 6. A type III dual plane technique is selected for constricted lower pole breasts (all degrees from mild to marked, including tuberous breasts) characterized by any combination of (1) a tight, constricted lower-breast envelope with a transversely short, tight inframammary fold; (2) parenchymal maldistribution, with the parenchyma tightly concentrated centrally, producing a narrow base width; (3) a short areola-to-inframammary fold distance under stretch of 2.0 to 5.0 cm.

tally free the parenchyma from the pectoralis major at the parenchyma-muscle interface to allow the inferior edge of the pectoralis to move superiorly. All medial pectoralis origins along the sternum were totally preserved to avoid excessive upward retraction, visible superior banding of the pectoralis, and visible implant edges or traction-rippling medially. In both constricted lower pole and glandular ptotic breasts, the implant must maximally contact parenchyma and project anteriorly without muscle restriction to optimally correct the deformities. In all glandular ptotic breasts, the parenchyma-muscle interface must be altered to prevent parenchyma from sliding off the anterior surface of the pectoralis. In constricted lower pole breasts, the implant must contact large areas of parenchyma to achieve parenchymal redistribution after scoring and to optimally expand the inferior envelope.

#### *Patient Follow-Up and Evaluation*

The patients were scheduled for follow-up at 2 days, 3 weeks, 3 months, and 1 year, and at 2-year intervals thereafter. The overall results were evaluated clinically and were subjectively rated according to the following levels and criteria for the breast types defined previously:

- Excellent (5): Near-perfect symmetry and form, straight-sloping upper pole with no excessive or deficient fill, excellent nipple-areola position on the breast mound, no visual parenchymal-implant step-off or double-bubble, and near-perfect inframammary fold depth and definition without irregularities.

- Very good (4): Very good symmetry and form, aesthetic upper pole but very slight inward or outward sloping, very good nipple-areola position on the breast mound, no visual parenchymal-implant step-off or double-bubble, and very good inframammary fold depth and definition without irregularities.
- Satisfactory (3): Satisfactory symmetry and form, aesthetic upper pole but very slight inward or outward sloping, good but not perfect nipple-areola position on the breast mound, minimal visual parenchymal-implant step-off or double-bubble, and satisfactory inframammary fold depth and definition without irregularities.
- Fair (2): Fair symmetry and form, apparent inward or outward sloping at the upper pole, good but not perfect nipple-areola position on the breast mound, mild visual parenchymal-implant step-off or double-bubble, and fair inframammary fold depth with minimal-to-mild irregularities.
- Poor (1): Poor symmetry and form, upper pole with significantly excessive or deficient fill, excellent nipple-areola position on the breast mound, moderate-to-marked parenchymal-implant step-off or double-bubble, and compromised inframammary fold depth or definition with moderate-to-marked fold distortions.

All patients were questioned at each postoperative visit about their perceived firmness of their breasts, any visible deformities, any change in pectoralis major function, and time required before returning to normal activities.

#### *Dual Plane Surgical Techniques*

Inframammary and periareolar incisional approaches facilitate dual plane techniques, but these techniques can also be applied endoscopically through the axillary approach.

Through an inframammary incision, dissect directly to the surface of the pectoralis directly beneath the incision. For type I dual plane procedures, do not dissect at all in the retro-mammary plane. Retract anteriorly to lift the pectoralis off the chest wall (use of adequate muscle relaxant facilitates retropectoral dissection). With the pectoralis tented, use needle-point electrocautery dissection to incise the pectoralis just above the skin incision, parallel to the inframammary fold and 1 cm above it (Fig. 7), entering the subpectoral space on a



line toward the medial border of the areola. In this direction, the space is easiest to enter because there are no attachments to pectoralis minor or serratus anterior. The large perforator that is usually located 2 to 3 cm above the inframammary fold (Fig. 8) is controlled with unipolar, hand-switching, needlepoint electrocautery forceps, and the remainder of the pocket dissection and muscle division are completed with these same forceps. Dividing pectoralis origins along the inframammary fold, with no additional separation of pectoralis from parenchyma at the parenchyma-muscle interface, allows the inferior cut edge of pectoralis to move 2 to 4 cm superiorly. Leaving a 1-cm stump of pectoralis origins along the inframammary fold (1) facilitates control of intramuscular blood vessels, (2) provides a “shelf” that may offer some support for the inferior edge of the implant in some cases, and (3) leaves attachments of deep subcutaneous fascia to the anterior surface of the muscle stump along the fold to reduce the risk of excessively lowering the fold.

With the needlepoint forceps in the closed position, using a blended cut and coagulation current, continue dissection medially to the sternum and inferiorly to the desired inframammary fold level. Using the longer end of a double-ended retractor to expose the pectoralis origins at the inframammary fold, incrementally and completely divide pectoralis origins from the incision medially to the sternum (Fig. 9). Divide muscle in small increments from the undersurface to the superficial surface of the muscle, using the forceps like an electrocautery needle until subcutaneous fat is visible and controlling intramuscular vessels as they are encountered. Check topographical landmarks

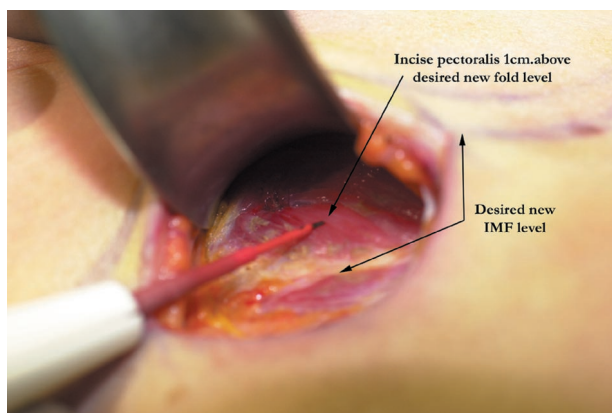


FIG. 7. Electrocautery incision of the tented pectoralis major to enter subpectoral space.

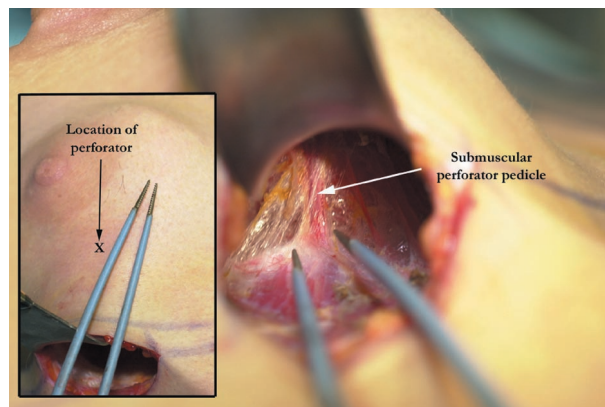


FIG. 8. Location and control of the large subpectoral perforating artery and vein.

frequently to ensure accuracy, and *stop muscle division medially where the inframammary fold meets the sternum*. Deep subcutaneous fascia overlying the pectoralis at the inframammary fold does not provide meaningful additional coverage and can restrict fold accuracy, so it is also divided to visualize subcutaneous fat (Fig. 10) except for when the soft-tissue pinch thickness at the inframammary fold is  $<0.4$  cm.

*Medially, along the sternum, divide only the isolated, white, tendinous origins that lie lateral to the main body of the pectoralis*, if tendinous origins are visible. Do not divide any of the main body of medial pectoralis origins along the sternum to avoid difficult or uncorrectable medial deformities, as mentioned earlier. Before removing the retractor, palpate the undersurface of the pocket along the inframammary fold to ensure complete, even release of inferior pectoralis origins and deep subcutaneous fascia. In exceedingly thin patients, the surgeon may choose to preserve muscle origins and fascia intact along the fold, accepting the tradeoffs of a less predictable fold location and configuration in exchange for thicker soft-tissue coverage for the implant at the inframammary fold.

With inferior pectoralis origins divided, sweep the pocket dissection from medial to lateral, lifting the pectoralis off the pectoralis minor and serratus anterior (Fig. 11). Completely divide any remaining pectoralis major origins lateral to the incision along the inframammary fold. Stop dissection at the lateral border of the pectoralis minor to avoid over-dissection of the lateral pocket, and enlarge it after the implant is in place by using a double-ended retractor and a spatula or malleable retractor for exposure.

Change to a longer, fiber-optic retractor with

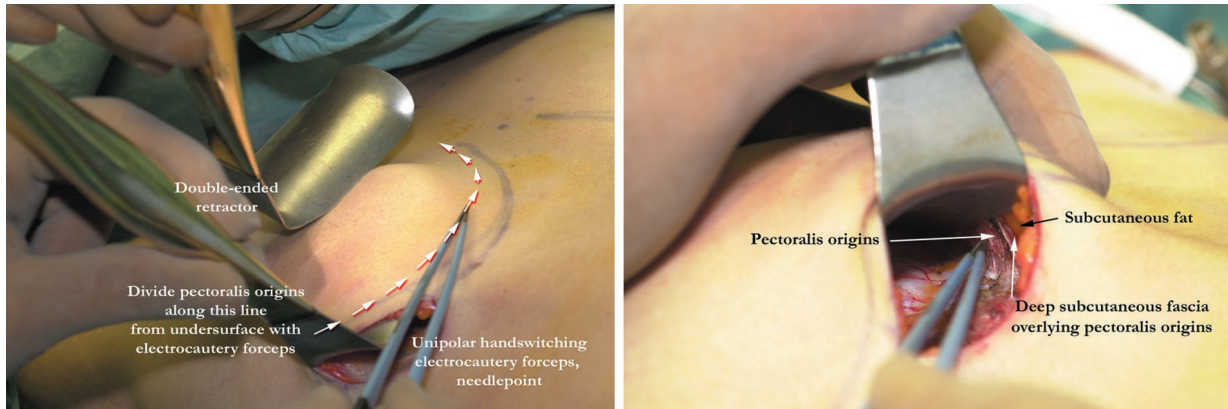


FIG. 9. (Left) Retraction for exposure and division of pectoralis major origins across and 1 cm above the inframammary fold. (Right) Unipolar, hand-switching, needlepoint electrocautery forceps divides pectoralis major origins.

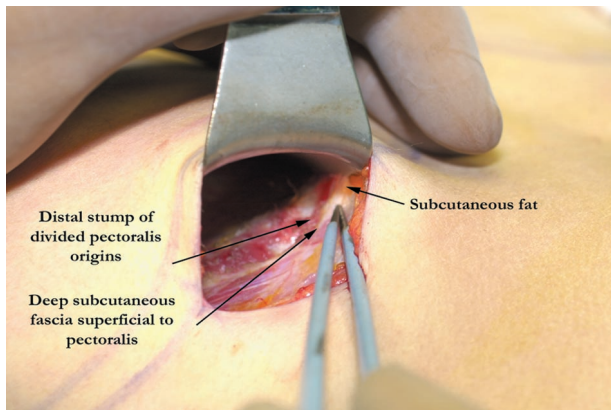


FIG. 10. Division of pectoralis major origins extended through the deep subcutaneous fascia to expose subcutaneous fat.

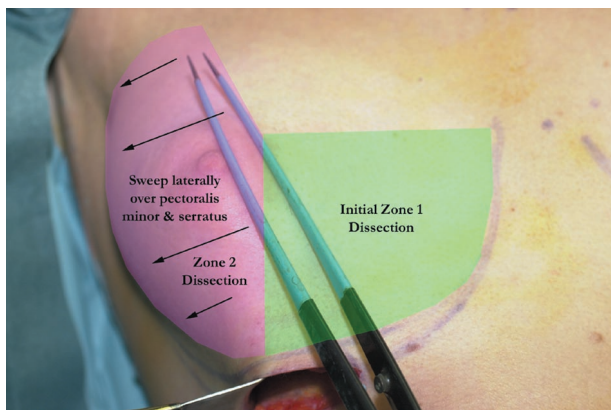


FIG. 11. Zone 2 subpectoral pocket dissection, sweeping laterally to separate pectoralis major from pectoralis minor and serratus muscles.

smoke-evacuation capabilities, and dissect superiorly, opening the superior subpectoral pocket until the thoracoacromial pedicle is visible, dissecting from lateral to medial (Fig. 12). Finally, open the medial pocket from superior to inferior along the sternum. Isolated, white,

tendinous origins of the pectoralis lateral to the main body of origins along the sternum medially can be safely divided to expand the medial pocket. Preserve all medial origins along the sternum intact to avoid the deformities that occur in a small percentage of patients and are difficult or impossible to correct. Narrowing the intermammary distance to  $<3$  cm in a subpectoral plane requires pectoralis division, risks leaving only thin skin and subcutaneous tissue over the implant edge medially, and should be avoided in all cases.

For types II and III dual plane procedures, enter the subpectoral plane, divide pectoralis muscle origins along the inframammary fold only, and complete the retropectoral pocket dissection exactly as described previously for the type 1 procedure. With the tissues now mobilized, place a double-ended retractor with the tip immediately inferior to the inferior cut border of the pectoralis at its attachment to the overlying parenchyma. Using upward traction on the retractor and traction with the fingers

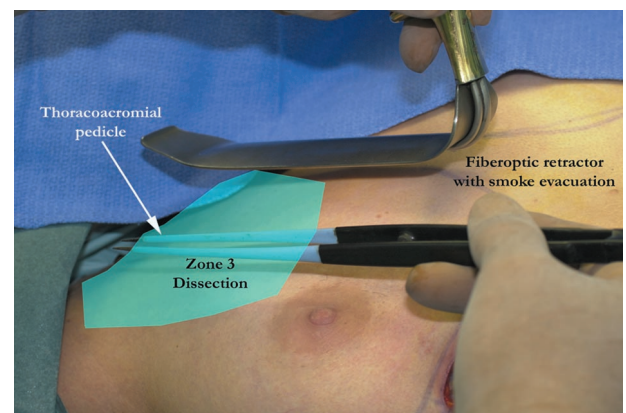


FIG. 12. Zone 3 subpectoral pocket dissected superiorly to visualize the thoracoacromial pedicle.

to keep the overlying tissues pulled onto the retractor blade exposes and defines the plane of attachments of pectoralis to the overlying parenchyma at the cut muscle edge (Fig. 13). With the closed needlepoint electrocautery forceps, free the muscle from the overlying parenchyma incrementally, sweeping the dissection from side-to-side and repositioning the retractor as necessary. Continue the separation at the parenchyma-muscle interface far enough laterally to free the lateral muscle adequately to allow it to move superiorly, but do not disrupt any medial pectoralis origins at the junction of the sternum with the inframammary fold. For the type II dual plane procedure, continue the dissection until the interface is free to approximately the *inferior* border of the areola, and for the type III procedure, to approximately the *superior* border of the areola. Free the interface in 1-cm increments, then insert the fingers and lift anteriorly to determine the precise muscle edge position relative to the topographical landmarks (Fig. 14). Continue freeing the muscle from the parenchyma until *no muscle banding is felt internally* that could restrict full implant projection. Leaving the medial origins of pectoralis intact along the sternum prevents excessive upward retraction and banding of the pectoralis superior to the implant.

Before irrigating the pocket and placing the implant, lift the skin envelope anteriorly to ensure there is no restriction to free movement of the tissues anteriorly. If any banding or restriction is felt at the level of the inferior border of the pectoralis, separate the muscle from

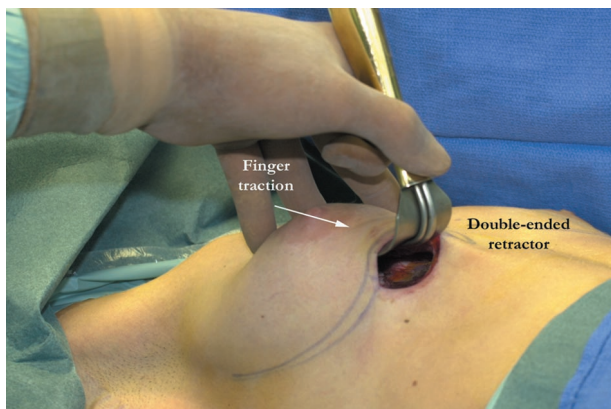


FIG. 13. Retraction for exposure of cut pectoralis muscle edge at the parenchyma-muscle interface, lifting anteriorly and pulling overlying tissue onto the retractor blade. Exposure for electrocautery forceps dissection to separate the pectoralis from the overlying parenchyma at the parenchyma-muscle interface in types II and III dual plane techniques.

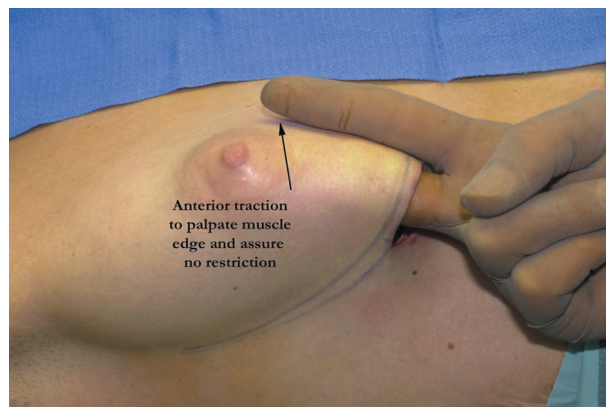


FIG. 14. Anterior traction for palpation to define the location of the inferior edge of the pectoralis and ensure no restriction to the anterior movement of the parenchyma and overlying envelope.

the overlying parenchyma with electrocautery forceps dissection in additional 1-cm increments superiorly. Recheck the free excursion anteriorly, and stop when the parenchyma moves anteriorly without restriction by the lower border of the pectoralis.

Implant placement follows basic guidelines, but it is imperative to bring the patient to a sitting position and to check the implant position. Regardless of implant type, the implant must be positioned adequately inferiorly, with its *inferior edge at the desired inframammary fold*. Leaving an implant in an excessively high position is a common error that precludes optimal results.

Through the periareolar approach in the type I dual plane procedure, dissection is carried over the breast parenchyma to the inframammary fold, where the pectoralis is divided as described previously for the inframammary approach. For types II and III procedures using the periareolar approach, dissection is directed through the breast parenchyma to the desired level of separation of the parenchyma from muscle, either the lower or upper border of the areola, respectively. When the muscle is visualized, dissection proceeds inferiorly in the retromammary plane to the desired new fold level, and the muscle is then divided 1 cm above the desired fold level to enter the subpectoral plane. When areolar asymmetry and/or pseudoherniation are a component of the breast deformity, the periareolar approach is the most logical to allow simultaneous correction of the areolar deformities.

The axillary incisional approach with endoscopic control is excellent for type I dual plane

procedures but impractical for types II and III. For type I, the pocket is created in the subpectoral plane with endoscopic assistance, and the pectoralis origins along the inframammary fold are then divided 1 cm above the desired fold with a needlepoint electrocautery endoscopic dissector.

#### CLINICAL EXPERIENCE AND RESULTS

A total of 468 patients (936 breasts) had dual plane augmentation between January of 1992 and March of 1998. All patients in this series underwent primary breast augmentation under general anesthesia as outpatients. All were female with an age range of 18 to 64 years (average, 28 years). In the series, 281 patients (60 percent) had type I breasts and received the type I dual plane procedure, 108 patients (23 percent) had type II breasts and received the type II procedure, and 79 patients (17 percent) had type III breasts and received the type III procedure.

The inframammary approach was used in 316 patients (67.5 percent), the periareolar approach in 55 patients (11.8 percent), and the axillary approach in 97 patients (20.7 percent). Round, textured silicone shell saline implants were used in 34 patients (7.3 percent); round, smooth shell saline implants were used in eight patients (1.7 percent); and textured, full-height anatomic saline implants (McGhan Style 468) were used in 426 patients (91 percent). The type of implant for all of the types I and II breasts was selected by patient choice. Patients with type III breasts were encouraged to select between a high-profile round implant and a high-profile anatomic implant.

Follow-up ranged from 3 months to 6 years. The patients were scheduled for follow-up at 2 days, 3 weeks, 3 months, and 1 year, and at 2-year intervals thereafter. Follow-up at 3 months was obtained in 92 percent of patients, at 6 to 23 months in 78 percent of patients, and at 2 years or longer in 46 percent of patients.

Results by breast type, graded according to

the criteria described previously, are listed in Table III. Representative results of corrections in four breast types using the three variations of dual plane techniques are shown in Figures 15 through 18.

#### Capsular Contracture

Ten patients (12 breasts) developed capsular contractures (two bilateral, eight unilateral) that were clinically significant with moderate-to-severe breast firmness, shape distortion and/or implant displacement, and discomfort (10 of 468 patients, 2.1 percent; 12 of 936 breasts, 1.3 percent). All were treated with complete capsulectomy (except on the posterior surface of the pectoralis) and placement of new implants. Two patients experienced a recurrence of the condition but received no additional surgery. One bilateral and four unilateral capsules (50 percent of the capsules) occurred in type III breasts, in which the implant was exposed to more parenchyma. Two capsules occurred with smooth implants (two of 16 breasts, 12.5 percent) in type II breasts, and the remaining 10 capsules occurred with textured implants (10 of 920 breasts, 1.1 percent).

#### Other Complications

Two hematomas occurred unilaterally, one in a patient with type III breasts who required extensive parenchymal scoring, the other in a patient with type II breasts (two of 936 breasts, 0.2 percent; two of 468 patients, 0.4 percent). No seromas occurred, and no patient developed visible rippling in any portion of the breast in the upright position. Six patients (six of 468, 1.3 percent) could demonstrate visible rippling laterally (traction rippling) when they leaned forward 90 degrees at the waist. Two of the six had round, smooth implants filled to the manufacturer's recommendations; one had a round, textured implant filled to the

TABLE III  
Results Graded by Breast Type

Breast Type	Grade 1: Excellent		Grade 2: Very Good		Grade 3: Satisfactory		Grade 4: Fair		Grade 5: Poor
	n	%	n	%	n	%	n	%	
I (n = 281)	107	38	132	47	42	15	0	0	0
II (n = 108)	37	34	42	39	28	26	1	1	0
III (n = 79)	21	26	46	58	10	13	2	3	0

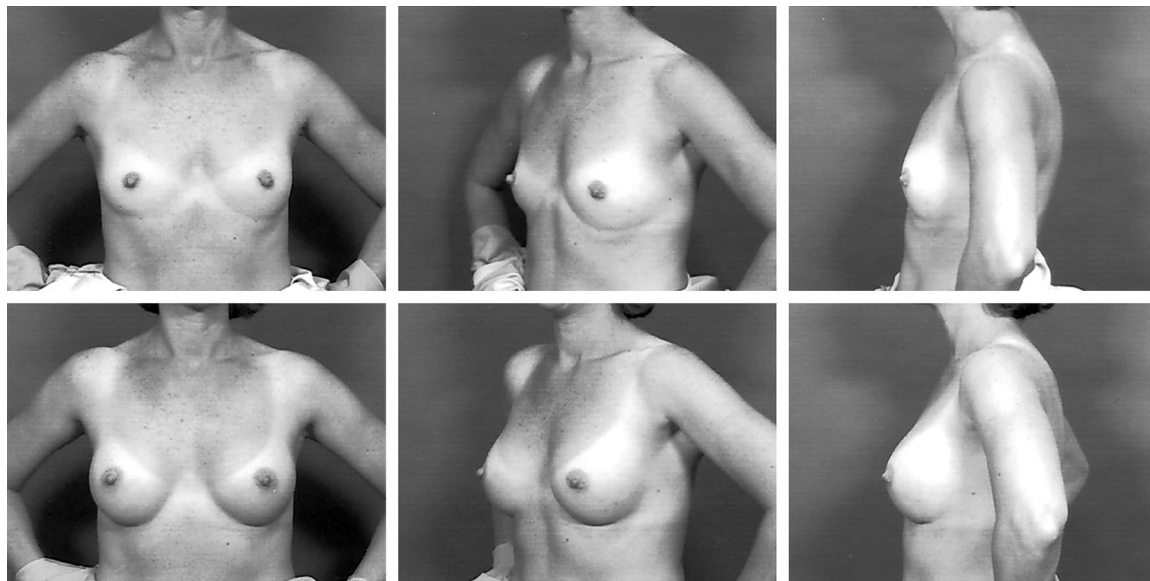


FIG. 15. Preoperative (*above*) and 20-month postoperative (*below*) views of an inframammary, type I dual plane augmentation in a 38-year-old, gravida 3, para 3 patient with McGhan Style 468 textured, anatomic implants, 240 cc bilaterally.

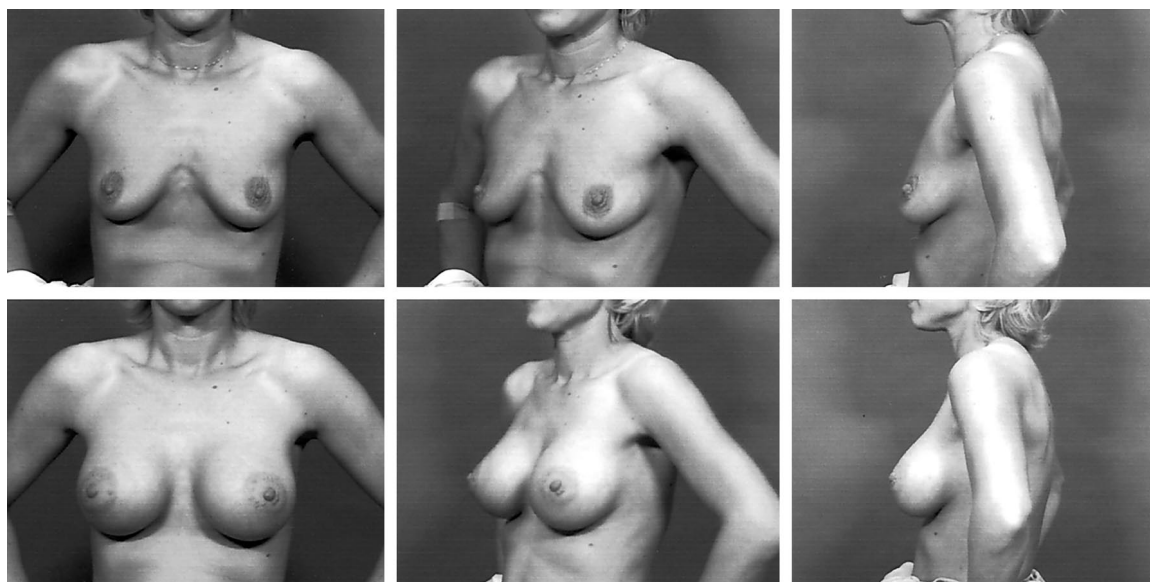


FIG. 16. Preoperative (*above*) and 28-month postoperative (*below*) views of an inframammary, type II dual plane augmentation in a 38-year-old, gravida 1, para 1 patient with McGhan Style 468 textured, anatomic implants, 285 cc bilaterally.

manufacturer's recommendations; and three had full-height textured, anatomic implants. Two unilateral infections occurred (two of 936 breasts, 0.2 percent; two of 468 patients, 0.4 percent). One infection (*Staphylococcus aureus*) occurred in a patient with type III breasts, and a second (*Staphylococcus epidermidis*) occurred in a patient with type II breasts. Both were treated with implant removal, and the infections resolved rapidly.

## DISCUSSION

### *Implant-Soft-Tissue Dynamics*

Implant-soft-tissue dynamics affect the short-term and long-term results of augmentation in both primary and reoperation cases. The implant exerts pressure on the overlying soft tissues to shape the breast. The overlying soft tissues exert counterpressure on the implant, depending on the compliance of the

envelope, the layers of tissue (parenchyma and/or muscle) interposed between implant and envelope, the projection and compliance (firmness) of the implant, and other factors such as genetic tissue characteristics. All patients' tissues age with time, usually becoming thinner and more compliant, which results in envelope stretch even without the additional weight of a breast implant. The interaction of tissue and implant forces over time, combined with the inevitable aging changes of the soft tissues, determines the long-term result in breast augmentation.

Placement of an implant in any pocket location initiates a complex series of events (anatomic, mechanical, and biological) that vary significantly from patient to patient over time. Wide anatomic variations exist in the soft-tissue envelope, parenchyma, and tissue interfaces between envelope and parenchyma and between parenchyma and underlying muscle, resulting in a wide range of breast types. The interaction of the implant with adjacent tissues in each of these widely varying breast types (implant-soft-tissue dynamics) varies in each patient according to anatomy, implant type, and soft-tissue characteristics. By *focusing on soft-tissue characteristics and implant-soft-tissue dynamics instead of selecting a single-technique solution for all breasts*, the surgeon can better select appropriate surgical techniques and adjust those techniques for optimal control and predictability in a wide range of breast types.

In general, a surgeon cannot change the genetic and aging characteristics of a patient's tissues. The surgeon can, however, recognize how these factors influence the choice of a breast implant to achieve optimal long-term results with minimal tradeoffs, risks, and compromises. Many of the limitations that are associated with each pocket location are mechanical. Modifications of tissue layers that contact the implant (the pocket) and implant selection allow adjustment of soft-tissue mechanics relative to the implant, enabling the surgeon to better control the implant-soft-tissue dynamics and the relative positions of the implant and soft tissues within the envelope. Controlling implant-soft-tissue dynamics short-term and long-term is a key to optimal long-term results.

#### *Implants*

Type I breasts do not require a highly projecting implant, and a wide variety of implants can produce satisfactory results. Types II and

III breasts with mobile parenchyma or constricted lower poles require a more projecting implant for optimal correction, because the implant must maximally expand the lower pole and/or provide projection for optimal nipple lift. Highly projecting round or anatomic implants provide better correction for breasts with highly mobile parenchyma, glandular ptotic breasts, and constricted lower pole breasts. Anatomic implants with a height slightly greater than their width provide better upper pole fill. Over the long term, any breast with a larger implant in a stretchy envelope will lose some upper fill.

#### *The Nulliparous Breast with Minimally Mobile Parenchyma*

In most nulliparous breasts or parous breasts with tight envelopes (Fig. 3) that require additional soft-tissue coverage superiorly (soft-tissue pinch thickness of the upper pole <2.0 cm), the surgeon can avoid many of the tradeoffs of partial retropectoral placement by completely dividing the origins of the pectoralis major from the lateral border of the pectoralis at the inframammary fold to the medial extent of the inframammary fold. Division of pectoralis origins across the inframammary fold reduces several tradeoffs associated with partial retropectoral placement:

1. Reduced pressure on the implant lower pole reduces the risk of superior displacement or malposition of the implant.
2. Pectoralis release decreases pressure on the upper implant to reduce lateral implant displacement over time.
3. The implant can rest more precisely at the lower border of the pocket, forming a deeper and more precise fold more quickly and obliterating dead space that can fill with fluid, undergo fibrous replacement, and cause fold distortions.

In exceedingly thin patients (soft-tissue pinch thickness at the inframammary fold <0.4 cm), the surgeon may elect to accept all of the potential tradeoffs listed above to maintain additional coverage at the inframammary fold level. Many current implants are designed with thicker shells for additional durability, and shell palpability (with or without lower pole muscle cover) is greater in both textured and smooth implants. Preserving the very thin layer of deep subcutaneous fascia when dividing the pectoralis origins along the inframam-

mary fold did not provide clinically significant coverage long-term in this series. Usually, exceedingly thin patients can feel the edges of any implant shell inferolaterally, whether or not the pectoralis origins are preserved, so in most cases, a palpable shell accepted preoperatively by the patient is preferable to the other potential tradeoffs of preserving muscle origins along the inframammary fold.

Therefore, in most nulliparous patients who need additional upper pole implant coverage, complete division of pectoralis origins along the inframammary fold with no undermining in the retromammary plane (type I dual plane) allows optimal accuracy and depth of the inframammary fold by allowing the inferior edge of the pectoralis to move superiorly 2 to 4 cm, decreasing pressure on the lower pole of the implant. In the type I breast, when the parenchyma is not sliding off the anterior surface of the pectoralis, it is unnecessary to further release the pectoralis by retromammary undermining to allow it to move more superiorly. The position of the parenchyma relative to the muscle remains the same in the middle and upper pole as the implant exerts pressure on the parenchyma through the overlying pectoralis. Clinically, in most cases, less breast distortion occurs with pectoralis contraction than when inferior origins are left intact. Although difficult to document, lateral implant displacement also seemed to occur less, but such factors as thickness of the lateral envelope and size of the implant complicate this determination.

“Bottoming” of the breast long-term seems to relate more to the genetic characteristics of the patient’s tissues and the size of the implant than to the integrity of pectoralis overlying the implant at the inframammary fold. In this series, dividing the pectoralis inferiorly did not increase the nipple-to-inframammary fold distance significantly in patients with similar-sized implants and tissue characteristics.

#### *The Parous Breast with Mobile Parenchyma*

In the routine parous breast (Fig. 4), implant–soft-tissue dynamics are similar to those of the nulliparous breast, except that the envelope is usually more compliant and the parenchyma is often softer. The parenchyma is often more mobile at the parenchyma-muscle interface and has a greater tendency to slide inferiorly off the anterior surface of the pectoralis

when the patient is upright. The advantages of a dual-plane approach with respect to the inframammary fold are similar to those in the nulliparous breast. Freeing some attachments at the parenchyma-muscle interface (freeing parenchyma from muscle) allows the inferior border of the pectoralis to move more superiorly to approximately the lower border of the areola. As a result, the implant has more contact with the parenchyma in the lower pole and therefore can place more direct pressure there to reduce any tendency to slide off the anterior surface of the pectoralis.

#### *The Breast with Highly Mobile Parenchyma: The Glandular Ptotic Breast*

In breasts with highly mobile parenchyma (Fig. 5), the parenchymal attachments to the pectoralis are insufficient to prevent the parenchyma from moving inferiorly in a stretched envelope. Inferior movement of the glandular tissue produces a glandular ptotic or truly ptotic breast. The larger the mass of breast parenchyma and the weaker the attachments to the pectoralis at the parenchyma-muscle interface, the more stretching force the parenchyma transmits to the lower pole skin envelope. As the lower skin envelope stretches, the distance from the nipple or from the inferior border of the areola to the inframammary fold increases. This distance, measured under maximal stretch, is an excellent objective parameter to assess the degree of ptosis and whether an implant or a mastopexy is likely to achieve the best correction. When the areola-to-inframammary-fold distance is 7 cm or less under *maximal stretch*, regardless of the position of the nipple relative to the inframammary fold, the ptosis can be corrected by an appropriate implant alone without mastopexy by using dual plane techniques. To optimally correct any degree of ptosis, the implant must adequately expand the pocket anteriorly, which requires an implant with adequate projection. Equally important is that the implant is wide enough to expand the pocket mediolaterally for optimal correction and the patient is willing to accept the tradeoffs of a larger implant that meets these criteria.

Optimal correction of glandular ptosis with an implant requires maximal contact of the anterior surface of the implant with the posterior surface of the parenchyma. With this degree of contact, an implant of adequate width and projection expands the lower-breast envelope

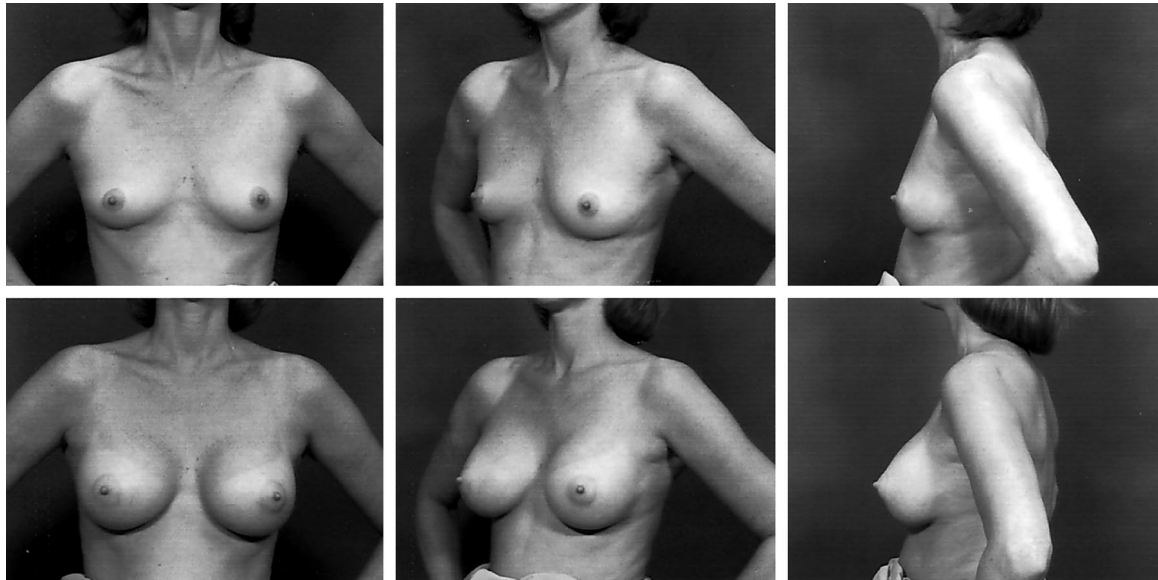


FIG. 17. Preoperative (*above*) and 24-month postoperative (*below*) views of an inframammary, type III dual plane augmentation in a 31-year-old, gravida 2, para 2 patient with McGhan Style 468 textured, anatomic implants, 315 cc bilaterally.

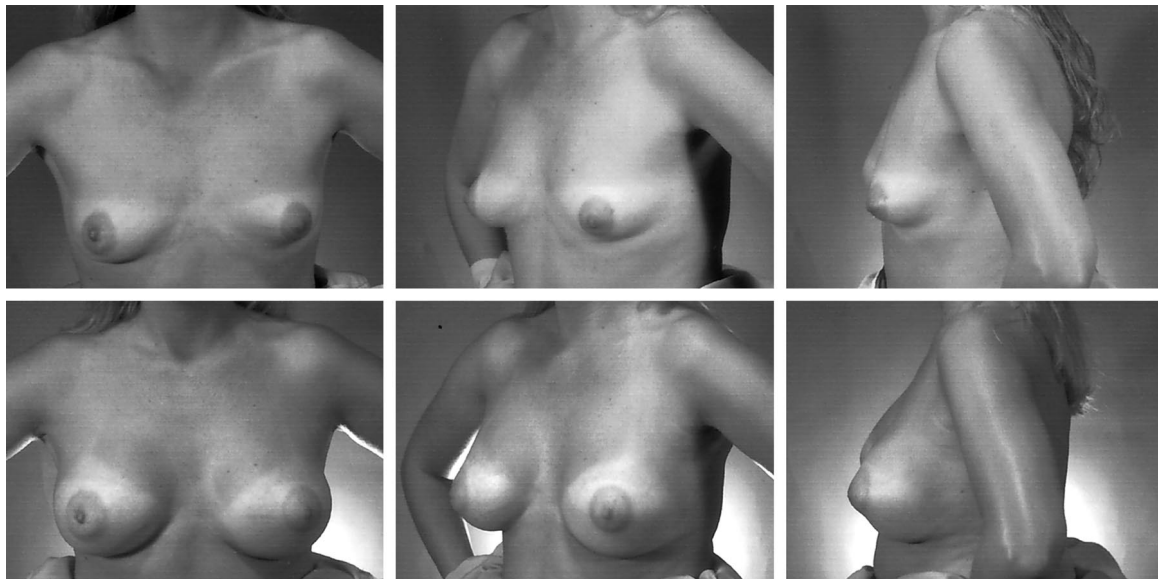


FIG. 18. Preoperative (*above*) and 20-month postoperative (*below*) views of a 24-year old, gravida 0, para 0 patient with breast asymmetry and a constricted lower pole left breast. The patient had an inframammary, type III dual plane augmentation with McGhan Style 468 textured, anatomic implants, 240 cc right, 270 cc left.

lope in all directions (Fig. 17). For this reason, and to avoid a double-bubble deformity, a retromammary placement has traditionally been the pocket of choice to correct glandular ptosis. As the envelope expands under the influence of an adequate base width and projection implant, the nipple position moves anterosuperiorly. Tradeoffs that the patient must accept are that (1) the nipple position will be higher, but the breast will not necessarily appear

higher on the torso; (2) a larger implant is required to fully expand the envelope for correction; and (3) a larger implant in a skin envelope that has already shown a tendency to stretch may require a mastopexy in the future.

Glandular ptosis in a *thin* patient (<2-cm pinch thickness superior to the parenchyma) presents the greatest challenge. A retromammary augmentation in this type of breast risks a visible implant edge or traction-rippling supe-



riorly or medially. A type III dual plane approach, by dividing pectoralis origins inferiorly and freeing the parenchyma-muscle interface up to approximately the superior border of the areola, accomplishes two objectives. First, it disrupts the parenchyma-muscle interface, so that the parenchyma can no longer slide inferiorly off the anterior pectoralis. Second, by allowing the muscle to retract superiorly, it allows maximal contact of the anterior surface of the implant with the parenchyma at the implant's point of maximal projection to provide an anterior force that "lifts" the nipple-areola complex. The pectoralis muscle no longer restricts maximal implant projection, and the implant can then optimally expand the lower-breast envelope for optimal correction while reducing the possibility of the parenchyma sliding off pectoralis and causing a double-bubble deformity.

#### *The Constricted Lower Pole Breast*

Constricted lower pole breasts represent a wide range of deformities, from mild constriction to a tubular or tuberous breast. Common characteristics are variable but often include (1) a narrow base width of the breast parenchyma; (2) constriction of the lower pole breast envelope mediolaterally, producing (3) a transversely short, often tight, and high inframammary fold; (4) varying degrees of areolar stretch or asymmetry caused by parenchymal pseudoherniation. Optimal correction must address all of these components of the deformity. Radial, and often concentric, parenchymal scoring are required to redistribute the centrally concentrated parenchyma and widen the base of the breast. The degree and depth of scoring required depend on the degree of deformity present. In severe deformities, radial and concentric parenchymal scoring completely through breast parenchyma and deep subcutaneous fascia may be necessary for optimal correction.

In a constricted lower pole breast, for optimal correction the implant must (1) increase the base width of the breast, (2) put pressure on the scored parenchyma to redistribute it over a wider base width of the implant, and (3) transmit pressure to stretch the lower pole skin envelope to expand the constricted area.

In a thin patient (<2 cm pinch thickness superior to the parenchyma) with a constricted lower pole breast, additional upper pole coverage is helpful to avoid visible implant edges or

possible rippling with saline implants. However, a retropectoral pocket location has been undesirable in the past, because the muscle restricts full expansion of the lower-breast envelope by the implant, the parenchyma is not redistributed and the old fold is not stretched, and a double-bubble deformity often results. With type III dual plane dissection, upper muscle coverage is preserved, but the inferior border of the pectoralis moves superiorly to the top of the areola, removing any muscle restriction of lower pole expansion. The surgeon has ideal access to the posterior surface of the parenchyma for scoring and redistribution, and an appropriate implant is more likely to optimally redistribute the parenchyma, expand the envelope, correct the constricted lower pole, and avoid the double-bubble deformity.

#### *Pectoralis Function and Appearance*

Pectoralis major muscle function postoperatively was evaluated only by examining the patient's history. The patients were encouraged to return to full normal activity immediately but to limit aerobic activity for 2 weeks. No patient in the series had drains or bandages postoperatively or reported any complaints related to pectoralis function. Many of the athletically active women, including professional athletes, in the series reported no functional compromise. The visible banding of the pectoralis at rest that sometimes occurs, with marked window-shading of the pectoralis, did not occur. Regardless of the degree of parenchyma-muscle interface separation, maintaining all medial pectoralis origins intact along the sternum to its junction with the inframammary fold definitely retards window-shading.

Dual plane techniques have limitations and tradeoffs. In glandular ptotic breasts, parenchyma may displace inferiorly despite disrupting the parenchyma-muscle interface and achieving optimal contact of the implant with parenchyma. If adequate implant pressure is not present (an implant with inadequate projection or width) or the parenchyma slides at the parenchyma-capsule interface, parenchyma can displace inferiorly. This occurred in two patients with type III breasts in the series. The capsular contracture rate was definitely higher in more severely constricted lower pole breasts that required maximal, radial, and concentric deep parenchymal scoring to redistribute parenchyma and correct the deformity. Decreased soft-tissue coverage from dividing

pectoralis origins along the fold has benefits and tradeoffs.

#### CONCLUSIONS

1. Dual plane augmentation mammoplasty is a logical approach to realize the benefits of retromammary and partial retropectoral implant placement while minimizing the tradeoffs of each pocket location, and the technique offers surgeons increased versatility in augmentation mammoplasty.
2. Dual plane augmentation improves implant–soft-tissue relationships by adjusting the positions of the pectoralis muscle and breast parenchyma relative to the implant to optimize implant–soft-tissue dynamics.
3. Dual plane augmentation techniques add surgical options for more predictable correction of breasts with highly mobile parenchyma, glandular ptotic breasts, and constricted lower pole breasts.
4. Dual plane augmentation techniques allow the surgeon to take advantage of additional soft-tissue coverage provided by the pectoralis major superiorly while reducing the tradeoffs of a purely partial retropectoral or total submuscular pocket location.

*John B. Tebbetts, M.D.*  
2801 Lemmon Avenue West  
Suite 300  
Dallas, Texas 75204  
[jbt@plastic-surgery.com](mailto:jbt@plastic-surgery.com)

#### REFERENCES

1. Cronin, T. D., and Gerow, R. M. Augmentation mammoplasty: A new “natural feel” prosthesis. In *Translations of the Third International Congress of Plastic Surgery*. Amsterdam: Excerpta Medica, 1964. Pp. 41–49. Excerpta Medica International Congress Series, No. 66.
2. Griffiths, C. O. The submuscular implant in augmentation mammoplasty. In *Translations of the Fourth International Congress of Plastic Surgery*. Amsterdam: Excerpta Medica Foundation, 1967. P. 1009.
3. Dempsey, W. C., and Latham, W. D. Subpectoral implants in augmentation mammoplasty: Preliminary report. *Plast. Reconstr. Surg.* 42: 515, 1968.
4. Regnault, P. Partially submuscular breast augmentation. *Plast. Reconstr. Surg.* 59: 72, 1977.
5. Mahler, D., Ben-Yakar, J., and Hauben, D. J. The retropectoral route for breast augmentation. *Aesthetic Plast. Surg.* 6: 237, 1982.
6. Tebbetts, J. B. Transaxillary subpectoral augmentation mammoplasty: Long-term follow-up and refinements. *Plast. Reconstr. Surg.* 74: 636, 1984.
7. Mladick, R. A. “No-touch” submuscular saline breast augmentation technique. *Aesthetic Plast. Surg.* 17: 183, 1993.
8. Papillon, J. Pros and cons of subpectoral implantation. *Clin. Plast. Surg.* 3: 321, 1976.
9. Pickrell, K. L., Puckett, C. L., and Given, K. S. Subpectoral augmentation mammoplasty. *Plast. Reconstr. Surg.* 60: 325, 1977.
10. Truppman, E. S., and Ellenby, J. D. A 13-year evaluation of subpectoral augmentation mammoplasty. In J. Q. Owsley and R. A. Peterson (Eds.), *Symposium on Aesthetic Surgery of the Breast*. St. Louis: Mosby, 1978.
11. Seckel, B. R., and Costas, P. D. Total versus partial musculofascial coverage for steroid-containing double-lumen breast implants in augmentation mammoplasty. *Ann. Plast. Surg.* 30: 296, 1993.
12. Spear, S. L., Matsuba, H., and Little, J. W., III. The medial periareolar approach to submuscular augmentation mammoplasty under local anesthesia. *Plast. Reconstr. Surg.* 84: 599, 1989.
13. Biggs, T. M., and Yarish, R. S. Augmentation mammoplasty: Retropectoral versus retromammary implantation. *Clin. Plast. Surg.* 15: 549, 1988.
14. Biggs, T. M., and Yarish, R. S. Augmentation mammoplasty: A comparative analysis. *Plast. Reconstr. Surg.* 85: 368, 1990.
15. Biggs, T. M., Cukier, J., and Worthing, L. F. Augmentation mammoplasty: A review of 18 years. *Plast. Reconstr. Surg.* 69: 445, 1982.
16. Mahler, D., and Hauben, D. J. Retromammary versus retropectoral breast augmentation: A comparative study. *Ann. Plast. Surg.* 8: 370, 1982.
17. Vazquez, B., Given, K. S., and Houston, G. C. Breast augmentation: A review of subglandular and submuscular implantation. *Aesthetic Plast. Surg.* 11: 101, 1987.
18. Tebbetts, J. B. Patient acceptance of adequately filled breast implants using the tilt test. *Plast. Reconstr. Surg.* 106: 139, 2000.