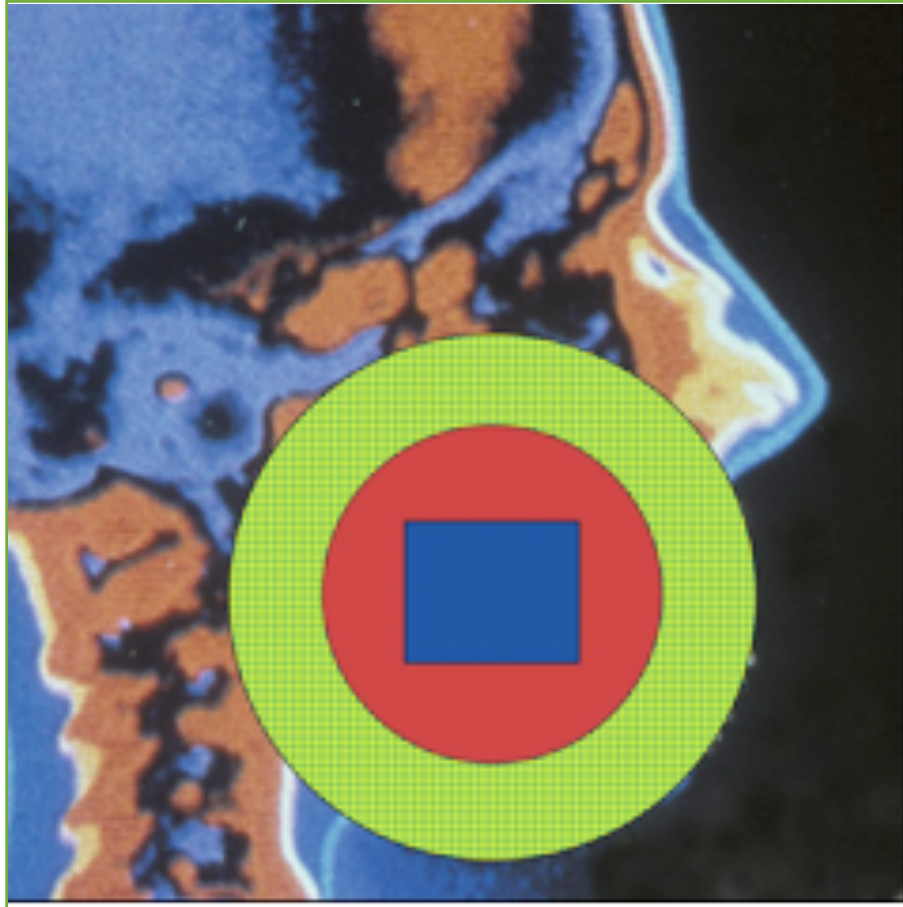


A SPECIAL REPORT

RECTANGULAR COLLIMATION

No longer a matter of choice!



Robert Langlais DDS MS FACD University of Texas San Antonio, Texas

This Special Report is made available by Interactive Diagnostic Imaging, LLC (IDI). IDI is an innovative product/software developer whose mission is to significantly improve dental diagnostics and patient oral health. Their goal is to increase the dental professions knowledge about advances in the technology and applications of x-rays.



Interactive Diagnostic Imaging


Interactive Diagnostic Imaging, LLC
659 Auburn Ave NE, Suite 155
Atlanta, GA 30312

Toll-Free: 855-IDI-XRAY
Fax: 888-707-6743
www.idixray.com

TABLE OF CONTENTS

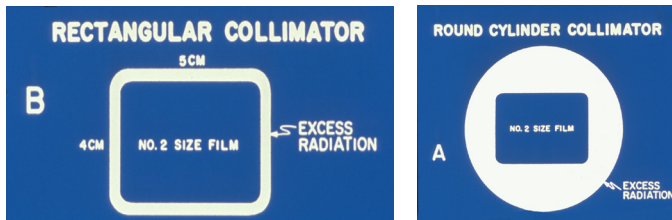
1. What is rectangular collimation?
2. Why is rectangular collimation no longer a matter of choice?
3. What are the advantages of rectangular collimation?
4. How is the X-ray beam positioned for rectangular collimation?
5. What is the proper beam filtration setting?
6. Are there any disadvantages to rectangular collimation?
7. How does this impact on my current intraoral x-ray equipment?
8. What ways are there available to convert my existing intraoral x-ray machines?
9. How does this affect current intraoral x-ray exposure techniques?
10. Are film holder-beam indicating devices needed?
11. Is rectangular collimation the same for film based and digital intraoral systems?
12. What sources are available for rectangular collimation conversion devices?
13. What are the costs of conversion to rectangular collimation?
14. Are there alternatives to the conversion of existing machines?
15. Appendix: Guidelines for prescribing dental radiographs.

1. WHAT IS RECTANGULAR COLLIMATION?



Collimation means restriction of the x-ray beam to a certain size as specified by federal law. This is done by means of a collimator, either at the tube head or at the end of the beam indicating device (cone). Until recently the beam needed to be collimated to a circle at the patient's skin no greater than 7 cm or 2.75 inches in diameter. Rectangular collimation is a further restriction of the beam size to approximately the size of a #2 periapical film or similar sized digital sensor.

2. WHY IS RECTANGULAR COLLIMATION NO LONGER A MATTER OF CHOICE?



Rectangular collimation has been widely available for many decades but has not found significant acceptance in the dental office in spite of being taught in the majority of educational institutions. The National Council on Radiation Protection (NCRP) published a report on December 31, 2003 (NCRP Report #145) and states in part: "Rectangular collimation of the beam shall be routinely used for periapical radiography. Each dimension of the beam, measured in the plane of the receptor, should not exceed the dimension of the receptor by more than two percent of the source-to-image receptor distance. Similar collimation should be used, when feasible, for interproximal (bitewing) radiography." NCRP Reports are the foundation upon which the Federal and State regulatory agencies base their regulations.

3. WHAT ARE THE ADVANTAGES OF RECTANGULAR COLLIMATION?

There are two major advantages of rectangular collimation.

A) Reduction of radiation dose to patient.

The published absorbed doses as calculated at The University of Texas at San Antonio Dental School and as quoted here are in the newer microgray units. One (1) microgray equals 0.1 millirads.

The FMX consists of a 20 film full mouth intraoral survey using E speed film. The BWs consist of 4 bitewings using E speed film. The PAN is a panoramic radiograph using T-Mat G film combined with a green sensitive 400 speed screen. Also round signifies a long round cone or BID and rectangular signifies a long rectangular cone. For the purposes of this report the absorbed doses to several anatomic regions are cited, however the pattern is similar to most of the jaws and surrounding tissues.

Here are some often cited sites:

Bone Marrow of the Mandible:

FMX round: 7090

FMX rectangular: 2539

BWs round: 2545

BWs rectangular: 555

PAN: 587

Parotid Gland:

FMX round: 5236

FMX rectangular: 859

BWs round: 2439

BWs rectangular 611

PAN: 670

Equivalent Whole Body Bone Marrow

Dose: FMX round: 143

FMX rectangular: 43

BWs round: 40

BWs rectangular 9

PAN: 12

Thyroid Gland:

FMX round: 628 with collar

FMX rectangular: 270 with collar

BWs round 232 with collar

BWs rectangular: 38 with collar

PAN: 47 without collar

Sublingual Gland:

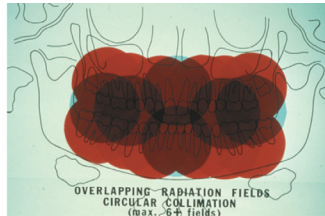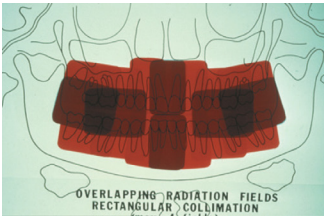
FMX round: 7833

FMX rectangular: 3490

BWs round: 2606

BWs rectangular 484

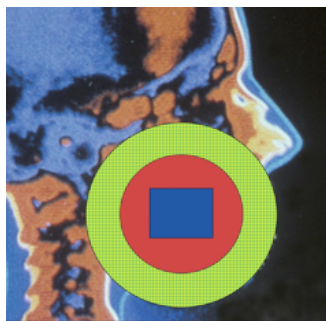
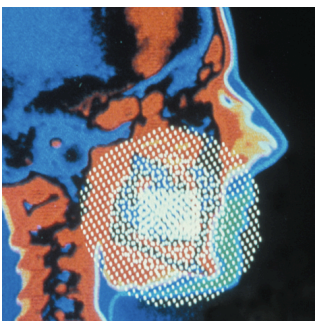
PAN: 134



Generally, it can be said that when going from the round cone to the rectangular cone, the overall absorbed dose for the FMX can be reduced by a factor of 2-3 times, or 200%-300%. Dental radiation sources have been implicated in the development of malignant parotid gland tumors and as can be seen rectangular collimation reduces the dose to this area six-fold. It may also be said that the FMX using rectangular collimation delivers about the same radiation dose as 4 bitewings using a round BID. It may also be said that a PAN delivers about the same dose as 4 BWs using rectangular collimation.



In terms of cancer risk calculations, the probability that radiation-induced cancer will develop ranges from 7.1 to 17 cases per million examinations using the long round cone and E speed film. The risk for the same examination, using the long rectangular cone, is 2.5 to 6.6 cancers per million examinations. This shows a risk reduction of approximately 61%. Notice the reduction in cancer risk is in the same proportion as the reduction in dose with rectangular collimation. Note: A reduction of 20% in the reported doses with E speed film can be obtained with F speed film and filtration of the PAN beam by placing a small piece of rare earth screen material over the slit at the tube head. This reduces PAN radiation doses as listed here by 20-40%.



B) Increased contrast and clarity.

The second advantage of rectangular collimation is that the rectangular cone reduces scatter radiation thereby increasing image contrast. Scatter radiation adds unwanted and non-diagnostic scattered photons of radiation to the image and this in turn produces a degradation in the inherent image quality by decreasing the contrast. This added bonus of rectangular collimation applies equally to both film and all types of digital sensors.

4. HOW IS THE X-RAY BEAM POSITIONED FOR RECTANGULAR COLLIMATION?

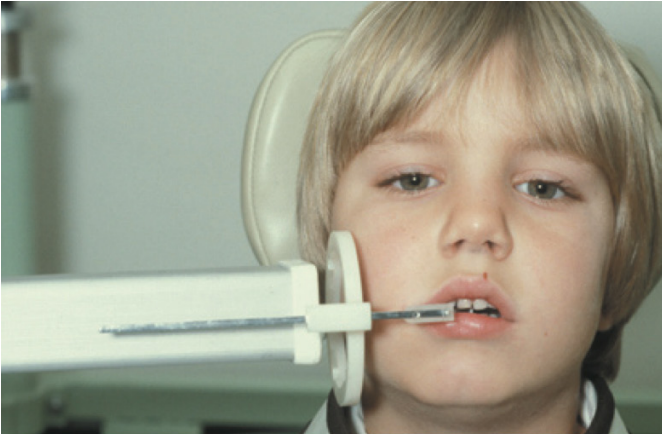The tissue area (and volume) exposed to the primary x-ray beam should not exceed the minimum coverage consistent with meeting diagnostic requirements and clinical feasibility. Proper collimation restricts the amount of primary radiation to the patient for periapical and bitewing radiography, rectangular collimation should be used whenever possible because a round field beam (as produced by open, round collimators) used with a rectangular image receptor produces segments of the beam circle that are not used in receptor exposure, which causes unnecessary radiation exposure to the patient. Round collimation delivers three to four times the absorbed radiation of rectangular collimation.^{10,13} Moreover, the position-indicating device, or PID, should be shielded and open-ended to further approximate beam size to the size of the image receptor and thus limit radiation exposure to patients and staff. Rectangular collimation of the beam can be obtained by replacing the round PID with a rectangular one, attaching a special rectangular collimating plate to the end of the round PID or using a film holder that incorporates a metal shield to block radiation beyond the edges of the film. Individual state regulations stipulate the maximum size of the x-ray beam. Supplemental beam collimation may be used to contain the size of the beam to that of the dental film or digital receptor.

5. WHAT IS THE PROPER BEAM FILTRATION SETTING?

Beam filtration should comply with federal and state regulations. The most judicious use of filtration involves selective filtration of excessively high-energy and excessively low-energy radiation. A kilovoltage best suited to the diagnostic purpose should be used. The range of 70 to 100 kilovolt peak, or kVp, is suitable for most purposes. A kVp below 70, however, can deliver unnecessarily high radiation doses. Within this range, lower kilovoltages are associated with higher-contrast images, shorter gray scale, higher entrance skin doses, lower deep-tissue doses, and lower levels of scattered radiation. Higher kilovoltages, associated with lower-contrast images but longer gray scale, enable a better separation of objects of different densities. Higher kilovoltages also provide lower entrance skin doses, higher deep-tissue doses and higher levels of scattered radiation.

In the United States, x-ray machine manufacturers are required to install internal aluminum beam filters in all x-ray units. Rare-earth beam filters may be added for supplemental use to further remove higher energy radiation from the beam and reduce patient exposure.

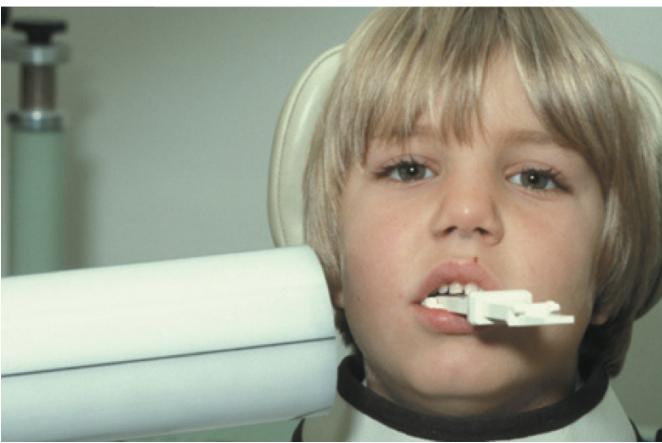6. ARE THERE ANY DISADVANTAGES TO RECTANGULAR COLLIMATION?



Actually, there are no real disadvantages of using rectangular collimation as educators have been teaching the technique for many years without any difficulty or complaint from the students. However, the following factors are to be considered:

The need to use a beam or position indicating device:

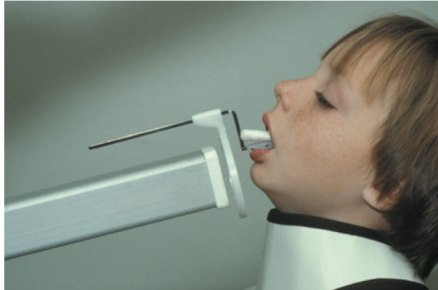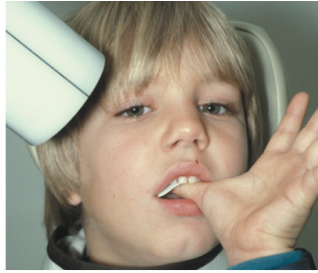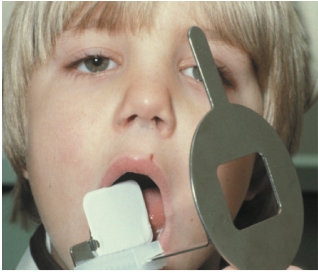This usually consists of a film / sensor holder and a movable ring on a shaft to position and align the BID or cone. This actually assures better results than "point-and-shoot" techniques, as proper film / sensor and beam alignment are assured which in turn produces optimal image quality. If a round cone is already in use with a beam alignment device, there is no change in the technique, except that a rectangular "ring" or a round ring with rectangular inserts is used with the new rectangular cone.



7. HOW DOES RECTANGULAR COLLIMATION IMPACT ON MY CURRENT INTRAORAL X-RAY EQUIPMENT?

There is certainly no reason to consider buying a whole new x-ray machine(s). There are two factors to consider: First, the need to collimate the beam to about the size of the film or receptor / sensor. Second, some means must be available to aim and align the beam, as "point-and-shoot" techniques will most likely result in alignment errors and most certainly "cone cuts". Devices, such as the IDI Tru-Image® position indicating instrument and the Rinn XCP® position indicating instruments, are readily available for this purpose.

8. HOW CAN I CONVERT MY EXISTING INTRAORAL X-RAY MACHINES?



Regarding the conversion of existing x-ray machines there are three basic methods: The first method is the use of a position indicating device with the round cone and which collimates the beam at the skin surface. This device is made of metal and is called the Masel Positioning Instrument. The second method is converting a round cone to rectangular collimation by slipping a collimator on the end of the round cone. The collimator itself will rotate at its base in order to properly align the now rectangular beam with the film/sensor. The third method is the use of a rectangular cone or BID. This method has been used for at least 20 years by the University of Texas Health Science Center at San Antonio. We replace the existing round cone with a rectangular cone. This cone must also rotate at its base where it attaches to the tube head in order to align the rectangular beam with the film/sensor. Rectangular cones, designed to adapt to most models of x-ray machines even those 25 and 30 years old, are available.

9. HOW DOES THIS AFFECT CURRENT INTRAORAL X-RAY EXPOSURE TECHNIQUES?

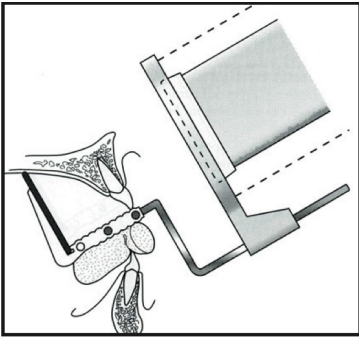
Collimating the x-ray beam does not alter the exposure times for a given film or sensor type. It does, however, require the use of a film-holding and beam alignment device.

10. ARE FILM HOLDER-BEAM INDICATING DEVICES NEEDED?

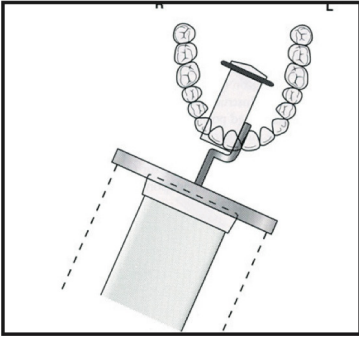
Yes. Film holder-beam indicating devices are needed for the following reasons:

A) To avoid "cone cuts" and retakes: As was stated, the "point and shoot" techniques can no longer be used with a highly collimated beam, as positive accurate alignment of the beam is needed to avoid "cone cuts".

B) To align the rectangular beam to the vertical orientation of the film/sensor: Rectangular cones must be designed with a capability to rotate at the base or in some other way. The beam indicating device indicates the exact orientation of the film/sensor in the vertical plane. Thus, the rectangular cone can be rotated to exactly match the vertical orientation of the rectangular film packet or sensor.



C) To get the resulting improved image quality when beam alignment devices are used: Geometric factors such as parallelism of the film / sensor and the teeth and the perpendicularity of the beam to both the teeth and to the film / sensor are optimized. This produces more accurate images in terms of minimizing inaccurate relationships of one structure to another, foreshortening, elongation, distortion, and the overlap of structures such as the contact points.



11. IS RECTANGULAR COLLIMATION THE SAME FOR FILM BASED AND DIGITAL INTRAORAL SYSTEMS?

Yes. However practitioners will need to be certain the position indicating device bite block can accommodate the digital sensor. For example, Photostimulable Phosphor Plates (PSPs) are extremely susceptible to scratching with routine placement into the bite block. Electronic sensors with a wire such as the Charge Coupled Device (CCD) or Complimentary Metal Oxide Sensor (CMOS) all have varying thicknesses and slight differences in size, so the bite block must be designed to accommodate the specific sensor and the wire. Wireless sensors are a little bulkier thus a specific holder will be needed.

12. WHAT SOURCES ARE AVAILABLE FOR RECTANGULAR COLLIMATION CONVERSION DEVICES?

Several devices are available from your local dental dealer. Ask your dealer for information about any of the following products: Masel film holder and positioning device, Rinn Rectangular collimator, Margraf Rectangular cone, and IDI Tru-Image Retrofit Kit.

13. WHAT ARE THE COSTS OF CONVERSION TO RECTANGULAR COLLIMATION?

Approximately \$500-\$1000.

14. ARE THERE ALTERNATIVES TO THE CONVERSION OF EXISTING MACHINES?

Yes. Here are some possibilities:

A) Purchase a new factory-equipped intraoral machine.

Manufacturers will soon be supplying machines with factory mounted rectangular cones, most likely at no or slight extra cost. This idea should be considered if the office is converting to digital imaging, as best results are obtained with new machines having the following two features:

- direct current (DC) type generators which produce a very homogeneous (less non-penetrating short wave length x-ray photons) beam in terms of wave length and reduce the radiation dose by about 20%
- faster timers capable of exposure intervals calibrated in 1/100th of a second to meet the need for short accurate exposures.

B) Wait for the arrival of the portable hand-held intraoral x-ray “camera”. This machine is currently under development and being tested at the University of Texas Health Science Center at San Antonio Dental School. Ideally, this machine would be used in conjunction with an advanced function digital PAN machine. Some of the planned features include:

- Light weight; about 6 pounds
- Integrated rectangular cone and sensor holder
- Instant image viewing of the x-ray image on the “camera” back like a digital camera
- Excellent object alignment due to the integrated sensor holder-beam alignment device affixed to the standard rectangular cone
- Wireless image transmission to viewing screens or the patient’s chart
- High-quality intraoral image due to enhanced positioning and tube head design
- Reduced x-ray equipment cost, as only one “x-ray camera” is needed per office
- Less sensor breakage due to the supplied neck strap support
- Enhanced esthetics/improved office design as no machine hangs on the wall

GUIDELINES FOR PRESCRIBING DENTAL RADIOGRAPHS

The recommendations in this chart are subject to clinical judgment and may not apply to every patient. They are to be used by dentists only after reviewing the patient's health history and completing a clinical examination. Because every precaution should be taken to minimize radiation exposure, protective thyroid collars and aprons should be used whenever possible. This practice is strongly recommended for children, women of childbearing age and pregnant women.

TYPE OF ENCOUNTER	PATIENT AGE AND DENTAL DEVELOPMENTAL STAGE			
	Child with Primary Dentition (prior to eruption of first permanent tooth)	Child with Transitional Dentition (after eruption of first permanent tooth)	Adolescent with Permanent Dentition (prior to eruption of third molars)	Adult, Dentate or Partially Edentulous
New patient* being evaluated for dental diseases and dental development	Individualized radiographic exam consisting of selected periapical/occlusal views and/or posterior bitewings if proximal surfaces cannot be visualized or probed. Patients without evidence of disease and with open proximal contacts may not require a radiographic exam at this time.	Individualized radiographic exam consisting of posterior bitewings with panoramic exam or posterior bitewings and selected periapical images.	Individualized radiographic exam consisting of posterior bitewings with panoramic exam or posterior bitewings and selected periapical images. A full mouth intraoral radiographic exam is preferred when the patient has clinical evidence of generalized dental disease or a history of extensive dental treatment.	Individualized radiographic exam, based on clinical signs and symptoms.
Recall patient* with clinical caries or at increased risk for caries**	Posterior bitewing exam at 6-12 month intervals if proximal surfaces cannot be examined visually or with a probe	Posterior bitewing exam at 12-24 month intervals if proximal surfaces cannot be examined visually or with a probe	Posterior bitewing exam at 6-18 month intervals	Not applicable
Recall patient* with no clinical caries and not at increased risk for caries**	Posterior bitewing exam at 12-24 month intervals if proximal surfaces cannot be examined visually or with a probe	Posterior bitewing exam at 18-36 month intervals	Posterior bitewing exam at 24-36 month intervals	Not applicable

GUIDELINES FOR PRESCRIBING DENTAL RADIOGRAPHS, cont'd.

TYPE OF ENCOUNTER	PATIENT AGE AND DENTAL DEVELOPMENTAL STAGE			
	Child with Primary Dentition (prior to eruption of first permanent tooth)	Child with Transitional Dentition (after eruption of first permanent tooth)	Adolescent with Permanent Dentition (prior to eruption of third molars)	Adult Dentate and Partially Edentulous
Recall patient* with periodontal disease	Clinical judgment as to the need for and type of radiographic images for the evaluation of periodontal disease. Imaging may consist of, but is not limited to, selected bitewing and/or periapical images of areas where periodontal disease (other than nonspecific gingivitis) can be identified clinically.			Not applicable
Patient for monitoring of growth and development	Clinical judgment as to need for and type of radiographic images for evaluation and/or monitoring of dentofacial growth and development		Clinical judgment as to need for and type of radiographic images for evaluation and/or monitoring of dentofacial growth and development. Panoramic or periapical exam to assess developing third molars	Usually not indicated
Patient with other circumstances including, but not limited to, proposed or existing implants, pathology, restorative/endodontic needs, treated periodontal disease and caries remineralization	Clinical judgment as to need for and type of radiographic images for evaluation and/or monitoring in these circumstances.			

***Clinical situations for which radiographs may be indicated include but are not limited to:**

A. Positive Historical Findings

1. Previous periodontal or endodontic treatment
2. History of pain or trauma
3. Familial history of dental anomalies
4. Postoperative evaluation of healing

5. Remineralization monitoring
6. Presence of implants or evaluation for implant placement

B. Positive Clinical Signs/Symptoms

1. Clinical evidence of periodontal disease
2. Large or deep restorations
3. Deep carious lesions
4. Malposed or clinically impacted teeth
5. Swelling
6. Evidence of dental/facial trauma
7. Mobility of teeth
8. Sinus tract ("fistula")
9. Clinically suspected sinus pathology
10. Growth abnormalities
11. Oral involvement in known or suspected systemic disease
12. Positive neurologic findings in the head and neck
13. Evidence of foreign objects
14. Pain and/or dysfunction of the temporomandibular joint
15. Facial asymmetry
16. Abutment teeth for fixed or removable partial prosthesis
17. Unexplained bleeding
18. Unexplained sensitivity of teeth
19. Unusual eruption, spacing or migration of teeth
20. Unusual tooth morphology, calcification or color
21. Unexplained absence of teeth
22. Clinical erosion

****Factors increasing risk for caries may include but are not limited to:**

1. High level of caries experience or demineralization
2. History of recurrent caries
3. High titers of cariogenic bacteria
4. Existing restoration(s) of poor quality
5. Poor oral hygiene
6. Inadequate fluoride exposure
7. Prolonged nursing (bottle or breast)
8. Frequent high sucrose content in diet
9. Poor family dental health
10. Developmental or acquired enamel defects

11. Developmental or acquired disability
12. Xerostomia
13. Genetic abnormality of teeth
14. Many multisurface restorations
15. Chemo/radiation therapy
16. Eating disorders
17. Drug/alcohol abuse
18. Irregular dental care