

Review articles

Venomous jellyfish of the world

Peter J Fenner

Key words

Envenomation, marine animals, jellyfish, review article

Abstract

(Fenner PJ. Venomous jellyfish of the world. *SPUMS J.* 2005; 35: 131-8.)

Jellyfish envenomation is far more common around the world than is realised. Although the vast majority of jellyfish stings are somewhat benign, there are some venomous species that regularly account for both deaths and severe morbidity in humans. Venomous jellyfish occur mainly in tropical and subtropical oceans. This article discusses relevant information on their appearance, distribution, and symptoms of envenomation, and first-aid and medical treatments for their stings.

General classification of jellyfish

There are three main classes of jellyfish that pose a threat to humans: scyphozoans, cubozoans, and hydrozoans.¹

SCYPHOZOANS (CLASS SCYPHOZOA)

These are the 'true' jellyfish. Members of this group are common worldwide. They have tentacles arising at regular intervals all around the bell (and often within the bell), i.e., they are 'radially' arranged.

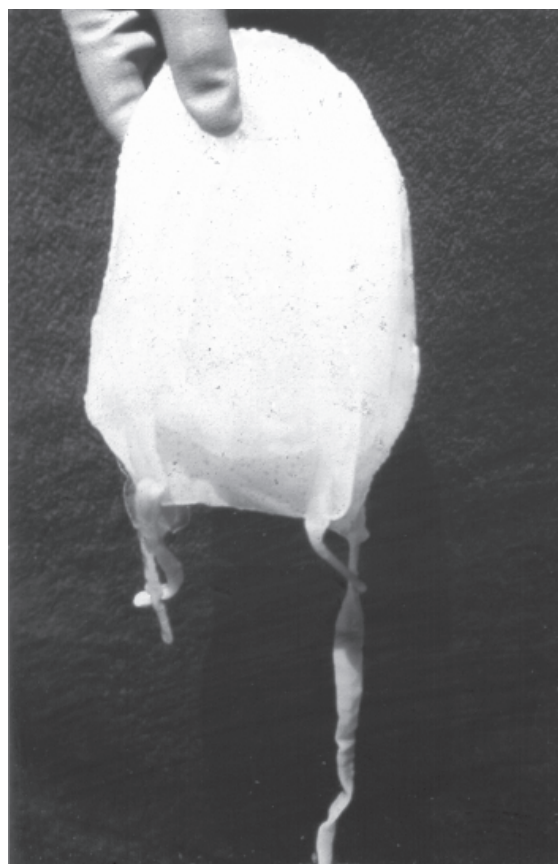
CUBOZOANS (CLASS CUBOZOA)

These are the 'box' jellyfish. Cubozoans are the most dangerous jellyfish and have caused hundreds, possibly thousands, of human deaths in tropical and subtropical waters worldwide.¹ They are shaped like a box (or cube) with tentacles arising only from the lower corners. There are two subgroups, or families within the class of cubozoans:

- **Carybdeids** – that have just one tentacle in the corner of each bell (Figure 1). They come in sizes ranging from a few millimetres to 500 mm bell height. Their stings cause symptoms varying from mild skin irritation to severe systemic symptoms; neither the size of the jellyfish, nor the size of the sting has any relation to the severity of the symptoms. There is one small species in Australia (the 'Irukandji') that has caused fatalities; otherwise the sting usually causes moderate to severe skin pain and possibly severe systemic symptoms in some species.
- **Chirodropids** – that have more than one and up to 15 tentacles arising from the corner of each bell (Figure 2). The bell may be up to 300 mm in diameter and the tentacles may reach up to 3 m in length. These jellyfish give severe stings and regularly cause human deaths each year (Table 1.) There are at least ten identified but

certainly more species of chirodropid worldwide. Unfortunately the original specimen, described as *Chiropsalmus quadrigatus* and caught by Haeckel in 1880,² was immature and its description fits many chirodropids in various parts of the world, although

Figure 1
 'Morbakka' from subtropical east coast of Australia, typical of 'large' carybdeid (cubozoan); 14 cm high, 10 cm width; painful welts ("fire jelly"); may cause mild Irukandji reaction in about 10% of cases



comparison of finer structures shows them to be different species. Thus many jellyfish in the western Indo-Pacific oceans that are basically different all bear the name *Chiropsalmus quadrigatus*. Fortunately all appear to cause similar, if not identical symptoms. Thus the first-aid and medical treatments suggested should prove effective for all chirodropid envenomations regardless of geographical location (see below).

'OTHER JELLYFISH' (CLASS *HYDROZOA*)

Members of this group are not actually jellyfish, although they resemble them, and are best dealt with as such. This group includes the siphonophore *Physalia sp.*, commonly known as the 'Portuguese man-of-war' and *Gonionemus sp.*, a small hydrozoan, which causes sting problems in the Sea of Japan.

The number of all jellyfish envenomations worldwide is measured in the millions; however, fortunately there is usually little need to identify the species of jellyfish. All cause skin pain that varies from a very mild irritation through to the severe, unbearable pain of a multi-tentacled box jellyfish sting. This skin pain can be treated simply, using the first-aid protocols suggested below.

Some jellyfish envenomations may cause systemic symptoms, including generalised muscle pains, painful breathing, breathing difficulty or breathlessness, anxiety, sweating, high blood pressure, heart failure, and even death, albeit rarely.³⁻⁶ Current geographical locations of human deaths from jellyfish are shown in Table 1.

Jellyfish causing human fatalities

CHIRODROPIDIS (MULTI-TENTACLED BOX JELLYFISH)

Envenomation

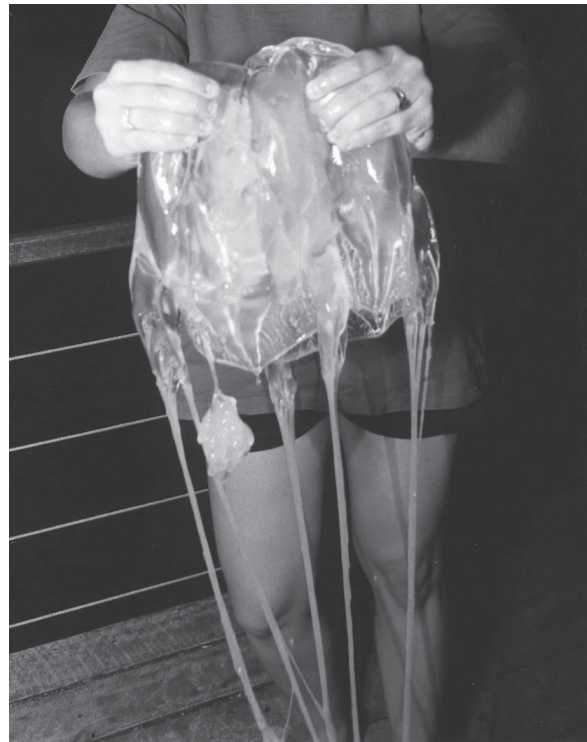Envenomation usually occurs in shallow water. Severe stings occur more often in women and young children, who are smaller and relatively hairless. Hair can prevent more intimate tentacle contact, and consequently reduce envenomation.

Chirodropids swim into shallow water when the wind is light and hot, and the water is calm. Unsuspecting victims frequently walk, or run, into tentacles trailing behind the transparent jellyfish bell, both of which are difficult to see in the water, with the tentacles being almost invisible. Most stings occur on the lower legs and body, as the unsuspecting victim enters the water.

Pain is instant and savage; the victim usually screams with the pain. Children, when stung, often stand in the water, picking at the tentacles and getting stung on the hands and arms, consequently increasing the envenomation, whilst adults frequently run out of the water, increasing the heart rate and circulation and thus the speed of venom absorption.

Figure 2

***Chironex fleckeri* – 30 cm diameter specimen caught off beach in north Queensland. Although stinging cells are not present on the bell and it can be held without being stung, wearing shorts (especially in a wind) with some 60 tentacles up to 3 metres in length nearby is not a recommended procedure!**



If the tentacles are rubbed, the stinging cells are compressed, causing further nematocyst discharge and thus increasing envenomation.

Adherent tentacles look like sticky threads on the skin of the victim; tentacle marks look like the victim has been whipped, or branded with irons.¹ If the victim lives, blistering and skin necrosis occur over the next few hours; scarring often occurs and lasts for life. Victims may rapidly stop breathing, sometimes within a few minutes of the initial envenomation, with death occurring rapidly unless prompt first aid and medical aid is available.⁷

Distribution

The widespread occurrence of chirodropid box jellyfish in tropical waters has been recognised since the turn of the century.² However, it was not until 1908 that Old first reported fatalities from jellyfish stings occurring in the Philippines.⁸ Deaths from jellyfish stings have since been confirmed in many areas around the world, although most reports remain inadequately authenticated.^{1,7,9-11}

Chirodropids occur in tropical waters, usually in the summer months of the northern and southern hemispheres. Their season is longest close to the equator and may last all year.¹

Indo-Pacific region – The presence of multi-tentacled box jellyfish species (chirodroids) has now been confirmed in the tropical Indo-Pacific oceans: westwards to the Maldives Islands, Southern India, Java, and the Malaysian archipelago (including west coast of Malaysia); eastwards to the Philippines; and northwards to Brunei, Sarawak, Sabah, Papua New Guinea, the Gulf of Thailand, and Okinawa, Japan.^{1,9,12–14}

Deaths have previously been reported from Penang, Malaysia; the Philippines; Bougainville Island, Solomon Islands; Sarawak; Brunei; Labuan Island; Sabah; D'Entrecasteaux Islands and Papua New Guinea.^{1,7–11} New or unreported deaths are included in this article.

Thailand – Anecdotal reports of a few deaths following jellyfish contact exist in which the species was not known.^{15,16} The first death reported in a major medical journal was of a 26-year-old British tourist, swimming off Chaweng Beach on the Thai Island of Koh Samui on 20 October 1999, who received a major box jellyfish sting. Resuscitation was unsuccessful.¹⁷

Other, unreported deaths in Thailand – A UK male aged 24 was stung late in the afternoon of 9 August 2002 at Hat Rin Nok beach on the western side of Koh Pan Ngan island in the Gulf of Thailand (Gulf of Siam) and died within minutes. A day later a Swedish female sustained stings to her chest, arms, body and legs on the same beach. She had a cardiac arrest on the beach within minutes of the sting and was resuscitated at the scene. Despite being transferred to a major hospital she arrested twice more before succumbing early the following morning, around 12 hours after the sting.

In 2002 a death was also reported to have occurred on Koh Samui island, adjacent to Koh Pan Ngan island in Thailand. No further details are available (personal communication, Professor Henry Wilde, 2002).

Koh Samui and Koh Pan Ngan are popular tourist islands with beaches, huts and good hotels, located off Sura Thani on the east coast of Thailand, 400 air miles south of Bangkok.

Indonesia – A previously unreported death of a seven-year-old boy occurred at Balikpapan, on the mid-east coast of Indonesia. He jumped off a pier, exited the water immediately, collapsed and died within four minutes. He was noted to be covered in whip-like marks over half of his body. The rapid death, the characteristic markings and the almost certain presence of chirodroids throughout this region suggest that this death has to have been caused by a chirodroid.

Philippines – The author visited the Philippines in 1987 to study jellyfish and researched further evidence of previously-reported fatal jellyfish stings. Chirodroid jellyfish proved to be well known in the area with stings occurring annually. Almost every village described a death

every two to three years, usually of a child. With some 50 small villages around the Bay of Sual alone, and many hundreds in tropical and subtropical areas of the Philippines, an estimated annual death rate from jellyfish stings in the Philippines of 20–40 was not thought to be excessive,¹ although Heeger, a biologist in the Philippines has estimated 20–30 deaths per year.¹⁸ As a death certificate is not necessary for burial at present, verification of these estimates in the Philippines is not possible.¹⁸ The jellyfish is again described as *Chiropsalmus quadrigatus*, but this cannot be confirmed.^{1,9}

Japan – A chirodroid currently identified (again, incorrectly) as *Chiropsalmus quadrigatus* occurs in Okinawa (latitude 27°), Japan.¹⁴ Its distribution extends to the Amani Islands in the north (latitude 28°). Four fatalities have been confirmed,¹ with two further fatalities since (personal communication, Tomihara, 2003). Many stings occur each year despite heightened awareness through an active advertising campaign on the danger of box jellyfish in the summer months, and the use of protective netting swimming enclosures, as in Australia.

India – The chirodroid *Chiropsoides buitendijke* occurs on the southern Indian coastline but no information is known about the west coast, or about how far north they extend.^{1,13} Swarms have been reported to cause overheating in power stations due to blockage of the cooling water inlet pipes that drain from the sea, but little envenomation data are available.¹ The author has a copy of a letter dated 1936 that was forwarded to him, which describes a death and serious envenomations in the Bombay area, but no further details have become available.

The Americas – The chirodroid *Chiropsalmus quadrumanus* (Muller 1859) has been described in waters along the eastern coast of the Americas between the tropics, including many Caribbean islands.^{1,13} Serious stings from *Chiropsalmus quadrumanus* have also been reported from beaches in Puerto Rico during the summer months (personal communication, Bertha Cutress, 1992). A swarm of *Chiropsalmus* caused many thousands of severe stings on the Atlantic coastline of Florida in the summer of 2003. A fatal chirodroid envenomation was recorded on 20 June 1990 of a four-year-old boy at Galveston Island in the Gulf of Mexico.¹⁰

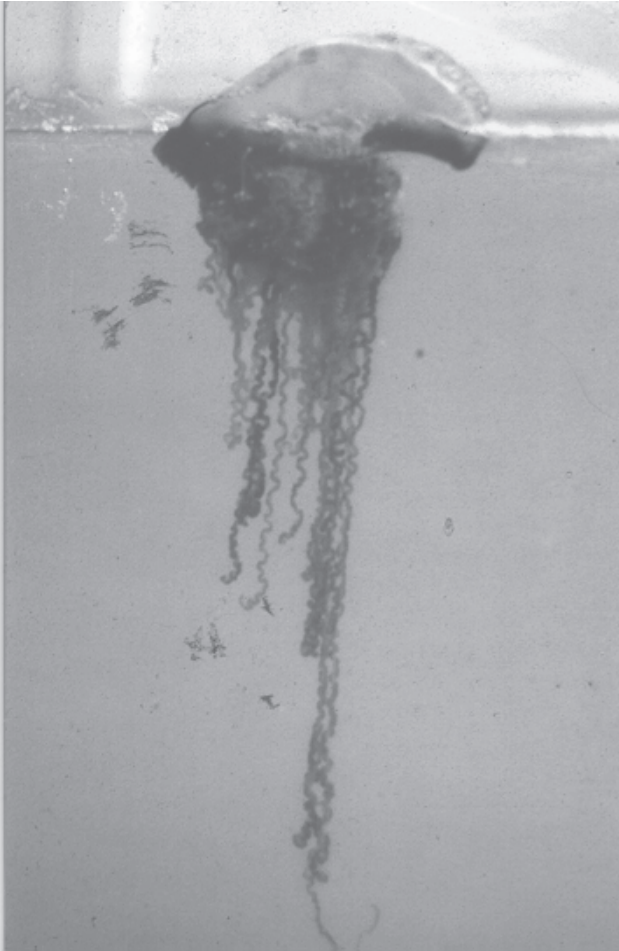Africa – There are neither reported deaths nor serious stings from *Chiropsalmus gorilla* described from the west coast of Africa, to the author's knowledge, nor from the east coast or Madagascar, although theoretically they should be present.¹

CARUKIA BARNESI (IRUKANDJI)

Carukia barnesi is distributed throughout tropical Australian waters. In appearance, it is a small, transparent carybdeid, usually 12–15 mm but up to 25 mm bell diameter, with four highly retractile tentacles, each arising in the lower corner of the bell.

Figure 3

Multi-tentacled *Physalia physalis*, ‘Pacific man-of-war’ – smaller cousin of Atlantic ‘Portuguese man-of-war’; causes very painful skin sting, often with nausea and sweating



A mild skin sting is followed after a short delay by severe muscular cramping pains, nausea, vomiting, sweating, anxiety and restlessness – known as the Irukandji syndrome.³ Hypertension, which may be severe, occurs in all severe cases, with some developing pulmonary oedema and toxic heart failure.^{4,5} Severe hypertension up to 300/150 mm Hg has been reported. This may be followed by an intra-vascular bleed – the cause of two deaths in north Queensland.⁶ This jellyfish was discussed in detail in the last issue.¹⁹

STOMOLOPHUS NOMURAI

Distribution

Stomolophus nomurai is reported in the Yellow Sea between China, South Korea and Japan.²⁰

Appearance

It has a large, translucent or milky-white dome with numerous non-stinging, sand-like dots on the outer surface

of the large bell, which may be 1–2 metres in width and can weigh over 100 kg. Many long brown tentacles hang underneath.

Envenomation

There is initial severe skin pain. Systemic symptoms are usually delayed, characteristically developing about 40 minutes after the sting, although this time may extend from a few minutes to about 50 minutes. This syndrome is similar to the ‘Irukandji syndrome’ with sweating, nausea, vomiting, anxiety and restlessness, although pulmonary oedema and toxic heart failure develop rapidly and may result in death.²⁰

Fatalities

Reports of eight deaths have now been published.²¹ Victims died from pulmonary oedema some 2–24 hours after the initial envenomation. No deaths have been reported since 1995, although this may be due to communication problems rather than a downturn in numbers of envenomations.

PORTUGUESE MAN-OF-WAR (*PHYSALIA PHYSALIS*)

Distribution

These hydrozoans are found throughout the world in temperate and tropical oceans. Stings appear to be more severe in warmer waters.¹

Appearance

The Portuguese man-of-war has a clearly visible blue float that may grow up to 25 cm in length in the Atlantic Ocean; in other oceans the maximum size appears to be 15–20 cm. Long, blue, highly retractile tentacles hang underneath and may extend up to 30 m in length in the largest specimens. The smaller specimens that occur in the Pacific are often referred to as the ‘Pacific man-of-war’ (Figure 3) to differentiate, as their sting, although very painful, has not proven life threatening. A similar ‘cousin’, *Physalia utriculus*, has just one tentacle and is common in the Pacific, especially around Australia, where it is usually known as the ‘bluebottle’.

Envenomation

Both the Pacific and Portuguese man-of-war cause very painful skin stings (although not as severe as those of *Chironex box* jellyfish) and can cause painful breathing (with reduced effort even leading to hypoxia), nausea, muscle cramps and anxiety.¹

Physalia sp. was thought to be responsible for a severe envenomation resulting in brachial artery spasm after a second sting, two weeks after the initial sting, at Mangalore in the Indian Ocean in the summer of 1983.²² The cause was attributed to hypersensitivity. Another serious envenomation off Goa in the Indian Ocean produced

Table 1
Locations of deaths from marine envenomation around the world

Jellyfish	Geographical location	Countries with fatalities
Chirodropids (Box jellyfish)	Tropical waters of: Pacific – West Coast Indian – East Coast and mid ocean Atlantic – East(?) and West Coasts	Australia Brunei Indonesia (Kalimatan), Labuan Malaysia (Penang & Langkawi Is.) Japan (Okinawa) Papua New Guinea Philippines, Sabah, Sarawak Solomon Islands (Bougainvillea) Thailand, USA
<i>Carukia barnesi</i> (Irukandji)	North and east tropical waters of Australia	Australia (North Queensland)
<i>Stomolophus nomurai</i>	China Sea	China (around Qindao – 8 deaths)
<i>Physalia physalis</i>	Worldwide	USA (South-east – 3 deaths)

localised vasospasm in upper limbs, finger necrosis, and gangrene. Based on serological titres from the patient, *Physalia sp.* was implicated, although the identity of the jellyfish was not confirmed.²³

Fatalities

There have been three deaths recorded from the Portuguese man-of-war in the south-eastern United States (Table 1).¹

Jellyfish causing severe envenomation syndromes

SANDERIA MALAYENSIS

Distribution

This jellyfish is present in the Indian Ocean, Singapore, East Africa, the Gulf of Aden, the Suez Canal, the Red Sea, and waters off Oman (and the Arabian Gulf), India, Malaysia, Japan and the Philippines.¹³

Appearance

Sanderia malayensis has a colourless to yellow, flat-topped bell 30–130 mm in diameter, with red spots extending over the bell surface and mouth arms. The bell edge drops vertically into a short 'skirt' with approximately sixteen tentacles hanging from the skirt edge, and four frilled mouth-arms hanging from the centre of the jellyfish.

Envenomation

The sting causes moderate to severe skin pain and local skin necrosis often occurs. The sting venom may be responsible for the peripheral vasospasm and tissue necrosis reported in the cases above. The severe skin pain and

appearance of the injury resemble those of a chirodropid and it may be difficult to distinguish between the two, especially in areas where both occur.¹

GONIONEMUS VERTENS VERTENS

Distribution

The small hydrozoan *Gonionemus vertens* is present worldwide; however, it causes severe envenomation effects only in the Sea of Japan around Vladivostok, and the north-west shores of Honshu Island, Japan, where it is referred to as *Gonionemus vertens vertens*, seemingly to differentiate it from the non-toxic variety.

Appearance

A small hydrozoan, 5–15 mm in diameter, the *Gonionemus* has many tentacles around the edge of the bell, within which a symmetrical, right-angled cross is visible.

Envenomation

Serious stings from *Gonionemus* tend to occur in the hot summer month of August in the Sea of Japan. Three types of envenomation syndrome have been described, making these jellyfish stings very unpleasant.¹

Painful syndrome (approximately 37%) – generalised painful muscle fasciculation with severe muscle, joint, chest and loin muscle pains that persist for 2–3 days.

Respiratory syndrome (approximately 44%), – allergic rhinitis, lacrymation, hoarseness, cough and dyspnoea, persisting from a few hours to two days.

Mixed syndrome (approximately 19%) – severe joint and muscular pains, with cough, bronchospasm, throat irritation, rhinitis and lacrymation. Some patients develop a tachycardia and mild hypertension. Psychic dysfunction with neuropsychiatric symptoms, depression and hallucinations has also been reported.

These symptoms occur mainly in northern Japan, usually in women gathering edible seaweeds. One sting even occurred after the victim ate this seaweed raw. It is presumed the syndrome resulted from ingestion of *Gonionemus*.¹

LARGE CARYBDEIDS (*TAMOYA* AND *CARYBDEA* SP.)

Distribution

Large carybdeids (box jellyfish) appear to be present in all temperate subtropical and tropical oceans, although they are much more common in the latter. Severe envenomations have been described from tropical areas with fringing reefs, including northern Australia, the Red Sea and Indian Ocean, and the Pacific coast of the far south-eastern United States, Mexico, Central and northern South America.^{1,22}

Envenomation

Skin pain occurs in all large carybdeid jellyfish stings and they frequently cause systemic symptoms similar to a mild-to-severe Irukandji syndrome. However, no deaths have been reported from these species to date.

'OTHER' SEVERE STINGS

Bali – On 17 October 2003, a nine-year-old boy and his father were snorkelling 15 metres from the beach when they felt a 'burning' pain, as if they were being electrocuted. When they exited the water they were covered in tentacles (blue and dark purple/black). The father was severely stung on both arms and shoulders, right neck and a third of his back; the son suffered less severe injuries.

At the diving centre some 25 m down the beach a local diver knew of the problem – “*It is a bad jellyfish – a hunting jellyfish and fire jellyfish*”. Divers started to remove the tentacles with their bare fingers and poured vinegar on the area. The son's symptoms settled quickly but the father had severe respiratory difficulties and muscle spasms in the back about 1–1.5 minutes after being stung. His hands, feet and lower legs became cold and blue, his arms and face, white. Seven minutes after the sting a local doctor arrived and gave him two injections, one an antihistamine, the other unknown. The victim then lay on the floor for some two hours before being able to get up and back to his hotel, still with severe burning pain all through the sting area. After a bad night with the pain and burning, he eventually settled with analgesia. This was probably a chirodroid sting, or possibly a severe sting from a multi-tentacled *Physalia physalis*.

Oman – A 60–70 cm carybdeid that he saw stung a diver on his right forearm in Omani waters in October 2002. He had severe burning over the stung area. He treated the area with vinegar but then went back into the water. About an hour later he felt dizzy and returned to the boat. The stung area on the right arm had raised, painful welts and the arm was slightly swollen. This swelling increased over the next five hours until he could not bend his arm at the elbow. During this time he developed stomach cramps, became nauseated and was vomiting for some five hours.

At 48 hours he still had severe pain and swelling of his right arm but flew home to the UK, feeling nauseated the whole flight. Despite resting the arm, over the next three days it began to blister and his nausea increased, he started vomiting and the stomach cramps returned and continued over the next three days. The severe blisters formed scabs, took weeks to heal and then scarred. The skin continues to feel very sensitive to touch. Could this have been a sting from *Carybdea alata* with Irukandji-like syndrome?

Puerto Morales – On Puerto Morales Beach, Mexico, a 29-year-old female was stung in April 2000 in open water near a coral reef. She described the jellyfish as the “invisible sea wasp” (no further details available). Initially she had a stinging pain in both her legs and a rash all over her body, like hives; she had severe muscle spasms, along with numbness in the arms and hands, palpitations, an “asthma attack” and she was itchy all over. Two years later she still had skin rashes, and had developed “food allergies” (which may or may not have been related). This could have been a sting from a carybdeid with Irukandji-like syndrome, or possibly a severe ‘sea bather’s reaction’ from *Linuche* sp.

Punta Cana, Dominican Republic – On 18 September 2002 a female swimmer was stung and developed large whip-like sting marks between the thighs, on the right shoulder and upper arm, and the left side of her abdomen. She started getting palpitations. The abdominal sting marks blistered and ulcerated and caused abdominal swelling; she also developed some facial swelling. The affected areas healed with little scarring. This could have been a carybdeid or mild chirodroid sting.

Red Sea – On 25 October 2002, a 54-year-old male, who had been diving for 34 years without problem or accident, was in Egypt diving in the Red Sea. He saw a carybdeid ‘box’ jellyfish just as he was stung on the leg. He had severe pain in his leg, and within five minutes could barely breathe: he thought he was “going to die”. Five to ten minutes after the sting he complained that he couldn't speak, although he could hear clearly. He developed severe vomiting and was taken to the hyperbaric centre at Sharm-el-Sheik within 20 minutes of the initial sting.

He was taken from there by boat and bus to another clinic; here they found his heartbeat was irregular but “it was corrected by medication”. The leg pain lasted about 24

hours with the stung area covered with thick blue welts. He then developed dysuria, urgency and incontinence. After 1–2 days the dysuria and frequency passed but he remained incontinent for a further two weeks. He also had abdominal pain and constipation, but laxatives caused faecal incontinence.

A week later he suddenly “felt awful”. Medical examination showed him to be hypertensive (205/120 mm Hg), in atrial fibrillation, with left ventricular dilatation and pulmonary oedema, which settled with medical treatment (exact details unknown). He then developed severe muscle weakness, causing difficulty walking and using his arms; he was unable to work. A neurologist was unable to define the cause and the muscle weakness slowly settled over the following year.

Mononeuritis multiplex

Two cases of mononeuritis multiplex following coelenterate stings have been reported.

Norfolk, Virginia, USA – A 25-year-old male was stung by a jellyfish off the coast of Norfolk, Virginia, USA. Although the animal responsible was not identified, both *Physalia* and *Cyanea* species were present in the water at the time of injury. The patient noticed typical erythematous wheals at the site of tentacle contact and had slight constitutional symptoms that disappeared within a day. During the subsequent week he noticed gradual weakness in his right hand and seven days later had diffuse weakness of the contralateral hand and arm. This delayed neuropathy of the radial and ulnar nerves improved spontaneously within 10 weeks.²⁴

Penang, Malaysia – A similar case occurred following a sting from an unidentified jellyfish in Penang, Malaysia.²⁵ A 26-year-old female was swimming off the beach when she felt immediate, severe pain on her right arm and hand. She became nauseated and faint, developed severe trunk pain, felt agitated and became breathless. Her right arm became swollen and she had pain up to her elbow, with numbness, paraesthesiae and muscular weakness. Over the next 24 hours she had more pain and swelling, and vesicular bullae appeared over the sting area, which then desquamated and later became hyper-pigmented.

Five weeks after the sting she had marked weakness of right hand dorsiflexion with mild thenar and hypothenar atrophy and decreased sensation in the distribution of the right median and radial nerves. This improved very slowly over the next year, still leaving her with some hand weakness and inability to perform her work as a typist.

Local lifeguards deny any knowledge of other severe stings in this area, but when the author visited in 1987 and asked local fishermen questions and showed them photos of chirodroids, they immediately recognised them. They

stated that they were present much of the year and one reported a death from a jellyfish sting within the previous couple of years. This was unsubstantiated by anyone else, including the local policeman. Cleland and Southcott had also described a fatal sting in that area in 1946.⁹

Treatment

Cold packs or ice stop the majority of skin pain in jellyfish stings tested to date when applied to the stung area for 5–15 minutes and can be repeated when necessary.²⁶ Heat has been shown to be useful in some areas after some delay (Hawaii; the large carybdeid *Carybdea alata*),²⁷ but in view of the high temperatures needed (over 42 °C) is difficult to maintain and entails the risk of scalding. Also, the time taken for the heat packs to ease the pain was similar to the natural regression of pain after most jellyfish stings.

CHIRODROID ENVENOMATION: FIRST-AID TREATMENT

To prevent further envenomation, household vinegar (4–6% acetic acid) is poured over the stung area for at least 30 seconds to inactivate stinging cells on remaining adherent tentacles. Others should be sent for help whilst the victim’s airway, breathing and circulation (ABC) are checked and expired air resuscitation (EAR), or cardiopulmonary resuscitation (CPR) commenced, if necessary.¹ Cold packs (15 minutes and repeated when necessary) will help ease skin pain but takes longer to work than in the smaller non-life-threatening stings, due to the severity of pain and tissue destruction.

Treatment of other envenomation symptoms, such as the Irukandji syndrome, is not possible in the first-aid situation, although glyceryl trinitrate spray or tablets, 1–2 as required (and if available), will reduce life-threatening hypertension.²⁸

Medical treatment

Clinical management is specific for the symptoms of serious envenomation: to provide analgesia, reduce hypertension, and provide specific drug therapy to manage severe symptoms. It may include advanced life support, antivenom administration, and management of both systemic and regional vascular problems. Antivenom is available for *Chironex fleckeri* stings and has been used with success in other chirodroid envenomations (author database).

Conclusions

Deaths from marine envenomation are not common, although four jellyfish species have been shown to cause many human fatalities, mostly in the Indo-Pacific region. Jellyfish envenomation has emerged as a major medical problem for local populations, indigenous or not, and tourists in both modern and third-world countries. Despite

heightened awareness and research of ecology, preventive measures and first-aid and medical treatment remain vestigial, with both undergraduate and postgraduate medical teaching remaining conspicuous by their absence.

References

- 1 Williamson J, Fenner P, Burnett J, Rifkin J, editors. *Venomous and poisonous marine animals: a medical and biological handbook*. Sydney, Australia: NSW University Press; 1996.
- 2 Haeckel E. System der acraspeden. zweite halfte des systems der medusen. *Denkschr Med-Naturwiss Ges Jena*. 1880; 1: 361-672.
- 3 Flecker H. 'Irukandji' stings to North Queensland bathers without production of wheals but with severe general symptoms. *Med J Aust*. 1952; 1: 89-91.
- 4 Fenner PJ, Williamson JA, Callanan V, Audley I. Further understanding of, and a new treatment for, 'Irukandji' (*Carukia Barnesi*) stings. *Med J Aust*. 1986; 145: 569-74.
- 5 Fenner PJ, Williamson JA, Burnett JW, Colquhoun DM, Godfrey S, Gunawardane K, et al. The "Irukandji Syndrome" and acute pulmonary oedema. *Med J Aust*. 1988; 149: 150-6.
- 6 Fenner PJ, Hadok JC. Fatal envenomation by jellyfish causing Irukandji syndrome. *Med J Aust*. 2002; 177: 362-3.
- 7 Southcott RV. Studies On Australian Cubomedusae, including a new genus and species apparently harmful to man. *Aust J Mar Freshw Res*. 1956; 7: 254-80.
- 8 Old HH. A report of several cases with unusual symptoms caused by contact with some unknown variety of jellyfish (Scyphozoa). *Philippine J Science*. 1908; B3; 329-33.
- 9 Cleland JB, Southcott RV. *Injuries to man from marine invertebrates in the Australian region*. Special Report Series No 12. Canberra: National Health And Medical Research Council; 1965. p. 282.
- 10 Bengston K, Nichols MM, Schnadig V, Ellis MD. Sudden death in a child following jellyfish envenomation by *Chiropsalmus quadrumanus*. Case report and autopsy findings. *JAMA*. 1991; 266: 1404-6.
- 11 Fenner PJ, Williamson JA. Worldwide deaths and severe envenomation from jellyfish stings. *Med J Aust*. 1996; 165: 658-61
- 12 Barnes JH. *Chironex fleckeri* and *Chiropsalmus quadrigatus*: morphological distinctions. *North Queensland Naturalist*. 1965; 32: 13-22.
- 13 Kramp PL. Synopsis of the medusae of the world. *J Mar Biol Assoc UK*. 1961; 40: 304-10.
- 14 Shokita S. *Dangerous animals and plants of Okinawa*. Okinawa: Shuppan Pub Co. Ltd (Pub); 1986. p. 18.
- 15 Anecdotal reports of a few deaths following jelly fish contacts, in which the species was not known. *Siriraj Hospital Gazette*. 1985.
- 16 Anecdotal reports of a few deaths following jelly fish contacts, in which the species was not known. *J Nakorn Ratchasema Hospital Report*. 1998.
- 17 Suntrarachun S, Roselieb M, Wilde H, Sitprijia V. A fatal jellyfish encounter in the Gulf of Siam. *J Travel Med*. 2001; 8: 150-1.
- 18 Heeger T, Möller H, Mrowietz U. Protection of human skin against jellyfish (*Cyanea Capillata*) stings. *Marine Biol*. 1992; 113: 669-78. (also quoted in reference 1)
- 19 Fenner PJ. Dangerous Australian box jellyfish. *SPUMS J*. 2005; 35: 76-83.
- 20 Mingliang Z. *The marine stinger*. Qingdao: Oceanology University Press; 1992.
- 21 Mingliang Z. A study on nematocyst dermatitis caused by jellyfish *Stomolophus nomurai*. *Acta Acad Med Qingdao*. 1987; 4: 1. (also quoted in reference 1)
- 22 Fenner PJ. *The global problem of cnidarian (jellyfish) stinging* [MD Thesis]. London: London University; 1997. p. 202.
- 23 Williamson JA, Burnett JW, Fenner PJ, Hach-Wunderle V, Hoe LY, Adiga KM. Acute regional vascular insufficiency after jellyfish envenomation. *Med J Aust*. 1988; 149: 698-701.
- 24 Filling-Katz MR. Mononeuritis multiplex following jellyfish stings. *Ann Neurol*. 1984; 15: 213.
- 25 Burnett JW, Williamson JA, Fenner PJ. Mononeuritis multiplex after coelenterate sting. *Med J Aust*. 1994; 161: 320-2.
- 26 Exton DR, Fenner PJ, Williamson JA. Cold packs: an effective topical analgesia in the treatment of painful stings by *Physalia* and other jellyfish stings. *Med J Aust*. 1989; 151: 625-6.
- 27 Thomas CS, Scott SA, Galanis DJ, Goto RS. Box jellyfish (*Carybdea alata*) in Waikiki: their influx cycle plus the analgesic effect of hot and cold packs on their stings to swimmers at the beach: a randomized, placebo-controlled, clinical trial. *Hawaii Med J*. 2001; 60: 100-7.
- 28 Fenner PJ, Lewin M. Sublingual glyceryl trinitrate as prehospital treatment for hypertension in Irukandji syndrome. *Med J Aust*. 2003; 179: 655.

Peter J Fenner, MD(London), MB, BS, DRCOG, FRCGP, FACTM, is Associate Professor, James Cook University School of Medicine, Townsville, and a general practitioner in North Mackay, Queensland. He is an advisor in marine envenomation to the World Health Organisation and International Life Saving. He was a Guest Speaker at the SPUMS ASM 2004.

Address for correspondence:

PO Box 3080, North Mackay,
Queensland 4740, Australia

Phone: +61-(0)7-4957-7800

Fax: +61-(0)7-4957-7824

E-mail: <pjf@occupationalhealthmackay.com.au>

This paper is based on a talk by Dr Fenner at the SPUMS Annual Scientific Meeting 2004 in Noumea.