

USE OF NUCLEAR MEDICINE IMAGING – SCINTIGRAPHY
IN DIAGNOSIS OF EQUINE ORTHOPEDIC DISEASE*
*UPOTREBA SCINTIGRAFIJE U DIJAGNOZI ORTOPEDSKIH
OBOLJENJA KONJA*

M. Kovač, M. Nowak, S. Petzoldt, Z. Tambur**

This study describes techniques, indications and findings of nuclear medicine imaging – scintigraphy of 42 horses with acute and chronic lameness of unknown origin. Most horses showed increased uptake of ^{99m}Tc-methylene diphosphonate in the tarsal joint (linked to the osteoarthritis and distal tarsal synovitis), the distal sesamoid bones (linked to the navicular disease), proximal attaches of the musculus interosseus medius on the palmar/plantar region of the metacarpus or metatarsus (linked to the insertions desmopathie) and in the dorsal processes of thoracic vertebrae (linked to the kissing spine syndrome). The interpretation of scintigraphy appeared to be a more reliable and sensitive diagnostic method than radiography in diagnosing these equine orthopedic disease.

Key words: horse, orthopedic diseases, diagnosis, scintigraphy

Introduction / Uvod

Routine diagnostic methods in the diagnosis of equine orthopedic disease include clinical examinations, local anesthesia, radiographic und ultrasound examination. These conventional orthopedic methods usually do not demonstrate abnormalities so early in the orthopedic disease process and they offer less insight into its current dynamic status (Chambers et al., 1995). Likewise, there are several orthopedic disease, with subtle lameness that cannot be easy localized with the routine diagnostic methods. The next logical step in the diagnosis of lameness is the use of nuclear medicine imaging or scintigraphy. Ueltschi (1977)

* Rad pripremljen za štampu 17. 1. 2003. godine

** Dr Milomir Kovač, dr Michael Nowak, S. Petzoldt, Bergische Equine Clinic, Flurweg 20, Heiligenhaus, Germany; mr Zoran Tambur, Military Medical Academy, Belgrade, Yugoslavia

first introduced „bone and joint imaging with technetium-99m (^{99m}Tc) labelled phosphates” as a new diagnostic aid in veterinary orthopedics.

Technetium-99m-labeled phosphonates concentrate very rapidly at sites of increased bone metabolism caused by skeletal disease. Gamma rays emitted by the decay of technetium-99m are counted with high sensitivity by gamma cameras, which locate and display their point of origin in the bone as images (Martinelli et al., 1995).

There are currently no large-scale research articles and case reports on equine bone scintigraphy. This paper describes our method, techniques, indications and findings of nuclear medicine imaging – scintigraphy in the evaluation of muscle-skeletal diseases of horses.

Materials and methods / Materijal i metode rada

Forty two adult (2-22 years old) warmblooded horses, of both sexes, admitted to the Bergische Equine Clinic, Heiligenhaus (Germany) were used in this scintigraphic study. Scintigraphic examinations were carried out in horses with acute and chronic lameness of unknown origin or unblockable lameness and in suspected degenerative changes in spines of horses, as well as by obvious lameness with possible involvement of the multiple sites of horses.

On admission, patients were examined (clinical, local anesthesia, radiographic and ultrasound), but diagnoses of lameness were mostly uncertain. Usually, the scintigraphic examination, was adjourned to 3 days after palmar digital nerve blocks and 7 days after any intraarticular analgesia, because this led to increased tracer uptake in the soft tissue image phase. Food and water were withheld from horses for 12 hours before scintigraphic examination. Each time, 30 min. before scintigraphic examination, the horses were sedated with acepromazine 10 mg/ 100 kg i.v.

The ^{99m}Tc -methylene diphosphonate was applied in horses i.v. in a dose of about 0.35 mCi/kg b.w. (3.7-4,2 GBq / per horse). Two hours after injection, the horses were imaged with the gamma scinti-camera (Elscint- APC-34 RS from GE Medical Systems, USA). The gamma camera was suspended by forklifts, allowing it to be moved in all directions around the horse. The scintigraphic-image views were used according to recommendation of Devous and Twardock (1984). The acquisition time or registration time with the gamma camera for every image was 60-90 seconds. During the registration time the horses were absolutely quiet. The gamma camera sent the digitized images to the processing computer. The processing computer processed the images and was used for digital image (soft copy) storage. Close to the acquisition time, the image acquisition was also determined with the number of counts per image and compared with the counts on the contralateral side.

Results / Rezultati rada

The regions with increased blood flow or osteoblastic activity demonstrated increase uptake of the radiopharmaceutical in delayed-phase bone images. According to our observations, the anatomical allocation increased uptake of the ^{99m}Tc -methylene diphosphonate is given in Table 1. Six of 42 horses showed multiple (two or more bone places) increase uptake of the ^{99m}Tc -methylene diphosphonate. Frequently increased uptake of the radiopharmaceutical was determined in examined horses as determined in the tarsal joint, the distal sesamoid bones and proximal attaches of the musculus interosseus medius (suspensory ligament), as well as in the dorsal processes of thoracic vertebrae.

In 13 horses, the increase uptake in the tarsal joint originate from the degenerative joint disease the distal tarsal synovitis and osteoarthritis (bone spavin). Similary, degenerative joint diseases in the stifle and elbow joints caused an increased uptake of the ^{99m}Tc -methylene diphosphonate (Table 1).

Table 1. Anatomical allocation of increased uptake of ^{99m}Tc -methylene diphosphonate
Tabela 1. Anatomska raspodela povećanog ugrađivanja ^{99m}Tc -metilen difosfonata

Location / Mesto	Number of cases / Broj slučajeva
Tarsal joint / Tarzalni zglob	13
Distal sesamoid bone / Distalna sesamoidna kost	11
<i>M. interosseus medius</i>	8
Thoracic vertebrae	5
Carpal joint / Karpalni zglob	2
Distal phalanx / Distalni članak (distalna falanga)	2
Proximal sesamoid bone / Proksimalna sesamoidna kost	2
Metacarpus	1
Tibia	1
Radius	1
Stifle joint / Koleni zglob	1
Elbow joint / Lakatni zglob	1

Increase uptake in the distal sesamoid bone was associated with the navicular disease. Navicular disease is seen as increased uptake in solar view delayed-phase images of the navicular bone region (Figure 1). The uptake was subtle, because of the relatively small size of the navicular bone compared with the distal phalanx.

In 8 cases we observed increased uptake of the ^{99m}Tc -methylene diphosphonate on attaches of the musculus interosseus medius on the the proxi-

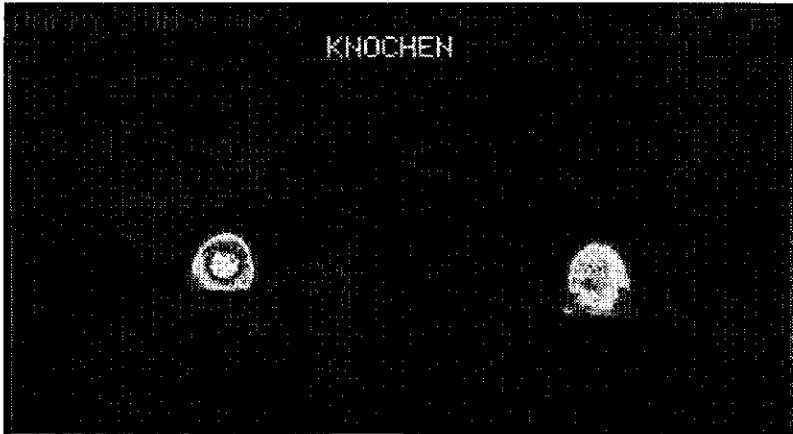


Figure 1. Solar view delayed – phase scintigraphic image of the left distal phalanx, showing increased uptake in the region of the navicular bone. Right image is solar view of a normal contralateral distal phalanx

Slika 1. Scintigrafska slika leve distalne falange u solearnoj projekciji. Vidi se povećano ugrađivanje u predelu navikularne kosti. Desno: normalna kontralateralna distalna falanga

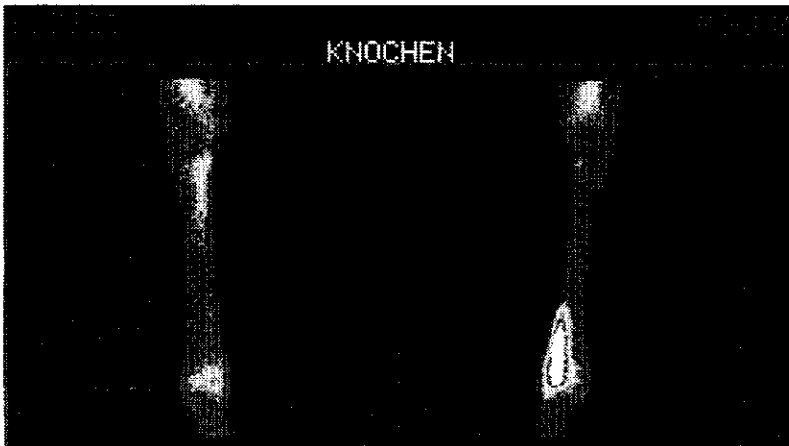


Figure 2. Dorsal view delayed – phase scintigraphic image of a normal metacarpus (left image) and images with fracture of the distal metacarpal bone (right image). Note the severe increased tracer uptake

Slika 2. Scintigrafska slika normalnog metakarpusa u dorzalnoj projekciji (levo) i slika frakture distalne metakarpalne kosti (desno). Primećuje se jako povećano ugrađivanje obeleživača

mal palmar/plantar region of metacarpus or metatarsus. It was linked with the enthesopathies formation or insertions desmopathie of this muscle (Table1).

In 5 horses we observed increased uptake of the ^{99m}Tc -methylene diphosphonate in the dorsal processes of thoracic vertebrae (Table1). This was linked with the kissing spine syndrome or degenerative joint disease of the articular facets. In 2 horses, increased uptake of the radiopharmaceutical in the carpal joint was associated with fissure of the os carpi radiale and os carpi intermedium (Table1).

Increase uptake in the distal phalanx in 2 horses was linked with laminitis and distal phalanx fracture (Table1). Two horses with sesamoiditis of the proximal sesamoid bones had almost increased uptake of the ^{99m}Tc -methylene diphosphonate (Table1). According to our observations in 2 horses with fissure of the radius and distale metacarpus (Figure 2) there was severely increased uptake of the radiopharmaceutical. One horse with a bone cyst in the distal tibia also had almost increased uptake of the ^{99m}Tc -methylene diphosphonate (Table 1).

Discussion / Diskusija

Although other organ (pulmonary, cardiovascular, renal, thyroid) systems can be imaged effectively via radiopharmaceutical agents, the greatest value of the nuclear medicine in equine practice has been in detecting causes of occult lameness (Twardock et al., 1991). Bone scans are done by using radiolabeled polyphosphonates, which have a high affinity for the calcium-hydroxy-appetite molecules in bone (Chambers et al., 1995). Images made at 2 - 4 hours postinjection reveal the uptake pattern in the bones (delayed image phase).

A predictable uptake pattern is seen in normal animals but severely increased uptake is seen with increased osteoblastic, mitotic or metabolic activity in bones and joints (Ueltsci, 1977). Scintigraphic images of bone demonstrate dynamic physiopathologic processes with high early-detection sensitivity but relatively poor anatomical detail. Radiographs exhibit excellent anatomical detail, but they usually do not demonstrate abnormalities as early in the disease process (Lamb et al., 1989).

According to our observations, 13 of 42 horses showed increased uptake of the ^{99m}Tc -methylene diphosphonate in the tarsal joint, as a symptom of the tarsal synovitis or osteoarthritis. These horses on admission to the clinic, showed minimal or inapparent radiographic changes of the tarsal joint. According to Winter et al. (1996) 7.2 % horses failed to possess radiographic indicators of osteoarthritis in the tarsal joint. Similarly, of 119 horses undergoing scintigraphy for uncertain lameness, 44 % demonstrated distal tarsal inflammation (Myhre et al., 1998).

Scintigraphy has been demonstrated as especially valuable in diagnosis of navicular disease in horses. According to our observations, 11 horses showed increased uptake of the ^{99m}Tc -methylene diphosphonate in solar view

delayed-phase images of the navicular bone region. Trout et al. (1991) also found that scintigraphy is more specific and sensitive than radiography in the diagnosis of navicular disease.

Periosteal reactions associated with enthesitis (enthesopathies formation) at ligamentous attachments produce intense hot spots of scintigraphic image in lesions that are difficult or impossible to demonstrate radiographically (Lamb et al., 1989). Common sites for enthesopathies are the proximal sesamoids (sesamoiditis), where the musc. interosseus medius (suspensory ligament) attaches to the abaxial surface of the os proximal sesamoidale and at the level of the tuber ischiadicum, where the caudal thigh muscles originate (Steyn, 2002). According to our findings, 8 horses showed increased uptake of the ^{99m}Tc -methylene diphosphonate, where musculus interosseus medius attaches on the proximal palmar/plantar region of metacarpus or metatarsus. This is a symptom of the insertions desmopathie (high suspensory ligament desmitis). Usually, the insertions desmopathie of the musculus interosseus medius has no apparent lesions radiographically but led to chronic lameness of horses. When lesions are detected, follow-up imaging examinations are a valuable method of evaluating the progress of healing (Lauk and Kimmich, 1997).

Regions with increased osteoblastic activity associated with conditions such as fissure, fractures and stress fractures demonstrate severely increased uptake of the radiopharmaceutical. According to our observations, the fissure and fractures were easily detected in the scintigraphic images. The amount of trace uptake seen at a fracture site can help determine the type of fracture (pathologic versus traumatic) and the relative time of injury (acute versus chronic). Chronic and subacute fractures (older than 48 hours) have intense increased uptake because of the considerable osteoblastic activity that is occurring (Steyn, 2002). Acute fractures have less radiopharmaceutical uptake because it takes approximately 24 hours for the osteoblastic activity at the injury site to be greater than that of the surrounding bone. Stress fissure and fractures of the dorsal cortex of the metacarpal and carpal bone most commonly seen in racing thoroughbred horses are often detected by nuclear medicine before they can be seen on radiographs (Koblik et al., 1988). Without this information, continued use of the horse might lead to a complete fracture.

The scintigraphic examination can be used to follow up a known lesion (to check the progress of healing), to examine radiographically normal but painful joints. Soft tissue uptake in the muscles can be seen in cases of rhabdomyolysis or changes associated with subchondral bone cysts (Morris et al., 1992).

In conclusion, nuclear medicine imaging or scintigraphy is a sensitive tool that augments lameness diagnosis. An advantage of scintigraphic imaging is to differentiate mixed lameness conditions in which the component of bone disease must be separated from that of soft tissues (Steckel, 1991). A disadvantage of this orthopedic method is the exposure to ionizing radiation of the horses, as well as indirectly veterinary personnel who do the scanning. Care must be taken

to avoid internal contamination through the accidental ingestion of the radionuclide. External radiation exposure occurs when the clinician is in the immediate vicinity of the horse, such as when scanning. Syringe shields should be used to reduce the radiation dose to the fingers. Personnel who scan horses should consider wearing a lead apron and a lead thyroid shield.

References / Literatura

1. Chambers M. D., Martinelli M. J., Baker G. J.: Nuclear medicine for diagnosis of lameness in horses. JAVMA, 206, 792-796, 1995. - 2. Koblik P. D., Hornof W. J., Seeherman H. J.: Scintigraphic appearance of stress-induced trauma of the dorsal cortex of the third metacarpal bone in racing Thoroughbred horses: 121 cases. JAVMA, 192, 390-395, 1998. - 3. Lamb R., Koblik D., O'Callaghan M., Mariner C.: Comparison of bone scintigraphy and radiography as aids in the evaluation of equine lameness: Retrospective analysis of 275 cases. Am Assoc Equine Pract, 34, 34-38, 1989. - 4. Lauk H. D., Kimmich M.: Vergleich thermographischer und scintigraphischer Befunde beim Pferd. Pferdeheilkunde, 13, 4, 329-334, 1997. - 5. Martinelli J., Chambers M.: Equine nuclear bone scintigraphy: Physiological principles and clinical application. Equine Vet Educ, 5, 281-287, 1995. - 6. Morris E., Seeherman H. J., O'Callaghan M.: Scintigraphic identification of skeletal muscle damage in horses 24 hours after strenuous exercise. Equine Vet J., 23, 347-352, 1991. - 7. Myhre G. D., Boucher N.: Incidence and correlation of scintigraphic findings to referral lameness at a private hospital. Proc Am Assoc Equine Pract, 44, 218-221, 1998. - 8. Nowak M.: Vergleichende röntgenologische und scintigraphische Untersuchungen an Sprunggelenken von Pferden. Proc. DVG. 11 Arbeitstagung, 284-290, 1990. - 9. Steckel R.: The role scintigraphy in the lameness evaluation. Vet Clin North Am Equine Pract. 7, 2, 207-39, 1991. - 10. Steyn F.: Nuclear medicine. In Adams lameness in horses, Fifth ed. Stashak T., Lippincott Williams, Philadelphia, 347-375, 2002. - 11. Trout D., Hornof J., O'Brien R.: Soft tissue- and bone-phase scintigraphy for diagnosis of navicular disease in horses. JAVMA, 198, 73-77, 1991. - 12. Twardock A., Baker G. J.: The impact of nuclear medicine as a diagnostic procedure in equine practice. Comp Cont Educ Pract Vet., Vol.13 (11), 1717-1723, 1991. - 13. Ueltschi G.: Bone and joint imaging with ^{99m}Tc -labeled phosphates as a new diagnostic aid in veterinary orthopedics. J Am Vet Radiol Soc., 18, 80-84, 1977. - 14. Winter D., Bruns E., Glodek P., Hertsc B.: Genetic disposition of bone diseases in sport Horses. Zuchtungskunde, 68, 92-108, 1996.

SRPSKI

UPOTREBA SCINTIGRAFIJE U DIJAGNOZI ORTOPEDSKIH OBOLJENJA KONJA

M. Kovač, M. Nowak, S. Petzoldt, Z. Tambur

Ova studija opisuje tehniku, indikacije i rezultate nuklearnog medicinskog odlikavanja – scintigrafije u 42 konja sa akutnom ili hroničnom hromosti nepoznatog porekla. Najveći broj ispitivanih konja je pokazivao povećano nakupljanje ^{99m}Tc -metylen diphosphonata u tarzalnom zglobu kao posledicu oboljenja - osteoartritis i distalni tarzalni sinovijalitis; u distalnoj sezamoidalnoj kosti kao posledica oboljenja - navikularna bolest; proksimalnom završetku *musculus interosseus medius* na palmarnom/plantarom području me-

takarpalne/metatarzalne kosti kao posledica oboljenja - insertaciona dezmozopatija; kao i na dorzalnim produžecima grudnih pršljenova kao posledica oboljenja - „kissing spine” sindrom. Scintigrafijska metoda pokazuje veću pouzdanost i senzitivnost u odnosu na radiološku metodu u dijagnostikovanju ovih ortopedskih oboljenja konja.

Ključne reči: konji, ortopedska oboljenja, dijagnostikovanje, scintigrafija

РУССКИЙ

УПОТРЕБЛЕНИЕ СЦИНТИГРАФИИ В ДИАГНОЗЕ ОРТОПЕДИЧЕСКИХ ЗАБОЛЕВАНИЙ ЛОШАДЕЙ

М. Ковач, М. Новак, С. Петзолдт, З. Тамбур

Эта студия описывает технику, индикации и результаты ядерного медицинского переснимания - сцинтиграфии у 42 лошадей с острой или хронической хромотой неизвестного происхождения. Наибольшее число испытанных лошадей показывало увеличенное накапливание ^{99m}Tc -*methylen diphosphonata* в тарзальном суставе как последствие заболеваний - остеоартрит и дистальный тарзальный синовит; в дистальной сезамовидальной кости как последствие заболевания - навикулярная болезнь; проксимальном окончании *muskulus interosseus medius* на пальмарной (плантарной области метакарпальной) метатарзальной кости как последствие заболевания - инертационная дезмопатия; словно и на дорсальных окончаниях грудных позвонков как последствие - *kissing spine* синдром. Сцинтиграфический метод показывает более большую надёжность и чувствительность в отношении радиологического метода в диагнозе этих ортопедических заболеваний лошадей.

Ключевые слова: лошади, ортопедические заболевания, диагностирование, сцинтиграфия