

## Case Report

**J Chin Med Assoc**

2004;67:93-98

Kuo-Fang Hsueh<sup>1,2</sup>

Pei-Yu Lin<sup>1,2</sup>

Shui-Mei Lee<sup>1,2</sup>

Chang-Fu Hsieh<sup>3</sup>

<sup>1</sup> Department of Ophthalmology, Taipei Veterans General Hospital;

<sup>2</sup> National Yang-Ming University School of Medicine, and

<sup>3</sup> Department of Life Science, National Taiwan University, Taipei, Taiwan, R.O.C.

# Ocular Injuries from Plant Sap of Genera *Euphorbia* and *Dieffenbachia*

Clinical findings in 3 cases of ocular injuries caused by the milky latex from *Euphorbia tirucalli* and *Dieffenbachia sequine* were reported. The initial symptoms of all patients were burning pain with subsequently blurred vision. Visual acuity was reduced between 6/30 and 6/20. *Euphorbia* sap caused punctate erosion, microbullae and Descemet's folds; while *Dieffenbachia* sap induced conjunctival chemosis and fine blue crystals in the stroma. Ocular symptoms developed in 5 to 18 hours despite immediately copious irrigation. Supportive treatment resulted in a full recovery without sequelae over 1 week. Wearing eye protection and washing the exposed areas with soap and water are advised while handling such plants.

### Key Words

calcium oxalate crystal;

cornea;

*Dieffenbachia*;

*Euphorbia*;

latex

Some ornamental garden plants with milky sap may cause ocular injuries in case of accidental contact with human eyes. The milky latex from different kinds of plants contains different chemical components. Some of them are toxic and may elicit different pathogenic mechanisms and different clinical manifestations.

The spectrum of ocular injuries from the family of *Euphorbiaceae* consists of contact or photo dermatitis, conjunctivitis, mild to severe keratitis, corneal ulceration, uveitis with hypopyon, corneal scarring, miosis and blindness.<sup>1,2</sup> Other plants from the genera *Dieffenbachia* have been reported to cause mild to moderate conjunctival chemosis and congestion, subconjunctival hemorrhage, and fine needle-like blue crystals in the stroma.<sup>3-5</sup> We report 2 cases of ocular injuries caused by *Euphorbia tirucalli* (also called pencil tree, milk bush, malabar tree) sap and 1 case caused by *Dieffenbachia sequine* (dumb-cane) sap.

## CASE REPORTS

### Case 1

A 70-year-old man had the plant sap splash on his face while he was cutting down *Euphorbia tirucalli* (Fig. 1). After washing face with tap water, he noticed mild irritation of both eyes which progressed into severe burning pain with redness and mild visual blurring in about 5 hours. He then rushed to the emergency room where ophthalmic examination disclosed visual acuity of 6/15 OD and 6/7.5 OS, with moderate conjunctival congestion. A layer of oily material was noted floating on the tear film while copious irrigation with normal saline was performed, but it could not be washed out completely. He was initially treated with topical corticosteroids and antibiotic eye drops. The examination in the next morning revealed the decreased vision of 6/30 OD and 6/15 OS. Diffuse corneal epithelial erosions, stromal edema and Descemet's

Received: March 31, 2003.

Accepted: September 25, 2003.

Correspondence to: Pei-Yu Lin, MD, Department of Ophthalmology, Taipei Veterans General Hospital, 201, Sec. 2, Shih-Pai Road, Taipei 112, Taiwan.

Fax: +886-2-2876-1351; E-mail: pylin@vghtpe.gov.tw

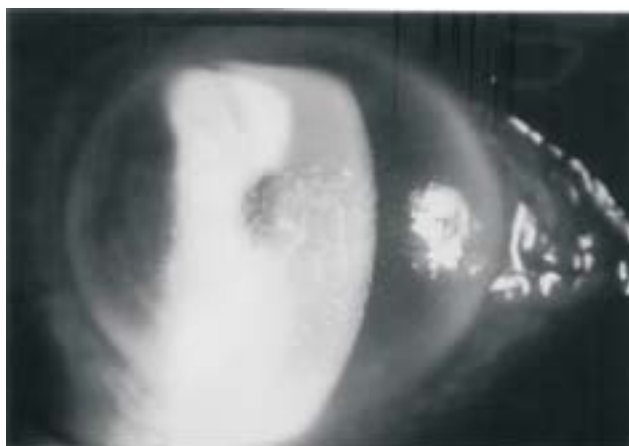folds (Fig. 2) developed mainly in the lid fissure areas of both corneas, more severe in the right eye. The intraocular pressure, anterior chamber and fundus were unremarkable. Treatment consisted of topical 0.02% fluorometholone eye drops, 0.25% chloramphenicol eye drops and oflovid ointment. The epithelial erosions healed in 2 days, and the stromal edema resolved in 1 week. His vision returned to 6/15 OD and 6/7.5 OS, with no sequelae in either cornea.

### Case 2

A 40-year-old man accidentally had *Euphorbia tirucalli* juice squirt into his left eye while he was trimming grass, where some pruned-away twigs of *Euphorbia tirucalli*



**Fig. 1.** *Euphorbia tirucalli* with free-flowing sap.



**Fig. 2.** Case 1. A 70 year-old male with corneal punctate erosions, underlying stromal edema, and Descemet's folds, 18 hours after exposure to *E. tirucalli* sap.

had been laid the day before. He paid little attention to it initially because the juice was mistaken for dew. He experienced severe burning pain, redness and marked lacrimation despite immediate rinse with tap water. He visited an eye doctor, who did irrigation again. However, his vision deteriorated at night and he was referred to our hospital in the next day. On examination, the visual acuity in his left eye was 6/20. The conjunctiva was mildly injected and the cornea showed microbullae, marked stromal edema, and Descemet's folds. The intraocular pressure, anterior chamber and fundus were normal. Topical 0.02% fluorometholone eye drops, 0.25% chloramphenicol eye drops and 0.3% gentamicin ointment were prescribed. Two days later, the stromal edema and Descemet's folds diminished markedly and his vision recovered to 6/8.6. Specular microscopy revealed symmetrical endothelial cells morphology and numbers in both eyes. His vision returned to 6/5 and the cornea had full recovery in a week.

### Case 3

A 64-year-old woman was inadvertently inoculated with the *Dieffenbachia sequine* (Fig. 3) sap into her left eye while she was cutting away the shrub. She felt a stinging pain and lacrimation immediately. She irrigated her left eye with tap water by herself, which was also done by a local practitioner 3 hours later. The symptoms worsened and visual blurring progressed, so she came to our emergency room for help 6 hours later.



**Fig. 3.** *Dieffenbachia sequine*.

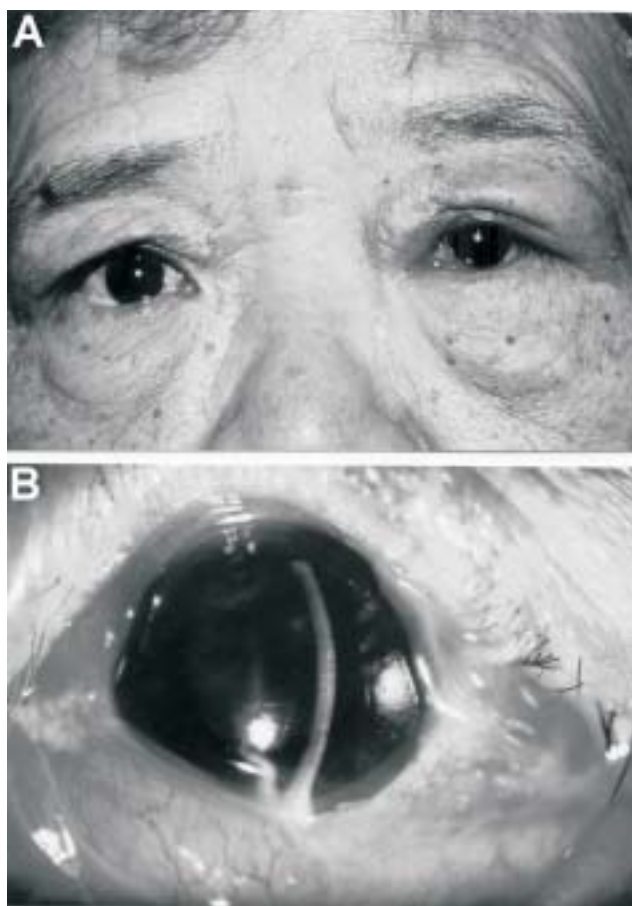
Ophthalmic examination of the left eye disclosed visual acuity of 6/30, with mild eyelid swelling and conjunctival chemosis. An epithelial defect sized  $2.0 \times 4.5$  mm was noted in the temporal cornea with stromal edema. The examination done in the next day showed that visual acuity in the left eye was still 6/30. There was severe upper eyelid swelling (Fig. 4A), as well as marked conjunctival chemosis (Fig. 4B) and injection with fibrin coating. The cornea revealed temporal epithelial defect, mild stromal edema, and fine refractile needle-like blue crystals extending from subepithelial layer to the posterior stroma (Fig. 4B), which were distributed predominantly in the interpalpebral cornea. There was no associated cellular infiltration within the cornea. The intraocular pressure, anterior chamber and

fundus were normal. The fellow eye was not involved. The left eye was treated with topical 1% prednisolone acetate, 0.25% chloramphenicol eye drops and 0.3% gentamicin ointment. Because of severe eyelid swelling and conjunctival chemosis, oral prednisolone 20 mg b.i.d. was given for 2 days. The corneal crystals gradually diminished, but were still noted 8 days later. Her vision returned to 6/8.6 in the last follow-up.

## DISCUSSION

There are 12 families, 20 genera and above 5000 species of plants with milky latex sap worldwide. They are used as patio decoration, food, or medicine, and have industrial value. The components of the plant sap are not well-known, but the toxic constituents have been identified, including essential oil, alkaloids, amino acids, cyanogenic glycerides, cardioactive glycerides, furanocoumarins, plant acids, poly-acetylene compounds, proteins and peptides, saponins and terpenes.<sup>6</sup> If orally ingested or locally used, these toxic compounds may cause clinical side effects, comprising irritation on the skin (erythema, swelling, vesicles and blisters), the eyes (conjunctivitis, keratitis, uveitis, corneal scarring, miosis and blindness), the nose and throat (burning sensation), the respiratory system (pulmonary edema), the neurological system (giddiness, seizures and coma), the gastrointestinal system (edema, vomiting, diarrhea and dehydration), and the hematological system (platelet aggregation); they may also have carcinogenicity.<sup>6</sup> There have been several case reports in the literature of ocular injuries in humans resulting from accidental exposure to the genera of *Euphorbia*,<sup>1,2,7-11</sup> *Hippomane*,<sup>12</sup> *Dieffenbachia*,<sup>3-5</sup> and *Asclepias* sap.<sup>13</sup> The toxicity is variable between and within genera and species. Some species have no apparent ill effects on the eyes, while the others may cause the same clinical pictures with variable severity. The severity of ocular inflammation may be related to the species of plant, the concentration of sap into the eye and the duration of contact.

Plants of genera *Euphorbia*, which include *E. tirucalli* (pencil tree), *E. trigona*, *E. lactea* (candlebra cactus), *E.*



**Fig. 4.** (A) Case 3. A 64 year-old female with contact dermatitis in left upper eyelid. (B) Severe conjunctival chemosis, temporal epithelial sloughing, mild stromal edema, and fine refractile needle-like blue crystals extending in the stroma, 1 day after exposure to *D. sequine* sap.

*peplus* (petty spurge), *E. lathyris* (caper spurge), *E. milii* (The crown of thorns), *E. palustris*, *E. characias*, *E. wulfenii*, *E. marginata*, *E. platyphyllos* and *E. robbiae*, all have polycyclic diterpene esters.<sup>1,2,7-11</sup> The ocular changes caused by *Euphorbia* latex usually follow a typical course. Ocular symptoms, such as burning or stinging pain, redness, photophobia and lacrimation, generally begin immediately on contact with the sap and may worsen in a few hours despite irrigation. Visual acuity may deteriorate to counting fingers several hours later and the corneal epithelium may slough off the following day. With appropriately supportive treatment and close follow-up, it takes about 2 days for epithelial healing and 1 week for the corneal edema to subside. The condition seems to be self-limiting without sequelae, but neglected cases can progress to corneal ulcer, or even blindness secondary to superimposed infection. The latex from species *Hippomane mancinella* in India, which belongs to the family of *Euphorbiaceae*, also contains diterpene esters toxins showing clinical pictures similar to that from genera *Euphorbia*.<sup>12</sup>

As described in Case 1, the patient felt burning pain in both eyes after washing his face with tap water when the plant sap had splashed on his face, not directly squirted into his eyes. The initial examination disclosed no changes in visual acuity, although there were oily tear films on the corneal surface with intact epithelium and clear cornea. We suspect that tap water can indirectly bring *Euphorbia* sap into the eyes damaging the anterior segment. The diterpene esters may resolve into hydrophilic and hydrophobic fractions after mixed with water and provoked by the plant enzymes.<sup>12</sup> The highly irritant hydrophilic fraction will erode the corneal epithelium, whereas the non-irritant hydrophobic fraction, which cannot be removed despite immediate or subsequent copious water irrigation, could be chemically activated to form irritant substances and subsequently penetrate the corneal stroma, leading to deterioration of vision several hours or days later. The corneal findings in Case 2, disclosing only micribullae, severe stromal edema without epithelial sloughing, also indicate the role of the hydrophobic fraction. We infer that the hydrophilic frac-

tion may have been washed away by the dew overnight so that corneal epithelial sloughing was not induced. According to research on the identification of the irritant chemicals from genera *Euphorbia*, the most likely candidates for the production of keratoconjunctivitis secondary to *Euphorbia tirucalli* are a mixture of phorbol 12, 13-diester, ingenol esters and euphorcinol (C<sub>30</sub>H<sub>48</sub>O).<sup>6</sup> These small, non-protein organic molecules are soluble in water, which explains why rainwater or dew can cause ocular injury without direct contact with the tree sap, as in Cases 1 and 2. The pathogenic mechanism of *Euphorbia* sap may be an irritation to the cells from diterpene esters.<sup>12</sup> The *Euphorbia* keratoconjunctivitis in our cases follows a similar clinical course to the published reports.

The genus *Dieffenbachia*, which includes *D. amoena* and *D. sequine*, has proteinaceous enzymes and calcium oxalates that produce pathognomonic fine blue crystals in the stroma.<sup>3-5</sup> The ocular toxicity in humans occurs from the family of *Araceae*, including genera *Arisaema*, *Colocasia*, *Pinellia*, *Dieffenbachia* and *Philodendron*, leading to keratoconjunctivitis associated with crystal deposits in the cornea.<sup>3,4</sup> Characteristically, the clinical course proceeds in the following manner.<sup>4</sup> Once epithelial penetration occurs, the crystals rapidly migrate to the anterior stroma within 24 hours and the concentration decreases posteriorly by 48 hours. The conjunctival injection disappears by the sixth day after corneal epithelium heals rapidly. Crystals decrease markedly by the eighth day and 75% are dissipated by the end of the second week. The remaining crystals slowly disappear over a period of 4 to 8 weeks. Plant sap from genus *Arisaema* (jack-in-the-pulpit), *Calla palustris* (wild calla), *Colocasia* (elephant's ear), *Philodendron* and *Symplocarpus foetidus* (skunk cabbage) also contain raphides of calcium oxalate and can cause forms of injury similar to genus *Dieffenbachia*, although reports of ocular injury in man are very rare.<sup>4</sup>

An animal study done by William Ellis *et al.*<sup>4</sup> have found no crystals in the corneal stroma when the free-flowing *Dieffenbachia* sap was applied on the intact or denuded cornea. Whereas, a preparation of plant juice made by pressing the stalk reproduced a full-blown le-



sion when applied to the intact cornea due to higher concentration of calcium oxalate crystals. No crystals were found in the stroma treated with the sap filtered through an 8  $\mu$  Millipore filter to remove crystals. Epithelial necrosis occurred with filtered as well as unfiltered preparation, independent of the presence of calcium oxalate crystals. Fochtman also attributed the toxicity in *Dieffenbachia* sap to labile water-insoluble "proteinlike" substances, not to the oxalate content in an animal study.<sup>5</sup>

In previous reports, there was only cornea involvement associated with mild conjunctival injection and chemosis, and minimally reduced vision after contact with *Dieffenbachia* sap.<sup>3</sup> However, the ocular damage in Case 3, exposed to a trace of *Dieffenbachia sequine* latex, was more severe than previously reported cases, particularly the severe swelling in her eyelid and conjunctiva. The visual acuity was markedly decreased initially, although it returned normal after the epithelium healed and corneal edema subsided on day 4. However, the blue crystals still persisted until day 8 without impairing her vision. Previous investigators have pointed out that some proteinolytic enzymes may disrupt the epithelial barrier, allowing penetration of calcium oxalate and plant proteins to make further chemical injury. The pathogenic mechanism is the combination of chemical injury from the proteinolytic enzymes and plant proteins, together with mechanical injury from the raphides of calcium oxalate.

Chakraborty has reported a case of corneal edema due to *Asclepias curassavica*.<sup>13</sup> The plants of family *Asclepiadaceae* contain resinoids and/or cardiac glycosides in their latex, stems, leaves and roots.<sup>6,13</sup> Toxic constituents in *A. curassavica* latex include calotropin, uscharin and calactin, which can penetrate the cornea without injury to the epithelium and act clinically by inhibiting the endothelial  $\text{Na}^+ - \text{K}^+ - \text{ATPase}$ , thus causing a decrease in intraocular pressure and corneal edema for 24 to 48 hours.<sup>13</sup> The toxic process may be transient and leave no sequelae.

In conclusion, being aware of these toxic plants and their sap constituents, the ophthalmologist can predict clinical findings and disease course when caring patients exposed to the plant sap. People who work with the plants with milky latex should be cautioned to wear gloves and eye protection and to wash the exposed areas with soap

and water before contact with any individual. Patients with a history of plant sap entering directly or indirectly into their eyes should be immediately irrigated with copious normal saline and be warned that their vision may get worse before it improves over hours or days. Ophthalmologists should ask the patients to bring in a sample of the plant for identification and understanding the clinical course that may happen. It is important to closely follow up in the first few days to control inflammation and to prevent infection and complications. Most of the condition is self-limiting and has a full recovery without sequelae after supportive treatment over a week. Further *in vitro* studies on corneas using fractionated components of the *Euphorbia* and *Dieffenbachia* sap are needed to elucidate the inciting chemicals and precise mechanism.

## REFERENCES

1. Eke T, Al-Husainy S, Raynor MK. The spectrum of ocular inflammation caused by Euphorbia plant sap. *Arch Ophthalmol* 2000;118:13-6.
2. Scott IU, Karp CL. Euphorbia sap keratopathy: four cases and a possible pathogenic mechanism. *Br J Ophthalmol* 1996; 80:823-6.
3. Seet B, Chan WK, Ang CL. Crystalline keratopathy from Dieffenbachia plant sap. *Br J Ophthalmol* 1995;79:98-9.
4. Ellis W, Barfort P, Mastman GJ. Keratoconjunctivitis with corneal crystals caused by the Dieffenbachia plant. *Am J Ophthalmol* 1973;76:143-7.
5. Fochtman FW, Manno JE, Winek CL, Cooper JA. Toxicity of the genus Dieffenbachia. *Toxicol appl Pharmacol* 1969;15: 38-45.
6. MICROMEDEX Inc. 1974-2000. POISINDEX<sup>®</sup> & IDENTIDEX<sup>®</sup> Systems <http://lib.vghtpe.gov.tw/cgi-bin/mdxcgi/mdxhtml.exe?&tmpl=pdxsrch.tml&SCRNAME=pdxsrch&CTL=/ovid/mdx/mdxcgi/megat.sys>
7. Desatnik H, Ashkenazi I, Avni I, Abraham F, Blumenthal M. Acute conjunctivokeratouveitis caused by latex from the pencil tree. *Am J Ophthalmol* 1991;112:464-6.
8. Crowder JI, Sexton RR. Keratoconjunctivitis resulting from the sap of Candelabra cactus and the pencil tree. *Arch Ophthalmol* 1964;72:476-84.
9. Biedner BZ, Sachs U, Witztum A. Euphorbia peplus latex keratoconjunctivitis. *Ann Ophthalmol* 1981;13:739-40.

10. Eke T. Acute kerato-uveitis associated with topical self-administration of the sap of the petty spurge (*Euphorbia peplus*). *Eye* 1994;8:694-6.
11. Antcliff RJ, Hodgkins PR, Bowman R, Keast-Butler J. *Euphorbia lathyris* latex keratoconjunctivitis. *Eye* 1994;8:696-8.
12. Pitts JF, Barker NH, Gibbons DC, Jay JL. Manchineel keratoconjunctivitis. *Br J Ophthalmol* 1993;77:284-8.
13. Chakraborty S, Siegenthaler J, Büchi ER. Corneal edema due to *Asclepias curassavica*. *Arch Ophthalmol* 1995;113:974-5.