



Contents lists available at [SciVerse ScienceDirect](http://www.sciencedirect.com)

# International Journal of Paleopathology

journal homepage: [www.elsevier.com/locate/ijpp](http://www.elsevier.com/locate/ijpp)



## Research Article

# A peaceful realm? Trauma and social differentiation at Harappa

Gwen Robbins Schug<sup>a,\*</sup>, Kelsey Gray<sup>b</sup>, V. Mushrif-Tripathy<sup>c</sup>, A.R. Sankhyan<sup>d</sup>

<sup>a</sup> Department of Anthropology, 401 Sanford Hall, Appalachian State University, Boone, NC 28608, USA

<sup>b</sup> Institute of Archaeology, University College, London, UK

<sup>c</sup> Department of Archaeology, Deccan College Post-Graduate Research Institute, Pune 411006, India

<sup>d</sup> Anthropological Survey of India, Indian Museum Campus, Spirit Building, 27 Jawaharlal Nehru Road, Kolkata 700016, India

## ARTICLE INFO

### Article history:

Received 4 April 2012

Received in revised form 13 August 2012

Accepted 17 September 2012

### Keywords:

Fracture

Trauma

Violence

Urbanization

Indus Civilization

Harappa

## ABSTRACT

Thousands of settlements stippled the third millennium B.C. landscape of Pakistan and northwest India. These communities maintained an extensive exchange network that spanned West and South Asia. They shared remarkably consistent symbolic and ideological systems despite a vast territory, including an undeciphered script, standardized weights, measures, sanitation and subsistence systems, and settlement planning. The city of Harappa (3300–1300 B.C.) sits at the center of this Indus River Valley Civilization. The relatively large skeletal collection from Harappa offers an opportunity to examine biocultural aspects of urban life and its decline in South Asian prehistory. This paper compares evidence for cranial trauma among burial populations at Harappa through time to assess the hypothesis that Indus state formation occurred as a peaceful heterarchy. The prevalence and patterning of cranial injuries, combined with striking differences in mortuary treatment and demography among the three burial areas indicate interpersonal violence in Harappan society was structured along lines of gender and community membership. The results support a relationship at Harappa among urbanization, access to resources, social differentiation, and risk of interpersonal violence. Further, the results contradict the dehumanizing, unrealistic myth of the Indus Civilization as an exceptionally peaceful prehistoric urban civilization.

© 2012 Elsevier Inc. All rights reserved.

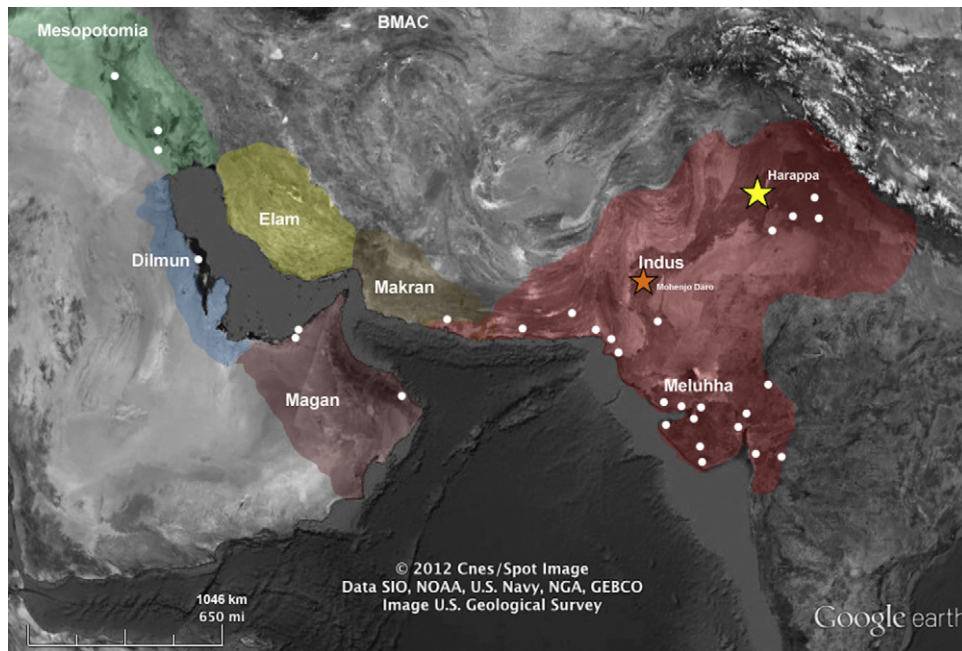
## 1. Introduction

At the height of the Indus Civilization (period III, 2600–1900 B.C.), thousands of cities and towns covered a million square kilometers of territory in South Asia (Fig. 1). This world was centered around the seven rivers that traverse the Indus Valley, but Indus territory extended from the Pakistan–Iran border in the West to the Ganga–Jumna doab in the East; Punjab in the North to the Rann of Kutch in the South. This civilization is best known from excavations at urban centers, which have revealed large, well-organized settlements, sanitation facilities and water works, standardized weights and measures, an undeciphered script, craft specialization, and an economic interaction sphere that spanned Central Asia in the third millennium B.C. Over this vast territory, there is local variation evident in style, customs, and wares but there is also remarkable continuity in symbolism, town planning, subsistence practices, weights, measures, and even brick sizes (Kenoyer, 1998; Lahiri, 2000; McIntosh, 2008; Meadow, 1991; Possehl, 2002; Vats, 1940; Wheeler, 1947).

Contemporaneous civilizations in West Asia went through a well-documented process of urbanization and state formation that included social differentiation, centralized power, institutionalized religion, monumental architecture, control over access to resources, state sanctioned violence, exclusion, and similar mechanisms of social control (Akkermans and Schwartz, 2003; Lloyd, 2010; Pollock, 1999; Wenke, 2009; Wright, 2010). The Indus civilization apparently departs from this pattern of prehistoric state formation (Kenoyer, 1997, 1998; Possehl, 1990, 1998, 2002; Ratnagar, 1991, 2001; Shaffer, 1982; Wright, 2010), which has led archeologists to employ alternative concepts of state formation to explain the social changes we see in the third millennium B.C. The most widely used concept is that of the heterarchical state (Possehl, 1990, 2002). The Indus Civilization has been constructed as a kind of corporation, a ‘grassroots’ government in which the population collectively assigned authority to political and religious leaders and only a weak hierarchical structure existed. The Indus Civilization has also consistently been described as exceptional in its peaceful egalitarianism (McIntosh, 2002, 2008) although the human skeletal material was not previously studied in regard to social differentiation, exclusion, or the presence of violence.

Analysis of burial treatment and paleoepidemiology provide an opportunity to test the characterization of Indus society as an exceptionally peaceful realm. When bone tissue is injured, the

\* Corresponding author. Tel.: +1 828 262 7505; fax: +1 828 262 2982.  
E-mail addresses: [Robbinsgm@appstate.edu](mailto:Robbinsgm@appstate.edu) (G. Robbins Schug),  
[kelseygray@gmail.com](mailto:kelseygray@gmail.com) (K. Gray), [vmushrif@gmail.com](mailto:vmushrif@gmail.com) (V. Mushrif-Tripathy),  
[arsankhyan@gmail.com](mailto:arsankhyan@gmail.com) (A.R. Sankhyan).



**Fig. 1.** At its height in period III (2600–1900 B.C.), the Indus territory (red) covered approximately 1,000,000 km<sup>2</sup> of South Asia. The Indus Civilization participated in exchange relationships across West Asia, a trade network known as the third millennium B.C. Interaction Sphere. (For interpretation of the references to color in this figure legend, the reader is referred to the web version of this article.)

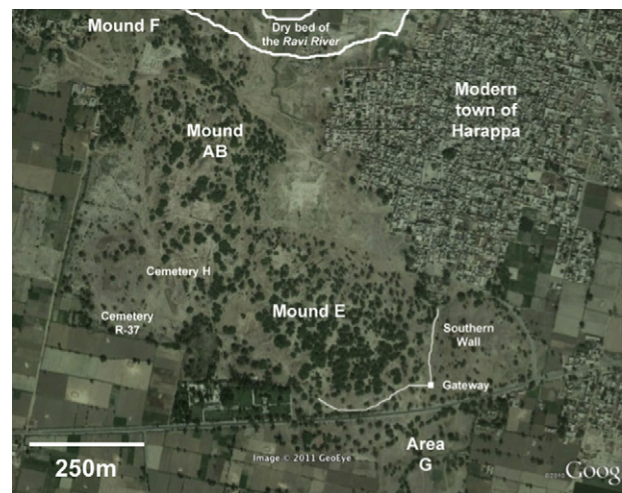assault is recorded in the human skeleton. Archeological records of these injuries include fractures, signs of healing, and sometimes infection in the human skeletal material. In this paper, we use these signs on the skeleton to infer the biosocial implications of urbanization, and its disintegration. We will reconstruct the mechanisms, patterning, and prevalence of injury for three burial communities at Harappa, which span the urban and post-urban time frame. Finally, we examine the evidence for social differentiation and structured risks for violence across time, sex, and burial treatment to test this hypothesis that Harappa was an exceptionally ‘peaceful realm’ without significant social differentiation.

## 2. Materials and methods

This analysis is based on human skeletal remains excavated from the Indus Civilization site of Harappa (30°37' North latitude, 72°52' East longitude) (Fig. 2). Excavations began at Harappa in 1929 and 26 field seasons have occurred since that time (see Vats, 1940; Wheeler, 1947, 1953; Dales and Kenoyer, 1991; Meadow, 1991). Harappa began as a small city founded on the southern bank of the Ravi River around 3800 B.C. and it grew relatively slowly for a millennium. The initial settlement was located on Mound F at the northern end of the site. Urbanization began around 2600 B.C. and Harappa rapidly grew to cover more than 100 ha<sup>1</sup> (Possehl, 1999). This process of urbanization led to expansion of the city limits, eastward to Mound E in period IIIA (2600–2450 B.C.), when an outer city wall was constructed. By period IIIB (2450–2200 B.C.), the population grew to more than 20,000 inhabitants; this population growth and accumulating refuse led to a shift in the core area of the city, to a high mound labeled Mound AB. Mound AB was now surrounded by another brick wall, characterized as a “citadel” (Wheeler, 1953). It was also during this period of expanding population size that

Cemetery R-37 was situated on a low plain southwest of Mound AB.

In period IIIC (2200–1900 B.C.), the archeological evidence suggests massive population growth overwhelmed all areas of the site of Harappa; the city became more densely populated, somewhat less organized in regard to settlement planning, and refuse began to accumulate on Mound AB (Kenoyer, 1998). Following this period of massive growth, another significant transition occurred. For reasons not fully understood, population growth in the cities halted. A process of decentralization began. As



**Fig. 2.** Harappa was a city on the south bank of the Ravi River. The settlement started as a small town centered around Mound F in the incipient stages of the settlement (3800–2600 B.C.). As many as 20,000 inhabitants lived Mound E and AB during the urban period (2600–1900 B.C.). Cemetery H (Stratum II) and the Area G ossuary were used in the post-urban period (1900–1700 B.C.). Area G is a low lying field southeast of the sewer drain at the southern gateway. Much of the site became depopulated during this time. A small population persisted at the site until it was completely abandoned in 1300 B.C. Cemetery H Stratum I was used during this late phase occupation.

<sup>1</sup> The extent of the city is estimated from the size of the mound of archaeological deposits and the artifact scatter but the actual extent may have been as much as 200 ha (Possehl, 2002, p. 66).

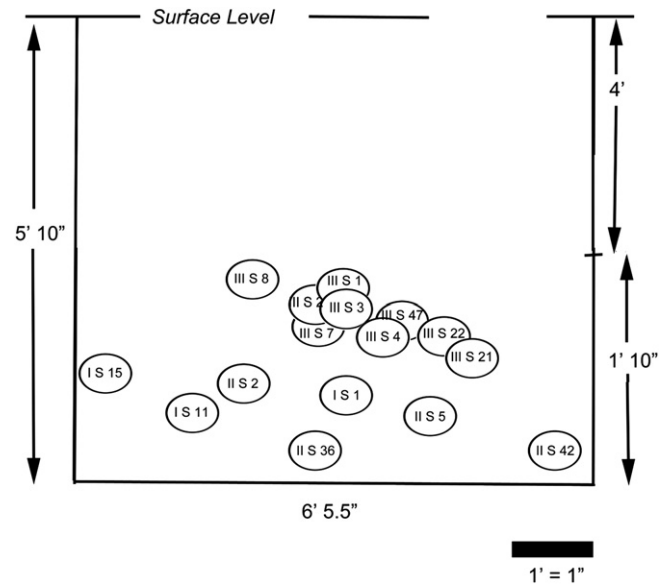
the urban centers diminished in size and importance, villages sprang up to the east and south of Indus territory. At Harappa, the center of Mounds AB and E continued to be occupied but peripheral areas of the mounds were abandoned in periods IV (1900–1700 B.C.) and V (1700–1300 B.C.). It was during these two phases that Cemetery H was utilized, located southwest of Mound AB but somewhat closer to the settlement than Cemetery R-37. It was also during this time (period IV) that an ossuary was dug (Area G), outside the city walls to the southeast of Mound E.

Human skeletal remains were recovered in excavations seasons 1929–1930, 1933–1934, 1938–1941, 1945–1946, 1967–1968 and 1986–1991. This paper reports on the skeletal remains from three localities that were excavated in 1929–1930, 1933–1934 (Vats, 1940), 1938–1939, 1940–1941 (Sastri, 1965), and 1946–1947 (Wheeler, 1947). These remains have previously been inventoried, photographed, and measured (Gupta et al., 1962). The skeletons derive from Cemetery R-37, Cemetery H, and Area G. Of the 235 individuals excavated in those five field seasons, 157 (67%) are available for study at the Anthropological Survey of India (AnSI), Kolkata.

Archeologists estimate that Cemetery R-37 covered about 50 m × 50 m during the mature Harappan period. Bodies were usually interred in a supine, extended posture, with a north-south orientation, head facing to the north. Two exceptions were an adult male in a brick lined chamber and an adult female buried in a shroud, inside a wooden coffin. Graves in Cemetery R-37 contained pottery; shell jewelry; beads of semi-precious stones, gold, and steatite; toilet objects such as mirrors, shell spoons, and small containers; and other grave goods. There were anywhere from 2 to 40 pots accompanying these burials, the average number of ceramic pieces was 18. The pots were both utilitarian and decorative forms similar to those found in the habitation area of the site. Shell bangles were only found in graves of female skeletons. These burials are also the only burials from the mature period IIIB at Harappa (2450–2150 B.C.) and they were the most elaborate and the richest of any cemetery at the site. A total of 209 skeletons<sup>2</sup> were excavated from Cemetery R-37; 66 (31.6%) individuals were available at AnSI for the present research.

Detailed scientific analyses were published on the human skeletal remains from Cemetery R-37 recovered from 1986 to 1989 during the HARP project (Hemphill et al., 1991; Lovell, 1994, 1997a; Lovell and Kennedy, 1989; Lukacs, 1992). This sample was skeletally relatively healthy with a low prevalence of iron-deficiency anemia (6.7%), as determined by the presence of porotic hyperostosis and cribra orbitalia in two out of 29 crania recovered. The most common pathological condition reported was degenerative joint disease (DJD), represented by pitting on the centra and osteophytes on the apophyseal margins of the cervical vertebrae. A low frequency of enamel defects (4.5% individuals affected) and a moderate caries rate (6.8% individuals affected) suggested a low level of developmental stress and a mixed economic system with heavy reliance on agricultural effort for subsistence (Lukacs, 1992). Dental discrete traits were used to infer population affinities, which suggested strong affinities among the mature period Harappans and neighboring communities through time (Hemphill et al., 1991). There was no evidence for any biological discontinuity among the Cemetery R-37 population and later cemetery populations at the site.

<sup>2</sup> Forty-seven individuals were recovered in the 1938–1941 excavations (Sastri, 1965); 61 individuals were recovered in the Wheeler excavations (Wheeler, 1947). Mughal (1968) recovered remains from 11 individuals in his excavation at the edge of Cemetery R-37; and 90 individuals were excavated during the HARP project (Meadow et al., 1991).



**Fig. 3.** Excavations at Area G were undertaken by Sahni in the late 1920s and early 1930s. After uncovering some poor shelters in this area, an ossuary was discovered. It contained a pile of 20 skulls and isolated postcrania from humans and a dog. The position of the skulls is diagrammed below (after Vats, 1940).

Cemetery H consisted of two strata—Stratum II was in use from 1900 to 1700 B.C. and Stratum I was used from 1700 to 1300 B.C. The skeletons buried in Stratum II were laid out in an extended posture; these burials contained ceramics but no other associated grave goods. Vats recovered 20 individuals and Wheeler recovered three additional individuals from Stratum II; these are available for study at AnSI. Burials from Stratum I were contained in funerary jars and preservation was generally good such that even small perinates were preserved. Of the 78 individuals excavated by Vats, only 45 individuals (57.6%) from Stratum I were available for study at AnSI.

Area G is located in a low lying field outside the south-eastern wall of the city, just beyond a sewage drain built under the south-eastern gateway. Area G consisted of poorly preserved architectural remains, which were excavated in the earliest field seasons at the site (Vats, 1940). Adjacent to the architectural features, archeologists uncovered an ossuary (18 m × 18 m × 18 m) which contained a small number of goblets, vases, and offering dishes as well as 20 human crania and three mandibles (Fig. 3). The ossuary was dated by the ceramic typology; the styles were identified as belonging to the “Cemetery H culture” (i.e. similar to those found in Cemetery H Stratum II dated to 1900–1700 B.C.). No absolute dates are available for Area G. A few human postcrania were associated with these remains—mainly long bones ( $n=5$ ), a scapula, and two partial human vertebral columns. An additional vertebral column identified as belonging to a dog was also found in the ossuary remains. Remains from a minimum of 23 individuals were interred here and were available for study at AnSI. An early description of this material revealed evidence for traumatic injury in the Area G material (Gupta et al., 1962). Subsequent analysis demonstrated this evidence was inconsistent with a massacre or the Aryan Invasion hypothesis; the evidence was not otherwise interpreted (Kennedy, 1984, 1992, 1994, 2000).

The present investigation was undertaken at Anthropological Survey of India in Kolkata from January to July of 2011. The available skeletal material from Harappa ( $n=160$ ) is fragmentary (see Gupta et al., 1962 for a complete inventory). Many individuals are incomplete, poorly preserved, or covered with

**Table 1**  
Age and sex of skeletons from Harappa.

	N total	n examined	Immature	YA (18–34)		MA (35–54)		OA (55+)		Indet. adult
				M	F	M	F	M	F	
Cemetery R-37	108	66	3	3	9	2	3	7	3	36
Cemetery H										
Stratum II	26	26	6	0	4	0	2	0	1	13
Stratum I	78	45	15	0	5	0	2	3	1	19
Area G	23	23	9	1	2	3	2	1	0	5
Total	235	160	33	4	20	5	9	11	5	73

a thick layer of vinyl acetate preservative, which sometimes hindered macroscopic evaluations of trauma. When the preservative could be removed with a soft tooth brush, this was done. Otherwise observations were limited to observable surfaces.

Because this skeletal collection was initially studied for evidence of 'racial' affinities, a priority for anthropological research for many decades, cranial material is all that remains preserved for most of the adults. Thus precise sex and age estimation were not always possible. Sex and age estimation for adult skeletons was performed using methods in Standards for Data Collection (Buikstra and Ubelaker, 1994). Sex was estimated using pelvic indicators when the pelvis was present; otherwise cranial features were used. Age was estimated using cranial suture stenosis and dental attrition (Lovejoy et al., 1985), the latter was preferred when teeth were available. The specimens were categorized into three general age groups: young adult (18–29), middle adult (30–54), and older adult (55+). These categories are consistent with earlier studies of the material from Cemetery R-37 (Lovell, 1994, 1997a; Lovell and Kennedy, 1989). Age was estimated for immature individuals based on dental development, dental eruption timing, and epiphyseal fusion (Scheuer and Black, 2000). Sexing of subadults was not attempted.

The skeletal remains were examined for evidence of trauma including fractures, dislocations, and signs of healing such as hematoma and callous formation (criteria from Lovell, 1997b, 2008). Evidence for medical intervention was also examined. Injuries were recorded by element affected, side, and specific location. The state of healing was described and type of injury was recorded. Cranial fractures were classified into injuries caused by sharp or blunt force trauma, the latter was defined as any injury resulting from a broad instrument. Blunt force trauma was further divided into linear versus depression fractures. Depression fractures were further subdivided into stellate, comminuted, and pond fractures. Postcranial trauma in long and tubular bones was recorded as affecting the proximal or distal epiphysis, proximal, middle or distal thirds of the shaft. These injuries were also recorded as transverse, oblique, spiral, impaction, avulsion, penetrating, crush and comminuted fractures.

Prevalence of injuries was estimated using the frequency of individuals affected by a given class of injury (cranial or postcranial trauma). The frequency of trauma in a particular class of skeletal elements was also examined (e.g. the percentage of metatarsals affected out of the number of individuals with metatarsals present in the skeletal assemblage). Inferences were drawn from direct observations on individuals analyzed for this project, as well as published observations on the skeletons excavated from Cemetery R-37 during the 1986–1989 HARP project excavation ( $n=90$ ). Those remains are stored elsewhere and were not available in the present analysis however, they have been analyzed previously for evidence of trauma (Lovell, 1994, 1997a; Lovell and Kennedy, 1989). The results of those analyses were negative; there was no evidence for traumatic injury in the 90 individuals studied previously.

### 3. Results

This project examined incomplete skeletal remains from 160 individuals excavated from three burial areas at Harappa. Age and sex were indeterminate for 68 individuals (42.5%) due to incompleteness of the remains and/or poor preservation (Table 1). Of the remainder, sex was not estimated for 33 (20.6%) immature individuals. Of 59 adults remaining, there were 24 young adults (40.7%), 14 middle aged adults (23.7%), and 15 older adults (25.4%). Fifty-eight individuals (36.3% of individuals examined) had intact crania—11 (33% of the immature individuals, 44 (77.8%) of the adults with age estimates, and 6 (8.8%) of the adults of indeterminate age (Table 2).

Trauma is divided into postcranial and cranial injuries. Postcranial trauma at Harappa affected only 3/160 (1.9%) individuals studied in this analysis and thus less attention will be given to this evidence. The postcranial injuries affected wrist, hand, and foot bones and they are consistent with either accidental or violent injuries. In this paper, we will focus on cranial trauma as it is the most common form of injury, affecting 9/58 (15.5%) of crania examined (the sample of crania is described in Table 2). Cranial trauma affected 4% of the total number of crania from Cemetery R-37<sup>3</sup>; 50% of the crania from Area G; 38% of the crania from Cemetery H Stratum II; and there were no affected individuals from Cemetery H Stratum I (Table 3). In all, 17% of the adult male crania were affected and 22% of the adult female crania were affected. Of 11 immature individuals studied, 18% were affected. Detailed description of the injuries are provided below.

#### 3.1. Postcranial trauma

The postcranial injuries included a healed Colle's fracture in an adult left radius and healed injuries to one adult left second metacarpal and one adult left fifth metatarsal. The Colle's fracture occurred in an isolated radius from an adult individual (G.289.L.7) interred in the Area G ossuary. The fracture was extra-articular, occurring just proximal to the distal articular capsule, however the radiocarpal joint surfaces for both the lunate and the scaphoid were affected by reduced surface area; the diaphysis is gracile suggesting the bone has undergone some resorption from disuse. The fracture is completely healed and the bone alignment was preserved during the healing phase. This type of fracture commonly occurs as a result of a fall, when an individual lands on an outstretched hand.

A fractured left second metacarpal was the only fractured hand bone in the Harappan skeletal series. The affected individual (H.255A) was an older adult male who was interred in Cemetery H Stratum I (the jar burials). This transverse fracture was located in the central segment of the diaphysis, 31 mm from the distal end of the bone (total length = 74 mm). There does not appear to have been rotation or displacement of the bone, suggesting intermetacarpal

<sup>3</sup> This percentage does not include 90 individuals excavated from Cemetery R-37 during the HARP project. That material was studied previously and no evidence for trauma was reported (Lovell, 1989, 1994, 1997a).

**Table 2**  
 Age and sex of skeletons from Harappa with intact crania.

	N total examined	n crania examined	Crania examined							
			Immature	YA (18–34)		MA (35–54)		OA (55+)		Indet. adult
Sex				M	F	M	F	M	F	
Cemetery R-37	66	24	3	3	3	2	3	7	3	0
Cemetery H										
Stratum II	26	8	2	0	3	0	2	0	1	0
Stratum I	78	16	3	0	3	0	2	2	0	6
Area G	23	10	3	1	2	2	1	1	0	0
Total	160	58	11	4	11	4	8	10	4	6

ligaments and intrinsic muscles may have remained intact. However, the angle of the shaft and the length, were affected. The fracture resulted in an angulation of the diaphysis, with a dorsal apex which shortened the metacarpal by approximately 5 mm and would have affected the metacarpo-phalangeal joint. This injury probably also affected the extensor ligament of the hand and limited range of motion in the first digit (Strauch et al., 1998). The fracture probably resulted from direct axial loading caused by a blow to the palmar surface of the hand. It is not possible to infer from the morphology of the break whether this injury was accidental, occupational, or intentional. There is no reason to suspect intentional violence.

There was one fractured metatarsal in the Harappan skeletal series. The affected individual (H.82b) was an adult who was also interred in Cemetery H Stratum I. The fracture occurs on the distal half of the diaphysis, 24 mm from the head (total length = 69 mm). The distal half of the diaphysis is rotated laterally; the diaphysis is angled with a dorsal apex that would have led to shortening of the metatarsal by more than 5 mm. The malalignment resulted in osteophyte growth on the plantar surface. This healed fracture resulted from direct force to the dorsal aspect of the foot, perhaps from an object falling on the foot; there is no reason to suspect intentional violence.

### 3.2. Cranial trauma

Nine individuals from Harappa suffered from cranio-facial trauma—two immature individuals, four adult females, and three adult males (Table 3). One adult male (8%) and one adult female (11%) from Cemetery R-37 were affected. Specimen H.796B was a middle aged adult male with two depression fractures on the right parietal. A fracture superior to and running parallel with the temporal line, caused plastic deformation and upheaval of the bone from the coronal suture to the parietal eminence. A second fracture runs perpendicular to the first, from the sagittal to the squamous suture. This fracture left a depression, approximately 50 mm in length and 20 mm in breadth. There is no evidence of healing or remodeling around either of these lesions. A round hole (5 mm in diameter) near asterion has been described previously as a trepanation (Sankhyan and Robbins Schug, 2011). In that paper, a raised margin around this hole was interpreted as indicating sclerosis. However, the margins are coated with preservative and not entirely visible. Trepanation

should be confirmed by imaging the rim and the internal compact bone using Computed Tomography. Until that imaging is done, this diagnosis remains speculative.

One adult female from Cemetery R-37 (H.820) has a completely penetrating defect on each of the right and left parietals (Fig. 4). Bilateral parietal thinning due to osteoporosis has contributed to the morphology of the perforations (Auferheide and Rodriguez-Martin, 1998, p. 15; Berryman and Symes, 1998). The smooth, rounded, slight margins of both lesions and porosity on the adjacent cortex support an antemortem origin. Osteitis is not diagnostic and would be expected whether the etiology of these perforations was solely related to parietal thinning, or if they were iatrogenic or traumatic in origin. However, the presence of adhering fragments along the scalloped, uneven edges of the perforations provides weak support for a traumatic origin. This older adult female also demonstrates evidence of a rhino-maxillary infection, including dental abscessing on the left maxilla, antemortem tooth loss of the anterior maxillary dentition, and widening of the nasal aperture.

Three adult female skeletons from Cemetery H Stratum II were affected by cranial trauma. Individual H.698 has four linear cranial depression fractures. An injury stretches across the frontal squama, from the right coronal suture to the midline. Another depression fracture follows the right temporal line, starting at pterion. These two fractures are approximately 20 mm in width. A large depression fracture, 40 mm in width, extends across the right side of the cranial vault, from the coronal to the lambdoid suture. Another fracture extends up from the mastoid to run perpendicular to and intersect with this fracture. Oblique fracture lines extend from all of these injuries and fracture 3 also has concentric fracture lines radiating from the injury. The extreme force involved, the number of blows, and the absence of any sign of healing indicates these injuries were perimortem (Sauer, 1998).

Two middle aged adult females in Cemetery H Stratum II had healing circular depression fractures on the frontal bone. Both of these lesions were 20 mm in diameter. Porosity and evidence for remodeling indicate these traumata occurred antemortem. Individual H710 had a similar small circular lesion on frontal bone near bregma. Peripheral upheaving at the circumference of this lesion indicates a powerful blow (Fig. 5). The latter individual also has a linear depression fracture on the occipital squama above the external occipital protuberance. This fracture is 10 mm wide. There is evidence for extracortical bone formation near

**Table 3**  
 Proportion of individuals affected by cranial trauma.

Burial area	Dates (B.C.)	n crania examined	Affected <sup>a</sup>	n affected immature crania	n affected male crania	n affected female crania
Cemetery R-37	2450–2150	24	0.04	0.00	0.08	0.11
Cemetery H St II	1900–1700	8	0.38	0.00	0.00	0.50
Cemetery H St I	1700–1300	16	0.00	0.00	0.00	0.00
Area G	1900–1700	10	0.50	0.66	0.50	0.33
Total		58	0.16	0.18	0.17	0.22


<sup>a</sup> n affected/n total crania examined.



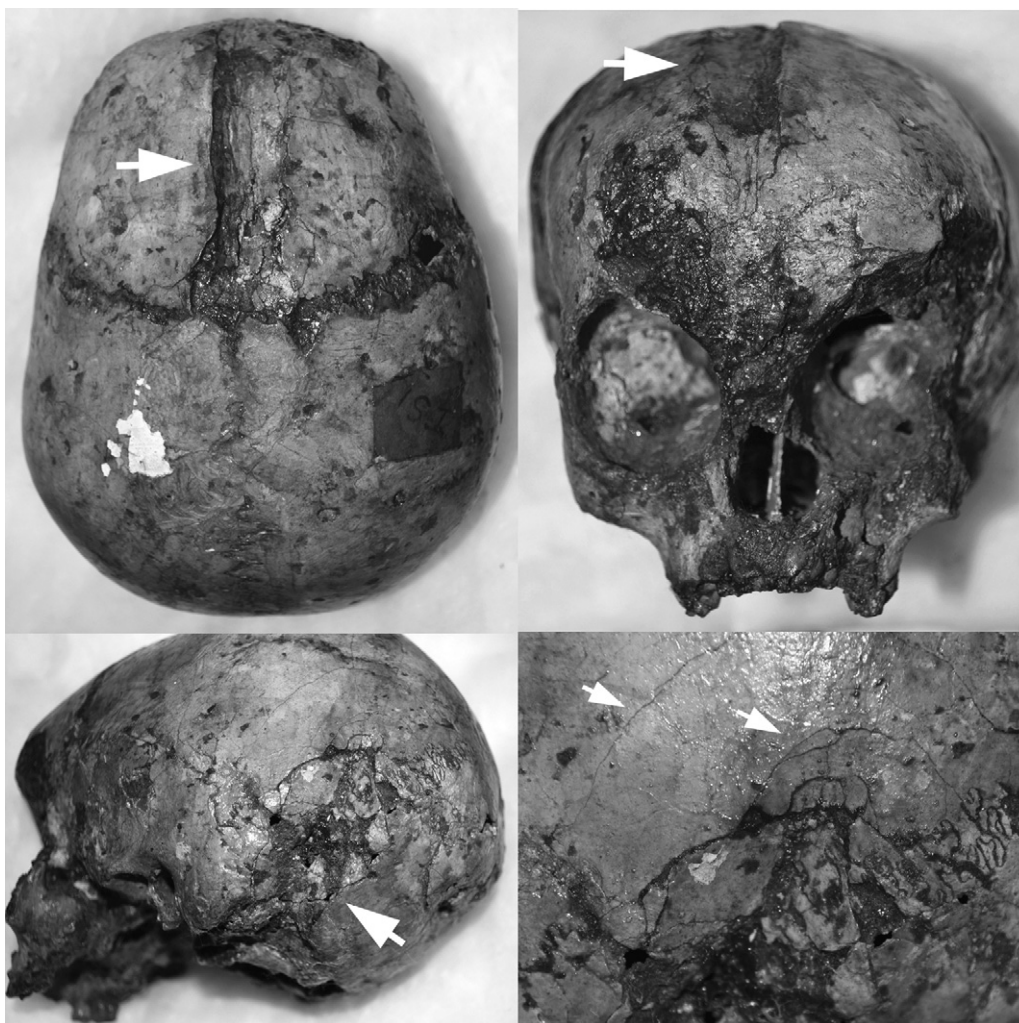
**Fig. 4.** An older adult female from Cemetery R-37 had two injuries on the right and left parietal. Parietal thinning due to advanced age affected this individual prior to these perforations in the skull. The margins of these openings in the cranial vault are thin, suggesting healing. The antemortem nature of these wounds is also indicated by their rounded margins, porosity inside the depressions, and adhering bone fragments.

this lesion, supporting an antemortem origin. Individual H.488 has a similar circular lesion on the squamous portion of the frontal bone 7 cm from the coronal suture at bregma. Though still visible, this lesion has undergone more significant remodeling.

Two immature and three adult crania from the Area G ossuary were affected by cranial trauma. Individual I.S.1 was a child, 4–6 years of age based on dental eruption. A depression fracture runs from bregma, down to the frontal squama between the eminences (Fig. 6). It is approximately 17 mm wide and 90 mm long. The outer



**Fig. 5.** This middle adult female from Cemetery H (Stratum II) had a depression fracture on the occipital (left) and a small round lesion on the frontal squama (top right). The occipital bone superior to the depression fracture was porous and actively remodeling (bottom right).



**Fig. 6.** This 4–6 year old child from Area G has a depression fracture on the frontal bone (top left and right) and another fracture on the occipital bone (bottom left and right).

table of compact bone is crushed near bregma. Oblique and concentric fracture lines at the superior end of the fracture extend to the coronal suture. A second injury is located on the left side of the skull along the lambdoid suture. This fracture is roughly 35 mm wide and 80 mm in length. Concentric fracture lines extend across the posterior left parietal and the left side of the occipital. Oblique fracture lines extend from the superior margin of the depression up the parietal. The outer table is crushed near the mastoid process. Neither injury demonstrates evidence of healing.

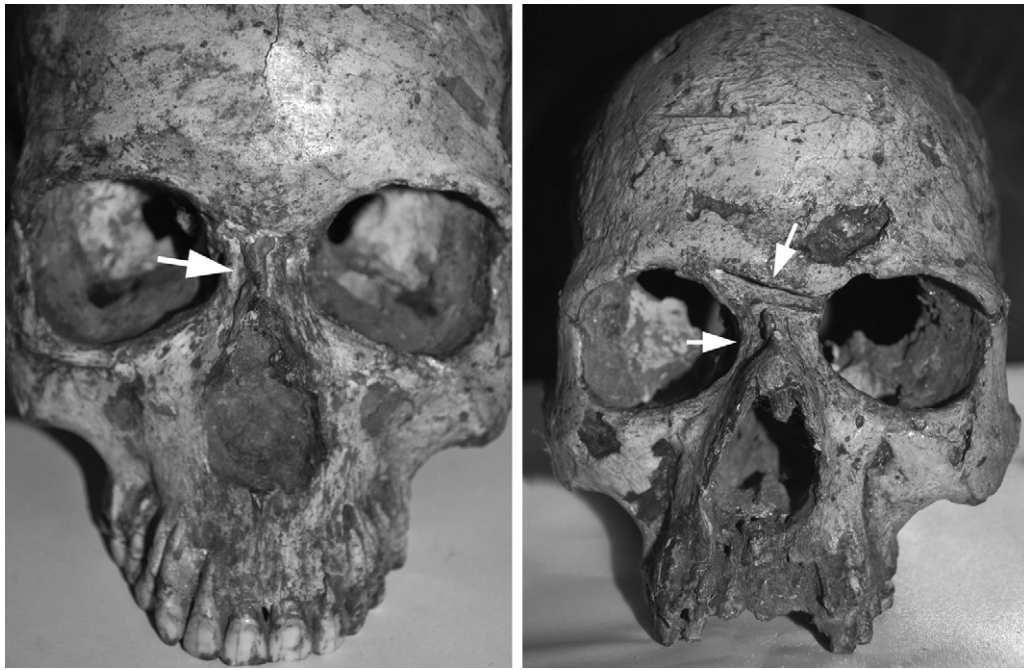Another cranium from a 4 to 6-year old child from the Area G ossuary (III.S.1) is damaged post-mortem, making evaluation difficult. However, this individual has plastic deformation on the posterior part of the right parietal, superior to the squamous suture. The plastic deformation suggests this occurred in the perimortem period. Adjacent to this depression, inferior to the parietal eminence on the right parietal, there are concentric fracture lines. Unfortunately the neurocranium is broken postmortem, obscuring the nature of this deformation. There is no evidence of healing on the portion of the vault that is present.

One adult female and two adult males from the Area G ossuary were affected. The adult female, individual III.S.47 has a depression fracture on the left parietal, approximately 17 mm wide and 75 mm in length. Oblique fracture lines extend from the superior and inferior margins, traversing the sagittal and coronal sutures. There is no evidence for healing on this cranium, however a large

amount of preservative and adhering matrix obscures some of the surfaces.

Fractures of the nasal bones affect both adult males from Area G (I.S.11 and II.S.5) (Fig. 7). Individual I.S.11 is a middle aged adult male. The nasal fracture affects the left nasal bone and the degree to which it has healed indicates an antemortem injury. This individual also has sharp blunt force trauma to the frontal bone at glabella, inflicted by a sharp, long, heavy object. The maximum width of this injury is 5 mm. It is 25 mm in length and extends to the medial margin of the left orbit.<sup>4</sup> Sclerosis on the medial margin indicates it was an antemortem injury. This individual also demonstrates destructive, remodeling lesions from an extensive infection affecting the frontal, parietals and the occipital bones (Fig. 8). Circular, crater-shaped lesions are most severe near the left coronal suture. In addition to these healed fractures in the splanchnocranium, II.S.5 has vertical fractures in the right and left central and lateral incisors and canines. These craze lines result from extreme occlusal forces; they are common and a relatively inconsequential form of enamel fracture (Kahler, 2008) that result from trauma, occupational behavior, and accidental injury.

<sup>4</sup> This is the only example of an injury like this in the Harappan series; however a similar injury was recorded in the left tibia of a skeleton from the Indus site of Kalibangan (Sharma, 1999). That injury was described as a “sword cut” but that evidence has yet to be confirmed.




**Fig. 7.** Two adult males from Area G had broken noses. One of these individuals had no other evidence of trauma (top left). The other male had a sharp blunt force injury to the frontal bone at glabella (right).

#### 4. Discussion

Trauma affects skeletal elements differently depending on the size, shape, and composition of the bone, the size and shape of the instrument that impacted the bone, and the force of the impact (Arbour, 2008). Thus, bioarcheologists can infer the proximate cause of injuries from an examination of the type, location, and shape of traumatic lesions. In our discussion, our first responsibility is to address the question of whether the data presented here represent evidence for post-mortem or peri-mortem damage, accidental or violent injury. Paleoepidemiology—an examination of the prevalence and pattern of injuries—can then be used to infer the ultimate causes of violence (Galloway, 1999; Lovell, 1997b; Walker, 2001). In this regard, we must first address historical explanations for conflict in the Indus Civilization, specifically the idea that this evidence might be misconstrued as supporting the ‘Aryan Invasion’ model. Finally, we will discuss intrinsic explanations for violent injury, implications for social structure, and state formation at Harappa.

We argue that the cranial traumata at Harappa are inconsistent with post-mortem damage or accidental injuries; instead, the data clearly indicate inter-personal violence. All of the traumata we have described demonstrate plastic deformation, oblique and concentric fracture lines, and/or evidence of healing. These features are consistent with peri- and ante-mortem origin of these injuries. Furthermore, the lesions lack sharp margins, crushing, color changes, and other characteristics associated with post-mortem damage (Galloway, 1999; Walker, 2001). The types of trauma seen in the Harappan skeletons are inconsistent with accidental injuries, which tend to result in blunt force trauma to the mid-section of the skull, above the ears (Berryman and Symes, 1998). The lesions we described are of five types: (1) injuries to the upper and lower portions of the cranial vault consistent with forceful blows from a long, club-like weapon, (2) circular depression fractures on the frontal squama, near bregma, (3) sharp blunt force trauma to the facial skeleton, (4) broken noses, and (5) lesions suggestive of trepanation. Aside from the last, this pattern of injuries is consistent with interpersonal violence, although nasal fractures can



**Fig. 8.** One male skull from Area G demonstrated evidence of sharp blunt force trauma. That individual also had destructive and remodeling lesions from an infection on the cranial vault.



occasionally occur as a result of accidental injury (Walker, 1997). As for the 'trepanations', they must be investigated further using CT and we refrain from interpretation of those cases until such time that research can be completed, if ever.

The total rate of violent cranial injury we observed at Harappa was 15.5% of crania observed (4% of individuals). Five individuals (5.6%) demonstrated no evidence for healing—both of the affected children, two females, and one male. Two of these five (40.0%) were immature individuals and one was beaten severely, having sustained four distinct injuries that were probably fatal. In fact, seven of the nine (77.8%) affected individuals from Harappa were injured more than once, indicating interpersonal violence was a recurrent feature of life for some individuals at Harappa.

The rate of injury we observed at Harappa is relatively high for urban societies in general (Pinker, 2011) but it becomes even more significant when considered in the South Asian context. Cranial trauma has not been frequently observed in previous studies of large skeletal series from diverse populations across the subcontinent. There is no evidence of violent cranial trauma in skeletal series from Early Holocene hunter-gatherer populations from the Gangetic plains (Kennedy et al., 1986, 1992; Lukacs and Pal, in preparation; Robbins et al., 2004); the Bronze Age cemetery at Timargarha (Bernhard, 1968); settled villages of the second millennium B.C. in west-central India (Lukacs and Walimbe, 1986; Mushrif and Walimbe, 2006; Robbins Schug, 2011; Walimbe, 1986); or more recent prehistoric sites like Sarai Khola (Bernhard, 1969), Jotsoma (Mushrif-Tripathy et al., 2009), and Kodumalan (Mushrif-Tripathy et al., 2011). In contrast, the rate at Harappa is significantly greater and is the highest recorded rate in the prehistoric period thus far recorded.

#### 4.1. Violence at Harappa: ultimate explanations

Historically, evidence for trauma at Indus sites has been framed by the debate about Indo-European, or 'Aryan' Invasion. Aryans are consistently invoked in linguistics, history, and archeology of the subcontinent (Chanda, 1916; Childe, 1926; Marshall, 1926–1927; Wheeler, 1947, 1953). Through this lens, monumental architecture at Harappa became a citadel; haphazardly arranged skeletons at Moenjo Daro embodied a massacre; the disintegration of centralized authority was evidence of destruction wrought by invaders (Wheeler, 1947, 1953; Piggott, 1950; Sorley, 1959). In response, processual anthropologists employed the dead as symbols of the mythical nature of the invasion (Dales, 1964; Kennedy, 1984, 1992, 1994; Leach, 1990). Some traumatic injuries from Harappa were vaguely described in early studies of the skeletal material (Gupta et al., 1962), but the interpretation of violence was framed entirely by the question of Aryan invasion (Kennedy, 1984, 1994). For example, in Kennedy's *God Apes and Fossil Men*, the evidence for traumatic injuries at Harappa is described only by saying "markers of trauma to the head [at Harappa] increase over postcranial lesions within the urban-village setting" (Kennedy, 2000, p. 305). After decades working to dispell the myth of Aryan Invasion, it is perhaps not surprising that no further interpretation was offered and evidence for violence at Harappa was, in effect, downplayed (though not at all ignored).

Because anthropologists and geneticists have effectively dispelled the Aryan Invasion model, we can begin to seek intrinsic explanations for violence at Harappa. Our goal in this analysis was to examine the hypothesis that Harappa was a 'peaceful realm' and a rare example of a state without social differentiation or structural violence. Thus, our main interest is in the ultimate cause of violence at Harappa, the structure of Indus society, and the function of violence within it. Human skeletons are artifacts, inscribed by lived experience and social meaning (Barrett, 1994; Meskell, 2000).

Osteobiographies can speak to "the 'texture' of dire affliction" (Farmer, 1997, p. 263) but above the level of the suffering inscribed on individual skeletons, there is a pattern of lesions that translates the matrix of social experience (Farmer, 1997; Meskell and Preucel, 2006). In addition, the dead do not bury themselves and so mortuary treatment and burial location can also inform us about the traditions, semiotics, and the agency of the living people who did the burying.

The pattern and prevalence of injuries at Harappa varies through time by sex, age, and burial community. The urban period Cemetery R-37 is distinguished by the lowest rate of cranial trauma at Harappa (2/24 crania, or 8.3%). Only one adult male (4.2%) demonstrates evidence of violent injuries. Previous research on the remains from Cemetery R-37 ( $n=90$ ) also recorded no evidence of violent cranial injuries (Lovell, 1994, 1997a,b). The low prevalence of violent trauma (1/156 total individuals, or 0.6% of individuals) in this burial population is interesting in light of other unique archeological features. Cemetery R-37 was the only burial ground excavated from the mature period and these burials are the only interments with abundant grave goods and personal ornaments. During the mature period, the population at Harappa reached more than 30,000 people. Obviously, the majority of those who died during this time were not buried in Cemetery R-37 and it is presently unclear how or why these individuals were differentiated. However, it is clear that social differentiation also appears to have been associated with relatively low risk for personal violence and perhaps greater access to medical intervention. Two individuals buried in this cemetery demonstrate lesions consistent with trepanation, possibly a medical intervention to deal with symptoms related to trauma or other pathology. If additional imaging is performed and an iatrogenic origin for these lesions is confirmed, then it is interesting to note that these medical interventions are also unique to the Cemetery R-37 burial community.

Violence is much more prevalent in the post-urban period burials; women and children were at greatest risk during this period. Of the 18 crania examined from the post-urban period (the pooled sample from Cemetery H Stratum II and the Area G ossuary), eight individuals were affected by cranial trauma (44.4%): two males (2/4, 50.0%), four females (4/9, or 44.4%), and two children (2/5, or 40.0%). Clear differences emerge between the two post-urban period burial communities as well. Of the six adult female individuals with well preserved cranial material from Cemetery H (Stratum II), 50% were affected by blunt force trauma. Six immature crania from Cemetery H were unaffected. In contrast, in the Area G sample, 50% of male crania (2/4), 33% of female (1/3), and 66% of immature crania (2/3) were affected by cranial trauma (50% of individuals with cranial remains). Area G was the only burial community at Harappa in which children suffered traumatic cranial injuries. At Area G, new types of injuries were also recorded including healed broken noses in both of the affected males, and a sharp blunt force trauma at glabella in one male.

The Area G ossuary is undoubtedly unique in other important ways. Unlike R-37 and H, Area G is not a formal cemetery. Instead, it is a trench that was dug in a low-lying area, where poorly constructed small dwellings were located outside the city wall. It also happens to be located southeast of the city's main sewer drain (Vats, 1940). Given the well-known Harappan preoccupation with cleanliness and sanitation, the placement of this ossuary appears significant. Also unlike the city cemeteries, individuals were not buried here. Instead, 20 crania were piled in this trench, along with isolated postcrania, and the articulated spinal column of a dog. In fact, this communal burial of human and animal body parts, with no special distinction for children, appeared so unique that the excavation report describes these remains as the discarded victims of an epidemic or a massacre (Vats, 1940).

Relative to the mature period cemetery, the level of violence clearly increased significantly in the post-urban period burials at Harappa. Also in the post-urban period, women and children were at increased risk, as were those individuals whose body parts were interred in Area G. The post-urban period was a time of social transformation throughout the Indus Civilization—the third millennium interaction sphere collapsed, the majority of the populace emigrated from the urban centers, and there was an apparent nihilism toward Indus technology, styles, symbols, and standards after 1900 B.C. (Possehl, 2002). Thus, it appears that increasing levels of violence accompanied the stress of dramatic, rapid social change in the post-urban period. Individuals that were already vulnerable due to their sex, age, social status, and other aspects of personal identity or community membership were increasingly at risk for inter-personal violence as the social structure disintegrated.

#### 4.2. Violence and the state: ideology and social structure at Harappa

Our results also provide limited insights into the development of Indus statehood. Despite the socio-cultural complexity of Indus cities and the standardization of styles and symbols across a vast territory during the Indus Age, defining this civilization as a prehistoric state has been problematic because it contrasts with contemporaneous states in West Asia, where tremendous burial monuments and obvious rulers provide clear evidence of social hierarchy, control over access to resources, and state monopoly on the use of force (Kenoyer, 1998; Possehl, 1998, 2002; Smith, 2003). In recognition of diverse human strategies for social organization and control of large territories (e.g. Smith, 2007), Possehl suggested 'exclusion' was not necessary for statehood. He argued for an alternative, heterarchical model whereby authority was based on a corporate model (Possehl, 2002). In more extreme interpretations, the Indus Civilization came to be portrayed as a 'peaceful realm' in which power was shared and society managed collectively (McIntosh, 2002, 2008). The human skeletal material was never consulted on questions of violence, exclusion, or social differentiation.

Violence is a heterogeneous category of behavior and the meaning of a violent act varies cross-culturally. While it is not possible to reconstruct 'normal' versus 'pathological' violence from the skeleton, or to tease apart the agency of individual actors from the institutional violence of a prehistoric state, it is clear that violent injury was a fact of life for some of the city's residents. Some Harappan people experienced, enacted, and witnessed violence. This violence varied in prevalence by sex, age, mortuary rites and mode of interment. Social differentiation and 'exclusion' clearly emerge from these data and they demonstrate that the Indus Civilization was not an exceptionally 'peaceful realm'. That idea must be rejected based on our evidence. Our results also suggest that it is not necessary to explain Indus statehood using a model of heterarchy because 'exclusion' and social differentiation are strongly indicated by mortuary and bioarcheological analysis. In addition, the uneven risk for violence and uneven access to resources may indicate further that Indus statehood was in fact based on exclusion and this structure determined the risk for violence. If supported by additional research, the Indus Civilization would have gone through a process of state formation that was not unique in the third millennium B.C.

#### 5. Conclusions

It is important to understand that bioarcheological analyses are impacted by incomplete, unexcavated, and poorly preserved

skeletal material. For example, the prevalence of trauma reported here only reflects the burials that were excavated, and the individuals with crania preserved for analysis. Our interpretations cannot represent the much larger numbers of dead who were not buried at Harappa, nor the living population.

However, based on the evidence for violent injury at Harappa, we argue that the Harappa was not an exceptional 'peaceful realm'. Rather, evidence of mortuary treatment, burial practice, and violence suggest that exclusion and social differentiation existed and they suggest that the social structure partially determined the risk for violent injury in Harappan society. We suggest that future research should address the hypothesis that structural violence—unequal power; uneven access to resources; systematic oppression; and, exploitation that kills through the denial of basic needs and/or outright violence (Galtung, 1969)—was part of the process of urbanization and state formation at Harappa. We predict that paleopathological analyses will reveal additional differences among these burial communities in the risk of disease, nutritional deficiencies, and developmental disturbances. Furthermore, evidence for social differentiation and structural violence should be examined in additional skeletal series from the Indus Age and future excavations should not be limited to the city, the cemetery, and the mound. Archeologists interested in questions of Indus statehood, social structure, and inequality must also excavate the beyond the city walls, in the low lying or 'outside' areas, at the margins of society.

The Indian archeologist, Sharma (1999) once suggested the Harappan people would be spinning in their graves, laughing that archeologists care so much about a people long dead. However, the concern with inter-personal violence and social structure at Harappa is not abstract in the Indian context, where stories about the remains of long dead people have a powerful impact on identity, religion, politics, and nationalism. The Harappans have so often been misrepresented as an exceptional, peaceful urban society without social stratification or structural violence. In reality, there is a predictable, longstanding relationship between structural violence, urbanization, and state formation and South Asia was not an exception. Because South Asia's past is a scholarly and a popular phenomenon though, work will be required to "forge a future" (Das and Kleinman, 1997) in relation to this representation of a past that was not free from violence.

#### Acknowledgments

This research was funded by a Fulbright-Nehru fellowship from the United States India Educational Foundation. Anthropological Survey of India allowed access to the collections and the Kolkata office staff provided research support. The authors would like to extend our appreciation to Rana Chakravarty, Shevanti Narayan, Sumanta Basu, Ambi Parasuram, and Laxmi Parasuram for logistical support. We would also like to thank Kamal K. Misra, Subhash Walimbe, Dilip Roy, and Ranjana Ray for their support. We appreciate comments on the manuscript from Mark Kenoyer and the anonymous reviewers.

#### References

- Akkermans, P.M.M.G., Schwartz, G.M., 2003. The Archaeology of Syria: From Complex Hunter-Gatherers to Early Urban Societies (c. 16,000–300 B.C.). Cambridge University Press, Cambridge.
- Auferheide, A.C., Rodriguez-Martin, C., 1998. Cambridge Encyclopedia of Human Paleopathology. Cambridge University Press, Cambridge.
- Arbour, L., 2008. Blunt force trauma. In: Kimmerle, E.H., Baraybar, J.P. (Eds.), Skeletal Trauma: Identification of Injuries Resulting from Human Rights Abuse and Armed Conflict. CRC Press, Boca Raton, pp. 151–180.
- Barrett, J.C., 1994. Defining domestic space in the Bronze Age of southern Britain. In: Pearson, M.P., Richards, C. (Eds.), Architecture and Order: Approaches to Social Space. Routledge, New York, pp. 87–97.

- Bernhard, W., 1968. Human skeletal remains from the bronze and early iron age cemetery of timargarha (Dir State, West Pakistan). In: Proceedings of 8th International Congress of Anthropological and Ethnological Sciences, Tokyo 2, pp. 144–215.
- Bernhard, W., 1969. Preliminary report on the human skeletal remains from the prehistoric cemetery of Sarai Khola, Pakistan. *Archaeology* 6 (1), 100–116.
- Berryman, H.E., Symes, S.A., 1998. Recognizing gunshot and blunt cranial trauma through fracture interpretation. In: Reichs, K. (Ed.), *Forensic Osteology. Advances in the Identification of Human Remains*. Charles C. Thomas, Springfield, pp. 333–352.
- Buikstra, J.E., Ubelaker, D.H., 1994. Standards for Data Collection from Human Skeletal Remains. Arkansas Archeological Survey, Fayetteville.
- Chanda, R.P., 1916. Indo-Aryan Races: A Study of the Origin of Indo-Aryan People and Institutions. Virendra Research Society, Rajshahi.
- Childe, V.G., 1926. The Aryans: A Study of Indo-European Origins. K. Paul, Trench, Trubner & Co., Ltd., London.
- Dales, G.F., 1964. The mythical massacre at Mohenjodaro. *Expedition* 6 (3), 37–43.
- Dales, G.F., Kenoyer, J.M., 1991. Summaries of five seasons of research at Harappa (District Sahiwal, Punjab, Pakistan) 1986–1990. In: Meadow, R.H. (Ed.), *Harappa Excavations 1986–1990 (Monographs in World Archaeology, No. 3)*. Prehistory Press, Madison, pp. 185–262.
- Das, V., Kleinman, A., 1997. Introduction. In: Das, V., Kleinman, A., Ramphele, M., Reynolds, P. (Eds.), *Violence and Subjectivity*. University of California Press, Berkeley, pp. 1–18.
- Farmer, P., 1997. On suffering and structural violence: a view from below. In: Kleinman, A., Das, V., Lock, M. (Eds.), *Social Suffering*. University of California Press, Berkeley, pp. 261–284.
- Galloway, A., 1999. Broken Bones: Anthropological Analysis of Blunt Force Trauma. Charles C. Thomas, Springfield.
- Galtung, J., 1969. Violence, peace, and peace research. *Journal of Peace Research* 6 (3), 167–191.
- Gupta, P., Dutta, P.C., Basu, A., 1962. Human Skeletal Remains from Harappa, vol. 9. Anthropological Survey of India, Memoire, New Delhi.
- Hemphill, B.E., Lukacs, J.R., Kennedy, K.A.R., 1991. Biological adaptations and affinities of bronze age Harappans. In: Meadow, R.H. (Ed.), *Harappa Excavations 1986–1990: A Multidisciplinary Approach to Third Millennium Urbanism (Monographs in World Prehistory No. 3)*. Prehistory Press, Madison, pp. 137–182.
- Kahler, W., 2008. The cracked tooth conundrum: terminology, classification, diagnosis, and management. *American Journal of Dentistry* 21 (5), 275–282.
- Kennedy, K.A.R., 1984. Trauma and disease in the ancient Harappans. In: Lal, B.B., Gupta, S.P. (Eds.), *Frontiers of the Indus Civilization*. Books and Books, New Delhi, pp. 425–436.
- Kennedy, K.A.R., 1992. Biological anthropology of human skeletons from Harappa: 1928 to 1988. *Eastern Anthropologist* 45 (1), 55–85.
- Kennedy, K.A.R., 1994. Identification of sacrificial and massacre victims in archaeological sites: the skeletal evidence. *Man and Environment* 19 (2), 242–251.
- Kennedy, K.A.R., 2000. God-Apes and Fossil Men: Paleoanthropology in South Asia. University of Michigan Press, Ann Arbor.
- Kennedy, K.A.R., Lovell, N.C., Burrow, C.B., 1986. Mesolithic Human Remains from the Gangetic Plain: Sarai Nahar Rai. Cornell University South Asian Occasional Papers and Theses, Cornell.
- Kennedy, K.A.R., Lukacs, J.R., Pastor, R.F., Johnston, T.L., Lovell, N.C., Pal, J.N., Hemphill, B.E., Burrow, C.B., 1992. Human Skeletal Remains from Mahadaha: A Gangetic Mesolithic Site. Cornell University, South Asia Program, Cornell.
- Kenoyer, J.M., 1997. Early city-states in South Asia: comparing the Harappan phase and early historic period. In: Nichols, D.L., Charlton, T.H. (Eds.), *The Archaeology of City-States: Cross-cultural Approaches*. Smithsonian Institution Press, Washington, DC, pp. 51–70.
- Kenoyer, J.M., 1998. Ancient Cities of the Indus Valley Civilization. Oxford University Press, London.
- Lahiri, N., 2000. The Decline and Fall of the Indus Civilization. Permanent Black, Delhi.
- Leach, E., 1990. Aryan invasions over four millennia. In: Ohnuki-Tierney, E. (Ed.), *Culture Through Time: Anthropological Approaches*. Stanford University Press, Palo Alto, pp. 227–245.
- Lloyd, A.B., 2010. A Companion to Ancient Egypt. John Wiley & Sons, New York.
- Lovejoy, O.C., Meindl, R.S., Mensforth, R.P., Barton, T.J., 1985. Multifactorial determination of skeletal age at death: a method and blind tests of its accuracy. *American Journal of Physical Anthropology* 68 (1), 1–14.
- Lovell, N.C., Kennedy, K.A.R., 1989. Society and disease in prehistoric South Asia. In: Kenoyer, J.M. (Ed.), *Old Problems and New Perspectives in the Archaeology of South Asia*. Wisconsin Archaeology Reports, vol. 2. Madison, WI, pp. 89–92.
- Lovell, N.C., 1994. Spinal arthritis and physical stress at bronze age Harappa. *American Journal of Physical Anthropology* 93 (2), 149–164.
- Lovell, N.C., 1997a. Anaemia in the ancient Indus valley. *International Journal of Osteoarchaeology* 7 (2), 115–123.
- Lovell, N.C., 1997b. Trauma analysis in paleopathology. *Yearbook of Physical Anthropology* 40, 139–170.
- Lovell, N.C., 2008. Analysis and interpretation of skeletal trauma. In: Katzenberg, M.A., Saunders, S.R. (Eds.), *Biological Anthropology of the Human Skeleton*. John Wiley & Sons, New York, pp. 341–386.
- Lukacs, J.R., 1992. Dental paleopathology and agricultural intensification in South Asia: new evidence from bronze age Harappa. *American Journal of Physical Anthropology* 87 (2), 133–150.
- Lukacs, J.R., Pal, J.N. Holocene Foragers of North India: the Bioarchaeology of Damdama, in preparation.
- Lukacs, J.R., Walimbe, S.R., 1986. Excavations at Inamgaon. *The Physical Anthropology of Human Skeletal Remains: Part I: An Osteographic Analysis*, vol. II. Deccan College Research Institute, Pune.
- McIntosh, J., 2002. *A Peaceful Realm: The Rise and Fall of the Indus Civilization*. Westview Press, Boulder.
- McIntosh, J., 2008. *The Ancient Indus Valley: New Perspectives*. ABC-CLIO, Santa Barbara.
- Marshall, J., 1926. The Indus culture. Annual Report of the Archaeological Survey of India. Govt. of India, New Delhi, pp. 51–60.
- Meadow, R.H. (Ed.), 1991. *Harappa Excavations 1986–1990: A Multidisciplinary Approach to Third Millennium Urbanism (Monographs in World Archaeology, No. 3)*. Prehistory Press, Madison.
- Meskell, L., 2000. Writing the body in archaeology. In: Rautman, A.E. (Ed.), *Reading the Body: Representations and Remains in the Archaeological Record*. University of Pennsylvania Press, Philadelphia, pp. 13–21.
- Meskell, L., Preucel, R.W., 2006. *A Companion to Social Archaeology*. Wiley-Blackwell, New York.
- Mughal, M.R., 1968. Harappa-1966 (Cemetery R-37). *Pakistan Archaeology* 5 (1), 63–68.
- Mushrif-Tripathy, V., Jamir, T., Vasa, D., Walimbe, S.R., 2009. Human Skeletal Remains from Megalithic Jotsoma. Center for Archaeological Studies and Training, Eastern India (CASTEI), Kolkata.
- Mushrif-Tripathy, V., Rajan, K., Walimbe, S.R., 2011. Palaeopathological Aspect of Osteological Studies Carried out on Iron Age site of Kodumanal, Tamil Nadu. Aryan Book Publisher, New Delhi.
- Mushrif, V., Walimbe, S.R., 2006. Human skeletal remains from chalcolithic nevasa: osteobiographic analysis. BAR International Series, vol.1476, London, UK.
- Pinker, S., 2011. *The Better Angels of Our Nature: Why Violence has Declined*. Viking Adult, New York.
- Piggott, S., 1950. *Prehistoric India to 1000 B.C.* Middlesex, Penguin Books.
- Pollock, S., 1999. *Ancient Mesopotamia: The Eden That Never Was*. Cambridge University Press, London.
- Possehl, G.L., 1990. Revolution in the urban revolution: the emergence of Indus urbanization. *Annual Review of Anthropology* 19, 261–282.
- Possehl, G.L., 1998. Sociocultural complexity without the state: the Indus Civilization. In: Feinman, G.M., Marcus, J. (Eds.), *Archaic States*. School of American Research Press, Santa Fe, pp. 261–291.
- Possehl, G.L., 1999. *The Indus Age: The Beginnings*. Oxford IBH, New Delhi.
- Possehl, G.L., 2002. *The Indus Civilization: A Contemporary Perspective*. Altamira Press, Lanham.
- Ratnagar, S., 1991. *Enquiries into the Political Organization of the Indus Civilization*. Ravish Publishers, Pune.
- Ratnagar, S., 2001. *Understanding Harappa: Civilization in the Greater Indus Valley*. Tulika, New Delhi.
- Robbins, G., Misra, V.D., Pal, J.N., Gupta, M.C., 2004. *Mesolithic Damdama: Dental Histology and Age Estimation*. Allahabad University Press, India.
- Robbins Schug, G., 2011. *Bioarchaeology and Climate Change: A View From South Asian Prehistory*. University Press of Florida, Gainesville.
- Sankhyan, A.R., Robbins Schug, G., 2011. First evidence of brain surgery in bronze age Harappa. *Current Science* 100 (11), 1621–1622.
- Sastri, K.N., 1965. *New Light on the Indus Civilization*. Atma Ram and Sons, Delhi.
- Sauer, N.J., 1998. The timing of injuries and manner of death: distinguishing among antemortem, perimortem and postmortem injuries. In: Reichs, K. (Ed.), *Forensic Osteology*. Charles C. Thomas, Springfield, pp. 321–332.
- Scheuer, J.L., Black, S., 2000. *Developmental Juvenile Osteology*. Academic Press, New York.
- Sharma, A.K., 1999. *The Departed Harappans of Kalibangan*. Sundeep Prakashan, New Delhi.
- Shaffer, J.G., 1982. Harappan culture: a reconsideration. In: Possehl, G.L. (Ed.), *Harappan Civilization: a Recent Perspective*. American Institute of Indian Studies and Oxford IBH, New Delhi, pp. 41–50.
- Smith, M.E., 2003. *The Social Construction of Ancient Cities*. Smithsonian Institution Press, Washington, DC.
- Smith, B.D., 2007. The transition to food production. In: Feinman, G.M., Price, T.D. (Eds.), *Archaeology at the Millennium: A Sourcebook*. Springer, New York, pp. 199–229.
- Sorley, H.T., 1959. The Former Province of Sind Including Khairpur State. Gazetteer of West Pakistan. Government of West Pakistan, Karachi.
- Strauch, R.J., Rosenwasser, M.P., Lunt, J.G., 1998. Metacarpal shaft fractures: the effect of shortening on the extensor tendon mechanism. *The Journal of Hand Surgery* 23 (3), 519–523.
- Vats, M.S., 1940. Excavations at Harappā, Being an Account of Archaeological Excavations at Harappā Carried Out Between the Years 1920–1921 and 1933–1934. Archaeological Survey of India, Govt. of India, New Delhi.
- Walimbe, S.R., 1986. Paleodemography of protohistoric daimabad. In: Sali, S.A. (Ed.), *Daimabad 1976–1979*. Archaeological Survey of India, New Delhi, pp. 641–740.
- Walker, P.L., 1997. Wife beating, boxing, and broken noses: skeletal evidence for the cultural patterning of interpersonal violence. In: Martin, D.L., Frayer, D. (Eds.), *Troubled Times: Violence and Warfare in the Past*. Gordon and Breach, New York, pp. 145–175.

- Walker, P.L., 2001. A bioarchaeological perspective on the history of violence. *Annual Review of Anthropology* 30, 573–596.
- Wheeler, R.E.M., 1947. Harappa 1946: the defenses and Cemetery R-37. *Ancient India* 3 (1), 58–130.
- Wheeler, R.E.M., 1953. *The Indus Civilization, Supplementary Volume: Cambridge History of India*. Cambridge University Press, London.
- Wenke, R.J., 2009. *The Ancient Egyptian State: The Origins of Egyptian culture (C. 8000–2000 B.C.)*. Cambridge University Press, London.
- Wright, R.P., 2010. *The Ancient Indus: Urbanism, Economy, and Society*. Cambridge University Press, London.