



Universitätsklinikum
Hamburg-Eppendorf

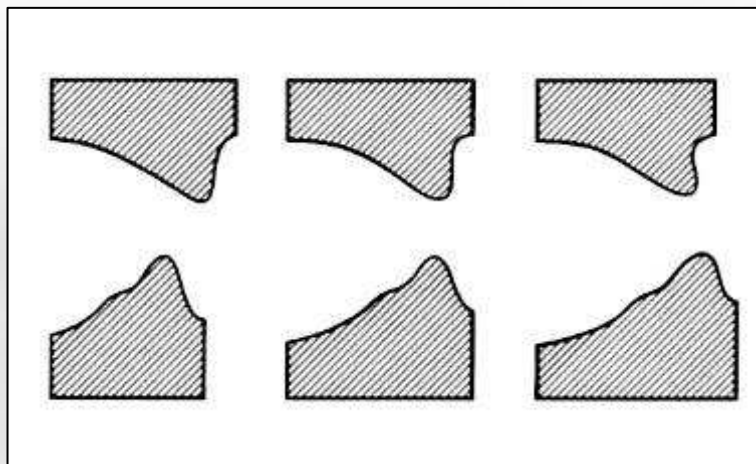
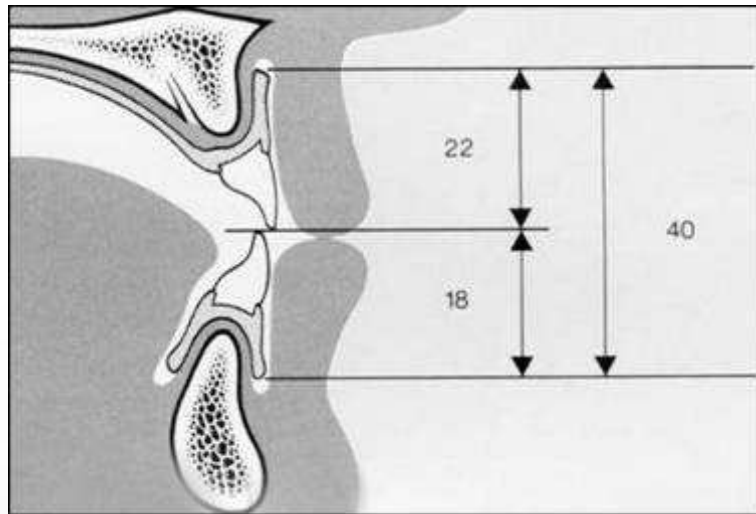
Zentrum für Zahn, Mund- und Kieferheilkunde
Poliklinik für Zahnärztliche Prothetik

TOTALPROTHETIK

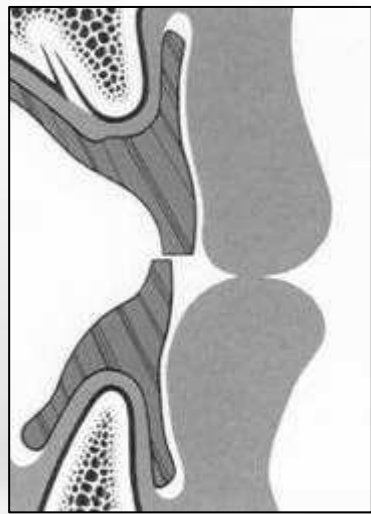
**Kieferrelationsbestimmung,
Modellmontage, Gerüstanprobe**
Prof. G. Heydecke



Herstellung der Registrierschablonen

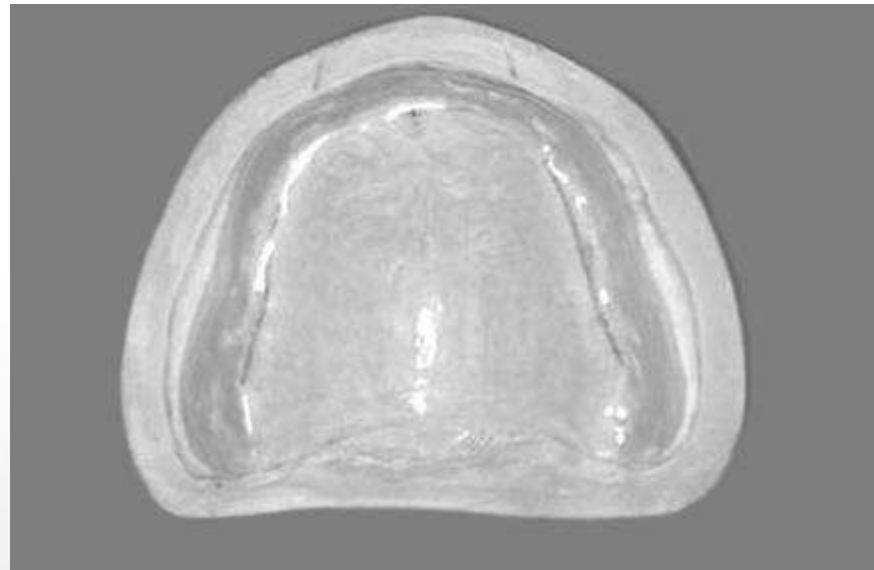
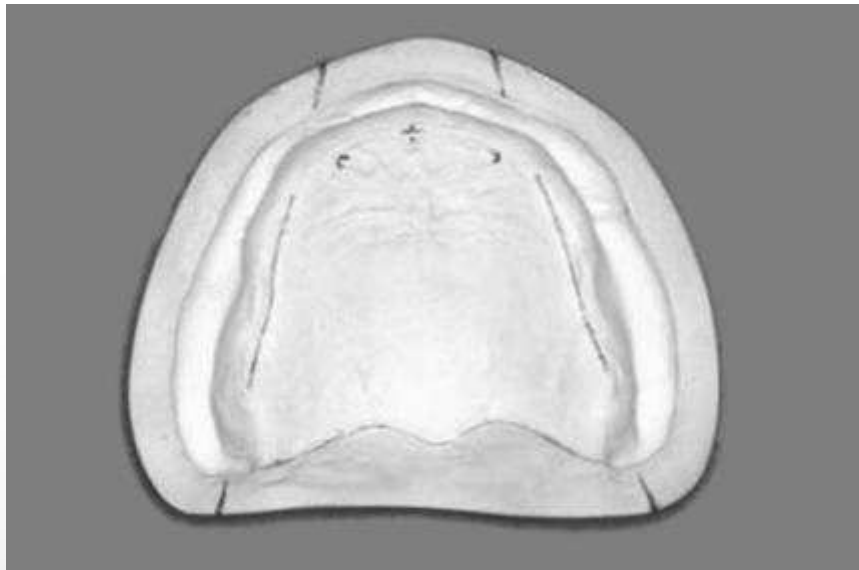

McGrane 1946

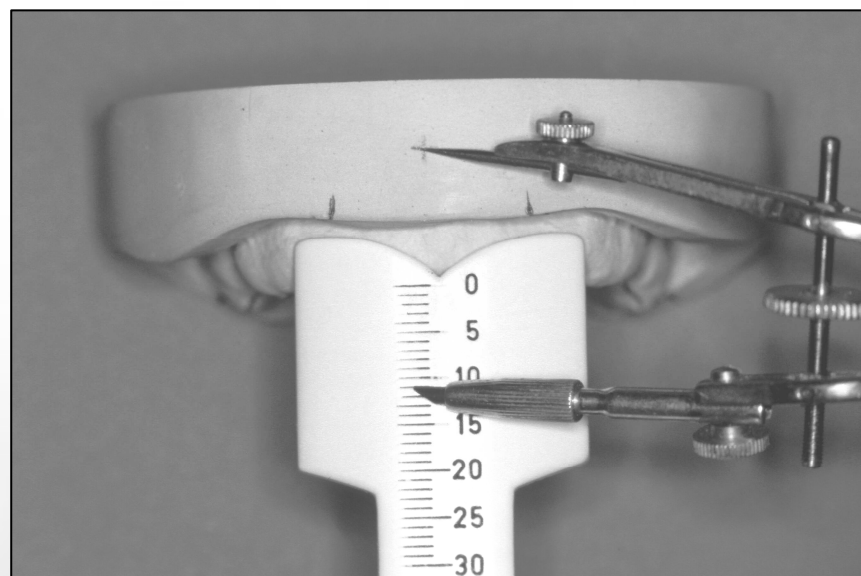
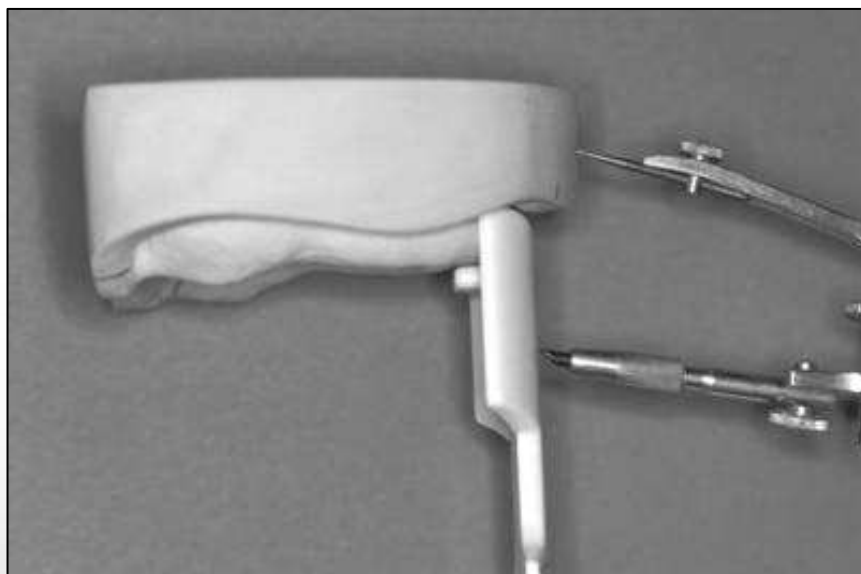




Herstellung der Registrierschablonen Oberkiefer

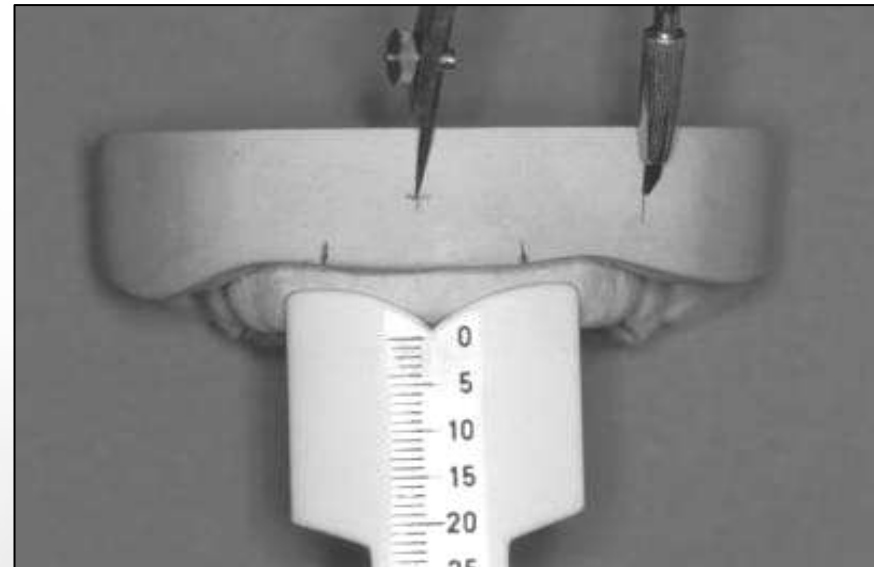
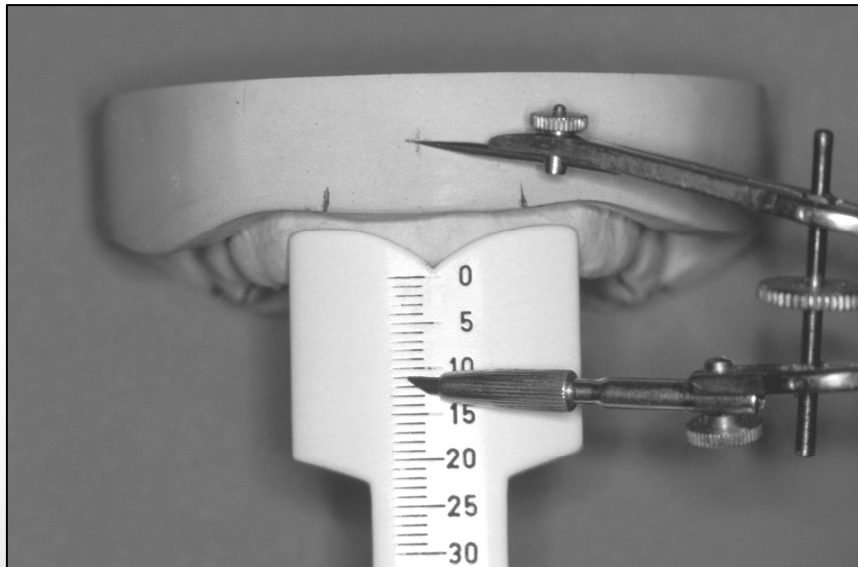


Herstellung der Registrierschablonen Oberkiefer





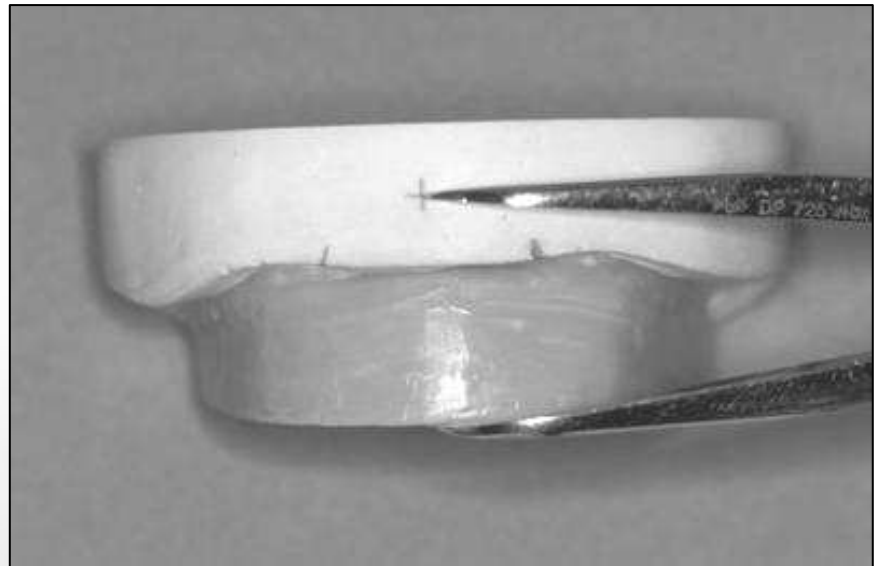

Herstellung der Registrierschablonen Oberkiefer



Intraoral gemessener Wert minus 2 mm!





Herstellung der Registrierschablonen Oberkiefer



Intraoral gemessener Wert minus 2 mm!



Herstellung der Registrierschablonen Oberkiefer

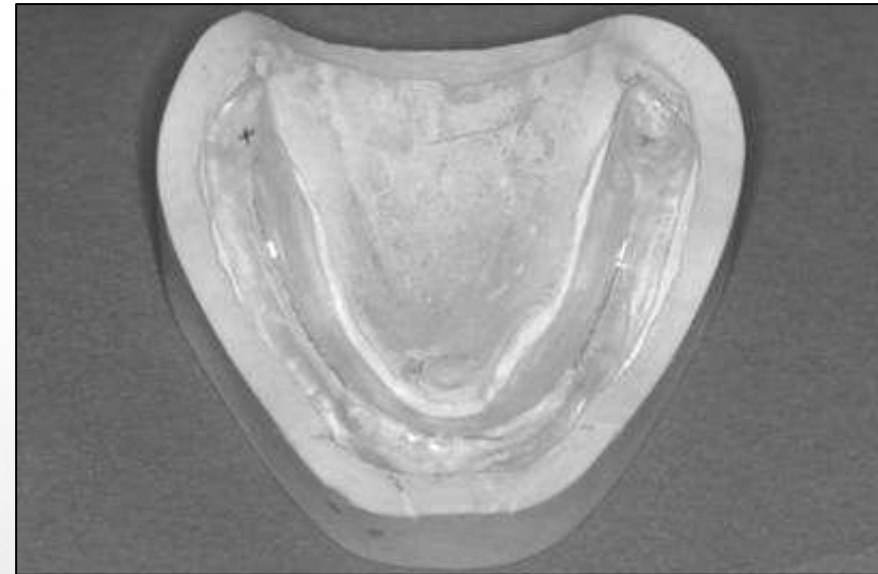
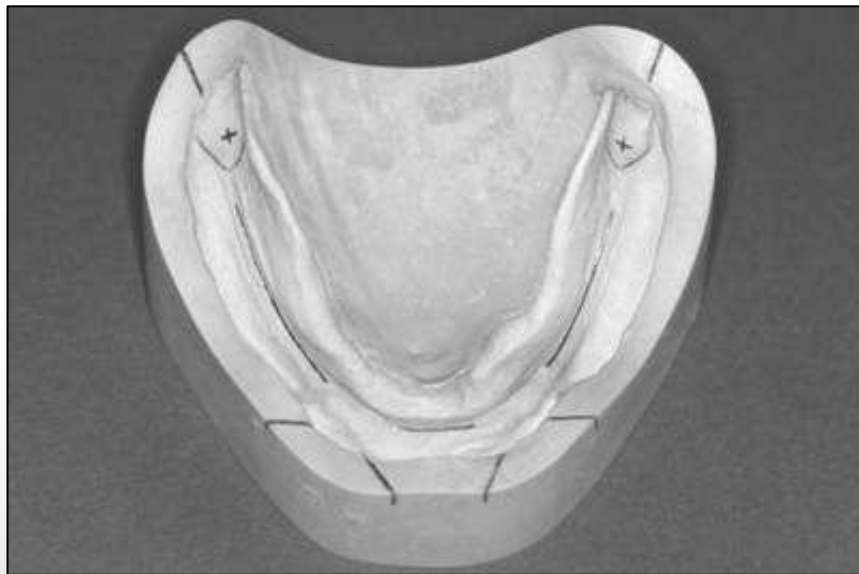
Wichtig:

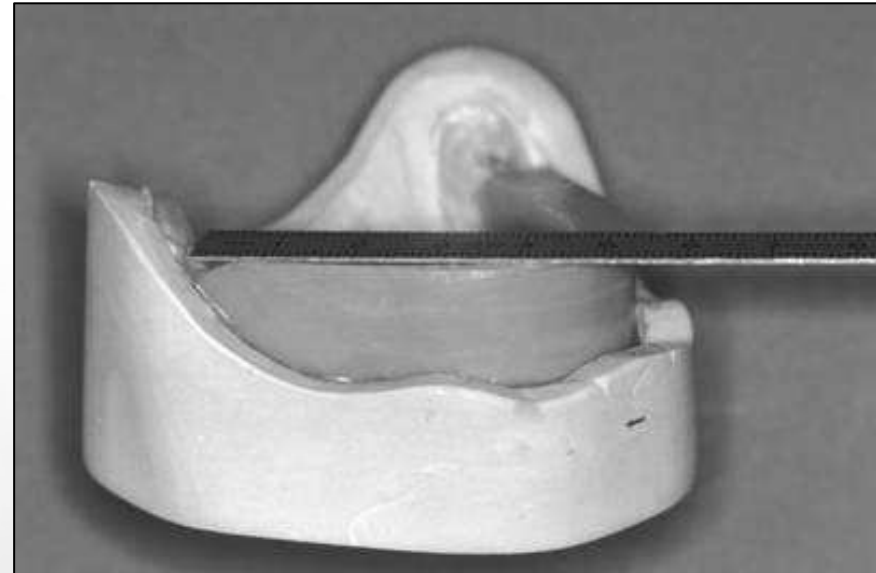
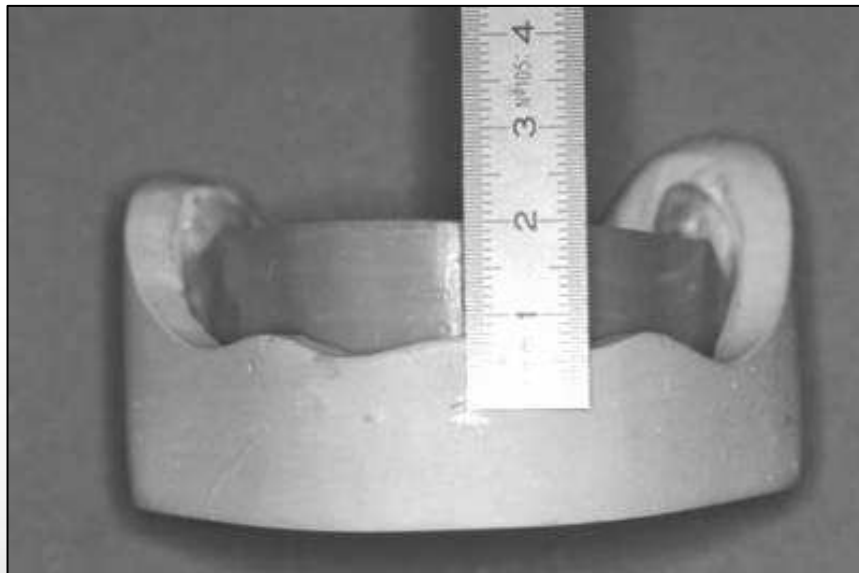
Dorsal abgeschrägten Rand des Wachswallformers hinter Tubera auf dem Modell abstützen!



Herstellung der Registrierschablonen Unterkiefer



Herstellung der Registrierschablonen Unterkiefer

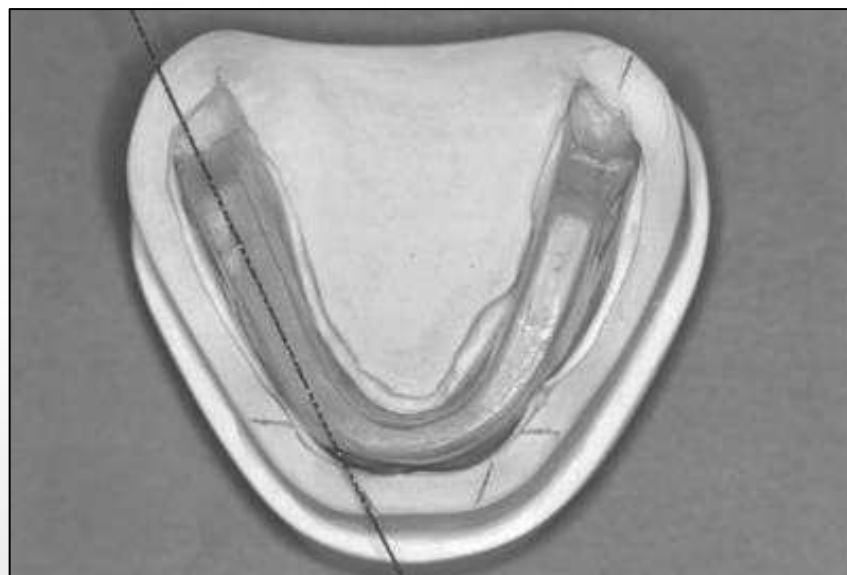
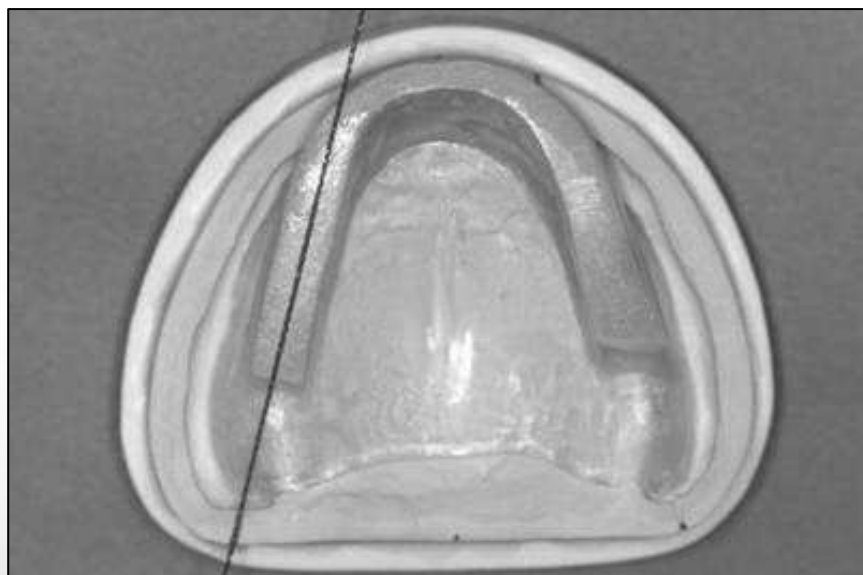


Wichtig:

Dorsal läuft Wachswall auf der Mitte des Trigonum retromolare aus!



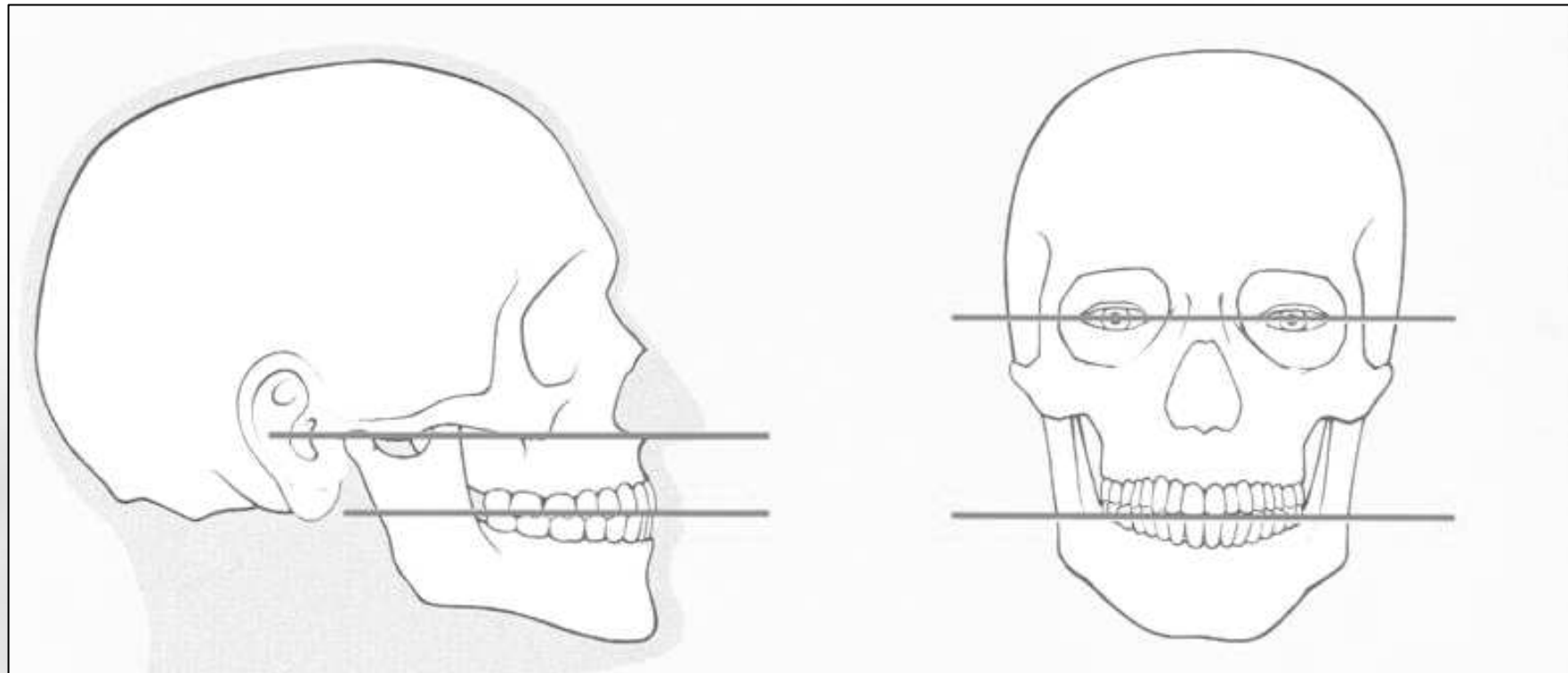
Fertiggestellte Registrierschablonen



Intraorales Ausrichten der Wachswälle

Oberkiefer

Parallel zur Bipupillarlinie und Camperschen Ebene

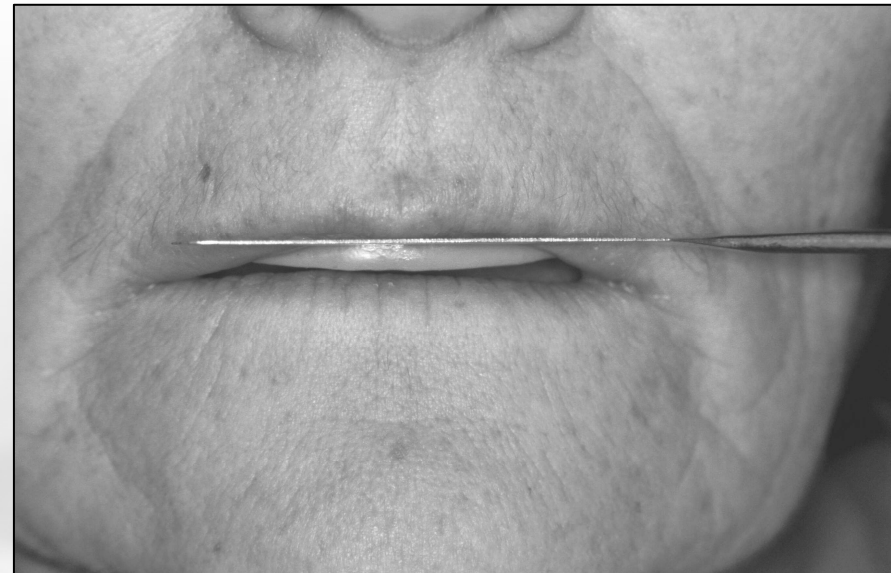




Intraorales Ausrichten der Wachswälle

Oberkiefer

- Lippenstütze und Wangenkontakt
- Länge gibt Frontzahnlänge vor
- Hilfslinien einzeichnen



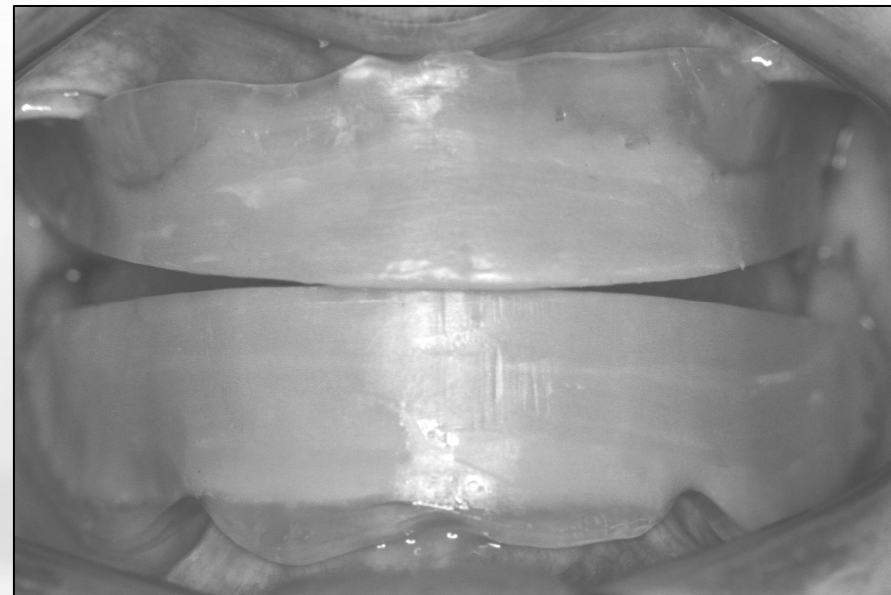
Kieferrelationsbestimmung, Modellmontage, Gerüstanprobe



Intraorales Ausrichten der Wachswälle

Unterkiefer

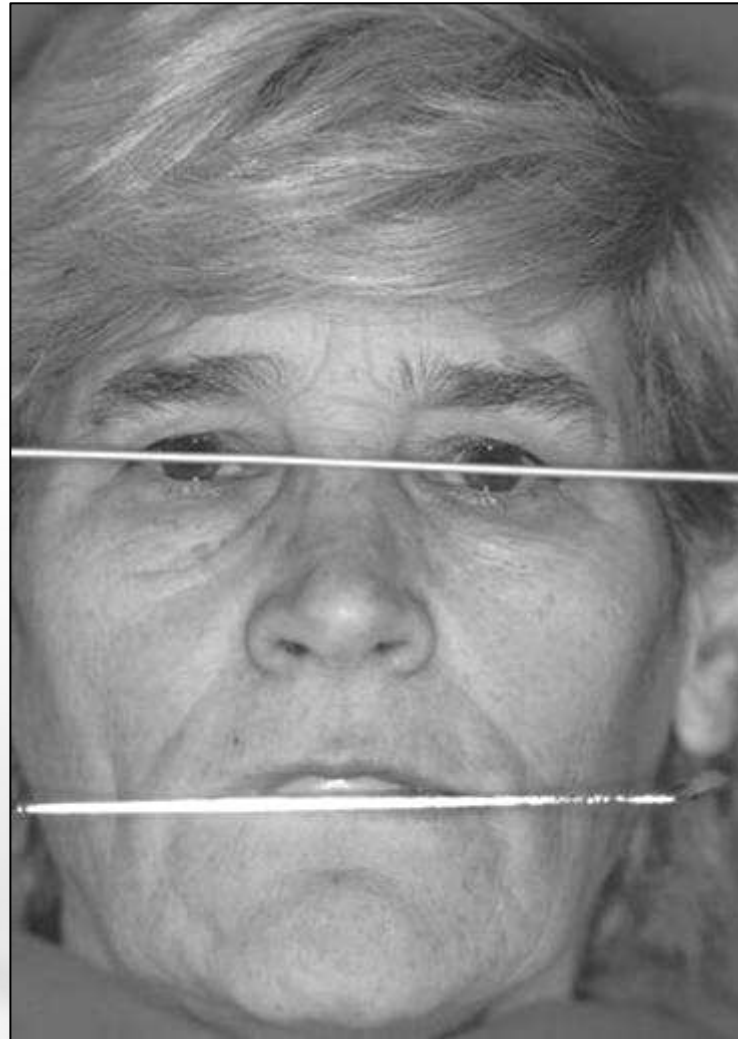
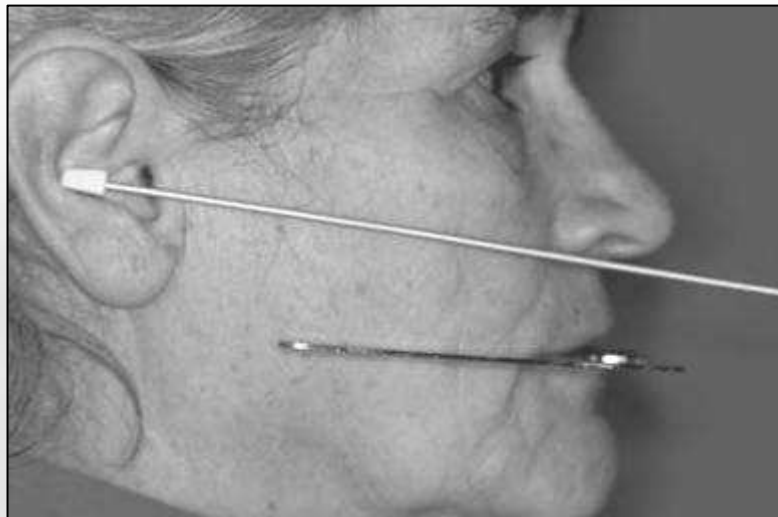
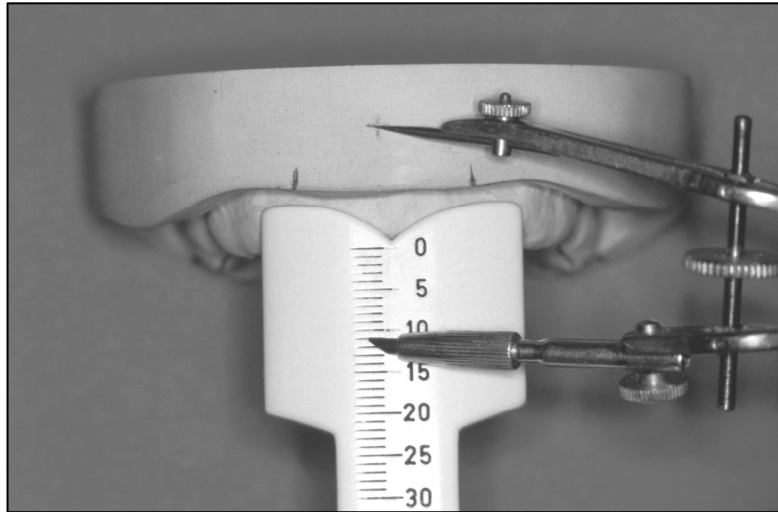
- Parallel zum oberen Wachswall
- Auf Höhe des Zungenäquators



Kieferrelationsbestimmung, Modellmontage, Gerüstanprobe

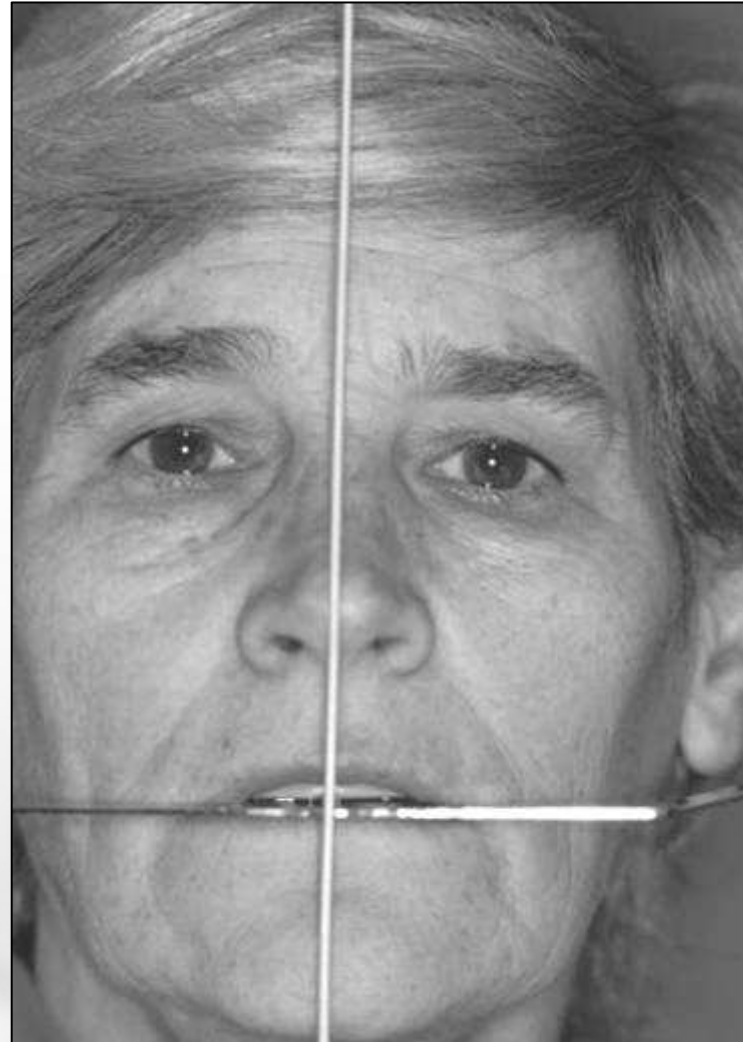
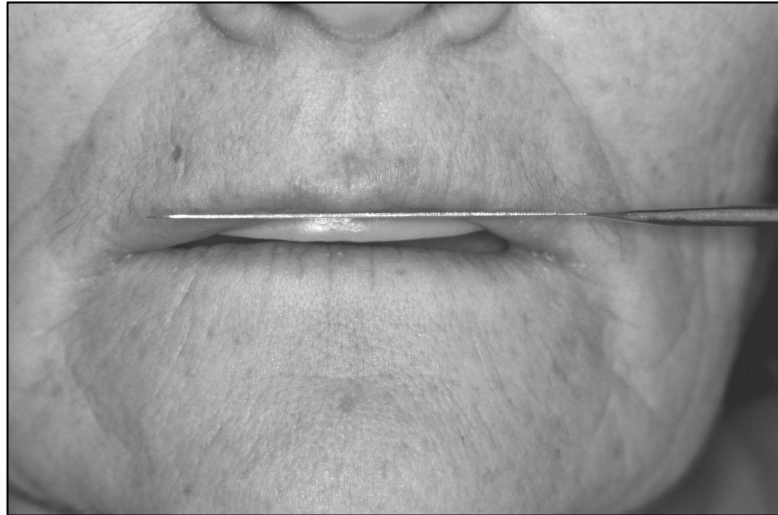


Ausrichten der Wachswälle



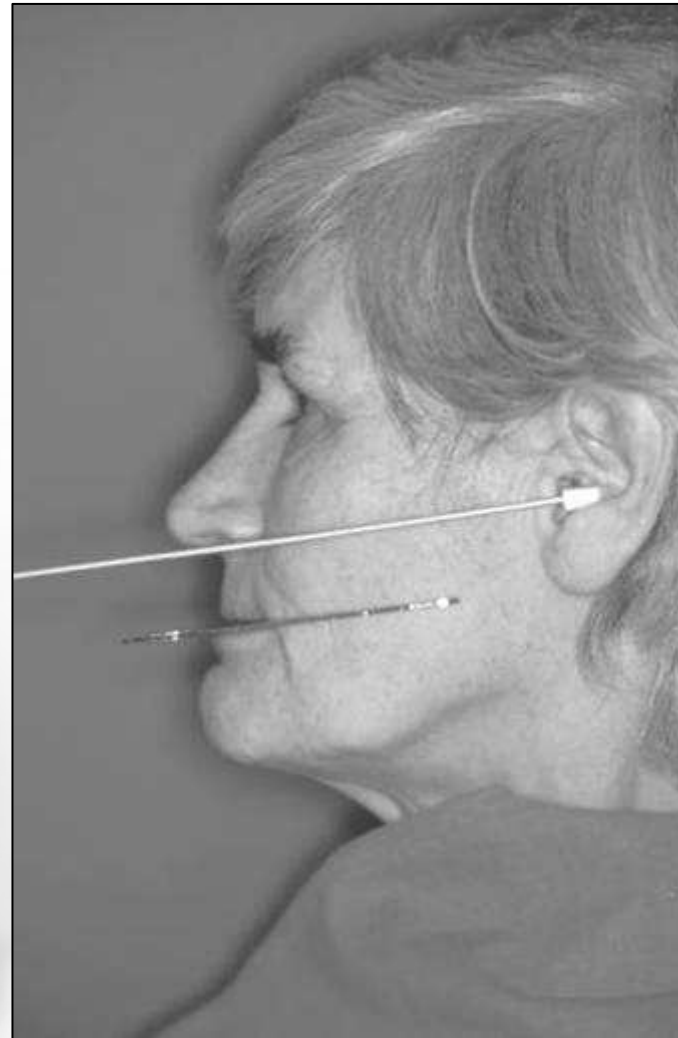
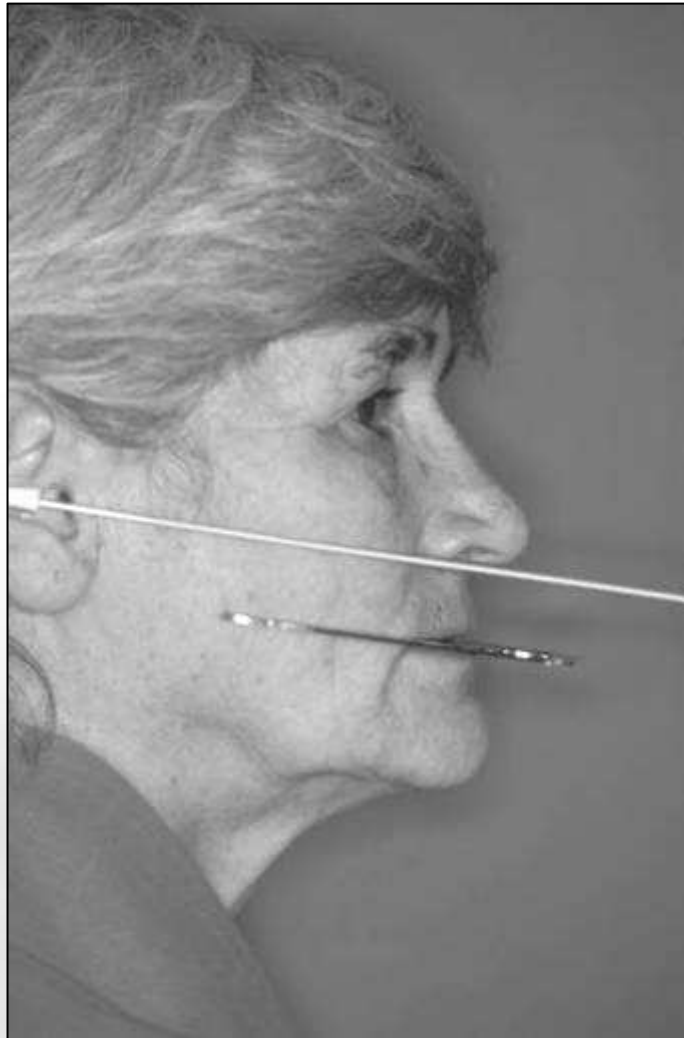


Ausrichten der Wachswälle



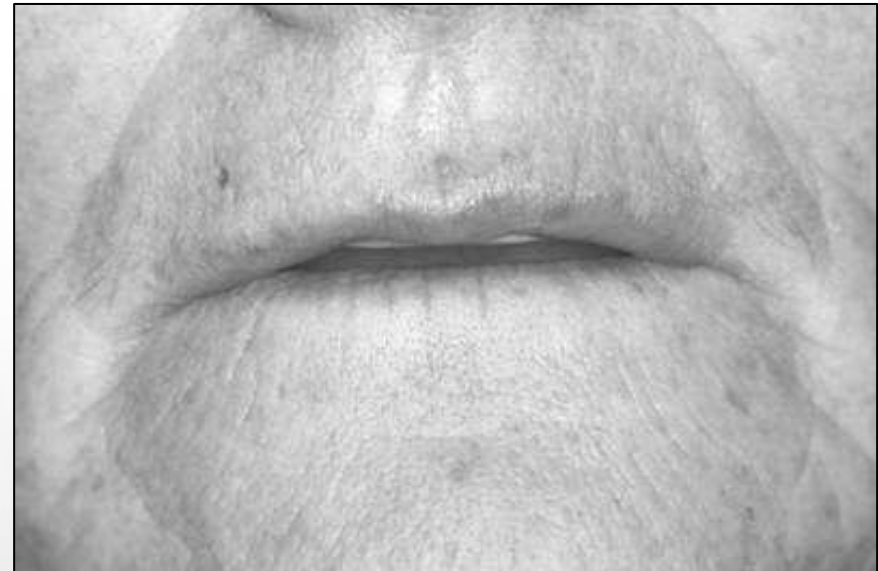
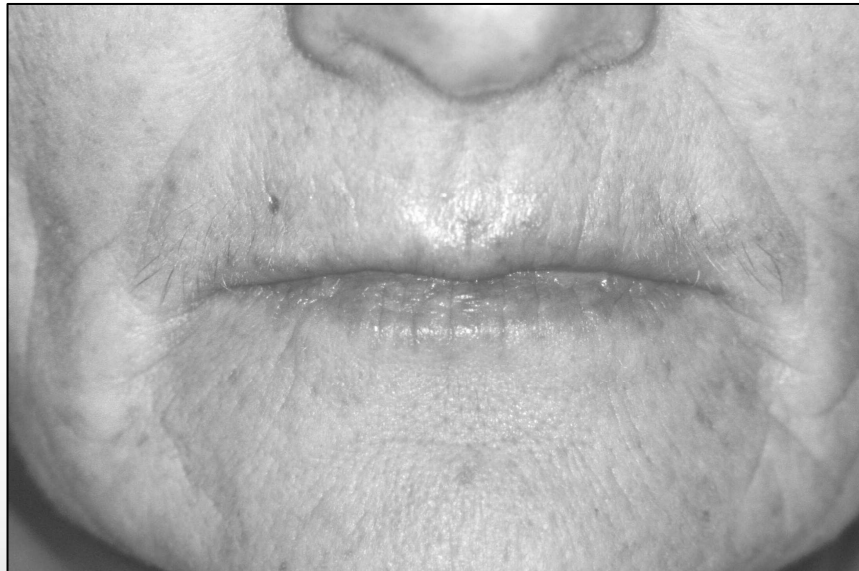
Ausrichten der Wachswälle



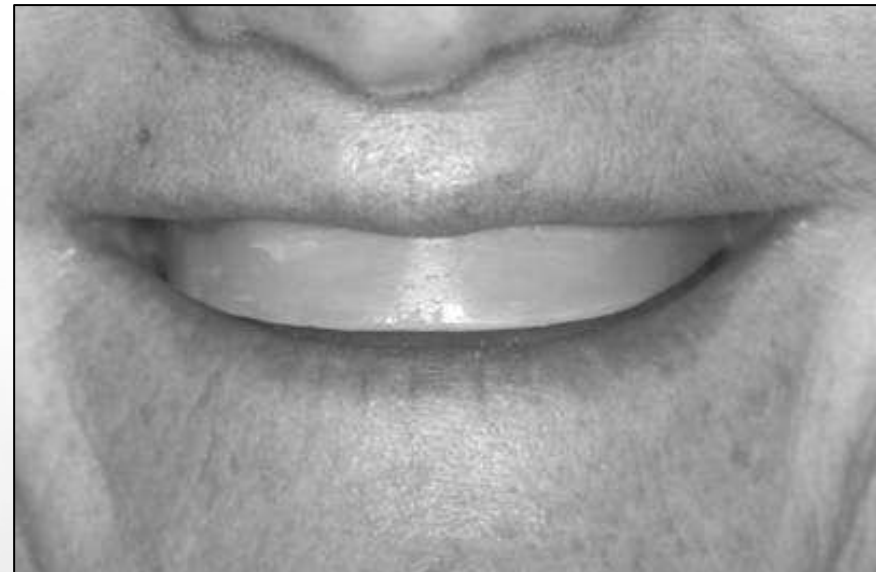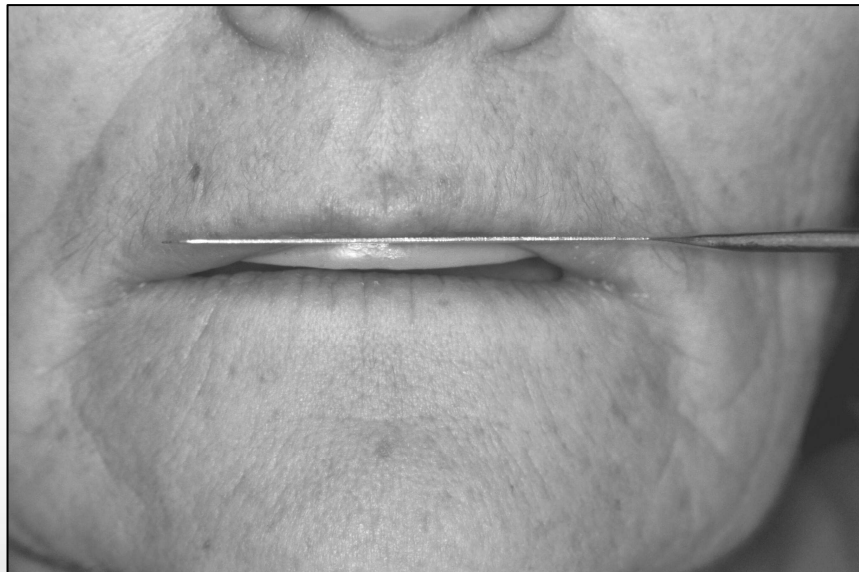


Ausrichten der Wachswälle Ästhetik





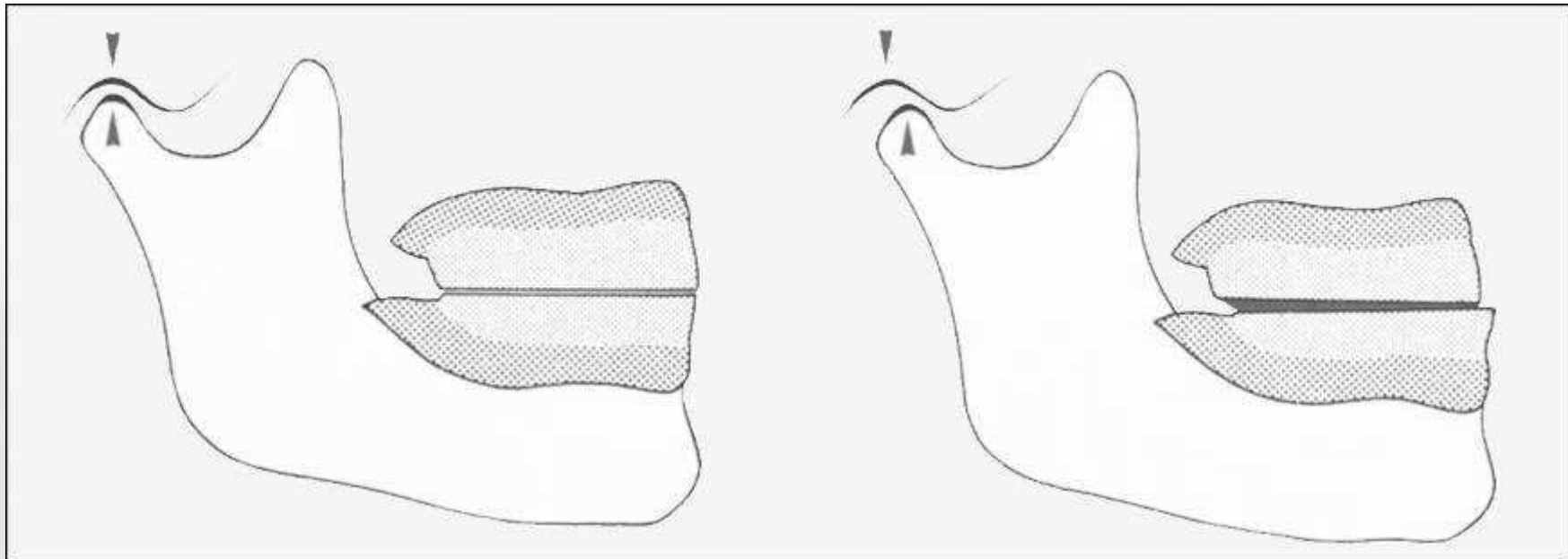
Ausrichten der Wachswälle Ästhetik



Erste Kieferrelationsbestimmung „Handbissnahme“

Provisorische (vorläufige) Registrierung

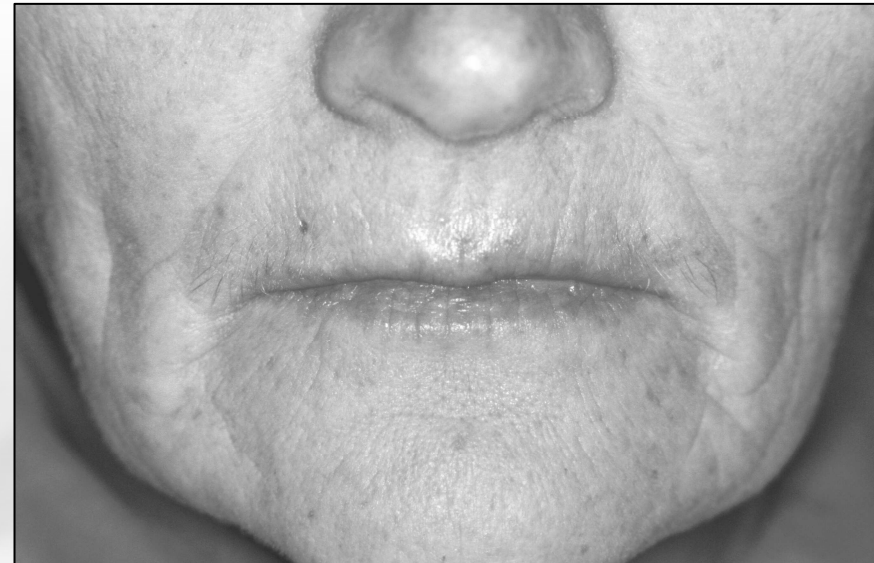- Bestimmung der vertikalen Kieferrelation
- Bestimmung der horizontalen Kieferrelation





Vertikale Kieferrelationsbestimmung


- Schluckmethode
- Phonetische Methode
 - "M" summen
 - Minimaler Sprechabstand (S- und Z-Laute)



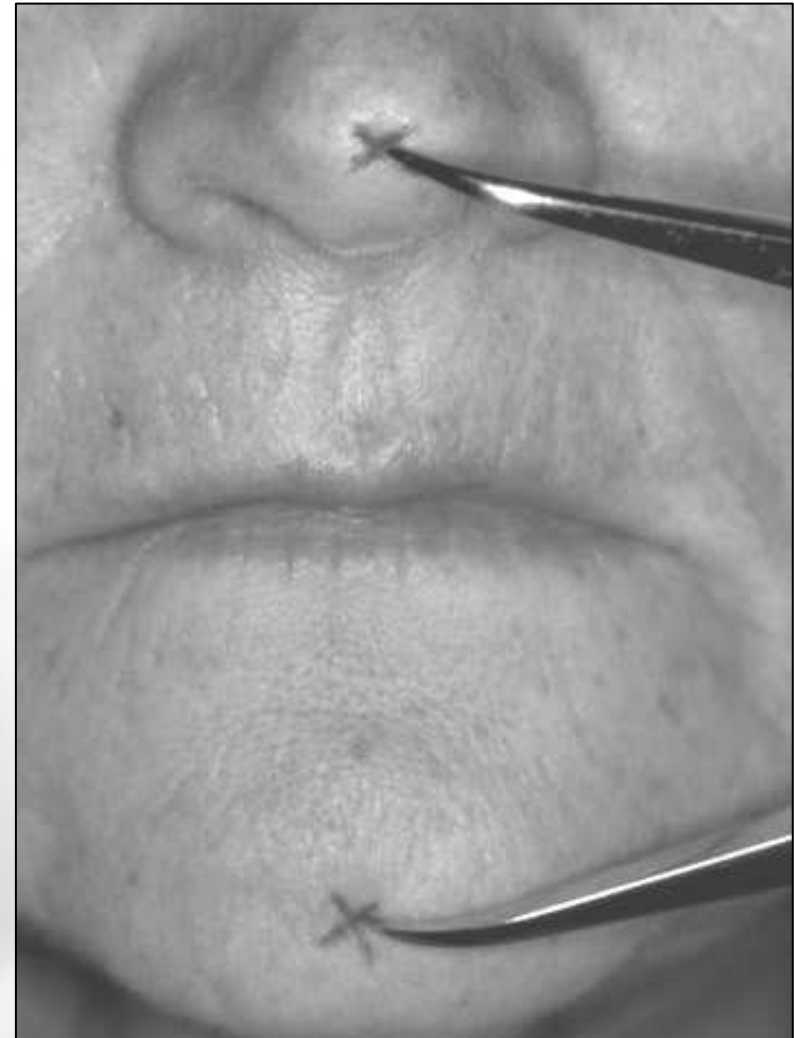Kieferrelationsbestimmung, Modellmontage, Gerüstanprobe

Vertikale Kieferrelationsbestimmung

- Gesichtsproportionen
- Entspannungsmethode
- Biofeedback
- Fernröntgenseitenbild




21



Kieferrelationsbestimmung, Modellmontage, Gerüstanprobe

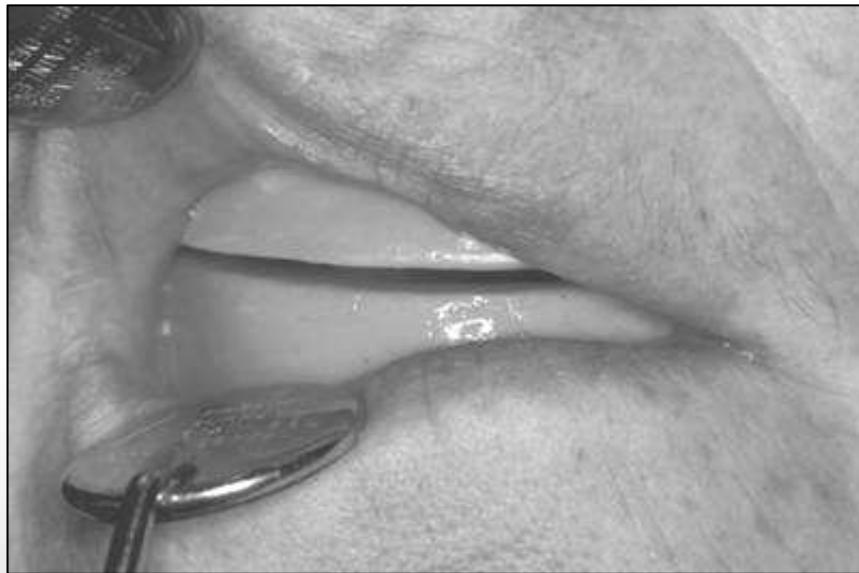


Vertikale Kieferrelationsbestimmung



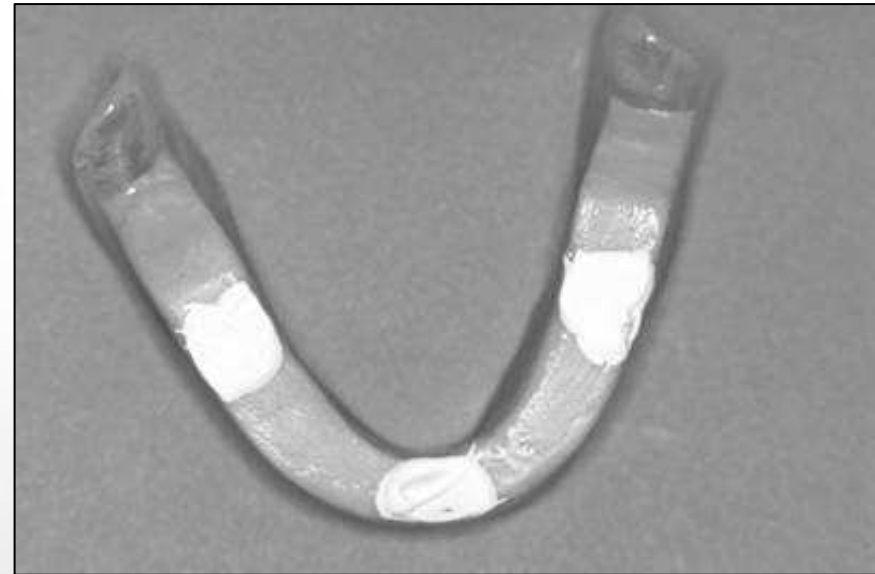
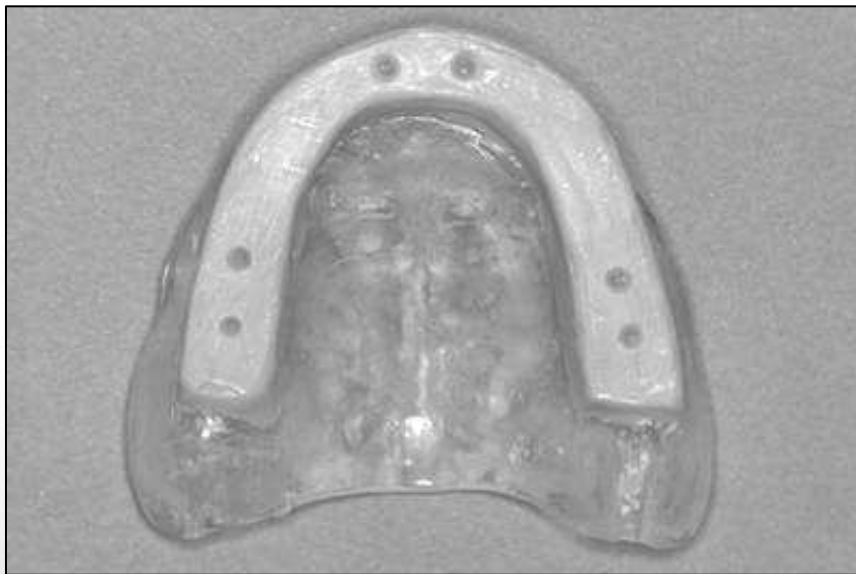

Vertikale Kieferrelationsbestimmung



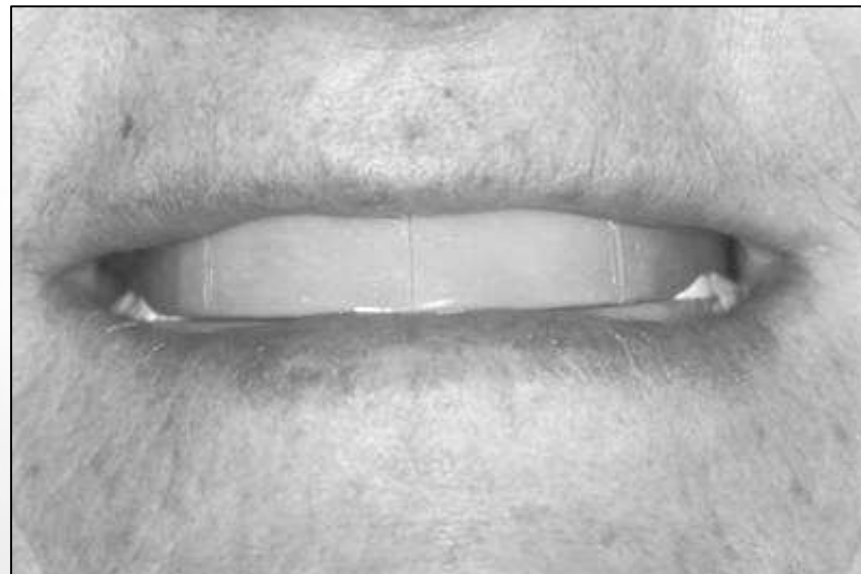
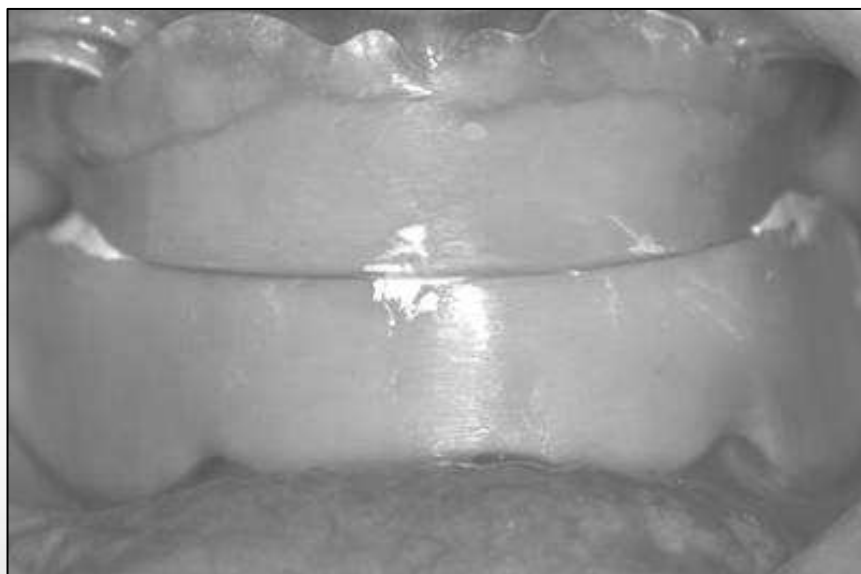


Horizontale Kieferrelationsbestimmung



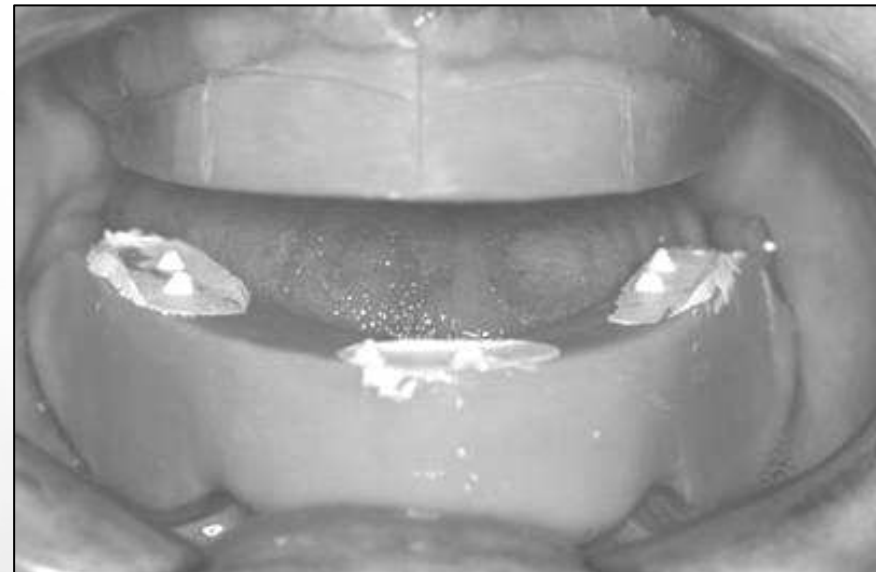



Horizontale Kieferrelationsbestimmung







Horizontale Kieferrelationsbestimmung



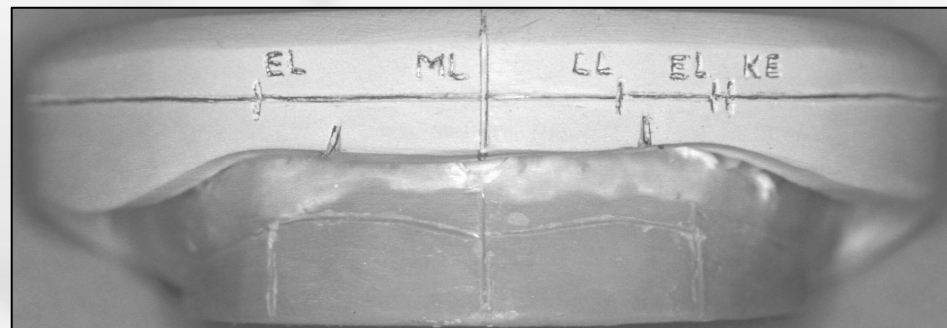
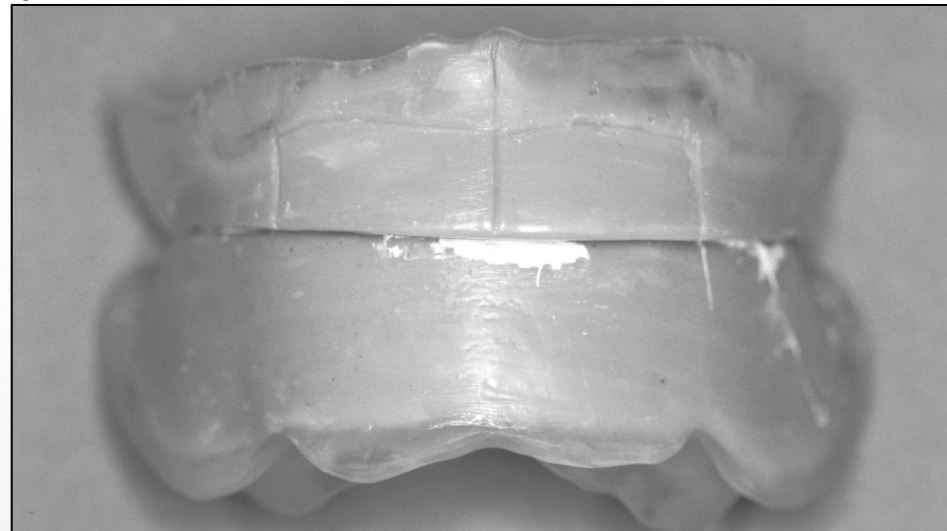


Horizontale Kieferrelationsbestimmung



Hilfslinien in den Wachswällen

- Lippenschlußlinie (LSL)
- Lachlinie (LL)
- Mittellinie (ML)
- Eckzahnlinie (EL)





Provisorische Montage der Meistermodelle






Gerber Condylator

Non-Arcon-Gerät in sagittaler Richtung

- unterer Rand des Kondylarausschnitts = Fossa
- Achse des Oberteils = Kondylus






Gerber Condylator


Arcon-Gerät in transversaler Richtung

- Achse des Oberteils = dachförmige Fossa
- Auflage am Kondylarausschnitt = Kondylus





Gerber Condylator

- Non-Arcon-Gerät in sagittaler Richtung
 - unterer Rand des Kondylarausschnitts = Fossa
 - Achse des Oberteils = Kondylus
- Arcon-Gerät in transversaler Richtung
 - Achse des Oberteils = dachförmige Fossa
 - Auflage am Kondylarausschnitt = Kondylus
- Kondylarkörper doppelt konisch geformt
 - Neigung des lateralen Konus zur Horizontalebene 12°
 - Neigung des medialen Konus 17° (Fischerwinkel)
- Frontzahnführungsteller 15°
- Retrusionsbewegung möglich



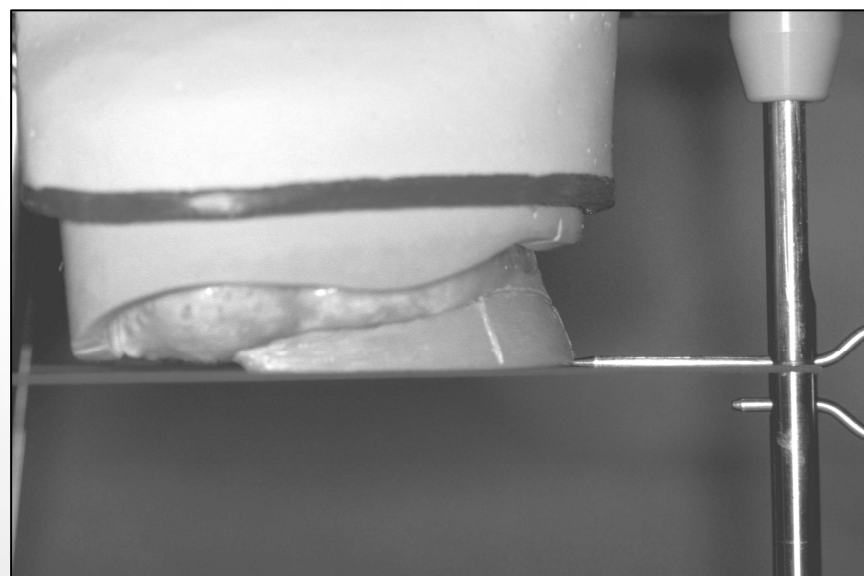
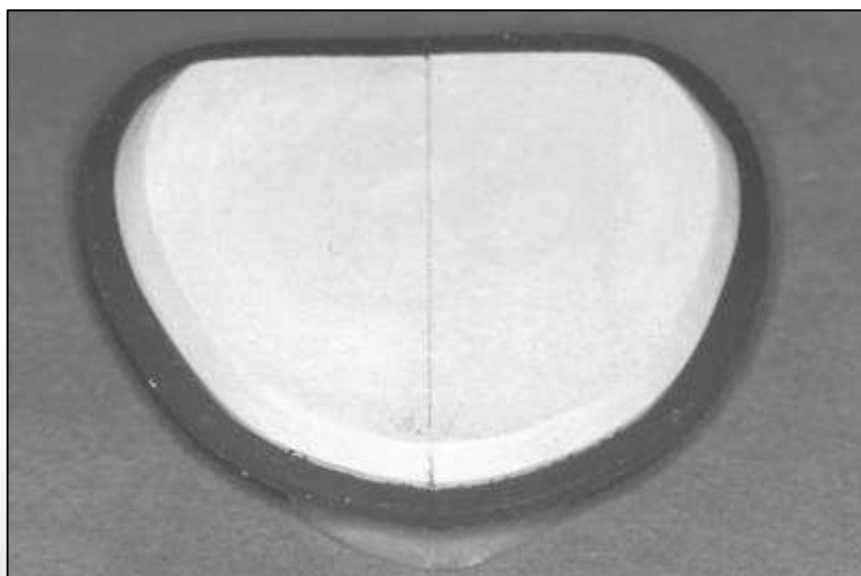


Provisorische Montage der Meistermodelle








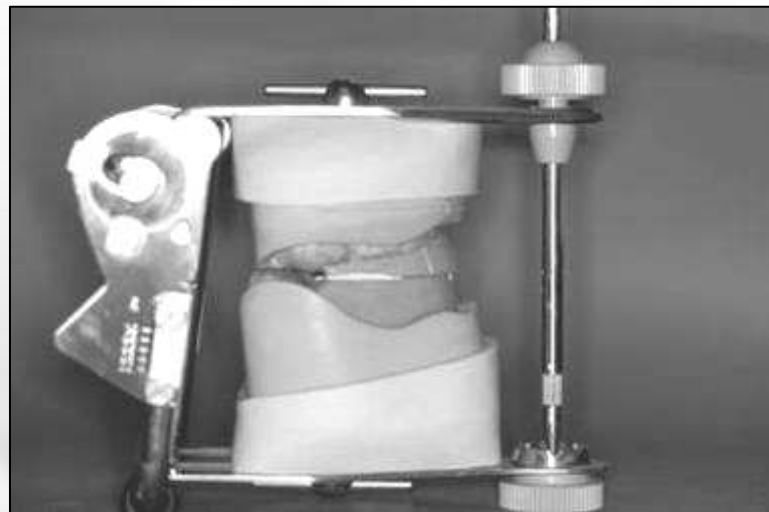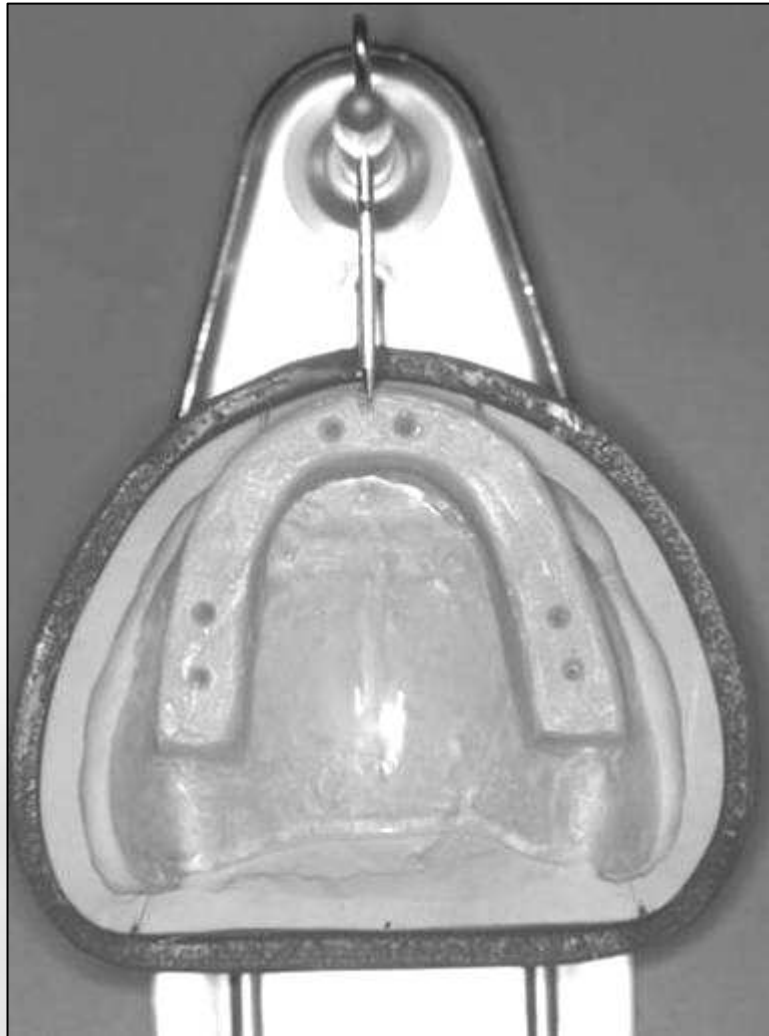

Provisorische Montage der Meistermodelle



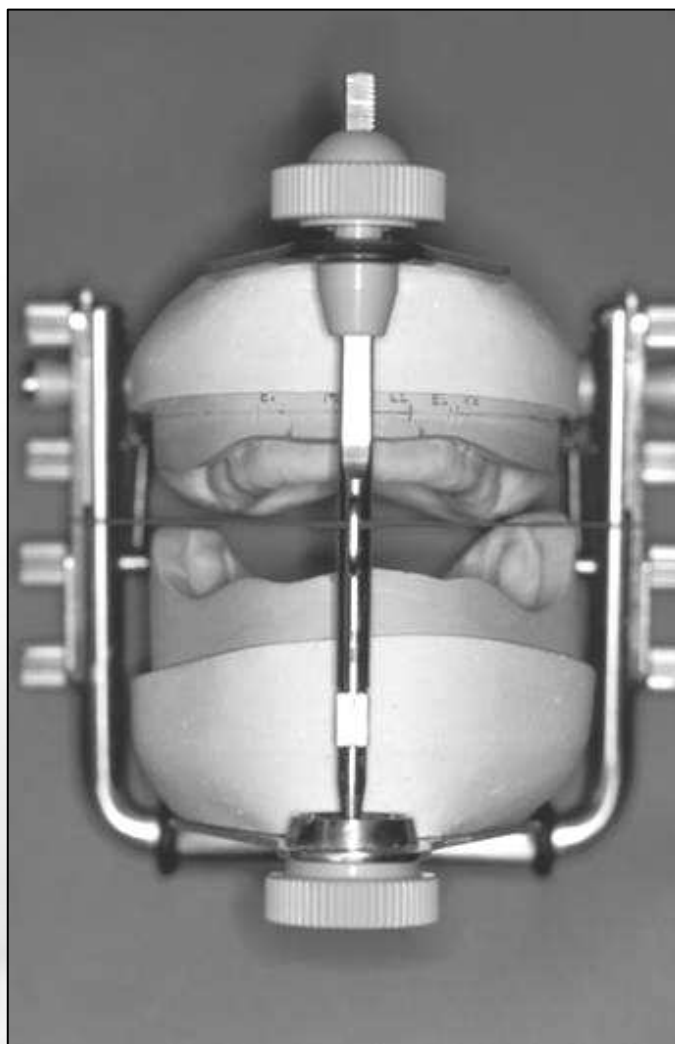

Provisorische Montage der Meistermodelle



Provisorische Montage der Meistermodelle

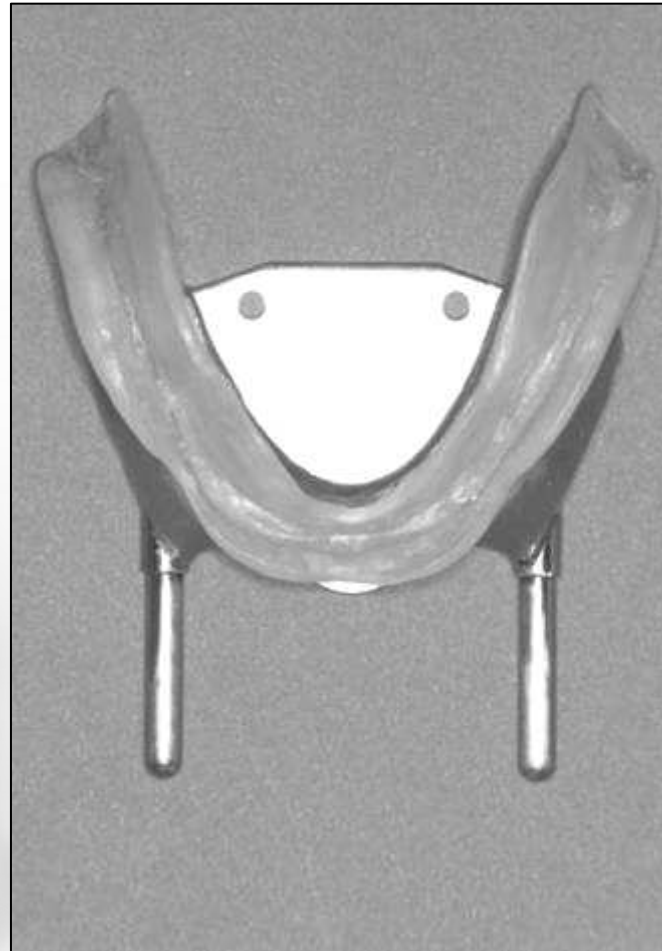
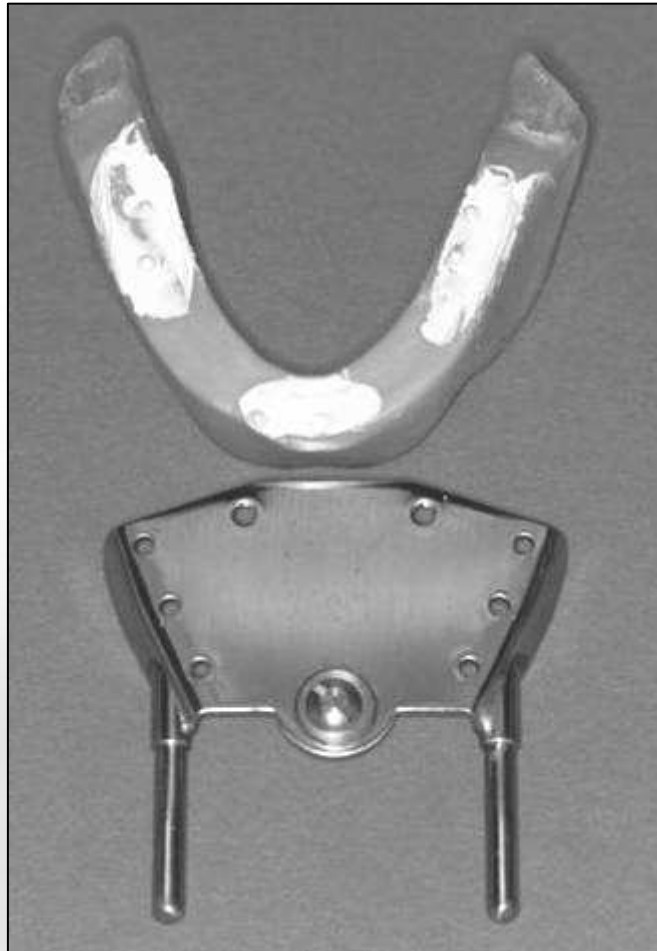


Provisorische Montage der Meistermodelle



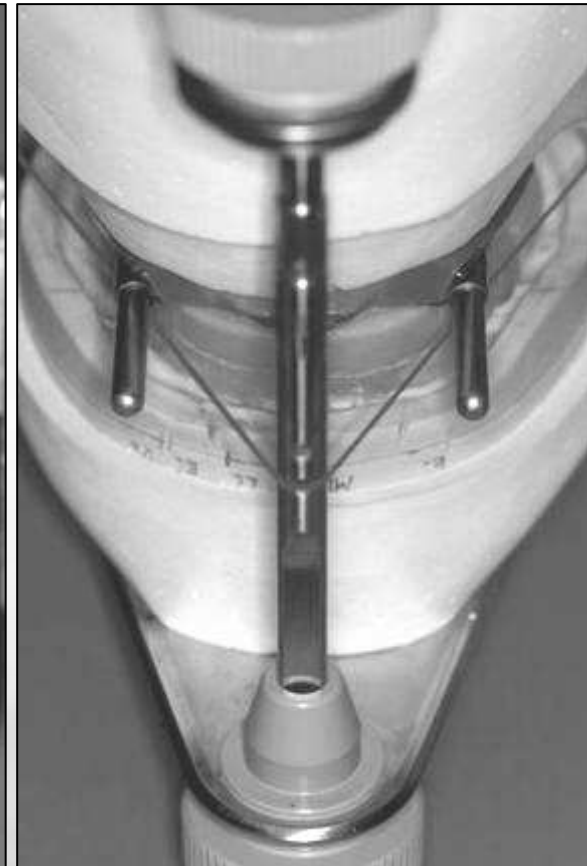
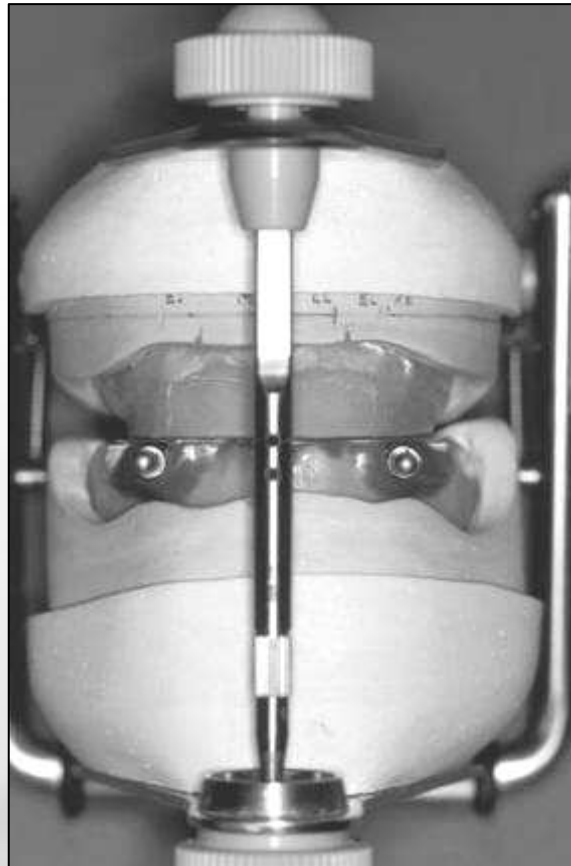



Montage der Schreibplatte mit Gesichtsbogenaufnahme



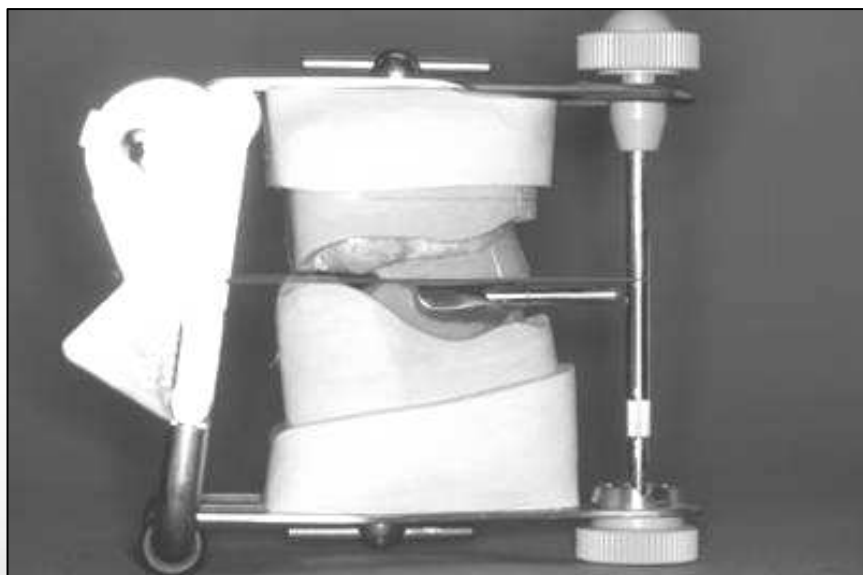

Montage der Schreibplatte mit Gesichtsbogenaufnahme



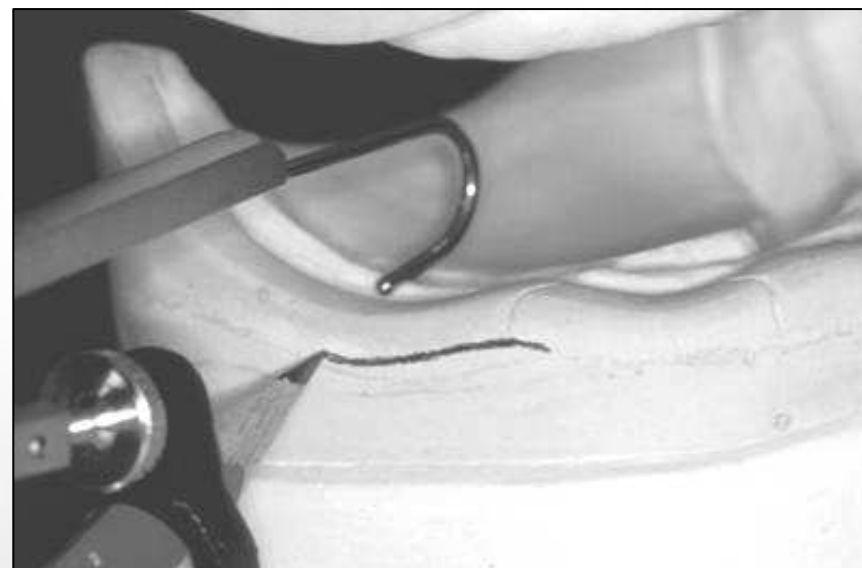


Kieferkammprofil



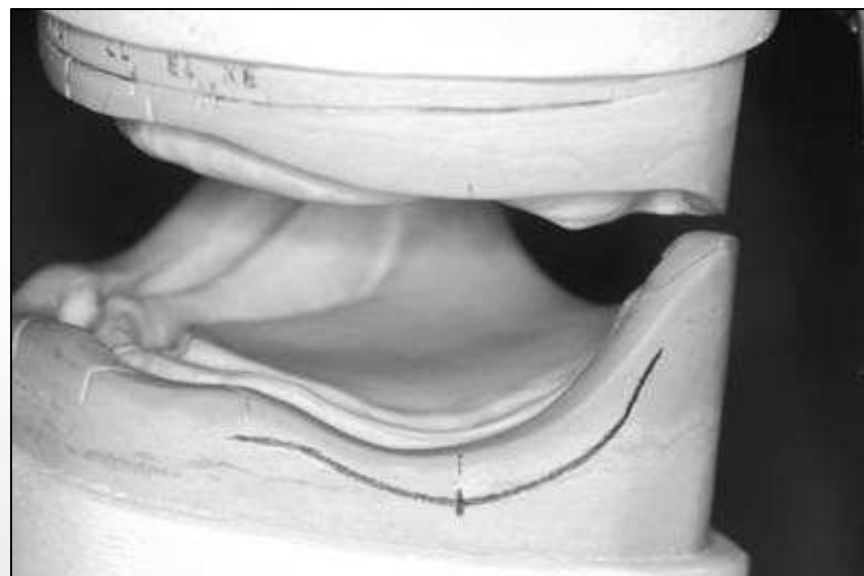
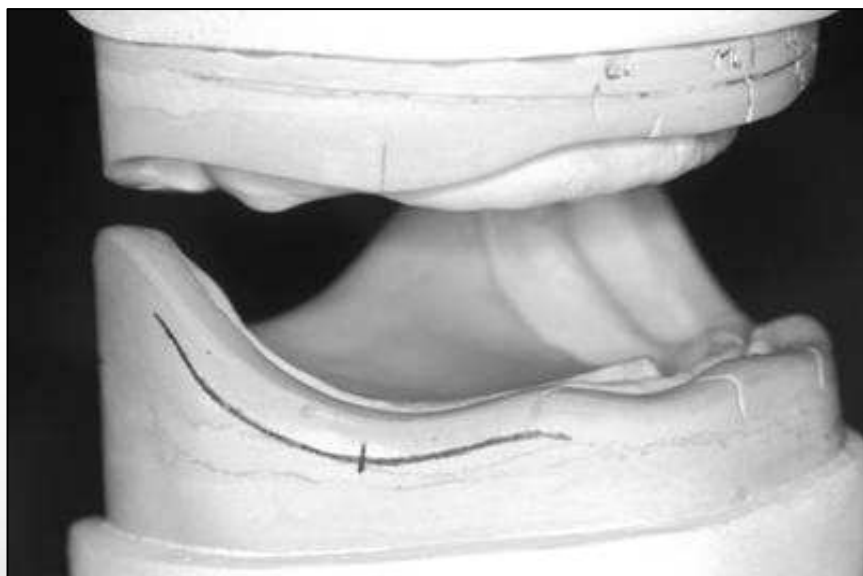


Kieferkammprofil



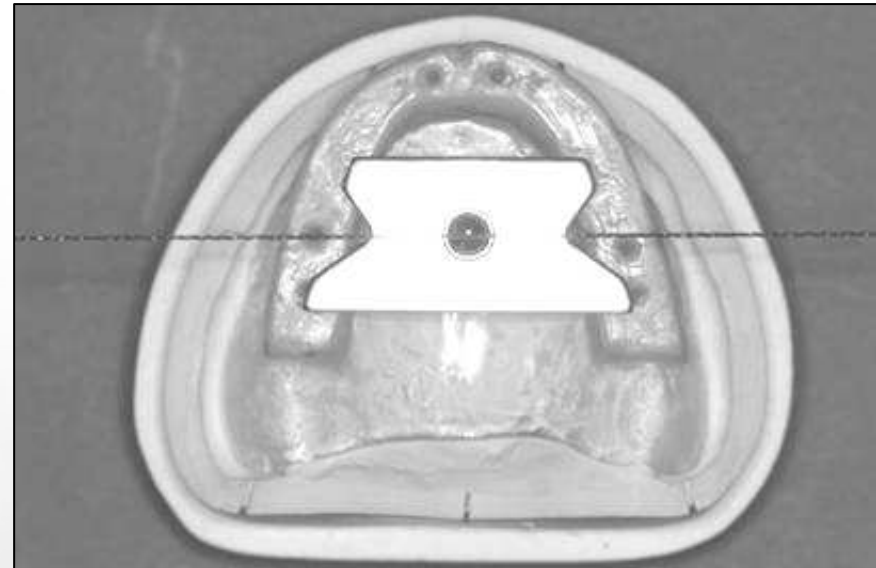
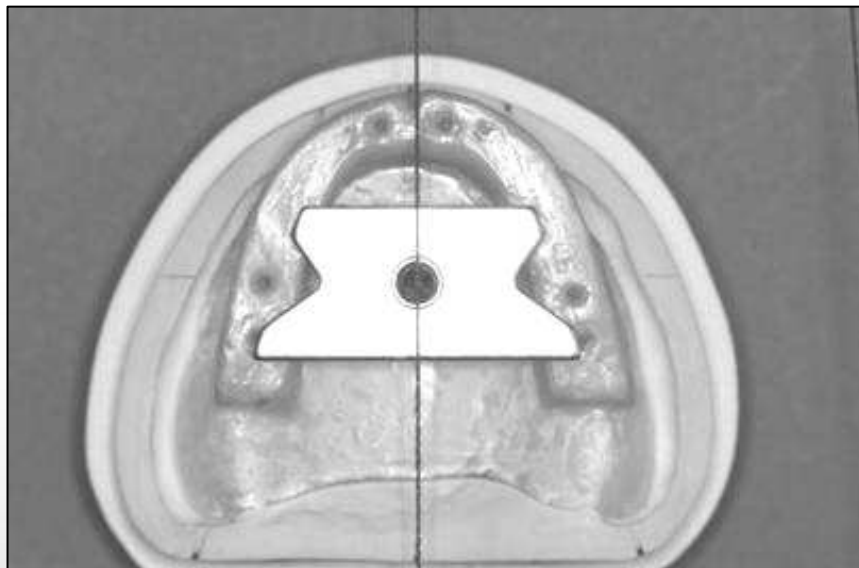


Kieferkammprofil



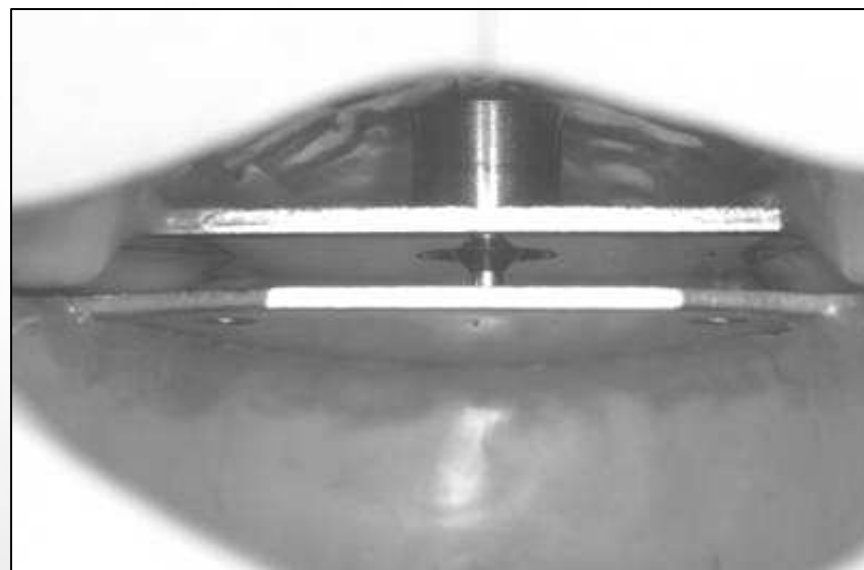



Montage des zentralen Stützstiftes



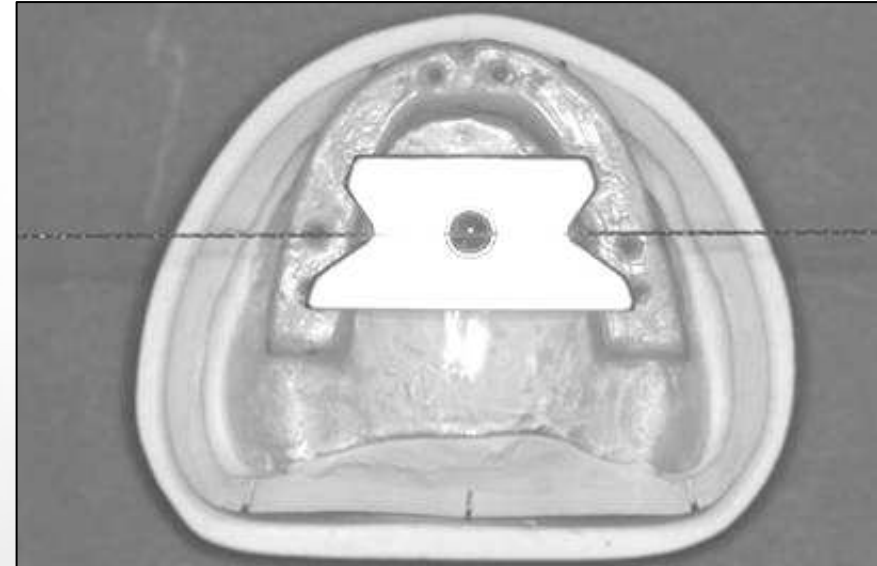
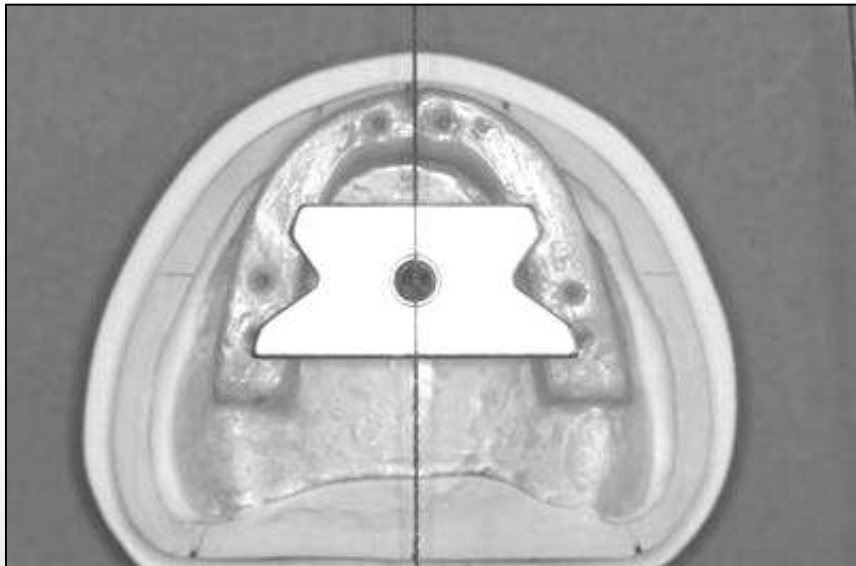


Montage des zentralen Stützstiftes



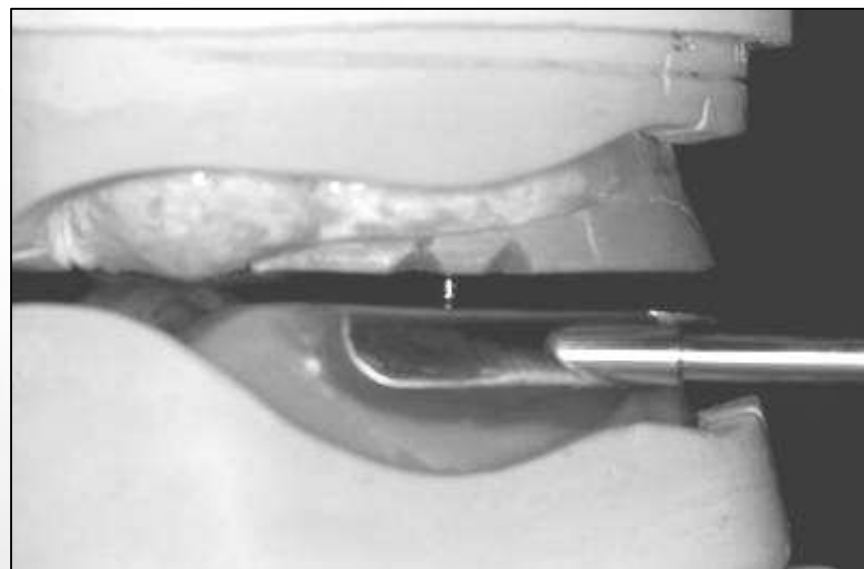
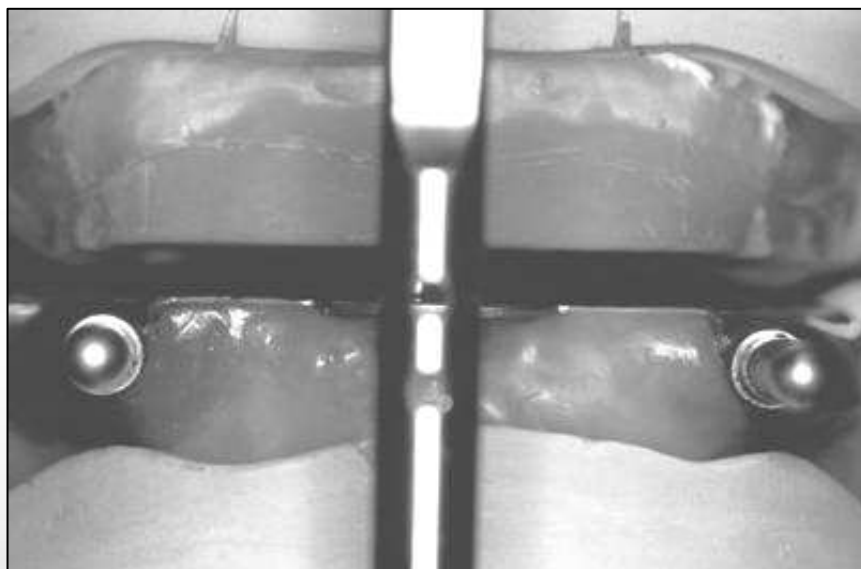


Montage des zentralen Stützstiftes



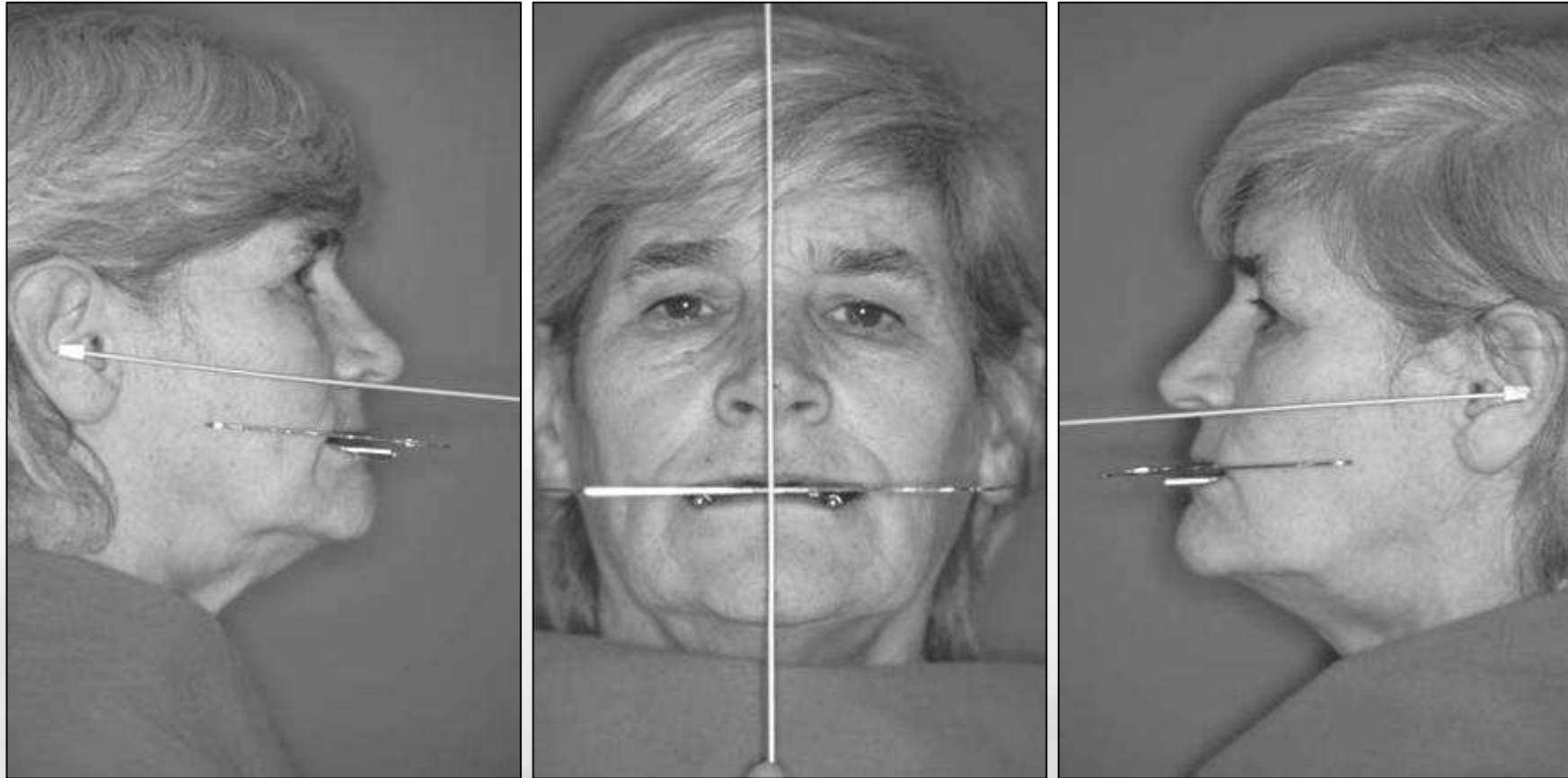


Montage des zentralen Stützstiftes



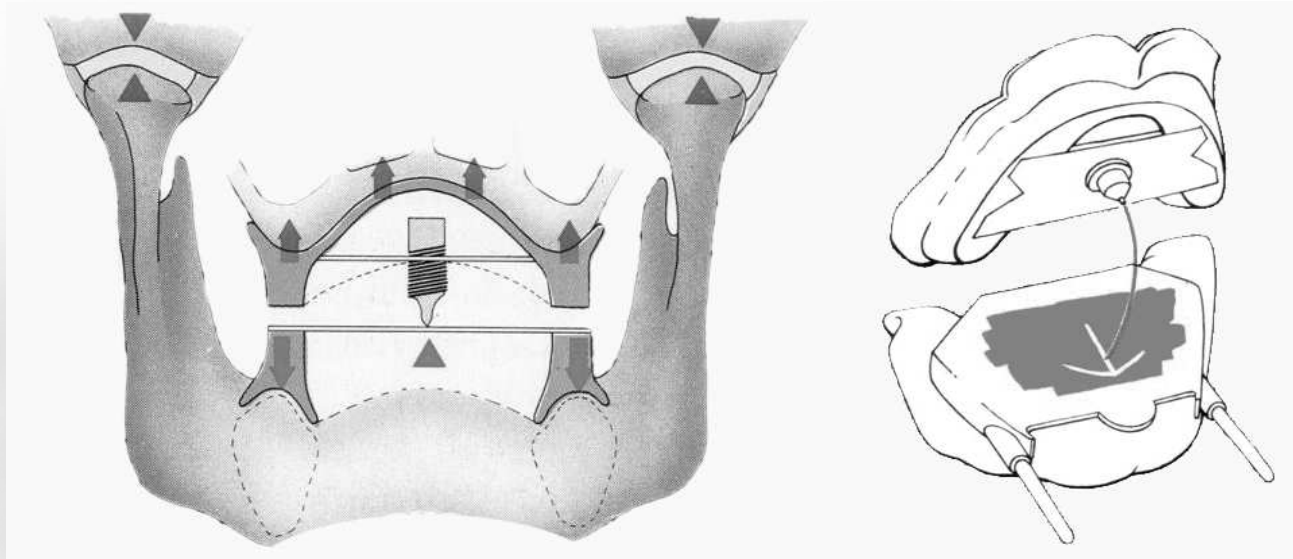


Erste Kieferrelationsbestimmung Extra- und intraorale Registrierung



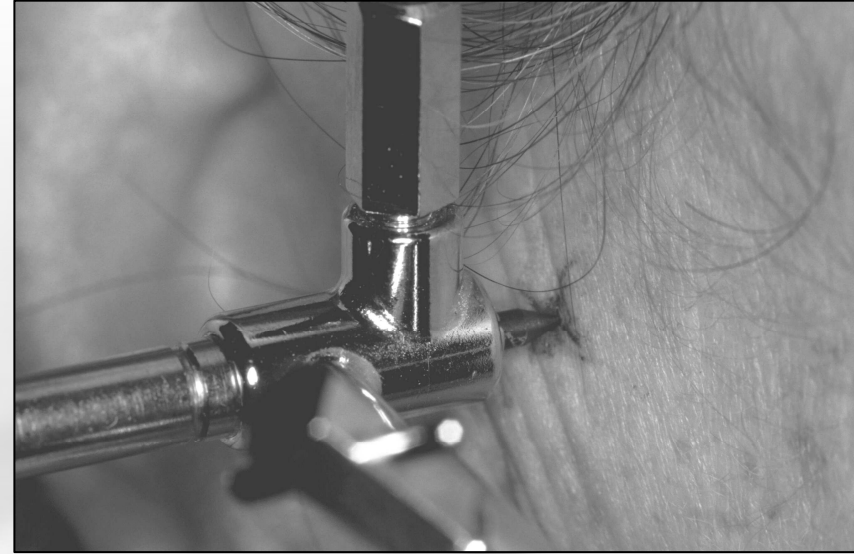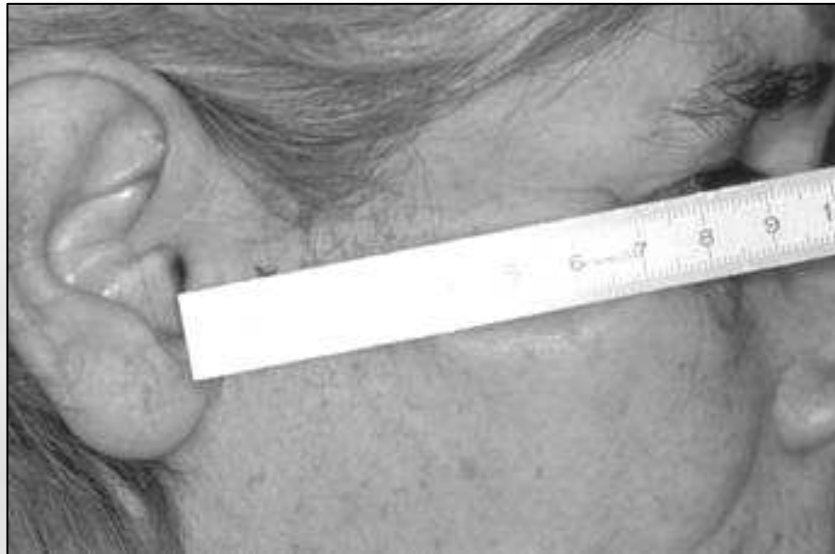Extraorale Registrierung

- Stützstift in zweiter Oberkieferbasisplatte
 - Stützstift senkrecht zur Kauebene und im Kauzentrum
- Registrierplatte in Unterkieferwachswall



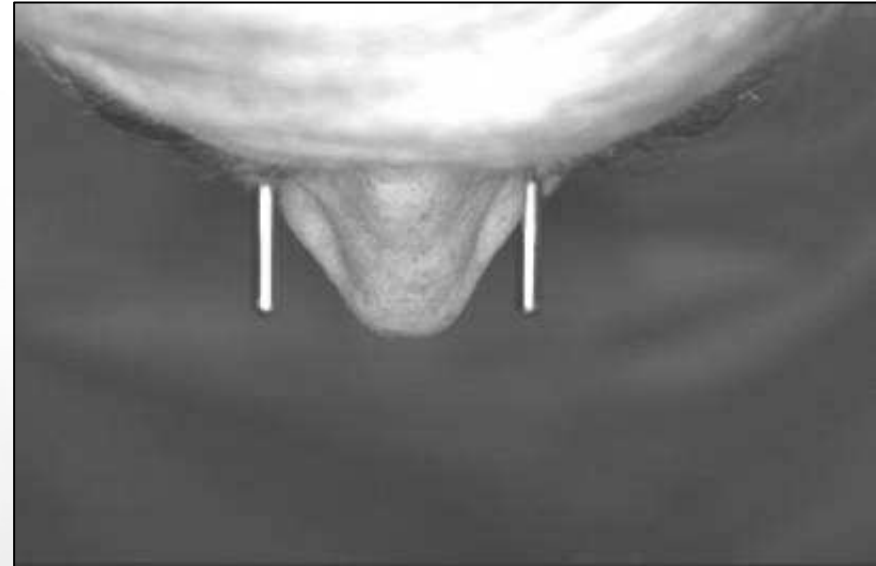

Extraorale Registrierung

- Übertragung der arbiträren Schanierachse
 - 13 mm vor Tragus auf der Tragus-Augenwinkel-Ebene
- Registrierung der sagittalen Kondylenbahnneigung bei Protrusion



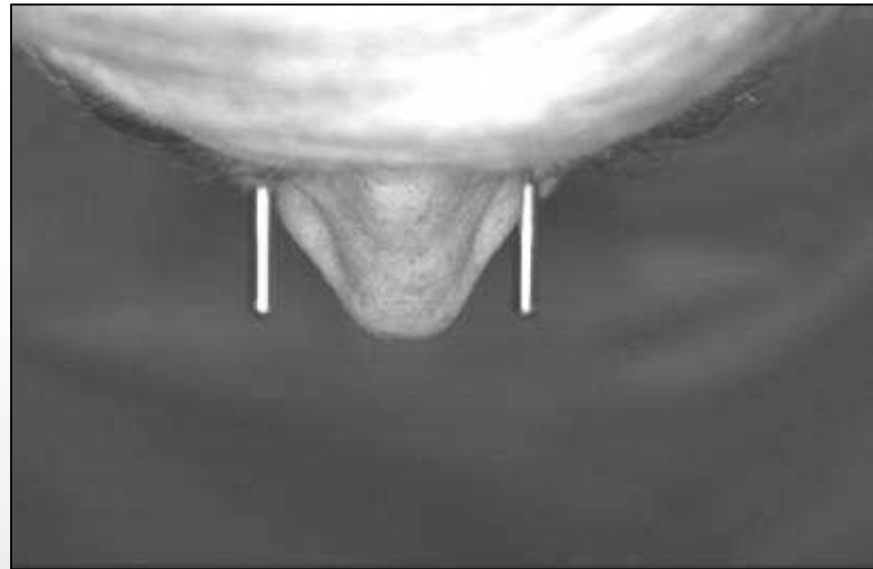
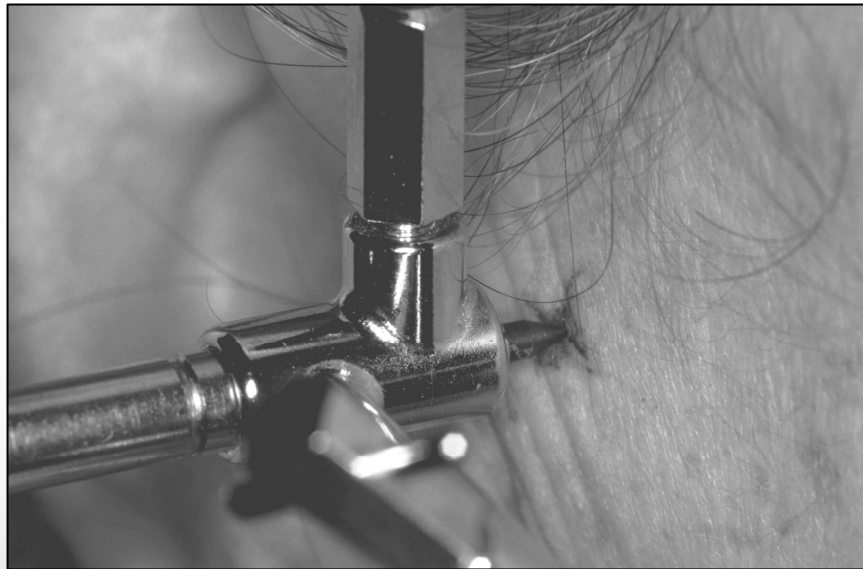


Gesichtsbogenübertragung



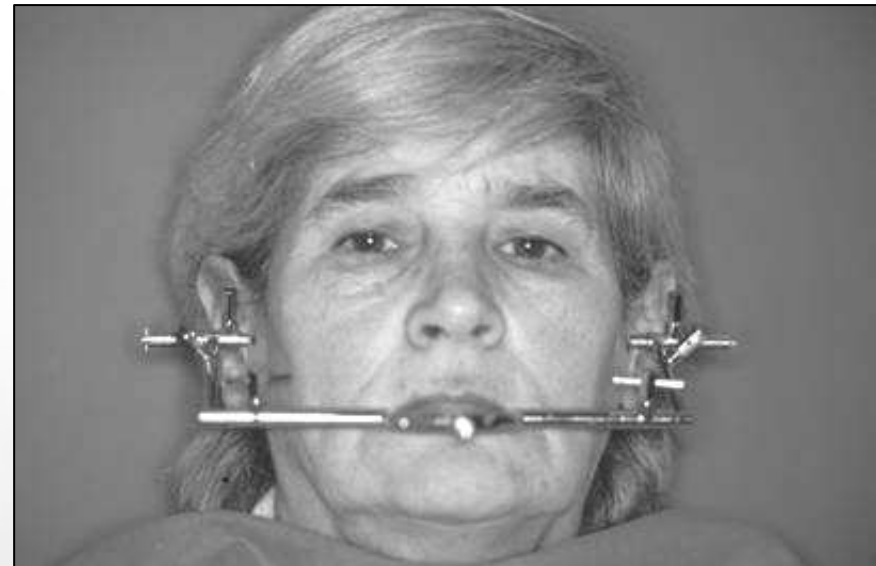
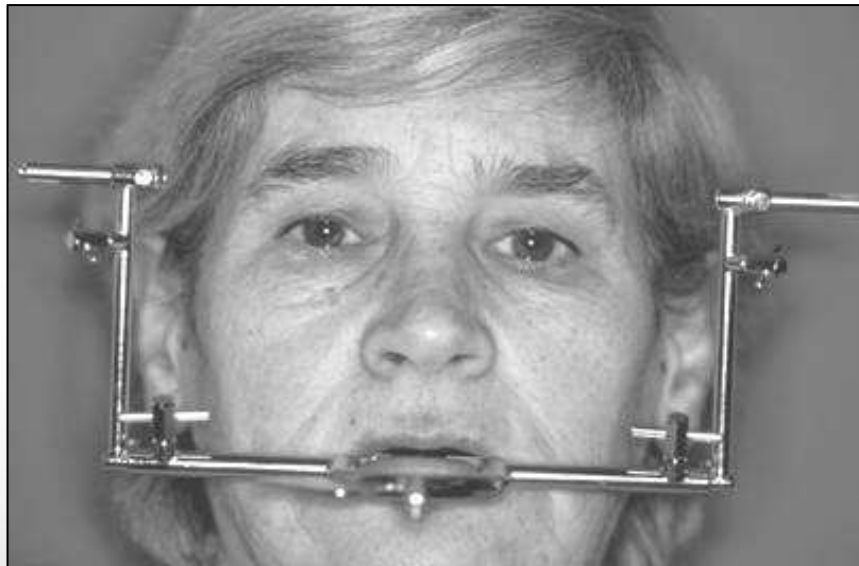
Gesichtsbogenübertragung



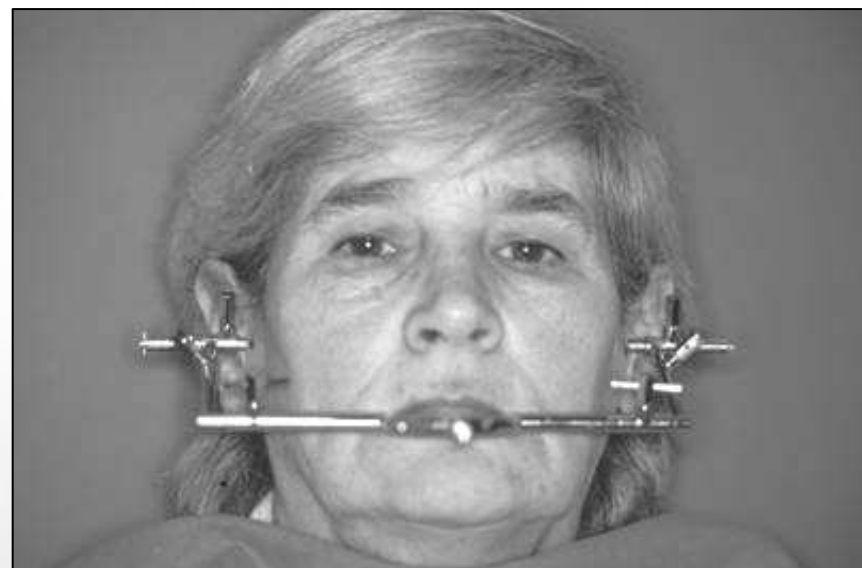
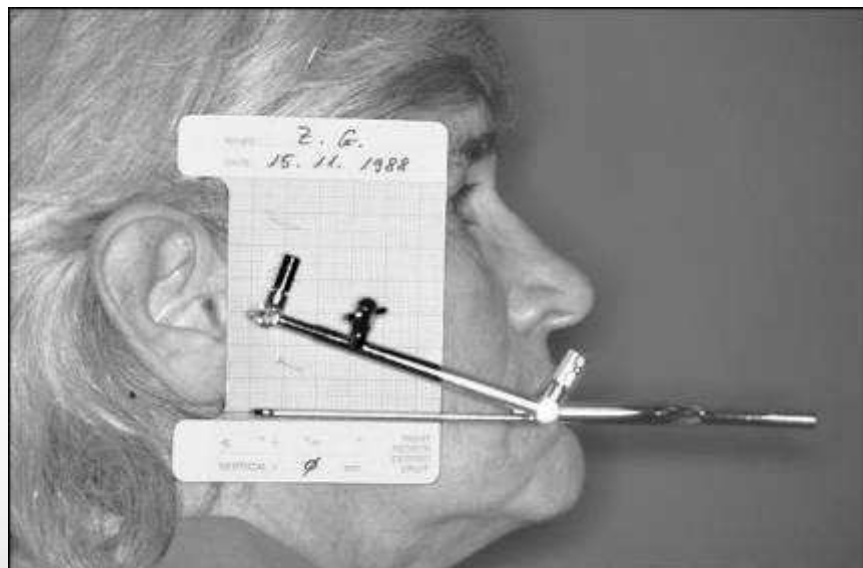


Gesichtsbogenübertragung

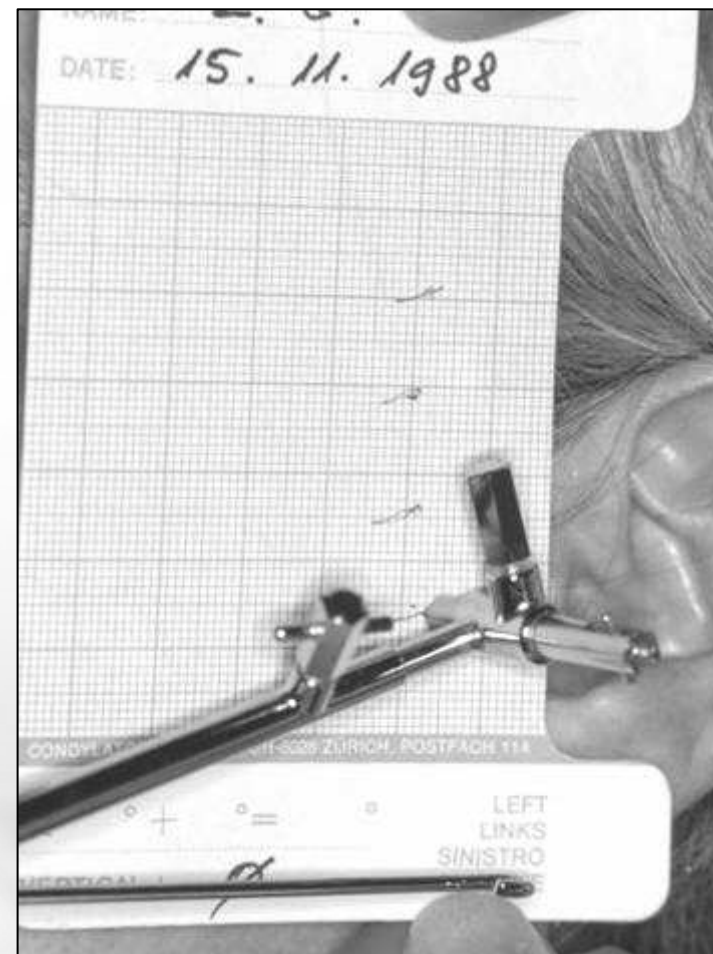
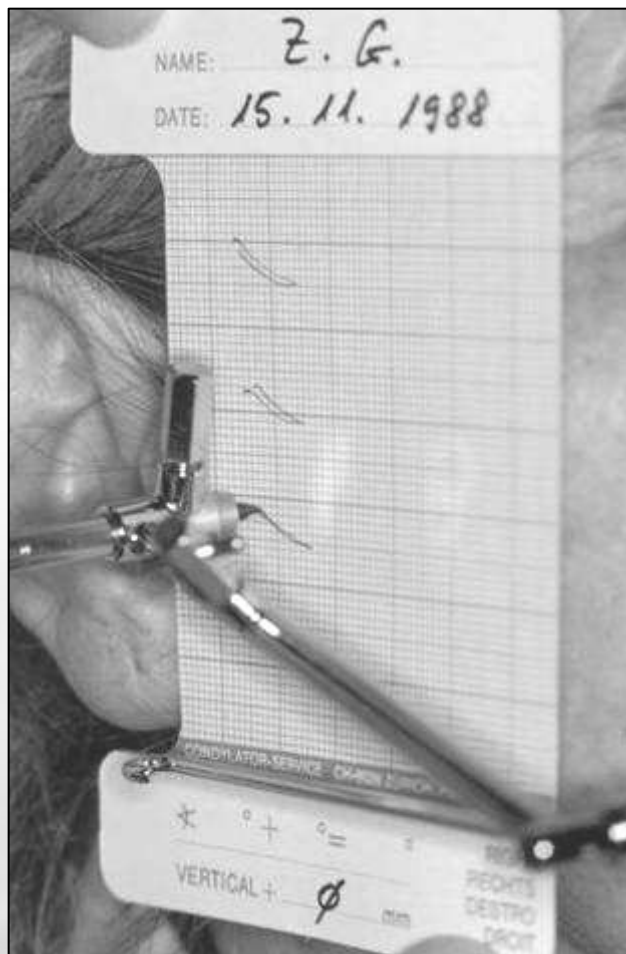




Gesichtsbogenübertragung

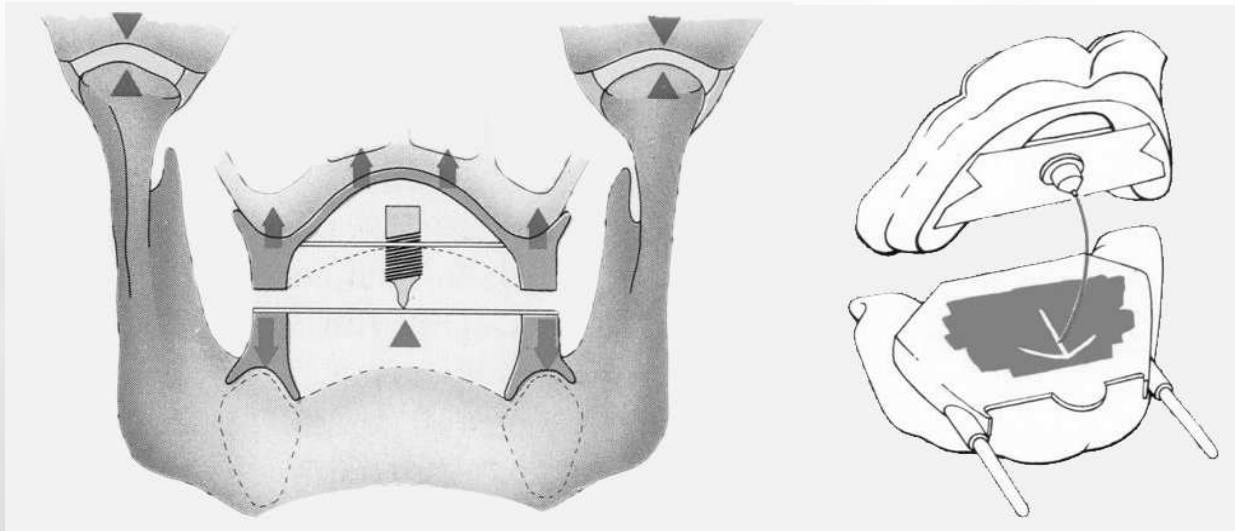


Registrierung der sagittalen Kondylenbahnneigung



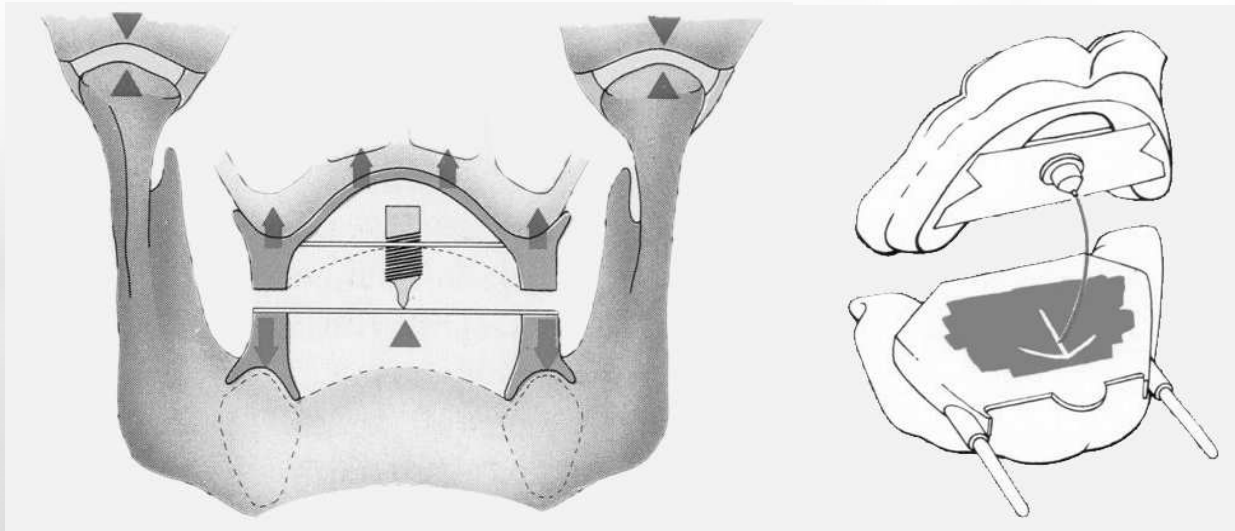
Intraorale Registrierung Horizontale Kieferrelationsbestimmung

- Zentrale Stützstiftmethode
- Registrierung der Grenzbewegungen in der Horizontalebene
- Pfeilspitze = "central bearing point" (CBP)




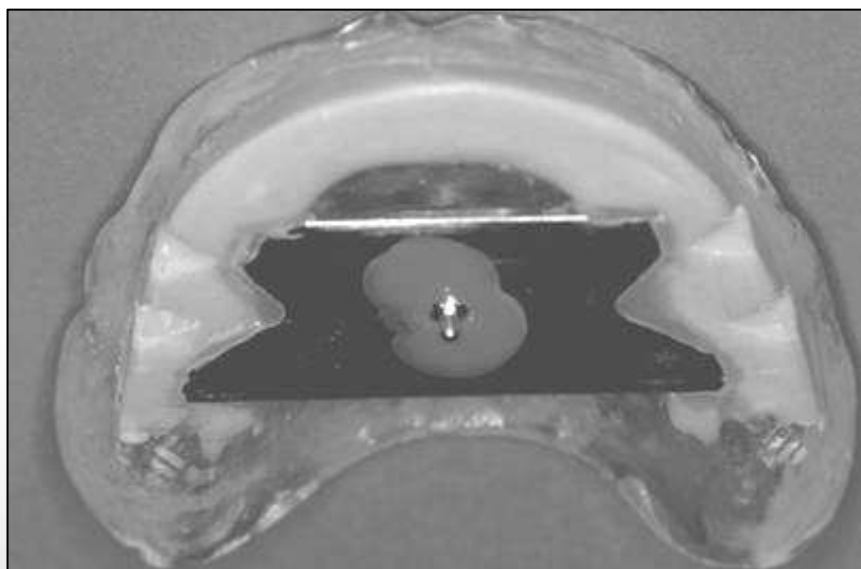
Intraorale Registrierung Horizontale Kieferrelationsbestimmung

- Verschlüsselung minimal posterior der Pfeilspitze (Pfeilspitze am Lochrand des Plättchens), d.h. in minimal protrusiver Unterkieferlage



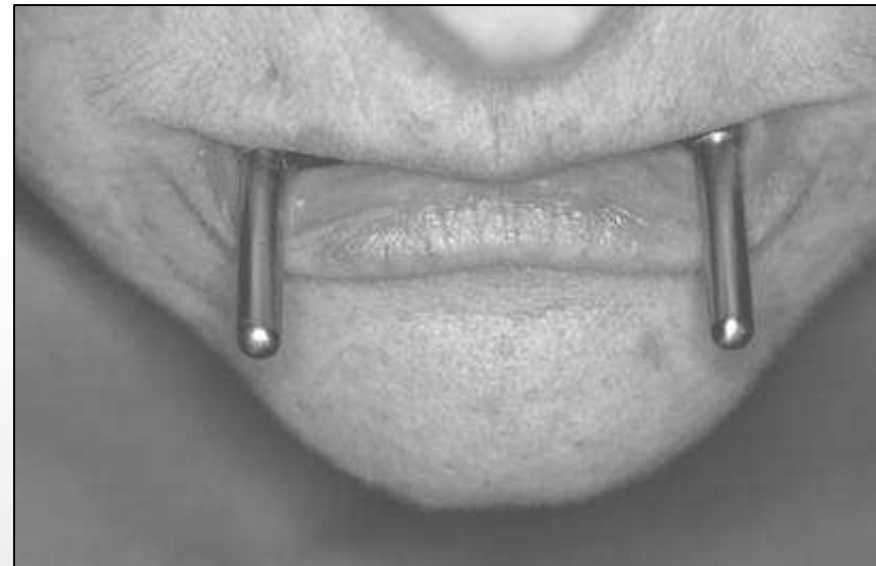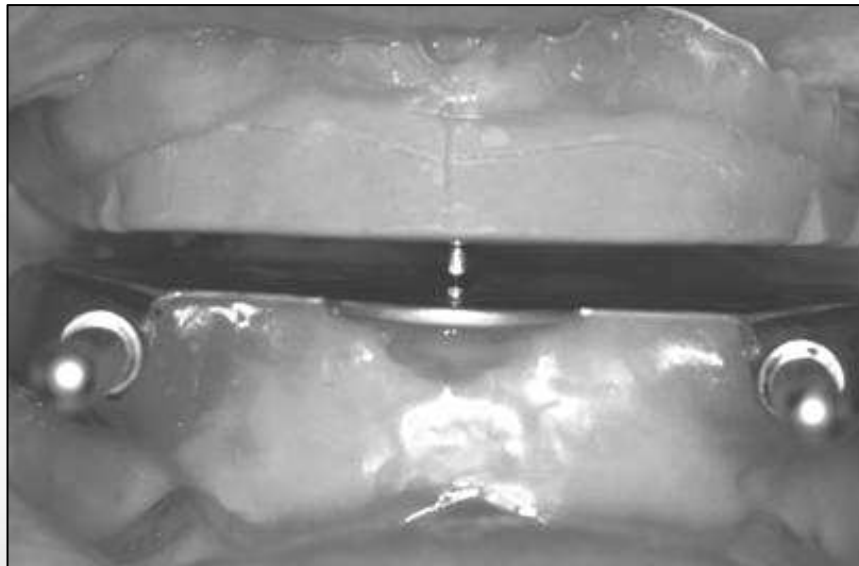


Stützstiftregistrierung



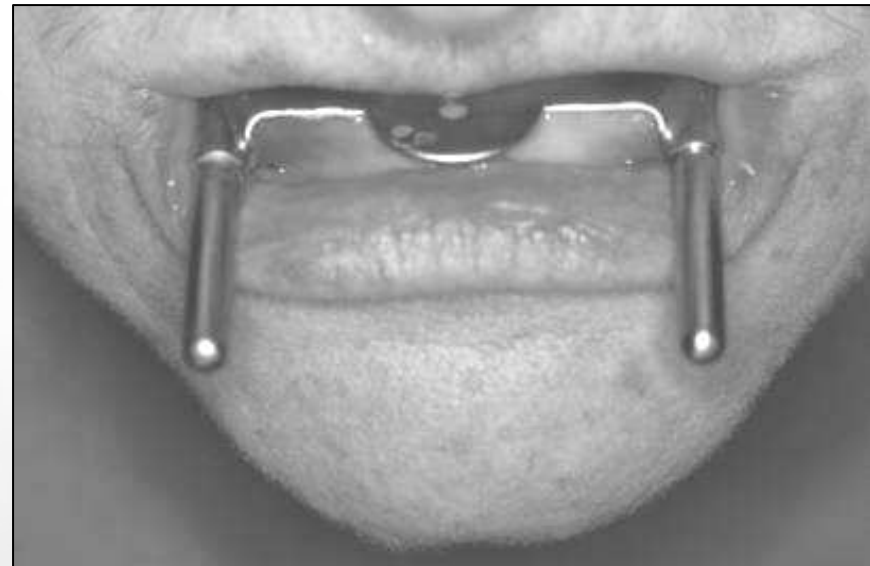
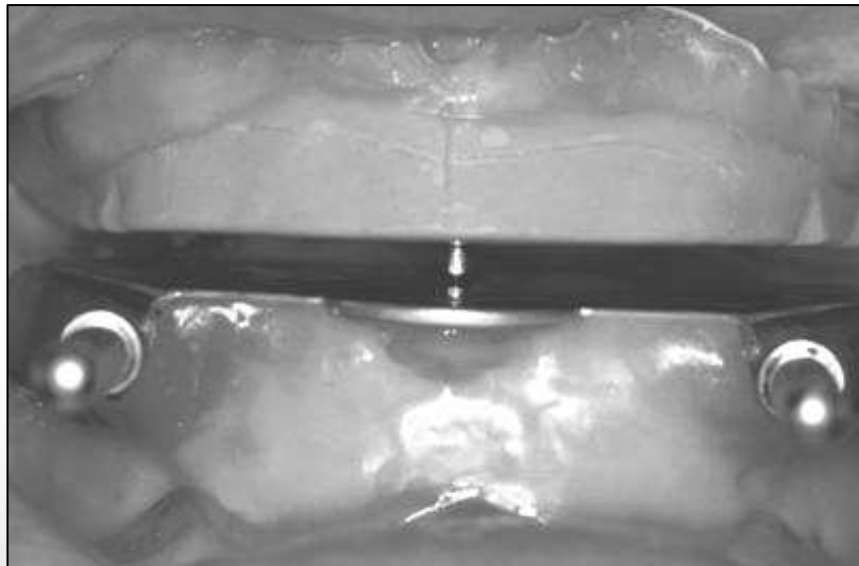


Stützstiftregistrierung



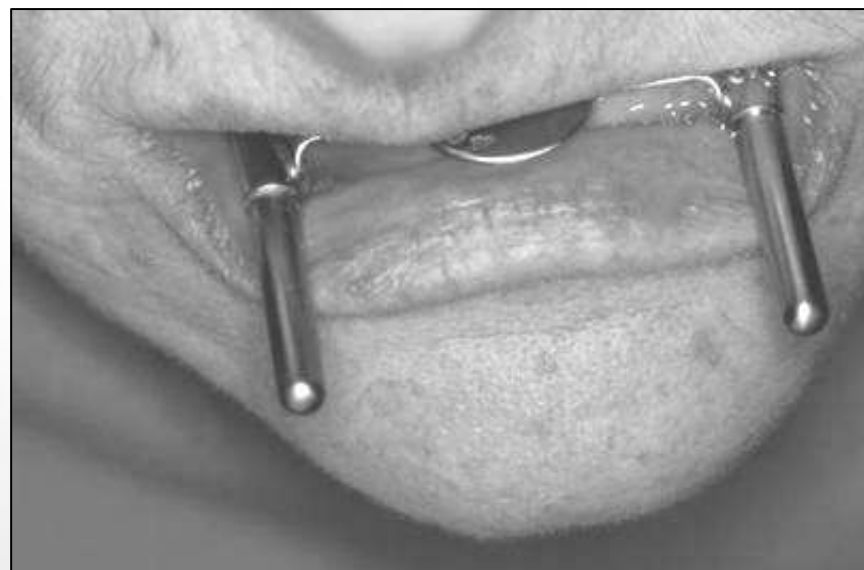
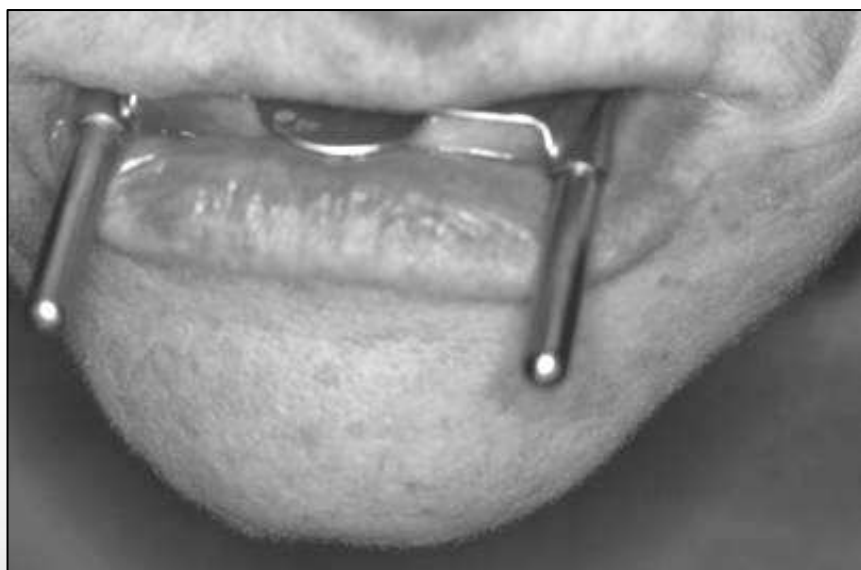
Stützstiftregistrierung






Stützstiftregistrierung







Stützstiftregistrierung



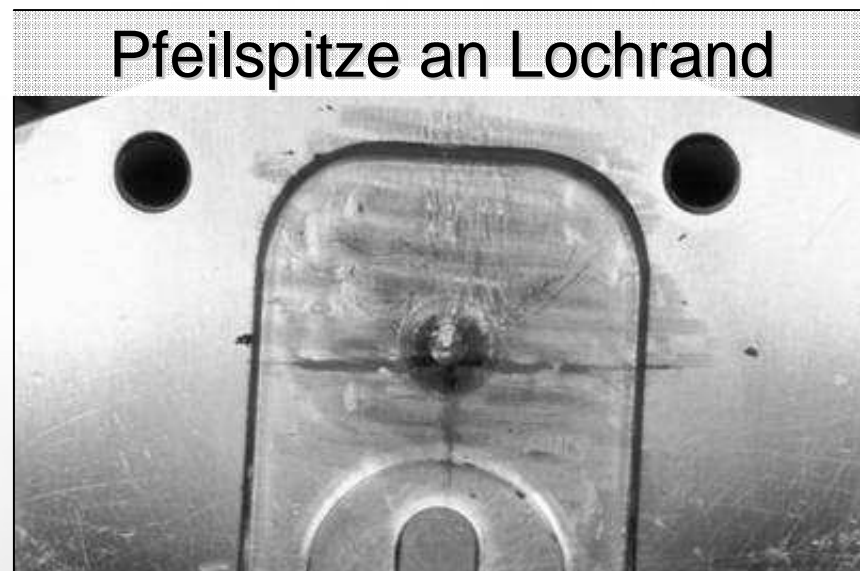


Stützstiftregistrierung





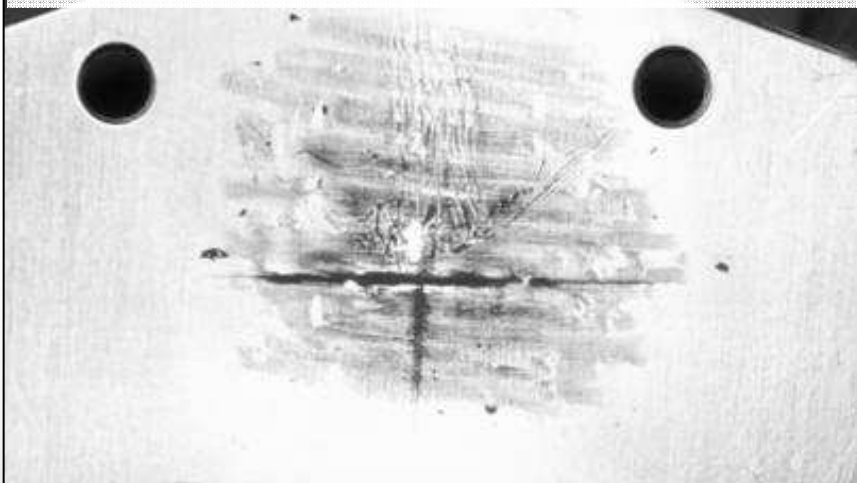
Stützstiftregistrierung



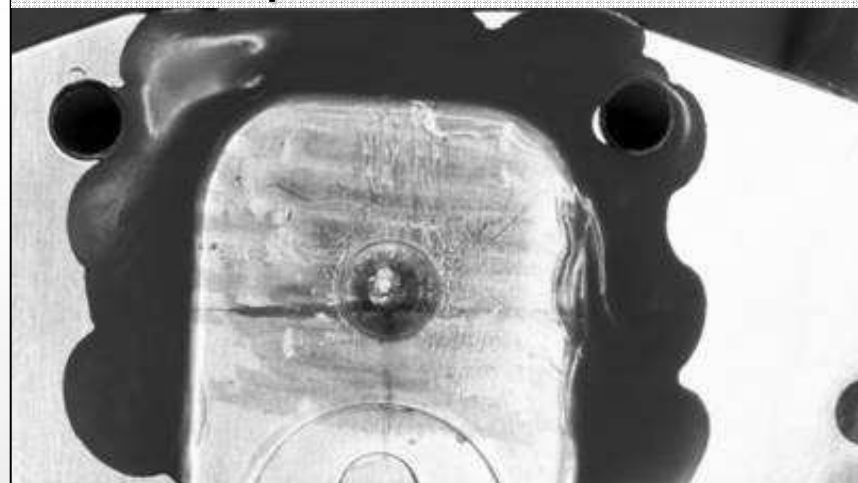


Stützstiftregistrierung

Adduktionsfeld

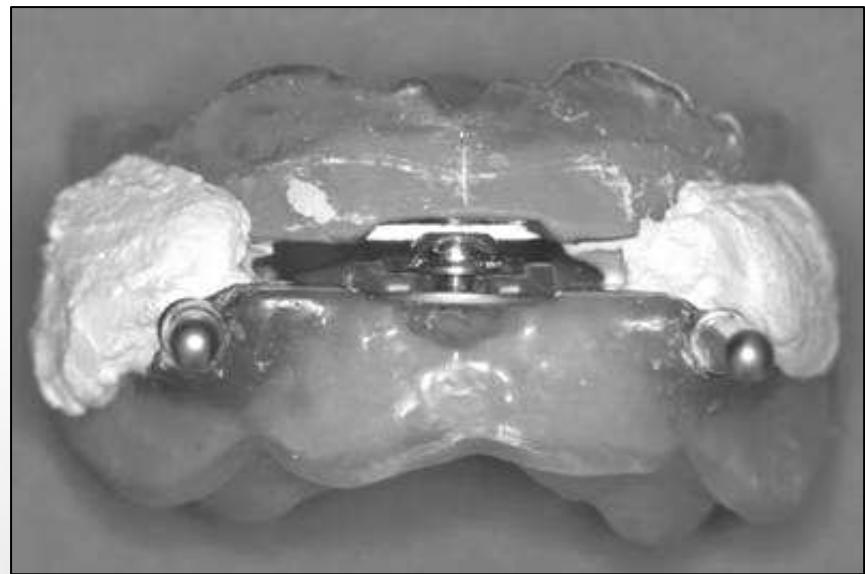
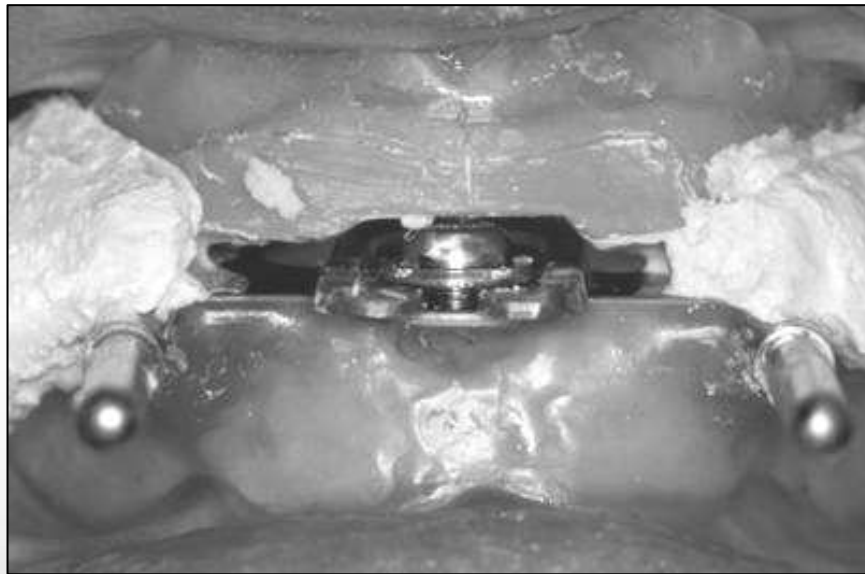


Pfeilspitze an Lochrand



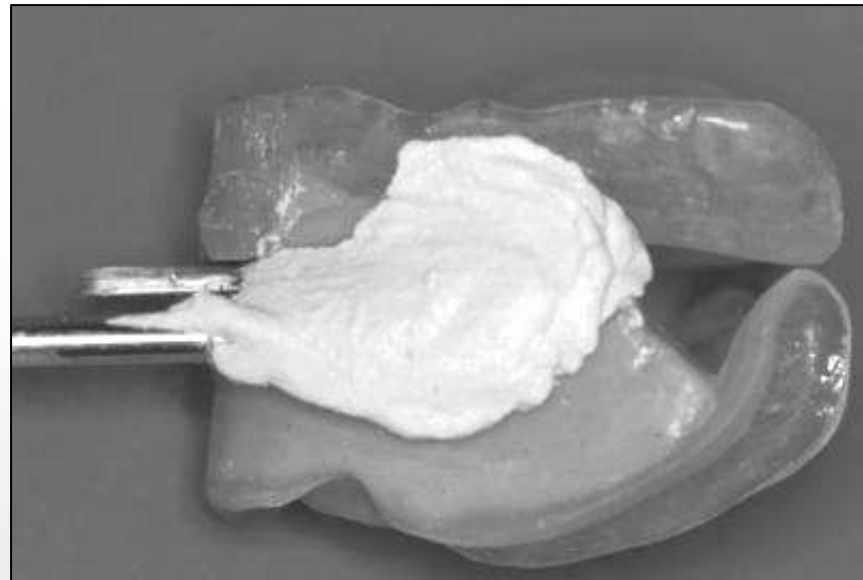
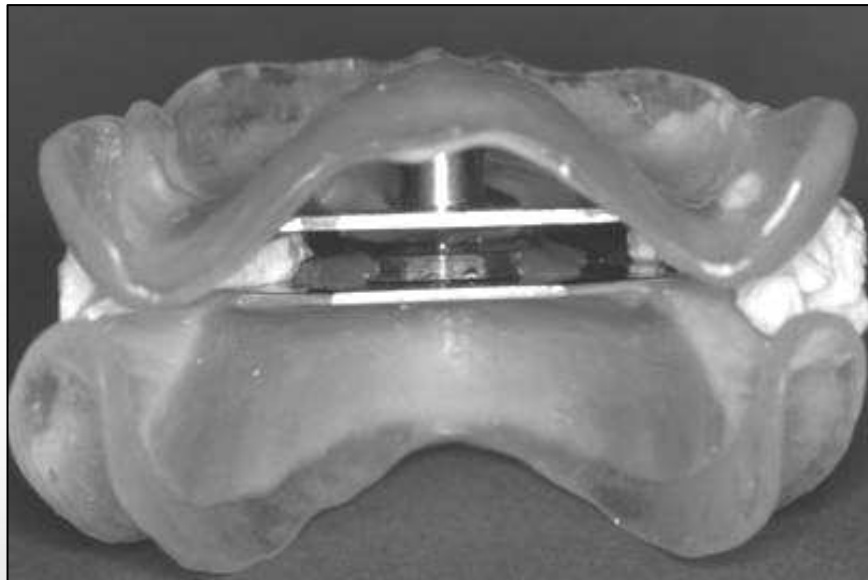


Verschlüsselung mit Abformgips Entnahme im Ganzen




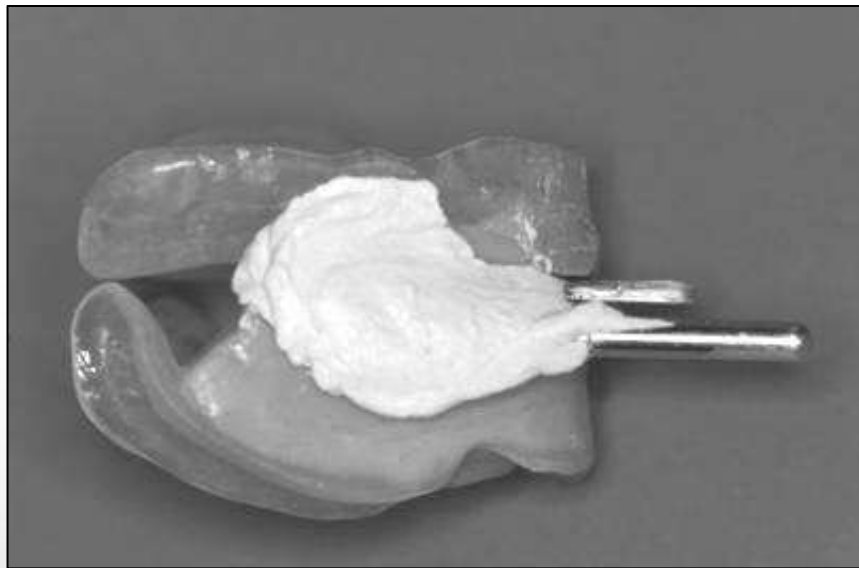


Verschlüsselung mit Abformgips Entnahme im Ganzen






Montage des Unterkiefer-Meistermodells







Montage des Unterkiefer-Meistermodells







Montage des Unterkiefer-Meistermodells



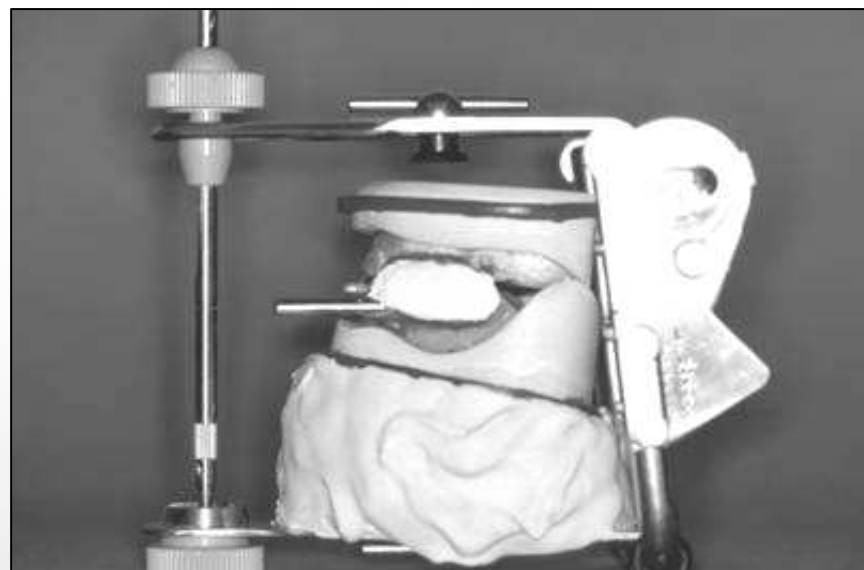



Montage des Unterkiefer-Meistermodells

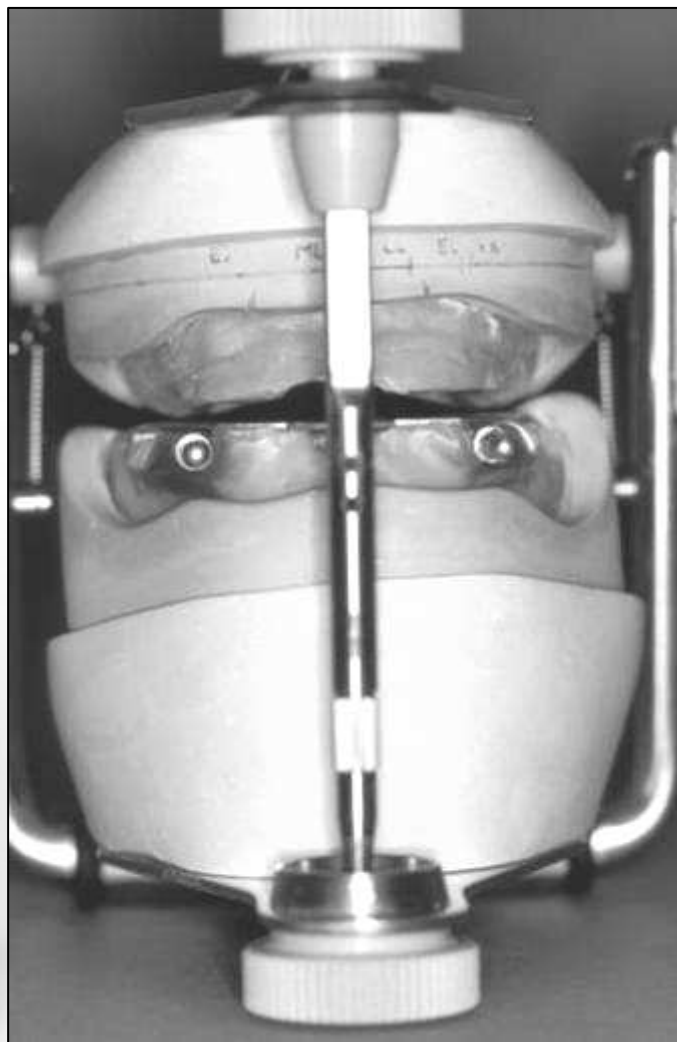
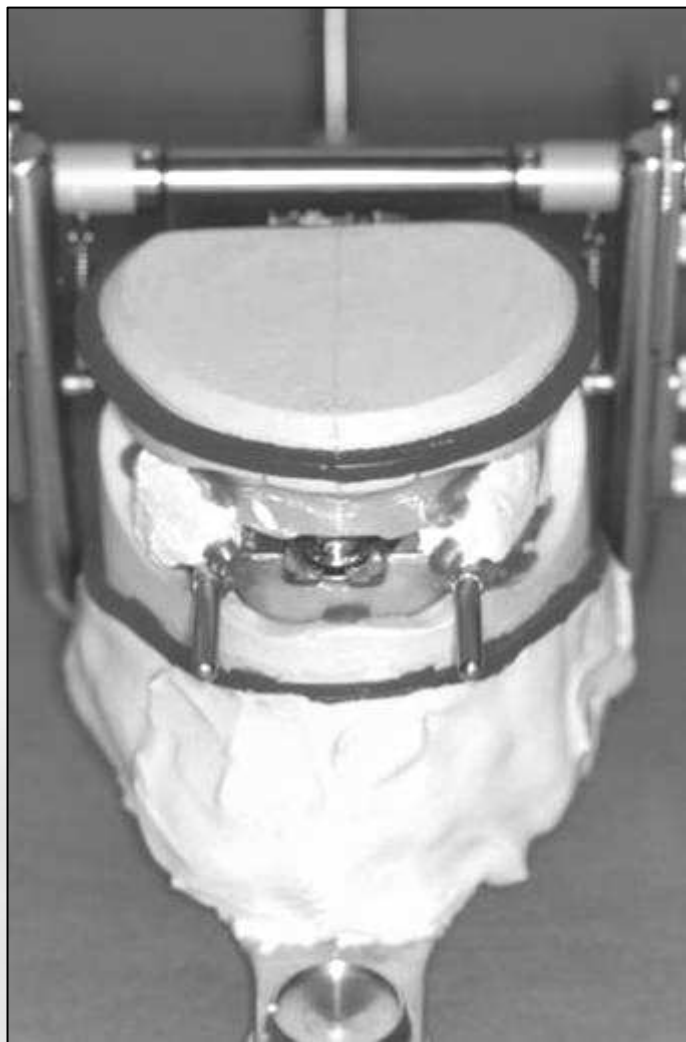




Montage des Unterkiefer-Meistermodells



Montage des Oberkiefer-Meistermodells





Universitätsklinikum
Hamburg-Eppendorf

Zentrum für Zahn, Mund- und Kieferheilkunde
Poliklinik für Zahnärztliche Prothetik

TOTALPROTHETIK

