

GnRH analogues in the treatment of uterine fibroids

A.Golan

Department of Obstetrics and Gynecology, Assaf Harofeh Medical Center,
(Affiliated to Sackler Faculty of Medicine, Tel-Aviv University, Tel-Aviv),
Zerifin 70300, Israel

It is now known that gonadotrophin-releasing hormone analogues (GnRHa) are extremely efficient at reducing uterine fibroid volume and reversing the related symptomatology. However, the fibroids tend to return to their pretreatment size about 6 months after discontinuing treatment. GnRHa treatment cannot be continued indefinitely due to its potential complications and high cost. It is therefore proposed that GnRHa treatment should be phase one of a two-phase treatment plan for uterine fibroids. The initial course of GnRHa should be followed by either menopause or surgery. Experience with presurgical GnRHa use indicates a definite treatment advantage and the use of GnRHa as adjuncts to surgery is well established. The value of GnRHa treatment as a alternative to surgery in pre-menopausal patients, however, remains to be established.

Key words: fibroids/GnRH analogues/treatment/uterine tumours

Introduction

Uterine fibroids are the most common solid tumours in the female pelvis. In the US alone, 175 000 hysterectomies and 18 000 myomectomies are performed every year for this indication. The reported recurrence rate for fibroids is ~50%, meaning that a large proportion of these patients will need to repeat surgery at some stage.

The symptomatology of fibroids includes low abdominal pain, abnormal bleeding and fertility problems. The treatment has always been surgery, the type of which depended on: symptomatology, number and size of the fibroids, age and fertility (past and future).

It has long been known that the uterine myomas are oestrogen-dependent; they increase in size during pregnancy and shrink during puerperium and menopause. The introduction of gonadotrophin-releasing hormone agonists (GnRHa) has proved to be an efficient new treatment in certain hormone-dependent conditions. GnRHa induces hypogonadism through pituitary desensitization, down-regulation of receptors and inhibition of gonadotrophins. It has been found to be useful in the management of various hormone-dependent tumours, endometriosis and uterine fibroids.

The first successful report of the effect of GnRHa on uterine myomas was by Filicori *et al.* (1983). A number of large series, describing increasing experience with the use of GnRHa in the management of fibroids were published during the late 1980s (Van Leusden, 1986; Lumsden *et al.*, 1987; Maheux *et al.*, 1987; Friedman *et al.*, 1987, 1989; Golan *et al.*, 1989).

In addition to the inhibition of the whole pituitary–ovarian axis, the exact mechanism by which the effect of GnRHa occurs, is not fully understood. Vollenhoven *et al.* (1994) demonstrated that uterine fibroids shrink following GnRHa treatment because of lower circulating oestradiol concentrations rather than a change in steroid receptor binding. However, Cirkel *et al.* (1994), using monoclonal antibodies, found an association between fibroid shrinkage and oestrogen receptor status. Fibroids also contain progesterone receptors and the addition of a progestine to GnRHa decreased its effectiveness, probably through interference with the progesterone receptors. When progesterone is administered following GnRH treatment it prevents fibroid regrowth (Bengiano *et al.*, 1993). The existence of specific binding sites for GnRHa in the myometrium and myomas is still an unresolved issue. Evidence exists that local regulation may operate at the fibroid or myometrium level. Epidermal growth factor (EGF) was suggested as a local mediator by Lumsden *et al.* (1988), and insulin-like growth factor (IGF)-I and IGF-II were suggested by Rein *et al.* (1990).

Comparing the features of uterine fibroids following treatment with GnRHa with those of untreated uterine fibroids, reduced cellularity was the only histopathological finding which was correlated with GnRHa treatment (2–3 months). There was no significant change in fibrosis, oedema or mitotic activity, as reported by Upadhyaya *et al.* (1990). Colgan *et al.* (1993) found that increased cellularity and necrosis were associated with fibroids which had been treated with GnRHa. There was no change from the controls with respect to vascular changes, fibrosis or oedema. Ischaemic injury and cellular atrophy were therefore suggested as the probable mechanism.

Johannisson and Brosens (1993) demonstrated decreased proliferative activity by DNA analysis in fibroid tissue following triptorelin treatment for 3 months. Reduced blood flow in myomas and myometrium was also clearly observed by Matta *et al.* (1988). The resistance index (RI) was found to be elevated in both uterine artery and fibroid vasculature.

We initially treated 32 patients aged 22–52 years, with symptomatic uterine fibroids, by monthly i.m. administration of triptorelin 3.75 mg for 6 months. The concentrations of follicle stimulating hormone (FSH) and luteinizing hormone (LH) decreased within 2 weeks (Figure 1). The concentration of oestradiol decreased to post-menopausal values and remained low throughout the treatment period (Figure 2). The mean uterine volume (as shown by ultrasonography) decreased from 600 to 320 ml and the mean myoma volume from 260 to 88 ml (Figures 3 and 4). The maximal effect was achieved by the fourth month of treatment (86% of the total uterine and the total myoma volumes). The maximal monthly decrease in volume was, however, observed during the first month of

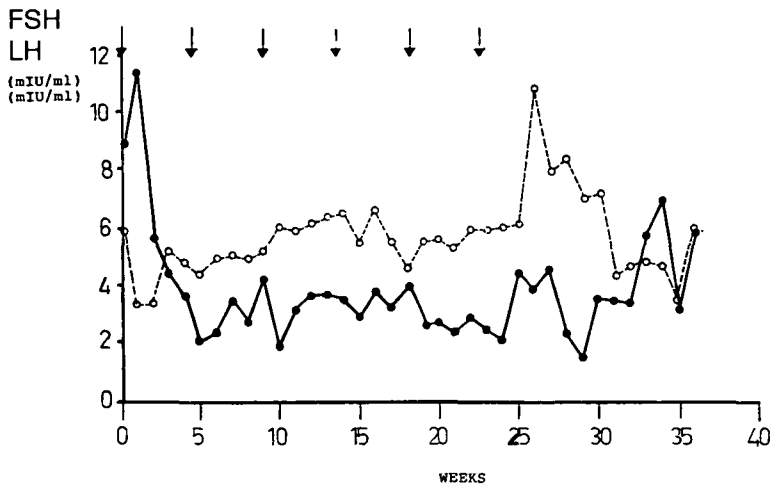


Figure 1. Serum concentrations of follicle stimulating hormone (FSH; ○) and luteinizing hormone (LH; ●) during the 6 month treatment period with triptorelin. Arrows indicate injections of triptorelin.

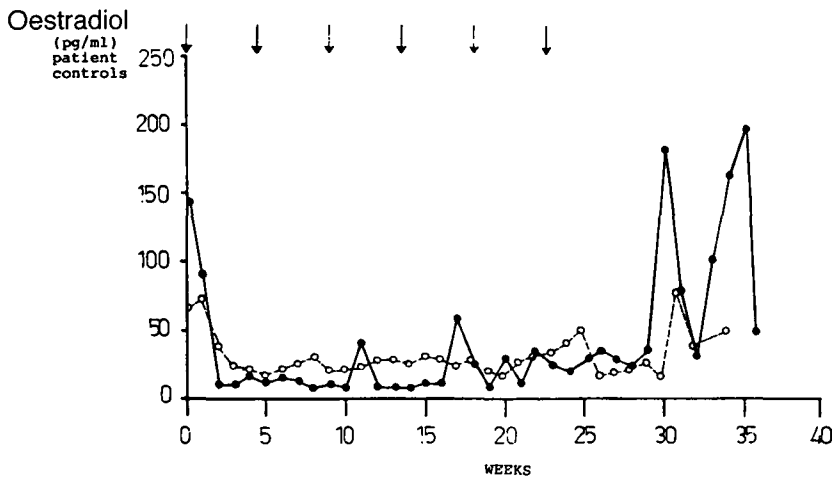


Figure 2. Serum oestradiol concentrations during a 6 month treatment period with triptorelin.

treatment (24% of the uterine volume and 32% of the myoma volume; Golan *et al.*, 1989).

It is already generally accepted that GnRHa treatment of uterine fibroids will achieve the following results: (i) the maximal shrinkage of the myomatous uterus is ~50% of its volume; (ii) the maximal effect is achieved within 3 months of treatment; (iii) amenorrhoea and hypo-oestrogenic side-effects occur; (iv) osteoporosis may occur, especially with treatments lasting >6 months.

However, the fibroids usually return to their pretreatment size 3–6 months following the end of GnRHa treatment. As it is not possible either to continue the GnRHa treatment indefinitely, nor to discontinue treatment, it seems that the initial dream of replacing a surgical therapy with a medical one is impractical. Therefore, it has become clear that GnRHa therapy should constitute phase one

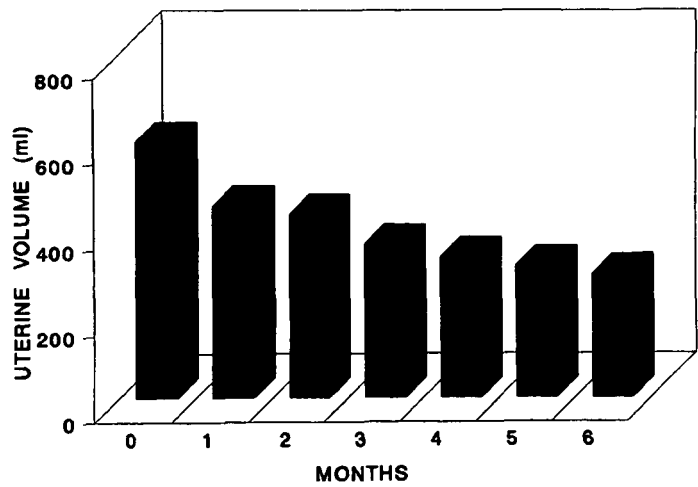


Figure 3. Uterine volume during a 6 month treatment period with triptorelin

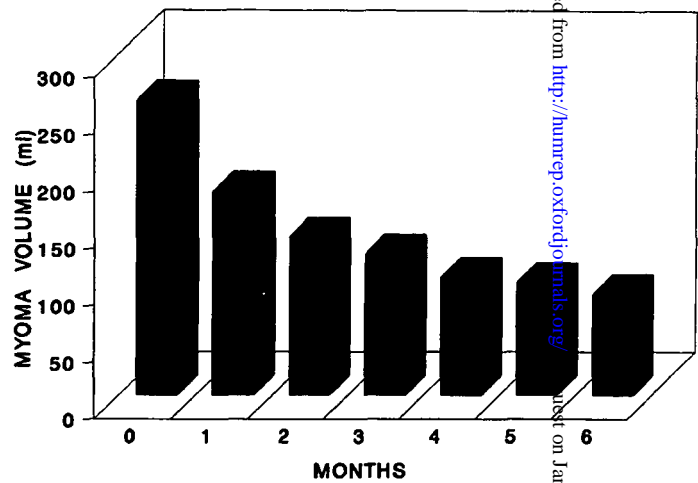


Figure 4. Myoma volume during a 6 month treatment period with triptorelin

of a two-phase plan. An initial course of GnRHa should be followed by either menopause or surgery.

The pre-menopausal group

The rationale with this group of patients was to induce a lasting menopause that would ultimately merge with the natural menopause. However, the fact that the onset of menopause is subject to great individual variation may pose a problem. The required duration of GnRHa therapy is, therefore, unpredictable and may be quite long.

Various add-back protocols have been suggested: tamoxifen (West *et al.*,

1992); gestrinon (Coutinho *et al.*, 1986); progestins (Friedman *et al.*, 1989); and oestrogen (the oestrogen threshold hypothesis; Friedman *et al.*, 1990).

Friedman *et al.* (1993) treated 51 pre-menopausal patients with large symptomatic fibroids by administering GnRHa for 3 months and then randomizing them to receive GnRHa with either progestin and oestrogen or progestin alone as an add-back regimen.

After 1 year, it appeared likely that the GnRHa steroid add-back regimen was able to provide a successful long-term treatment strategy. The combined oestrogen and progestin regimen appeared to be superior to the progestin-only regimen in inhibiting the regrowth of the fibroids and had a more favourable effect on the serum lipid profile. However, a recent study by Balash *et al.* (1995) did not find any beneficial effect of low dose oral contraceptives following GnRH treatment in peri-menopausal women with a fibroid uterus.

Interestingly, Kettel *et al.* (1993), reported success using the GnRH antagonist Nal-Glu, which was able to induce a 53% reduction in fibroid size after 1 month of treatment. When the GnRH antagonist treatment was not followed by surgery, regrowth to the original size was observed within 1 month.

Broekmans *et al.* (1993) tried a different approach. Instead of oestrogen add-back, they attempted to continue GnRHa treatment for 20 weeks after reducing the dose from 500 µg to as little as 5 µg daily. This results of this interesting GnRHa draw-back approach are, however, very preliminary (only six cases).

In an attempt to safely extend the treatment duration with GnRHa, Watanabe *et al.* (1992) reduced the dose of GnRHa (triptorelin) by half. They compared the administration of 1.88 mg with that of 3.75 mg (6 months, 41 patients). No difference could be found between the two groups, either in their hormonal profiles, nor in the effect observed upon the fibroid uteri.

Blumenfeld *et al.* (1991) attempted an interrupted (on and off) protocol. They administered GnRHa for 3 months, stopped for 3 months, retreated for 3 months and stopped again for 3 months (Figure 5). They found that this interrupted mode of treatment was longer, safer and more cost-effective.

The effect of 3.75 mg depot triptorelin lasts for >1 month, and the menses recur ~3 months following the last administration. Therefore, as an alternative to changing, we decided to increase the interval between the injections. We treated 11 patients aged 48–53 years with injections of depot triptorelin 3.75 mg every 8–10 weeks. A significant decrease in the mean uterine and myoma volumes was observed after six injections (42 and 38% respectively) (Figures 6–8).

The preoperative 'young' group

A total of 75 patients aged 34–48 years were scheduled for surgery. Of these, 41 constituted the study group (24 were planned for transabdominal hysterectomy (TAH) and 17 for myomectomy); 34 served as controls (21 TAH, and 13 myomectomies). The patients in the study group received two injections of depot triptorelin (3.75 mg) at monthly intervals prior to surgery. The controls received no injections. Uterine volume, the hormonal profile and the haemoglobin

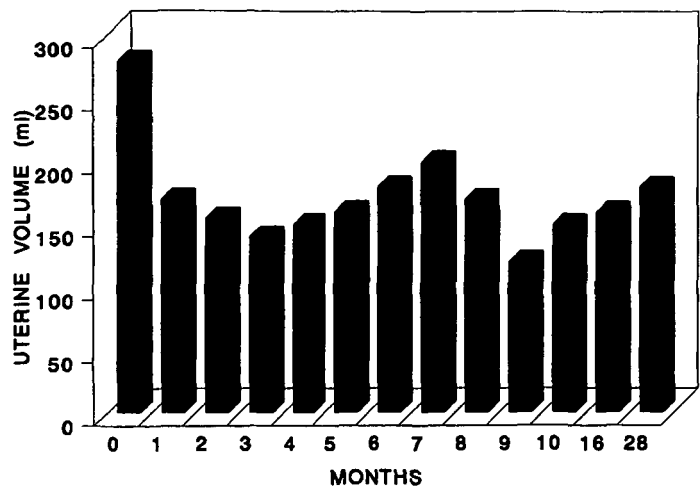


Figure 5. Uterine volumes during 'on and off' protocol (Blumenfeld *et al.*, 1991).

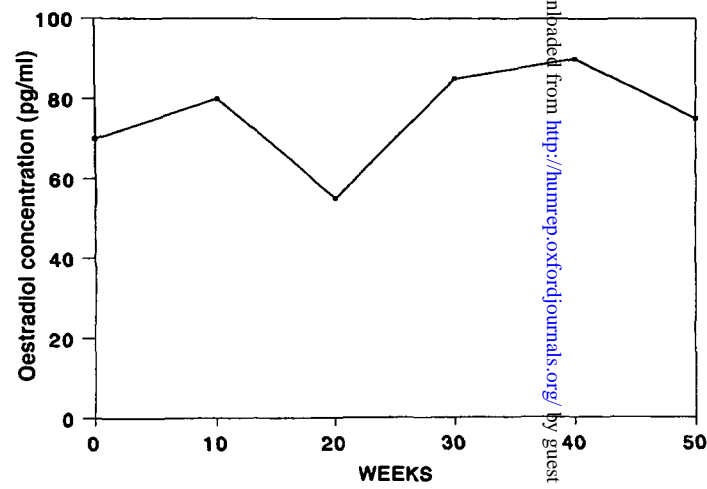


Figure 6. Serum oestradiol concentrations during 'long interval' treatment.

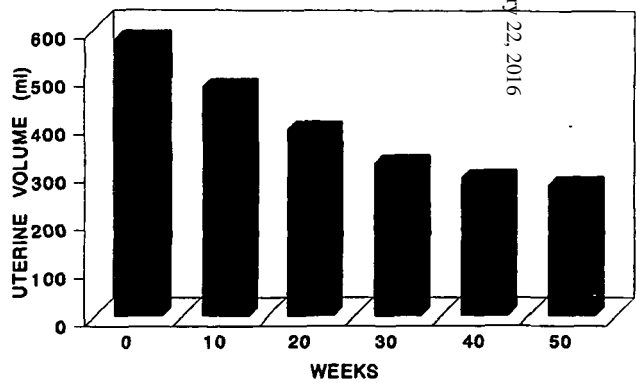


Figure 7. Uterine volume during 'long interval' treatment

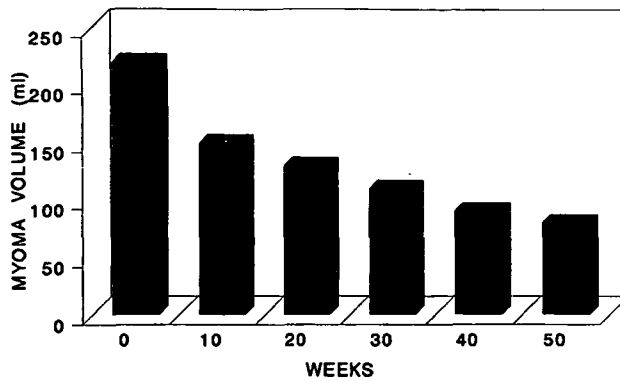


Figure 8. Myoma volume during 'long interval' treatment with D-TRP-6 luteinizing hormone-releasing hormone every 70 days.

concentration were monitored. The duration of surgery, the amount of intraoperative blood loss and the need for blood transfusion, the duration of hospital stay and the post-operative complications were recorded. A statistically significant drop in uterine volume was observed in the study group, following 2 months of preoperative treatment (32%). The haemoglobin concentration increased just before surgery in this group, in comparison with the presurgery values in the control group, although the increase did not reach statistical significance. The duration of surgery was significantly shorter in the study group compared with the controls (49 versus 70 min in the TAH and 80 versus 96 min in the myomectomies). The intra-operative blood loss was statistically significantly lower in the study group, in comparison with the controls (208 versus 309 ml in the TAH and 320 versus 476 ml in the myomectomies). Fewer blood transfusions were, therefore, needed in the study group, although the difference could not be evaluated statistically because of the small numbers. No difference could be observed in hospital stay between the groups. Preoperative shrinkage of uterine fibroids by GnRHa administration was seen to effectively shorten the duration of surgery, diminish blood loss and the need for blood transfusions. We also feel that surgery following triptorelin injection is smoother and post-operative complications are fewer (Golan *et al.*, 1993). Ylikovkala *et al.* (1995) in a randomized double-blind placebo-controlled study, confirmed the ability of preoperative GnRH treatment to increase low haemoglobin concentrations which in turn may reduce the need for blood transfusion. They found no objective benefit during surgery, such as duration and blood loss, but this may have been related to the less than optimal hypo-oestrogenism induced in their GnRHa-treated patients.

In endoscopic surgery, several studies utilizing preoperative preparation with GnRHa have been published: 150 cases of laparoscopic myectomy were reported by Mettler and Semm (1993). They concluded that the technique is easier, and decreased blood loss is incurred. In 114 reported cases of hysteroscopic surgery (58 submucous myomas), Perino *et al.* (1993) concluded that surgery was easier, with decreased blood loss, the duration of surgery was shorter and there was less

medium infused when preoperative GnRHa was administered. Donnez *et al.* (1990) reported 60 cases of hysteroscopic resection of submucous myomas and observed that surgery was easier, the haemoglobin concentration was higher and fluid absorption was lower following preoperative administration of GnRHa.

In conclusion, we can say that GnRHa is an important weapon today in the treatment of uterine myomas. There is no doubt of the value of its administration as an adjunct to surgery. This is particularly important in cases requiring endoscopic gynaecological surgery, where the decrease in the size of the uterus and the fibroids may be crucial. This has proved to be the cause for operative laparoscopy, as well as operative hysteroscopy. However, it still remains to establish the value of GnRHa and the best method of treatment in peri-menopausal patients in which they GnRHa administration may constitute an alternative to surgery.

References

- Balash, J., Manau, B., Mino, J. *et al.* (1995) Sequential gonadotropin-releasing hormone agonist/low dose oral contraceptive treatment for leiomyomata uteri. *Hum. Reprod.*, **10**, 529–532.
- Benagiano, G., Priero, F.M. and Villani, C. (1993) GnRH analogues in the management of uterine leiomyomas and other benign gynecological situations. In Lunenfeld, B. and Insler, V. (eds), *GnRH Analogues. The State of Art 1993*. Parthenon Publishing, Camforth, UK, pp 55–85.
- Blumenfeld, Z., Thaler, I., Weiner, Z. *et al.* (1991) Treatment of uterine leiomyomata with GnRH analog (nafarelin): a clinical protocol of interrupted (on-and-off) treatment. In Blumenfeld, Z. (ed.), *Advances in the Study of GnRH Analogs. Proceedings of the 2nd International Symposium on GnRH Analogs*. Vol. 4. Parthenon Publishing Group Ltd, London, pp. 123–131.
- Broekmans, F.J., Hompes, P.G. and Schoemaker, J. (1993) GnRH agonist of uterine leioma: complete followed by partial pituitary suppression (preliminary results). [Abstr.] *Gynecol. Endocrinol.*, **7**, 37.
- Cirkel, U., Ochs, H., Roehl, A. and Schneider, H.P. (1994) Estrogen and progesterone receptor content of enucleated uterine myomata after luteinizing hormone-releasing hormone analog depot therapy. *Acta Obstet. Gynecol. Scand.*, **73**, 328–332.
- Colgan, T.J., Pendergast, S. and LeBlanc, M. (1993) The histopathology of uterine leiomyomas following treatment with gonadotropin-releasing hormone analogs. *Hum. Pathol.*, **24**, 1073–1077.
- Coutinho, E.M., Boulanger, G.A. and Goncalve, M.T. (1986) Regression of uterine leiomyomas after treatment with gestrinone, an anti-estrogen, antiprogesterone. *Am. J. Obstet. Gynecol.*, **155**, 761.
- Donnez, J., Gillerot, S., Bourgonjon, D. *et al.* (1990) Neodymium:YAG laser hysteroscopy in large submucous fibroids. *Fertil. Steril.*, **54**, 999–1003.
- Filicori, M.D., Hall, D.A., Loughlin, J.S. *et al.* (1983) A conservative approach of the management of uterine leiomyomata: pituitary desensitization by a luteinizing hormone-releasing hormone analogue. *Am. J. Obstet. Gynecol.*, **147**, 726–727.
- Friedman, A.J., Barbieri, R.L., Benacerraf, B.R. and Schiff, I. (1987) Treatment of leiomyomata with intranasal or subcutaneous leuprolide, a gonadotropin-releasing hormone agonist. *Fertil. Steril.*, **48**, 560–564.
- Friedman, A.J., Harrison Atlas, D., Barbieri, R.L. *et al.* (1989) A randomized, placebo-controlled, double-blind study evaluating the efficacy of leuprolide acetate depot in the treatment of uterine leiomyoma. *Fertil. Steril.*, **51**, 251–256.
- Friedman, A.J., Lobel, S.M., Rein, M.S. and Barbieri, R.L. (1990) Efficacy and safety considerations in women with uterine leiomyomas treated with gonadotropin-releasing hormone agonists: the estrogen threshold hypothesis. *Am. J. Obstet. Gynecol.*, **163**, 1114–1119.
- Friedman, A.J., Daly, M., Juneau-Norcross, M. *et al.* (1993) A prospective, randomized trial of

GnRH analogues in the treatment of uterine fibroids

- gonadotropin-releasing hormone agonist plus estrogen-progestin or progestin 'add-back' regimens for women with leiomyomata uteri. *J. Clin. Endocrinol. Metabol.*, **76**, 1439–1445.
- Golan, A., Bukovsky, I., Schneider, D. *et al.* (1989) D-Trp-6-luteinizing hormone-releasing hormone microcapsules in the treatment of uterine leiomyomas. *Fertil. Steril.*, **52**, 406–411.
- Golan, A., Bukovsky, I., Pansky, M. *et al.* (1993) Preoperative gonadotropin-releasing hormone agonist treatment in surgery for uterine leiomyomata. *Hum. Reprod.*, **8**, 450–452.
- Johannissen, E. and Brosens, I. (1993) The effect of Decapeptyl on the growth of leiomyomata. [Abstr.] *Gynecol. Endocrinol.*, **7**, 36.
- Kettel, L.M., Murphy, A.A., Morales A.J. *et al.* (1993) Rapid regression of uterine leiomyomas is response to daily administration of gonadotropin-releasing hormone antagonists. *Fertil. Steril.*, **60**, 642–646.
- Lumsden, M.D., West, C.P., Baird, D.T. (1987) Goserelin therapy before surgery for uterine fibroids. *Lancet*, **i**, 36–37.
- Lumsden, M.A., West, C.P., Bramley, T. *et al.* (1988) The binding of epidermal growth factor to the human uterus and leiomyomata in women rendered hypooestrogenic by continuous administration of an LHRH agonist. *Br. J. Obstet. Gynaecol.*, **95**, 1299–1304.
- Maheux, R., Samson, Y., Farid, N.R. *et al.* (1987) Utilization of luteinizing hormone-releasing hormone agonist in pulmonary leiomyomatosis. *Fertil. Steril.*, **48**, 315–317.
- Matta, W.H., Stabile, I., Shaw, R.W., and Campbell, S. (1988) Doppler assessment of uterine blood flow changes in patients with fibroids receiving the gonadotropin-releasing hormone agonist Buserelin. *Fertil. Steril.*, **49**, 1083–1088.
- Mettler, L. and Semm, K. (1993) Laparoscopic approach of fibroid excision after treatment with GnRH analogue. [Abstr. no. 39] *Gynecol. Endocrinol.*, **7**, 30.
- Perino, A., Chianchiano, N., Petronio, M. and Cittadini, E. (1993) Role of leuprolide acetate depot in hysteroscopic surgery: a controlled study. *Fertil. Steril.*, **59**, 507–510.
- Rein, M.S., Friedman, A.J., Stuart, J.M. and MacLaughlin, D.T. (1990) Fibroid and myometrial steroid receptors in women treated with gonadotropin-releasing hormone agonist leuprolide acetate. *Fertil. Steril.*, **53**, 1018–1023.
- Upadhyaya, N.B., Doody, M.C. and Googe, P.B. (1990) Histopathological changes in leiomyomata treated with leuprolide acetate. *Fertil. Steril.*, **54**, 811–814.
- Van Leusden, H.A. (1986) Rapid reduction of uterine myomas after short-term treatment with microencapsulated D-Trp-LHRH. *Lancet*, **ii**, 1213.
- Vollenhoven, B.J., Pearce, P., Herington, A.C. *et al.* (1994) Steroid receptor binding and messenger RNA expression in fibroids from untreated and gonadotropin-releasing hormone agonist pretreated women. *Clin. Endocrinol. Oxf.*, **40**, 537–544.
- Watanabe, Y., Nakamura, G., Matsuguchi, H. *et al.* (1992) Efficacy of a low-dose leuprolide acetate depot in the treatment of uterine leiomyomata in Japanese women. *Fertil. Steril.*, **58**, 66–71.
- West, C.P., Lumsden, M.A., Lawson, S. *et al.* (1987) Shrinkage of uterine fibroids during therapy with goserelin (Zoladex): a luteinizing hormone-releasing hormone agonist administered as a monthly subcutaneous depot. *Fertil. Steril.*, **48**, 45–51.
- West, C.P., Lumsden, M.A. and Baird, D.T. (1992) Goserelin (Zoladex) in the treatment of fibroids. *Br. J. Obstet. Gynecol.*, **99**, 27–30.
- Ylikovkala, O., Tiitinen, A., Hulkko, S. *et al.* (1995) Decrease in symptoms, blood loss and uterine size with nafarelin acetate before abdominal hysterectomy: a placebo-controlled, double-blind study. *Hum. Reprod.*, **10**, 1470–1474.