



Electrocardiographical case. ST elevation: is this an infarct?

H C Chew, S H Lim

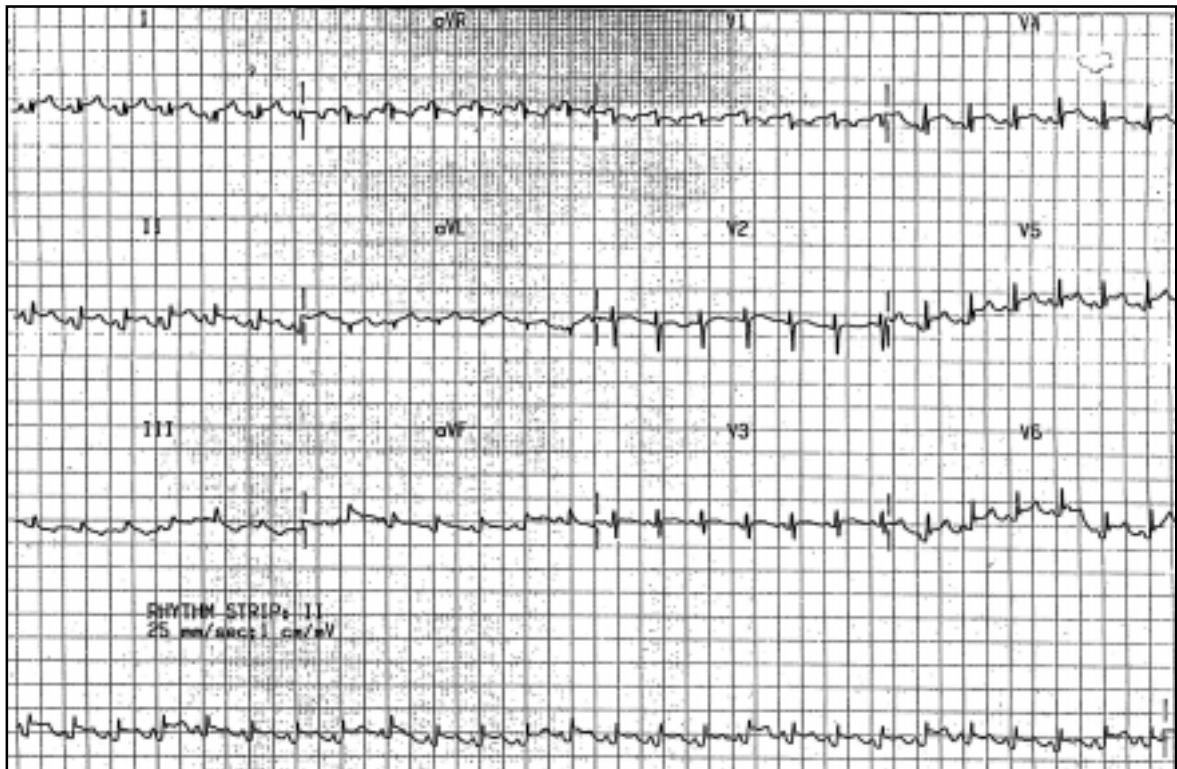


Fig. 1 12-lead ECG.

Department of
Emergency Medicine
Singapore General
Hospital
Outram Road
Singapore 169608

H C Chew, MMed,
MRCP, MRCSE
Registrar

S H Lim, MBBS,
FRCS, FAMS
Senior Consultant
and Head

Correspondence to:
Dr Chew Huck Chin
Tel: (65) 9856 0027
Fax: (65) 6462 4178
Email: chinjing@
pacific.net.sg

CLINICAL PRESENTATION

A 25-year-old man presented with complaints of chest pain and fever. A 12-lead electrocardiogram (ECG) was performed (Fig. 1). What is the diagnosis?

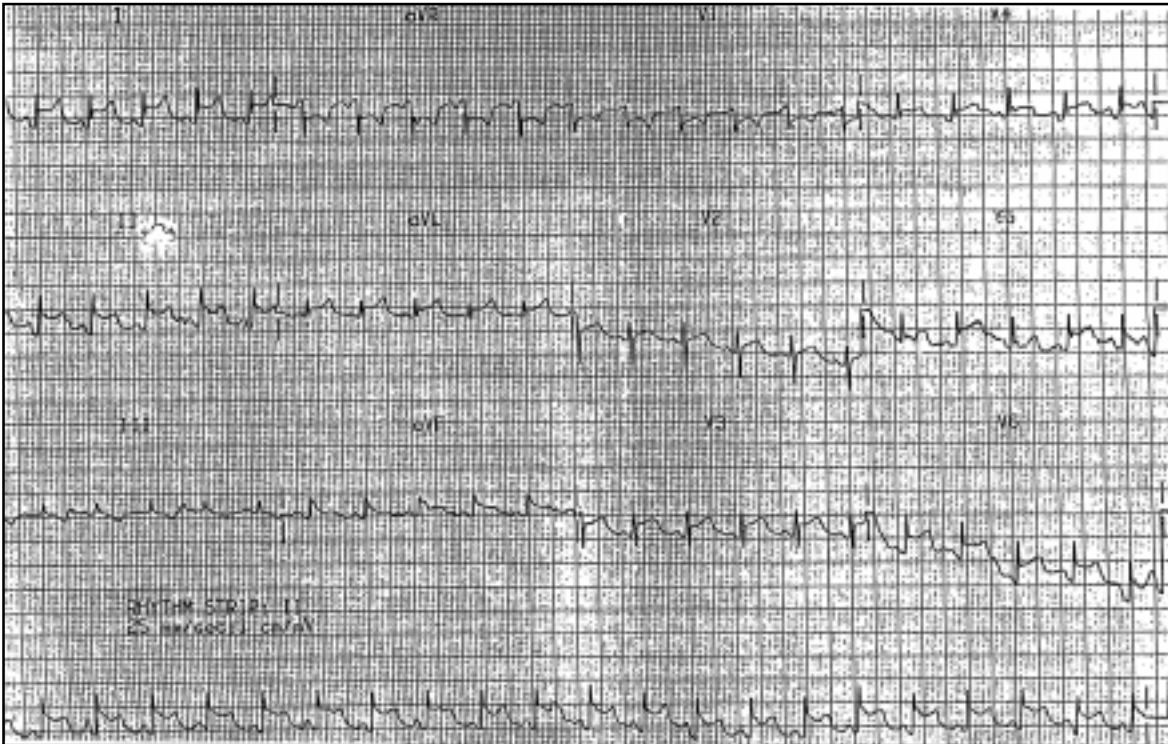


Fig. 2 64-year-old man who complained of shortness of breath with anterior chest pain for the three days, was relieved by sitting upright. He had underlying chronic renal failure. ECG shows concave ST segment elevation in leads I, II, V3, V4, V5 and V6, with concomitant PR segment depression in leads I and V4. In addition, the ST/T ratio in lead V6 is >0.25 . The PR segment in lead aVR is elevated. This patient was found to have a small pericardial effusion on echocardiography with serum creatinine levels of 1200mmol/L. He was diagnosed with uraemic pericarditis with acute-on-chronic renal failure and was admitted to the intensive care unit where he underwent dialysis.

ECG INTERPRETATION

ECG (Fig. 1) showed concave ST segment elevation in leads I, II, III, aVF as well as V4, V5 and V6. Q waves were not seen and there was PR depression present in leads II, V5 and V6. The PR segment in aVR was elevated. The R waves were well preserved.

DIAGNOSIS

Pericarditis.

CLINICAL COURSE

The patient had a pericardial rub on auscultation. Erythrocyte sedimentation rate was elevated and cardiac enzymes were negative. The patient was admitted to the cardiology unit for observation. He was well when discharged one week later.

DISCUSSION

Pericarditis is a syndrome caused by inflammation of the pericardium. This inflammatory response causes increased vascular permeability, vasodilation and transudation of fluid into the pericardial space. There are many different aetiologies (Fig. 2), the more common causes being idiopathic, viral, tuberculous and neoplastic. Others are listed in Table I⁽¹⁻⁶⁾.

Patients typically present with complaints of a sharp central chest pain that is described to be worse

with inspiration and recumbency, relieved by sitting up and leaning forwards⁽⁷⁾. The pain may radiate to the ridge of the trapezius, shoulder, arm or epigastrium. Non-specific symptoms that have been described include fever, hiccups, hoarseness of voice, palpitations, cough, nausea and vomiting⁽⁷⁾. The pathognomonic finding on clinical examination is a pericardial friction rub that classically corresponds to the three phases of atrial systole, ventricular systole and diastole. This is best heard with the patient in exhalation. However, all three components are heard less than 50% of the time⁽⁸⁾.

The ECG is very useful in diagnosing acute pericarditis. Abnormalities have been reported in up to 90% of cases⁽⁹⁾. These ECG changes are purported to be due to superficial myocardial inflammation⁽¹⁰⁾. The most sensitive finding has been that of diffuse ST segment elevation, which reflects the abnormal repolarisation as a result of pericardial inflammation. Other conditions must also be considered in the differential diagnosis of pericarditis on ECG (Table II).

The two most common conditions that are confused with that of pericarditis based on ECG findings include that of an acute myocardial infarction and early repolarisation, which is a normal variant on the ECG usually occurring in young black males.

Table I: Causes of acute pericarditis.

Idiopathic origin	Drugs	Irradiation
Viral infection	Procainamide	Trauma or surgery
Coxsackie virus A and B	Hydralazine HCL (Apresoline)	Post pericardiotomy syndrome
Echoviruses	Isoniazid (Nydravid)	Chylopericardium
Adenoviruses	Phenytoin (Dilantin)	Influenza virus vaccine (FluMist,
Human immunodeficiency virus (HIV)	Metabolic disorders	Fluvirin, Fluzone)
Bacterial and purulent infections	Hypothyroidism	
<i>Staphylococcus aureus</i>	Uraemia (dialysis-related)	
<i>Streptococcus pneumoniae</i>	Vasculitis	
<i>Mycoplasma pneumoniae</i>	Neoplasms	
Anaerobic bacteria	Myocardial infarction	
Gram-negative species	Connective tissue disease	
Fungal infection	Systemic lupus erythematosus	
<i>Histoplasma capsulatum</i>	Rheumatoid arthritis	
<i>Aspergillus</i> species	Sarcoidosis	
Mycobacterial infection	Scleroderma	
<i>Mycobacterium tuberculosis</i>	Idiopathic thrombocytopenic purpura	
Rickettsial infection	Amyloid	
Parasitic infection	Aortic dissection	

Early repolarisation is distinguished by the absence of symptoms in the patient with failure to evolve through the four stages of ECG changes as first described by Spodick⁽¹⁴⁾. In addition, the ST segments in normal variants are limited to the precordial leads with elevation of the ST segment in lead V1, an isoelectric ST segment in lead V6, notching of the terminal aspect of the QRS complex and a shift to baseline of the ST segments with exercise^(12,15). Ginzton and Laks⁽¹⁶⁾ also noted that a ST/T ratio of >0.25 in lead V6 on ECG discriminated

patients with acute pericarditis from normal variants. The various distinguishing features are listed in Table III.

The classical ECG changes of pericarditis have been described into four stages (Table IV), although progression through all four stages occurs in less than 50% of patients.

The pattern of ST segment elevation is important in distinguishing pericarditis from other diseases of the myocardium. Distinct features seen on ECG in patients with pericarditis include:

1. Concave ST segment elevation.
2. Widespread ST segment elevation not corresponding to any specific arterial territory.
3. Absence of reciprocal changes and Q waves.
4. Possible presence of low voltages.

Further investigations include laboratory markers such as C-reactive protein, erythrocyte sedimentation rate and leukocyte count which are usually elevated with pericarditis⁽⁷⁾. Some have also reported

Table II. Differential diagnosis of pericarditis on ECG^(9,13).

- Transmural myocardial infarction
- Early repolarisation
- Myocarditis
- Pulmonary embolism
- Cerebrovascular accident
- Hyperkalaemia
- Ventricular aneurysm
- Left bundle branch block

Table III. Comparison of ECG changes associated with acute pericarditis, myocardial infarction and early repolarisation^(9,13).

ECG finding	Acute pericarditis	Myocardial infarction	Early repolarisation
ST-segment shape	Concave upward	Convex upward	Concave upward
Q waves	Absent	Present	Absent
Reciprocal ST-segment changes	Absent	Present	Absent
Location of ST-segment elevation	Limb and precordial leads	Area of involved artery	Precordial leads
ST/T ratio in lead V6	>0.25	NA	<0.25
Loss of R-wave voltage	Absent	Present	Absent
PR-segment depression	Present	Absent	Absent

Table IV. ECG changes in acute pericarditis: the four stages^(9,11-13).

Stage	Timing	ECG changes
1	First few days (up to two weeks)	<ul style="list-style-type: none"> • Diffuse concave upward ST segment elevation in leads I, II, aVF and V2 - V6 without reciprocal ST segment depression • ST segment elevation is higher in lead II than lead III with ST segment depression in aVR or V1 • PR segment depression best seen in all leads except aVR and V1⁽⁹⁾ indicative of subepicardial atrial injury • PR segment elevation seen in aVR is characteristic⁽¹⁴⁾ • Low voltages in leads
2	Days to weeks	<ul style="list-style-type: none"> • ST segments return to baseline • T wave flattening
3	Second to third week	<ul style="list-style-type: none"> • T wave inversion
4	Weeks to months (up to three months)	<ul style="list-style-type: none"> • Gradual resolution of T wave inversion⁽¹⁵⁾

raised Troponin I levels in such patients^(19,20). Chest radiographs may be useful in detecting an enlarged cardiac silhouette which could reflect a large pericardial effusion. This would have to be confirmed via echocardiography. Routine pericardiocentesis, pericardial biopsy and pericardectomy are not routinely performed as they have a low diagnostic yield. These are reserved typically for therapeutic indications or rarely for diagnosis of patients with prolonged illness suspicious of tuberculosis⁽²¹⁾.

Idiopathic causes of pericarditis are self-limited and usually resolve within two to six weeks. Potential complications include recurrent pericarditis, cardiac tamponade and constrictive pericarditis. Besides treatment of the underlying aetiology, therapeutic measures involve pain relief and prevention of further inflammation with non-steroidal anti-inflammatory drugs (NSAIDs), bed rest and supportive treatment. Antibiotics are directed toward those with purulent or tuberculous pericarditis. Corticosteroids and immunosuppressant therapy are only reserved for patients whose symptoms are refractory to NSAIDs⁽⁷⁾.

ABSTRACT

A 25-year-old man presented at the emergency department with complaints of fever and chest pain. The electrocardiogram (ECG) showed concave ST segment elevation that was not confined to any arterial territory. There was PR segment elevation in lead aVR as well as PR segment depression in leads II, V5 and V6. This was consistent with pericarditis. The electrocardiographical changes associated with pericarditis are discussed. A second case of a 64-year-old man with uraemic pericarditis with similar ECG changes is illustrated.

Keywords: electrocardiographical changes, pericarditis, ST elevation, uraemic pericarditis

Singapore Med J 2005; 46(11):656-660

REFERENCES

1. Ross AM, Grauer SE. Acute pericarditis. Evaluation and treatment of infectious and other causes. *Postgrad Med* 2004; 115:67-70, 73-5.
2. Farraj RS, McCully RB, Oh JK, et al. Mycoplasma-associated pericarditis. *Mayo Clin Proc* 1997; 72:33-6.
3. Brook I. Pericarditis due to anaerobic bacteria. *Cardiology* 2002; 97:55-8.
4. Paz A, Potasman I. Mycoplasma – associated carditis: case reports and review. *Cardiology* 2002; 97:83-8.
5. de Meester A, Luwaert R, Chaudron JM. Symptomatic pericarditis after influenza vaccination: report of two cases. *Chest* 2000; 117:1803-5.
6. Gunukula SR, Spodick DH. Pericardial disease in renal patients. *Semin Nephrol* 2001; 21:52-6.
7. Aikat S, Ghaffari S. A review of pericardial diseases: clinical, ECG and hemodynamic features and management. *Cleve Clin J Med* 2000; 67:903-14.
8. Lowell BH. Pericardial diseases. In: *Heart Disease: a Textbook of Cardiovascular Medicine*. Philadelphia: WB Saunders, 1997: 1478-85.
9. Marinella MA. Electrocardiographic manifestations and differential diagnosis of acute pericarditis. *Am Fam Physician* 1998; 57:699-704.
10. Baljepally R, Spodick DH. PR-segment deviation as the initial electrocardiographic response in acute pericarditis. *Am J Cardiol* 1998; 81:1505-6.
11. Dehmer GJ, O'Meara JJ 3rd. Update on acute pericarditis. *Hosp Med* 1995; 31:39-44.
12. Chou TC. Pericarditis. In: *Electrocardiography in Clinical Practice*. 3rd Ed. Philadelphia: Saunders, 1991: 219-34.
13. Teo WS. Electrocardiographic case. Significance of raised ST segments? *Singapore Med J* 1992; 33: 296, 310.
14. Spodick DH. Diagnostic electrocardiographic sequences in acute pericarditis. Significance of PR segment and PR vector changes. *Circulation* 1973; 48:575-80.
15. Friedman HH. Pericarditis. In: *Diagnostic Electrocardiography and Vectorcardiography*. 3rd ed. New York: McGraw-Hill, 1985: 320-7.
16. Ginzton LE, Laks MM. The differential diagnosis of acute pericarditis from the normal variant: new electrocardiographic criteria. *Circulation* 1982; 65:1004-9.
17. Spodick DH. Differential characteristics of the electrocardiogram in early repolarisation and acute pericarditis. *N Engl J Med* 1976; 295:523-6.
18. Wanner WR, Schaal SF, Bashore TM, et al. Repolarization variant vs acute pericarditis. A prospective electrocardiographic and echocardiographic evaluation. *Chest* 1983; 83:180-4.
19. Brandt RR, Filzmaier K, Hanrath P. Circulating cardiac troponin I in acute pericarditis. *Am J Cardiol* 2001; 87:1326-8.
20. Bonnefoy E, Godon P, Kirkorian G, et al. Serum cardiac troponin I and ST-segment elevation in patients with acute pericarditis. *Eur Heart J* 2000; 21:832-6.
21. Permyer-Miralda G, Sagrista-Sauleda J, Soler-Soler J. Primary acute pericardial disease: a prospective series of 231 consecutive patients. *Am J Cardiol* 1985; 56:623-30.

SINGAPORE MEDICAL COUNCIL CATEGORY 3B CME PROGRAMME

Multiple Choice Questions (Code SMJ 200511B)

	True	False
Question 1. Common causes of pericarditis include:		
(a) Viral infections such as Coxsackie virus A and B.	<input type="checkbox"/>	<input type="checkbox"/>
(b) Tuberculosis.	<input type="checkbox"/>	<input type="checkbox"/>
(c) Neoplastic.	<input type="checkbox"/>	<input type="checkbox"/>
(d) Idiopathic.	<input type="checkbox"/>	<input type="checkbox"/>
Question 2. The following statements regarding pericarditis are true:		
(a) Pericarditis is characterised by chest pain that is worse on sitting up and leaning forward.	<input type="checkbox"/>	<input type="checkbox"/>
(b) The pericardial rub is the pathognomic finding of pericarditis.	<input type="checkbox"/>	<input type="checkbox"/>
(c) ST segment depression is the most sensitive finding in acute pericarditis.	<input type="checkbox"/>	<input type="checkbox"/>
(d) 90% of cases of pericarditis have an abnormal ECG.	<input type="checkbox"/>	<input type="checkbox"/>
Question 3. Differential diagnosis of pericarditis on ECG include:		
(a) Non- ST segment elevation myocardial infarction.	<input type="checkbox"/>	<input type="checkbox"/>
(b) Pulmonary embolism.	<input type="checkbox"/>	<input type="checkbox"/>
(c) Left bundle branch block.	<input type="checkbox"/>	<input type="checkbox"/>
(d) Ventricular aneurysm.	<input type="checkbox"/>	<input type="checkbox"/>
Question 4. The four stages of acute pericarditis include:		
(a) Concave upward ST segment elevation.	<input type="checkbox"/>	<input type="checkbox"/>
(b) Return of ST segments with T wave flattening.	<input type="checkbox"/>	<input type="checkbox"/>
(c) Peaked T waves.	<input type="checkbox"/>	<input type="checkbox"/>
(d) Return of T waves to baseline.	<input type="checkbox"/>	<input type="checkbox"/>
Question 5. Other markers that may be elevated in acute pericarditis include:		
(a) C-reactive protein.	<input type="checkbox"/>	<input type="checkbox"/>
(b) Leukocyte count.	<input type="checkbox"/>	<input type="checkbox"/>
(c) Troponin I.	<input type="checkbox"/>	<input type="checkbox"/>
(d) Erythrocyte sedimentation rate.	<input type="checkbox"/>	<input type="checkbox"/>

Doctor's particulars:

Name in full: _____

MCR number: _____ Specialty: _____

Email address: _____

Submission instructions:**A. Using this answer form**

1. Photocopy this answer form.
2. Indicate your responses by marking the "True" or "False" box
3. Fill in your professional particulars.
4. Post the answer form to the SMJ at 2 College Road, Singapore 169850.

B. Electronic submission

1. Log on at the SMJ website: URL <<http://www.sma.org.sg/cme/smj>> and select the appropriate set of questions.
2. Select your answers and provide your name, email address and MCR number. Click on "Submit answers" to submit.

Deadline for submission: (November 2005 SMJ 3B CME programme): 12 noon, 25 December 2005**Results:**

1. Answers will be published in the SMJ January 2006 issue.
2. The MCR numbers of successful candidates will be posted online at <<http://www.sma.org.sg/cme/smj>> by 20 January 2006.
3. All online submissions will receive an automatic email acknowledgment.
3. Passing mark is 60%. No mark will be deducted for incorrect answers.
4. The SMJ editorial office will submit the list of successful candidates to the Singapore Medical Council.