

Unusual Rectal Foreign Body: Treatment Using Argon-Beam Coagulation

A 44-year-old homosexual man had introduced a large, cellophane-covered green apple into the rectum 24 hours before admission, probably with the aim of sexual stimulation. Spontaneous defecation was subsequently not possible. The sigmoidoscopy showed the intact covered apple within the rectum (Figure 1). Since it was not possible to remove the apple with the ordinary endoscopic instruments, the surface of the solid foreign body was treated with the argon-beam coagulator (Arco-MC, Söring, Quickborn, Germany; level 3, gas flow 4 l/min, power 110 W), melting down the apple continuously. The cellophane cover was soon

removed using a foreign-body removal forceps. With progressive size reduction, several attempts to catch the remainder with a sling failed. After two and a half hours of intermittent coagulation, the size of the apple had been reduced by more than 50%. Several parts were additionally removed with the foreign-body forceps, and a remnant with a relatively soft consistency was finally left (Figure 2), which was easily passed with defecation the following morning.

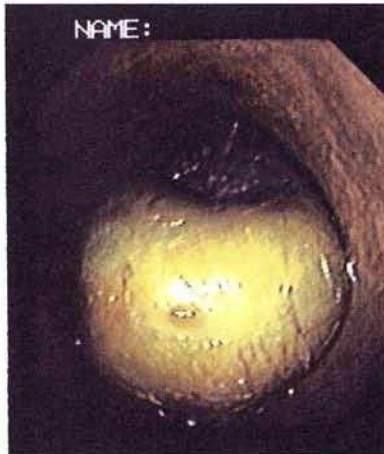


Figure 1: Endoscopic view of the cellophane-covered green apple within the rectum.

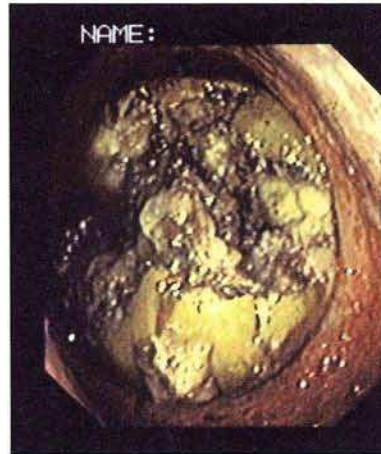


Figure 2: Soft remnant of the apple after argon-beam coagulation.

In argon-beam coagulation, high-frequency alternating current is applied without contact with the target object (1,2). The case described shows that the argon beamer can even be used to coagulate large organic foreign bodies.

J. Glaser, T. Hack, M. Rüksam
 Dept. of Internal Medicine and Gastroenterology, District Hospital, Fulda, Germany

Corresponding Author
 J. Glaser, M.D.
 Abteilung für Allgemeine Innere Medizin
 und Gastroenterologie
 Herz-Jesu-Krankenhaus
 Buttlarstrasse 74
 36039 Fulda
 Germany
 Fax: +49-661-1 53 09

References

1. Johanns W, Jakobeit C, Luis W, et al. Kontaktlose Argon-Gas-Koagulation in der flexiblen Endoskopie des Gastrointestinaltrakts: In-vitro-Untersuchungen und erste klinische Erfahrungen. *Z Gastroenterol* 1995; 33: 694–700.
2. Farin G, Grund KE. Technology of argon plasma coagulation, with particular regard to endoscopic applications. *Endosc Surg* 1994; 2: 71–7.