

# 3

## The Genitourinary System

*Radionuclide renal scintigraphy provides important functional data to assist in the diagnosis and management of patients with a variety of suspected genitourinary problems. Not all renal scans, however, are the same; there is a choice of five different renal radiopharmaceuticals and several imaging protocols. To make sure the patient receives the optimal radiopharmaceutical and the most appropriate test procedure, it is essential to clearly specify the clinical question when referring a patient for renal scintigraphy.*

### SCANS AND PRIMARY CLINICAL INDICATIONS

- |   |         |
|---|---------|
| I. Basic renogram   | Page 47 |
| <ul style="list-style-type: none"><li>● To assess renal function and urodynamics</li><li>● To determine what percent of the total renal function is contributed by each kidney</li></ul>                                  |         |
| II. Diuresis renogram   | Page 52 |
| <ul style="list-style-type: none"><li>● To diagnose or exclude urinary tract obstruction</li></ul>  |         |
| III. Angiotension-converting enzyme (ACE)-inhibition (renovascular hypertension or captopril) renogram  | Page 56 |
| <ul style="list-style-type: none"><li>● To diagnose or exclude renovascular hypertension</li></ul>  |         |
| IV. Renal transplant scintigraphy   | Page 61 |
| <ul style="list-style-type: none"><li>● To evaluate arterial flow and function</li><li>● To help diagnose rejection and acute tubular necrosis</li><li>● To detect urinary leak, infarct or outflow obstruction</li></ul> |         |

V. Renal cortical scintigraphy	Page 62
● To detect or exclude pyelonephritis	
● To determine what percent of the total renal function is contributed by each kidney	
VI. Testicular scan	Page 63
● To distinguish acute torsion from an inflammatory process (epididymitis)	
VII. Radionuclide cystography	Page 64
● To detect, quantitate and follow reflux	
● To evaluate asymptomatic siblings of children with reflux	

## CLINICAL QUESTIONS

### Obstruction

1. Ultrasound or CT shows a dilated collecting system. Is there ureteral obstruction?	Page 66
2. A patient with previous obstruction has recurrent symptoms. Has obstruction recurred?	Page 66
3. Has surgery successfully relieved a documented obstruction?	Page 66
4. Does a patient presenting with flank pain have acute renal colic? If so, can he be managed conservatively?	Page 67
5. Antenatal sonography shows a dilated pelvis and ureter. Is there obstruction or a loss of renal function?	Page 67

### Renovascular hypertension

6. Does a hypertensive patient have renovascular hypertension?	Page 67
--	---------

### Kidney function

7. What percent does each kidney contribute to total function?	Page 69
8. What is the global (total) renal function?	Page 69
9. Is the global (total) renal function stable compared with the most recent measurement?	Page 69
10. A patient presents with acute renal failure. What is the cause?	Page 70

### Bladder outlet obstruction

11. Is there bladder outlet obstruction or bladder dysfunction?	Page 70
12. What is the postvoid bladder residual?	Page 70

### Renal transplant

13. Is the transplant functioning normally?	Page 70
14. Is there a leak? Is there obstruction?	Page 70
15. What is the cause of a poorly functioning renal transplant or rising creatinine?	Page 70

### Testicular torsion

16. Does a patient presenting with acute scrotal pain have testicular torsion?	Page 71
--	---------

## Congenital abnormalities

17. Is there congenital abnormality? How well is the kidney in question functioning? Page 71

## Pyelonephritis

18. Does a child presenting with an acute urinary tract infection have acute pyelonephritis? Page 71

## Ureteral reflux

19. Does the patient have ureteral reflux? Page 72

20. Is reflux present in an asymptomatic sibling of a child with reflux? Page 72

21. Has previously documented ureteral reflux resolved or diminished? Page 72

## Kidney morphology

22. Is a questionable mass on an intravenous urogram a column of Bertin? Page 73

## Trauma

23. Is there a urine leak? Page 73

24. Is the kidney functioning normally? Page 73

25. Is a traumatized kidney recovering its function? Page 73

## PATIENT INFORMATION

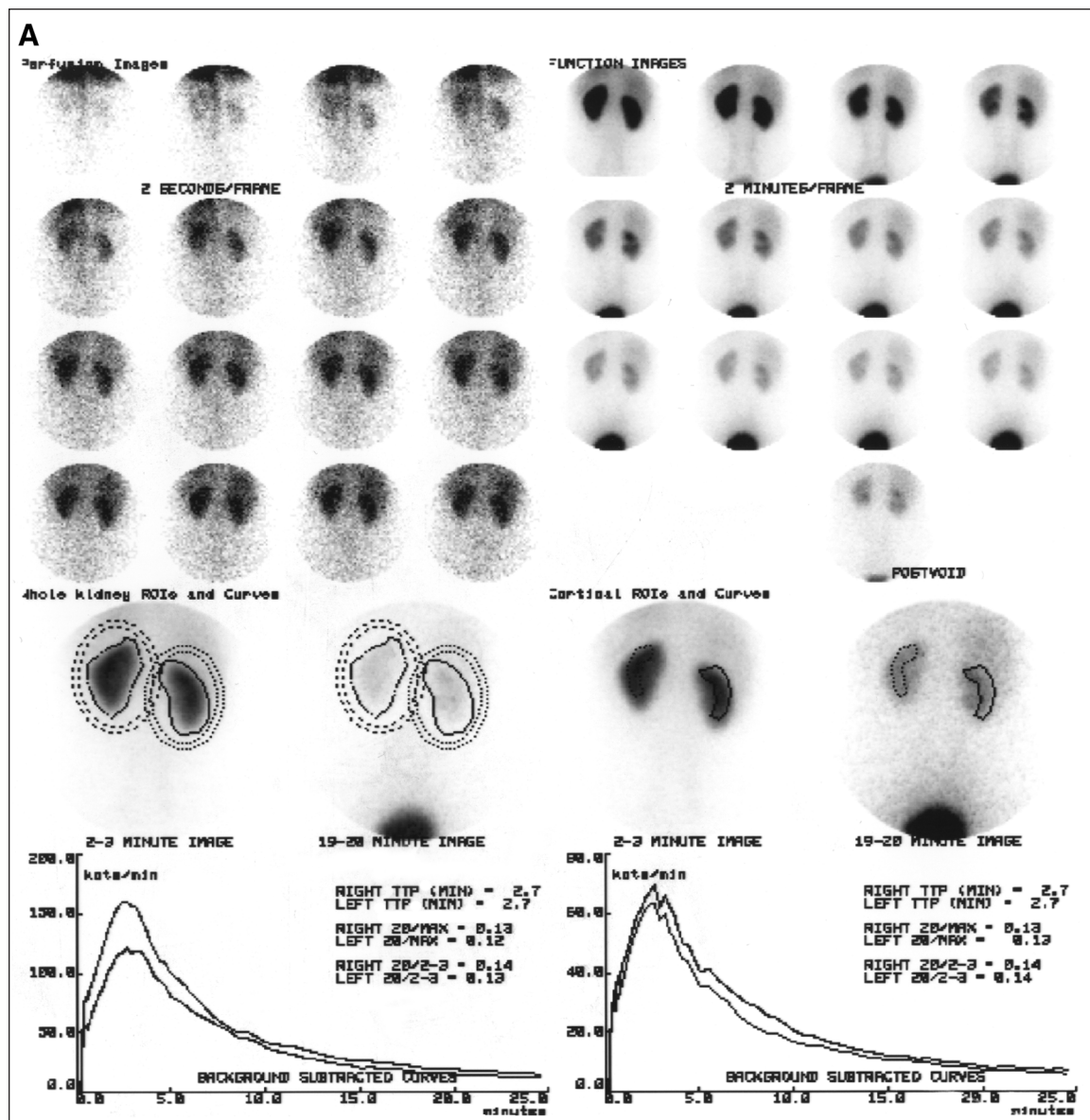
I. Radionuclide renogram Page 74

# SCANS

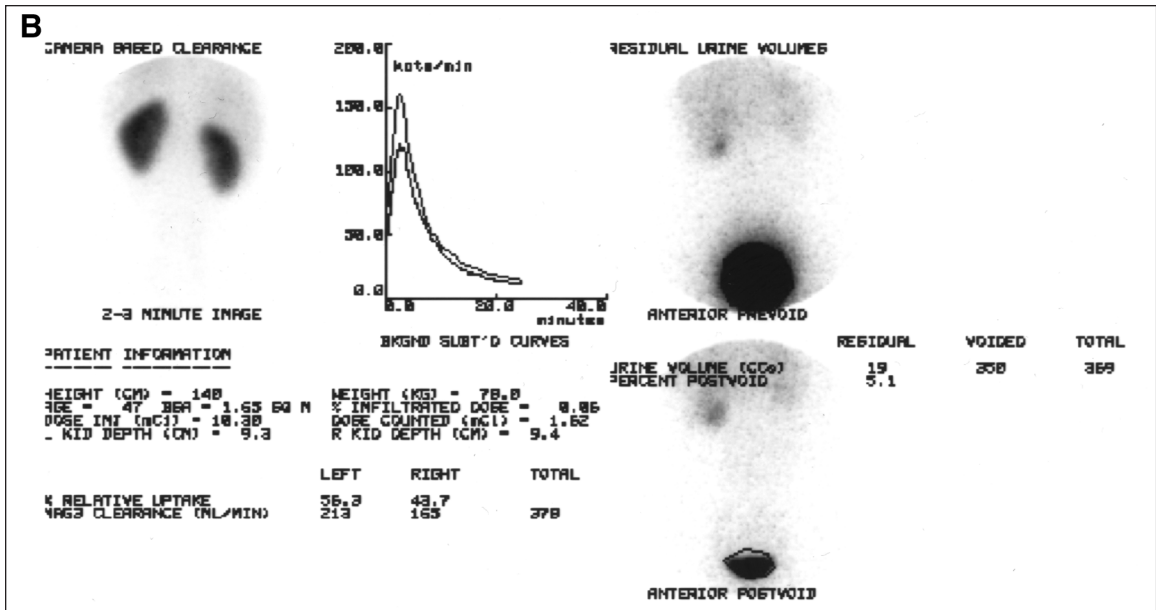
## I. BASIC RENOGRAM

### A. Background

The basic renogram is the backbone of the more advanced procedures, such as the diuresis and ACE-inhibition renograms. The basic renogram includes a series of images of the kidney as the tracer is removed from the blood, transits the kidney and enters the bladder (Fig. 1). Renogram curves quantitating the tracer movement through each kidney are typically generated; these curves complement the images and are used in the interpretation of the study. At a minimum, the basic renogram also should provide a measurement of relative renal function. In some institutions, a measurement of total renal function and additional quantitative data are provided to facilitate interpretation of the study. The integration of the clinical presentation with the images and physiologic data derived from the scan often can provide important diagnostic and prognostic information for patients with known or suspected renal disease. The more advanced procedures (diuresis and ACE-inhibition renograms) are modifications of the basic renogram to answer specific questions.



**Figure 1A.** Normal renal scan. The patient received an intravenous injection of 10.3 mCi (381 MBq) of  $^{99m}\text{Tc}$ -MAG3. The images were acquired with the patient's back facing the camera. The left kidney is on the reader's left. Upper left panel. Sixteen sequential 2-sec dynamic flow images are presented showing the initial bolus of activity traveling down the abdominal aorta into both kidneys. Upper right panel. Twelve sequential 2-min images showing the rapid MAG3 uptake by the kidneys at 2 min. Ureters can be faintly visualized, and the bladder first appears on the 2–4 min image. A postvoid image also is shown at the bottom of this panel. Lower left panel. The regions of interest used to correct for background and used to generate the renogram curves are displayed on the 2- to 3-min image and on the 19- to 20-min image. The curves peak by 5 min and show rapid washout of the tracer from the kidneys. The time to peak height for both kidneys is 2.7 min. The 20 min/maximum and 20 min/2–3 min activity ratios also are displayed and are normal. Lower right panel. The regions of interest used to generate the cortical renogram curves are displayed. The cortical quantitative data also are displayed. Because the patient was well hydrated and there was no significant retention of the tracer in the collecting system, the quantitative data for the cortical and whole-kidney renogram curves are essentially identical.



**Figure 1B.** Left panel. This panel displays quality-control data, including the patient's height, weight, dose injected and infiltrated dose. There was no significant infiltration—0.06% of the injected dose. The panel also shows the relative uptake—56.3% in the left kidney and 43.7% in the right kidney—as well as the individual and total MAG3 clearance using a camera-based technique. The MAG3 clearance was 378 ml/min, which is normal. Right panel. The panel displays the prevoid and postvoid bladder images used to calculate residual volume. The patient voided 350 ml of urine and had a residual urine volume of 5% or 19 ml.

## B. Radiopharmaceuticals

1. *Technetium-99m-mercaptoacetyl triglycine (MAG3)*. MAG3 is the most commonly used renal radiopharmaceutical in the United States. After intravenous administration, about 40–50% of the MAG3 in the blood is extracted by the proximal tubules with each pass through the kidneys; the proximal tubules then secrete the MAG3 into the tubular lumen. MAG3 has a much higher extraction fraction than DTPA (see below); consequently, it is a better diagnostic agent than <sup>99m</sup>Tc-DTPA, particularly in neonates, in patients with impaired function and in patients with suspected obstruction. The MAG3 clearance is highly correlated with the effective renal plasma flow (ERPF), and the MAG3 clearance can be used as an independent measure of renal function.

2. *Technetium-99m-diethylenetriaminepentaacetic acid (DTPA)*. DTPA is the second most commonly used renal radiopharmaceutical in the United States primarily because it is the least expensive. Technetium-99m-DTPA is filtered by the glomerulus and may be used to measure the glomerular filtration rate (GFR). The extraction fraction of <sup>99m</sup>Tc-DTPA is approximately 20%, about half that of MAG3.

3. *Iodine-131-orthoiodohippurate (OIH)*. OIH is extracted primarily by the proximal tubules although a small component is filtered. The extraction fraction of

OIH is 80% in normal individuals, and the OIH clearance often is called the ERPF. The typical adult dose is 300  $\mu\text{Ci}$  (11.1 MBq) but  $^{131}\text{I}$ -OIH is used rarely in the United States because of suboptimal imaging characteristics of  $^{131}\text{I}$  and its beta emission. The beta emission from  $^{131}\text{I}$  can lead to a relatively high radiation dose to the kidney and thyroid, particularly if a patient has obstruction or impaired renal function.

### C. How the study is performed

The patient lies in the supine position and the usual adult dose of 1–10 mCi (37–370 MBq) of MAG3 or DTPA is injected into a peripheral vein. Images are acquired dynamically for 20–30 min; post-void views may be obtained at the conclusion of the study. The technologist must then process the study on the computer to generate the renogram curve and various qualitative and quantitative indices.

*Renal clearance measurements.* Advances in nuclear medicine methodologies provide the opportunity to assess renal function (GFR, ERPF and MAG3 clearance) using either plasma sample clearances or camera-based methods. Plasma sample clearances involve blood sampling. Camera-based techniques do not require blood or urine samples to measure GFR, ERPF or a MAG3 clearance, but these measurements are not considered to be as accurate as plasma sample techniques and require specialized software (See F2 below, availability of clearance measurements under Potential Problems).

### D. Patient preparation

The patient should be well hydrated when he/she comes to the nuclear medicine department for a basic renogram; there are no medication or dietary restrictions. (For diuresis or ACE-inhibition renography, there are diet and medication restrictions [see Patient Preparation for Diuresis and ACE-Inhibition Renograms, IID and IIID, respectively].)

### E. Understanding the report

The report sent to the referring physician may include a description of the renogram curve and various quantitative indices of uptake and excretion. These data are integrated with the clinical presentation and other imaging data to provide the final impression.

The renogram curve is the time activity curve of the tracer as it transits the kidney; this curve is displayed routinely along with sequential timed images of the kidneys. In some institutions, two sets of renogram curves are generated: (a) a renogram curve from a region of interest (ROI) over the whole kidney and (b) a renogram curve from an ROI over the renal cortex (Fig. 1). As renal function deteriorates, the renogram curve often will flatten, reflecting delayed uptake and delayed washout.

The relative uptake of the radiopharmaceutical provides a measure of relative renal function and should be described in the report because it is an important clinical parameter. The report also may refer to the following indices:

1.  $T_{max}$  is the time to peak height of the renogram curve. MAG3, DTPA and OIH renograms normally peak by 5 min after injection and reach half peak height by about 15 min after injection; however, physiologic retention of the tracer in the renal calyces or pelvis can alter the shape of the renogram curve and lead to prolonged values for the time to peak, 20 min/max ratio and half-life ( $T_{1/2}$ ).

2. The *20 min/max activity ratio* is the ratio of the activity at 20 min to the maximum (peak) activity and provides an index of the transit time and parenchymal function. With the tubular agents, it is an especially useful index in the detection of renovascular hypertension.

3.  $T_{1/2}$  refers to the time it takes for the activity in the kidney to fall to 50% of its maximum value. This measurement is most useful after diuretic administration in patients with suspected obstruction (see below).

4. The *20 min/2–3 min ratio* relates the rate of washout (activity at 20 min) to the renal function (activity at 2–3 min); it is used in monitoring renal transplants and may prove to be useful in patients with suspected obstruction. Renogram curves generated from cortical ROIs (ROIs placed over the renal parenchyma that avoid the collecting system) and the indices generated from the cortical renogram curves may provide a clearer index of parenchymal function (Fig. 1).

## F. Potential problems

1. *Hydration.* Occasionally there is nonspecific retention in the renal pelvis or calyces that distorts the whole kidney curve, whereas the cortical or parenchymal renogram curve is normal. Mild dehydration, for example, can cause calyceal or pelvic retention. This potential problem can be minimized by instructing the patient to be well hydrated when he/she comes for the study.

2. *Availability of clearance measurements.* Plasma sample clearances are not available in most nuclear medicine departments in the United States. Plasma sample clearance methods require meticulous attention to detail and are subject to error if performed infrequently or by inexperienced personnel. Validated camera-based clearance measurements require specialized software and are not available in many institutions. Camera-based clearances are not as accurate as properly performed plasma sample clearances, but they appear to be equally reproducible. Often a precise measurement of renal function is not as important as being able to reliably determine if the renal function is improving, remaining the same or deteriorating.



3. *Availability of correlative imaging studies.* Interpretation of the renal scan may be less useful if the interpreting physician does not have access to any correlative imaging studies of the kidney that may have been obtained.

## II. DIURESIS RENOGRAM

### A. Background

Obstruction usually results in a loss of function by the affected kidney unless it is an acute process. The purpose of intervention is to preserve renal function. Diuresis renography is a noninvasive test and the only study that can evaluate renal function and urodynamics in a single test. Urine outflow obstruction may be suspected based on clinical findings, the incidental detection of a dilated renal collecting system, or the previous diagnosis of obstruction in a patient referred for follow-up. Obstruction to urinary outflow may lead to obstructive uropathy (dilation of the calyces, pelvis or ureters) and obstructive nephropathy (damage to the kidney itself). Diuresis radionuclide renography is the noninvasive equivalent of a Whitaker test. The Whitaker test (pressure perfusion flow study) is an invasive nonphysiologic study that requires a percutaneous nephrostomy; the diagnosis of obstruction is based on an abnormal rise in pressure after perfusion of fluid directly into the dilated system. Because of its invasive nature, the use of the Whitaker test tends to be reserved for special situations. Diuretic renography is based on a high endogenous urine flow rate stimulated by the administration of furosemide. Instead of a rise in pressure, the diagnosis of obstruction is based on an abnormally slow washout of the tracer from a dilated collecting system. Furthermore, diuresis renography is widely available.

### B. Radiopharmaceuticals

MAG3 is preferred over DTPA for diuresis renography (See IB above, Radiopharmaceuticals). The use of MAG3 results in fewer false-positive or indeterminate studies than DTPA, particularly in neonates or in patients with impaired function. Although it is not the optimal agent, DTPA is sometimes used because it is less expensive than MAG3.

### C. How the study is performed

The study usually consists of a basic renogram followed by the intravenous administration of furosemide and another 20–30 min of imaging. Typically, the scan takes no longer than 1 hr to complete. In equivocal cases, some investigators recommend repeating the study with the “F – 15 renogram,” in which the furosemide is administered 15 min before the injection of the tracer such that the patient is in a state of maximum diuresis at the time of MAG3 or DTPA administration. In selected cases, an equivocal study will become clearly normal or abnormal. Although furosemide will not affect the relative function measurements, many clinicians prefer to visualize the baseline urodynamics and do not make the “F – 15 renogram” the routine procedure.



## D. Patient preparation

The patient should be well hydrated as for the basic renogram. Some physicians withhold diuretics for 24 hr before the study to minimize the chance of the patient arriving for the study dehydrated (see Patient Information for Radionuclide Renography).

## E. Understanding the report

The report contains the same information as the basic renogram report. In addition, the report comments on the washout of the tracer after furosemide administration, may provide the  $T_{1/2}$  measurement and states whether the kidney is obstructed or nonobstructed or if the study is indeterminate (see Potential Problems, below).

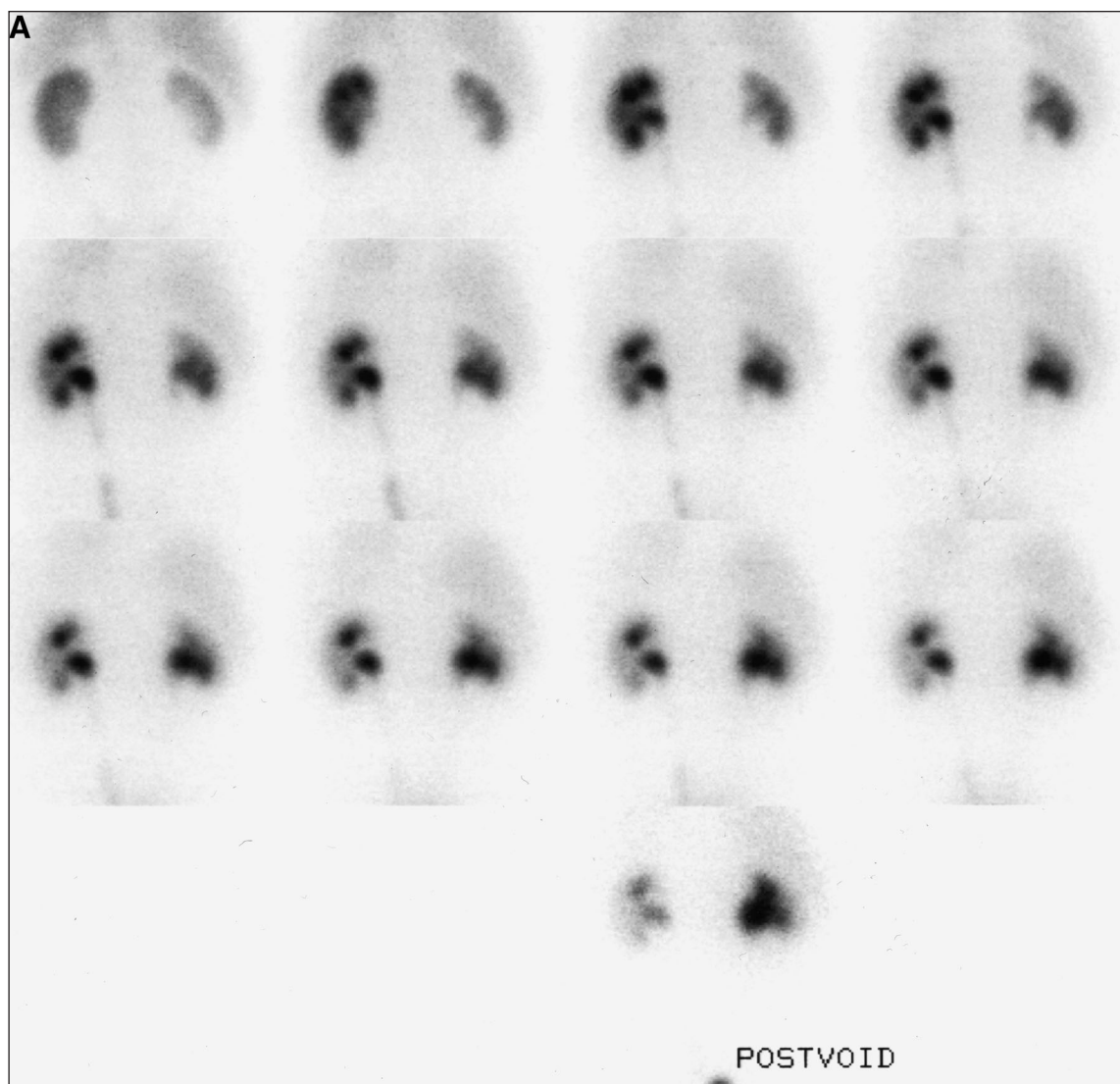
*Interpretation of the test.* Interpretation of the test is based on the rate of washout of the tracer from the dilated collecting system. If there is prompt renal uptake of the tracer and prompt washout from the upper urinary tract collecting system, there is no obstruction (Fig. 2). Rapid washout of the tracer may occur before furosemide is administered, and depending on the local protocol, furosemide may not be necessary. The response to furosemide usually begins 2–4 min after injection, but the maximum diuresis usually is not reached until 15 min after injection. Some experts interpret the study based on a visual analysis of the washout curve; others, however, attempt to quantitate the rate of washout by measuring the  $T_{1/2}$  (time for the activity in the collecting system to fall to 50% of its original value). Prompt clearance of the tracer from the renal pelvis with a  $T_{1/2} < 10$  min is a normal response and excludes obstruction, and some authors will accept a  $T_{1/2} < 15$  min as normal. Values between 15 and 20 min are often considered to be indeterminate, and a  $T_{1/2} > 20$  min is considered suspicious for obstruction (see F1, below).

## F. Potential problems

1.  $T_{1/2}$ . The  $T_{1/2}$  not only depends on the presence or absence of obstruction but also on the level of function of the kidney in question, the placement of the ROI around the whole kidney or just around the dilated collecting system, the radiopharmaceutical used in the study, the delay between administering the tracer and administering furosemide, the method of hydration, the presence or absence of a bladder catheter, the dose of furosemide and the interval used to make the measurement. For the reasons just outlined, measurement of the  $T_{1/2}$  has not been standardized, and an isolated  $T_{1/2}$  value should not be the sole criterion for determining the presence or absence of obstruction; the  $T_{1/2}$  must be interpreted in the context of the whole set of images, curves and data analysis.

2. *Equivocal or false-positive studies.* Equivocal or false-positive studies may result from the following:

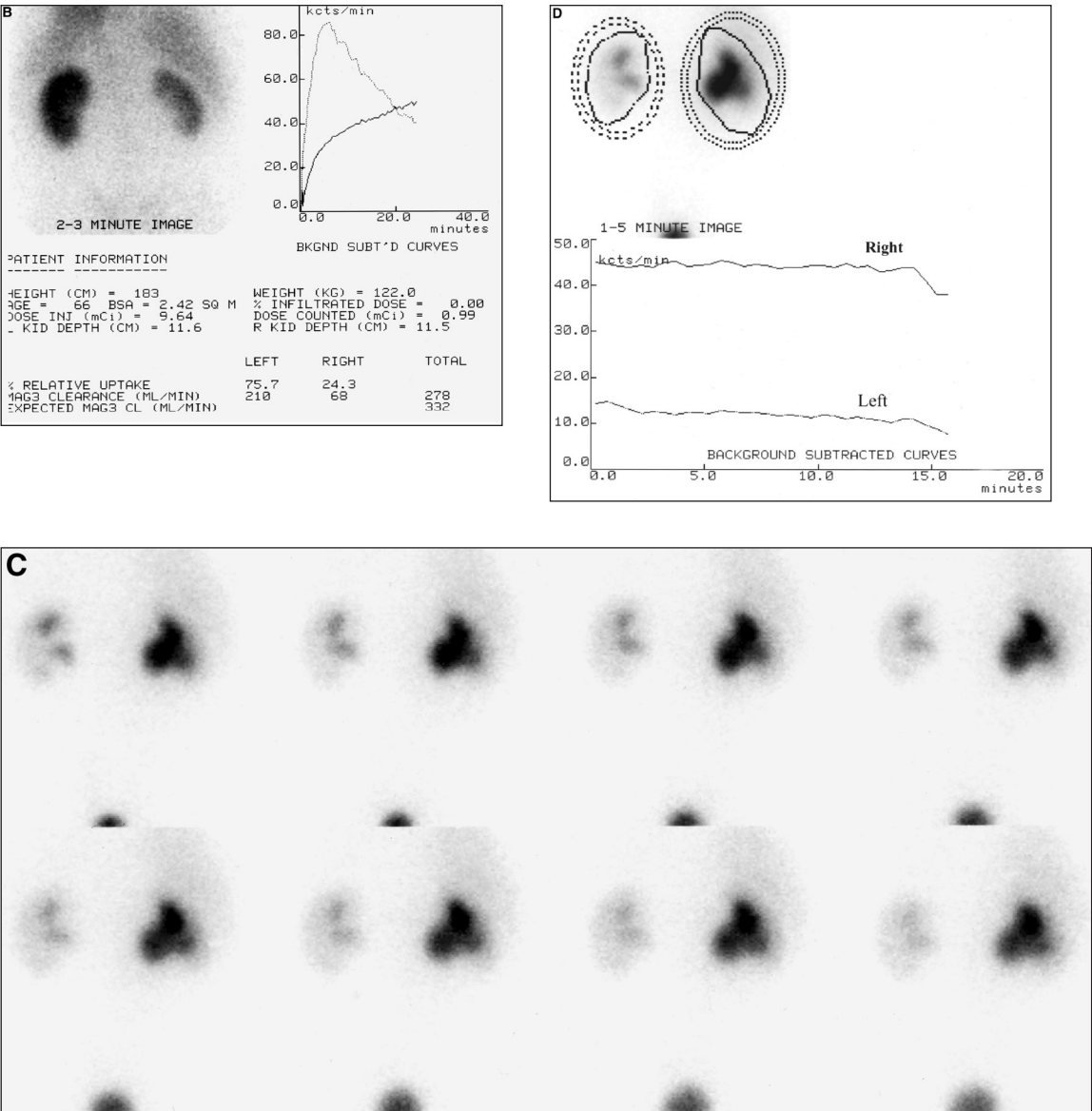
- 1) The failure of the kidney under investigation to respond to furosemide. Urine flow rates decrease as renal function decreases,



**Figure 2A.** A patient presented with a dilatated renal pelvis and possible obstruction of the right kidney. Sequential 2-min images show prompt uptake in both kidneys with marked retention in the right renal pelvis. There was no significant drainage from the right pelvis when the patient voided.

but urine flow rates as high as 4 ml/min have been reported from kidneys with creatinine clearances 15–20% of normal. This flow rate often makes it possible to obtain a diagnostic test even in patients with poor renal function, particularly if the renal pelvis is not massively enlarged.

- 2) *Slow washout of the tracer due to a grossly dilatated collecting system.* A greater problem than reduced function is a grossly dilatated



**Figure 2B-D.** (B) This figure displays the 2- to 3-min image, whole-kidney renogram curves and quality-control and functional data. The renogram curve of the left kidney peaks by 5 min and shows a normal washout pattern. The renogram curve of the right kidney is continuously rising and is abnormal. The left kidney contributes approximately 76% of the total renal function, whereas the right kidney contributes 24%. The total MAG3 clearance is 278 ml/min, which is normal. (C) Because of the persistence of MAG3 activity in the right renal pelvis, the patient received 40 mg of furosemide and additional 2-min images were obtained. There is no significant washout of tracer from the right kidney; the tracer has already largely washed out of the left kidney. (D) Regions of interest were assigned over each kidney, and background regions were automatically assigned. Both curves are relatively flat with a  $T_{1/2} > 20$  min. The scan pattern, functional data, washout curves and  $T_{1/2}$  show obstruction of the right kidney. The prolonged  $T_{1/2}$  of the left kidney reflects the fact that the tracer was largely eliminated from the kidney before the furosemide portion of the study was begun.

collecting system. For any given rate of urine flow, the rate of tracer washout decreases as the size of the dilated collecting system increases; consequently, a dilated renal collecting system may result in a prolonged  $T_{1/2}$ , even in the absence of obstruction.

- 3) *Slow washout of the tracer due to a distended bladder.* A distended bladder may slow washout of the tracer from the renal collecting system. Many institutions have the patient void before furosemide administration. Patients usually are upright to void, and gravity can facilitate drainage from a dilated but nonobstructed collecting system.

### III. ACE INHIBITION (RENOVASCULAR HYPERTENSION OR CAPTOPRIL) RENOGRAM

#### A. Background

Renovascular hypertension is estimated to affect <3% of the unselected hypertensive population and up to 30% of patients referred to a subspecialty center for problematic hypertension. Renovascular hypertension is defined as an elevated blood pressure caused by renal hypoperfusion, usually due to anatomic renal artery stenosis and activation of the renin-angiotensin system. Advances in percutaneous renal angioplasty, renal artery stenting and surgical techniques have renewed interest in developing better tests for identifying patients with potentially correctable hypertension or renal dysfunction secondary to renovascular disease.

*1. Renovascular hypertension versus renal artery stenosis.* It is important to distinguish between renovascular hypertension and the presence of anatomic renal artery stenosis. Renal artery stenosis may be a consequence of hypertension rather than its cause and is common even in normotensive individuals over age 50. Renal artery stenosis may be an incidental finding in a hypertensive patient. Revascularization is expensive, is not without risk and may not result in any improvement in blood pressure in as many as 30–40% of patients undergoing the procedure. An ACE-inhibition renogram interpreted as high probability for renovascular hypertension carries a high predictive value (90%) that renal artery stenosis is present and that the hypertension will be ameliorated or cured by revascularization.

*2. Mechanism of an abnormal scan after ACE inhibition.* Renovascular hypertension is dependent on renin secretion from the juxtaglomerular apparatus of the underperfused, stenotic kidney. Renin converts angiotensinogen to angiotensin I, which is in turn converted to angiotensin II by ACE. Angiotensin II causes preferential vasoconstriction of the postglomerular (efferent) arteriole. Vasoconstriction of the efferent arteriole increases resistance to flow and can maintain the transglomerular pressure gradient and, thereby, maintain GFR

even in the presence of a reduced perfusion pressure. Within the stenotic kidney, ACE inhibition reduces the angiotensin II dependent constriction of the postglomerular arteriole, decreases the resistance to flow and thereby lowers the transcapillary pressure gradient maintaining GFR. The resulting decrease in glomerular filtration of the stenotic kidney can be detected noninvasively with ACE-inhibition renography by either a change in relative function or retention of the tracer in the renal tubules due to decreased GFR and decreased flow of the filtrate through the tubules (Fig. 3).

## B. Radiopharmaceuticals

Technetium-99m-MAG3 is preferred in azotemic patients. In patients with normal function, MAG3 and DTPA are equally acceptable. (See IB, Basic Renogram Pharmaceuticals, above).

## C. How the study is performed

ACE-inhibition renography may be performed using oral captopril or intravenous enalaprilat (Vasotec) as the ACE inhibitor. A normal renogram that becomes abnormal in the left or right kidney after ACE inhibition is highly specific for renovascular hypertension. Two diagnostic approaches can be taken; the choice depends on local factors.

*1. Basic renogram followed by an ACE inhibitor (oral captopril or intravenous enalaprilat) and a repeat renogram.* This option provides the most definitive information but it requires two renograms and requires the patient to spend 2–3 hr in the nuclear medicine department.

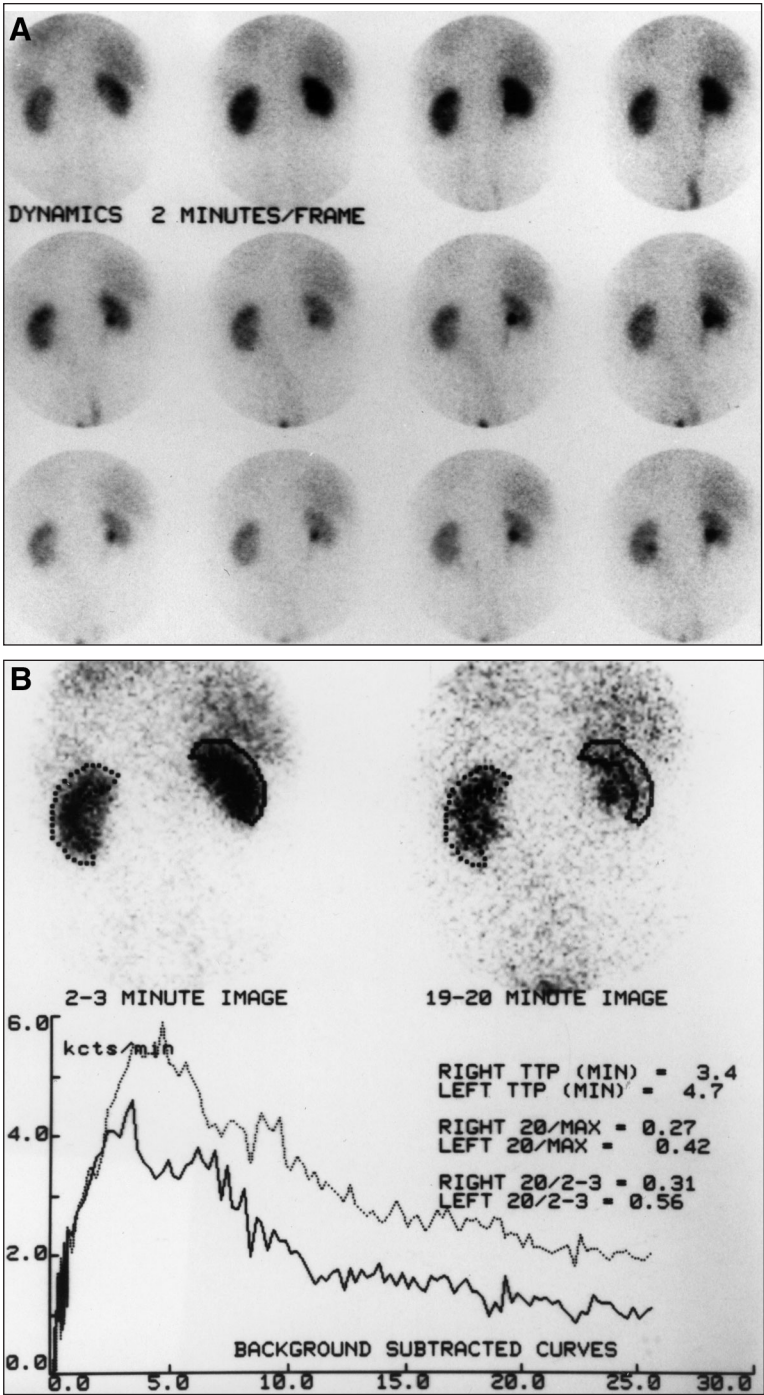
*2. The baseline renogram is omitted, and the patient receives the ACE inhibitor followed by a renogram.* If the ACE-inhibition renogram is normal, the study is low probability for renovascular hypertension, and there is no need for the baseline renogram. If it is abnormal, the patient needs to return another day for the baseline study to maximize specificity; alternatively, high-risk patients with an abnormal study may be referred for angiography. This option provides the same diagnostic information as option 1 above if the study is normal, but it is less specific if the study is abnormal; however, only one renogram is required, and the patient spends only 1–2 hr in the department.

## D. Patient preparation

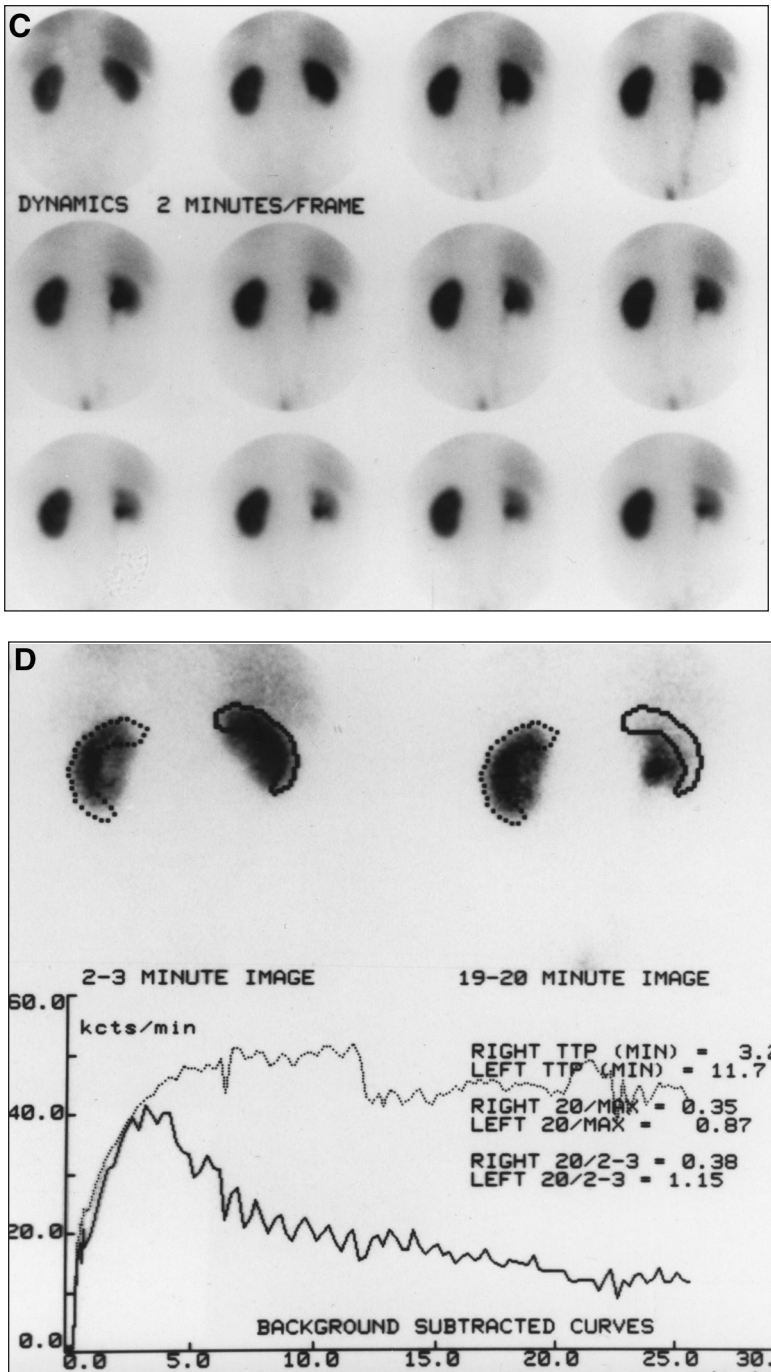
*1. Hydration.* The patient should be instructed to be well hydrated when he/she arrives for the examination.

*2. No food before captopril renography.* If oral captopril is to be given, the patient should be instructed not to eat any solids after midnight before the examination. Food may delay gastric emptying and interfere with the absorption of captopril. The instructions should clearly distinguish between avoiding solid food and the importance of drinking water.





**Figure 3.** A 78-yr-old man presented with dizziness and was found to have a creatinine of 1.7 mg/dl and blood pressure of 230/120. He underwent baseline scintigraphy with 1.2 mCi of  $^{99m}\text{Tc}$ -MAG3. (A) Images obtained at 2-min intervals for 24 min show prompt uptake and washout of the tracer. The relative uptake at 2–3 min was 52% in the right kidney and 48% in the left kidney. (B) The cortical renogram curves, however, show that the left kidney had an elevated 20 min/max ratio of 0.42, which is more than three standard deviations above normal.



**Figure 3 (continued).** (C) After completion of the baseline study, the patient was given 50 mg of captopril. Approximately 1.5 hr later,  $^{99m}\text{Tc}$ -MAG3 scintigraphy was performed with 9.3 mCi. Sequential 2-min images show cortical retention in the left kidney; however, the right kidney appears normal. (D) The left cortical renogram curve is markedly abnormal with a 20 min/max ratio of 0.87. The 20 min/max activity ratio for the right cortical region of interest has increased slightly from a baseline high normal value of 0.27 to a borderline elevated value of 0.35. Angiography demonstrated bilateral renal artery stenosis. A revascularization procedure was not performed. (Reprinted with permission from Taylor A, Nally JV. Clinical applications of renal scintigraphy. *AJR Am J Roentgenol* 1995;164:31-41.)



3. *Diuretics.* Diuretics should be discontinued for 3 days before the study to avoid dehydration and minimize the risk of hypotension.

4. *ACE inhibitors and angiotensin II receptor blockers.* Chronic ACE inhibition and angiotensin II receptor blockade may reduce the sensitivity of the test. For optimal sensitivity, these drugs should be discontinued for 4–7 days before the study with the longer half-life drugs discontinued for 7 days. With the exception of diuretics, other antihypertensive medications can be substituted for ACE inhibitors and angiotensin II receptor blockers if the patient requires replacement therapy during the 4–7 days before the ACE-inhibition renogram.

## E. Understanding the report

The accuracy of ACE-inhibitor renography in identifying patients with renovascular disease appears to be high, with studies reporting sensitivities and specificities of around 90% in patients with normal renal function. Furthermore, most investigators have observed that a positive test predicts a successful reduction in blood pressure after revascularization, whereas a negative test indicates a low likelihood of renovascular hypertension. A recent consensus panel has recommended that the test be interpreted as high, low or indeterminate probability for renovascular hypertension:

- 1) High probability. Significant deterioration of the renogram curve after ACE inhibition compared with the baseline study.
- 2) Indeterminate (intermediate) probability. An abnormal baseline renogram that is unchanged after ACE inhibition. The majority of patients in this group have hypertension with azotemia or a small, poorly functioning kidney. Depending on the level of clinical suspicion, such a patient may be referred for an additional diagnostic test (see Clinical Question 6).
- 3) Low probability. A normal ACE-inhibition renogram is low probability for renovascular hypertension. Even if renal artery stenosis is present, hypertension in this group of patients is much less likely to improve with revascularization than in patients with a positive test (See Potential Problems, Ischemic Nephropathy, below).

## F. Potential problems

1. *False-positive or false-intermediate probability studies.* These can occur because of dehydration, radiotracer extravasation, poor renal function, obstruction or a distended patient bladder at the start of the scan. A false-positive test also can be obtained if the patient becomes hypotensive during the study.

2. *ACE inhibitors or angiotensin II receptor blockers.* The sensitivity of the test may be reduced in patients on chronic ACE inhibition. To maximize sensitivity, ACE inhibitors and angiotensin II receptor blockers should be withheld for 3–7 days before the study depending on the half-life of the particular ACE inhibitor. When

patients arrive for an ACE-inhibitor study and are found to be on chronic ACE inhibition, most centers elect to proceed with the scan and accept a slightly lowered sensitivity.

**3. Ischemic nephropathy.** A positive test result in a patient with azotemia or in a patient with a small, poorly functioning kidney indicates a high likelihood that the hypertension will be ameliorated by revascularization. Unlike the population of patients with normal renal function, as many as 50% of patients in this patient population may have an indeterminate or intermediate probability test result (an abnormal baseline study that does not change after ACE inhibition). A false-negative study also is more likely to occur in this patient population, possibly because of the absence of renin-dependent hypertension. Depending on the diagnostic goals, some clinicians will refer patients with ischemic nephropathy and a high pretest probability for renovascular hypertension directly to angiography. Magnetic resonance angiography or Doppler ultrasound are alternatives if there is a need to avoid contrast.

## IV. RENAL TRANSPLANT SCINTIGRAPHY

### A. Background

Complications of renal transplantation can be divided into parenchymal failure (acute tubular necrosis [ATN], acute and chronic rejection and cyclosporine/tacrolimus toxicity) and mechanical failure (injury to the renal artery or vein, ureteral obstruction and urine leak). A normal scan immediately after transplant excludes mechanical complications. Serial scans during the first 1–3 wk after transplantation can be used to monitor recovery from post-transplantation ATN and may detect early rejection 24–48 hr before biochemical abnormalities occur. Classically, rejection presents as diminished flow with delayed uptake and excretion, and ATN presents with good flow and delayed uptake and excretion, but severe ATN also can present with diminished flow. Indices such as the 20 min/2–3 min ratio and clearance measurements can be useful, but their use and availability varies from center to center.

### B. Radiopharmaceuticals

Technetium-99m-MAG3 and DTPA are used to assess transplant function, but MAG3 is preferred in patients with impaired renal function (see Basic Renogram, Radiopharmaceuticals, above).

### C. How the study is performed

The typical adult patient receives an intravenous injection of 1–10 mCi (37–370 MBq) of MAG3 or DTPA, and imaging is performed as described in the basic renogram with the camera positioned over the transplant.

### D. Patient preparation

The patient should be well hydrated; otherwise, no special preparation is required.

## E. Understanding the report

Images and renogram curves are evaluated for adequacy of flow, uptake and excretion. The report is similar to that described for the basic renogram (See Basic Renogram, Understanding the Report, above).

## F. Potential problems

1. *Hydration.* See Basic Renogram, Potential Problems, above.

2. *Cyclosporine/tacrolimus toxicity.* Interpretation takes into account the clinical presentation including the number of days after transplant and knowledge of cyclosporin level. An abnormal scan indicating poor function may exclude infarct, leak and obstruction, but it may not reliably distinguish between rejection and cyclosporin/tacrolimus toxicity. Once renal damage is advanced, it is difficult for any imaging study to distinguish causes.

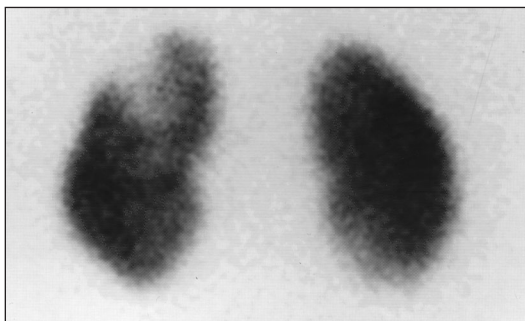
# V. RENAL CORTICAL SCINTIGRAPHY

## A. Background

Technetium-99m-dimercaptosuccinic acid (DMSA) and  $^{99m}\text{Tc}$ -glucoheptonate (GH) provide excellent visualization of the renal cortex. These agents are used most often to detect pyelonephritis (Fig. 4) and are more sensitive than ultrasound or intravenous urography in detecting pyelonephritis. Cortical scans also can confirm a suspected column of Bertin, measure relative function and identify functioning renal tissue in patients with congenital abnormalities

## B. Radiopharmaceuticals

1. *Technetium-99m-DMSA.* DMSA is an excellent cortical imaging agent. Approximately 40% of the injected dose binds to the renal tubules within 1 hr after injection; the remainder is excreted slowly in the urine over the subsequent 24 hr. DMSA is used when high-resolution anatomic images are required, such as for the detection of pyelonephritis. In patients with poor renal function, delayed images 2–24 hr after injection can substantially improve kidney visualization.



**Figure 4.** A 3-yr-old child presented with fever, leukocytosis and pyuria. A  $^{99m}\text{Tc}$ -DMSA scan shows a focal wedge-shaped abnormality in the upper pole of the left kidney consistent with acute pyelonephritis.

2. *Technetium-99m-GH*. GH is cleared by GFR and the renal tubules. In patients with normal renal function, most of the dose is excreted rapidly; however, 10–15% of the injected dose remains bound to the renal tubules and high-resolution delayed static images can be obtained. Because of the cortical retention, GH is not recommended in patients with possible obstruction or to detect renovascular hypertension. Furthermore, some GH also may be excreted via the hepatobiliary system with resultant gallbladder visualization.

### C. How the study is performed

The usual adult dose of 1–5 mCi (37–185 MBq) of DMSA or 1–10 mCi (37–370 MBq) of GH is injected intravenously. After GH administration, sequential images often are obtained as the tracer enters and transits the kidney; delayed images are obtained 1–4 hr after injection. Delayed images 1–4 hr after injection are obtained after DMSA administration. If a patient has impaired renal function, delaying the images up to 24 hr will provide better cortical detail. Standard images take approximately 30 min, and up to 1 hr is required if SPECT images are obtained.

### D. Patient preparation

No special preparation is required.

### E. Understanding the report

The relative renal uptake of  $^{99m}\text{Tc}$ -DMSA or GH can be quantitated to provide an index of relative renal function. The cortical images are evaluated for homogeneous distribution throughout the renal cortex. Pyelonephritis is recognized by decreased uptake of DMSA or GH in the renal parenchyma (Fig. 4). Normal scintigraphic findings effectively exclude acute pyelonephritis. A column of Bertin can be confirmed when functioning renal cortical tissue corresponds to the mass questioned on ultrasound or CT.

### F. Potential problems

Any process that replaces, injures or destroys normal cortical parenchyma will result in an abnormal scan. The configuration of the abnormality may suggest renal cyst, infection, tumor, infarct or scarring, but the study must be used and interpreted in the proper clinical context. Correlation with other imaging modalities is important to confirm the presence of a column of Bertin.

## VI. TESTICULAR SCAN

### A. Background

Spermatic cord torsion is a medical emergency and prompt surgical exploration is necessary to salvage the involved testis. The cause of acute unilateral testicular swelling and pain is usually torsion of the spermatic cord or acute epi-

didymitis. Other possibilities include torsion of the testicular appendage, orchitis, strangulated hernia or hemorrhage. Radionuclide scrotal imaging can distinguish between acute epididymitis (no surgical intervention) and probable torsion, which requires prompt surgical exploration. Adequate examinations will detect more than 95% of patients with torsion; 80–85% of patients with nontorsion will be correctly identified and spared unnecessary surgery (See Clinical Question 16).

## B. Radiopharmaceutical

Technetium-99m-pertechnetate is inexpensive and is commonly used to evaluate blood flow to the testicles.

## C. How the study is performed

The study can be performed in 10–15 min. The patient is given a bolus injection of  $^{99m}\text{Tc}$ -pertechnetate, and a radionuclide angiogram of testicular perfusion is obtained, followed by additional static images. The typical adult dose of  $^{99m}\text{Tc}$ -pertechnetate is 10–20 mCi (370–740 MBq); the pediatric dose is appropriately reduced.

## D. Patient preparation

None required.

## E. Understanding the report

An area of decreased vascularity corresponding to the involved testis indicates that torsion is likely. If the clinically involved testis is normally perfused or hypervascular, emergency surgery is unnecessary.

## F. Potential problems

Correlation of the scan results with the history and physical examination is vital for proper interpretation; this correlation should be done by the physician performing the study. Decreased flow to the affected testicle could be interpreted as increased blood flow to the contralateral testicle if the contralateral testicle were wrongly identified as the testicle at risk.

# VII. RADIONUCLIDE CYSTOGRAPHY

## A. Background

Vesicoureteral reflux, urinary tract infections and renal scarring can lead to hypertension and end-stage renal disease; however, a large percentage of patients with pyelonephritis do not have reflux. Furthermore, reflux often resolves spontaneously. Management of patients with urinary tract infection and/or reflux tends to be individualized and may vary from center to center. Reflux may be suspected based on an antenatal ultrasound showing ureteral or calyceal dilatation,

acute pyelonephritis or documented reflux in a sibling. Conventional voiding cystourethrography (VCUG) with fluoroscopy is usually the first test in males to evaluate the possibility of posterior urethral valves as well as to grade the degree of reflux. Because congenital abnormalities of the bladder and urethra are rare in girls, radionuclide cystography may be used as the initial test. If follow-up studies are required in males or females, the patient should be followed up with radionuclide cystography; the technique is accurate for detecting reflux, and the radiation dose to the gonads is much less than with VCUG. Radionuclide cystography also is used to assess the results of antireflux surgery and in the serial evaluation of reflux in a patient with a neurogenic bladder.

## B. Radiopharmaceuticals

Technetium-99m-pertechnetate, DTPA or sulfur colloid usually are infused directly into the bladder via a catheter (See Basic Renogram, Radiopharmaceuticals, above). Technetium-99m sulfur colloid is composed of radioactive particles about 0.5  $\mu\text{m}$  in diameter (See Chapter 6, Infection Imaging). These agents are not absorbed into the blood from the urinary bladder.

## C. How the study is performed

1. *Direct radionuclide cystography.* The bladder is catheterized, and the study is performed by instilling saline containing approximately 1 mCi (37 MBq) of a  $^{99\text{m}}\text{Tc}$  radiopharmaceutical into the bladder. Imaging is performed continuously during filling of the bladder and subsequent voiding. Reflux can be quantitated by recording data on the computer during the study.

2. *Indirect radionuclide cystography.* Bladder catheterization is not required. The patient receives an intravenous injection of a  $^{99\text{m}}\text{Tc}$  radiopharmaceutical. Because of its more rapid clearance, MAG3 is preferred to DTPA. The patient then undergoes evaluation of individual kidney function, urine drainage and reflux with dynamic images obtained during bladder filling, during voiding and after voiding. Indirect radionuclide renography avoids catheterization, but it is not as sensitive as direct radionuclide cystography for detecting reflux.

## D. Patient preparation

None is required.

## E. Understanding the report

The presence of reflux, as well as the grade, and whether reflux occurs during filling and/or voiding should be reported. The total bladder capacity and bladder capacity at the time of reflux also may be reported. These data can provide guidance regarding patient management and prognosis.

## F. Potential problems

As with any pediatric imaging study, meticulous attention to detail in a facility with experience in pediatric imaging is important.

## CLINICAL QUESTIONS

3

1. Ultrasound or CT shows a dilated collecting system. Is there ureteral obstruction?

Dilatation of the urinary tract with no apparent cause may be incidentally detected by ultrasound, CT or MRI in a patient with no symptoms of acute obstruction. If the dilated collecting system represents chronic obstruction, an intervention may be required to preserve renal function; if there is simply dilatation of a nonobstructed collecting system, no further work-up is required. Diuresis renography is preferred in the evaluation of the nonacute dilated collecting system because it is noninvasive and it is the only test that can evaluate renal function and urodynamics in a single examination. Diuresis renography allows the clinician to quantitate the physiologic significance of the anatomic abnormality by measuring the relative renal function and the diuretic stimulated washout of the tracer from the dilated system. Furthermore, contrast is avoided and the gonadal radiation dose is reduced substantially, being only 20% of the gonadal dose from intravenous urography.

In 10–15% of diuresis renography studies, the renal scan will be equivocal because washout of the tracer from the collecting system is not rapid enough to exclude obstruction and not slow enough to definitively diagnose obstruction. Indeterminate rates of tracer washout are most likely to occur in kidneys with poor function or massively dilated collecting systems (see Basic Renography, Potential Problems, above). Even if the washout rate is indeterminate, the measurement of relative function provides important clinical information. If a kidney with an equivocal washout rate contributes 50% of a patient's total renal function, there has been no functional compromise and obstruction is less likely. In the chronic setting, it may be appropriate to follow up with serial scans to ensure that function does not deteriorate rather than intervene surgically. If the kidney in question has reduced function, a percutaneous nephrostomy may be performed.

2. A patient with previous obstruction has recurrent symptoms. Has obstruction recurred?

A patient with previous documented and treated obstruction may present with symptoms suggesting recurrent obstruction; ultrasonography often is not helpful in this setting because the urinary tract can be dilated secondary to the previous episode of obstruction. Diuresis renography is the preferred examination (see Clinical Question 1, above).

3. Has surgery successfully relieved a documented obstruction?

A radionuclide scan can document adequate urine flow and relief of obstruction; at the same time, the scan can evaluate the function of the kidney in question



and determine (assuming the existence of a preobstruction scan) if there has been any improvement in renal function after the surgical procedure. Furthermore, the scan then serves as a baseline if the patient subsequently becomes symptomatic.

4. Does a patient presenting with flank pain have acute renal colic? If so, can he be managed conservatively?

Knowledge of the size of the obstructing calculus is important because calculi <5 mm generally pass spontaneously; as the size of the calculus increases, spontaneous passage becomes less likely. Intravenous urography (IVU) is often the first procedure performed, but it does involve risk of contrast reaction. Relative contraindications to IVU include renal insufficiency, diabetes, dehydration, allergy to iodinated contrast agents and pregnancy. Renal ultrasound with intrarenal Doppler and a plain x-ray of the abdomen are less accurate than IVU and requires skilled personnel; furthermore, ultrasound cannot differentiate dilatation without obstruction from true obstruction. Noncontrast enhanced spiral CT is rapidly gaining acceptance as an accurate screening method and is becoming the procedure of choice for patients presenting with acute renal colic.

There are acute situations, however, in which renal scintigraphy may be preferred. Many calculi between 3 and 8 mm are followed up conservatively in the hope of spontaneous passage, and patients may be managed on an outpatient basis. In this setting, it may be important to know that renal function is preserved and that delay is unlikely to lead to renal damage. Repeat abdominal x-rays can show that the calculus is moving downward. A baseline renal scan defines the relative function and degree of obstruction. Serial scans can confirm that renal function is preserved and that conservative management is safe. Deteriorating renal function of the affected kidney or increasing obstruction may point to the need for an intervention. The radionuclide renal scan can be used in patients allergic to contrast or with renal insufficiency.

5. Antenatal sonography showed a dilated pelvis or ureter. Is there obstruction or loss of renal function?

The significance of an abnormal antenatal renal sonogram can be readily evaluated by diuresis renal scintigraphy in the newborn (see Clinical Question 1). Because of its higher extraction efficiency, MAG3 is superior to DTPA in this setting.

6. Does a hypertensive patient have renovascular hypertension?

Risk factors for renovascular hypertension include abrupt or severe hypertension, hypertension resistant to medical therapy, abdominal or flank bruits, unexplained azotemia in an elderly hypertensive patient, worsening renal function during therapy with ACE inhibitors, grade 3 or 4 hypertensive retinopathy, a history of heavy smoking, occlusive disease in other vascular beds and onset of

hypertension under age 30 or over age 55. To determine the most appropriate test, patients need to be categorized into (a) those with low likelihood of renovascular hypertension, (b) those with moderate to high likelihood of renovascular hypertension and normal renal function and (c) those with moderate to high likelihood of renovascular hypertension and compromised renal function.

*Low likelihood of renovascular hypertension.* The utility of a test to detect renovascular hypertension depends on the prevalence of the disease in the population studied. If a hypertensive patient has no risk factors, there is a low likelihood of renovascular hypertension and diagnostic tests for renovascular hypertension are not indicated.

*Moderate to high likelihood of renovascular hypertension, normal renal function.* ACE-inhibitor renography is highly accurate in patients with normal renal function (normal creatinine and the absence of a small, poorly functioning kidney); the sensitivity and specificity of ACE-inhibitor renography for renovascular hypertension in this patient population approach 90%. As an initial approach, angiography in this clinical setting is not cost effective; moreover, the presence of renal artery stenosis does not indicate that revascularization will be beneficial. The strength of ACE-inhibition renography is that it is the only widely available examination that directly examines for the presence of renovascular hypertension.

*Moderate to high likelihood of renovascular hypertension, compromised renal function.* Patients with impaired renal function often have nondiagnostic ACE-inhibition renograms. A positive ACE-inhibition test result indicates that hypertension is likely to improve after revascularization, but many patients with azotemia or a small, poorly functioning kidney have an intermediate probability or nondiagnostic ACE-inhibition test result (abnormal baseline study that does not change after ACE inhibition). Even if a small, poorly functioning kidney is supplied by a tightly stenotic renal artery, kidney function may not be salvageable, and the kidney may need to be removed or embolized.

In the appropriate clinical setting, an intermediate test result may be sufficient to refer a patient for angiography. Alternatively, patients may be referred for duplex sonography or magnetic resonance angiography. Duplex sonography can be time consuming to perform, and it has achieved reliability only at certain dedicated centers because of difficulties inherent in performing and interpreting the examination.

When there is a high index of suspicion, azotemic patients may be referred directly for angiography. Revascularization is sometimes performed in azotemic patients with renal artery stenosis in an attempt to improve renal function and ameliorate any co-existing hypertension. Intuitively, it seems reasonable to revascularize an azotemic patient to improve renal function, and renal function may be improved, but there are no controlled studies showing that survival after revascularization is superior to available medical therapy.

*Prognosis and alternative tests.* The renovascular hypertension renogram has important prognostic value in determining which patients will benefit from revascularization. Other imaging examinations only evaluate for the presence of renal artery stenosis. Conventional angiography or digital subtraction angiography are the gold standards for the diagnosis of renal artery stenosis (not necessarily renovascular hypertension), but they are invasive and subject the kidney to a contrast load. Thus, they are of less utility as screening examinations, especially for patients with poor renal function. CT angiography is noninvasive but subjects the kidney to a contrast load. Magnetic resonance angiography is gaining wider appeal because of its noninvasive nature and lack of iodinated contrast. These tests may be more useful in older patients who are most likely to have proximal renal artery stenosis; they are less sensitive for segmental or distal renal artery stenosis. Other tests such as renal vein renin sampling, hypertensive IVU and intravenous digital subtraction angiography are not appropriate as screening procedures, although renal vein renin assays, as well as ACE-inhibitor renography, can be used to evaluate the significance of a renal artery stenosis.

*Summary.* ACE-inhibition renography provides a logical diagnostic approach to the patient with one or more risk factors for renovascular hypertension, normal renal function and no known unilateral kidney disease. A normal ACE-inhibition renogram obviates further work-up. An abnormal study should lead to referral for angiography and revascularization. If a small, poorly functioning kidney is identified, angiography, CT angiography, magnetic resonance angiography or duplex sonography, depending on local experience and expertise, would be a reasonable next step. The evaluation of the patient with azotemia or a patient known to have a small, poorly functioning kidney is more problematic. ACE-inhibitor renography is a noninvasive procedure, and a positive test result should lead to angiography and revascularization if technically feasible. A disadvantage of ACE-inhibitor renography in this patient population is that as many as half of the test results may be intermediate probability; false-negative test results also can occur in this patient population. The advantages and disadvantages of other diagnostic approaches have been described, and test selection should be based on how the test result will influence patient management.

- 7–9. What percent does each kidney contribute to total function? What is the global (total) renal function? Is the global (total) renal function stable compared with the most recent measurement?

*Relative renal function.* The renal scan excels in determining relative function; the measurement can be made using the standard renogram or a cortical scan.

*Total renal function.* Quantitation of total renal function is often critical in patient management, particularly if there is underlying azotemia, the patient is taking nephrotoxic drugs, or the surgical question is total versus partial nephrectomy. In

many patients, a precise measurement of renal function is not as important as being able to reliably determine if the total renal function is increasing, remaining the same or deteriorating. The most common measurements of renal function are the serum creatinine and the creatinine clearance. Often these determinations are sufficient, but both are global indices and provide no information regarding regional or individual function. More than 50% of the renal function may be lost before the serum creatinine rises to an abnormal value. A formal creatinine clearance measurement using blood samples and 24 hr urine collection is cumbersome and often unreliable. Advances in nuclear medicine methodology allow the GFR, ERPF and MAG3 clearance to be measured using either plasma sample clearances or camera-based methods. Available data indicate that radionuclide clearances have less variability than the creatinine clearance and are superior to the creatinine clearance in monitoring changes in renal function; however, radionuclide clearance measurements are not available in many institutions.

10. A patient presents with acute renal failure. What is the cause?

There are various causes of renal failure, and the clinical presentation will dictate the diagnostic approach. Acute failure initially is evaluated best with ultrasound (renal size, atrophy, dilated collecting system), but if there is a question of obstruction or underlying asymmetrical renal disease, a renal scan can provide important ancillary information. The scan can detect or exclude obstruction and quantitate the relative renal function; furthermore, good renal uptake of the radiopharmaceutical indicates the presence of functioning renal tissue and represents a favorable prognostic sign.

11 and 12. Is there bladder outlet obstruction or bladder dysfunction? What is the postvoid bladder residual?

The postvoid bladder residual can be measured by catheterization; however, ultrasound and radionuclide scintigraphy provide a simple and noninvasive means to answer this question. Residual urine volume can be determined as part of the routine radionuclide renal scan, saving the cost of an additional procedure. The measurement requires a prevoid and postvoid image of the bladder and measurement of the voided urine volume. The main source of error is tracer retained in a dilated pelvis or ureter that drains into the bladder after voiding. In many nuclear medicine departments, this measurement is not routine and will need to be requested.

13–15. Is the transplant functioning normally? Is there a leak? Is there an obstruction? What is the cause of a poorly functioning renal transplant or rising creatinine?

The radionuclide renal scan can evaluate flow to the transplant, detect infarcts and leaks and distinguish between obstruction and a dilated but nonobstructed

collecting system. The ACE-inhibition renogram is useful for detecting renovascular hypertension due to transplant artery stenosis. Duplex sonography can evaluate flow. Sonography can detect extrarenal fluid collections and determine if the renal pelvis is dilated. Sonography cannot distinguish between obstruction and a nonobstructed dilated collecting system. Neither test can reliably distinguish between rejection and cyclosporine/tacrolimus toxicity. Interpretation of the renogram requires integration of the test results with the clinical presentation including a knowledge of the antirejection therapy, the number of days that have elapsed since transplantation and the function of the transplant during this period. A scan showing a poorly functioning cadaveric transplant 1 day after surgery typically represents ATN; sequential scans showing a deterioration in function usually represent rejection, although cyclosporine/tacrolimus toxicity can have a similar presentation (See Renal Transplant Scintigraphy, Background, above). Institutions vary considerably in regard to how these examinations are used and at what point biopsy is performed.

16. Does the patient presenting with acute scrotal pain have testicular torsion?

The diagnosis of testicular torsion must be made as rapidly as possible because testicular viability decreases to about 80% within the first 5 hr and falls to about 20% after 10–12 hr. Radionuclide scrotal scintigraphy and scrotal sonography with color flow Doppler (duplex imaging) are acceptable diagnostic approaches to distinguish testicular torsion from nonsurgical causes of scrotal pain, such as epididymitis or epididymo-orchitis. The choice depends largely on clinical expertise, cost and availability of the two tests. In patients with suspected torsion, surgery should never be delayed because of a delay in obtaining a test.

17. Is there is a congenital renal abnormality? How well is the kidney in question functioning?

Congenital abnormalities often are detected by sonography in utero. The basic renogram is often important in determining the physiologic significance of a dilated collecting system detected in utero or after birth (See Clinical Question 4, above). In addition to evaluating the presence or absence of obstruction, the scan can determine if both kidneys are functioning, if only a portion of a kidney is functioning or if there is functioning renal tissue in an unusual location such as a horseshoe or pelvic kidney.

18. Does a child presenting with an acute urinary tract infection have acute pyelonephritis?

Pyelonephritis is a serious illness in the pediatric population; renal scarring from recurring infection remains an important cause of end-stage renal disease and hypertension. Clinical and experimental studies have demonstrated that scarring can be prevented or diminished by early diagnosis and aggressive ther-

apy. It is important to emphasize that in infants and young children, pyelonephritis is not always accompanied by high fever, an elevated sedimentation rate and leukocytosis. A normal voiding cystourethrogram does not exclude acute pyelonephritis, and it is increasingly recognized that sonography and excretory urography cannot be used to exclude acute pyelonephritis in infants and children. Renal cortical (DMSA) scintigraphy is much more sensitive for the detection of pyelonephritis than ultrasonography, and many investigators recommend cortical scintigraphy in the initial evaluation of children with suspected pyelonephritis. MRI and CT with contrast are also sensitive tests for the detection of pyelonephritis, but MRI is expensive, and there is the possibility of an allergic reaction to iodinated contrast given during the CT scan.

*Will the diagnosis of acute pyelonephritis alter patient management?* The diagnostic algorithm depends on what the clinician will do with the information. Some institutions treat pediatric patients with suspected pyelonephritis empirically and only pursue diagnostic studies if the patient does not respond. In other institutions, patients with pyelonephritis receive more aggressive therapy or follow-up in the hope of reducing the risk of scarring and recurrent infection and thereby avoiding the subsequent development of hypertension and renal failure. In these institutions, it is important to distinguish between a lower urinary tract infection and pyelonephritis because the diagnosis of pyelonephritis changes patient management. An episode of acute pyelonephritis in males often leads to VCUG to check for reflux and posterior urethral valves. In girls, congenital abnormalities are rare but VCUG or radionuclide cystography may be obtained to check for reflux. Once congenital abnormalities are excluded, radionuclide cystography is preferred to VCUG to monitor reflux because the tests are equally sensitive and radiation dose to the gonads from the radionuclide cystogram is only 1–2% of the gonadal radiation dose from VCUG.

*Acute pyelonephritis in adults.* Acute pyelonephritis generally causes flank pain and fever and frequently is accompanied by signs and symptoms such as urgency, frequency and dysuria. Uncomplicated urinary tract infection is relatively benign, rarely leads to progressive renal failure and usually is diagnosed and treated without the need for imaging studies. The diagnosis is based on the clinical features and results of urinalysis and urine cultures. For these reasons, a cortical scan is not considered necessary in the adult population. For suspected complications such as perinephric abscess, CT is much more valuable.

19–21. Does the patient have ureteral reflux? Is reflux present in an asymptomatic sibling of a child with reflux? Has previously documented ureteral reflux resolved or diminished?

In a male with suspected ureteral reflux, an iodinated contrast examination such as VCUG should be performed initially to evaluate the urethra and reflux. If reflux is established, radionuclide cystography is the ideal follow-up procedure.



Radionuclide cystography is just as sensitive as VCUG in detecting reflux, and the radiation dose to the patient is substantially less (See Question 12, above).

Renal scans can also be important in monitoring individual renal function during conservative management of ureteral reflux. Deterioration of renal function in a refluxing kidney is an indication for ureteral reimplantation.

## 22. Is a questionable mass on an intravenous urogram a column of Bertin?

Excellent anatomic images of the kidneys can be obtained using renal cortical scintigraphy in patients with allergies to contrast media or in those with a relative contraindication to contrast media administration. Hypernephromas have not been reported to concentrate any renal radiopharmaceutical. Most other renal masses, whether cyst, neoplasm or abscess, fail to concentrate radiopharmaceuticals used for renal imaging. They appear as areas of decreased activity, indistinguishable from one another. A renal column of Bertin is composed of normal cortical tissue, but it can appear as a questionable mass on ultrasound or IVU. The presence of normal cortical tissue can be confirmed by a cortical scan, which shows concentration of the radiopharmaceutical corresponding to the questionable area.

## 23–25. Is there a urine leak? Is the kidney functioning normally? Is a traumatized kidney recovering its function?

A CT scan is usually the first diagnostic imaging procedure obtained in a patient with suspected abdominal trauma; CT with contrast also can detect a urinary leak. A radionuclide renal scan can determine the effect of trauma on renal function, monitor functional recovery and identify a urine leak.

# WORTH MENTIONING

## 1. Exercise renography

Preliminary studies suggest that many patients with essential hypertension will have abnormal exercise renograms. Exercise renography is performed with the patient exercising at a submaximal level in a sitting position on a stationary bicycle. The test is not widely used because, at present, the significance or clinical utility of the finding has not been determined.

## 2. Aspirin renography

Preliminary studies suggest that aspirin renography also may be useful in detecting renovascular hypertension. Aspirin blocks the breakdown of bradykinin, which modulates blood flow to the medulla. The role of aspirin renography in conjunction with or versus ACE-inhibition renography has not been determined.



### 3. Angiotensin II receptor blocker renography

Preliminary studies suggest the angiotensin II receptor blockers also may be useful in detecting renovascular hypertension. The role of angiotensin II receptor blocker renography in conjunction with or versus ACE-inhibition renography has not been determined.

### 4. Suspected infected renal cyst

The largest cyst is not necessarily an infected cyst. When a patient has multiple cysts, a cortical scan to localize the cysts combined with a gallium or labeled white cell scan to determine which cyst is infected can facilitate an appropriate drainage procedure.

### 5. Renal function and retroperitoneal fibrosis

Ureteral obstruction due to retroperitoneal fibrosis can be detected and followed up by radionuclide renography. This approach can be particularly important when the patient receives nonsurgical therapy such as steroids for retroperitoneal fibrosis.

## PATIENT INFORMATION

### I. RADIONUCLIDE RENOGRAM

#### A. Test/Procedure

Your physician has referred you for a kidney scan. This procedure is tailored to fit your individual needs, depending on the clinical question. In most cases, you will lie on a flat table, a large camera will be moved beneath the table and a very small amount of a radioactive tracer will be injected into an arm vein. You will remain on the table for 20–30 min while specialized pictures are being made as the radioactive tracer is removed from the blood by the kidneys and drains into the bladder. If there is suspected obstruction of the kidney, a drug to increase your urine flow may be injected and imaging of the kidneys may continue for another 20 min. If you are referred because of high blood pressure possibly caused by a narrowing of the renal artery, two 20–30 min imaging sessions of the kidney sometimes are performed in the same day.

#### B. Preparation

*Diet.* There are no food restrictions unless you are referred for suspected narrowing of the renal artery as the cause of high blood pressure. In this specialized case, you may be given a drug (captopril) in the nuclear medicine department. Food in the stomach may delay stomach emptying or interfere with the absorption of the captopril; for these reasons, you should not eat after midnight before the study, but you should be well-hydrated and continue to drink fluids; water, juice and soft drinks are acceptable. At a minimum, drink at least two large glasses of water when you get out of bed and two more just before coming

to the nuclear medicine department. If you have a question, you may want to call the nuclear medicine department to find out if you will be given captopril.

**Medications.** Check with your doctor before stopping any medications. If you are having the test to determine if narrowing of the artery to the kidney is the cause of your high blood pressure, you may be asked to discontinue certain drugs including diuretics and drugs called ACE inhibitors or angiotensin II blockers.

### C. Radiation and other risks

The radiation exposure is minimal and is comparable to that of many other diagnostic x-ray tests. In patients with normal kidney function, more than 95% of the radiation leaves the body by 4 hr. The effective radiation dose to your whole body is less than half of the radiation dose a person living in the United States receives each year from cosmic rays and naturally occurring background radiation. The radiation dose is less than 5% of the yearly radiation dose considered safe for doctors and technologists who work with radiation. You can be around other people and use a bathroom without risk to others.

### D. Pregnancy

If you are pregnant or think you may be pregnant, please inform your doctor so that this can be discussed with the nuclear medicine physician before your test.

### References

1. Rosenbaum JL. Evaluation of clearance studies in chronic kidney disease. *J Chron Dis* 1970;22:507–514.
2. Brown SCW, O'Reilly PH. Glomerular filtration rate measurement: a neglected test in urological practice. *Br J Urol* 1995;75:296–300.
3. Blaufox MD, Aurell M, Bubeck B, et al. Report of the radionuclides in nephrourology committee on renal clearance. *J Nucl Med* 1996;37:1883–1890.
4. Kass EJ, Fink-Bennett D, Cacciarelli AA, Balon H, Pavlock S. The sensitivity of renal scintigraphy and sonography in detecting nonobstructive acute pyelonephritis. *J Urol* 1992;148:606–608.
5. Rushton HG. The evaluation of acute pyelonephritis and renal scarring with technetium 99m-dimercaptosuccinic acid renal scintigraphy: evolving concepts and future directions. *Pediatr Nephrol* 1997;11:108–120.
6. Conway JJ, Cohn RA. Evolving role of nuclear medicine for the diagnosis and management of urinary tract infection. *J Pediatr* 1994;124:87–90.
7. Rushton HG, Majd M. Dimercaptosuccinic acid renal scintigraphy for the evaluation of pyelonephritis and scarring: a review of experimental and clinical studies. *J Urol* 1992;148:1726–1732.
8. Mittal BR, Kumar P, Arora P, et al. Role of captopril renography in the diagnosis of renovascular hypertension. *Am J Kidney Dis* 1996;28:209–213.
9. Holley KE, Hunt JC, Brown AL Jr, et al. Renal artery stenosis: a clinical-pathologic study in normotensive and hypertensive patients. *Am J Med* 1964;37:14–22.
10. Taylor A, Nally J, Aurell M, et al. Consensus report on ACE inhibitor renography for detecting renovascular hypertension. *J Nucl Med* 1996;37:1876–1882.

11. Blafox MD, Middleton ML, Bongiovanni J, et al. Cost efficacy of the diagnosis and therapy of renovascular hypertension. *J Nucl Med* 1996;37:171–177.
12. O'Reilly P, Aurell M, Britton K, Kletter K, Rosenthal L, Testa T. Consensus on diuresis renography for investigating the dilated upper urinary tract. *J Nucl Med* 1996;27:1862–1876.
13. Taylor A. Radionuclide renography: a personal approach. *Semin Nucl Med* 1999;29:102–127.
14. Taylor A, Nally JV. Clinical applications of renal scintigraphy. *AJR Am J Roentgenol* 1995;164:31–41.