

# Alfred W. Adson (1887–1951): his contributions to surgery for tumors of the spine and spinal cord in the context of spinal tumor surgery in the late 19th and early 20th centuries

## Historical vignette

CHRISTOPH J. GRIESSENAUER, M.D.,<sup>1</sup> R. SHANE TUBBS, M.S., P.A.-C., PH.D.,<sup>2</sup>  
MOHAMMADALI M. SHOJA, M.D.,<sup>1</sup> JOEL RABORN, B.S.,<sup>1</sup> CHRISTOPHER J. BOES, M.D.,<sup>3</sup>  
MARTIN M. MORTAZAVI, M.D.,<sup>1</sup> AND GIUSEPPE LANZINO, M.D.<sup>4</sup>

<sup>1</sup>Division of Neurosurgery, Department of Surgery, University of Alabama at Birmingham; <sup>2</sup>Pediatric Neurosurgery, Children's Hospital, Birmingham, Alabama; and Departments of <sup>3</sup>Neurology and <sup>4</sup>Neurosurgery, Mayo Clinic, Rochester, Minnesota

Alfred W. Adson was a pioneer in the field of neurosurgery. He described operations for a variety of neurosurgical diseases and developed surgical instruments. Under his leadership the Section of Neurological Surgery at the Mayo Clinic was established and he functioned as its first chair. Adson's contributions to the understanding of spinal and spinal cord tumors are less well known. This article reviews related medical records and publications and sets his contributions in the context of the work of other important pioneers in spinal tumor surgery at the time.  
(<http://thejns.org/doi/abs/10.3171/2013.9.SPINE13220>)

**KEY WORDS** • spine • spinal cord • tumor • history

**A**LFRED W. Adson (1887–1951) was the founding father of neurosurgery at the Mayo Clinic in Rochester, Minnesota. Under his leadership the Section of Neurological Surgery was first established in 1919; he functioned as its chair until 1946.<sup>64</sup> Adson first came to Mayo as a fellow in surgery in 1914 and worked as an assistant to William and Charles Mayo, E. Starr Judd, and Emil Beckman, the first Mayo surgical staff member to develop an interest in neurosurgery. In 1916 Adson joined the surgical staff and performed general surgery and the occasional neurosurgical case. Early on, William Mayo had envisioned Adson as a surgeon who would eventually focus entirely on neurosurgery. Adson was initially hesitant to fill this role, but after some convincing by Mayo and satisfying experiences with his first neurosurgical operations he changed his mind about neurosurgery, and in 1921 devoted all his efforts to this new surgical specialty.

Adson was a pioneer of neurosurgery, designing various instruments, including self-retaining retractors. He described the transcranial approach as a treatment for CSF rhinorrhea, a straight lateral approach for unilateral suboccipital craniectomy, and approaches to the gasserian ganglion. He published on sympathectomy for peripheral vascular disease and hypertension as well as outlet syndromes of the upper extremity.<sup>64</sup> Beyond that, Adson also made significant contributions to the surgical treatment for spinal and spinal cord tumors, which over time became an important component of his practice.

Throughout his career he published extensively on the various aspects of this topic. Adson should be included among the other great spinal tumor surgeons of the time.

## Illustrative Cases

In 1919 Adson published his initial experience with surgery for spinal tumors.<sup>6</sup> The paper reported 16 cases of presumed spinal cord tumors that Adson had performed surgery on in 1917. Overall, two-thirds of patients improved; remarkable for a “high school boy doing neurosurgery,” as the British army surgeon Sir Berkeley Moynihan referred to the 30-year-old, youthful-looking Adson when the former was visiting the Mayo Clinic and watched Adson performing what was reportedly his first operation on a thoracic spinal meningioma.<sup>64</sup> Medical records and Adson's notes for those 16 cases (Table 1) were reviewed for illustrative material.

### *Intramedullary Spinal Cord Tumors*

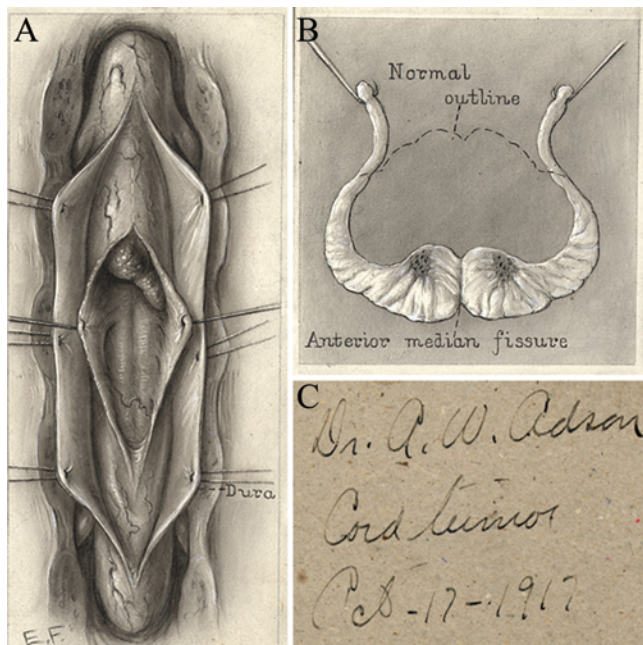
*Case 1 (J. R. W.).* It was probably on January 11, 1917, that Adson performed his first operation for a presumed spinal tumor in the thoracic area (see Fig. 1). Six days prior to the operation he saw a 46-year-old man with a 12-month history of progressive paraplegia, sensory

This article contains some figures that are displayed in color online but in black-and-white in the print edition.

TABLE 1: Adson's first surgeries for spinal tumors in 16 patients\*

Patient	Age (yrs), Sex	Diagnosis	Surgical Findings	Spinal Level	Duration of Symptoms	Outcome	Remarks
<b>intramedullary tumors</b>							
J. J. O.	29, M	SCT, Hx of syphilis	angioma	thoracolumbar	10 mos	slow improvement	
G. H.	21, F	SCT (50%), myelitis (50%)	intramedullary fibroma	cervicothoracic	7 yrs (1 yr marked)	slow improvement	
A. W. E.	41, M	SCT	intramedullary tumor	cervicothoracic	8 yrs (1.5 yrs marked)	slow improvement	
M.	32, F	SCT	unilat inflammatory mass	thoracolumbar	1.5 yrs	unimproved	drainage of CSF
C. C.	40, M	Hx of syphilis w/ level signs	gumma	thoracic	1.5 yrs	unimproved	
J. R. W.	46, M	SCT	meningomyelitis	thoracic	1 yr	unimproved	
B.	31, M	SCT, syringomyelia	meningomyelitis	cervicothoracic	1 yr	improved	
M. O. B.	31, M	chronic meningial cord tumor, Hx of meningitis 9 yrs ago	meningomyelitis	cervical	9 yrs (1 yr marked)	death	death 30 hrs postop from fat embolism
<b>extramedullary tumors</b>							
W. A. M.	30, M	SCT	meningioma	thoracic	10 mos	rapid improvement	
C. A.	57, F	SCT	meningioma	thoracic	2 yrs	rapid improvement	
W. M.	40, F	SCT	glioma	thoracic	3 yrs	slow improvement	cystitis
J. B. P.	45, F	SCT	meningioma	cervicothoracic	3.5 yrs	moderately rapid improvement	
C. L.	35, M	SCT (50%), myelitis (50%)	meningioma	thoracic	7 yrs	slow improvement	
W. D.	45, M	SCT	fibroma	cervical	3 yrs	improvement & relapse at 10 mos	reop for pressure on cord from developing lordosis
S. E. D.	55, F	SCT	meningioma	thoracic	2 yrs	rapid improvement	
T. E. Y.	45, F	SCT	angioneuroma	thoracic	6 mos	slow improvement	

\* Hx = history; SCT = spinal cord tumor.



**FIG. 1.** Illustration of one of Adson's first intramedullary spinal cord tumor cases. **A:** Drawing of the inferior aspect of the tumor after opening of the dura mater and dorsal myelotomy. **B:** Cross-sectional drawing demonstrating a spinal cord flattened from tumor compression. **C:** Indication of the date of this artwork: October 17, 1917.

changes, and subtle urinary retention. Adson records the following findings in his operative note:

Upon opening the dura, a marked increase in the spinal pressure was observed. The cord was covered with a white plastic exudate which contained the hard calcareous plaque and also many dilated and tortuous blood vessels. The cord was about normal in size but was congested and covered with these tortuous vessels. No tumor could be found in the region of the explored cord. The condition is probably one of myelitis associated with an inflammatory plastic exudate of the membranes.

One year later Adson received a letter from the patient, who reported a temporary improvement in his ability to ambulate until he eventually lost all lower-extremity function as well as bowel and bladder control. Adson promptly replied:

at the time you were here we told you that we found that your condition was due to an inflammatory process, and one which we felt we could relieve to some extent. Of course, such inflammatory processes are sometimes very difficult to control. I was glad to hear of the improvement that was made upon your return home but am not surprised to hear what has happened since then, as every now and then a person will have an extension of this inflammatory disturbance. Unfortunately, a second operation does not give much relief.

Adson's first case illustrates the dilemma in spinal tumor surgery at the time, because in surgery other non-neoplastic processes, mainly inflammatory or infectious in nature, were frequently encountered instead of a tumor, and surgical exploration remained the sole option in the hope for treatment and cure. Based on his description, the intraoperative findings are most consistent with meningo-myelitis or a spinal vascular lesion. The case also demonstrates how Adson used the mail for communication with his patients, who frequently traveled long distances to see

him; this was a standard practice for physicians to follow up on their patients at that time.

*Case 2 (B.).* On January 16, 1917, Adson performed a C6–T1 laminectomy in a 31-year-old man with a 1-year history of urinary problems, weakness (initially in the lower extremities and progressing to the upper extremities), and severe back pain accompanied by a rash attributed to dermatitis herpetiformis. Adson noted

the intraspinal pressure to be markedly increased. Upon opening the dura covering the cord, about 1 1/2 ounces of fluid spurted out. The cord presented a peculiar whitish and filmy exudate. This extended over the 7th cervical and the first thoracic segment. The spinal cord was about normal in size, but the dorsal surface was covered with many tortuous blood vessels.

No tumor was found and the intraoperative picture appeared consistent with meningo-myelitis. The patient was discharged and it was not until 1930, 13 years later, that Adson received a letter from another institution regarding the patient's progress. The patient reportedly had improved to the point where he was essentially free of symptoms for many years until symptoms recurred, which warranted a "redo" operation at that facility in January 1930. The surgeon reported the following intraoperative findings to Adson:

At operation an extra-dural cystic mass was found three or four inches in length with thick walls. The inner surface presented with "Zuckerguss" appearance and contained a mucoid material. Into this cyst projected in the form of a tiny hernia a little tissue from the posterior side of the spinal cord. This was excised and showed nothing unusual on section. Following the removal of the cyst, the cord seemed to pulsate normally. I have never seen such a condition and am at a loss to explain it. As someone has suggested, perhaps a leak of cerebrospinal fluid had persisted into this extradural fascial space permitting the development of an adventitious bursa.

One and one-half years later, the patient had somewhat improved.

The findings at the reoperation, which was performed years later, are indicative of a contained pseudomeningocele, probably a complication of Adson's operation more than a decade prior.

*Case 3 (A. W. E.).* On June 13, 1917, Adson probably removed his first intramedullary tumor. He performed a C6–T3 laminectomy and notes

dura exposed and opened. Very little fluid escaped. Cord rotated in its bed to expose the ventral surface. Third right dorsal root divided in order to do this and the dentate ligament held (no tumor anteriorly). Dorsally, the cord was opened for a distance of 2 inches in the midline. Opening of the cord revealed several cysts apparently due to a degenerating tumor of gelatinous nature. The cord appeared normal both above and below the area of cystic degeneration. The condition was due to a cystic degenerating tumor of the cord, probably a glioma. Bleeding in cord substance easily controlled. There was considerable trauma to the dorsal surface of the cord when attempts were made to evacuate the cysts.

Adson concluded "diagnosis questionable," although the description fits an intramedullary ependymoma.

*Case 4 (G. H.).* This 21-year-old woman presented with symptoms of paralysis involving the lower extremities, bladder, and bowels that localized to the lower cervi-



## Adson spinal tumors

cal/upper thoracic spinal cord. On August 6, 1917, Adson exposed C6–T3.

The dura was opened and cord partially rotated in its bed – a dural tumor could not be demonstrated. After making the exposure, the dura was found to bulge to a marked degree and had a cystic feel. When opened, the spinal cord immediately extruded through the opening. Upon opening the cord, the tumor presented in the form of a brown cystic necrotic mass. Considerable brown, thick, gelatinous fluid escaped. The tumor did not have a definite outline or cleavage and could not be enucleated. Exposed spinal cord covered with non-adhesive animal membrane before making closure.

In September of the same year, he corresponded with the patient's referring physician from Detroit and reported that the patient "had not noticed any material improvement." In 1948, more than 30 years after her operation, the patient mailed a letter to him stating: "I live as normal life as anyone can in a wheel-chair – even go flying. I have full use of my hands and arms, but from the 4th vertebrae down there is no feeling whatever."


### *Extramedullary Spinal Cord Tumors*

*Case 5 (W. A. M.).* On October 1917, Adson evaluated and subsequently operated on a 30-year-old man for a thoracic meningioma with distinct evidence of a Brown-Séquard lesion (right leg weakness and loss of pain and temperature sensations on the left side below the T-9 level). Sensation disturbances extended as high as the sixth thoracic segment before a normal area was reached. Sensation to touch was normal on the left side. In his operative note, Adson recorded the ability to palpate the tumor through the dura mater after laminectomy at T-6. He removed the extramedullary mass without difficulties, resected the affected dura, and closed the defect with a fascial graft. This case has been separately reported as Adson's first laminectomy and therefore attracted some attention and fame.<sup>64</sup> Adson's records indicate the opposite, and prove that he had already performed several laminectomies for spinal tumors that year. The overstatement of the case might be related to the presence of visiting physicians from the British (Sir Berkeley Moynihan), the French (Dr. Duval), and Italian armies (Dr. Bastianelli) during the case (Fig. 2). The patient did well and Adson was so pleased with the patient's recovery that he invited him to accompany him to scientific meetings in Duluth, Minnesota, in August 1918 and Rochester, Minnesota, in October 1921, where Adson presented his case. Adson's letter to his patient in August 1918 reads:

You know as well as we do that spinal cord surgery is more or less a closed book, and that we have to convince a few people that something can be done for paralyzed individuals. We shall be glad to cover your railroad expenses and hotel bills while there.

### *Technical Aspects of Adson's Spinal Tumor Surgery*

Many principles currently applied in spinal tumor surgery have a long tradition. Aside from reporting clinical and pathological aspects in the patients treated, Adson emphasized the technical aspects of spinal tumor surgery in several of his publications.<sup>2,6,9,10,12–14</sup> Ether was the an-



**Fig. 2.** Left: Portrait of 35-year-old Alfred W. Adson. Right: Visitors Sir Berkeley Moynihan (standing on the right) and Dr. Raffaele Bastianelli (on the left).

esthetic of choice in the majority of cases. In morbidly obese patients and in those with high surgical risk, local, paravertebral anesthesia was used. This also allowed continuous examination of the patient at a time before neuromonitoring became available.<sup>14</sup> The laminectomy was performed in standard fashion. To preserve stability and avoid deformity, Adson advocated unilateral laminectomies in the cervical region.<sup>14</sup> Adson also found that unilateral laminectomy decreased bleeding and the frequency of shock.<sup>4,7</sup>

Technical pearls include the division of the dorsal root to rotate the cord or the application of animal membrane to close dural defects. In his early publications and in his medical records, he did not indicate the type of animal. Later he disclosed the secret. He used Cargile membrane, peritoneum of the ox, for this purpose.<sup>12</sup> Muscles and skin were closed in multiple layers with catgut. Generally he preferred 1-stage operations, even though he had to perform surgery in multiple stages due to the extensiveness of the lesions in numerous patients.<sup>12</sup> Postoperatively, patients were kept prone with the head lower than the surgical site for 3–4 days, and then the patient was turned to the side and laid on his or her back for 10–12 days after surgery to enhance wound healing and decrease CSF leakage, particularly if the dura mater was left open after intradural surgery. After 2 weeks the patient was allowed to sit up.<sup>14</sup> Avoiding catheterization was important for the prevention of postoperative cystitis and pyelonephritis, but if catheterization was necessary, care was taken to change the catheter after several days while acid sodium phosphate and urotropin were administered.<sup>4</sup>

## Discussion

Between 1919<sup>6</sup> and 1952,<sup>5</sup> Adson published 19 manuscripts related to the spinal cord and spinal tumors. His publication record demonstrates his great experience with this pathology and underlines his significant value as an important spinal tumor surgeon of the day. Nevertheless, surgery on tumors of the spine was performed long before, with the first reports dating back to the mid-18th century.

The French pathologist Le Cat in 1765 and the Italian anatomist Morgagni in 1761 provided the first accounts of

cord tumors.<sup>45,46</sup> Morgagni was one of the first to establish a relationship between a lesion in a particular location of the CNS and a neurological deficit by correlating lower-extremity paralysis with spinal cord dysfunction. In his publication, he referred to a case reported by Cowper and Saltzmann, probably an example of Pott disease rather than neoplasia.<sup>63,74</sup> Centuries prior, Galen of Pergamon (CE 129–199) had investigated spinal cord transection at various levels and corresponding neurological deficits.<sup>62</sup> Several reports of spinal tumors followed at the end of the 18th and 19th centuries.<sup>18,19,22,26,47,54,66</sup> As detailed in his publication from 1895,<sup>73</sup> in 1874 von Leyden was the first to propose that spinal tumors might be amenable to surgery, but surgery was actually not attempted until 1883 when Macewen performed thoracic laminectomies for resection of a “fibrous neoplasm of the theca,” probably a meningioma, in a patient with complete motor and sensory paralysis and bowel and bladder dysfunction. The patient supposedly made a complete functional recovery.<sup>63,71,73,74</sup> Adson<sup>6</sup> and others<sup>28</sup> credited Horsley with the first spinal tumor resection. In 1887 Horsley resected a meningioma, which resulted in recovery of the patient.<sup>35</sup> As told by Walker,<sup>74</sup> at first Horsley did not find the lesion at the expected level, but eventually, on the recommendation of his assistant Ballance that the lesion might in fact be a level higher than the clinical evaluation suggested, he found and removed the tumor. In 1888 Horsley performed a second case, but the patient died shortly after the operation. The report by Gowers and Horsley was certainly a milestone in the history of surgery on spinal tumors. The report also drew much attention from other areas in the medical field and received more publicity than Macewen’s case. For the first time, surgery had proved to be a viable option for the treatment of this entity.

Thorburn,<sup>65</sup> Abbe,<sup>1</sup> Roy,<sup>59</sup> Laquer,<sup>44</sup> Caponotto and Pescarolo,<sup>17</sup> Zavaleta,<sup>76</sup> Eskridge and Freeman,<sup>32</sup> Schultze,<sup>60</sup> Putnam and Warren,<sup>55</sup> Henschen and Lennander,<sup>37</sup> Krause,<sup>42</sup> Oppenheim and colleagues,<sup>48–52</sup> and Cushing<sup>23,24</sup> all contributed to the literature on the surgical treatment of spinal cord tumors, even though the uncertainty of a correct histological character of the mass confounds the literature; infectious diseases involving the spine (like tuberculosis and syphilis) were prevalent, and the actual nature of true neoplasms was frequently unclear.<sup>1,27,39,48,74</sup>

The first attempts to resect an intramedullary spinal cord tumor were undertaken by Fenger, reported by Church and Eisendrath in 1892,<sup>20</sup> and Cushing in 1905 (as related by Walker).<sup>74</sup> In Fenger’s case, a well-defined “spindle-celled sarcoma” was removed from the posterior half of the cord. Unfortunately, the patient became septic.<sup>20,55</sup> Cushing removed a small piece of an intramedullary glioma by incising the posterior funiculus, and the patient improved.<sup>25</sup> The first successful removal of an intramedullary tumor, a “neurofibrosarcoma,” was performed in 1907 by von Eiselsberg and Ranzi,<sup>21,70</sup> only 4 years after von Leyden stated that intramedullary tumors are not to be touched.<sup>21,58,70,72</sup> Even though this case is widely considered the first successful intramedullary tumor removal, it was probably Krause who first resected a lesion, infectious in origin, from the spinal cord. He removed a pea-

sized tuberculoma from the thoracic spine, which resulted in significant improvement.<sup>58</sup> Table 2 summarizes the first case reports on intramedullary spinal tumor surgery. Nine patients had benefited from surgery (see von Eiselsberg Cases I<sup>21,70</sup> and II,<sup>57,68,69</sup> Cushing,<sup>25</sup> Veraguth and Brun,<sup>67,68</sup> Elsberg and Beer,<sup>31</sup> Krause,<sup>39</sup> Reichmann-Röpke,<sup>56,57</sup> Schultze,<sup>61</sup> and Rothmann<sup>58</sup> [case reported by Marburg]), whereas 4 patients died (see Krauss,<sup>43</sup> Brun,<sup>15</sup> Elsberg and Beer,<sup>31</sup> and Krause<sup>39</sup>).

To counteract the high risk related to intramedullary surgery, Elsberg advocated a 2-stage approach for the removal of intramedullary spinal tumors, a concept he more or less discovered incidentally. In that case, after localization of the tumor and incision of the cord, the patient worsened and surgery was aborted. One week later a second operation was performed, which revealed a large gliosarcoma lying almost outside of the cord, and the patient made an impressive recovery.<sup>31</sup> Brun<sup>15,67</sup> and Krause<sup>40,41</sup> also discussed the utility of a 2-stage approach for intramedullary tumors. Given the close temporal relationship to Elsberg’s paper, the idea of a 2-stage approach for intramedullary tumors might actually have been developed independently by these authors. Von Eiselsberg did not favor the 2-stage approach, and criticized Elsberg’s paradigm.<sup>69</sup> In the years of the second decade of the 20th century, surgery was also common for intramedullary tumors.<sup>33,51</sup> Von Eiselsberg’s overly optimistic statement from 1917 that the mortality from surgery on intramedullary tumors was considered equivalent to that from extramedullary tumors exemplifies the progress in the treatment of this disease over just 1 decade.<sup>69</sup>

#### *Adson’s Contributions to Spinal Tumor Surgery*

In 1919, Adson described 16 patients who underwent laminectomies for spinal cord lesions beginning in 1917 (see illustrative cases, Table 1).<sup>6</sup> Of these 16 patients, half had extramedullary and half had intramedullary lesions, of which 3 were actually meningomyelitis. He found that two-thirds of patients improved after surgery and suggested that exploratory laminectomy was warranted because it is the only way to determine if a tumor is present and potentially removable. Under Adson’s leadership, surgical treatment of spinal cord tumors at the Mayo Clinic improved significantly in just a few years. Of the 23 patients who underwent surgery prior to 1916, only 22% had complete resection and in 39% no tumor was found. From 1916 to 1920, he performed operations in 39 patients and achieved complete removal in 51% and cure or improvement in 56%. The rate of negative exploration dropped to 13%.<sup>8</sup>

Just a few years into his practice, Adson reported an impressive number of 112 operated cases. A systematic review found that tumor location, duration of symptoms, nerve root pain, and spinal fluid findings including xanthochromia, cell count, and globulin were important signs and indicative of success of recovery. In 76% of cases a tumor was found, and 56% of those had improvement. The mean follow-up duration was almost 3 years. Adson wrote to his patients to obtain follow-up data, and most replied. He concluded that the outcome in the series may have been even better, because patients who are well may be less likely to reply.<sup>14</sup> Adson also published on specific

TABLE 2: Initial experience with intramedullary tumor surgery around the beginning of the 20th century\*

Authors & Year	Age (yrs), Sex	Signs & Symptoms	Level	Pathology	Intervention/Surgical Findings	Outcome
von Eiselsberg & Marburg, 1917 <sup>69</sup> von Eiselsberg & Ranzi, 1913 <sup>70</sup> Clairmont, 1907	29 (27 <sup>70</sup> ), F	course of disease: ~0.5 yr sensation: reduced to touch & painful stimuli up to 3 fingers above umbilicus motor: contractions in hip & knee joints	T-6	neurofibrosarcoma (4 x 1 cm)	11/13/1907: T7-10 laminectomy at T-6; rt bluish, oval tumor covered by thin cord layer	slow improvement; 22 mos post-op ambulatory, normal sensation, no urinary difficulties 1913: patient "completely cured" <sup>70</sup> 1917: no complaints <sup>69</sup>
von Eiselsberg & Marburg, 1917 von Eiselsberg & Ranzi, 1913 <sup>70</sup> Rothmann, 1913	36, F	course of disease: ~3 mos sensation: paresthesias in lt hand, tender upper cervical vertebrae motor: paresis of lt recurrent laryngeal nerve	C4-6	cystic tumor	11/25/1910: C4-6 laminectomy & extirpation of intramedullary cyst	rapid improvement 1913: no difficulties walking, no changes of sensation 1914: working <sup>70</sup>
Krauss, 1910 Cushing, 1910	36, M	sensation: anesthesia up to mammillae motor: LE paresis, neurogenic bladder	T3-4	tuberculoma  glioma	extirpation of intramedullary "tumor"  incision of pst funiculus & extirpation of small tumor component	death  improvement
Veraguth & Brun, 1910, <sup>67</sup> 1916 <sup>68</sup>	32, M	course of disease: ~2 mos sensation: neck pain, arm paresthesia, lt hand stereognosis, rt dysesthesia motor: weakness (arms), paresis (lt arm), spasticity (lt leg), lt hemiparesis, lt phrenic paresis	C4-5	solitary tuberculoma	11/18/1910: C3-4 laminectomy; edematous spinal cord, small mark lt pst, extirpation of tumor; reop after 4 wks <sup>68</sup>	rapid improvement; cured & discharged 56 days postop
Brun, 1911	28, M	course of disease: ~3 mos sensation: hypesthesia up to T-8 motor: lt LE paresis	T-6	subpial glioma & glioma of lt pst funiculus at T-4	09/21/1910: T6-7 laminectomy & extirpation of tumor located subpial, lt pst	death
Eisberg & Beer, 1911	42, M	course of disease: ~3 yrs sensation: neck & arm pain, anesthesia up to mammillae motor: LE paresis	C5-7	gliosarcoma (5.3 x 2 cm; soft)	01/13/1910: C4-T1 laminectomy & incision of edematous pst funiculi 01/20/1910: extirpation of expelled, rubiginous tumor	rapid improvement; 2 mos postop ambulatory, normal sensation; able to write 8 mos postop
Krause, 1911	40, F	course of disease: ~2 yrs sensation: arm pain, anesthesia up to mammillae motor: quadriplegia, neurogenic bladder, hindered respiration	C4-6	cystic glioma (4.5 x 2 cm)	11/19/1910: C4-T1 laminectomy & extirpation of tumor	death
Krause, 1911	13, M	course of disease: ~5 mos sensation: loss of temperature sensation on rt up to inguinal ligament motor: LE paresis	T8-9	glioma	01/05/1911: T7-8 laminectomy & longitudinal incision of pst funiculi; expulsion of gliomatous mass	unchanged after mos; discharged 04/20/1911
	32, M	course of disease: a few wks sensation: hypesthesia below xiphoid process motor: LE paresis, no control over bladder, rectum	T-4	solitary tuberculoma	T4-5 laminectomy & incomplete removal of gray-reddish mass	death

(continued)



TABLE 2: Initial experience with intramedullary tumor surgery around the beginning of the 20th century\* (continued)

Authors & Year	Age (yrs), Sex	Signs & Symptoms	Level	Pathology	Intervention/Surgical Findings	Outcome
Reichmann, 1912, Röpke, 1911	20, M	course of disease: ~4 yrs sensation: anesthesia up to umbilicus motor: LE paresis	T5-9	multiple neurofibromas	07/07/1910: T5-10 laminectomy & removal of 2 extramedullary tumors w/ extirpation of intramedullary, cherry-sized tumor in pst funiculi	slow improvement; 8 mos postop ambulation w/ crutches, slight ataxia, & later independent ambulation
Schulze, 1912	29, M	course of disease: ~8 mos sensation: tender C-6 vertebra motor: atrophy of it hand, Brown-Séquard	C-6	angioma	02/19/1912: laminectomy & extirpation of tumor located in pst funiculi	almost complete cure
Rothmann, 1913				intramedullary tumor		cure

\* LE = lower extremity; pst = posterior.

characteristics of 12 tumors involving the conus and cauda equina and how they are unique due to their symptoms and the surgical technique required to treat them.<sup>53</sup>

In 1924 Adson's series had grown to 151 patients, and his rate of complete tumor removal was approximately 50%. In 25% of cases, he accomplished partial removal. Approximately two-thirds of patients with complete or partial removal (62%) had a satisfactory outcome. Adson's experience was published 1 year prior to Elsberg's landmark paper on surgery of spinal tumors,<sup>30</sup> and underlines Adson's critical contributions to the field. Elsberg, one of the most renowned spinal tumor surgeons at the time, reported on 119 cases. In approximately 80% of patients the tumor could be removed, and 72% of those patients had a satisfactory outcome. Adson's lower rate of satisfactory outcomes can be attributed to a much higher rate of intramedullary tumors in his series. Interestingly, Adson operated on 32 patients (21%) in whom no tumor was found or the tumor was found later, which compares unfavorably to Elsberg, who claimed to have not found a tumor on first attempt in only 2% of cases in his series. The credibility of this number is in question because just years earlier, Elsberg's rate was 36%.<sup>29</sup>

In 1931, Adson and company (see Kernohan et al.)<sup>38</sup> proposed a classification of intramedullary spinal tumors based on clinical, surgical, and pathological features. The authors also described the unique correlation between intramedullary spinal tumors and syringomyelia.

Over his career Adson developed an algorithm for spinal tumors emphasizing the importance of distinguishing features observed on neurological examination. He adapted the "three cycle" theory of spinal tumor symptomatology, a theory originally described by Frazier and Allen<sup>34</sup> suggesting that all spinal tumors arising from nerve roots, blood vessels, or meninges invariably cause pain (root cycle) followed by partial spinal cord compression (Brown-Séquard syndrome), and eventually complete loss of spinal cord function below the level of the lesion. He also discussed the value of lumbar puncture, CSF analysis, plain radiographs, and Lipiodol (a radiopaque oil) injection for radiographic studies used for diagnosis.<sup>3,4,7,10,11</sup> Over the years Adson added to this algorithm.<sup>2,8-11</sup> He also suggested that trauma may be a risk factor for certain tumors<sup>2,12</sup> and advocated for unilateral laminectomy for tumors of the cervical region to prevent vertebrae from sliding forward. For large dumbbell neurofibromas of the thoracic region, he performed laminectomy followed by thoracotomy. He described and applied several techniques to improve the outcome of surgery. Electrocoagulation became available<sup>36</sup> to control bleeding, and dural repair with animal membrane was used to prevent entrance of blood into the arachnoid space and to close dural defects after meningioma resection, a practice applied frequently by surgeons at the time.<sup>12</sup> Gutta-percha, a rubbery substance derived from the latex of any of several tropical trees, was used to prevent refilling after opening of intramedullary cysts.<sup>12</sup> Adson refrained from operating on patients with metastatic tumors.<sup>12</sup>

With the advent of what was then called roentgenography used in neurosurgery, Camp, Adson, and Shugrue<sup>16</sup> characterized the radiographic appearance of spinal tumors.

## Adson spinal tumors

Adson and coworkers also reported an impressive series of 119 intramedullary tumors, including mostly ependymomas and astrocytomas.<sup>75</sup> Both tumors were found to present with a long duration of symptoms, and the operation consisted mostly of removal and partial removal or decompression, with some patients undergoing only biopsy. The authors also observed less aggressive behavior of spinal cord gliomas compared with gliomas of the brain. Patients with tumors higher in the cord fared best, whereas those with tumors of the conus had the worst survival rate, of approximately 5 years. This last paper was published in 1951, the year of Adson's death, and is a testament to his tremendous dedication and endless effort to contribute to the field of neurosurgery.

### Conclusions

Adson made significant contributions to all aspects of the management of spinal cord tumors. This publication will help in giving him late recognition for his work and establish him as one of the pioneers of spinal tumor surgery.

### Disclosure

Dr. Lanzino is a consultant for ev3/Covidien and for Stryker. The authors report no conflict of interest concerning the materials or methods used in this study or the findings specified in this paper.

Author contributions to the study and manuscript preparation include the following. Conception and design: Griessenauer, Tubbs, Lanzino. Acquisition of data: Griessenauer, Boes, Lanzino. Analysis and interpretation of data: Griessenauer, Tubbs, Boes, Lanzino. Drafting the article: Griessenauer, Raborn. Critically revising the article: all authors. Reviewed submitted version of manuscript: all authors. Approved the final version of the manuscript on behalf of all authors: Griessenauer. Statistical analysis: Tubbs. Administrative/technical/material support: Griessenauer, Raborn, Boes, Lanzino.

### References

1. Abbe R: Spinal surgery: a report of eight cases. **Med Rec** **38**: 85–92, 1890
2. Adson AW: The diagnosis and treatment of surgical lesions of the spinal cord. **Postgrad Med**:125–135, 1935
3. Adson AW: Diagnosis and treatment of tumors of the spinal cord. **Lancet** **54**:464–466, 478, 1934
4. Adson AW: Diagnosis and treatment of tumors of the spinal cord. **Northwest Med** **14**:309–317, 1925
5. Adson AW: Neurosurgical conditions of brain and spinal cord. **GP** **5**:45–54, 1952
6. Adson AW: Results of the surgical treatment of spinal cord tumors. **Minn Med** **2**:205–210, 1919
7. Adson AW: Spinal cord tumors. **Surg Gynecol Obstet** **39**: 109–110, 1924
8. Adson AW: Surgery of spinal cord tumors. **Lancet** **40**:637–638, 1920
9. Adson AW: Surgical lesions of the spinal cord; diagnosis and treatment. **Miss Valley Med J** **71**:117–123, 1949
10. Adson AW: Tumors of the spinal cord: diagnosis and treatment. **Tex State J Med** **28**:354–360, 1932
11. Adson AW: Tumors of the spinal cord: surgical treatment and results. **Minn Med** **7**:79–83, 1924
12. Adson AW: Tumors of the spinal cord; symptoms; differential diagnosis and treatment. **Rocky Mt Med J** **45**:989–999, 1948
13. Adson AW: Tumors of the spinal cord: diagnosis and treatment. **Can Med Assoc J** **40**:448–454, 1939
14. Adson AW, Ott WO: Results of the removal of tumors of the spinal cord. **Arch Neurol Psychiatry** **8**:520–537, 1922
15. Brun H: Über einen zweiten Fall von operativer Entfernung eines subpial gelegenen Rückenmarkstumors. **Deutsche Zeitschr Chir** **110**:487–506, 1911
16. Camp JD, Adson AW, Shugrue JJ: Roentgenographic findings associated with tumors of the spinal column, spinal cord, and associated tissues. **Am J Cancer** **17**:348–372, 1933
17. Caponotto A, Pescarolo B: Estirpazione di un tumore intradurale del canale rachideo. **Riforma Med** **8**:543–549, 1892
18. Charcot JM: Hemiparaplegia determinee par une tumeur qui comprimait la moitie gaucuche de la moelle epiniere audessus du renflement dorsolumbaire. **Arch Physiol** **2**:291, 1869
19. Chaussier J: Paralyse des membres inferieurs causee par un kyste vermineux penetrant de la poitrine dans le rachis. **J Med Chir Pharmacie** **14**:231–237, 1807
20. Church A, Eisendrath DW: A contribution to spinal cord surgery. **Am J Med Sci** **103**:395–412, 1892
21. Clairmont: 3. Jahresversammlung d. Nervenärzte in Wien. **Deutsche Zeitschr f Nervenheilk** **Bd 38**, S. 236, 1907 [unverified]
22. Cruveilhier J: Une tumeur au niveau des dernieres vertebres lombaires; sa dissection met à nu la moelle epiniere. **Bull Soc Anat Paris** **7**:47–70, 1832
23. Cushing H: IV. Intradural tumor of the cervical meninges. With early restoration of function in the cord after removal of the tumor. **Ann Surg** **39**:934–955, 1904
24. Cushing H: The special field of neurological surgery. **Bull Johns Hopkins Hosp** **16**:77–87, 1905
25. Cushing H: The special field of neurological surgery: five years later. **Bull Johns Hop Hosp** **21**:325–339, 1910
26. Duplay A: Observations de maladies des centres nerveux; recueilliés à l'hospital de la Pitié, dans le service de M. le professeur Rostan. **Arch Gen Med (2nd er)** **6**:478–499, 1834
27. Ebers P: Fall von operiertem Rückenmarkstumors. **Dtsch Med Wochenschr** **39**:70–71, 1913
28. Ellis H: The early days of spinal tumour surgery. **J Perioper Pract** **21**:428–429, 2011
29. Elsberg CA: Concerning spinal cord tumors and their surgical treatment. **Am Jour Med Sc**:194–207, 1920
30. Elsberg CA: Some aspects of the diagnosis and surgical treatment of tumors of the spinal cord: with a study of the end results in a series of 119 operations. **Ann Surg** **81**:1057–1073, 1925
31. Elsberg CA, Beer E: The operability of intramedullary tumors of the spinal cord. A report of two operations with remarks upon the extrusion of intraspinal tumors. **Am J Med Sci** **142**:630–647, 1911
32. Eskridge JT, Freeman L: Intradural spinal tumor opposite the body of the fourth dorsal vertebra; complete paralysis of the parts below the lesion; operation; recovery, with ability to walk without assistance within three months. **Phil Med J** **2**:1236–1243, 1898
33. Förster O: Fall von intramedullärem Tumor, erfolgreich operiert. **Berl Klin Wochenschr** **14**:238, 1917
34. Frazier CH, Allen AR: Spinal tumors, in: **Surgery of the Spine and Spinal Cord**. New York: D Appleton & Co, 1918, pp 498–607
35. Gowers WR, Horsley V: A case of tumour of the spinal cord. Removal; recovery. **Med Chir Trans** **71**:377–428, 11, 1888
36. Greenwood J Jr: Two point interpolar coagulation. A new principle and instrument for applying coagulation current in neurosurgery. **Am J Surg** **50**:267–270, 1940
37. Henschen SE, Lennander KG: Rückenmarkstumors, mit Erfolg extirpiert. **Mitteilungen aus den Grenzgebieten der Medizin und Chirurgie** **10**:673–712, 1902
38. Kernohan JW, Woltman HW, Adson AW: Intramedullary tumors of the spinal cord. A review of 51 cases with an attempt at histologic classification. **Arch Neurol Psychiatry** **25**:679–699, 1931
39. Krause F: **Chirurgie des Gehirns und Rückenmarks Nach**



- Eigenen Erfahrungen.** Berlin: Urban & Schwarzenberg, 1911, Vol 2
40. Krause F: Erfahrungen bei 26 operativen Fällen von Rückenmarkstumoren mit Projektionen. **Dtsch Z Nervenheilkd** **36**: 106–113, 1908
  41. Krause F: Operationen am Rückenmark und an den peripheren Nerven. **Zeitschr Ärztl Fortbildung Nr. 7 und 8**, 1909
  42. Krause F: Zur Segmentdiagnose der Rückenmarksgeschülste, nebst einem neuen durch Operation geheilten Fall. **Berl Klin Wochenschr** **38**:541, 583, 604, 1901
  43. Krauss WC: Three cases of spinal cord tumors observed within a period of ten days; observations on the behavior of the cerebrospinal fluid. **J Nerv Ment Dis** **4**:222–236, 1910
  44. Laquer L: Ueber Compression der Cauda equina; Compressions-Erscheinungen im Gebiete der Lumbal und Sacralwurzeln; Eröffnung des Canalis sacralis; Exstirpation eines Lymphangioma cavernosum; Beseitigung fast aller Beschwerden. **Neurol Centralbl** **10**:193–204, 1891
  45. Le Cat CN: **Traité de l'existence, de la nature et des propriétés du fluide des nerfs, et principalement de son action dans le mouvement musculaire: Ouvrage couronné en 1753 par l'Académie de Berlin: suivi des dissertations sur la sensibilité des meninges, des tendons etc, l'insensibilité du cerveau, la structure des nerfs, l'irritabilité hallerienne.** A Berlin, 1765
  46. Morgagni GB: **De Sedibus, et causis morborum per anatomicen indagatis libri quinque.** Venice: Typographia Remondini, 1761, p 23
  47. Ollivier CP: **De la Moelle Epinière et des ses Maladies. Ouvrage Couronné par la Société Royale de Médecine de Marseille dans sa Séance Publique du 23 Octobre 1823, Revue Corrigée et Augmentée. 3rd ed. 2 Vols.** Paris: Méquignon-Marvis & Fils, 1837
  48. Oppenheim H: Diagnose und Behandlung der Geschwülste innerhalb des Wirbelkanals. **Dtsch Med Wochenschr** **35**: 1905–1911, 1909
  49. Oppenheim H: **Lehrbuch der Nervenkrankheiten für Ärzte und Studierende.** Berlin: S. Karger, 1908
  50. Oppenheim H: Über einen Operativ behandelten Fall von Rückenmarkstumor. **Berliner Klin Wochenschr** **39**:905–908, 1902
  51. Oppenheim H, Borchardt M: Beitrag zur chirurgischen Therapie des "intramedullären Rückenmarkstumors." **Mitt Grenzgeb Med Chir** **36**:811–826, 1913
  52. Oppenheim H, Krause F: Über die operative Behandlung von Hirn- und Rückenmarkstumoren. **Verh Ges Dtscher Natur Ärzte** **2**:194–202, 1906
  53. Ott WO, Adson AW: The diagnosis and treatment of tumors of the spinal cord, involving the conus and cauda equina. **New Orleans Med Surg J** **76**:169–172, 1923
  54. Phillips T: An account of a tumor situated on the lumbar vertebrae, of a very extraordinary size and singular appearance, which ensued from a fall (with an engraving). **N Lond Med J** **1**:144–148, 1792
  55. Putnam JJ, Warren JC: The surgical treatment of tumors within the spinal canal. **Am J Med Sci** **118**:377–393, 1899
  56. Reichmann V: Über einen operativ geheilten Fall von mehrfachen Rückenmarksgeschwülsten bei Recklinghausenscher Krankheit nebst Bemerkungen über das chemische und cytologische Verhalten des Liquor cerebrospinalis bei Gehirn- und Rückenmarksgeschwülsten. **Dtsch Zeitschr Nervenheilk** **44**: 95–110, 1912
  57. Röpke W: Ueber die operative Entfernung intramedulläre Rückenmarkstumoren, zugleich ein Beitrag zur Kenntniss über die Beschaffenheit des Lumbalpunktats bei Rückenmarkstumoren. **Arch Klin Chir** **96**:963–980, 1911
  58. Rothmann M: Gegenwart und Zukunft der Rückenmarkschirurgie. **Berliner Klin Wochenschr** **12**:528–533, 1913
  59. Roy CD: Report of a case of spinal exsection and removal of a tumor from the cord. **South M Rec** **20**:564–566, 1890
  60. Schultze F: Ueber Diagnose und erfolgreiche Behandlung von Geschwülsten der Rückenmarkshäute. **Dtsch Z Nervenheilkd** **16**:114–139, 1899
  61. Schultze F: Weiterer Beitrag zur Diagnose und operativen Behandlung von Geschwülsten der Rückenmarkshäute und des Rückenmarks. Erfolgreiche Operation eines intramedullären Tumors. **Dtsch Med Wochenschr** **36**:1676–1679, 1912
  62. Singer CJ: **Galen on Anatomical Procedures: De Anatomicis Administrationibus.** London: Oxford University Press, 1956
  63. Sonntag VKH: History of degenerative and traumatic diseases of the spine, in Greenblatt SH, Dagi TF, Epstein MH (eds): **A History of Neurosurgery: In Its Scientific and Professional Contexts.** Park Ridge, IL: American Association of Neurological Surgeons, 1997, pp 355–371
  64. Spinner RJ, Al-Rodhan NR, Piepgras DG: 100 years of neurological surgery at the Mayo Clinic. **Neurosurgery** **49**:438–446, 2001
  65. Thornburn W: **A Contribution to Surgery of the Spinal Cord.** London: Charles Griffin & Co., 1889
  66. Velpeau M: Observation sur une maladie de la moelle épinière tendant à démontrer l'isolement des fonctions des racines sensibles et motrices des nerfs; recueillie à la Clinique et sous les yeux de M. le professeur Bougnon. **Arch Gen Med** **7**:68–82, 1825
  67. Veraguth O, Brun H: Subpialer, makroskopisch intramedullärer Solitär tuberkel in der Höhe des 4. und 5. Cervicalsegmentes. Operation, Heilung. **Korrespondenzblatt für Schweizer Ärzte** **33**, 1910
  68. Veraguth O, Brun H: Weiterer Beitrag zur Klinik und Chirurgie des intramedullären Konglomerattuberkels. **Korrespondenzblatt für Schweizer Ärzte** **46**:385, 424, 1916
  69. von Eiselsberg A, Marburg O: Zur Frage der Operabilität intramedullärer Rückenmarkstumoren. **Arch Psychiatr Nervenkr** **59**:453–461, 1917
  70. von Eiselsberg AF, Ranzi E: Über die chirurgische Behandlung der Hirn- und Rückenmarkstumoren. **Arch Klin Chir** **102**:309–468, 1913
  71. von Leyden E: **Klinik der Rückenmarks-Krankheiten.** Berlin: Verlag von August Hirschwald, 1874
  72. von Leyden E, Goldscheider A: **Die Erkrankungen des Rückenmarks und der Medulla oblongata.** Vienna: A Hölder, 1903
  73. von Leyden E, Goldscheider A: **Die Rückenmarksgeschwülste. In Die Erkrankungen des Rückenmarks und der Medulla oblongata.** Berlin: A Hölder, 1895, Vol 3
  74. Walker AE: **A History of Neurological Surgery.** Baltimore: Williams & Wilkins, 1951
  75. Woltman HW, Kernohan JW, Adson AW, Craig WM: Intramedullary tumors of spinal cord and gliomas of intradural portion of filum terminale; fate of patients who have these tumors. **AMA Arch Neurol Psychiatry** **65**:378–395, 1951
  76. Zavaleta MA: Reseccion de vertebrae. **An Cir Med Argent** **15**:497–502, 1892

Manuscript submitted March 4, 2013.

Accepted September 12, 2013.

Please include this information when citing this paper: published online October 18, 2013; DOI: 10.3171/2013.9.SPINE13220.

Address correspondence to: Christoph J. Griessenauer, M.D., 1530 3rd Ave. S., Birmingham, AL 35294. email: cgriessenauer@uabmc.edu.