

European Association of Echocardiography recommendations for the assessment of valvular regurgitation. Part 1: aortic and pulmonary regurgitation (native valve disease)

Patrizio Lancellotti (Chair)^{1*}, Christophe Tribouilloy², Andreas Hagendorff³, Luis Moura⁴, Bogdan A. Popescu⁵, Eustachio Agricola⁶, Jean-Luc Monin⁷, Luc A. Pierard¹, Luigi Badano⁸, and Jose L. Zamorano⁹ on behalf of the European Association of Echocardiography

Document Reviewers: Rosa Sicari^a, Alec Vahanian^b, and Jos R.T.C. Roelandt^c

¹Department of Cardiology, Valvular Disease Clinic, University Hospital, Université de Liège, CHU du Sart Tilman, 4000 Liège, Belgium; ²Department of Cardiology, University Hospital of Amiens, Picardie, France; ³Department für Innere Medizin, Kardiologie, Leipzig, Germany; ⁴Oporto Medical School, Portugal; ⁵Department of Cardiology, 'Carol Davila' University of Medicine and Pharmacy, Bucharest, Romania; ⁶Division of Noninvasive Cardiology, San Raffaele Hospital, IRCCS, Milan, Italy; ⁷Cardiologie/maladie valvulaires cardiaques Laboratoire d'échocardiographie CHU Henri Mondor, Créteil, France; ⁸Department of Cardiology, University of Padova, Padova, Italy; ⁹University Clinic San Carlos, Madrid, Spain

^aInstitute of Clinical Physiology, PISA, Italy; ^bHôpital Bichat, Paris, France; and ^cDepartment of Cardiology, Thoraxcentre, Erasmus MC, Rotterdam, The Netherlands

Received 11 February 2010; accepted after revision 15 February 2010

Valvular regurgitation represents an important cause of cardiovascular morbidity and mortality. Echocardiography has become the primary non-invasive imaging method for the evaluation of valvular regurgitation. The echocardiographic assessment of valvular regurgitation should integrate quantification of the regurgitation, assessment of the valve anatomy, and function as well as the consequences of valvular disease on cardiac chambers. In clinical practice, the management of patients with valvular regurgitation thus largely integrates the results of echocardiography. It is crucial to provide standards that aim at establishing a baseline list of measurements to be performed when assessing regurgitation.

Keywords

Valvular regurgitation • Echocardiography • Recommendations • Aortic valve • Pulmonary valve

Introduction

Valvular regurgitation is increasingly prevalent and represents an important cause of cardiovascular morbidity and mortality.¹ Echocardiography has become the primary non-invasive imaging method for the evaluation of valvular regurgitation. It provides detailed anatomic and functional information and clarifies the mechanisms that play a role in valvular regurgitation. Doppler echocardiography not only detects the presence of regurgitation but also permits to understand mechanisms of regurgitation and quantification of its severity and repercussions. In clinical practice, the management of patients with valvular regurgitation largely

integrates the results of echocardiography. It is thus crucial to provide standards that aim at establishing a baseline list of measurements to be performed when assessing regurgitation. Practically, the evaluation of valvular regurgitation requires using different echocardiographic modalities [M-mode, Doppler, two-/three-dimensional (2D/3D), and transoesophageal echocardiography (TEE)], should integrate multiple parameters, and should be faced with clinical data.

This document results from the review of the literature and is based on a consensus of experts. To maintain its originality, it has been divided into two parts: (i) general recommendations and aortic regurgitation (AR) and pulmonary regurgitation (PR),

* Corresponding author. Tel: +32 4 366 71 94, Fax: +32 4 366 71 95, Email: plancellotti@chu.ulg.ac.be

Published on behalf of the European Society of Cardiology. All rights reserved. © The Author 2010. For permissions please email: journals.permissions@oxfordjournals.org.

and (ii) mitral (MR) and tricuspid regurgitation (TR). Both discuss the recommended approaches for data acquisition and interpretation in order to minimize observer variability, facilitate inter-study comparison, and maintain consistency among echocardiographic laboratories. Present recommendations are not limited to a basic quantification of valvular regurgitation but provide elements on the assessment of ventricular performance, cardiac chambers size, and anatomy of valve. Modern parameters derived from advanced echocardiographic techniques as 3D, tissue Doppler, and strain imaging are also provided when relevant.

General recommendations

Valvular regurgitation or insufficiency is defined as the presence of backward or retrograde flow across a given closed cardiac valve.² With the advent of Doppler techniques, it is frequent to detect some degree of regurgitation even in the absence of valve lesion. Trivial regurgitation, particularly of the right-sided valve, should be considered as physiological. In other situations, a complete echocardiographic assessment is appropriate and should integrate quantification of the regurgitation, assessment of the valve anatomy and function, and the consequences of valvular disease on cardiac chambers. Practically, the quantification of regurgitation is based on the integration of a set of direct and indirect parameters. Indirect criteria are mainly represented by the impact of regurgitation on the cardiac size and function. Direct criteria derive from colour Doppler echocardiography.

In practice, the evaluation starts with two-dimensional (2D) echocardiography, which can orient readily to a severe regurgitation in the presence of a major valvular defect or to a minor leak when the valve anatomy and leaflet motion are normal. Then, a careful assessment of the regurgitant jet by colour Doppler, using multiple views, can rapidly diagnose minimal regurgitation, which requires *a priori* no further quantification. In other cases, the use of a more quantitative method is advised when feasible. In the second step, the impact of the regurgitation on the ventricles, the atrium, and the pulmonary artery pressures is estimated. Finally, the collected data are confronted with the individual clinical context in order to stratify the management and the follow-up.

Of note, the comprehensive haemodynamic evaluation of patients with complex valve disease, including full quantitation of valvular regurgitation, should be performed by echocardiographers with advanced training level and appropriate exposure to valvular heart disease patients, according to the EAE recommendations.³

Valve anatomy and function

Echocardiography provides a rapid overview of the cardiac structures and function. It allows a comprehensive evaluation of the aetiology and mechanisms of valvular regurgitation. The use of a common language for the valve analysis is strongly advocated. Instead of the cause of valvular regurgitation, the precise location of the involved leaflets/scallops, the lesion process (e.g. ruptured chordae), and the type of dysfunction (e.g. valve prolapse) should be described. The most frequently used classification of this dysfunction has been described by Carpentier, according to leaflet motion independently of the aetiology.⁴ Type I: the leaflet motion is normal, type II: increased and excessive leaflet mobility,

and type III: reduced leaflet motion. Such assessment offers direct clues as to the possibility of valve repair. The indications of TEE have decreased in parallel with the improvement of the transthoracic imaging quality. It is still recommended when the transthoracic approach is of non-diagnostic value or when further diagnostic refinement is required. The place of 3D transthoracic echocardiography (TTE) and especially 3D TEE in the evaluation of the valve morphology and function is growing. In experimented centres, 3D echocardiography is the advised approach. The current effort is to advance this technology from the research arena to general clinical practice.

Valve assessment: recommendations

- (1) TTE is recommended as the first-line imaging modality in valvular regurgitation.
- (2) TEE is advocated when TTE is of non-diagnostic value or when further diagnostic refinement is required.
- (3) 3D TEE or TTE is reasonable to provide additional information in patients with complex valve lesion.
- (4) TEE is not indicated in patients with a good-quality TTE except in the operating room when a valve surgery is performed.

Key point

Valve analysis should integrate the assessment of the aetiology, the lesion process, and the type of dysfunction.

Assessment of ventricular size and function

Valvular regurgitation creates a volume overload state. The duration and the severity of the regurgitation are the main determinants of the adaptive cardiac changes in response to volume overload. Three major physiopathological phases can be described: (i) acute phase, (ii) chronic compensated phase, and (iii) chronic decompensated phase. In chronic situation, the increased volume load is accompanied by a progressive increase in end-diastolic volume and eccentric hypertrophy to maintain forward stroke volume (SV). In mitral and TR, preload is increased whereas the afterload is normal or occasionally decreased in such a way that the ventricular emptying is facilitated. Conversely, in AR and PR, the afterload is increased resulting in additional concentric hypertrophy. Furthermore, the consequences of regurgitation on the ventricular volumes provide indirect signs on the chronicity and the severity of the regurgitation. In each type of valvular regurgitation, the prolonged burden of volume overload may result in ventricular dysfunction and irreversible myocardial damage.

Quantification of cardiac chamber size and function ranks among the most important step in the evaluation and management of patients with valvular regurgitation. Although, the scope of this document is not to fully discuss the assessment of ventricular performance, it provides a number of clues on how to quantify cardiac size and function in the context of valvular regurgitation.^{5,6}

Left-sided chambers

General recommendations are as follows: (i) images are best acquired at end-expiration (breath-hold) or during quiet respiration, (ii) avoid Valsalva manoeuvre which can degrade the image quality and alter cardiac volumes, (iii) at least 2–3 representative cardiac cycles are analysed in sinus rhythm and 3–5 in atrial fibrillation.

For the linear measurements of the left ventricular (LV) size, current guidelines on the management of valvular disease still refer to the leading edge method by using M-mode echocardiography (Figure 1A). Linear measurements from correctly aligned 2D are however particularly recommended in abnormally shaped LV, especially when it is impossible to obtain an M-mode line perpendicular to the LV long axis.

Linear dimensions from M-mode or 2D are not recommended for calculating LV volumes and ejection fraction. Unless 3D echocardiography is used, the 2D-based biplane (four- and two-chamber views) summation method of disc is recommended for the estimation of these parameters (Figure 1B and C). In contrast to 2D, 3D echocardiography makes no assumptions about the LV shape and avoids foreshortened views resulting in a similar accuracy with cardiac MRI regarding the assessment of LV mass and volumes. A common limitation of 2D/3D is the accurate visualization of the endocardial border. When <80% of the endocardial edge is adequately visualized, the use of contrast agents for endocardial border delineation improves inter-observer variability to a level obtained by MRI. This approach is advised in the case of poor visualization of the endocardial border.⁷

In volume overload situation, it should be emphasized that LV ejection fraction could be maintained in the low-normal range despite the presence of significant myocardial dysfunction. The LV ejection fraction is a load-dependent parameter and does not reflect myocardial contractility. This volume-based parameter represents the sum of the forward ejection fraction and the regurgitant volume. New parameters (tissue Doppler imaging and 2D speckle tracking) are currently available for a better assessment of LV function in overloaded ventricle.

Although the left atrial (LA) size is not included in the current guidelines, it is an important parameter reflecting the chronicity of volume overload and diastolic burden. By convention, LA size is determined from the parasternal long-axis view using either M-mode or 2D oriented plane. With this approach, the LA size using this single diameter may be underestimated because this chamber may enlarge longitudinally. Therefore, the LA diameter should also be measured from apical views (tip of the mitral valve to the posterior wall of the left atrium) (Figure 1D). Practically, the determination of LA volume is the best approach to evaluate the LA size and the biplane area-length method using the apical four- and two-chamber views is the recommended method. In experimented laboratories, LA volumes are best estimated by 3D echocardiography.

Right-sided chambers

The general recommendations and limitations of the method used are similar to the above. The normal right ventricle (RV) is a complex crescent-shaped structure wrapped around the LV.⁸ RV dimension is measured by M-mode echocardiography from the

parasternal long-axis view. Linear measurements by 2D are more accurate. By using the apical four-chamber view, the minor and long-axis diameters at end-systole and end-diastole are measured. Calculation of RV area based on single-plane echocardiographic methods correlates with RV ejection fraction but assumes constant relationship between the dimensions of the RV in two planes. 2D estimation of RV volumes and ejection fraction is based on the biplane Simpson method. A combination of apical four-chamber and subcostal RV outflow views is the most used. However, the determination of RV ejection fraction and volumes using 2D is more difficult and less reliable than for LV. In experimented laboratories, 3D echocardiography has shown to be as accurate as MRI for the assessment of RV volumes.⁹ As for the LV, the RV ejection fraction is a crude estimate of the RV function. Emerging techniques (i.e. tissue Doppler velocities or strain) could provide new indices of RV function.

LV size and function: recommendations

- (1) Quantitative assessment of LV diameters, volumes, and ejection fraction is mandatory.
- (2) 2D measurement of LV diameters is strongly advocated if the M-mode line cannot be placed perpendicular to the long axis of the LV.
- (3) The 2D-based biplane summation method of disc is the recommended approach for the estimation of LV volumes and ejection fraction.
- (4) 3D echo assessment of LV function is reasonable when possible.
- (5) Contrast echo is indicated in patients with poor acoustic window.
- (6) Qualitative assessment of LV function is not recommended.

Doppler methods

Colour flow Doppler

Doppler echocardiography is the most common technique for the detection and evaluation of valvular regurgitation. The analysis of the three components of the regurgitant jet with colour Doppler (flow convergence zone, vena contracta, and jet turbulence) has shown to significantly improve the overall accuracy of the estimation of the regurgitation severity. The assessment of the regurgitant jet in the downstream chamber, source of many errors, is however being replaced by the analysis of the vena contracta width and the flow convergence zone.

Colour flow imaging. The colour imaging of the regurgitant jet serves for a visual assessment of the regurgitation. Practically, the colour Doppler should be optimized to minimize the source of errors. The best rule of thumb is to standardize the instrument set-up within a given laboratory and leave these constant for all examinations. The colour scale is classically set at 50–60 cm/s or at the highest limit allowed by the machine. Figure 2A shows how reducing the colour scale or Nyquist limit from 60 to 16 cm/s results in a dramatic increase in the MR jet size. Colour gain should be set step by step just below the appearance of colour noise artefacts.¹⁰ The regurgitant jet area is frequently measured by planimetry.

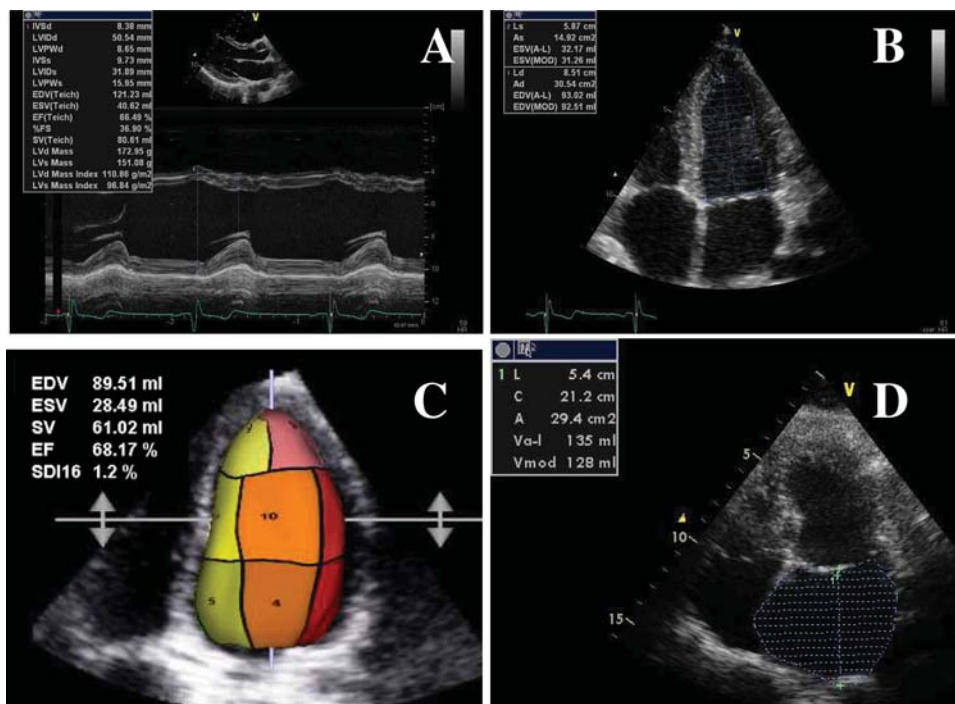


Figure 1 (A) M-mode measurement of left ventricular (LV) diameters; (B) estimation of LV volumes and ejection fraction by summation method of disc; (C) three-dimensional echo assessment of LV volumes; (D) estimation of left atrial volume by the summation method of disc.

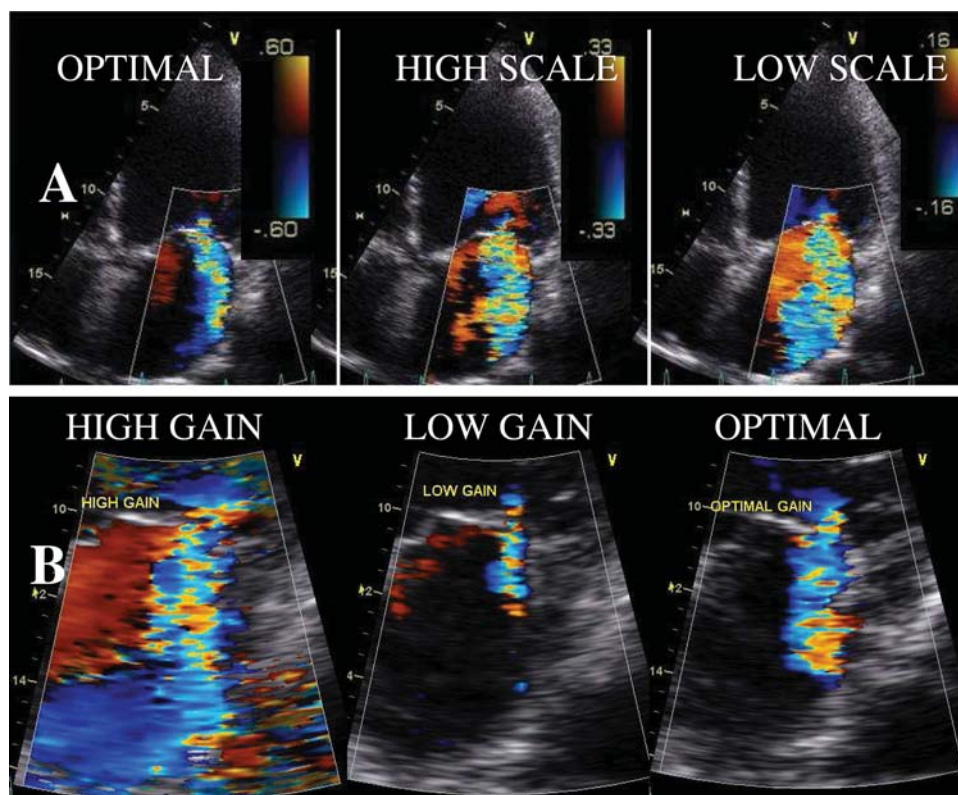


Figure 2 Effect of colour scale (A) and gain setting (B) on mitral regurgitant jet size.

Although this measurement appears to be the easiest method, the jet area is influenced by several factors: the mechanism of the regurgitation, the direction of the jet, the jet momentum, the loading conditions, the LA size, the patient's blood pressure.¹¹ Other major limitations include technical factors, such as gain settings, pulse repetition frequency, and aliasing velocity. This approach largely overestimates central jet and underestimates eccentric jet (Coanda effect). It is thus not recommended to quantify the severity of regurgitation.

Vena contracta width. The vena contracta is the narrowest portion of the regurgitant jet downstream from the regurgitant orifice.^{12,13} It is slightly smaller than the anatomic regurgitant orifice due to boundary effects. To properly identify the vena contracta, a scan plane that clearly shows the three components of the regurgitant jet has to be selected. In some cases, it may be necessary to angulate the transducer out of the normal echocardiographic imaging planes to separate the area of proximal flow acceleration, the vena contracta, and the downstream expansion of the jet. The colour sector size and imaging depth are reduced as narrow as possible to maximize lateral and temporal resolution. Visualization is optimized by expanding the selected zone. The selected cine loop is reviewed step by step to find the best frame for measurement. The largest diameter of a clearly defined vena contracta is measured if possible in two orthogonal planes (i.e. MR). In contrast to the jet in the receiving chamber, the vena contracta is considerably less sensitive to technical factors and relatively independent of flow rate. If the regurgitant orifice is dynamic, the vena contracta may change during the cardiac cycle. It is theoretically limited by the lateral resolution of colour Doppler echocardiography, which frequently is inadequate to distinguish minor variations in the vena contracta width. Because of the small values of the vena contracta width, small errors in its measurement may lead to a large percentage of error and misclassification of the severity of regurgitation. The presence of multiple jets and of non-circular orifice makes this method inaccurate.

The proximal isovelocity surface area or flow convergence method. The flow convergence method is a quantitative approach that is based on the principle of conservation of mass.¹⁴ Briefly, as blood flow converges towards a regurgitant orifice, it forms concentric isovelocity shells, roughly hemispheric, of decreasing surface area and increasing velocity. Therefore, the flow in each of these hemispheres is the same as that crossing the orifice. Colour flow Doppler offers the ability to image one of these hemispheres at a settled Nyquist limit or aliasing velocity. By setting the aliasing velocity to obtain an optimal hemispheric convergence zone, the flow rate (Q) through the regurgitant orifice is calculated as the product of the surface area of the hemisphere ($2\pi r^2$) and the aliasing velocity (V_a) ($Q = 2\pi r^2 \times V_a$). This flow rate across the proximal isovelocity surface area (PISA) is equal to the flow rate at the regurgitant orifice. Assuming that the maximal PISA occurs at the peak regurgitant orifice, the maximal effective regurgitant orifice area (EROA) is obtained by dividing the flow rate by peak velocity of the regurgitant jet by continuous-wave (CW) Doppler ($EROA = Q/\text{peak orifice velocity}$). The regurgitant volume is estimated as follows: R Vol (mL) = EROA (cm²)/TVI (cm) of the regurgitant jet, where TVI is the time-velocity integral.

Key point

The PISA method is acceptably reproducible in mitral regurgitation, TR, and AR. The following steps are

recommended: (1) optimize the colour flow imaging (Variance OFF) with a small angle from an apical or parasternal window, (2) expand the image using zoom or regional extension selection, (3) shift the colour flow zero baseline towards the regurgitant jet direction to obtain a hemispheric PISA, (4) use the cine mode to select the most satisfactory hemispheric PISA, (5) display the colour Doppler off when necessary to visualize the regurgitant orifice, (6) measure the PISA radius using the first aliasing, and (7) measure the regurgitant velocity.

The PISA method has several advantages. Instrumental and haemodynamic factors do not seem to substantially influence flow quantification by this approach. The aetiology of regurgitation or the presence of concomitant valvular disease does not affect the regurgitant orifice area calculation. Although less accurate, this method can still be used in eccentric jet without significant distortion in the isovelocity contours.¹⁵

The PISA method makes several assumptions.¹⁶ The configuration or shape of PISA changes as the aliasing velocity changes. The convergence zone is flatter with higher aliasing velocities and become more elliptical with lower aliasing velocities. Practically, the aliasing velocity is set between 20 and 40 cm/s. Another limitation regards variation in the regurgitant orifice during the cardiac cycle. This is particularly important in mitral valve prolapse where the regurgitation is often confined to the latter half of systole. The precise location of the regurgitant orifice can be difficult to judge, which may cause an error in the measurement of the PISA radius (a 10% error in radius measurement will cause more than 20% error in flow rate and regurgitant orifice area calculations). A more important limitation is the distortion of the isovelocity contours by encroachment of proximal structures on the flow field. In this situation, an angle correction for wall constraint has been proposed but it is difficult in practice and thus not recommended. 3D echocardiography has been shown to overcome some of these limitations. Although promising, further 3D experience remains still required.

Doppler volumetric method

The total forward volume across a regurgitant orifice is the sum of systemic SV and regurgitant volume.¹⁷ Hence, regurgitant volume can be obtained by calculating the difference between the total SV (regurgitant valve) and systemic SV (competent valve). R Vol = SV regurgitant valve – SV competent valve.

In MR, the total SV is calculated as the product of mitral annulus area ($\pi d^2/4 = 0.785 d^2$) and mitral inflow TVI. The mitral annulus diameter (d) is measured in diastole in the apical four-chamber view (assuming a circular orifice) at the maximal opening of the mitral valve (2–3 frames after the end-systole). The inner edge to inner edge measurement is recommended. The mitral inflow TVI is obtained by placing the sample volume at the level of the mitral annulus plane (not at the tips of mitral leaflets to avoid recording higher velocities). Systemic SV is obtained by multiplying the LV outflow tract (LVOT) area ($\pi d^2/4 = 0.785 d^2$, where d is the diameter of the LVOT measured just below the aortic valve in

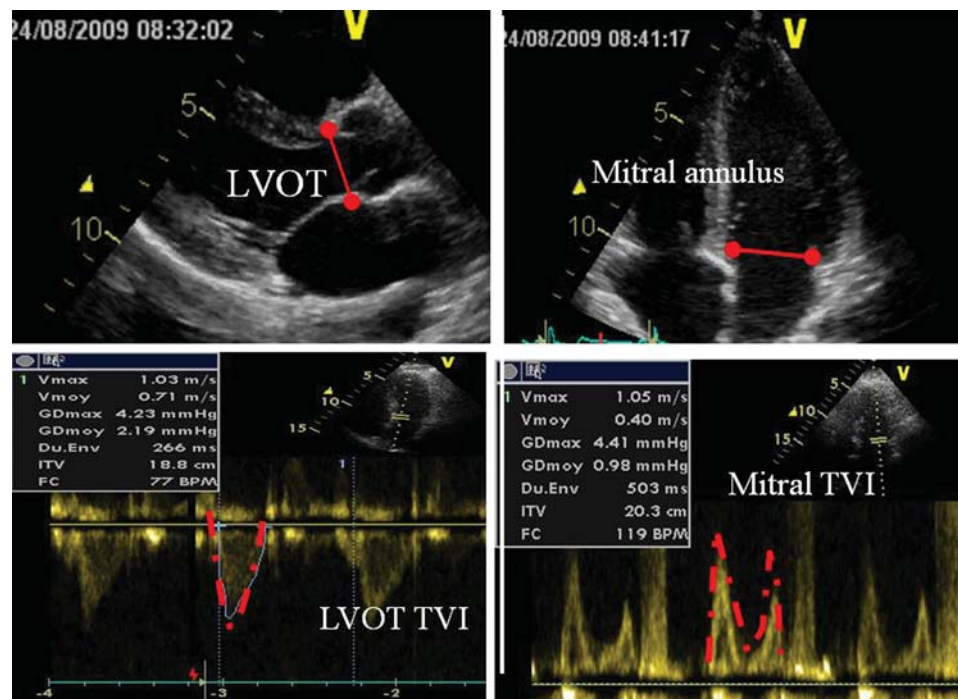


Figure 3 The quantitative assessment of aortic/pulmonary regurgitation severity by the Doppler volumetric method requires the measurement of the left ventricular outflow tract diameter (LVOT), the mitral annulus diameter and of two pulse wave velocity profiles (outflow tract and mitral inflow velocities). TVI, time–velocity integral.

the parasternal long-axis view) by LVOT TVI. The mitral regurgitant volume is estimated as the mitral inflow volume minus the LVOT SV (Figure 3). This calculation is inaccurate in the presence of significant AR. In this situation, the systemic flow could be calculated at the pulmonary annulus, although this site is often less accurate.¹⁸

In AR, the regurgitant volume corresponds to the difference between the LVOT SV (total) and the mitral inflow volume (competent valve).

In both, the EROA is calculated as R Vol divided by the TVI of the regurgitant jet velocity recorded by CW Doppler (EROA = R Vol/TVI regurgitant jet). Regurgitant fraction is expressed as regurgitant flow divided by total flow.

This approach is technically demanding (multiple measurements) and source of many errors (multistage calculations). It should be considered as optional or reserved to experienced laboratories. The most common limitation relies to the measurement of the mitral annulus (error is squared in the formula). To overcome this limitation, the mitral SV can be obtained from 2D or 3D echocardiography by subtracting LV end-diastolic volume from LV end-systolic volume. This approach still needs to be validated on a large-scale approach.

Other Doppler approaches

Several alternative Doppler methods can give indirect evidence to the severity of valvular regurgitation. For instance, the signal intensity of the CW envelope of the regurgitant jet represents a qualitative index of severity. The denser the signal, the more significant the regurgitation (the greater the number of red

cells exhibiting regurgitation). The other Doppler parameters are more valve-specific and will be discussed according to the valve involved.

Estimation of the severity of valvular regurgitation: recommendations

- (1) The colour flow area of the regurgitant jet is not recommended to quantify the severity of valvular regurgitation.
- (2) Both the vena contracta measurement and the PISA method are the recommended approaches to evaluate the severity of regurgitation when feasible.
- (3) Adjunctive parameters should be used when there is discordance between the quantified degree of regurgitation and the clinical context.

Aortic regurgitation

AR is a common valvular disease. Echocardiography plays a valuable role in the assessment and management of patients with underlying AR.^{18,19}

Anatomy and function of the aortic valve

The aortic valve consists of a complex of structures surrounding the aortic orifice along the LVOT. Typically, the valve has three

leaflets which are semi-lunar in shape. The cusps are inserted into a fibrous connective tissue sleeve, which is attached to the aorta media above. Below, the cusps are attached to the myocardium of the LVOT and to the anterior mitral leaflet. Each cusp is attached along its curves edge, and the cusps meet at three commissures that are equally spaced along the circumference of the sleeve at the supra-aortic ridge. The area of the cusps is ~40% greater than the cross-sectional area of the aortic root. In normal aortic valve, the cusps are symmetrical, mobile, and free to the commissures, with equal overlap on closure. The sinuses of Valsalva are located between the valve sleeve and cusps. The cusps are called left coronary, right coronary, and non-coronary cusps based on the location of the coronary ostia.

The parasternal long-axis view is classically used to measure the LVOT, the aortic annulus, and the aortic sinuses. Leaflet thickening and morphology can be visualized from this window as well as from the parasternal short-axis view and the apical five-chamber view. However, not uncommonly, 2D TTE does not allow to correctly identifying the anatomy and causes of AR. In this situation, 3D echo could provide better delineation of the aortic valve morphology. In some cases, TEE is needed particularly for assessing the mechanisms and causes of AR as well as the aortic root dimensions.

Aetiology and mechanisms of aortic regurgitation

AR results from disease of either the aortic leaflets or the aortic root that distorts the leaflets to prevent their correct apposition. Common causes of leaflet abnormalities that result in AR include senile leaflet calcifications, bicuspid aortic valve, infective endocarditis, and rheumatic fever. Aortic causes of AR include annuloaortic ectasia (idiopathic root dilatation, Marfan's syndrome, aortic dissection, collagen vascular disease, and syphilis).

Aetiology

Degenerative calcific aortic regurgitation

Calcification of a tricuspid aortic valve is most prominent in the central part of each cusp. There is no commissural fusion. A stellate-shaped systolic orifice is observed on the parasternal short-axis view.²⁰

Rheumatic aortic regurgitation

Rheumatic AR is characterized by commissural fusion, calcifications, and variable thickening of the leaflets especially at the level of their free edge. The resulting retraction of aortic leaflets usually induces central regurgitation.

Bicuspid aortic regurgitation

A small proportion of the adult population has bicuspid aortic valves. These valves lead to stenosis, regurgitation, or both, owing to abnormal leaflet architecture and coaptation. Bicuspid aortic valves may be associated with dilatation of the aorta. A congenitally abnormal valve is strongly suspected whenever markedly eccentric leaflet coaptation is seen in parasternal views. The long-axis view may reveal an asymmetric closure line, a systolic doming or a diastolic prolapse of the leaflets. The short-axis view is more specific. The diagnosis is confirmed when only two leaflets are seen in systole with two commissures framing an elliptical systolic orifice. Diastolic image may mimic a trileaflet valve when a raphe is

present. The fusion of the right and left coronary cusps (large anterior and small posterior cusps with both coronary arteries arising from the anterior cusp) is the more frequent.²¹ The 3D echo reliably defines the morphological details of bicuspid aortic valve with the precision of anatomopathological examination.²²

Mechanisms of aortic regurgitation

In recent years, repair techniques for diseased aortic valves have received increasing attention. The knowledge of the mechanism responsible for AR is essential. Several functional classifications can be used. The adapted Carpentier classification for the AR is the most common. Type I: aortic root dilatation or leaflet perforation; type II: prolapse of one or more cusps; and type III: restricted motion as the consequence of rheumatic disease or secondary significant calcifications (*Figure 4*).²³ However, 2D TTE does not always show the lesion responsible for leaflet malcoaptation. In this situation, TEE provides useful information regarding the cusp pathology (redundancy, restriction, cusp height to indicate likely adequacy of coaptation, mobility/pliability, thickness, and integrity), commissure variations (fusion, splaying, attachment site, and alignment), and root morphology (septal hypertrophy, annular size, sinus, sinotubular junction dimension, and ascending aorta dimension). Recently, the diagnostic value of TEE in defining the mechanisms of AR has been highlighted (*Table 1*).²³ Three functional mechanisms have been described: type 1: enlargement of the any components of the aortic root (aortic annulus, sinuses of Valsalva, and sinotubular junction) with normal cusps; type 2: cusp prolapse or free edge fenestration with an eccentric regurgitant jet; type 3: poor cusp tissue quality [cusp retraction, extensive cusp calcifications (\geq grade 3), endocarditis]. Cusp prolapses are further categorized into three groups: cusp flail (eversion of the cusps into the LVOT), partial cusp prolapse, and whole cusp prolapse (free edge of aortic cusp overriding the plane of aortic annulus). The degree of calcification of the aortic valve is scored as follows: grade 1: no calcification; grade 2: isolated small calcification spots; grade 3: bigger calcification spots interfering with cusp motion; and grade 4: extensive calcifications of all cusps with restricted cusp motion. The incidence of valve sparing or repair decreases with the severity of dysfunction and is less than 50% in type 3 dysfunction. 3D echocardiographic observation of the aortic valve may provide unique additional information in the diagnosis of various types of aortic valve disease.

Key point

In patients with AR, careful aortic valve analysis is mandatory. The echo report should include information about the aetiology, the lesion process, and the type of dysfunction. The likelihood of valve repair should also be discussed in the case of pure AR.

Other two-dimensional/M-mode findings in aortic regurgitation

In addition to the anatomic evaluation of the aortic valve and the assessment of the aortic root diameters (valve annulus, aortic sinuses, sinotubular junction, and proximal ascending aorta measurements are generally performed in mid-systole), several 2D and M-mode echo findings can be observed in AR (*Figure 5*). If the regurgitant jet impinges on the anterior mitral valve leaflet,

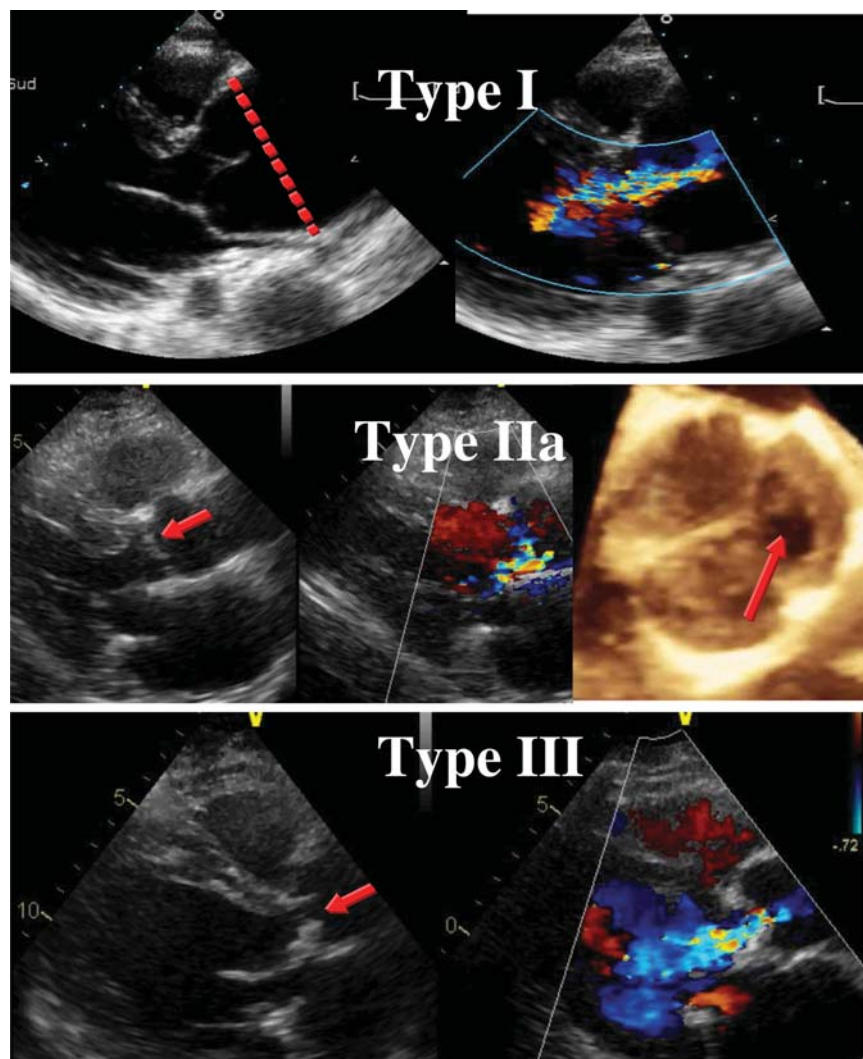


Figure 4 Mechanisms of aortic regurgitation according to the Capentier functional classification. Type I, aortic annulus dilatation; Type IIa, prolapse of the left coronary cusp (arrow); Type III, rheumatic aortic valve disease with restricted cusp motion.

a reverse doming (concavity toward the ventricular septum) of the anterior leaflet can be observed on the parasternal long-axis view (Figure 6A). As a result, the leaflet presents a high-frequency fluttering during diastole and its opening can be compromised. The M-mode echo can confirm the fluttering motion of the anterior leaflet (Figure 6B). It can also appear on the mitral valve chordae or the interventricular septum. Its absence (i.e. in the case of mitral valve stenosis) cannot rule out the diagnosis of AR and a pseudo-fluttering can be observed in atrial fibrillation and in cardiac hyperkinesis. The M-mode echo is also helpful in demonstrating the premature mitral valve closure as a sign of severe, usually acute, AR and marked increase in LV diastolic pressure. Rarely, a premature diastolic opening of the aortic valve may appear if LV pressure exceeds aortic pressure. In chronic AR, if the regurgitant jet is eccentric towards the septum, a fibrotic reaction can occur at the contact site, and a local rise in echogenicity can sometimes be seen.

Key point

Additional echo findings are used as complementary findings to assess the severity of AR. The assessment of the morphology and dimension of the aortic root is mandatory.

Assessment of AR severity

Colour flow Doppler

Colour flow imaging. Colour flow Doppler provides a semi-quantitative approach to evaluate AR severity.²⁴ The regurgitant jet into the LV in diastole can be visualized by using multiple views. The parasternal views are preferred over the apical views because of better axial resolution. The colour jet area and length are weakly correlated with the degree of AR. They are particularly affected by the aortic to LV diastolic pressure gradient and LV compliance. Both jet area and length are often overestimated in the apical views and are not currently recommended. Practically, it serves for a visual assessment of AR. Central jets are highly

Table 1 Functional classification of AR lesions

Dysfunction	Echo findings
I: enlargement of the aortic root with normal cusps	Dilatation of any components of the aortic root (aortic annulus, sinuses of Valsalva, sinotubular junction)
IIa: cusp prolapse with eccentric AR jet Cusp flail Partial cusp prolapse	Complete eversion of a cusp into the LVOT in long-axis views Distal part of a cusp prolapsing into the LVOT (clear bending of the cusp body on long-axis views and presence of a small circular structure near the cusp free edge on short-axis views)
Whole cusp prolapse	Free edge of a cusp overriding the plane of aortic annulus with billowing of the entire cusp body into the LVOT (presence of a large circular or oval structure immediately beneath the valve on short-axis views)
IIb: free edge fenestration with eccentric AR jet	Presence of an eccentric AR jet without definite evidence of cusp prolapse
III: poor cusp quality or quantity	Thickened and rigid valves with reduced motion Tissue destruction (endocarditis) Large calcification spots/extensive calcifications of all cusps interfering with cusp motion

suggestive of rheumatic disease whereas eccentric jets are often associated with aortic valve prolapse or perforation. Colour-coded M-mode is suitable for time dependency of flow signals during the heart cycle (Figure 7). The diameter and the cross-sectional area of the jet at its origin are other colour Doppler indices of AR severity. The maximum colour jet diameter (width) is measured in diastole immediately below the aortic valve (at the junction of the LVOT and aortic annulus) in the parasternal long-axis view. The jet width is proportional to the size of the aortic valve defect. However, if the orifice is irregular, as in bicuspid valve, the colour jet width is less related to the degree of regurgitation. Its accuracy can thus be improved by dividing the jet width by the LVOT diameter. The cross-sectional areas of the jet from the parasternal short-axis view and its ratio to the LVOT area are also indicators of AR severity. Although these measurements suffer from a high inter-observer variability, a jet width ratio >65% is a strong argument for severe AR.²⁴

Key point

The colour flow area of the regurgitant jet is not recommended to quantify the severity of AR. The colour flow imaging should only be used for a visual assessment of AR. A more quantitative approach is required when more than a small central AR jet is observed.

Vena contracta width. For AR, imaging of the vena contracta—the regurgitant jet as it traverses the aortic orifice or the effective

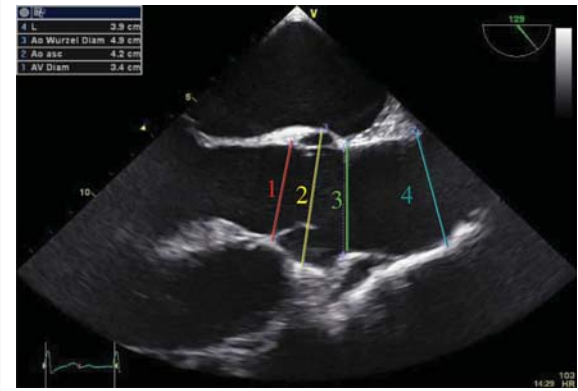


Figure 5 Measurements of the aortic diameters. 1, valve annulus; 2, aortic sinuses; 3, sinotubular junction; 4, proximal ascending aorta.

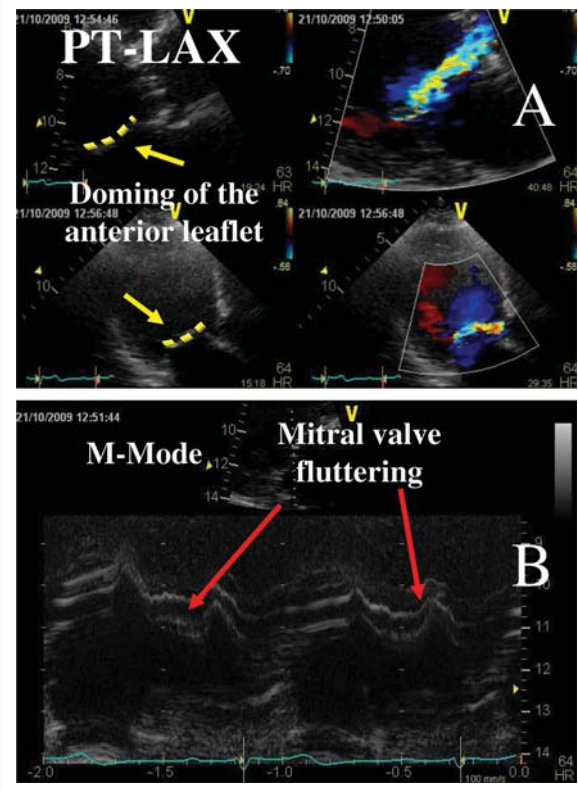


Figure 6 (A) Example of aortic regurgitation (AR) jet impinging on the anterior mitral valve leaflet with a reverse doming of the anterior mitral valve leaflet; (B) M-mode recording showing the fluttering motion of the anterior mitral leaflet in a patient with severe AR.

regurgitant area—is obtained from the parasternal long-axis view.^{25–27} To properly identify the vena contracta, the three components of the regurgitant jet should be visualized. A narrow colour sector scan coupled with the zoom mode is recommended to improve measurement accuracy. Practically, the vena contracta

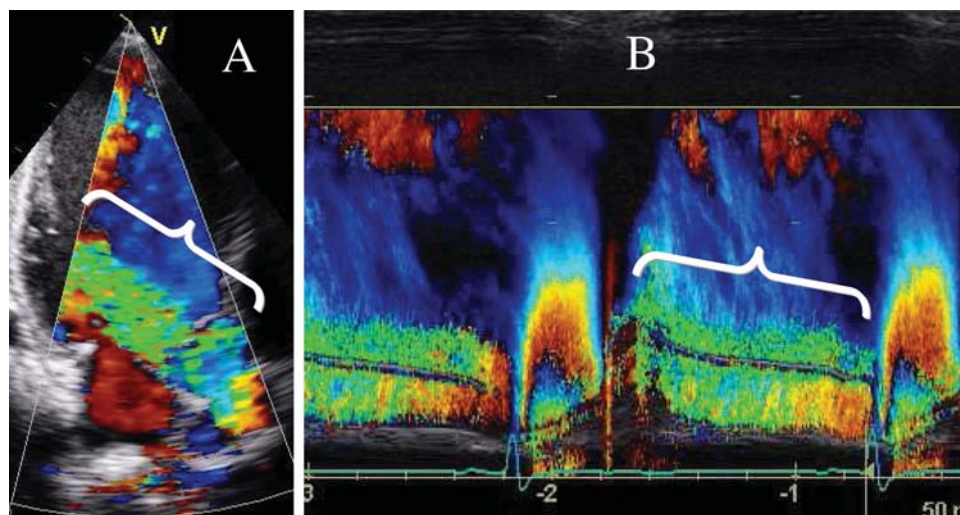


Figure 7 (A) Colour Doppler showing a severe aortic regurgitation; (B) colour-coded M-mode depicting the time dependency of flow signal during the heart cycle.

represents the smallest flow diameter at the level of the aortic valve in the LVOT, immediately below the flow convergence region (Figures 8 and 9). It provides thus an estimate of the size of the EROA and is smaller than the regurgitant jet width in the LVOT (expansion of the jet immediately after the vena contracta). Using a Nyquist limit of 50–60 cm/s, a vena contracta width of <3 mm correlates with mild AR, whereas a width >6 mm indicates severe AR. The measurement of the vena contracta is affected by several factors as the presence of multiple jets. In this situation, the respective widths of the vena contracta are not additive. The concept of vena contracta is indeed based on the assumption that the regurgitant orifice is almost circular. The orifice is however often elliptic or irregular, which changes the width of the vena contracta in different views. 3D colour Doppler echo has been shown to be a useful tool in the visualization of the actual shape of the regurgitant orifice and could be used to measure the vena contracta in experienced hands. With 3D echo, an EROA <20 mm² and an EROA >60 mm² have been proposed to define mild AR and severe AR, respectively.²⁷ However, these thresholds need to be confirmed in further studies.

Key point

When feasible, the measurement of the vena contracta width is recommended to quantify AR. Intermediate vena contracta values (3–6 mm) need confirmation by a more quantitative method, when feasible. The vena contracta can often be obtained in eccentric jet. In the case of multiple jets, the respective values of vena contracta width are not additive. The assessment of the vena contracta by 3D echo is still reserved for research purposes.

The flow convergence method. The assessment of the flow convergence zone has been less extensively performed in AR than in MR.^{28–30} Imaging of the flow convergence zone is obtained from the apical three- or five-chamber or parasternal long-axis or upper right parasternal views (Figures 10 and 11). The area of interest is expanded by using the zoom mode, the sector size is reduced as narrow as possible to maximize frame rate, and the

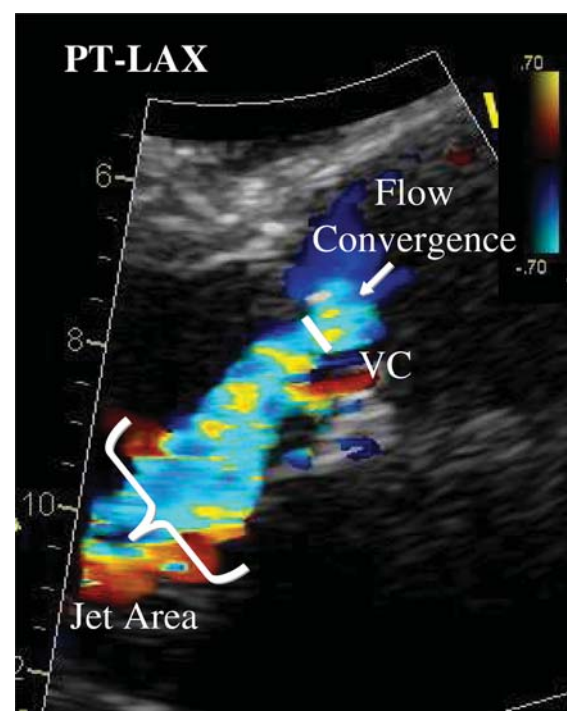


Figure 8 Semi-quantitative assessment of aortic regurgitation severity using the vena contracta (VC) width. The three components of the regurgitant jet (flow convergence zone, vena contracta, jet turbulence) are obtained. PT-LAX, parasternal long-axis view.

Nyquist limit is adjusted to obtain a clearly visible, round, and measurable PISA radius. The colour flow velocity scale is shifted towards the direction of the jet (downwards or upwards in the left parasternal view depending on the jet orientation and upwards in the apical view). The PISA radius is measured from a

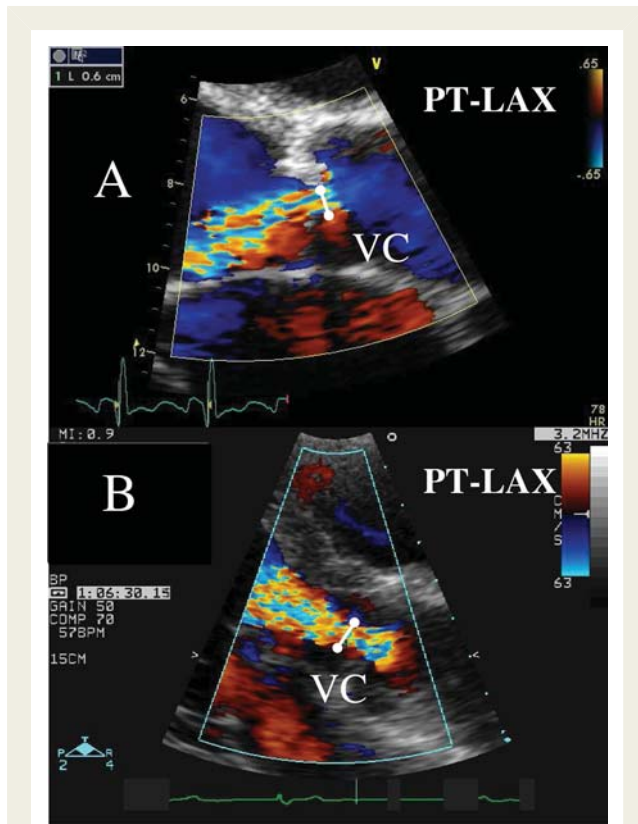


Figure 9 Two other examples of the measurement of the vena contracta (VC) width in two patients with moderate aortic regurgitation. PT-LAX, parasternal long-axis view.

stop frame as the distance between the regurgitant orifice and the first aliasing in early diastole (closest to the peak of regurgitant velocity). When imaged from the apical window, the PISA method significantly underestimates AR severity in the presence of eccentric AR jets. In this situation, imaging the flow convergence zone from the parasternal long axis improves the accuracy of the PISA method (if the jet is directed towards either the anterior mitral leaflet or the interventricular septum). For central AR jets, the apical view remains the most appropriate. The PISA method has several limitations. First, it is not feasible in a significant percentage of patients with AR due to interposition of valve tissue and difficulty in correctly identifying the flow convergence zone. Non-planar or confined flow convergence zones that invalidate the hemispheric assumption are potential causes of either under- or over-estimation of AR severity by the PISA method. Accordingly, caution should be exercised when using the PISA method in patients with obtuse flow convergence angles, such as those with aneurysmal dilation of the ascending aorta or those with confined flow convergence zone such as could occur in patients with cusp perforation or commissural leaks. Grading of the severity of AR classifies regurgitation as mild, moderate, or severe, and subclassifies the moderate regurgitation group into 'mild-to-moderate' (EROA of 10–19 mm² or an R Vol of 30–44 mL) and 'moderate-to-severe' (EROA of 20–29 mm² or an R Vol of 45–59 mL). An EROA ≥ 30 mm² or an R Vol ≥ 60 mL indicates severe AR.

Key point

When feasible, the PISA method is highly recommended to quantify the severity of AR. It can be used in both

central and eccentric jets. In eccentric AR jets, we recommend to use the parasternal long-axis view to evaluate the flow convergence zone. An EROA ≥ 30 mm² or an R Vol ≥ 60 mL indicates severe AR.

Pulsed Doppler

Doppler volumetric method. As for MR, PW Doppler method can be used as an alternative method to quantify the AR severity.³¹ In the absence of significant MR, the mitral inflow is used to calculate the systemic SV. The pulmonic site can be used in patient with significant MR. This approach is time-consuming and is associated with several drawbacks (see above). In general, a regurgitant fraction greater than 50% indicates severe AR.

Diastolic flow reversal in the descending aorta (or peripheral arteries). AR can lead to diastolic flow reversal in the aorta. The flow reversal is best imaged in the upper descending aorta at the aortic isthmus level using a suprasternal view by using pulsed Doppler. The sample volume is placed just distal to the origin of the left subclavian artery and it is aligned as much as possible along the major axis of the aorta. The Doppler filter is decreased to its lowest setting to allow detection of low velocities (< 10 cm/s). With milder degrees of regurgitation, there is a brief reversal of flow limited to early diastole. As the degree of the regurgitation increases, the duration and the velocity of the reversal flow increases. It becomes sustained throughout diastole at velocities exceeding 20 cm/s in severe AR (end-diastolic velocity measured at peak R wave) (Figure 12). This cut-off value has been validated in the proximal descending aorta just beneath the aortic isthmus.³² Significant holodiastolic reversal in the abdominal aorta is also a sensitive sign of severe AR. However, in the case of reduced aortic compliance (advancing age) or in the presence of increased heart rate, the duration and velocity of flow reversal may be increased. In severe acute AR, diastolic velocity decreases quickly with no end-diastolic velocity due to equalization of aortic and LV diastolic pressures.

Key point

The measurement of the diastolic flow reversal in the descending aorta is recommended, when assessable. It should be considered as the strongest additional parameter for evaluating the severity of AR.

Continuous-wave Doppler of the AR jet

CW Doppler of the AR jet reflects the pressure difference between the aorta and the LV during diastole. It is classically best obtained from the apical five-chamber view (Figure 13). However, effort should be made to obtain correct Doppler angle in order to minimize errors related to possible ultrasound beam misalignment. For eccentric jets, better signals may be obtained from the right parasternal window. Although faint spectral display is compatible with trace or mild AR, significant overlap between moderate and severe regurgitation exists in more dense jet tracings. Practically, the CW density does not provide useful information about the severity of AR. The grading by this method is qualitative.

The rate of deceleration of the diastolic regurgitant jet and the derived pressure-half time reflect both the degree of regurgitation and the ventricular end-diastolic pressures. As the degree of AR increases, the aortic diastolic pressure decreases and the LV end-diastolic pressure increases.³³ The late diastolic jet velocity is thus reduced and the pressure half-time shortened. A pressure half-

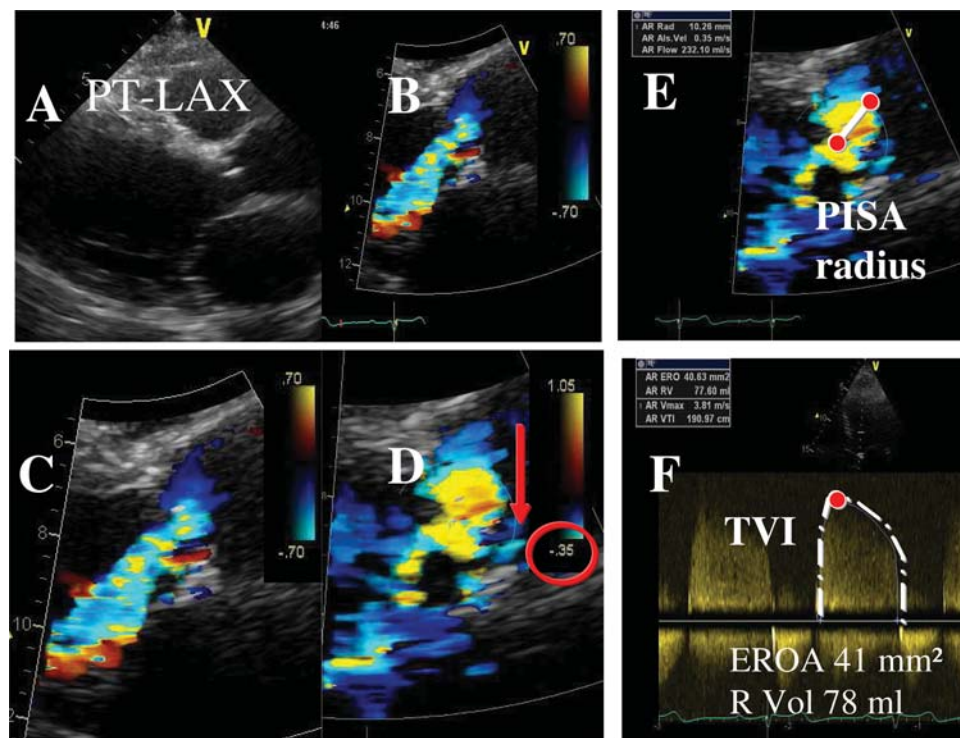
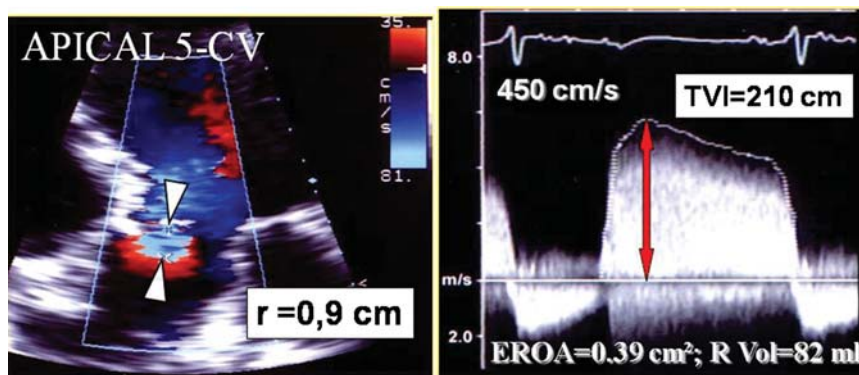


Figure 10 Quantitative assessment of aortic regurgitation (AR) severity using the proximal isovelocity surface area (PISA) method. Stepwise analysis of AR: (A) parasternal long-axis view (PT-LAX); (B) Colour flow display; (C) zoom of the selected zone; (D) downward shift of zero baseline to obtain a hemispheric PISA; (E) measure of the PISA radius using the first aliasing; (F) continuous-wave Doppler of AR jet allowing calculation the effective regurgitant orifice area (EROA) and regurgitant volume (R Vol). TVI, time–velocity integral.



$$\text{ERO} = \text{Flow/Peak velocity} = 178/450 = 0.39 \text{ cm}^2$$

$$\text{R Vol} = \text{EROA} \times \text{TVI} = 0.39 \text{ cm}^2 \times 210 \text{ cm} = 82 \text{ mL}$$

Figure 11 Quantitative assessment of aortic regurgitation severity using the proximal isovelocity surface area method from the apical five-chamber view (CV). Arrows: white: PISA radius, Red: peak regurgitant velocity.

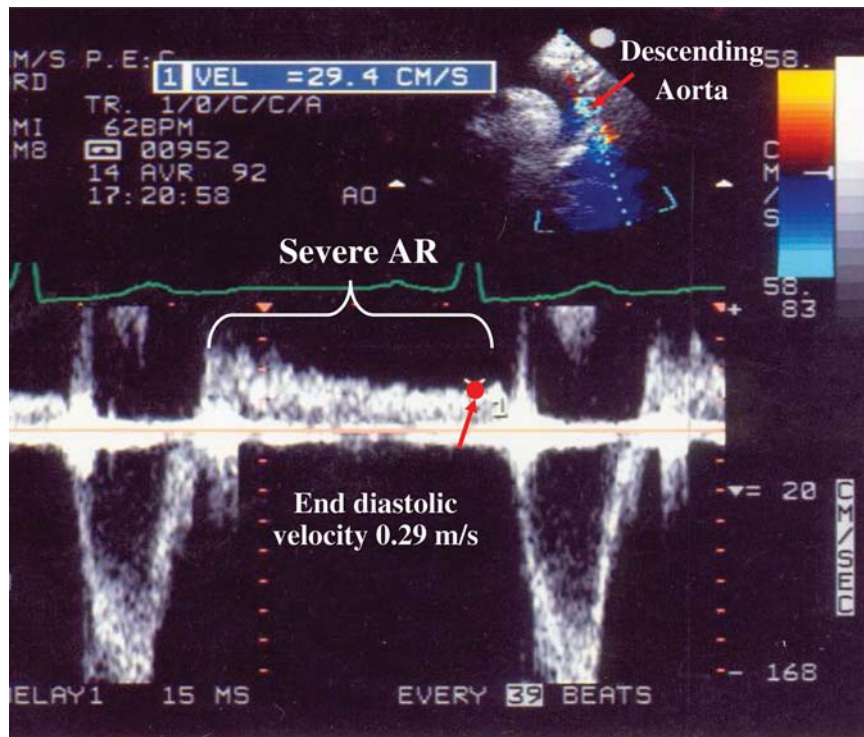


Figure 12 A pulsed-Doppler recording within the descending aorta from a patient with severe aortic regurgitation (AR) demonstrates flow reversal throughout diastole. An end-diastolic flow velocity >20 cm/s is indicative of severe AR.

time of <200 ms is consistent with severe AR, whereas a value of >500 ms suggests mild AR. The pressure half-time is however influenced by chamber compliance in addition to chamber pressures. For a given severity of AR, pressure half-time may be further reduced by elevated LV diastolic pressures or prolonged in patients with increase in peripheral resistance or who have a dilated aorta with increased aortic compliance.³⁴ It tends to normalize with chronic LV adaptation to AR. Accurate measurement of pressure half-time is also dependent on obtaining an adequate spectral envelope of the regurgitant jet.

Key point

The CW Doppler density of the AR jet does not provide useful information about the severity of AR. The assessment of the pressure half-time requires good Doppler beam alignment. A careful probe angulation is often needed. Because this parameter is influenced by chamber compliance and chamber pressures, it serves only as a complementary finding for the assessment of AR severity.

Consequences of aortic regurgitation

The presence of severe AR has significant haemodynamic effects, primarily on the LV.

Left ventricular size and function AR imposes additional volume load on the LV. In acute AR, the LV is classically not enlarged, whereas in the chronic situation, the LV progressively dilates and irreversible LV

damage may occur. In the current guidelines, surgery is recommended in asymptomatic patients with severe AR when the LV ejection fraction is $\leq 50\%$ and/or when the end-systolic diameter (less preload dependent) is >50 mm (>25 mm/m²).^{1,35} An LV end-systolic volume index ≥ 45 mL/m² has been shown to be predictive of outcome and could thus be used for referring patients for surgery.²⁹ New parameters are currently available for a better assessment of LV function. A tissue Doppler peak systolic velocity measured at the medial annulus <9.5 cm/s seems to be a good indicator of a poor exercise response.³⁵ Strain rate imaging is also a sensitive tool in detecting the spectrum of changes in radial and longitudinal deformation in asymptomatic or minimally symptomatic patients with AR.³⁶ However, data supporting the incremental value of tissue Doppler and strain imaging for detecting subclinical LV dysfunction are still scarce.³⁴

Key point

LV diameters, volumes, and ejection fraction should always be evaluated and reported. It is strongly recommended to index the LV diameters to the body surface area.

Role of exercise echocardiography

The development of symptoms during exercise testing is useful in predicting outcome in patients with severe AR who are apparently asymptomatic at rest.^{37,38} The additional value of stress imaging is unclear. The observed magnitude of change in ejection fraction or SV from rest to exercise is related not only to myocardial contractile function but also to severity of volume-overload and

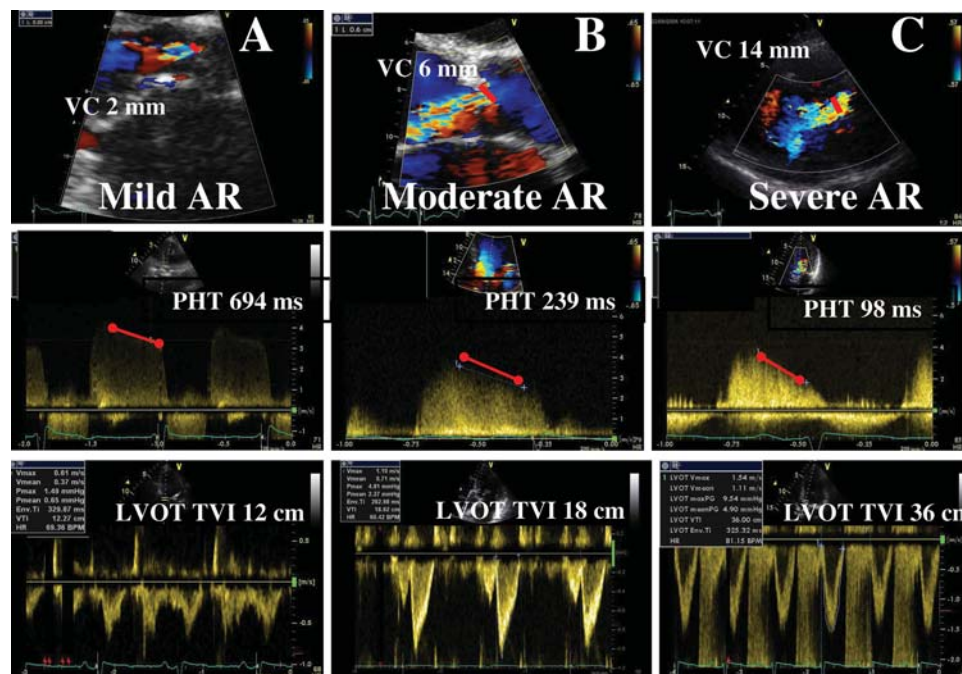


Figure 13 Three examples of aortic regurgitation (AR) are provided, all taken from the parasternal long-axis view using colour Doppler (top) and from the apical five-chamber view using continuous-wave Doppler (mid). The vena contracta (VC) increases with the severity of AR. The pressure half-time (PHT) decreases with more severe AR, whereas the left ventricular outflow time–velocity integral (LVOT TVI) increases.

exercise-induced changes in preload and peripheral resistance. However, the absence of contractile reserve—decrease in LV ejection fraction by 5% at exercise—seems to be predictive of LV decompensation after surgery.³⁹ As the incremental value of stress echocardiography in predicting outcome of patients with asymptomatic AR is limited by the small number of available studies, this specific application is classically limited for research to experienced centre.

Key point

Exercise echocardiography is useful in patients with severe AR and equivocal symptoms. It could also be useful in patients with borderline values in terms of LV ejection fraction (50–55%) or end-systolic diameter (closed to 50 mm or 25 mm/m²).

Integrating indices of severity

Echocardiographic assessment of AR includes integration of data from 2D/3D imaging of the aortic root, aortic valve, and ventricle as well as Doppler measures of regurgitation severity (Table 2). Effort should be made to quantify the degree of regurgitation, except in the presence of mild or less AR. Both the vena contracta width and the PISA method are recommended, whenever possible. Adjunctive parameters help to consolidate about the severity of AR and should be widely used particularly when there is discordance between the quantified degree of AR and the clinical context. These parameters should be interpreted according to the chronicity of AR and the LV remodelling. Advantages and limitations of the various echo Doppler parameters used in assessing AR severity are detailed in Table 3.

Recommended follow-up

Echocardiography is a good guide to the timing of surgery. This should be considered when LV deterioration starts to occur. To determine the rapidity of progression of AR, initial evaluation should be repeated in 2–3 months in the absence of surgical indications. In asymptomatic patients with mild AR, little or no LV dilatation, and normal LV ejection fraction at rest, echocardiograms can be done every 2–3 years. They should be done every 12 months for asymptomatic patients with severe AR and LV end-diastolic size of 60–65 mm and normal LV systolic function. Echocardiograms should be performed more often (every 6 months) for patients with LV end-diastolic diameter close to 70 mm, or end-systolic diameter close to 50 mm (25 mm/m²). Serial echocardiograms are also required when symptoms occur (which represents an indication for surgery) or when worsening AR or increasing LV size is clinically suggested or in patients with aortic root dilatation (<50 mm for bicuspid aortic valve, <45 mm for patients with Marfan's syndrome, and <55 mm for other patients).^{1,40}

Pulmonary regurgitation

A slight amount of PR has been reported in 40–78% of patients with normal pulmonary valves. Acquired mild-to-moderate PR is most often seen in patients with pulmonary hypertension with dilatation of the pulmonary artery. Severe PR is uncommon and usually observed in patients with anatomic abnormalities of the valve or after valvulotomy.^{41,42} There are very few validated studies owing to the low prevalence rates and difficulties in imaging.

Table 2 Grading the severity of AR

Parameters	Mild	Moderate	Severe
Qualitative			
Aortic valve morphology	Normal/Abnormal	Normal/Abnormal	Abnormal/flail/large coaptation defect
Colour flow AR jet width ^a	Small in central jets	Intermediate	Large in central jet, variable in eccentric jets
CW signal of AR jet	Incomplete/faint	Dense	Dense
Diastolic flow reversal in descending aorta	Brief, protodiastolic flow reversal	Intermediate	Holodiastolic flow reversal (end-diastolic velocity >20 cm/s)
Semi-quantitative			
VC width (mm)	<3	Intermediate	>6
Pressure half-time (ms) ^b	>500	Intermediate	<200
Quantitative			
EROA (mm ²)	<10	10–19; 20–29 ^c	≥30
R Vol (mL)	<30	30–44; 45–59 ^c	≥60
+LV size ^d			

AR, aortic regurgitation; CW, continuous-wave; LA, left atrium; EROA, effective regurgitant orifice area; LV, left ventricle; R Vol, regurgitant volume; VC, vena contracta.

^aAt a Nyquist limit of 50–60 cm/s.

^bPHT is shortened with increasing LV diastolic pressure, vasodilator therapy, and in patients with a dilated compliant aorta or lengthened in chronic AR.

^cGrading of the severity of AR classifies regurgitation as mild, moderate or severe and subclassifies the moderate regurgitation group into 'mild-to-moderate' (EROA of 10–19 mm² or an R Vol of 30–44 mL) and 'moderate-to-severe' (EROA of 20–29 mm² or an R Vol of 45–59 mL).

^dUnless for other reasons, the LV size is usually normal in patients with mild AR. In acute severe AR, the LV size is often normal. In chronic severe AR, the LV is classically dilated. Accepted cut-off values for non-significant LV enlargement: LV end-diastolic diameter <56 mm, LV end-diastolic volume <82 mL/m², LV end-systolic diameter <40 mm, LV end-systolic volume <30 mL/m².

Anatomy and function of the pulmonary valve

The pulmonary valve is a three-leaflet structure, anatomically similar to the aortic valve. The pulmonic valve structure is however thinner because of the lower pressures in the right than in the left heart system.

With 2D echo, typically only one or two leaflets can be simultaneously visualized (Figure 14). On occasion, the pulmonary valve can be seen in a short-axis view. In adults, visualization of the pulmonary valve is obtained from the parasternal short-axis view at the level of the aortic valve or from a subcostal approach. Evaluation of the pulmonary valve anatomy is however more difficult than for other valves (limited by poor acoustic access). In pulmonary hypertension, the dilatation of pulmonary artery allows better assessment of the valve. The role of TEE in PR is limited since the pulmonary valve is more difficult to image with TEE (far from the probe). The views that maximize visualization of the pulmonary valve include horizontal (0 degrees) plane imaging at 25–30 cm from the incisors and a deep gastric view in 120° imaging plane.

Aetiology and mechanisms

PR may be caused by congenital anomalies (quadricuspid or bicuspid valves), hypoplasia, post-repair of tetralogy of Fallot or prolapse of the pulmonary valve. Other causes include infective endocarditis, carcinoid syndrome, and rheumatic heart disease. Carcinoid syndrome results in shortening and thickening of the pulmonary valve leaflet, similar to the involvement of the tricuspid valve. Myxomatous valve is rare, resulting in

thickening, redundancy, and sagging of the pulmonary valve leaflets. As for AR, examining the anatomic abnormalities associated with PR may help define the mechanisms of regurgitation and yield clues to its severity. TTE, TEE, or 3D echo could provide useful information regarding anomalies of cusp number (bicuspid or quadricuspid valves), motion (doming or prolapse), or structure (hypoplasia, dysplasia, absence of pulmonary valve).¹⁸

Assessment of pulmonary regurgitation severity

Determination of the PR severity has been less validated than determination of AR degree.

Colour flow Doppler

Colour flow imaging

Detection of PR relies almost exclusively on colour flow imaging. PR is diagnosed by documenting a diastolic jet in the RV outflow tract directed towards the RV. Pathological PR is distinguished from physiological PR by a longer duration of flow (holodiastolic) and a wider jet as the regurgitant jet crosses the pulmonic valve.³⁵ Functional PR jets are usually very small, central, and spindle-shaped. In severe PR, where equalization of diastolic pulmonary artery and RV pressures occurs early in diastole, the colour jet area can be brief and inaccurate (dependency on the driving pressure).⁴³ The assessment of PR severity is usually estimated by the diameter of the jet at its origin.⁴⁴ The maximum colour jet diameter (width) is measured in diastole immediately below

Table 3 Echocardiographic parameters used to quantify aortic regurgitation severity: recordings, advantages, and limitations

Parameters	Recordings	Usefulness/Advantages	Limitations
Aortic valve morphology	<ul style="list-style-type: none"> • Visual assessment • Multiple views 	<ul style="list-style-type: none"> • Flail valve is specific for significant AR 	<ul style="list-style-type: none"> • Other abnormalities are non-specific of significant AR
Colour flow AR jet width and area	<ul style="list-style-type: none"> • Optimize colour gain/scale • Parasternal long- and short-axis views 	<ul style="list-style-type: none"> • Ease of use • Evaluates the spatial orientation of AR jet • Quick screen for AR 	<ul style="list-style-type: none"> • Influenced by technical and haemodynamic factors • Inaccurate for eccentric jet • Expands unpredictably below the orifice
VC width	<ul style="list-style-type: none"> • PT-LAX is preferred (apical four-chamber if not available) • Optimize colour gain/scale • Identify the three components of the regurgitant jet (VC, PISA, Jet into LV) • Reduce the colour sector size and imaging depth to maximize frame rate • Expand the selected zone (Zoom) • Use the cine loop to find the best frame for measurement • Measure the smallest VC (immediately distal to the regurgitant orifice, perpendicular to the direction of the jet) 	<ul style="list-style-type: none"> • Relatively quick and easy • Relatively independent of haemodynamic and instrumentation factors • Not affected by other valve leak • Good for extremes AR: mild vs. severe • Can be used in eccentric jet 	<ul style="list-style-type: none"> • Not valid for multiple jets • Small values; small measurement errors lead to large % error • Intermediate values need confirmation • Affected by systolic changes in regurgitant flow
PISA method	<ul style="list-style-type: none"> • Apical five-chamber for central jets (PT-LAX for eccentric jets) • Optimize colour flow imaging of AR • Zoom the image of the regurgitant aortic valve • Increase the Nyquist limit in apical views/decrease or increase in PT-LAX • With the cine mode select the best PISA • Display the colour off and on to visualize the AR orifice • Measure the PISA radius at diastole using the first aliasing and along the direction of the ultrasound beam • Measure AR peak velocity and TVI (CW) • Calculate flow rate, EROA, R Vol 	<ul style="list-style-type: none"> • Can be used in eccentric jet • Quantitative: estimate lesion severity (EROA) and volume overload (R Vol) 	<ul style="list-style-type: none"> • PISA shape affected <ul style="list-style-type: none"> – by the aliasing velocity – in the case of non-circular orifice – by systolic changes in regurgitant flow – by adjacent structures (flow constraint) • PISA radius is more a hemi-ellipse • Errors in PISA measurement are squared • Inter-observer variability • Not valid for multiple jets • Feasibility limited by aortic valve calcifications
Doppler volumetric method (PW)	<ul style="list-style-type: none"> • Flow across the mitral valve • Measure the mitral inflow by placing the PW sample volume at the mitral annulus (apical four-chamber view) • Measure the mitral annulus diameter (apical four-chamber view) at the maximal opening of the mitral valve (2–3 frames after the end-systole) • Flow across the aortic valve • Measure the LVOT flow by placing the PW sample volume 5 mm below the aortic cusps (apical five-chamber view) • Measure the LVOT diameter (parasternal long-axis view) 	<ul style="list-style-type: none"> • Quantitative: estimate lesion severity (ERO) and volume overload (R Vol) • Valid in multiple jets 	<ul style="list-style-type: none"> • Time-consuming • Requires multiple measurements: source of errors • Not applicable in the case of significant MR (use the pulmonic site)
CW AR jet profile	<ul style="list-style-type: none"> • Apical five-chamber 	<ul style="list-style-type: none"> • Simple, easily available 	<ul style="list-style-type: none"> • Qualitative, complementary finding • Complete signal difficult to obtain in eccentric jet

Continued

Table 3 Continued

Parameters	Recordings	Usefulness/Advantages	Limitations
Pressure half-time	<ul style="list-style-type: none"> • Apical five-chamber • CW AR jet 	<ul style="list-style-type: none"> • Simple 	<ul style="list-style-type: none"> • Affected by LV compliance, blood pressure, acuity of AR
Diastolic flow reversal in descending aorta	<ul style="list-style-type: none"> • PW Doppler • Proximal descending aorta/abdominal aorta 	<ul style="list-style-type: none"> • Simple 	<ul style="list-style-type: none"> • Affected by sample volume location and acuity of AR • Affected by aortic compliance • Brief velocity reversal is normal • Cut-off validated for distal aortic arch
LV size	<ul style="list-style-type: none"> • Use preferably the Simpson method 	<ul style="list-style-type: none"> • Dilatation sensitive for chronic significant AR • Normal size almost excludes significant chronic AR 	<ul style="list-style-type: none"> • Dilatation observed in other conditions (non-specific) • May be normal in acute severe AR

AR, aortic regurgitation; CW, continuous-wave; EROA, effective regurgitant orifice area; LV, left ventricle; PW, pulse wave; R Vol, regurgitant volume; VC, vena contracta.

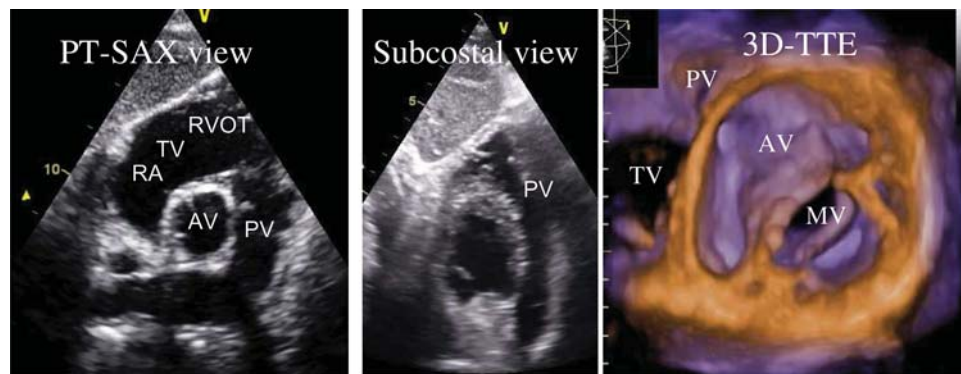


Figure 14 Two- and three-dimensional echo recordings of the pulmonic valve. PT-SAX, parasternal short-axis view.

the pulmonic valve (at the junction of the RV outflow tract and pulmonary annulus) in the parasternal short-axis view or from the subcostal view. Although this measurement suffers from a high inter-observer variability, a jet width that occupies >65% of the RV outflow tract width measured in the same frame is in favour of severe PR.

Vena contracta width

Although the vena contracta width is probably a more accurate method than the jet width to evaluate PR severity by colour Doppler, it lacks validation studies (Figures 15 and 16). As for other regurgitations, the same limitations are applicable. The shape of the vena contracta is complex in most cases. The 3D vena contracta is correlated with the 2D vena contracta but provides more quantitative assessment of PR.⁴⁵ The EROA values of <20, 21–115, and >115 mm² have been proposed to serve as cut-offs for PR grade mild, moderate, and severe. By multiplying

the 3D vena contracta with the spectral Doppler-derived velocity integral of the PR jet, the R Vol can be obtained. The regurgitant volume values of <15, 15–115, and >115 mL have also been proposed to serve as cut-offs for PR grade mild, moderate, and severe. These values require further validation since they are coming from a single study. Values are relatively high and could reflect some technical drawbacks.

The flow convergence method

In some patients, the flow convergence zone can be assessed (Figure 17). However, no studies have examined the clinical accuracy of this method in quantifying the severity of PR.

Pulsed Doppler

Theoretically, PW Doppler assessment of the forward and the reverse flows at the pulmonary annulus and in the pulmonary artery can be used to calculate R Vol and regurgitant fraction.

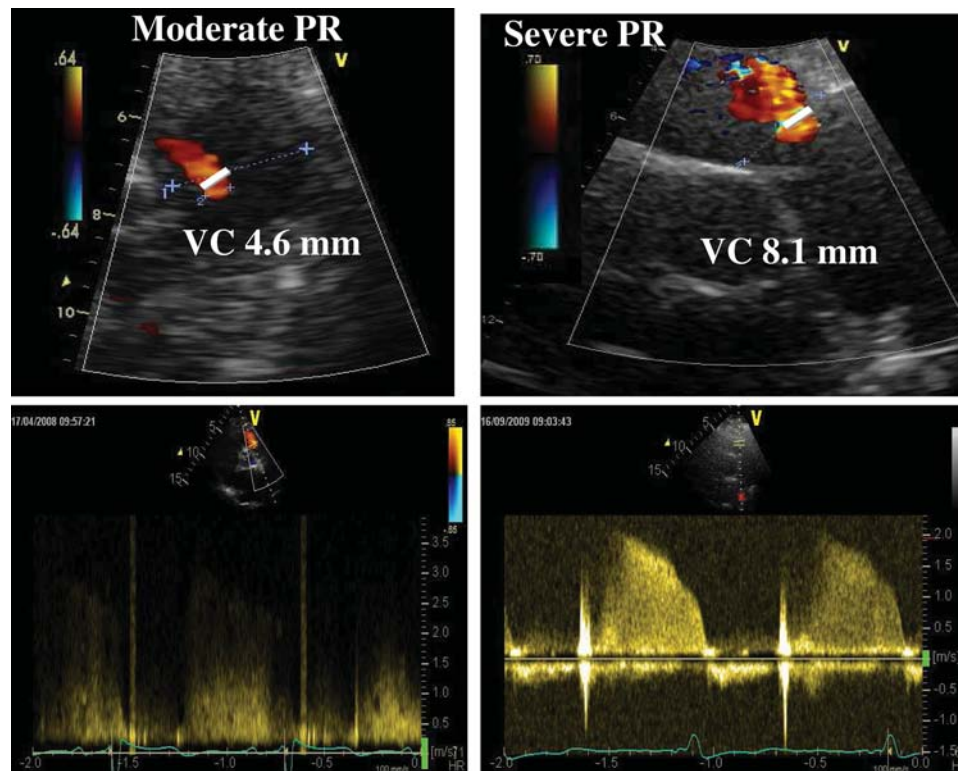


Figure 15 Assessment of pulmonary regurgitation (PR) severity by using colour flow imaging. (Top) Measurement of the vena contracta width in two patients with PR (left: moderate, right: severe). (Bottom) Continuous-wave Doppler recordings.

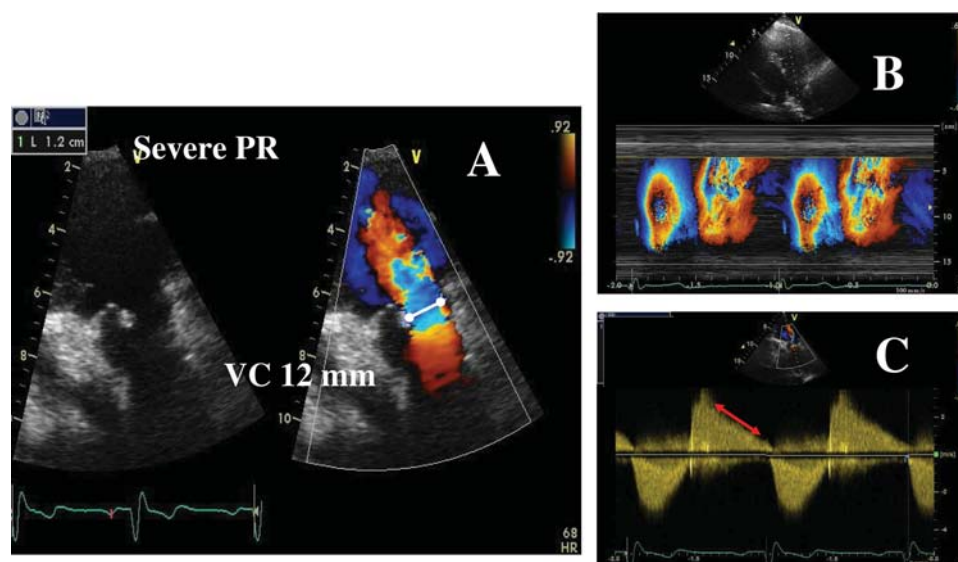


Figure 16 Example of a patient with a severe pulmonary regurgitation (PR). (A) Complete lack of valve coaptation (left) and measurement of the vena contracta width (VC) (right); (B) colour-coded M-mode depicting the time dependency of flow signal during the heart cycle; (C) continuous Doppler recording of PR showing a rapid flow deceleration during the diastole (red arrow) and increased systolic flow velocity (not related to concomitant pulmonary stenosis).

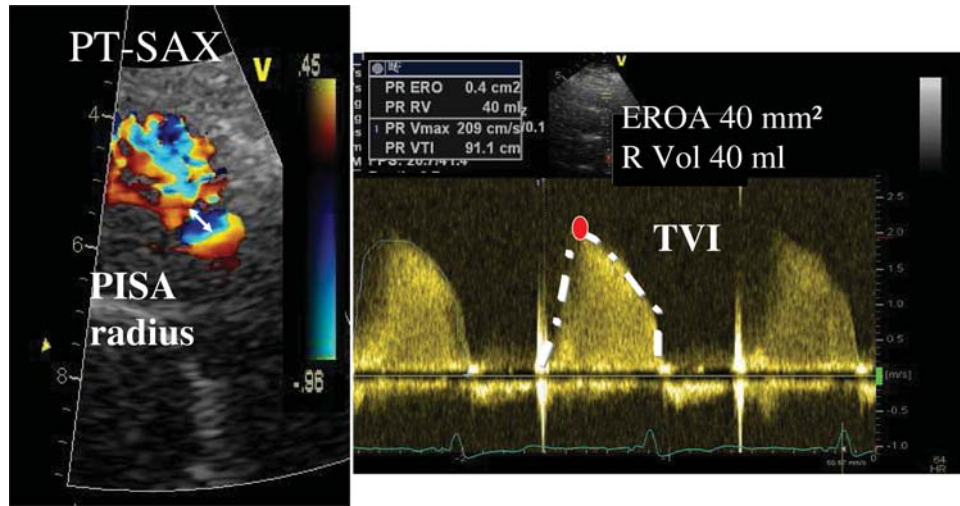


Figure 17 Assessment of pulmonary regurgitation by the proximal isovelocity surface area (PISA) method. PT-SAX, parasternal short-axis view; EROA, effective regurgitant orifice area; R Vol, regurgitant volume.

Table 4 Grading the severity of PR

Parameters	Mild	Moderate	Severe
Qualitative			
Pulmonic valve morphology	Normal	Normal/ abnormal	Abnormal
Colour flow PR jet width ^a	Small, usually <10 mm in length with a narrow origin	Intermediate	Large, with a wide origin; may be brief in duration
CW signal of PR jet ^b	Faint/slow deceleration	Dense/variable	Dense/steep deceleration, early termination of diastolic flow
Pulmonic vs. Aortic flow by PW	Normal or slightly increased	Intermediate	Greatly increased
Semi-quantitative			
VC width (mm)	Not defined	Not defined	Not defined
Quantitative			
EROA (mm ²)	Not defined	Not defined	Not defined
R Vol (mL)	Not defined	Not defined	Not defined
+RV size ^c			

PR, pulmonic regurgitation; CW, continuous wave; EROA, effective regurgitant orifice area; PW, pulse wave; RV, right ventricle; R Vol, regurgitant volume; VC, vena contracta.

^aAt a Nyquist limit of 50–60 cm/s.

^bSteep deceleration is not specific for severe PR.

^cUnless for other reasons, the RV size is usually normal in patients with mild PR. In acute severe PR, the RV size is often normal. Accepted cut-off values for non-significant RV enlargement (measurements obtained from the apical four-chamber view): Mid RV dimension ≤ 33 mm, RV end-diastolic area ≤ 28 cm², RV end-systolic area ≤ 16 cm², RV fractional area change $>32\%$, maximal.

The pulmonary annulus should be measured carefully during early ejection (2–3 frames after the R wave on the ECG), just below the valve. This technique is subject to errors in measurement and is not well validated.⁴⁶

Continuous-wave Doppler

There is no clinically accepted method of quantifying PR using CW Doppler. The density of the CW signal provides a qualitative measure of regurgitation.⁴⁷ In mild PR, there is a slow deceleration

of the jet velocity. A rapid deceleration rate with termination of flow in mid to late diastole is not specific but compatible with severe regurgitation.

Consequences of pulmonary regurgitation

Evaluation of the size and function of the RV in the absence of pulmonary hypertension provides indirect clues to the severity of PR.⁸

Table 5 Echocardiographic parameters used to quantify PR severity: recordings, advantages, and limitations

Parameters	Recordings	Usefulness/Advantages	Limitations
Pulmonic valve morphology	<ul style="list-style-type: none"> • Visual assessment • Multiple views 	<ul style="list-style-type: none"> • Flail valve is specific for significant PR 	<ul style="list-style-type: none"> • Other abnormalities are non-specific of significant PR
Colour flow PR jet	<ul style="list-style-type: none"> • Optimize colour gain/scale • Evaluate in parasternal short-axis view 	<ul style="list-style-type: none"> • Ease of use • Evaluates the spatial orientation of PR jet • Good screening test for mild vs. severe PR 	<ul style="list-style-type: none"> • Influenced by technical and haemodynamic factors
VC width	<ul style="list-style-type: none"> • Parasternal short-axis view • Optimize colour gain/scale and identify the three components of the regurgitant jet • Reduce the colour sector size and imaging depth to maximize frame rate • Expand the selected zone (zoom) and find the best frame for measurement • Measure the smallest VC 	<ul style="list-style-type: none"> • Possible if the pulmonic valve is well visualized • Relatively independent of haemodynamic and instrumentation factors • Not affected by other valve leak • Normally good as for the other valves 	<ul style="list-style-type: none"> • Difficult to perform in the majority of patients • Lacks published data
PISA method	<ul style="list-style-type: none"> • Parasternal short-axis view • Optimize colour flow imaging of PR and zoom the selected region • Decrease the Nyquist limit (colour flow zero baseline) • Measure the PISA radius at mid-systole using the first aliasing and along the direction of the ultrasound beam • Measure PR peak velocity and TVI (CW) • Calculate flow rate, EROA, R Vol 	<ul style="list-style-type: none"> • Quantitative • Normally good as for the other valves 	<ul style="list-style-type: none"> • Difficult to perform in the majority of patients • Lacks published data
CW PR jet profile	<ul style="list-style-type: none"> • Parasternal short-axis view 	<ul style="list-style-type: none"> • Simple, easily available 	<ul style="list-style-type: none"> • Qualitative, complementary finding
RV size	<ul style="list-style-type: none"> • Use preferably the RV dimension from the apical four-chamber view 	<ul style="list-style-type: none"> • Dilatation sensitive for chronic significant PR • Normal size almost excludes significant chronic PR 	<ul style="list-style-type: none"> • Dilatation observed in other conditions (non-specific) • May be normal in acute severe PR

CW, continuous-wave; RV, right ventricle; MR, mitral regurgitation; VC, vena contracta

Evidence of RV dilatation is however not specific for severe PR. Nevertheless, its absence suggests milder degree of PR. As for TR, the RV function is classically evaluated by the RV ejection fraction. The utility of the new indices deriving from tissue Doppler imaging has not been extensively examined in the context of PR unrelated to congenital heart disease. In the tetralogy of Fallot, the severity of PR has a negative influence on RV functional parameters and there is significant relation between RV functions and exercise capacity. In this disease, the myocardial acceleration during the isovolumic contraction is a new emerging index of RV function. The assessment of RV function in the setting of congenital heart disease is not the scope of this document.

Role of exercise echocardiography

Latent RV dysfunction and impaired functional response to stress can be unmasked by exercise echocardiography. Except in the

setting of congenital heart disease, the value of exercise testing in patients with PR has not been examined.⁴⁸

Integrating indices of severity

Echocardiographic assessment of PR includes integration of data from 2D/3D imaging of the pulmonary valve and RV as well as Doppler measures of regurgitant severity (Table 4). In the absence of extensive data on quantitation of PR, the experts recommend to assess the PR severity by using the different approaches available and to corroborate each other. Advantages and limitations of the various echo Doppler parameters used in assessing PR severity are detailed in Table 5.

Key point

Grading of PR severity remains difficult since standards for quantification of PR are less robust than for AR. The vena contracta is probably the most accurate approach. If possible the PISA method could provide quantitative

evaluation of PR. In all cases, the experts recommend corroborating the results of these methods with the other available parameters.

Recommended follow-up

As for other valvular regurgitation, the follow-up of patients with PR depends on the aetiology and the severity of PR, the size and function of the RV, and the associated diseases. Although information is limited, careful follow-up should be organized in patients with moderate-to-severe PR.

Conflict of interest: none declared.

References

- Vahanian A, Baumgartner H, Bax J, Butchart E, Dion R, Filippatos G *et al*. Guidelines on the management of valvular heart disease: the Task Force on the Management of Valvular Heart Disease of the European Society of Cardiology. *Eur Heart J* 2007;**28**:230–68.
- Zoghbi WA, Enriquez-Sarano M, Foster E, Grayburn PA, Kraft CD, Levine RA *et al*. Recommendations for evaluation of the severity of native valvular regurgitation with two-dimensional and Doppler echocardiography. *J Am Soc Echocardiogr* 2003;**16**:777–802.
- Popescu BA, Andrade MJ, Badano LP, Fox KF, Flachskampf FA, Lancellotti P *et al*. European Association of Echocardiography recommendations for training, competence, and quality improvement in echocardiography. *Eur J Echocardiogr* 2009;**10**:893–905.
- Carpentier A, Chauvaud S, Fabiani JN, Deloche A, Relland J, Lessana A *et al*. Reconstructive surgery of mitral valve incompetence: ten-year appraisal. *J Thorac Cardiovasc Surg* 1980;**79**:338–48.
- Evangelista A, Flachskampf F, Lancellotti P, Badano L, Aguilar R, Monaghan M *et al*. European Association of Echocardiography. European Association of Echocardiography recommendations for standardization of performance, digital storage and reporting of echocardiographic studies. *Eur J Echocardiogr* 2008;**9**:438–48.
- Lang R, Bierig M, Devereux R, Flachskampf F, Foster E, Pellikka P *et al*. Recommendations for chamber quantification. *Eur J Echocardiogr* 2006;**7**:79–108.
- Senior R, Becher H, Monaghan M, Agati L, Zamorano J, Vanoverschelde JL *et al*. Contrast echocardiography: evidence-based recommendations by European Association of Echocardiography. *Eur J Echocardiogr* 2009;**10**:194–212.
- Haddad F, Doyle R, Murphy DJ, Hunt SA. Right ventricular function in cardiovascular disease, part II: pathophysiology, clinical importance, and management of right ventricular failure. *Circulation* 2008;**117**:1717–31.
- Badano LP, Agricola E, Perez de Isla L, Gianfagna P, Zamorano JL. Evaluation of the tricuspid valve morphology and function by transthoracic real-time three-dimensional echocardiography. *Eur J Echocardiogr* 2009;**10**:477–84.
- Chen CG, Thomas JD, Anconina J, Harrigan P, Mueller L, Picard MH *et al*. Impact of impinging wall jet on color Doppler quantification of mitral regurgitation. *Circulation* 1991;**84**:712–20.
- Lebrun F, Lancellotti P, Piérard LA. Quantitation of functional mitral regurgitation during bicycle exercise in patients with heart failure. *J Am Coll Cardiol* 2001;**38**:1685–92.
- Roberts BJ, Grayburn PA. Color flow imaging of the vena contracta in mitral regurgitation: technical considerations. *J Am Soc Echocardiogr* 2003;**16**:1002–6.
- Fehske W, Omran H, Manz M, Köhler J, Hagedorff A, Lüderitz B. Color-coded Doppler imaging of the vena contracta as a basis for quantification of pure mitral regurgitation. *Am J Cardiol* 1994;**73**:268–74.
- Enriquez-Sarano M, Seward JB, Bailey KR, Tajik AJ. Effective regurgitant orifice area: a noninvasive Doppler development of an old hemodynamic concept. *J Am Coll Cardiol* 1994;**23**:443–51.
- Enriquez-Sarano M, Tajik AJ, Bailey KR, Seward JB. Color flow imaging compared with quantitative Doppler assessment of severity of mitral regurgitation: influence of eccentricity of jet and mechanism of regurgitation. *J Am Coll Cardiol* 1993;**21**:1211–9.
- Enriquez-Sarano M, Miller FA Jr, Hayes SN, Bailey KR, Tajik AJ, Seward JB. Effective mitral regurgitant orifice area: clinical use and pitfalls of the proximal isovelocity surface area method. *J Am Coll Cardiol* 1995;**25**:703–9.
- Enriquez-Sarano M, Bailey KR, Seward JB, Tajik AJ, Krohn MJ, Mays JM. Quantitative Doppler assessment of valvular regurgitation. *Circulation* 1993;**87**:841–8.
- Tribouilloy C, Shen WF, Leborgne L, Trojette F, Rey JL, Lesbre JP. Comparative value of Doppler echocardiography and cardiac catheterization for management decision - making in patients with left sided valvular regurgitation. *Eur Heart J* 1996;**17**:272–80.
- Gerding A, Mügge A. What the cardiac surgeon needs to know prior to aortic valve surgery: impact of echocardiography. *Eur J Cardiothorac Surg* 2009;**35**:960–4.
- Baumgartner H, Hung J, Bermejo J, Chambers JB, Evangelista A, Griffin BP *et al*. EAE/ASE. Echocardiographic assessment of valve stenosis: EAE/ASE recommendations for clinical practice. *Eur J Echocardiogr* 2009;**10**:1–25.
- Nkomo VT, Enriquez-Sarano M, Ammass NM, Melton LJ 3rd, Bailey KR, Desjardins V *et al*. Bicuspid aortic valve associated with aortic dilatation: a community-based study. *Arterioscler Thromb Vasc Biol* 2003;**23**:351–6.
- Espinola-Zavaleta N, Muñoz-Castellanos L, Attié F, Hernández-Morales G, Zamora-González C, Dueñas-Carbajal R *et al*. Anatomic three-dimensional echocardiographic correlation of bicuspid aortic valve. *J Am Soc Echocardiogr* 2003;**16**:46–53.
- de Waroux JB, Pouleur AC, Goffinet C, Vancraeynest D, Van Dyck M, Robert A *et al*. Functional anatomy of aortic regurgitation: accuracy, prediction of surgical reparability, and outcome implications of transesophageal echocardiography. *Circulation* 2007;**116**:1264–9.
- Perry GJ, Helmcke F, Nanda NC, Byard C, Soto B. Evaluation of aortic insufficiency by Doppler colour flow mapping. *J Am Coll Cardiol* 1987;**9**:952–9.
- Tribouilloy CM, Enriquez-Sarano M, Bailey KR, Seward JB, Tajik AJ. Assessment of severity of aortic regurgitation using the width of the vena contracta: A clinical color Doppler imaging study. *Circulation* 2000;**102**:558–64.
- Eren M, Eksik A, Gorgulu S, Norgaz T, Dagdeviren B, Bolca O *et al*. Determination of vena contracta and its value in evaluating severity of aortic regurgitation. *J Heart Valve Dis* 2002;**11**:567–75.
- Fang L, Hsiung MC, Miller AP, Nanda NC, Yin WH, Young MS *et al*. Assessment of aortic regurgitation by live three-dimensional transthoracic echocardiographic measurements of vena contracta area: usefulness and validation. *Echocardiography* 2005;**22**:775–81.
- Tribouilloy CM, Enriquez-Sarano M, Fett SL, Bailey KR, Seward JB, Tajik AJ. Application of the proximal flow convergence method to calculate the effective regurgitant orifice area in aortic regurgitation. *J Am Coll Cardiol* 1998;**32**:1032–9.
- Pouleur AC, de Waroux JB, Goffinet C, Vancraeynest D, Pasquet A, Gerber BL *et al*. Accuracy of the flow convergence method for quantification of aortic regurgitation in patients with central versus eccentric jets. *Am J Cardiol* 2008;**102**:475–80.
- Detaint D, Messika-Zeitoun D, Maalouf J, Tribouilloy C, Mahoney DW, Tajik AJ *et al*. Quantitative echocardiographic determinants of clinical outcome in asymptomatic patients with aortic regurgitation: a prospective study. *JACC Cardiovasc Imaging* 2008;**1**:1–11.
- Ekery DL, Davidoff R. AR: quantitative methods by echocardiography. *Echocardiography* 2000;**17**:293–302.
- Tribouilloy C, Avinée P, Shen WF, Rey JL, Slama M, Lesbre JP. End diastolic flow velocity just beneath the aortic isthmus assessed by pulsed Doppler echocardiography: a new predictor of the aortic regurgitant fraction. *Br Heart J* 1991;**65**:37–40.
- Samstad SO, Hegrenæs L, Skjaerpe T, Hatle L. Half time of the diastolic aortoven-tricular pressure difference by continuous wave Doppler ultrasound: a measure of the severity of AR? *Br Heart J* 1989;**61**:336–43.
- Griffin BP, Flachskampf FA, Siu S, Weyman AE, Thomas JD. The effects of regurgitant orifice size, chamber compliance, and systemic vascular resistance on aortic regurgitant velocity slope and pressure half-time. *Am Heart J* 1991;**122**:1049–56.
- Vinereanu D, Ionescu AA, Fraser AG. Assessment of LV long-axis contraction can detect early myocardial dysfunction in asymptomatic patients with severe AR. *Heart* 2001;**85**:30–6.
- Marciniak A, Sutherland GR, Marciniak M, Claus P, Bijmens B, Jahangiri M. Myocardial deformation abnormalities in patients with aortic regurgitation: a strain rate imaging study. *Eur J Echocardiogr* 2009;**10**:112–9.
- Piérard LA, Lancellotti P. Stress testing in valve disease. *Heart* 2007;**93**:766–72.
- Picano E, Pibarot P, Lancellotti P, Monin JL, Bonow RO. The emerging role of exercise testing and stress echocardiography in valvular heart disease. *J Am Coll Cardiol* 2009;**54**:2251–60.
- Wahi S, Haluska B, Pasquet A, Case C, Rimmerman CM, Marwick TH. Exercise echocardiography predicts development of LV dysfunction in medically and surgically treated patients with asymptomatic severe AR. *Heart* 2000;**84**:606–14.
- Bonow RO, Carabello BA, Chatterjee K, de Leon AC Jr, Faxon DP, Freed MD *et al*. 2008 Focused update incorporated into the ACC/AHA 2006 guidelines for the management of patients with valvular heart disease. *Circulation* 2008;**118**:e523–661.
- Choong CY, Abascal VM, Weyman J, Levine RA, Gentile F, Thomas JD *et al*. Prevalence of valvular regurgitation by Doppler echocardiography in patients with structurally normal hearts by two-dimensional echocardiography. *Am Heart J* 1989;**117**:636–42.
- Bouzas B, Kilner PJ, Gatzoulis MA. Pulmonary regurgitation: not a benign lesion. *Eur Heart J* 2005;**26**:433–9.

43. Kobayashi J, Nakano S, Matsuda H, Arisawa J, Kawashima Y. Quantitative evaluation of pulmonary regurgitation after repair of tetralogy of Fallot using real-time flow imaging system. *Jpn Circ J* 1989;**53**:721–7.
44. Williams RV, Minich LL, Shaddy RE, Pagotto LT, Tani LY. Comparison of Doppler echocardiography with angiography for determining the severity of pulmonary regurgitation. *Am J Cardiol* 2002;**89**:1438–41.
45. Pothineni KR, Wells BJ, Hsiung MC, Nanda NC, Yelamanchili P, Suwanjutha T et al. Live/real time three-dimensional transthoracic echocardiographic assessment of pulmonary regurgitation. *Echocardiography* 2008;**25**:911–7.
46. Goldberg SJ, Allen HD. Quantitative assessment by Doppler echocardiography of pulmonary or aortic regurgitation. *Am J Cardiol* 1985;**56**:131–5.
47. Lei MH, Chen JJ, Ko YL, Cheng JJ, Kuan P, Lien WP. Reappraisal of quantitative evaluation of pulmonary regurgitation and estimation of pulmonary artery pressure by continuous wave Doppler echocardiography. *Cardiology* 1995;**86**:249–56.
48. Marx GR, Hicks RW, Allen HD, Goldberg SJ. Noninvasive assessment of hemodynamic responses to exercise in pulmonary regurgitation after operations to correct pulmonary outflow obstruction. *Am J Cardiol* 1988;**61**:595–601.