

Review

Hymen: facts and conceptions

Hegazy AA^{1,2}, Al-Rukban MO³

¹Department of Anatomy & Embryology, Faculty of Medicine, Zagazig University, Egypt, ²Department of Anatomy & Embryology, College of Medicine, Majmaah University, Kingdom of Saudi Arabia, ³Department of Family & Community Medicine, College of Medicine, King Saud University, Kingdom of Saudi Arabia

Correspondence

Abdelmonem A. Hegazy
Department of Anatomy & Embryology, Faculty of Medicine, Zagazig University, Egypt

E-mail:

ahegazy@zu.edu.eg

Keywords:

Hymen, Anatomy, Development, Abnormalities, Virginity

Funding

None

Competing Interest

None declared.

Received: October 9, 2012

Accepted: December 14, 2012

Abstract

Background: In conservative cultures, the presence of hymen without rupture in a virgin girl represents an indication of female pride and honor. Accordingly, there are many crimes, committed due to wrong views and conceptions among young people in such societies. The current review aimed to highlight the anatomy of the hymen, in a trial to create a better understanding and to eliminate misconceptions about virginity.

Methods: Databases of PubMed, ScienceDirect, SpringerLink, Wiley Interscience and others were searched. The research papers are studied and discussed.

Results: The hymen is a thin mucous membrane, partially closing the vaginal orifice. It represents an embryological remnant, originating from the urogenital sinus. It varies greatly in shape. Its elasticity increases after puberty so that it may allow penile penetration without rupture and bleeding.

Conclusions: Hymen is not an accurate indication of virginity. Knowledge of the hymen anatomy and its abnormalities is essential to eliminate the misconceptions about it.

Introduction

The hymen is a membrane, partially closing the external vaginal opening. Until now, many myths regarding its anatomy exist but are based primarily on dogma and lack of scientific knowledge.¹ In conservative cultures, its presence without rupture in a premarital girl represents an indication of her pride and honor. According to Arab customs, woman who is not found to be virgin on her wedding night will bring a great shame on her family. She might be killed by her brothers, uncles or even her father, thereby "cleansing the shame". Although such murders are illegal, the perpetrators escape prosecution because the tribal customs that underpin these actions are so strong.² Also, the husband might kill his bride, if he does not notice a bleeding as a result of defloration. In such cultures, the traditional proof of virginity is the occurrence of bleeding from ruptured hymen on wedding night. Therefore, the ignorance about structure of the hymen can lead to violence, such as 'honor killing' as well as psychological problems including suicidal feelings. Meanwhile, the physician's testimony about the appearance of the genitalia may be one of the key factors which determine the outcome of such cases.³ Therefore, the clinician should be familiar with normal prepubertal genital anatomy and hymenal configuration.⁴

The current review aimed to highlight anatomy of the hymen for medical practitioners and to eliminate misconceptions of some population about virginity that might represent a matter of life and death.

Methods

Databases of PubMed, ScienceDirect, SpringerLink, Wiley Interscience and others were searched. Search included all the available years. It was conducted between May 2011 and April 2012. The available research papers were studied and discussed. The contents included the results, discussion and conclusion.

Results

General Overview

The hymen is named after the God of marriage "Hymenaios" in classical Greek mythology.⁵ The word "hymen" is usually synonymous with virgin membrane. This concept has originated in Western cultures, since the medieval era when chastity among women was expected.⁶ In modern times, adolescents who live in countries with more liberal attitudes about sexuality may change their views about the hymen.⁷ The original concept is still predominant among people in Islamic culture. Sex before marriage is frowned upon by Muslims, but generally approved by non-Muslims. Sex out-

ide marriage is haram (a sin) in Islam.⁸

Humans are unique members of the primate group, possessing sexual characteristics different from other hominoids (apes).⁹ According to many sources, human female is the only primate member to possess a hymen.^{10,11} However, Balke et al reported the presence of membranous constriction (hymen) with an orifice, less than 2 cm in diameter in nulliparous elephants, that is not broken by mating, but only during birth.¹² Also, abnormal occurrence of hymen was detected in Murrah buffalo. It was considered to be a developmental anomaly of the genital tract in cattle.¹³

Anatomy of the vulva

Vulva is the term given to the female external genitalia. Its structure includes mons pubis, labia majora and labia minora (Fig 1). Anteriorly, the labia minora form the prepuce and split to enclose the clitoris. The vestibule is the area enclosed by the labia minora and contains the urethral and vaginal orifices.¹⁴ Bartholin’s glands (mucus-secreting glands) open into the groove between the hymen and the posterior part of the labia minora.¹⁵ Arterial supply of the vulva is derived from superficial and deep external pudendal branches of the femoral artery and the internal pudendal artery on each side. Venous drainage occurs via external pudendal veins to the long saphenous vein. Lymphatic drainage reaches superficial inguinal nodes, then femoral nodes and eventually to pelvic nodes. The sensory innervation is carried by the ilio-inguinal nerve (L1), perineal nerve (S3) and the perineal branch of the posterior cutaneous nerve of the thigh (S2).¹⁶

Variations of Hymenal Morphology

The hymen is a thin fold of mucous membrane situated just within the vaginal orifice.¹⁶ It is perforated to allow the egress of the menses. The aperture of the hymen ranges in diameter from pinpoint to one that admits the tip of one or even two fingers.¹⁷ The configuration of hymen differs dramatically from one female to another one.¹⁸ At birth, it is commonly annular in shape, while the crescentic configuration is most prevalent in children over age 3 years.¹⁹ Furthermore, the redundancy of the hymen decreased in 75% of subjects

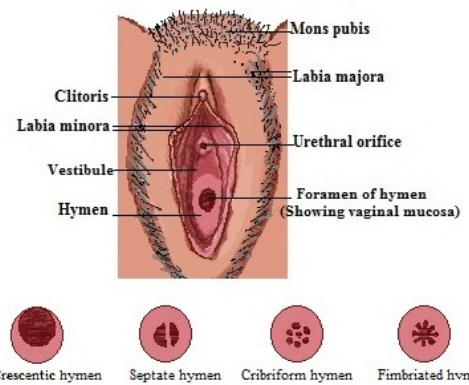


Figure 1: Normal anatomy of vulva and variations in the hymenal appearance.

during this period.²⁰ The adult hymen varies greatly in shape and area. When stretched, it is annular and widest posteriorly. Sometimes it is semilunar, concave towards the mons pubis. Occasionally it is cribriform (multiple small openings), septate hymen (a residual band, usually in the anteroposterior diameter) or fimbriated (or redundant) hymen (Fig 1).^{16, 21, 22} The common hymenal configurations in some studies are summarized in table 1.

Hymen size

Early attempts to clarify the normal size of hymen in a pre-pubertal girl focused on the opening size. The size of the transverse hymenal opening diameter was one of the most frequently used indicators of sexual abuse. Despite the upper normal limit of the normal diameter is not clearly established, some studies suggested that a diameter greater than 4 mm is too wide parameter, indicating sexual abuse children of all ages.^{28,29} However, other studies showed an upper limit of 8 mm in the absence of sexual abuse.³⁰ Confusions about the normal values of hymenal opening diameters led other authors to focus on the size of hymenal tissue, as an alternative criterion of sexual abuse. Narrowing (or attenuation) of the inferior hymenal rim is correlated with sexual abuse.³¹ The amount of tissue present between the hymenal edge and vestibule inferiorly at 6 o’clock, detected in non-abused girls is at least 1.0 mm in width.³² However, some studies conclu-

Table 1: Hyemenal configuration in previous studies

	Cases (n)	Age (m)	M (annular/ concentric)	Crescentic/ Posterior rim	Sleeve like/ small orifice	Fimbriated	Septate
Berenson et al. ²³	468	nb	80			19	1
Al Herbish ²⁴	345	nb	60	4.9	22	12.5	
Berenson and Grady ²⁵	135	36	39	61	2		1
	93	60	23	77	2		1
	80	84	18	82	3		1
	61	108	10	90	3		1
Heger et al. ²⁶	147	63	53	29.2	14.9		2
Myhre et al. ²⁷	194	69	6.7	78.4		0.5	

Data is mentioned as %.

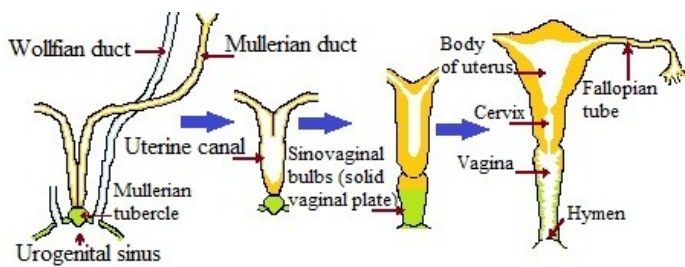


Figure 2: Development of female genital ducts (coronal sections).

ed that hymenal measurements demonstrated a high degree of overlapping between abused and non-abused girls.^{27,33} Furthermore, these values differ according to the child age, type of hymen, position of the examination, state of relaxation and cooperation of the female.³⁴

Histological structure

Hymen is composed mainly of elastic and collagenous connective tissue, covered on its both surfaces by stratified squamous epithelium, without any evidence of cornification. The epithelium is thicker at the attached edge. Nerve fibers are scarce, at the free margin of the hymen. No nerve cells and fibers are present at the free edge of the hymen. There is no trace of glandular or muscle element.³⁵ Hymen is relatively an avascular membrane so it is unlikely to bleed significantly even if it is torn.³⁶

Age related changes

Despite, there is no significant difference in hymenal configuration by race, a wide variations are noted by age.³⁷ In the newborn the hymen is vascular and the epithelium is thick.³⁵ In the prepubertal female, the lack of estrogen renders the hymenal tissue thin and friable.²² Therefore, there is no distensibility prior to puberty.²¹ At puberty, it becomes thick and redundant with a tendency of folding out.³⁸ During adolescence, circumferential hymenal elasticity increases.³⁹ The adolescent who has been sexually active may have a hymen that does not show obvious trauma, or the hymen may have old or new lacerations, extending down to the base.⁴⁰ At pregnancy, the epithelium of hymen becomes very thick and very rich in glycogen.⁴ After childbirth, nothing is left but few tags termed *carunculae myrtiformes*.¹⁵ At menopause, the epithelium becomes thin in response to estrogen deprivation.⁴

Development of Hymen

It is important to have a good grasp of embryology of the hymen to understand its nature and common anomalies that may ensue. Although the sex of the developing embryo is determined at the time of fertilization, external genitalia are the same till the 7th week of embryological development.⁴¹ The genital ducts develop from two pairs of ducts; mullerian and wolffian ducts (Fig 2). The mullerian duct arises as a longitudinal invagination of the epithelium on the anterolateral surface of the urogenital ridge. Cranially, the duct opens into the abdominal cavity. Caudally, it passes lateral to wolffian duct, then crosses it ventrally to grow caudomedially in close contact with the opposite duct. The two adjacent parts of the

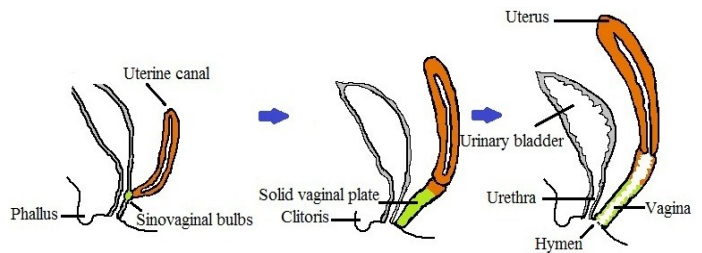


Figure 3: Development of vagina and uterus (sagittal sections).

ducts fuse together forming the uterine canal. The caudal tip of this canal forms a bulge into the posterior wall of urogenital sinus, forming mullerian tubercle.⁴² The fate of these ducts depends upon the genetic sex of the embryo. In XX individuals, the mullerian ducts develop into a uterus, fallopian tubes and vagina.⁴³ Vagina develops from two sources; the caudal part of uterine canal as well as solid vaginal plate, proliferating from the sinovaginal bulbs at the tip of fused mullerian ducts.⁴² Later, central canalization of the vaginal plate occurs, leaving the peripheral cells that form the epithelium of the vagina. Until late in the female's fetal life, the lumen of the vagina is separated from the cavity of the urogenital sinus by the hymen (Fig 3). During the perinatal period, it ruptures and remains as a thin fold of mucous membrane just within the vaginal orifice.⁴¹

Abnormalities of the Hymen

a. Hymenal polyps and tags

Hymenal polyps and tags are elongated projection of hymenal tissue protruding beyond the hymenal rim or extending from the rim itself.²⁰ They are common after birth. They are usually very small (less than 5 mm). Most resolve spontaneously and they are rarely seen after the age of 3 years. Very rarely they can persist and become more polypoid.⁴³ Although the etiology of this congenital feature is unknown, its frequent occurrence in the midline at birth has led to suggestion that these projections originate from septate hymens that cleave in utero or shortly after birth.⁴⁴

b. Hymenal ridges and bands

This congenital feature might be observed on the external or internal surface of the hymen. External ridges may be found, inferiorly at 6 o'clock or superiorly at 12 o'clock, immediately under the urethra. They occur in up to 86% of newborn females.²³ As the hymen becomes less redundant with aging, external ridges tend to resolve and can be observed by 3 years of age in only 7% of children who had this finding at birth.¹⁹ Internal ridges extend longitudinally from the hymen into the vagina. They may observed on the all four quadrants of hymen.²³

c. Hymenal notches

An angular or V-shaped indentation on the edge of the hymenal membrane is defined as a notch. Superior and lateral notches have been observed in 35% of newborn girls.²³ Their frequency decreases with age as superior notches widen to form crescentic hymens, or as superficial notches disappear

as the hymen becomes less redundant.^{44, 45} A notch extending to the junction of the hymen and vestibule in any location has been shown only in victims of abuse or trauma and should not be considered as a congenital finding.²⁰

d. Imperforate Hymen

It has been reported to occur in up to 0.1% of female newborns.^{46, 47} Imperforate hymen occurs mostly in a sporadic manner, although rare familial cases do occur.⁴⁷ It may be detected in the neonatal period, less commonly in childhood or, more typically, at adolescence when the girl presents with cryptomenorrhoea and haematocolpos.⁴⁸ Treatment is generally aimed to form a patent outflow tract. The traditional treatment is surgical hymenectomy with T, X, plus, or cruciform incisions and removal of excess hymenal tissue.⁴⁹ It is a simple procedure and yields good results. However, it may result in social problems for some girls, due to destruction of the hymen that represents a symbol of virginity in some cultures. There is another technique using the Foley catheter that represents an adequate alternative when preservation of the hymen is required.^{50, 51} Basaran et al stated that the imperforate hymen is somewhat thicker than the borders of the normal hymen.⁵² Therefore simple incision and sutures will eventually form a thick posterior rim of hymenal tissue suitable for defloration during sexual intercourse. Although, conservative surgery with simple incision and sutures might be an alternative option to standard treatment, the follow-up is necessary to exclude occurrence of re-closure of the hymen.⁵³

e. Microperforate Hymen

Microperforate hymen is a rare congenital condition consisting of a tiny hymeneal orifice with normal female genitals.^{54, 55} The microperforation is quite difficult to visualize.⁵⁴ Donato et al reported a case of microperforate hymen in which diagnosis and treatment was performed after decades of urethral coitus.⁵⁵

Function of the Hymen

The hymen has no known biological function and its rupture is of no medical consequences.⁵ However, its psychological and cultural significance as a sign of virginity has been enormous. In many societies, virginity of wives with intact hymen is highly desired and even demanded. A second hypothesis, suggests that the hymen is functioning in protection of the vaginal area from contamination by fecal and other materials, especially at the early stage of life.⁹

Rupture of the Hymen

The hymen may be ruptured by sexual intercourse. The rupture appears as irregular hymenal edges and narrow rims at the point of the injury. Later on, the jagged angular margins appear to be smoothed off.⁵⁶ However, deeper penetrating injuries of the hymen may lead to defects in the integrity of the hymen, situated posteriorly or posterolaterally.¹⁵ Despite definitive evidence of sexual contact (pregnancy), Kellogg et al noticed only 2 of 36 examined adolescents having genital changes that were diagnostic of penetrating trauma.⁵⁷ Possi-

ble explanations for the lack of genital trauma include: penetration does not result in visible tissue damage, or acute injuries occur but heal completely.⁵⁸ Similarly, Onan et al reported a case of spontaneous formation of imperforate hymen during pregnancy in the absence of previous surgical procedures.⁵⁹ This might be attributed to glycogenated epithelium, occurring in response to estrogen exposure at pregnancy.^{35, 59} In the prepubertal girl, because of the relative size of the structures, penetration occurs through the hymenal tissue and causes tearing. However, in the adolescent girl and adult woman consensual penetration occurs into the orifice which thus stretches, resulting in spreading and indeterminate disruption.^{60, 61} Many authors agreed that the so called rupture and bleeding of the hymen is not to be routinely expected after first coitus.^{60, 62-64} Other causes of hymenal rupture, other than sexual intercourse include vaginal insertion of objects such as tampons and digits, vigorous sporting activities, surgical procedures and falling on sharp objects.^{5, 65}

Hymen reconstruction

Hymen reconstruction, also described as hymenoplasty or hymenorrhaphy, has emerged as a procedure restoring the ability of the hymen to bleed at sexual intercourse on the wedding night. It is indicated in some communities to protect women from violent reprisals.⁶⁶ It is sometimes needed as part of rape rehabilitation.⁵ Hymen reconstruction is a minor operation, performed on the eve of the wedding.⁶⁷ It is done by approximating the free borders of the remnants, using fine, absorbable sutures to achieve partial occlusion of the introitus. If hymenal remnants are inadequate, a small flap of vaginal mucosa is reflected from the posterior vaginal wall and approximated to the anterior wall as a band across the hymenal ring.⁶⁸

Virginity and chastity

Virginity revolves around whether a female has ever had sex. It has been noticed that the description "virgin" itself shows women's subordination to men, since the French term "virgine" is derived from Latin by combination of the words "vir," meaning "man," and "genere," meaning generated or "created for".⁶⁹ The Jewish, Christian, Muslims faiths all attach considerable importance to the premarital virginity.⁷⁰ In fact, virginity is a physiological state, indicated though not conclusively by an intact hymen (since some may be sufficiently elastic to allow sexual penetration), whereas chastity is a status of moral virtue.⁵ The postpubertal hymen is elastic so that some prostitutes have been found to have intact hymens.⁷¹ Therefore, the absence of any injury to the hymen should not be used as a reason to negate the possibility that the adolescent has experienced vaginal penetration.⁶¹ Strengthening the norm of virginity or delaying sex might be helpful to prevent HIV and other sexually transmitted infections among young people in some rural settings where access to information and condoms is limited.⁷²

Virginity Testing

Extraordinary as it may seem in the 21st century, examinati-

tion of young women to ascertain evidence of consenting sexual activity remains a flourishing activity.⁷³ If there is any suspicion about virginity, young girls are forced to undergo hymen examination against their will. This forced virginity testing appears to be a factor in a significant number of suicides of young Turkish women. Nurses and midwives are always being involved in this procedure.⁷⁴ Virginity testing is likely to be harmful for many girls, regardless of whether they pass the test. This examination strips the girl of her dignity. Some parents under societal pressure may coerce or persuade their daughters to undergo the practice. To preserve their virginity, girls sometimes will have anal sexual intercourse. This carries more risk of HIV infection than vaginal intercourse if the sexual partner is HIV-infected.⁷⁵

Discussion

Misconceptions in regard to virginity may lead to many avoidable social disasters in conservative cultures. The importance of virginity in such cultures is not only a matter of individual wishes or values, but it is rooted in traditions regarding the honor of the extended families of the bride and groom. Virgin in Islamic cultures is defined as the girl who has not married and never experienced penile penetration of the vagina. Conceptions about the hymen and virginity carry many wrong ideas. Despite knowing female menses, many male youths especially in rural areas do not know that the hymen is normally perforated for egress of that menses. Moreover, the traditional proof of virginity is the occurrence of bleeding as a result of defloration. On contrary to these misconceptions, the post pubertal hymen is elastic so that it may stretch to allow sexual penetration without tears and bleeding.⁷¹

On the other hand, the postpubertal hymen is relatively a bloodless membrane, so if it is torn, it mostly result in a slight bleeding.³⁶ This bleeding might be unnoticed by the husband especially after ejaculation, where the color of blood becomes faint after its mixing with the seminal fluid. Factors that may increase the likelihood of bleeding at that time are forced sexual relations, lack of arousal or lubrication, vaginal infection, genital malformation (e.g. imperforate hymen), generalized bleeding disorder, or if the girl is at prepuberty.⁷⁶ Contrary to the common popular belief, the hymen is not a solid septum separating the vagina from the external world, but rather an embryological thin mucous membrane remnant. This misconception might lead to fixation of the groom upon defloration that in conjunction with ignorance about the anatomy of the hymen and female genitalia can result in a traumatic wedding night, instead of the required pleasure. Violent penile penetration leading to minor lacerations of vaginal wall rather than that of hymen appears to be responsible for "blood stained bed-sheets".³⁶ On the other hand, tears are more likely to occur in cases prepubertal assault than after puberty due to coverage of estrogen. Other factors might play a role in the occurrence of severe bleeding in cases of children. These factors include the increased vascularity and decreased elasticity of the prepubertal hymen, as well as incongruous of genitalia size of the

adult male and prepubertal female. Moreover, the hymenal tissue of prepubertal females is thin and friable, rendering it to be easily torn.²² Therefore, marriage before puberty that usually happened in some rural areas should be prohibited.

Some girls who denied past intercourse had complete clefts in the posterior rim of the hymen.^{61,62} This might be explained by factors other than sexual intercourse that might lead to hymenal tears. These factors include violent sports, falling on sharp objects, use of tampons and surgical procedures.^{5,65} Premarital girls in such societies must avoid such factors. They can use pads for menses, instead of using tampons, until they become sexually active after marriage. Also, it is imperative that the examiner digitally explore the vaginal orifice before any attempt to insert a speculum is made. In case of female with intact hymen, the anterior wall of the rectum might be the method of examining the pelvic organs instead of vaginal examination.

In some societies, women who have had sexual relationships before marriage, might request the hymen repair due to fear of being divorced or even killed. According to Amy, there are increasing demands from young women, mostly but not exclusively of Muslim faith, to seek certificates of virginity for them or to reconstruct their hymen before they marry in Europe.⁷⁰ Through the creation of artificial virginity, she becomes pure again and her honor is regained.² Although, it is a simple procedure, many Muslim doctors refuse to perform it. They consider such procedure as a fraud for her groom. This is because the adultery or sexual relationship outside marriage is strictly prohibited in Islam.

The hymen is perforated during embryonic life. Failure of this process could result in imperforate hymen. These cases need surgical hymenectomy to relieve the blockage, for egress of menses. Follow-up after this surgery is necessary to exclude occurrence of re-closure of the hymen. Also, it should be done under great care and asepsis as the closed vagina lacks its protecting Doederlein's bacilli and the pH is alkaline or weakly acidic, so there is poor natural resistance to bacteria entering from below and the blood and debris provide a good culture medium.⁷⁷ Imperforate hymen is considered another cause for loss of the hymen, without experience of sexual intercourse.

The integrity of the hymen is not easily assessed. This is attributed to the wide varieties of its shape. Also, there are many congenital features that might mislead with the sexual assault. Hymenal notches or bumps are often present in the normal child and should not prompt evaluation of sexual abuse without associated history or parental concern. The exception to this is the finding of notches in the inferior portion of the hymen from 5 to 7 o'clock, which should prompt screening for sexual abuse.⁴⁵ If virginity testing is inevitable, it should be done by experienced medical professionals e.g. gynecologists or forensic physicians to avoid the danger of over-interpreting small anatomic findings that may lie within the range of normal variations. Many authors showed that measurement of the hymenal diameter has no association

with sexual abuse.^{25, 27, 44} Furthermore, it is generally accepted that the hymen is a poor indicator of penetrative sexual activity in postpubertal girls.^{57, 61, 62} Given these facts, it is obvious that hymenal bleeding on the wedding night might not be a sign of virginity or even chastity. On the other hand, if a girl does not bleed at the first experience of sexual intercourse, it does not mean that she has lost her virginity before. Therefore, promoting the concept of bleeding on the wedding night as a sign of virginity is nothing but perpetuation of myth. Health education for youths is recommended to eliminate such myths and wrong views about the hymen and virginity.

Conclusion

The hymen is a thin embryological remnant, partially closing the vaginal orifice. It is not an accurate indication of virginity. It may be ruptured by sexual intercourse. However, some hymens are elastic, allowing vaginal intercourse without being injured. At the same time, it may be broken accidentally by tampon use or vigorous exercise.

References:

1. Frasier LD, Makoroff KL. Medical evidence and expert testimony in child sexual abuse. *Juvenile Family Court J*, 2006;41-50.
2. Kandela P. Egypt's trade in hymen repair. *Lancet*. 1996;347:1615.
3. Baum E, Grodin MA, Alpert JJ, Glantz L. Child sexual abuse, criminal justice and the pediatrician. *Pediatrics*. 1987;79:437-9.
4. Berek JS, Rinehart RD. Berek & Novak's Gynecology (14th edition). 2007. California, Lippincott Williams & Wilkins.
5. Cook RJ, Dickens BM. Hymen reconstruction: ethical and legal issues. *Int J Gynaecol Obstet*. 2009;107:266-9.
6. Wogan-Brown J. Virginity now and then: a response to medieval virginities. In: Bernau A, Evans R, Salih S, editors. *Medieval Virginities*. Cardiff, UK: Cardiff University of Wales Press. 2003:234-53.
7. Christianson M, Eriksson C. A girl thing: perceptions concerning the word "hymen" among young Swedish women and men. *J Midwifery Women's Health*. 2011;56:167-72.
8. Smerecnik C, Schaalma H, Gerjo K, Meijer S, Poelman J. An exploratory study of Muslim adolescents, views on sexuality: Implications for sex education and prevention. *BMC Public Health* 2010;10:533.
9. Hobday AJ, Haury L, Dayton PK. Function of the human hymen. *Med Hypotheses*. 1997;49:171-3.
10. Bufley N. The evolution of concealed ovulation. *Am Nat*. 1979;114:835-58.
11. Smith R L. Human sperm competition. In: Smith R L, editor. *Sperm Competition and the Evolution of Animal Mating Systems*. New York: Academic Press. 1984:601-59.
12. Balke JM, Boever WJ, Ellersieck MR, Seal US, Smith DA. Anatomy of the reproductive tract of the female African elephant (*Loxodonta africana*) with reference to development of techniques for artificial breeding. *J Reprod Fertil*. 1988;84:485-92.
13. Singh G, Singh P, Pandey AK, Kumar S, Sunder S, et al. A case report of persistent hymen in a Murrah buffalo. *Haryana Vet*. 2010;49:75.
14. Faiz O, Moffat D. *Anatomy at a Glance*. 2002. Oxford Blackwell Science Ltd.
15. Ellis H. *Clinical Anatomy: A revision and applied anatomy for clinical students* (11th edition). 2006. Oxford: Blackwell Publishing Ltd.
16. Standring S. *Gray's Anatomy: The anatomical basis of clinical practice* (39th edition). 2008. Elsevier Inc. Churchill Livingstone.
17. Leveno KJ, Bloom SL, Hauth JC, Rouse DJ, Spong CY. *Williams Obstetrics* (23rd edition). 2010. McWGraw-Hill Companies.
18. Pokorny SF. Configuration of the prepubertal hymen. *Am J Obstet Gynecol*. 1987;157:950-6.
19. Berenson AB. A longitudinal study of hymenal morphology in the first 3 years of life. *Pediatrics*. 1995;95:490-6.
20. Berenson AB. Normal anogenital anatomy. *Child Abuse Negl*. 1998;22:589-96.
21. Van Eyk N, Allen L, Giesbrecht E, Jamieson MA, Kives S, et al. Pediatric vulvovaginal disorders: a diagnostic approach and review of the literature. *J Obstet Gynaecol Can*. 2009;31:850-62.
22. Stukus KS, Zuckerbraun NS. Review of the prepubertal gynecologic examination: techniques and anatomic variation. *Clin Ped Emerg Med*. 2009;10:3-9.
23. Berenson A, Heger A, Andrews S. Appearance of the hymen in newborns. *Pediatrics*. 1991;87:458-65.
24. Al Herbish AS. The hymen morphology in normal newborn Saudi girls. *Ann Saudi Med*. 2001;21:188-9.
25. Berenson AB, Grady JJ. A longitudinal study of hymenal development from 3 to 9 years of age. *J Pediatr*. 2002;140:600-7.
26. Heger AH, Ticson L, Guerra L, Lister J, Zaragoza T, et al. Appearance of the genitalia in girls selected for nonabuse: review of hymenal morphology and nonspecific findings. *J Pediatr Adolesc Gynecol*. 2002;15:27-35.
27. Myhre AK, Berntzen K, Bratlid D. Genital anatomy in non-abused preschool girls. *Acta Paediatr*. 2003;92:1453-62.
28. Cantwell HB. Vaginal inspection as it relates to child sexual abuse in girls under thirteen. *Child Abuse Negl*. 1983;7:171-6.
29. Goff CW, Burke KR, Rickenback C, Buebendorf DP. Vaginal opening measurement in prepubertal girls. *Am J Dis Child*. 1989;143:1366-8.
30. Hobbs CJ, Wynne J. Child sexual abuse - an increasing rate of diagnosis. *Lancet*. 1987;330:837-41.
31. Emans SJ, Woods ER, Flagg NT, Freeman A. Genital findings in sexually abused, symptomatic and asymptomatic girls. *Pediatrics*. 1987;79:778-85.
32. Pillai M. Genital findings in prepubertal girls: what can be concluded from an examination? *J Pediatr Adolesc Gynecol*. 2008;21:177-85.
33. Gardner JJ. Descriptive study of genital variation in healthy, nonabused premenarchal girls. *J Pediatr*. 1992;120:251-7.
34. McCann J, Voris J, Simon M, Wells R. Comparison of genital examination techniques in prepubertal girls. *Pediatrics*. 1990;85:182-7.
35. Mahran M, Saleh AM. The microscopic anatomy of the hymen. *Anat Rec*. 1964;149:313-8.
36. Raveenthiran V. Surgery of the hymen: from myth to modernization. *Indian J Surg*. 2009;71:224-6.
37. Berenson AB, Heger AH, Hayes JM, Bailey RK, Emans SJ. Appearance of the hymen in prepubertal girls. *Pediatrics*. 1992;89:387-94.
38. Myhre AK, Myklestad K, Adams JA. Changes in genital anatomy and microbiology in girls between age 6 and age 12 years: a longitudinal study. *J Pediatr Adolesc Gynecol*. 2010;23:77-85.
39. Pokorny SF, Murphy JG, Preminger MK. Circumferential hymen elasticity. A marker of physiologic maturity. *J Reprod Med*. 1998;43:943-8.
40. Ryan KJ, Berkowitz RS, Barbieri RL, Dunaif A. *Kistner's Gynecology & Women's Health* (7th edition). 1999. Mosby, Inc.
41. Moore KL, Persaud TVN. *The Developing Human: Clinically Oriented Embryology* (8th edition). 2007. Philadelphia: Saunders.
42. Sadler TW. *Langman's Medical Embryology*, Ch. 15, Urogenital System (11th edition). 2010. Philadelphia: Lippincott Williams & Wilkins.

43. Creighton SM. Common congenital anomalies of the female genital tract. *Rev Gynecol Practice*. 2005;5:221-6.
44. McCann J, Wells R, Simon M, Voris J. Genital findings in prepubertal girls selected for non abuse: a descriptive study. *Pediatrics*. 1990; 86:428-39.
45. Berenson AB. Appearance of the hymen at birth and one year of age: a longitudinal study. *Pediatrics*. 1993;91:820-5.
46. Stelling JR, Gray MR, Davis AJ, Cowan JM, Reindollar RH. Dominant transmission of imperforate hymen. *Fertil Steril*. 2000;74:1241-4.
47. Sakalkale R, Samarakkody U. Familial occurrence of imperforate hymen. *J Pediatr Adolesc Gynecol*. 2005;427-9.
48. Garden AS, Bramwell R. Treatment of imperforate hymen by application of Foley catheter. *Eur J Obstet Gynecol Reprod Biol*. 2003;106:3-4.
49. Te Linde RW, Rock JA, Jones HW. *Te Linde's Operative Gynecology* (9th edition). 2003. Philadelphia, Lippincott Williams & Wilkins.
50. Acar A, Balci O, Karatayli R, Capar M, Colakoglu MC. The treatment of 65 women with imperforate hymen by a central incision and application of Foley catheter. *BJOG*. 2007;114:1376-9.
51. Chelli D, Kehila M, Sfar E, Zouaoui B, Chelli H, et al. Imperforate hymen: Can it be treated without damaging the hymenal structure?. *San-te*. 2008;18:83-7.
52. Basaran M, Usal D, Aydemir C. Hymen sparing surgery for imperforate hymen: case reports and review of literature. *J Pediatr Adolesc Gynecol*. 2009;22:e61-4.
53. Abu-Ghanem S, Novoa R, Kaneti J, Rosenberg E. Recurrent urinary retention due to imperforate hymen after hymenotomy failure: a rare case report and review of the literature. *Urology*. 2011;78:180-2.
54. Goto K, Yoshinari H, Tajima K, Kotsuji F. Microperforate hymen in a primigravida in active labor: a case report. *J Reprod Med*. 2006;51:584-6.
55. Di Donato V, Mancini N, Palaia I, Bellati F, Perniola G, et al. Urethral coitus in a patient with a microperforate hymen. *J Minim Invasive Gynecol*. 2008;15:642-3.
56. McCann J, Voris J, Simon M. Genital injuries resulting from sexual abuse: a longitudinal study. *Pediatrics*. 1992;89:307-17.
57. Kellogg ND, Menard SW, Santos A. Genital anatomy in pregnant adolescents: "normal" does not mean "nothing happened". *Pediatrics*. 2004;113:67-9.
58. Finkel MA. Anogenital trauma in sexually abused children. *Pediatrics*. 1989;84:317-22.
59. Onan MA, Turp AB, Taskiran C, Ozogul C, Himmetoglu O. Spontaneous closure of the hymen during pregnancy. *Am J Obstet Gynecol*. 2005;193:889-91.
60. Curtis E, Lazaro CS. Appearance of the hymen in adolescents is not well documented. *BMJ*. 1999; 318:605.
61. Adams JA, Botash AS, Kellogg N. Differences in hymenal morphology between adolescent girls with and without a history of consensual sexual intercourse. *Arch Pediatr Adolesc Med*. 2004;158:280-5.
62. Eman SJ, Woods ER, Allred EN, Grace E. Hymenal findings in adolescent women, impact of tampon use and consensual sexual activity. *J Pediatr*. 1994;125:153-60.
63. Bekker MHJ, Rademakers J, Mouthaan I, de Neef M, Huisman WM, et al. Reconstructing hymens or constructing sexual inequality? Service provision to Islamic young women coping with the demand to be a virgin. *J Community Applied Social Psychology*. 1996;6:329-34
64. Rogers DJ, Stark M. The hymen is not necessarily torn after sexual intercourse. *BMJ*. 1998; 317:414.
65. Goodyear-Smith FA, Laidlaw TM. Can tampon use cause hymen changes in girls who have not had sexual intercourse? A review of the literature. *Forensic Sci Int*. 1998;94:147-53.
66. Usta I. Hymenorrhaphy: what happens behind the gynecologist's closed door?. *J Med Ethics*. 2000;26:217-18.
67. Mernissi F. Virginity and patriarchy. *Women's Studies International Forum*. 1982;5:183-91.
68. Renganathan A, Cartwright R, Cardozo L. Gynecol cosmetic surgery. *Exp Rev Obstet Gynecol*. 2009;4:101-4.
69. O'Connor M. Reconstructing the hymen: mutilation or restoration? *J Law Med*. 2008;16:161-75.
70. Amy J. Certificates of virginity and reconstructions of the hymen. *Eur J Contracept Reprod Health Care*. 2008;13:111-3.
71. Dhall A. Adolescence: myths and misconceptions. *Health Millions*. 1995;21:35-8.
72. Molla M, Berhane Y, Lindtjorn B. Traditional values of virginity and sexual behaviour in rural Ethiopian youth: results from a cross-sectional study. *BMC Public Health*. 2008;8:9.
73. Wells DL. Sexual assault practice: Myths and mistakes. *J Clin Forensic Med*. 2006;13:189-93.
74. Gürsoy E, Vural G. Nurses' and midwives' views on approaches to hymen examination. *Nurs Ethics*. 2003;10:485-96.
75. Ndlovu C. Virginity testing raises many questions. *Network*. 2005;23:14.
76. Essén B, Blomkvist A, Helström L, Johnsdotter S. The experience and responses of Swedish health professionals to patients requesting virginity restoration (hymen repair). *Reprod Health Matters*. 2010;18:38-46.
77. Dane C, Dane B, Erginbas M, Cetin A. Imperforate hymen - a rare cause of abdominal pain: Two cases and review of the literature. *J Pediatr Adolesc Gynecol*. 2007;20:245-7.