

Effect of curcumin on chromium-induced oxidative damage in male reproductive system

Amar K. Chandra^{a,*}, Aparajita Chatterjee^a, Rituparna Ghosh^a, Mahitosh Sarkar^b

^a Endocrinology and Reproductive Physiology Laboratory, Department of Physiology, University of Calcutta, University College of Science & Technology, 92 Acharya Prafulla Chandra Road, Kolkata 700009, West Bengal, India

^b Department of Physiology, Gurunanak Institute of Dental Science & Research, Kolkata, India

Received 13 October 2006; received in revised form 8 April 2007; accepted 25 April 2007

Available online 13 May 2007

Abstract

Hexavalent chromium, an environmental contaminant, undergoes redox cycling with generation of free radicals inside the biological system. Curcumin, the yellow bioactive component of turmeric has established its antioxidant activities. The present study evaluates possible ameliorating effects of curcumin on potassium dichromate ($K_2Cr_2O_7$) (hexavalent chromium) induced reproductive toxicity in adult male Sprague–Dawley rats. Three experimental groups, each consisting of eight rats, were treated with 0.4 mg $K_2Cr_2O_7$ /kg bw/day, 0.4 mg $K_2Cr_2O_7$ /kg bw/day + 20 mg curcumin/kg bw on every alternate day and 20 mg curcumin/kg bw on every alternate day, respectively, for 26 days. Altered testicular histology, reduced sperm count, low testosterone level, decreased accessory sex organs weight, enhanced lipid peroxidation along with reduced SOD and catalase activities were observed following $K_2Cr_2O_7$ exposure while curcumin supplementation along with $K_2Cr_2O_7$ exposure had shown to prevent the altered parameters. The results thus suggest that curcumin may have a protective role against chromium(VI) induced oxidative damage in male reproductive system. © 2007 Elsevier B.V. All rights reserved.

Keywords: Chromium; Catalase; Curcumin; SOD; Lipid peroxidation; Testis

1. Introduction

Chromium is a metallic element that exists in a variety of oxidative states. Biologically, trivalent (+3) [Cr(III)] and hexavalent (+6) chromium [Cr(VI)] are most important. Hexavalent chromium compounds are generally man-made and considered as more toxic than trivalent chromium (Sugiyama, 1992). It is widely used in refractory, pigment, stainless steel factory, leather tannery, wood processing, welding, cement manufacturing factory, catalytic converter for automobile and cooling plant, etc. (Stohs et al., 2001). Disposal of industrial wastes leads to severe environmental pollution. Cr(VI) from fossil fuel combustion and steel production plant comprises two-thirds of the chromium in the air in urban areas (Stohs et al., 2001).

Hexavalent chromium has been reported to produce carcinogenic, genotoxic and cytotoxic effects both in human and laboratory animals (Stohs et al., 2001). Elevated levels of

chromium in blood, urine and some body tissues are found in workers occupationally exposed to chromium (Kumar et al., 2005). Presence of chromium is well documented in foetuses and infants of women working or living near dichromate industries (Shmitova, 1990). Workers exposed to chromium in welding industry suffered from increased risk of reduced semen quality, sperm abnormalities leading to infertility (Bonde, 1993). Chromate has been shown to concentrate in the testis after intraperitoneal injection led to injuries in seminiferous epithelium in mice (Saxena et al., 1990).

Various studies demonstrated that hexavalent chromium is a major risk factor to growing testis (Saxena et al., 1990) and it also causes testicular atrophy, reduced sperm count and motility in adult rats (Ernst, 1990; Ernst and Bonde, 1992). Chromium compounds induce oxidative stress leading to tissue damage (Stohs et al., 2001). Testicular tissue is a major target for metal-induced oxidative damage because of its high content of polyunsaturated membrane lipids (Acharya et al., 2004). Kawanishi et al. (1986) demonstrated that ROS including superoxide anion, singlet oxygen and hydroxyl radicals are produced by chromium(VI) during the formation of chromium(V) intermediates. Further studies

* Corresponding author. Tel.: +91 33 2350 8386; fax: +91 33 2351 9755.
E-mail address: amark.chandra@yahoo.co.in (A.K. Chandra).

also indicate hexavalent chromium-induced dysfunction in male reproductive system (Aruldas et al., 2004, 2005). However, no substantial information is available on the amelioration of male reproductive system against Cr(VI)-induced toxicity.

Trends on applying nutritional antioxidants in diseases related to oxidative stress have gained immense interest in recent years. Plant products are known to exert their protective effects by scavenging free radicals and modulating antioxidant defence system. Curcumin, an active component of turmeric (*Curcuma longa* Linn) exhibits antioxidant property. It is a yellow coloured phenolic pigment yield from the rhizome of turmeric (family *Zingiberaceae*). The most important feature of curcumin is that it has no side effects despite being a therapeutic agent with multiple beneficial functions (Khanna, 1999). It acts as a scavenger of free radicals (Khanna, 1999). Curcumin is considered to be an effective antioxidant against oxidative tissue damage. It can significantly inhibit the generation of reactive oxygen species (ROS) both *in vitro* and *in vivo* (Joe and Lokesh, 1994). Therefore, the present study has been undertaken to evaluate the ameliorating effect of curcumin on Cr(VI)-induced oxidative damage in testis of adult Sprague–Dawley rats.

2. Materials and methods

2.1. Animals

Three-month-old male albino rats of Sprague–Dawley strain *Rattus norvegicus* weighing 200 ± 10 g were used in the present study. The animals were maintained as per national guidelines and protocols, approved by the Institutional Animal Ethics Committee. The animals were purchased from Indian Institute of Chemical Biology, Kolkata, and housed in clean polypropylene cages and maintained in an air-conditioned animal house with constant 12 h light and 12 h dark schedule. Animals were fed on standardized diet for rodents and water *ad libitum* (Mukhopadhyay et al., 2004).

2.2. Reagents

Thiobarbituric acid (TBA), NAD, NADPH, β -estradiol (98%) and curcumin were purchased from Sigma Chemical Company, St. Louis, MO, USA. Potassium dichromate ($K_2Cr_2O_7$), Triton X, triethanol amine, diethanolamine, EDTA, $MnCl_2$ and dimethyl sulfoxide (DMSO) was purchased from E-Merck, Mumbai, India. All other reagents were purchased from Sisco Research Laboratories (SRL), Mumbai, India, and all the reagents were of analytical grade.

2.3. Animal treatment

The rats were divided into four groups. Each group consists of eight animals. Group I: control rats were injected with 0.1 ml sterile distilled water intraperitoneally (i.p.) daily for 26 days as vehicle. Group II: rats received i.p. injection of potassium dichromate ($K_2Cr_2O_7$) (hexavalent chromium salt) dissolved in sterile distilled water at a dose of 0.4 mg/kg bw daily for 26 days. The doses used in this study were selected based on preliminary experiments in our laboratory using sub-chronic treatment with $K_2Cr_2O_7$. Group III: rats were administered with i.p. injection of 0.4 mg $K_2Cr_2O_7$ /kg bw daily and simultaneously i.p. injection with curcumin at a dose of 20 mg/kg bw on every alternate day (Dasgupta et al., 1969; Sinha et al., 1974) in 5% DMSO solution (Kalpana and Menon, 2004) for 26 days. Group IV: rats received i.p. injection of curcumin at a dose of 20 mg/kg bw on every alternate day in 5% DMSO solution for 26 days. Treatment for 26 days was selected, as the duration of one seminiferous cycle is 13.2 days in albino rats (Sarkar et al., 2003). All the animals were sacrificed 24 h after the last treatment following protocols and ethical procedures. Blood sam-

ples for hormone assay were collected from the hepatic portal vein under light ether anaesthesia. Plasma samples were separated by centrifugation, frozen and stored at $-20^\circ C$ until assayed.

2.4. Body and organ weights

The body weights were recorded on the day of sacrifice. The testicles and accessory sex organs, viz. seminal vesicles, ventral prostate, cauda epididymis, coagulating glands were dissected out, trimmed off the attached tissues and weighed. The relative weight of organs was expressed per as mg/100 g of body weight. The left testis of each rat was used for histological study and the right for other biochemical estimations.

2.5. Histopathological study

Immediately after removal, the testis was fixed in Bouin's fluid and embedded in paraffin. Sections of 5 μm thickness were taken from the mid portion of each testis and stained with haematoxylin-eosin and examined under a light microscope. Quantitative analysis of spermatogenesis was carried out by counting the relative number of each variety of germ cells at stage VII of the seminiferous cycle, i.e. type-A spermatogonia (ASg), preleptotene spermatocytes (pLSc), mid pachytene spermatocytes (mPSc) and step 7 spermatids (7Sd), according to the method of Leblond and Clermont (1952). The nuclei of different germ cells were counted in 20 round tubules of each rat. All the counts (crude counts) of the germ cells were corrected for differences in the nuclear diameter by the formula of Abercrombie (1946): true count = (crude count \times section thickness)/(section thickness – nuclear diameter of germ cell). The nuclear diameter of each variety of germ cell was measured with a Leitz micrometer. The possibility of variable tubular shrinkage in the sections of $K_2Cr_2O_7$ treated, curcumin-supplemented $K_2Cr_2O_7$ -treated and curcumin-supplemented groups were eliminated by the index of tubular shrinkage which was obtained from the average number of Sertoli cell nuclei containing prominent nucleoli in the sections of the treated rats divided by that of the controls (Clermont and Morgentaler, 1955). Stage VII spermatogenesis was analyzed because this stage is highly susceptible to testosterone deficiency (Russell et al., 1987) and also reflects the final stages of spermatid maturation and thus provides evidence of spermatogenesis as a whole (Clermont and Harvey, 1967).

Theoretically, each primary spermatocytes, after two successive reduction divisions, forms four spermatids. Therefore, the mPSc-to-7Sd ratio should be 1:4 (Clermont and Morgentaler, 1955). The percentage of 7Sd degeneration was calculated from this ratio. Subtraction of the percentage of 7Sd degeneration in vehicle-treated rats showed the effective percentage of spermatids degeneration.

2.6. Epididymal sperm number

Sperm samples were collected from the cauda epididymis. The epididymal sperm number was determined by haemocytometer following the method of Majumder and Biswas (1979). The count was repeated for five times for each sample to minimize the error.

2.7. ELISA of serum testosterone

Serum testosterone was assayed using ELISA kit obtained from Equipar Diagnostici, SRL, Italy (code no. 74010) following the manufacturer procedure. The absorbance was read against blank well at 450 nm within 30 min in ELISA Reader (Merck). The sensitivity of the testosterone assay was 5 pg/ml and inter-run and intra-run precisions had a coefficient of variation of 3.9 and 6.2% respectively.

2.8. Determination of lipid peroxidation

Lipid peroxidation (LPO) was measured by the method of Buege and Aust (1978). The level of LPO in the testicular homogenate was measured based on the formation of thiobarbituric acid-reactive substances (TBARS). Malondialdehyde (MDA) forms adducts with thiobarbituric acid, which is measured spectrophotometrically (UV-1240 Shimadzu, Japan) at 532 nm. MDA, a product

of LPO, was used as a standard. An extinction coefficient of $156,000 \text{ M}^{-1} \text{ cm}^{-1}$ was applied for calculation.

2.9. Antioxidant enzyme assay

2.9.1. Determination of superoxide dismutase (SOD) activity

The method described by Paoletti and Mocali (1990) was used for the assay of SOD activity. This method consists of purely chemical reaction sequence, which generates superoxide from molecular oxygen in the presence of EDTA, manganese(II) chloride and mercaptoethanol. NAD(P)H oxidation is linked to the availability of superoxide anions in the medium. The decrease in absorbance at 340 nm was monitored for 20 min at 5 min interval in a spectrophotometer (UV-1240 Shimadzu, Japan). In this assay system, 1 unit of SOD activity is defined as the amount of enzyme required to inhibit the rate of NADPH oxidation of the control by 50%.

2.9.2. Determination of catalase (CAT) activity

The activity of catalase was assayed by the method of Aebi (1974). In the ultraviolet range, H_2O_2 shows a continual increase in absorption with decreasing wavelength. The decomposition of H_2O_2 can be correctly followed by monitoring the decrease in absorbance at 240 nm for 60 s in spectrophotometer (UV-1240 Shimadzu, Japan). The change in absorbance is the measure of the catalase activity and is expressed as nmoles/mg protein/s. The extinction coefficient of H_2O_2 at 240 nm is $40 \text{ M}^{-1} \text{ cm}^{-1}$.

2.10. Protein estimation

Proteins were estimated by the method of Lowry et al. (1951) using bovine serum albumin (BSA) as the standard protein.

2.11. Statistical analysis

Results were expressed as mean \pm standard deviation (S.D.). One-way analysis of variance (ANOVA) test was first carried out to test for any differences between the mean values of all groups. If differences between groups were established, the values of the treated groups were compared with those of the control group by a multiple comparison *t*-test. A value of $p < 0.05$ was interpreted as statistically significant (Fisher and Yates, 1974).

3. Results

3.1. Body and organ weight

Food and water intake in experimental group of rats remained unaltered in comparison to the control group but the gain in body weight was less in chromium-treated group. All the animals were in docile condition and no mortality was observed. Relative weight of testis was unaltered in

Table 1
Effect of chromium (Cr), curcumin and their combination on the overall means (\pm S.D.) of body weight, relative weight of testis (g/100 g bw) and accessory sex organs (mg/100 g bw) weight in rats

Parameter	Group			
	Control	Cr	Curcumin	Cr + curcumin
Body weight	260.54 \pm 10.25	246.78 \pm 7.34	258.91 \pm 9.67	255.62 \pm 11.41
Testis (pair) weight	1.20 \pm 0.04	1.19 \pm 0.02	1.19 \pm 0.03	1.21 \pm 0.02
Epididymis weight	172.08 \pm 7.58	120.27 \pm 6.64 ^a	170.07 \pm 8.87	166.55 \pm 8.06 ^b
Seminal vesicle weight (without fluid)	157.41 \pm 6.02	113.59 \pm 8.65 ^a	155.17 \pm 6.65	148.85 \pm 6.24 ^b
Coagulating gland weight	49.16 \pm 5.16	33.86 \pm 3.82 ^a	50.76 \pm 3.65	47.50 \pm 4.58 ^b
Ventral prostate weight	216.12 \pm 14.49	97.94 \pm 8.43 ^a	209.89 \pm 12.77	176.43 \pm 10.01 ^{a,b}

Values are mean \pm standard deviation of eight observations. Values bearing superscript are significantly different by ANOVA at $p < 0.05$.

^a When compared with control.

^b When compared with Cr.

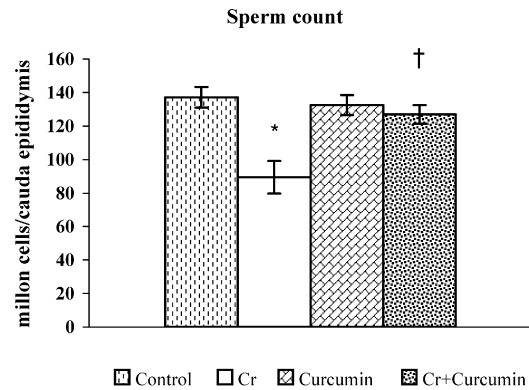


Fig. 1. Comparison in sperm count in control, Cr(VI)-treated, curcumin-supplemented Cr(VI)-treated and curcumin-treated group. Values are mean \pm standard deviation of eight observations. Values bearing superscript are significantly different by ANOVA at $p < 0.05$: *when compared with control; †when compared with Cr.

all the experimental animals; however, relative weight of prostate, epididymis, seminal vesicle and coagulating gland decreased significantly in Cr(VI)-exposed rats (Table 1). Curcumin supplementation in Cr(VI)-exposed group caused significant increase ($p < 0.05$) in accessory sex organs weight in comparison to the Cr(VI)-exposed group and controls.

3.2. Epididymal sperm count

Potassium dichromate treatment significantly decreased epididymal sperm number than control and curcumin-supplemented chromium-treated group (Fig. 1). Live dead staining shows that the number of dead sperm is higher in Cr(VI)-treated group in comparison to the control animals. In contrast, most of the sperm remain alive in curcumin-supplemented Cr(VI)-treated group.

3.3. Serum testosterone level

Serum testosterone level decreased significantly in chromium-administered animals than in control group of animals. No such change was observed in serum testosterone level of curcumin-supplemented chromium-treated and curcumin-treated groups, respectively (Fig. 2).

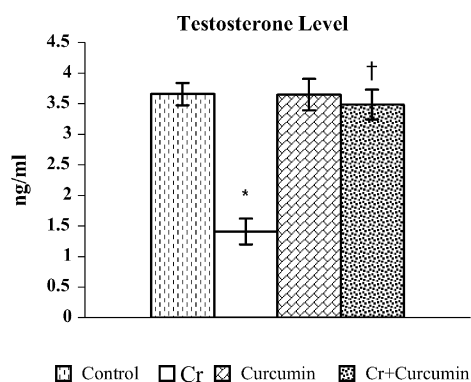


Fig. 2. Comparison in testosterone level in control, Cr(VI)-treated, curcumin-supplemented Cr(VI)-treated and curcumin-treated group. Values are mean \pm standard deviation of eight observations. Values bearing superscript are significantly different by ANOVA at $p < 0.05$: *when compared with control; †when compared with Cr.

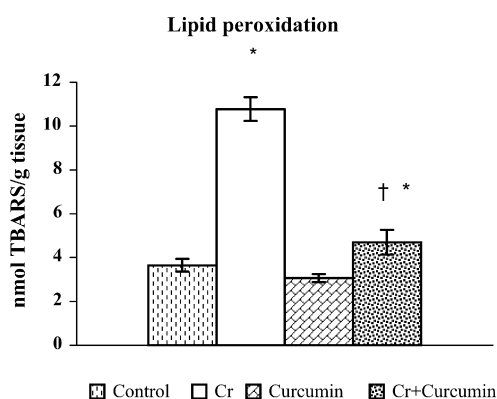


Fig. 3. Comparison in lipid peroxidation in control, Cr(VI)-treated, curcumin-supplemented Cr(VI)-treated and curcumin-treated group. Values are mean \pm standard deviation of eight observations. Values bearing superscript are significantly different by ANOVA at $p < 0.05$: *when compared with control; †when compared with Cr.

3.4. Testicular antioxidant enzyme activity and lipid peroxidation

Chromium treatment significantly increased the lipid peroxidation in testis (Fig. 3) and decreased the activities of testicular SOD and catalase (Figs. 4 and 5). Concomitant curcumin supplementation normalizes testicular lipid peroxidation as well as the activities of SOD and catalase. However, no changes were observed in the above-mentioned parameters in animals treated with curcumin alone.

3.5. Histopathological study of testis

Histological study (Plate 1) demonstrates normal testicular structure in control and curcumin-treated animals. On the other hand, degenerative changes in the testis with severe disintegration of spermatocytes, resulting in spermatogenic arrest with moderate tubular necrosis and Leydig cell degeneration, were observed in chromium-treated testis. Testicular histoarchitecture of curcumin-supplemented Cr-treated group shows moderate disintegration and Leydig cell hyperplasia with mild spermatogenic

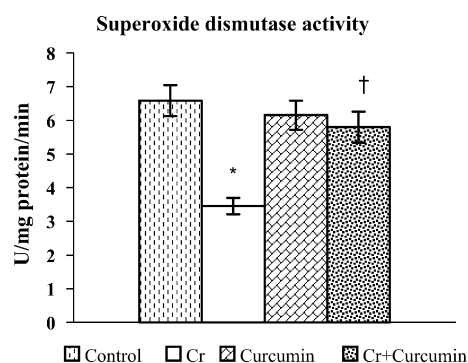


Fig. 4. Comparison in SOD activity in control, Cr(VI)-treated, curcumin-supplemented Cr(VI)-treated and curcumin-treated group. Values are mean \pm standard deviation of eight observations. Values bearing superscript are significantly different by ANOVA at $p < 0.05$: *when compared with control; †when compared with Cr.

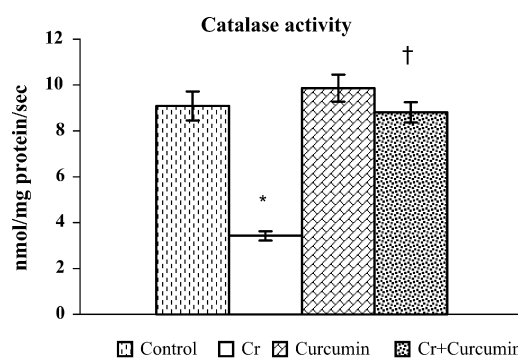


Fig. 5. Comparison in catalase activity in control, Cr(VI)-treated, curcumin-supplemented Cr(VI)-treated and curcumin-treated group. Values are mean \pm standard deviation of eight observations. Values bearing superscript are significantly different by ANOVA at $p < 0.05$: *when compared with control; †when compared with Cr.

genic arrest. Most of the animals in curcumin-supplemented Cr(VI)-treated group showed normal histological structure as compared to the control.

The quantitative study of germ cells at stage VII (Table 2) revealed that curcumin supplementation increased the number of stage VII spermatids (7Sd) significantly in comparison to chromium-treated group. Chromium treatment significantly reduced the number of ASg, pLSc, mPSc and 7Sd when compared with control. The ratio of mPSc and 7Sd was 1:3.35 in control and 1:2.80 in chromium-treated group. The percentage of spermatid degeneration (30.00%) as calculated from the above ratio was significantly high after chromium treatment but reduced markedly after simultaneous curcumin supplementation (22.75%).

4. Discussion

The purpose of the present study is to find out the ameliorating effect of curcumin on chromium-induced oxidative damage in spermatogenesis of adult male albino rats. The net body weight gain reduced in Cr(VI)-treated rats as compared to the control animals. The results are similar with the earlier observations where decrease in body weight due to gain in lean body mass and

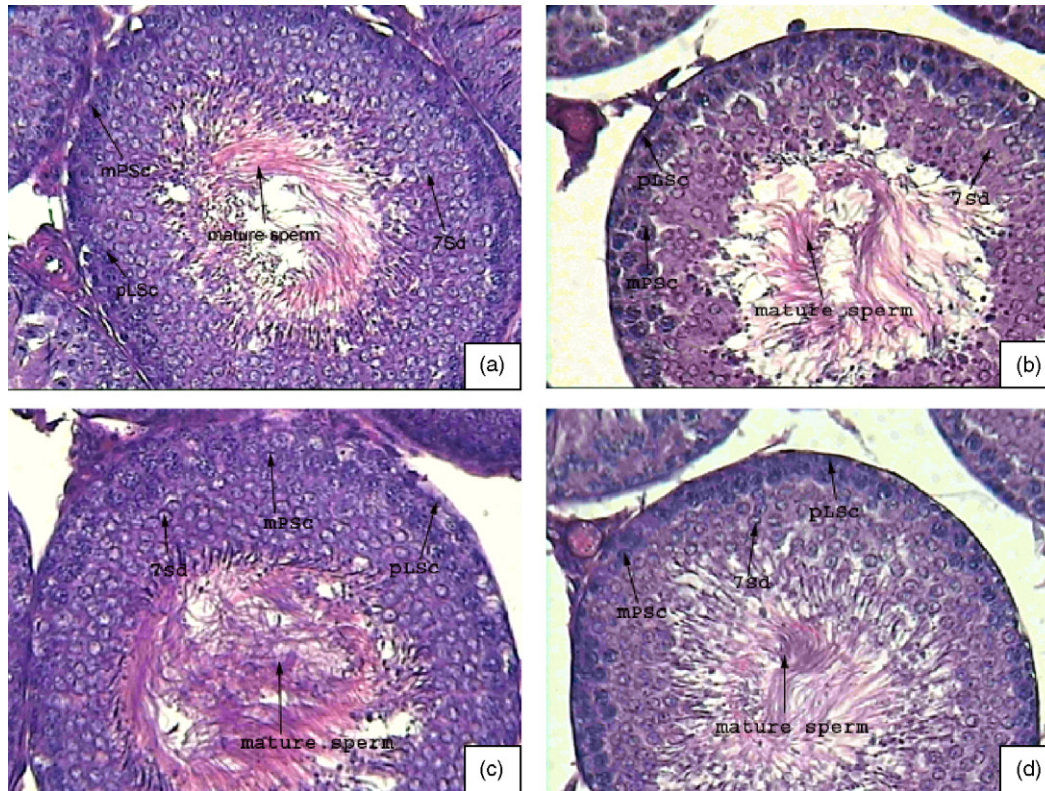


Plate 1. Photomicrographs of HE-stained rat seminiferous tubules at stage VII of spermatogenesis. ASg = spermatogonia A; pLSc = preleptotene spermatocytes; mPSc = mid pachytene spermatocytes; 7Sd = step 7 spermatid. (a) Seminiferous tubule (400 \times) from control animals, showing normal cellular morphology and association with numerous mature spermatozoa in the lumen. (b) Seminiferous tubule (400 \times) from Cr-treated animals (0.4 mg/kg, i.p. for 26 days), showing disruption of cellular association with decreased number of germ cells and mature spermatozoa. (c) Seminiferous tubule (400 \times) from curcumin-treated animals (20 mg/kg, i.p. on every alternate day for 26 days), showing normal cellular association like that of control. (d) Seminiferous tubule (400 \times) from Cr-treated and curcumin-supplemented animals (Cr 0.4 mg/kg/day i.p. + curcumin 20 mg/kg on every alternate day i.p. for 26 days), showing increased number of ASg, pLSc, mPSc, 7Sd and plenty of mature spermatozoa in the tubular lumen.

decrease in body fat was noted in human exposed to chromium picolinate (Gilbert et al., 1998, 1996). Occupational exposure to Cr(VI) led to reduction in sperm counts, sperm motility and shows substantial abnormalities in the histology of testis (Li et al., 2001a). Present study demonstrated that chronic Cr(VI) administration at sub-lethal dose reduces accessory sex organs weight and epididymal sperm number, which indicates an interference with spermatogenesis.

The pachytene spermatocyte:spermatid ratio is 1:3.35 in our control rats instead of the theoretical value of 1:4 (Clermont and Morgentaler, 1955). This result indicates 16.25% spermatid

degeneration in control group. In chromium-treated animals, this ratio is 1:2.80, indicating that during the process of spermatocyte to spermatid conversion, 30.00% of the cells are degenerated, which is significantly less (22.75%) in curcumin-supplemented Cr(VI)-treated group.

In addition, Cr(VI) also affects the histoarchitecture of testis. There was visible disruption in the germ cell population in the seminiferous tubule with degenerative changes observed in Leydig cell. Testosterone, secreted from the Leydig cells of testis, is responsible for the activation and maintenance of spermatogenesis (Singh et al., 1995). Testosterone helps in the maturation

Table 2
Effect of chromium (Cr), curcumin and their combination on spermatogenesis at stage VII of seminiferous cycle in rats

Group	Spermatogenesis pattern at stage VII				mPSc:7Sd	7Sd degeneration (%)	Effective 7Sd degeneration
	ASg	pLSc	mPSc	7Sd			
Control	0.69 \pm 0.05	19.28 \pm 1.03	19.03 \pm 1.66	63.82 \pm 1.89	1:3.35	16.25	–
Cr	0.51 \pm 0.60 ^a	15.82 \pm 1.81 ^a	14.39 \pm 1.53 ^a	40.39 \pm 1.93 ^a	1:2.80	30.00	+13.75 ^a
Curcumin	0.64 \pm 0.05	18.72 \pm 1.66	18.98 \pm 1.63	61.38 \pm 1.88	1:3.23	19.25	+3.00
Cr + curcumin	0.61 \pm 0.05 ^b	17.89 \pm 1.24 ^b	17.09 \pm 1.28 ^b	52.89 \pm 2.13 ^a	1:3.09	22.75	+6.50 ^b

ASg = spermatogonia A; pLSc = preleptotene spermatocytes; mPSc = mid pachytene spermatocytes; 7Sd = step 7 spermatid. Values are mean \pm standard deviation of eight observations. Values bearing superscript are significantly different by ANOVA at $p < 0.05$.

^a When compared with control.

^b When compared with Cr.

of round elongated spermatids by promoting the conversion of round spermatid between stages VII and VIII of the spermatogenic cycle (O'Donnell et al., 1994). Sun et al. (1990) found that the conversion of round to elongated spermatid was suppressed when testosterone in the interstitial fluid was 5% of control. The importance of testosterone on spermatogoneal and spermatocyte number has been investigated by numerous workers (Steinberger and Steinberger, 1975; Sun et al., 1989). Low level of serum testosterone in Cr(VI)-treated rats may be the possible cause behind the spermatogenic impairment and depleted epididymal sperm number. Decreased serum testosterone level in Cr(VI)-treated rats is also responsible for the reduction in weight of accessory sex organs. It is well documented that testosterone is responsible for the growth of accessory sex organs (Li et al., 2001b; Steinberger and Steinberger, 1975). Curcumin supplementation had prevented Cr(VI)-induced decrease in weight of accessory sex organs due to normal serum testosterone level and had restored epididymal sperm number and normal sperm production in the seminiferous tubule. Curcumin suppressed the adverse effects of Cr(VI) possibly due to its antioxidant activity (Sharma, 1976).

Hexavalent chromium has shown to be involved in Fenton-like oxidative cycling, generating reactive oxygen species (ROS). Once Cr(VI) is taken inside the cell, it undergoes a reduction division by the cellular reductants to generate different reactive chromium intermediates, such as Cr(V) and Cr(IV). During Cr(VI) reduction process, molecular oxygen is reduced to superoxide radical (O_2^-), which subsequently forms H_2O_2 . Both Cr(V) and Cr(IV) are able to react with H_2O_2 to generate hydroxyl radical (OH^-). Superoxide radical (O_2^-), H_2O_2 and OH^- collectively form ROS (Shi et al., 1999a,b). Increased ROS production due to Cr(VI) exposure may lead to generation of oxidative stress, which is responsible for many deleterious effects in the cell including DNA damage, lipid peroxidation and protein modification (Stohs et al., 2001). Oxidative stress is an established major factor responsible for male infertility. High levels of ROS are detected in the semen samples of infertile males (Sikka, 1996). Elevated ROS level in chromium-treated mice induces impaired Leydig cell function, changes several biochemical indices of cells including lipid peroxidation (Acharya et al., 2004). Adult male monkeys exposed to Cr(VI) at doses 100, 200 and 400 mg/l for 6 months showed significant decrease in seminiferous tubular diameter along with abnormalities in germ cell population while concentration of reduced glutathione, H_2O_2 and OH^- increased significantly in the testis of Cr(VI)-exposed animals (Aruldas et al., 2005). Over production of ROS is evidenced in the present study from significant increase in testicular lipid peroxidation of Cr(VI)-treated rats. Activities of testicular anti-oxidative enzymes, viz. SOD and catalase decrease significantly in Cr(VI)-treated rats, indicating that testicular defence mechanism fails to protect the over production of ROS. Oxidative stress is also responsible for the deterioration of accessory sex organs (Ochsendorf, 1999). In the present study, Cr-induced decrease in accessory sex organs weight and sperm count correlates with the observation of Subramanian et al. (2006).

Cellular damage caused by Cr(VI) exposure can be prevented by free radical scavengers or antioxidants, which further strengthens the hypothesis that free radicals play a key role in chromium toxicity (Ueno et al., 1995; Tsou and Yang, 1996). Antioxidants are the frontline of defence against free radicals (Osawa and Kato, 2005). The antioxidant mechanism of curcumin is due to its specific conjugated structure of two methoxylated phenols and an enol form of β -diketone. This structure is responsible for free radical trapping ability as a chain breaking antioxidant (Masuda et al., 2001). Curcumin prevents free radical generation by competing with peroxidant metals for cell binding sites, which decrease the possibility of free radical formation or by maintaining the activities of antioxidant enzymes like SOD and catalase (Pulla Reddy and Lokesh, 1992). It also protects free radical induced damage by defending sulfhydryl groups against oxidation (Khanna, 1999). SOD and catalase are primary defenders against oxidative damage. SOD can eliminate destructive superoxide molecules produced in the body. It can also block the oxidation of harmful LDL cholesterol (Khanna, 1999). Curcumin is reported to protect nicotine-induced oxidative damage (Kalpana and Menon, 2004) and indomethacin-induced gastric lesion (Chattapadhyay et al., 2004).

SOD and catalase levels in the testis of curcumin-supplemented Cr(VI)-treated group were shown to increase significantly than in Cr(VI)-exposed group, indicating that curcumin may have protective action against the ROS-mediated Cr(VI) toxicity. Curcumin is responsible for the inhibition of peroxidation of membrane lipids by scavenging or neutralising free radicals and by chelating metal ions. Inhibition of lipid peroxidation maintains cell membrane integrity and their function (Pulla Reddy and Lokesh, 1994). Curcumin supplementation has normalized the raised level of lipid peroxidation when compared with that of chromium-treated group, showing that curcumin prevents the ROS generation in the Cr(VI)-induced testis.

Therefore, simultaneous administration of curcumin to Cr(VI)-treated rats prevents the Cr(VI)-induced spermatogenic damage, decreased sperm count, reduced testosterone level and generation of free radicals by inducing antioxidant defence mechanism. The present study thus indicates that curcumin may have protective action against Cr(VI)-induced testicular damage.

References

- Abercrombie, M., 1946. Estimation of nuclear population from microtome sections. *Anat. Rec.* 94, 239–247.
- Acharya, U.R., Mishra, M., Mishra, I., Tripathy, R.R., 2004. Potential role of vitamins in chromium induced spermatogenesis in Swiss mice. *Environ. Toxicol. Pharmacol.* 15, 53–59.
- Aebi, H., 1974. Catalase. In: Bergmeyer, H.U. (Ed.), *Methods of Enzymatic Analysis*, vol. 2. Academic Press, New York, pp. 673–678.
- Aruldas, M.M., Subramanian, S., Sekar, P., Chandrasaran, G., Govindarajulu, P., Akbarsha, M.A., 2004. Microcanalization in the epididymis to overcome ductal obstruction caused by chronic exposure to chromium—a study in the mature bonnet monkey (*Macaca radiata* Geoffroy). *Reproduction* 128, 127–137.
- Aruldas, M.M., Subramanian, S., Sekar, P., Vengatesh, G., Chandrasaran, G., Govindarajulu, P., Akbarsha, M.A., 2005. Chronic chromium exposure-induced changes in testicular histoarchitecture are associated with oxidative

- stress: study in a non-human primate (*Macaca radiata* Geoffroy). Hum. Reprod. 20 (10), 2801–2813.
- Bonde, J.P., 1993. The risk of male subfecundity attributable to welding of metals: studies of semen quality, infertility, adverse pregnancy outcome and childhood malignancy. Int. J. Androl. 16 (Suppl. 1), 1–29.
- Buege, J.A., Aust, S.D., 1978. Microsomal lipid peroxidation. Methods Enzymol. 52, 302–310.
- Chattopadhyay, I., Biswas, K., Bandyopadhyay, U., Banerjee, R.K., 2004. Turmeric and curcumin: biological actions and medicinal applications. Curr. Sci. 87 (1), 44–53.
- Clermont, Y., Harvey, S.C., 1967. Effect of hormones on spermatogenesis in the rat. Ciba Found. Coll. Endocrinol. 16, 173–196.
- Clermont, Y., Morgentaler, H., 1955. Quantitative study of spermatogenesis in hypophysectomized rats. Endocrinology 57, 369–382.
- Dasgupta, S.R., Sinha, M., Sinha, C.C., Mukherjee, B.P., 1969. A study of the effect of an extract of *Curcuma longa* Linn on experimental gastric ulcers in animals. Indian J. Pharmacol. 1, 49–54.
- Ernst, E., 1990. Testicular toxicity following short term exposure to tri and hexavalent chromium: an experimental study in rat. Toxicol. Lett. 51, 269–275.
- Ernst, E., Bonde, J.P., 1992. Sex hormones and epididymal sperm parameters in rats following subchronic treatment with hexavalent chromium. Hum. Exp. Toxicol. 11, 255–258.
- Fisher, R.A., Yates, R., 1974. Statistical Tables for Biological, Agricultural and Medical Research. Longman Group, London.
- Gilbert, R.K., Kenneth, B., Jeffrey, A.F., Jack, A.A., 1996. Effects of chromium picolinate supplementation on body composition: a randomized, double-masked, placebo-controlled study. Curr. Ther. Res. 57 (10), 747–756.
- Gilbert, R.K., Kenneth, B., Dennis, P., Samuel, C.K., Robert, W., 1998. A randomized, double-masked, placebo-controlled study of the effects of chromium picolinate supplementation on body composition: a replication and extension of a previous study. Curr. Ther. Res. 59 (6), 379–388.
- Joe, B., Lokesh, B.R., 1994. Role of capsaicin, curcumin and dietary n-3 fatty acids in lowering the generation of reactive oxygen species in rat peritoneal macrophages. Biochem. Biophys. Acta 1224, 255–263.
- Kalpana, C., Menon, V.P., 2004. Modulatory effects of curcumin on lipid peroxidation and antioxidant status during nicotine-induced toxicity. Pol. J. Pharmacol. 56, 581–586.
- Kawanishi, S., Inoue, S., Sano, S., 1986. Mechanism of DNA cleavage induced by sodium chromate (VI) in the presence of hydrogen peroxide. J. Biol. Chem. 261, 5952–5958.
- Khanna, N.M., 1999. Turmeric—nature's precious gift. Curr. Sci. 76 (10), 1351–1356.
- Kumar, S., Sathwara, N.G., Gautam, A.K., Agarwal, K., Shah, B., Kulkarni, P.K., Patel, K., Patel, A., Dave, L.M., Parikh, D.J., Saiyed, H.N., 2005. Semen quality of industrial workers occupationally exposed to chromium. J. Occup. Health 47, 424–430.
- Leblond, P.C., Clermont, Y., 1952. Definition of the stages of the seminiferous epithelium in the rat. Ann. N. Y. Acad. Sci. 55, 548–573.
- Li, H., Chen, Q., Li, S., 2001a. Effect of Cr(VI) exposure on sperm quality: human and animal studies. Ann. Occup. Hyg. 45, 505–511.
- Li, H., Chen, Q., Li, S., Yao, W., Li, L., Shi, X., Wang, L., Castranova, V., Vallyathan, V., Ernst, E., Chen, C., 2001b. Effect of Cr(VI) exposure on sperm quality: human and animal studies. Ann. Occup. Hyg. 45 (7), 505–511.
- Lowry, O.H., Rosebrough, N.J., Farr, A.L., Randall, R.J., 1951. Protein measurement from phenol reagent. J. Biol. Chem. 193, 265.
- Majumder, G.C., Biswas, R., 1979. Evidence for the occurrence of ecto (adenosine triphosphatase) in rat epididymal spermatozoa. Biochem. J. 183, 737–743.
- Masuda, T., Maekawa, T., Hidaka, K., Bando, H., Takeda, Y., Yamaguchi, H., 2001. Chemical studies on antioxidant mechanisms of curcumin: analysis of oxidative coupling products from curcumin and linoleate. J. Agric. Food Chem. 49, 2539–2547.
- Mukhopadhyay, S., Lahari, D., Tripathy, S., Jana, S., Chandra, A.K., 2004. Evaluation of possible goitrogenic and anti thyroid activity of soyabean (*Glycine max*) of Indian origin. Indian J. Physiol. Allied Sci. 58, 1–12.
- O'Donnell, L., McLachlan, R.I., Wreford, N.G., Robertson, D.M., 1994. Testosterone promotes the conversion of round spermatids between stages VII and VIII of the rat spermatogenic cycle. Endocrinology 135 (6), 2608–2614.
- Ochsendorf, F.R., 1999. Infection in male genital tract and reactive oxygen species. Hum. Reprod. Update 5 (5), 399–420.
- Osawa, T., Kato, Y., 2005. Protective role of antioxidative food factors in oxidative stress caused by hyperglycemia. Ann. N. Y. Acad. Sci. 1043, 440–451.
- Paoletti, F., Mocali, A., 1990. Determination of superoxide dismutase activity by purely chemical system based on NAD(P)H oxidation. Methods Enzymol. 186, 209–220.
- Pulla Reddy, A., Lokesh, B.R., 1992. Studies on spice principles as antioxidants in the inhibition of lipid peroxidation of rat liver microsomes. Mol. Cell. Biochem. 111, 117–124.
- Pulla Reddy, A., Lokesh, B.R., 1994. Effect of dietary turmeric (*Curcuma longa*) on iron induced lipid peroxidation in the rat liver. Food Chem. Toxicol. 32, 279–283.
- Russell, L.D., Alger, L.F., Naquin, L.G., 1987. Hormonal control of pubertal spermatogenesis. Endocrinology 120, 1615–1632.
- Sarkar, M., Roy Chaudhury, G., Chattopadhyay, A., Biswas, N.M., 2003. Effect of sodium arsenate on spermatogenesis, plasma gonadotrophins and testosterone in rats. Asian J. Androl. 5 (1), 27–31, Mar.
- Saxena, D.K., Murthy, R.C., Lal, B., Srivastava, R.S., Chandra, S.V., 1990. Effect of hexavalent chromium on testicular maturation in the rat. Reprod. Toxicol. 4, 223–228.
- Sharma, O.P., 1976. Antioxidant activity of curcumin and related compounds. Biochem. Pharmacol. 25, 1811–1812.
- Shi, X., Ding, M., Wang, S., 1999a. Cr (IV) causes activation of nuclear transcription factor NF- κ B, DNA strand breaks and dG hydroxylation via free radical reactions. J. Inorg. Biochem. 75, 37–44.
- Shi, X., Chiu, A., Chen, J., 1999b. Reduction of chromium(VI) and its relationship to carcinogenesis. J. Toxicol. Environ. Health 2, 87–104.
- Shmitova, L.A., 1990. Contents of hexavalent chromium in biological substrates of pregnant and puerperant women working in production of chromium compounds. Gig. Tr. Prof. Zabol. 2, 33–35.
- Sikka, S.C., 1996. Oxidative stress and antioxidants in normal and abnormal sperm function. Front. Biosci. 1, 78–86.
- Singh, J., O'Neill, C., Handelsman, D.J., 1995. Induction of spermatogenesis by androgens in gonadotropin-deficient (*hpg*) mice. Endocrinology 136 (12), 5311–5321.
- Sinha, M., Mukherjee, B.P., Mukherjee, B., Dasgupta, S.R., 1974. Study on the 5-hydroxytryptamin contents in guinea pig stomach with relation to phenyl butazone induced gastric ulcers and the effects of curcumin thereon. Indian J. Pharmacol. 6, 87–96.
- Steinberger, E., Steinberger, A., 1975. Hormonal control of testicular function in mammals. In: Hamiltol, D.W., Greep, R.O. (Eds.), Handbook of Physiology, Endocrinology, vol. IV, Part 2. Williams and Wilkins, Baltimore, MD, pp. 325–345.
- Stohs, J.S., Bagchi, D., Hassoun, E., Bagchi, M., 2001. Oxidative mechanism in the toxicity of chromium and cadmium ions. J. Environ. Pathol. Toxicol. Oncol. 20 (2), 77–88.
- Subramanian, S., Rajendiran, G., Sekhar, P., Gowri, C., Govindarajulu, P., Aruldas, M.M., 2006. Reproductive toxicity of chromium in adult bonnet monkeys (*Macaca radiata* Geoffroy). Reversible oxidative stress in the semen. Toxicol. Appl. Pharmacol. 215, 237–249.
- Sugiyama, M., 1992. Role of physiological antioxidant in Cr(VI) induced cellular injury. Free Rad. Biol. Med. 12, 397–407.
- Sun, Y.T., Irby, D.C., Robertson, D.M., deKretser, D., 1989. The effects of exogenously administered testosterone on spermatogenesis in intact and hypophysectomized rats. Endocrinology 125, 1000–1010.
- Sun, Y., Wreford, N.G., Robertson, D.M., deKretser, D.M., 1990. Quantitative cytological studies of spermatogenesis in intact and hypophysectomized rats: identification of androgen dependent stages. Endocrinology 127, 1215–1223.
- Tsou, T.C., Yang, J.L., 1996. Formation of reactive oxygen species and DNA strand breakage during interaction of chromium(III) and hydrogen peroxide *in vitro*: evidence for a chromium(III)-mediated Fenton-like reaction. Chem. Biol. Interact. 102, 133–153.
- Ueno, S., Sugiyama, M., Nobuyuki, S., 1995. Effect of dimethylthiourea on chromium(VI)-induced DNA single-strand breaks in Chinese hamster V-79 cells. Mutat. Res. 346, 247–253.