

Clinical Examination of the Foot and Ankle

Craig C. Young, MD^{a,b,c,*},
Mark W. Niedfeldt, MD^{a,b,c,d},
George A. Morris, MD^{a,c}, Kevin J. Eerkes, MD^{e,f}

^a*Division of Sports Medicine, Medical College of Wisconsin,
9200 W Wisconsin Avenue, Milwaukee, WI 53226, USA*

^b*Department of Orthopaedic Surgery, Medical College of Wisconsin,
9200 W Wisconsin Avenue, Milwaukee, WI 53226, USA*

^c*Department of Family and Community Medicine, Medical College of Wisconsin,
9200 W Wisconsin Avenue, Milwaukee, WI 53226, USA*

^d*Department of Cell Biology, Neurobiology, and Anatomy, Medical College of Wisconsin,
9200 W Wisconsin Avenue, Milwaukee, WI 53226, USA*

^e*Department of Sports Medicine, New York University,
726 Broadway, 4th Floor, New York, NY 10003-9580, USA*

^f*Department of Medicine, New York University, School of Medicine,
726 Broadway, New York, NY 10003, USA*

In humans, the foot and ankle serve as the primary interface between the ground and the body during ambulation. This requires that the foot and ankle complex be able to absorb impact loading forces, adapt to uneven ground, and allow efficient propulsion. To accomplish this task, the foot and ankle are usually composed of 26 primary bones, not including the tibia, fibula, accessory bones, and sesamoid bones. A good clinical examination can supplement the history and assist the examiner in making the diagnosis of any problem. Because reproduction of a patient's symptoms is the key to making a correct diagnosis, this article correlates clinical anatomy and testing with common complaints of the foot and ankle (Figs. 1–4).

Stance, gait, and movement

The foot and ankle examination begins with observing the patient's mobility, gait, and stance. These observations are helpful in diagnosing foot

* Corresponding author. Department of Orthopaedic Surgery, Medical College of Wisconsin, 9200 W Wisconsin Avenue, Milwaukee, WI 53226.

E-mail address: cyoung@mcw.edu (C.C. Young).

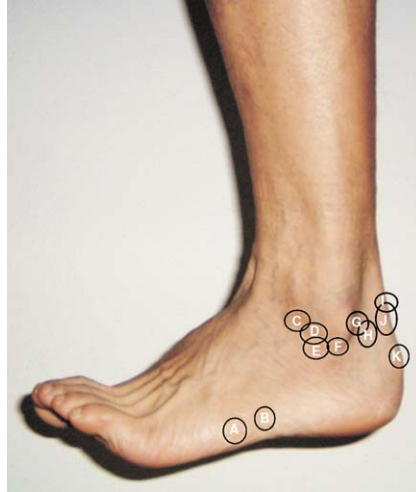


Fig. 1. Lateral foot and ankle—typical locations of injury symptoms and selected anatomic structures: (A) Jones fracture; (B) avulsion fracture of the fifth metatarsal; (C) anterior ankle impingement; (D) anterior talofibular ligament; (E) sinus tarsi; (F) calcaneofibular ligament; (G) posterior ankle impingement; (H) retrocalcaneal bursitis; (I) Achilles tendon rupture; (J) Achilles tendonitis; (K) calcaneal apophysitis (Sever's condition) and "pump bump."

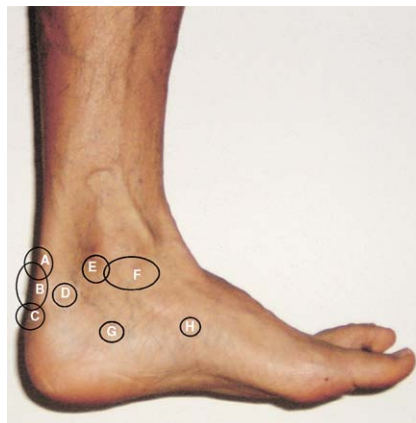

Fig. 2. Medial foot and ankle—typical locations of injury symptoms and selected anatomic structures: (A) Achilles tendon rupture; (B) Achilles tendonitis; (C) calcaneal apophysitis (Sever's condition) and "pump bump"; (D) retrocalcaneal bursitis; (E) tarsal tunnel syndrome; (F) medial ankle sprain; (G) entrapment site of first branch of lateral plantar nerve; (H) master knot of Henry, entrapment site of medial plantar nerve.

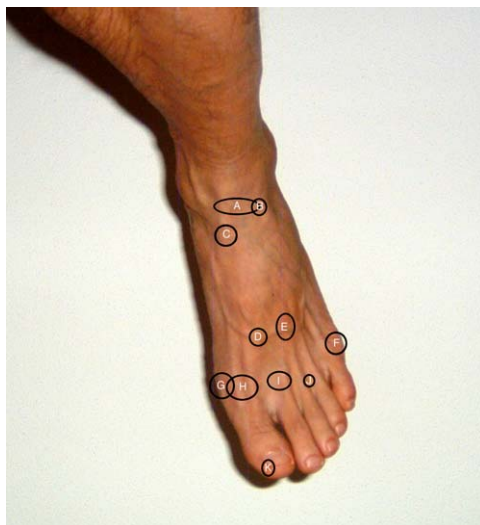


Fig. 3. Dorsal foot and ankle—typical locations of injury symptoms and selected anatomic structures: (A) anterior ankle impingement; (B) osteochondritis dissecans (OCD) of the lateral talar dome; (C) the N spot—navicular stress fracture; (D) Lisfranc sprain; (E) anterior tarsal tunnel syndrome; (F) bunionette; (G) bunion; (H) hallux rigidus; (I) avascular necrosis of second metatarsal head (Freiberg’s infarction); (J) interdigital neuroma (Morton’s neuroma); (K) paronychia.

and ankle dysfunction and injury, and give valuable information about the function of the foot-ankle complex. A patient’s stance and gait should be observed from the front, the side, and the back. Any asymmetry, limitation, hesitancy, or avoidance of weight bearing should be noted. Because these findings may occur gradually, they may escape the notice of the patient.

General body alignment

The patient should first be observed standing. The position of the trunk and hips should be observed, because asymmetry may represent an anatomic variation that may predispose a patient to a particular injury, or may be a compensatory change in response to an injury. Specific observations should include an evaluation of hip and knee alignment and position, because the lower extremity functions as a unit and not in isolation (see the article on biomechanics of the lower extremity elsewhere in this issue). A difference in relative position of the iliac crest may be a sign of an anatomic leg-length discrepancy, or a functional leg-length discrepancy from a condition such as sacroiliac joint dysfunction or scoliosis. Knee alignment variants such as genu varus (bowlegs) or genu valgus (knock-knee) should be noted, because these variations have been traditionally considered to be risk factors for many overuse injuries [1–7]; note, however, that recent studies have shown that these “malalignments”

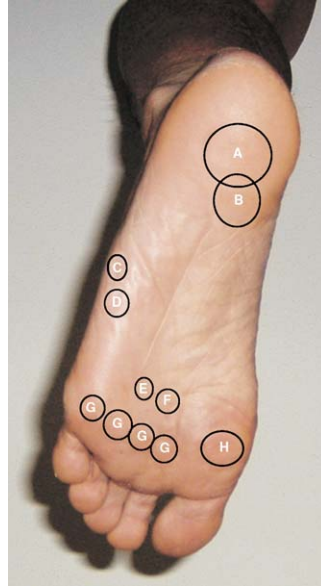


Fig. 4. Plantar foot—typical locations of injury symptoms and selected anatomic structures: (A) plantar fat pad; (B) plantar fasciitis; (C) avulsion fracture of the fifth metatarsal; (D) Jones fracture; (E) stress fracture of the third metatarsal; (F) stress fracture of the second metatarsal; (G) metatarsalgia; (H) sesamoiditis.

may be only minor risk factors, and probably do not need to be corrected in asymptomatic individuals [2,4,8,9].

Arches

The medial arch is examined in both weight-bearing and non-weight bearing positions. The height at the apex of a normal medial longitudinal arch is approximately 1 cm when the patient is weight bearing. A low arch (pes planus) may be congenital, or may be associated with trauma, posterior tibial tendon dysfunction, rheumatoid arthritis, or contraction of the Achilles tendon. A patient who has a flexible flatfoot will appear to have a normal or near-normal arch when non-weight bearing, but will have substantial loss of height of the arch when weight bearing (Fig. 5). A high arch (pes cavus) may be idiopathic or associated with congenital or neurologic disease, whereas a convex, or rocker bottom, foot can be seen in diabetic patients who have Charcot neuropathic arthropathy.

Patients who have high or low arches may have no problems and when asymptomatic, need no treatment; however, these conditions may place people at slight increased risk for overuse injuries such as plantar fasciitis and shin splints, because both these conditions are thought to decrease the dissipation of the forces of impact loading of the foot [1–5,7,10–12].

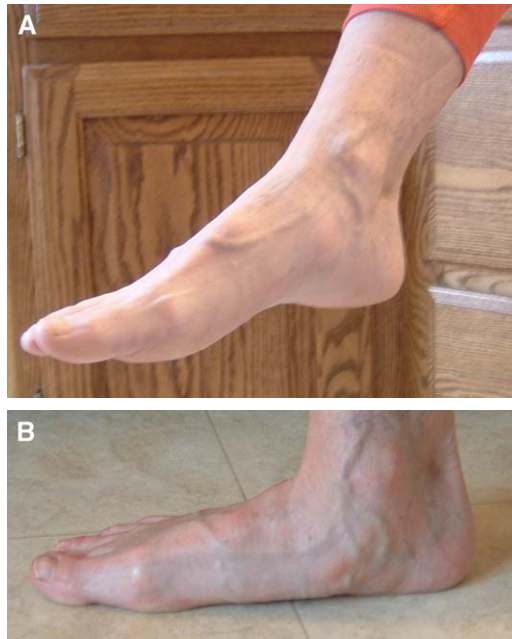


Fig. 5. Flexible flatfoot. (A) Non-weight bearing—the arch appears relatively normal. (B) Weight-bearing—the arch disappears.

Foot shape

An Egyptian foot, found in approximately 69% of the population, is one in which the great toe is longest. A Greek foot, or Morton's foot, is one in which the second toe is longest, and is found in approximately 22% of the population. Approximately 9% of the population has a squared foot, in which the great toe and second toe are the same length. Whichever toe is the longest in the foot places an increased load on its proximal metatarsal and metatarsal phalangeal joint, increasing the risk for injury and arthritis in these structures [13].

Antalgic gait

Antalgic gait can be found in any condition that causes pain in the lower extremity. In antalgic gait, the stance (weight-bearing) phase is shorter on the affected side [14], resulting in shorter stride length on the uninvolved side and overall decreased walking velocity.

Foot slap and steppage gait

An individual who has weak dorsiflexors may walk with a foot slap or steppage gait. A steppage gait involves excessive hip and knee flexion to give

additional ground clearance for the foot and toes. This gait may also be seen with loss of ankle range of motion. Heel walking is a general test of ankle dorsiflexor strength, especially the tibialis anterior muscle. Individuals should normally be able to keep the metatarsal heads several centimeters off the floor. Dorsiflexion weakness is suspicious for deep peroneal or common peroneal (L4, L5) nerve injury or an L4 radiculopathy.

Other gait tests

Having the patient walk on the toes (tiptoeing) is a general test of ankle plantar flexor strength, especially the gastrocnemius-soleus complex. Individuals should normally be able to keep their heels several centimeters off the floor. A better test for evaluating subtle deficits in plantar flexor strength is single-leg heel raises, because the plantar flexors are relatively strong muscles (Fig. 6). Plantar flexor weakness is suspicious for either an injury to the Achilles tendon or dysfunction of either the sciatic or tibial nerve, which supply most of the main plantar flexors, including the gastrocnemius, soleus, plantaris, flexor digitorum longus, flexor hallucis longus, and tibialis posterior. The possibility of neurologic involvement is raised if toe flexion weakness is also present.

Lateral foot walking (Fig. 7) tests inversion strength, which is primarily a function of the tibialis posterior muscle and tibial nerve. Medial foot walking (Fig. 8) tests eversion strength, which is primarily a function of the peroneal muscles and superficial peroneal nerve. This movement is rarely tested because it is relatively difficult for most patients.

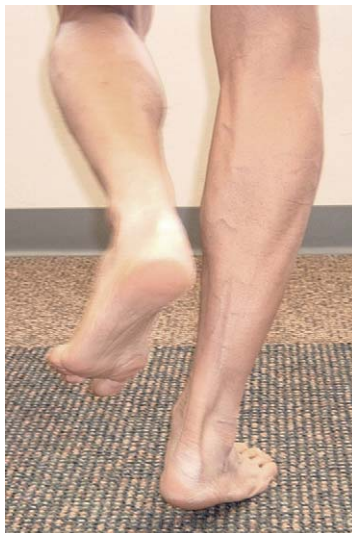

Fig. 6. Single-leg heel raise.

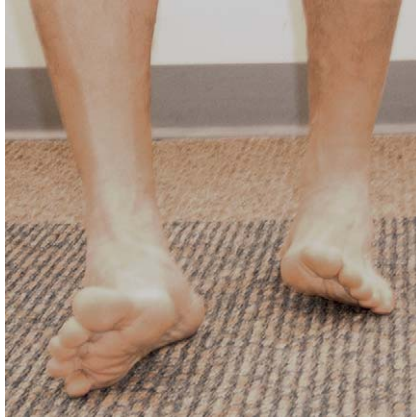

Fig. 7. Lateral foot walking.

Supination is clinically defined as a combination of inversion, adduction, and plantar flexion motions [13]. Supination allows the foot and ankle joints to move into a relatively closed packed or locked position, and gives the foot rigidity to transfer energy efficiently during ambulation. Pronation is a combination of eversion, abduction, and dorsiflexion motions. It allows the foot and ankle complex to form a more flexible configuration to absorb shocks and adapt to terrain. Anatomists and kinesiologists sometimes define pronation and supination differently, which can lead to some confusion in the literature [13,15].

Signs in shoe-wear patterns

Examining the patient's shoes for wear pattern may give clues about overpronation and oversupination. Because most runners wear out the outer

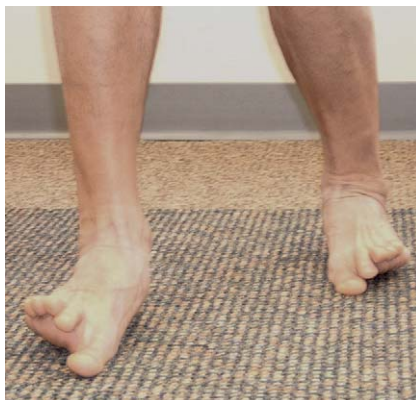

Fig. 8. Medial foot walking.

corner of the heel, the key area to evaluate is the area under the forefoot. Most runners wear down the central region, but the shoes of overpronators show more medial wear, whereas those of oversupinators show more lateral wear (Fig. 9) [16]. The shoes of severe overpronators can easily be recognized, because the inner corner of their shoe heels tend to wear out [16]. Permanent bulging of the medial shoe wall suggests an everted foot, whereas bulging on the lateral shoe wall suggests an inverted foot [13].

In all patients who have foot and ankle problems, it is also important to check shoe size. Many individuals wear shoes that are the wrong size, usually too small [17]. The location of the toebox crease should be at the position of the metatarsal heads, and a significant discrepancy may indicate a possible shoe-foot mismatch. For optimal fitting, feet should be sized at the end of the day or after exercise, when feet are slightly larger from fluid collection. The toecap should be 0.25 to 0.5 inch (ie, approximately one thumb's width) longer than longest toe of the largest foot, and the eyestays should be parallel when laced snugly [16,17]. Shoes should be also checked for friction points (Figs. 10A, B) that may be a cause of injury.

Traditionally, it is thought that inadequate cushioning in footwear leads to increased stress throughout an athlete's lower extremities, and thus an increased risk of stress injuries [7,11,16,18,19]; however, more recently, some biomechanists have theorized that increased cushioning may actually interfere with a runner's neuromuscular feedback and increase impact forces [20–22]. Shoe manufacturers have published studies that have shown a decrease in injuries with better cushioned shoes in aerobic dancers [11], and several studies of military recruits have shown a protective effect of increased cushioning in shoe wear [23–27]; however, whether or not this applies to the athletic population is unknown. It has been shown that athletic shoes lose a significant amount of cushioning ability over time and with use [18]. It is not known, though, if this loss of cushioning leads to an increase in injuries. Despite this, some experts still recommend that athletic shoes be changed at least once a year or after 300 to 500 miles of running [6,16,18,28,29].

Dermatologic conditions

The skin may show signs of infectious disease, immune system and circulatory problems, friction and other irritations, and abnormal loading of the foot. Plantar warts usually appear as areas of slightly raised, thickened skin containing visible black specks. The specks, which are thrombosed capillaries, are usually visible on initial examination, but sometimes the skin has to be pared down before they can be seen. Tinea pedis usually presents with macerated tissue in the web spaces, most commonly between the third and fourth toes and between the fourth and fifth toes. Tinea pedis may also present as in a moccasin-type distribution, with dry scaling and erythema

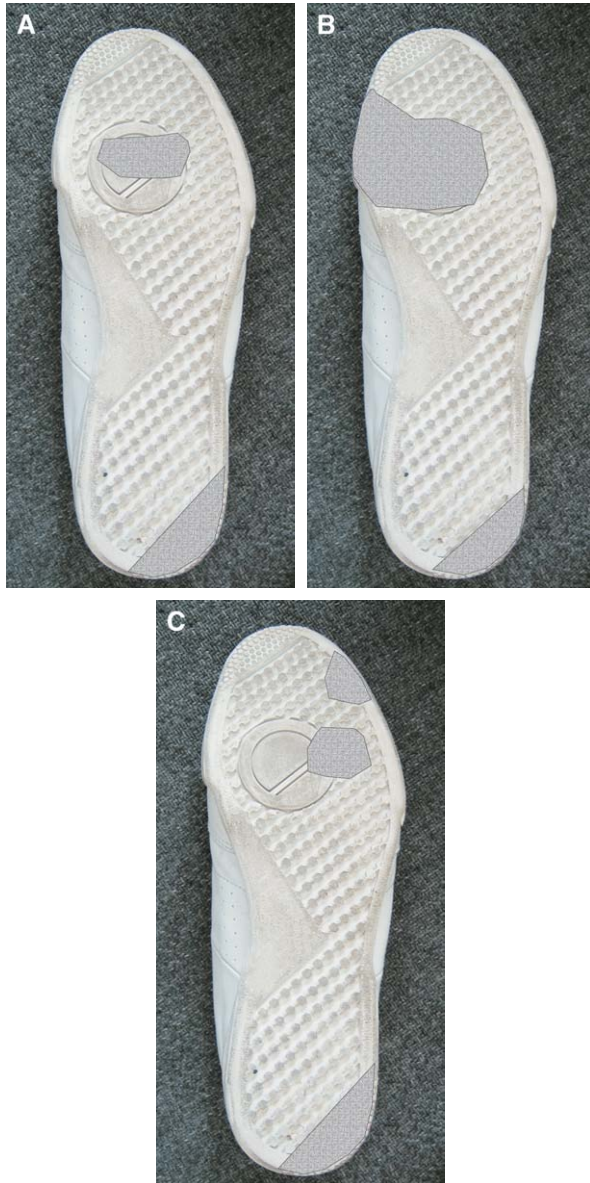


Fig. 9. Shoe sole wear patterns. (A) The areas of shoe wear by a person with normal gait are shown in gray. (B) The areas of shoe wear by a person who is a mild overpronator are shown in gray. (C) The areas of shoe wear by a person who is an oversupinator are shown in gray.



Fig. 10. Shoe upper wear from excess medial ankle swing. (A) an older shoe with obvious wear indicated by white arrow and more subtle wear indicated by black arrow. (B) A newer shoe with subtle wear as indicated by the black arrows.

around the foot. Dyshidrotic eczema produces small, deep-seated, clear vesicles, especially in the toe region [30]. Juvenile plantar dermatosis can also mimic tinea pedis. In children, this usually begins with symmetric redness, cracking, and dryness of the weight-bearing aspects of the great toes, with subsequent involvement of the entire forefoot [31]. Onychocryptosis, an ingrown toenail, can be caused by improperly fitting footwear, improper toenail trimming, trauma, or infections. It occurs when a sharp corner of the toenail digs into the surrounding skin, and can lead to pain and infection. Acute paronychia is an infection of the periungual soft tissue. It appears most often as an ingrown toenail, usually on the great toe, surrounded by a painful, erythematous, inflamed, periungual mass. A purulent exudate is frequently present.

Pitted keratolysis is found on the weight-bearing aspects of the foot, most often in the sole. It appears as a series of small pits and erosions in the stratum corneum, and is caused by a superficial corynebacterium infection [32]. Unlike tinea pedis, pitted keratolysis usually spares the web spaces. Pitted keratolysis usually causes little pain; thus the most common patient complaint is of a malodorous foot. Another condition that tends to spare the web spaces is contact dermatitis, most often found on the dorsal surface of the foot, where the skin is thinner. This condition is most frequently caused by allergies to shoe material and dyes, although it may also be caused by soaps, detergents, lotions, and powders [31].

Thickening of the skin (hyperkeratosis) may indicate an area of increased friction or loading. A callus is a generalized area of thickened skin, whereas a corn (heloma) is an isolated, localized area of thickened skin. A hard corn is very dense tissue usually found on exposed surfaces, whereas soft corns are frequently found in pairs on opposing skin surfaces, such as between toes.

Chronic irritation to the nail matrix from frequent wearing of tight shoes, high heels, and cleats may result in onychodystrophy, or distortion, thickening, and groove formation in the nail (Fig. 11). Onychogryphosis,

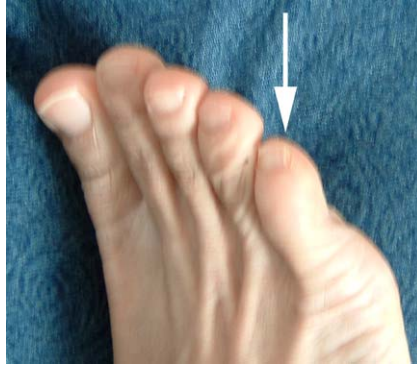

Fig. 11. Nail grooving (*white arrow*).

or clawed nails, can be the result of toe malalignment, wearing inappropriate shoes, or aging.

Thickened toenails also can be caused by fungi and immune system responses. Onychomycosis, a fungal infection of the toenails, usually appears in only some of the toenails, leaving “skipped,” or normal, nails, in between [32]. In contrast, psoriasis and poor arterial perfusion have a tendency to affect all ten toenails. Onychomycosis usually appears initially beneath the distal free edge of the nail, with hyperkeratosis and discoloration of the nail. Subungual debris accumulates beneath the nail plate, and is ideal for sampling for culture and microscopic examination with potassium hydroxide.

Innervation

Innervation of the foot and ankle is highly variable [13]. The tibial nerve innervates the flexor digitorum longus, posterior tibialis, gastrocnemius, and soleus muscles, and provides the posterior calf with sensation (Table 1). Branches of the tibial nerve include the medial and lateral plantar nerves, which supply the medial and lateral plantar surfaces respectively, and the medial calcaneal nerve, which supplies the medial and plantar heel (Fig. 12). The deep peroneal nerve supplies the tibialis anterior, extensor digitorum longus, and extensor hallucis longus muscles, and provides sensation to the first web space. The superficial peroneal nerve supplies the peroneal muscles and provides sensation to the dorsum of the foot. The sural nerve is formed from branches of both the tibial and common peroneal nerves, and supplies sensation to the lateral foot. The saphenous nerve provides sensation to the medial leg, ankle, and hindfoot.

Because a compartment syndrome of the leg may cause referred symptoms in the foot and ankle, it is essential to remember which compartment each nerve travels through in order to direct possible testing and treatment options (see Table 1). It is important to regularly check the

Table 1
Typical innervation of the major muscles and areas of the foot and ankle

| Nerve (and leg compartment) | Sensation ^a | Muscle | Nerve root | Action |
|--|---------------------------|----------------------------|------------|-----------------------------------|
| Tibial (deep posterior leg compartment) | Medial plantar heel | Gastrocnemius ^b | S1, S2 | Plantar flexion |
| | | Soleus ^b | S1, S2 | Plantar flexion |
| | | Tibialis posterior | L5, S1 | Foot adduction & inversion |
| | | Flexor digitorum longus | L5, S1 | Lateral toe flexion |
| Superficial peroneal (lateral leg compartment) | Dorsum of foot | Flexor hallucis longus | L5-S2 | Great toe flexion |
| | | Peroneus longus | L4-S1 | Foot eversion |
| | | Peroneus brevis | L4-S1 | Foot eversion |
| Deep peroneal (anterior compartment) | 1 st web space | Tibialis anterior | L4-S1 | Foot inversion & dorsiflexion |
| | | Extensor digitorum longus | L4-S1 | Toe extension & foot dorsiflexion |
| | | Extensor hallucis longus | L4-S1 | Great toe extension |

^a The nerves may supply other areas of the foot and ankle (see Figure 12). The areas listed in this table are areas, which, in general, are only supplied by the listed nerve.

^b These muscles travel in superficial posterior leg compartment.

skin sensitivity of the feet in diabetic patients. This can be done by pressing a 0.10 g-, 5.07-diameter nylon monofilament over a representative sampling of points on the plantar surface [33]. Lack of skin sensitivity at this level substantially increases the risk of a patient in developing foot ulcers.

Examining the ankle

The ankle is among the most frequently injured joints in the body. The ankle consists of the articulation between the talus of the hindfoot and the tibia and fibula of the leg. Although most ankle injuries are sprains caused by accidental inversion, a number of other diagnoses should be considered, particularly if the mechanism of injury is atypical [34,35].

An acutely injured ankle should be observed for any soft-tissue swelling or bruising. Unfortunately, the ankle has a tendency to develop diffuse swelling rather quickly, limiting the use of swelling and ecchymosis as a way to locate the point of the injury. Palpating areas of point tenderness can help to localize an area suspicious for bony injury; however, the usefulness of palpation may also be limited by the soft-tissue swelling, which can result in diffuse pain. Pain localized along the anterior or posterior ankle joint line may indicate a capsular or intra-articular pathology.

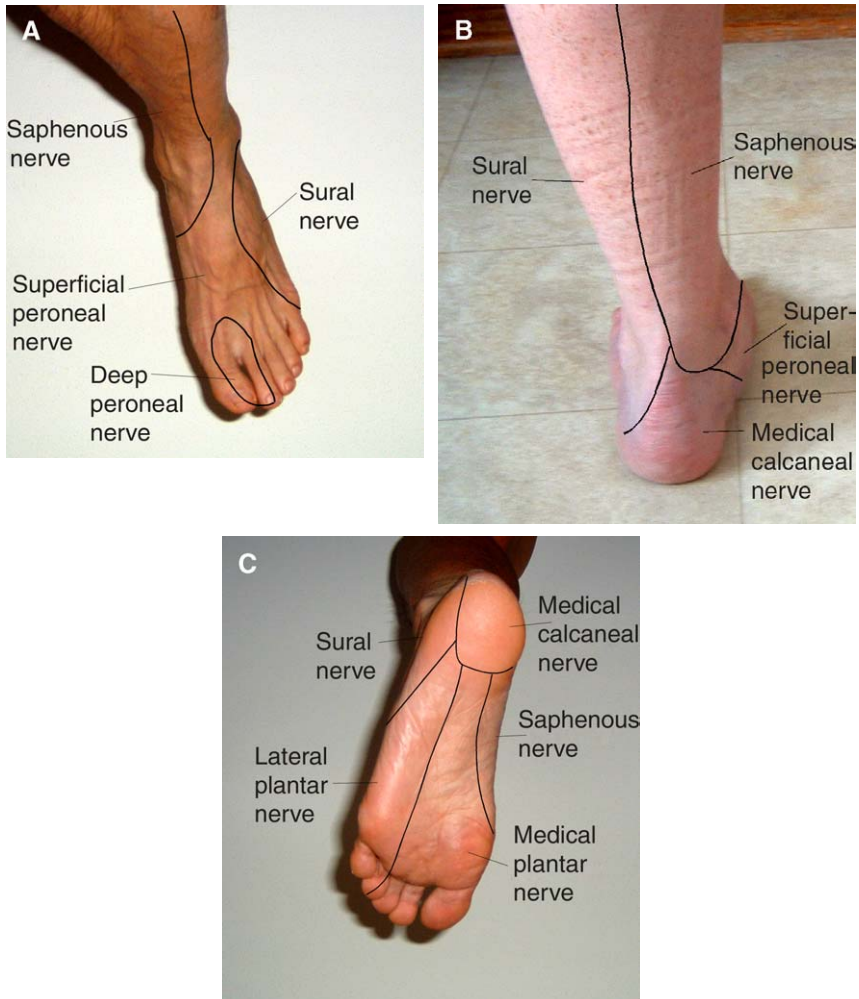


Fig. 12. (A, B, C) Typical sensory innervation of the foot and ankle.

Ankle sprains

The most common ankle injury is a lateral sprain caused by inversion of the foot, with over 25,000 occurring each day in the United States [36]. If examined immediately after the injury, the patient usually will have localized tenderness over the anterior talofibular ligament region (see Fig. 1). In the case of a more severe ankle injury, the patient will also have tenderness over the calcaneofibular ligament region (see Fig. 1). Unfortunately, a delay in the examination as short as a few hours after an ankle sprain often results in diffuse ankle swelling and tenderness. For patients from 2 to 65 years of age,

the Ottawa ankle rules are a validated, useful guide in determining whether to order radiographs [37–39]. Radiographs should be ordered if any of the following exist:

- Deformity
- Area of bony point tenderness, especially of navicular and base of fifth metatarsal (Ottawa ankle rules). Buffalo modification of Ottawa ankle rules—only count ridge of distal fibula [39].
- Cannot weight bear; inability to walk more than four steps
- Mechanism of injury along with history and physical suggest fracture, especially for high-impact injury (ie, motor vehicle accidents).

The anterior drawer test assesses the integrity of the anterior talofibular ligament. The patient should allow the ankle to relax ($\sim 20^\circ$ plantar flexion) while the examiner stabilizes the leg with one hand and pulls the heel forward with the other hand (Fig. 13). A positive test is noted when there is more than 3 to 5 mm of difference in laxity between the injured and uninjured sides. Unfortunately, a history of previous ankle sprains or inability of the patient to relax may limit the usefulness of this test. The end point should also be noted, because it is often softer on the injured side after a severe, acute injury.

The talar tilt test (inversion stress test or varus stress test) assesses calcaneofibular and anterior talofibular ligament integrity. To perform the test, the examiner stresses the ankle with a varus force (Fig. 14). An absolute angulation of greater than 23° or a difference of more than 10° between the uninjured ankle and the injured ankle is suggestive of complete tears of

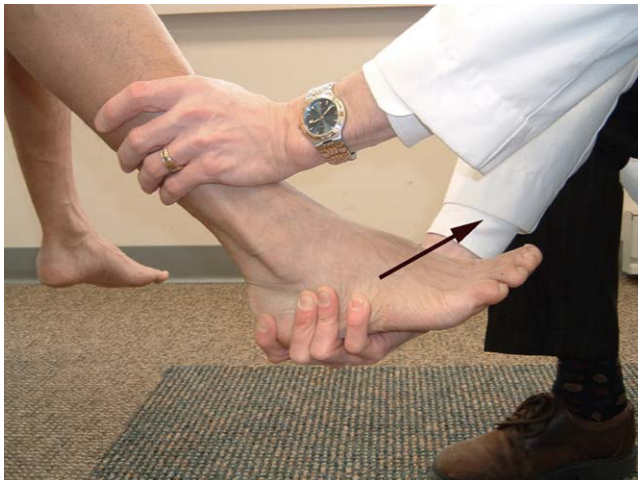

Fig. 13. Anterior drawer test—the examiner stabilizes the leg and pulls the heel forward in the direction indicated by the black arrow ($\sim 90^\circ$ to axis of the leg).

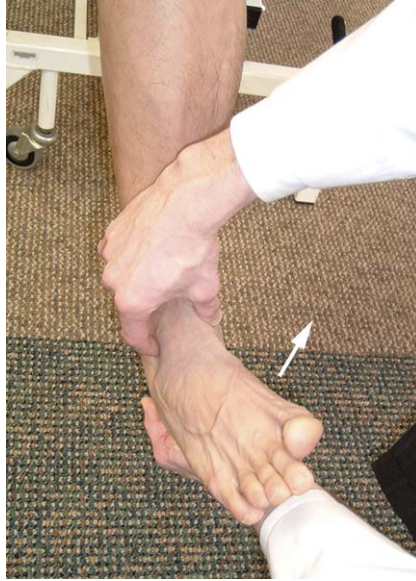

Fig. 14. Talar tilt test—the examiner stabilizes the leg and places a varus stress on the heel as indicated by the white arrow.

both the calcaneofibular and anterior talofibular ligament [40]. Maximal dorsiflexion to lock the subtalar joint may improve the sensitivity of this test [41]; however, it is important to examine both ankles, because some individuals have naturally lax joints.

To rule out high ankle sprain, evaluate the integrity of the syndesmosis membrane and the anterior and posterior inferior tibiofibular ligaments. Two useful tests to evaluate these structures are the squeeze test and the external rotation test.

A squeeze test is done by gently squeezing the tibia and fibula together in the midshaft region (Fig. 15). If the test produces pain at the distal (ankle) end, a high ankle sprain is likely. Pain at the proximal (fibular head) end raises the suspicion of a Maisonneuve fracture of the proximal fibula, which is usually associated with a severe medial ankle injury. An external rotation test is done by placing the ankle in maximal dorsiflexion and applying an external rotation force on the ankle, using the foot as a lever arm. Increased pain with this stress suggests a high ankle sprain.

Poor proprioceptive function, which frequently manifests as ankle instability, is a common cause of recurrent ankle sprains and is an indication for formal rehabilitation. Using the uninjured side first to set a baseline, perform a Romberg test to evaluate proprioception (Fig. 16). Have the patient stand on one foot, first with eyes open, then with eyes closed, and observe the ability to balance on the foot.

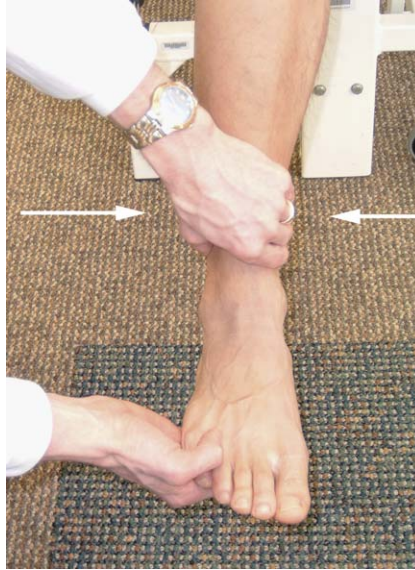

Fig. 15. Squeeze test—the examiner gently squeezing the tibia and fibula together as indicated by the white arrows.

Achilles tendon region injuries

In the posterior ankle region, the most common problems relate to the Achilles tendon. A complete Achilles tendon rupture is an injury for which timely treatment is needed to achieve optimal results. The best test to diagnosis this injury is the Thompson test (Fig. 17A, B). With the patient lying prone on the examination table with the knee flexed to 90°, gently squeeze the calf to induce passive plantar flexion of the foot (see Fig. 17A). If the Achilles tendon is intact or partially torn, the foot will flex. If a complete Achilles tendon rupture has occurred, the foot will not move passively (see Fig. 17B). In the case of a complete tear, a defect in the Achilles tendon can often be palpated, approximately 2 to 3 cm proximal to the calcaneal insertion (see Figs. 1, 2). Significant swelling and ecchymosis usually accompany an acute Achilles tendon rupture. Most patients who have complete Achilles tendon ruptures will have significant weakness in plantar flexion strength and will be unable to do a heel raise on the affected side. It is important to test with a heel raise instead of resisting ankle plantar flexion manually, because muscular patients will maintain good plantar flexion strength as long as their remaining flexor tendons (eg, the plantaris, flexor digitorum longus, peroneus longus, peroneus brevis, flexor hallucis longus and tibialis posterior) are intact and functioning.

In Achilles tendonitis, palpating the tendon will cause pain, but no defect will be felt and the Thompson's test will be negative. With chronic Achilles tendonosis, a tender, boggy soft-tissue mass often encases the distal 2 to

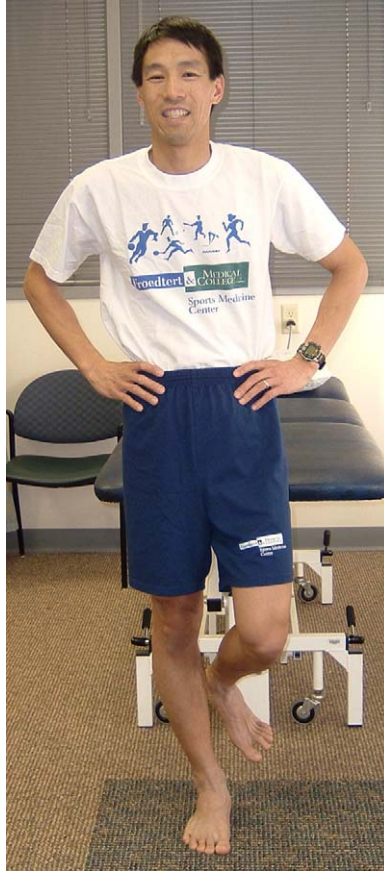

Fig. 16. Romberg test.

3 cm of the Achilles tendon sheath (see Figs. 1, 2). With these injuries, patients usually have tenderness to plantar flexion against resistance, and frequently tenderness to extreme passive dorsiflexion of the ankle as well [42].

Haglund's deformity is an increased prominence of the posterior superior lateral calcaneus. The soft-tissue thickening that usually accompanies Haglund's deformity is often called a "pump bump" because of its frequency in women who wear high heels. Calcaneal apophysitis (Sever's condition) presents with tenderness in this region in adolescent patients. The retrocalcaneal bursa can be palpated in the space between the Achilles tendon and the superior calcaneal tuberosity (see Figs. 1, 2).

Other ankle problems

Patients who have ankle locking may have osteochondritis dissecans (OCD) of the talar dome (see Fig. 3). The posterior talar dome can be

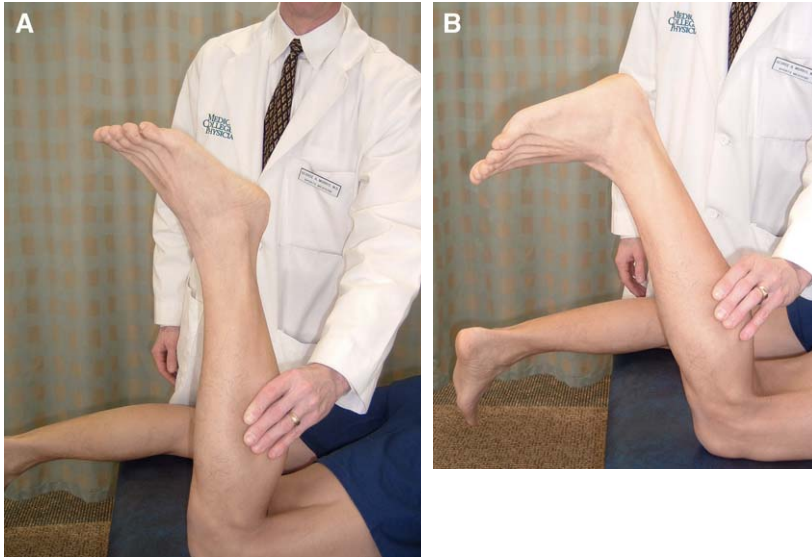


Fig. 17. Thompson test. (A) A normal Thompson test results in passive plantar flexion of the foot. (B) An abnormal (positive) Thompson test has no passive plantar flexion to squeezing the calf (simulated examination).

palpated by maximally dorsiflexing the ankle, whereas the anterior talar dome can be palpated by maximally plantar flexing the ankle. Anterior impingement symptoms may be reproduced at the anterior joint line (see Figs. 1, 3) by a quick, sharp dorsiflexion movement. Posterior impingement symptoms may be reproduced at the posterior joint line (see Fig. 1) by a quick, sharp plantar flexion movement. Patients who have impingement syndromes may also have loss of motion caused by bone spurs or an accessory bone, usually an os trigonum posteriorly. To measure passive dorsiflexion, place the hindfoot in neutral position and lock the forefoot in inversion to minimize forefoot apparent motion, then dorsiflex the ankle using the foot as a lever arm. The average patient has approximately 20° of dorsiflexion. Other causes of loss of dorsiflexion include gastrocnemius or soleus contracture or syndesmosis scarring.

Examining the foot

Hindfoot

Observation of the hindfoot usually begins from behind, with the patient standing. The examiner should note the hindfoot alignment with the midline of the calf. In noninjured patients, the alignment is approximately 5° to 10° valgus (Fig. 18). Excessive angulation may be caused by overpronation or pes planus. Normally only one or two lateral toes are visible from a posterior

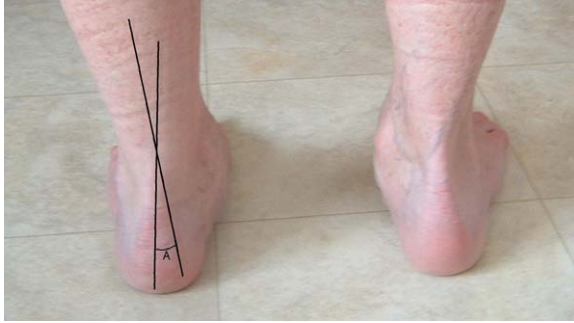

Fig. 18. Hindfoot alignment and too-many-toes sign. Hindfoot alignment—on the left side, a valgus hindfoot alignment of approximately 15° is indicated by the letter A. Too-many-toes sign—on the right foot, three toes are visible. Also visible in the right foot is mild medial bulging.

aspect. Seeing more toes is the “too-many-toes” sign (see Fig. 18). Pes planus is the most frequent cause of the presence of the too-many-toes sign bilaterally; however, when found unilaterally, the cause may be from tibialis posterior dysfunction. The tibialis posterior tendon inserts on the tarsal navicular and contributes to the support of the medial arch. When ruptured, a fall in the arch will result, giving a positive too-many-toes sign on the affected side.

Tibialis posterior dysfunction may be tested by a heel rise test. When the patient does a heel rise, the heels should normally invert (Fig. 19). Lack of heel inversion suggests tibialis posterior dysfunction or rupture. Subtalar joint motion may be measured by grasping the heel and maximally inverting and everting it. The average eversion is 20° , and the average inversion is 40° . Severe subtalar restriction in a child or adolescent may indicate tarsal coalition. Severe restriction in an adult is often the result of an old hindfoot fracture, most commonly of the calcaneus.

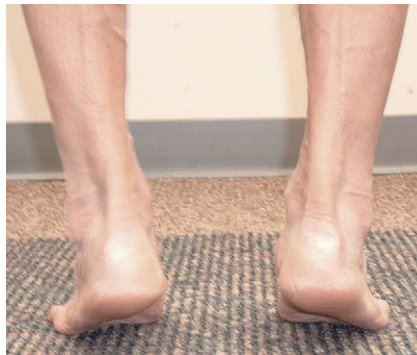

Fig. 19. Heel rise—note valgus heel alignment.

Lateral hindfoot

Peroneal tendonitis is probably the most common of the lateral hindfoot injuries. The peroneal muscles are the primary everters of the foot. These are very strong muscles, and the examiner should not be able to overcome them. The peroneus brevis muscle can usually be palpated where it travels around the posterior border of the lateral malleolus to its insertion on the base of the fifth metatarsal. It usually is seen with resisted eversion testing. The peroneus longus travels deep to the brevis and is difficult to examine separately. If the peroneal tendon is subluxing, it may be felt by palpating the tendon posteriorly to the lateral malleolus while the patient rotates the ankle clockwise and counterclockwise. Everting the dorsiflexed foot against resistance may also reproduce the subluxation [40].

The sinus tarsi is the space between the lateral talus and the calcaneus (see Fig. 1). It is usually hidden under a fat pad. Tenderness to palpation of this region may indicate subtalar injury or arthritis. The anterior process of the calcaneus is located distal to the sinus tarsi. Tenderness on palpation of this area may represent an occult fracture; fractures in this area are often missed on standard foot radiographs (see the article on Achilles tendon disorders elsewhere in this issue).

The sural nerve can be entrapped anywhere along its course from just lateral to Achilles tendon to an area 2 cm above the ankle. Nerve impingement syndromes, such as sural nerve entrapment, may be diagnosed with a positive Tinel's test, in which percussion over the entrapment site of the nerve reproduces symptoms.

Medial hindfoot

Posterior tibial tendinitis and dysfunction are common causes of medial hindfoot pain. The posterior tibial tendon courses posterior to the medial malleolus to insert on the navicular. Just superficial to the posterior tibial tendon (in order from anterior and medial to posterior and lateral) are the flexor digitorum longus tendon, the posterior tibial artery, the posterior tibial nerve, and the flexor hallucis longus. The order of these structures is often represented by the classic mnemonic "Tom, Dick, and Harry".

Of these medial hindfoot structures, usually only the posterior tibial tendon is easily observed. The pain of posterior tibial tendonitis is usually aggravated by resisted inversion. Posterior tibialis dysfunction is a common cause of acquired flatfoot, and can be tested by a first metatarsal rise test or a heel rise test. The first metatarsal rise test is done by passively externally rotating the lower leg of a standing patient. With posterior tibial dysfunction, the first metatarsal rises off the ground; with normal function, the first metatarsal remains in contact with ground because of the tethering effect of the intact posterior tibialis. A heel rise test should normally accentuate the medial longitudinal arch and result in slight inversion of the

heel (see Fig. 19); however, usual findings may be absent in patients who have coexisting arthritis, tarsal coalition, posterior tibial tendon dysfunction, or spring ligament injury.

Flexor hallucis longus tendonitis is a common injury in ballet dancers. The flexor hallucis longus tendon travels posterior and lateral to the posterior tibial nerve. The tendon travels relatively deeply, and is usually best felt posterior to the medial malleolus while the patient wiggles the great toe.

The tarsal tunnel is the space posterior to the medial malleolus and medial to both the talus and the calcaneus (see Fig. 2). The posterior tibial nerve travels beneath the flexor retinaculum in this space, and can be impinged by many lesions, including scar tissue, varicose veins, and bone spurs. The radicular symptoms of tarsal tunnel syndrome can often be reproduced by a Tinel's test, in which the tunnel is percussed, or a Phalen's test, in which the tunnel region is placed under prolonged pressure by manually compressing the overlying soft tissue.

The first branch of the lateral plantar nerve (Baxter's nerve) can also be entrapped. The usual location of this entrapment is between the abductor hallucis and quadratus plantae muscles, just anterior to medial calcaneus (almost in line with the medial malleolus) (see Fig. 2). This condition usually presents with chronic medial heel pain, which is worse in the morning and with weight bearing, and which radiates to inferomedial heel and medial ankle. It is characterized by the absence of numbness.

Anterior hindfoot

The most medial of the anterior ankle tendons is the anterior tibialis tendon. Lateral to the anterior tibial tendon lie the extensor hallucis longus tendon, the deep peroneal nerve, the dorsalis pedis artery, the extensor digitorum longus tendon, and the peroneus tertius tendon. The anterior tibialis tendon is visible in most people, whereas the other tendons are only seen in leaner individuals. The tendons can be accentuated with resisted motions.

Plantar hindfoot

Plantar fasciitis is a common condition of the plantar hindfoot. The plantar fascia attaches broadly to the anterior calcaneus, deep under the plantar fat pad. On examination, the patient usually has a point of maximal tenderness at the anteromedial region of the calcaneus (see Fig. 4). The patient may also have pain along the proximal plantar fascia. The pain may be exacerbated by passive toe dorsiflexion or by having the patient tiptoe. By passively placing the foot and toes in maximal dorsiflexion, a patient who has plantar fasciitis may note irritation secondary to the windlass mechanism (Fig. 20) [43,44].

The plantar fat pad, which lies over the plantar aspect of the calcaneus, is an important structure in dissipating the forces of ambulation (see Fig. 4).

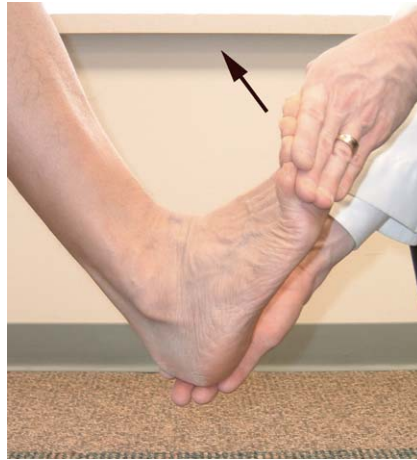

Fig. 20. Windlass mechanism stressing—the examiner maximally dorsiflexes the ankle and toes in the direction indicated by the black arrow.

Repetitive cortisone injections in this area can cause atrophy of this structure and lead to painful heel strike with ambulation. The plantar fat pad may also be injured by a direct blow, which causes a heel bruise. A calcaneal stress fracture should be considered in patients complaining of persistent heel pain. On examination, bony point tenderness, pain with lateral squeezing of the calcaneus, and pain reproduced with vibrations from a tuning fork or ultrasound may be found [40].

Examining the midfoot

Anterior tarsal tunnel syndrome presents with tingling over the dorsum of the foot to the web space between the first and second toes. Its cause is entrapment of the deep peroneal nerve under the extensor retinaculum (see Fig. 3). On examination, the patient may have a positive Tinel's test. A prominent navicular, which may appear to be a second ankle bone, is seen with navicular osteochondrosis (Köhler's condition), which is a disease of the ossification center characterized by osteonecrosis followed by recalcification, and with an accessory navicular (Fig. 21). Pain at the apex of the navicular, the N spot, is suspicious for a navicular stress fracture [45]. A Lisfranc sprain occurs most commonly at the joint between the proximal first metatarsal, second metatarsal, medial cuneiform, and intermediate cuneiform (see Fig. 3). On examination, the patient has localized tenderness, and may have some swelling. These sprains are best evaluated by ordering a weight-bearing foot radiograph series. Usually, the most obvious sign is malalignment of the medial border of the second metatarsal and the medial border of the intermediate cuneiform on the weight-bearing anteroposterior (AP) [46]. Secondary signs include separation of 2 mm or more between the

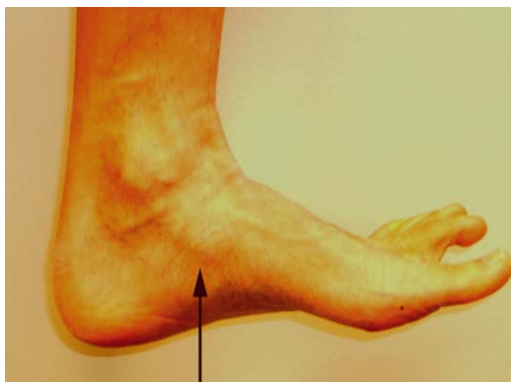

Fig. 21. “Second ankle bone” (*black arrow*), in this case from accessory navicular.

base of the first and the proximal second metatarsal on the AP, and a reversal of the normal relationship between the fifth metatarsal and the medial cuneiform. In a Lisfranc injury, the fifth metatarsal lies above the plantar surface of the medial cuneiform instead its normal position below it [46,47].

Plantar nerve entrapment may lead to medial arch pain, aching, decreased sensation, or chronic heel pain. The plantar nerve is most frequently entrapped at either the medial branch or the lateral branch (for lateral branch entrapment, see the medial hindfoot section of this article above). The medial plantar nerve entrapment occurs at the master knot of Henry and causes medial arch pain, especially with weight bearing. The master knot of Henry is located just distal to the navicular tuberosity where the flexor hallucis longus (FHL) and flexor digitorum longus (FDL) tendons cross (see Fig. 2). On examination, the patient may have a positive Tinel’s test. Passively everting the foot or having the patient stand on the toes may also reproduce the symptoms. Jogger’s foot is a variation in which irritation of the medial plantar nerve causes decreased sensation and aching in the medial plantar foot immediately after running.

Examining the forefoot and toes

Metatarsal fractures are common injuries of the forefoot. They can occur both traumatically and from overuse. The fractures usually cause bony point tenderness. One of the most common traumatic metatarsal fractures is an avulsion fracture of the base of the fifth metatarsal (see Figs. 1, 4). Common locations for overuse-related stress fractures are the distal third of the second and third metatarsals and the proximal fifth metatarsal (Jones fracture) (see Figs. 1, 3, and 4). Stress fractures may not be visible on initial plain radiographs [28]. Therefore, a high index of suspicion for stress

fracture needs to be maintained in individuals whose activities include repetitive impact loading of the foot. Most fractures of the foot heal well; however, the Jones fracture is at high risk for nonunion and requires prompt treatment and close observation (see the article elsewhere in this issue on common injuries and treatment of the foot).

A Morton's neuroma or interdigital neuroma is most often located between the third and fourth metatarsal heads (see Fig. 3). A squeeze test, or Morton's test, is done by pressing the first and fifth metatarsal heads together. A positive test reproduces the pain. Mulder's click is the palpable click that is sometimes felt by the observer during a squeeze test.

Metatarsal-phalangeal joint

Acquired anatomic deformities can affect range of motion and gait. They are often found in the great toe metatarsal-phalangeal (MTP) joint. The great toe normally has at least 70° of extension and 45° of flexion. Hallux rigidus is a loss of motion at the first MTP joint, which results in a gait with supination of the foot and walking on the lateral border of the foot. Loss of extension at the MTP joint is most critical from a functional standpoint; loss of interphalangeal motion is less problematic. Swelling at the first MTP is usually caused by a bunion, gout, or osteoarthritis. A bunion is a large soft-tissue and bony deformity at the first MTP joint, whereas hallux valgus describes the deviation of the great toe away from the midline of the first metatarsal axis by an angle greater than 15°. The pain of a bunion is usually caused by associated adventitial bursitis that appears with a swollen, tender, erythematous first MTP joint. A bunionette (tailor's bunion) is a similar lesion at the fifth MTP joint. Pain and swelling at the second MTP joint is usually caused by overuse synovitis or, much less often, by avascular necrosis of second MT head (Freiberg's infarction) (see Fig. 3). Pain on the plantar surface of the first MTP joint may be caused by sesamoiditis or sesamoid fracture (see Fig. 4). This pain may be aggravated by resisted flexion or maximally passive dorsiflexion of the great toe. Metatarsalgia will present with tenderness on the plantar aspect of the affected MTP joint (see Fig. 4).

Instability of the MTP joints may be tested by stabilizing the foot, grasping the proximal phalanx, and stressing the joint in dorsal and plantar directions (Fig. 22). Instability may represent chronic synovitis or claw-toe deformity [33]. Inability to actively spread or abduct the toes may represent the loss of intrinsic muscle function.

Toe deformities

A mallet toe is a deformity defined as chronic flexion of the distal interphalangeal (DIP) joint. A mallet toe is usually found in a single digit with callus on the dorsum of the DIP. A hammertoe is a deformity defined

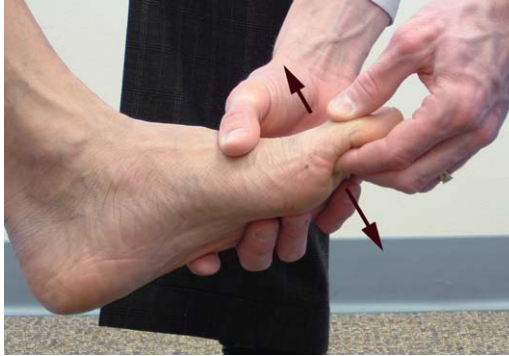

Fig. 22. Assessing MTP stability—the examiner stabilizes the foot, grasps the proximal phalanx, and places dorsal and plantar stresses on the MTP as indicated by the black arrows.

as hyperextension of the MTP and DIP joints and hyperflexion of the proximal interphalangeal (PIP) joint. A hammertoe is usually found in a single digit with callus on the dorsum of the PIP. A claw toe is defined as having the PIP and DIP joints flexed. When present, claw toe is usually found in multiple digits. Claw toes may be idiopathic, but are often adaptive changes to diseases such as Charcot-Marie-Tooth, rheumatoid arthritis, cavus foot deformities, or chronic rupture of Achilles tendon [33,41].

A toe fracture is usually caused by axial loading (eg, stubbing) or a crushing injury (eg, dropped object) [48]. Common physical findings include ecchymosis, swelling, and pain. On examination, the patient usually has bony point tenderness. Axial loading of the affected digit usually causes pain in the presence of a fracture [48].

Summary

The foot and ankle are critical components in our ability to ambulate. Injuries to either can significantly interfere with a patient's ability to carry out normal activities. In severe cases, they can be devastating to a patient's independence. Careful examination of the foot and ankle using established mechanical tests, along with understanding of the anatomy of the complex, is needed to confirm the history and to assist in the diagnosis and treatment of foot and ankle injuries.

The following points are key to clinical examination of the foot and ankle:

- The examination of the foot and ankle needs to be done with the patient in both weight-bearing and non-weight bearing positions.
- The examination of the foot and ankle should include an evaluation of the patient's gait.

- Reproduction of a patient's symptoms is the key to making a correct diagnosis.
- Although anatomic variants may predispose some individuals to injury, in general, if asymptomatic, no treatment should be done.

Acknowledgments

The authors would like to thank Chris McLaughlin and Sharon Busey, MD for their editorial help, and Amy Overlin, MD and Sharon Busey, MD for their help with the photography.

References

- [1] Lysholm J, Wiklander J. Injuries in runners. *Am J Sports Med* 1987;15(2):168–71.
- [2] Kannus VPA. Evaluation of abnormal biomechanics of the foot and ankle in athletes. *Br J Sports Med* 1992;26(2):83–9.
- [3] Shea M, Fileds KB. Plantar fasciitis. *Phys Sportsmed* 2001;30(7):21–5.
- [4] Gross MT. Lower quarter screening for skeletal malalignment—suggestions for orthotics and footwear. *J Orthop Sports Phys Ther* 1995;21(6):389–405.
- [5] Wilder RP, Sethi S. Overuse injuries: tendinopathies, stress fractures, compartment syndrome, and shin splints. *Clin Sports Med* 2004;23(1):55–81.
- [6] Epperly T, Fields KB. Epidemiology of running injuries. In: O'Connor FG, Wilder RP, editors. *Textbook of running medicine*. New York: McGraw-Hill; 2001. p. 3–9.
- [7] Wilder RP, O'Connor FG. Evaluation of the injured runner. In: O'Connor FG, Wilder RP, editors. *Textbook of running medicine*. New York: McGraw-Hill; 2001. p. 47–57.
- [8] Wen DY, Puffer JC, Schmalzried TP. Lower extremity alignment and risk of overuse injuries. *Med Sci Sports Exerc* 1997;29(10):1291–8.
- [9] Wen DY, Puffer JC, Schmalzried TP. Injuries in runners: a prospective study of alignment. *Clin J Sport Med* 1998;8(3):187–94.
- [10] Burns B, Maffuli N. Lower limb injuries in children in sports. *Clin Sports Med* 2000;19(4): 637–62.
- [11] Frey C. Footwear and stress fractures. *Clin Sports Med* 1997;16(2):249–57.
- [12] Simons SM. Foot injuries in the runner. In: O'Connor FG, Wilder RP, editors. *Textbook of running medicine*. New York: McGraw-Hill; 2001. p. 213–26.
- [13] Magee DJ. Lower leg, ankle, and foot. In: *Orthopedic physical assessment*. 3rd edition. Philadelphia: WB Saunders; 1997. p. 559–672.
- [14] Sutherland DS. Gait disorders in childhood and adolescence. In: Baltimore: Williams & Wilkens; 1984. p. 51–64.
- [15] Jenkins DB. Hollinshead's functional anatomy of the limbs and back. 6th edition. Philadelphia: W.B. Saunders; 1991.
- [16] Reid DC. Running: injury patterns and prevention. In: *Sports injury assessment and rehabilitation*. New York: Churchill Livingstone; 1992. p. 1131–58.
- [17] Niedfeldt MW, Young CC. Common foot problems in women. *Female Patient* 1998;23(9): 15–6; 18; 21–2; 24; 30–2.
- [18] Cook SD, Kester MA, Brunet ME, et al. Biomechanics of running shoe performance. *Clin Sports Med* 1985;4(4):619–26.
- [19] Parkkari J, Kujala UM, Kannus P. Is it possible to prevent sports injuries? Review of controlled trials and recommendations for future work. *Sports Med* 2001;31(4):985–95.
- [20] Robbins SE, Gouw GJ. Athletic footwear: unsafe due to perceptual illusions. *Med Sci Sports Exerc* 1991;23(2):217–24.

- [21] Robbins SE, Gouw GJ. Athletic footwear and chronic overloading. *Sports Med* 1990;9(2): 76–85.
- [22] Nigg BM. The role of impact forces and foot pronation: a new paradigm. *Clin J Sport Med* 2001;11(1):2–9.
- [23] Milgrom C, Giladi M, Kashtan H, et al. A prospective study of the effect of a shock absorbing orthotic device on the incidence of stress fractures in military recruits. *Foot Ankle* 1985;6(2):101–4.
- [24] Schwellonus MP, Jordan G, Noakes TD. Prevention of common overuse injuries by the use of shock absorbing insoles. *Am J Sports Med* 1990;18:636–41.
- [25] Gillespie WJ, Grant I. Interventions for preventing and treating stress fractures and stress reactions of bone of the lower limbs in young adults. *Cochrane Database of Syst Rev* 2004; (4):CD000450.
- [26] Finestone A, Giladi M, Elad H, et al. Prevention of stress fractures using custom biomechanical shoe orthoses. *Clinical Orthopaedics & Related Research* 1999;390:182–90.
- [27] Mundermann A, Stefanyshyn DJ, Nigg BM. Relationship between footwear comfort of shoe inserts and anthropometric and sensory factors. *Med Sci Sports Exerc* 2001;33(11):1939–45.
- [28] Beck BR, Matheson GO. Common stress fractures. *Clin Fam Practice* 1999;1(1):251–74.
- [29] Johnson JA. The running shoe. In: O'Connor FG, Wilder RP, editors. *Textbook of running medicine*. New York: McGraw-Hill; 2001. p. 589–94.
- [30] Lynch PJ. Eczematous diseases of the hands, feet and groin. In: *Dermatology for the house officer*. 2nd edition. Baltimore (MD): Williams & Wilkins; 1987. p. 268–77.
- [31] Weston WL, Lane AT. Dermatitis. In: *Color textbook of pediatric dermatology*. St. Louis (MO): Mosby Year Book; 1991. p. 26–40.
- [32] Omura EF, Rye B. Dermatologic disorders of the foot. *Clin Sports Med* 1994;13(4):825–41.
- [33] Pfeffer GB, Clain MR, Frey C, et al. Foot and ankle. In: Snider R, editor. *Essentials of musculoskeletal care*. 1st edition. Rosemont (IL): American Academy of Orthopaedic Surgeons; 1997. p. 366–489.
- [34] Liu SH, Jason WJ. Lateral ankle sprains and instability problems. *Clin Sports Med* 1994; 13(4):793–809.
- [35] Young CC: Ankle sprain. *eMedicine Journal* 2001;2(9). Available at: <http://www.emedicine.com/sports/topic6.htm>. Accessed April 3, 2004.
- [36] Pfeffer G. Foot and ankle. In: Greene WB, editor. *Essentials of musculoskeletal care*. 2nd edition. Rosemont (IL): American Academy of Orthopaedic Surgeons; 2001. p. 406–517.
- [37] Stiell IG, McKnight RD, Greenberg GH, et al. Decision rules for use of radiography in acute ankle injuries: refinement and prospective validation. *JAMA* 1993;269:1127–32.
- [38] Plint AC, Bulloch B, Osmond MH, et al. Validation of the Ottawa Ankle Rules in children with ankle injuries. *Acad Emerg Med* 1999;6(10):1005–9.
- [39] Leddy JJ, Smolinski RJ, Lawrence J, et al. Prospective evaluation of the Ottawa Ankle Rules in a university sports medicine center. With a modification to increase specificity for identifying malleolar fractures. *Am J Sports Med* 1998;26(2):158–65.
- [40] Mahaffey D, Hiltz M, Fields KB. Ankle and foot injuries in sports. *Clin Fam Practice* 1999; 1(1):233–50.
- [41] Brage ME, Reider B. Lower leg, foot, and ankle. In: Reider B, editor. *The orthopaedic physical examination*. Philadelphia: W.B. Saunders Company; 1999. p. 249–300.
- [42] Young CC, Niedfeldt MW. Achilles' tendinitis. In: Bracker MD, editor. *The 5-minute sports medicine consult*. Philadelphia: Lippincott, Williams & Wilkins; 2001. p. 4–5.
- [43] Young CC, Rutherford DS, Niedfeldt MW. Treatment of plantar fasciitis. *Am Fam Physician* 2001;63(3):467–74.
- [44] Young CC. Plantar fasciitis 2001. *eMedicine Journal* 2(9). Available at: <http://www.emedicine.com/sports/topic103.htm>. Accessed April 3, 2004.
- [45] Khan KM, Fuller PJ, Bruckner PD, et al. Outcome of conservative and surgical management of navicular stress fracture in athletes. *Am J Sports Med* 1992;20(6):657–66.

- [46] Mullen JE, O'Malley MJ. Sprains—residual instability of subtalar, Lisfranc joints, and turf toe. *Clin Sports Med* 2004;23(1):97–121.
- [47] Mantas JP, Burks RT. Lisfranc injuries in the athlete. *Clin Sports Med* 1994;13(4):719–30.
- [48] Hatch RL, Hacking S. Evaluation and management of toe fractures. *Am Fam Physician* 2003;68(12):2413–8.