

High-Grade Ductal Carcinoma In Situ: An Overview for the Radiologist

Luke J. Ballard, M.D.,¹ and Geneva R. Ballard M.D.²

¹Division of Breast Imaging, Wilford Hall Ambulatory Surgical Center, San Antonio, TX

²Department of Radiology, San Antonio Military Medical Center, San Antonio, TX

Introduction

Ductal carcinoma in situ (DCIS) is a common pre-invasive malignancy of the breast, representing approximately 20% of all breast cancer diagnoses.^{1,2} It is widely believed that DCIS is a precursor lesion to invasive ductal carcinoma, but the exact biologic nature is not completely understood and debated by some.³⁻⁵ DCIS is unarguably a heterogeneous disease with variable malignant potential. Evidence shows that high-grade DCIS is an aggressive subtype with an overall poorer prognosis than non-high-grade disease. There have been many studies evaluating the role of the radiologist in the diagnosis of high-grade DCIS with emphasis on radiologic-pathologic correlation using standard mammography and magnetic resonance imaging. Our current understanding of the clinical importance of high-grade DCIS from the perspective of a radiologist and characteristic imaging features are discussed in detail.

Clinical Implication of DCIS

The diagnosis of DCIS has increased dramatically over the last several decades from an incidence of less than 2 per 100,000 in the early 1970's to 32.5 in 2004.¹ Much of this increase has been attributed to the advent of screening mammography. Some advocates of screening see this as a victory, achieving one of the goals of a screening program: the prevention of life threatening invasive cancer by detection and treatment at the in situ stage.⁶ Detractors, however, believe the detection of DCIS leads to a substantial number of patients being over-diagnosed and over-treated for a non-life threatening condition.⁷ While large scale trials have shown survival benefit of screening mammography in the range of 30 percent, the screening debate goes on and is beyond the scope of this discussion.⁸⁻¹¹

Much of the controversy regarding the increase in diagnosis of DCIS over the years lies in our limited knowledge of the natural history of the disease. There

is little argument that DCIS is likely a precursor to invasive ductal carcinoma. However, it is very clear that some - but not all - of DCIS will progress over the lifetime of a patient. The evidence well summarized by Erbas et al. showed that 14-53% of DCIS misdiagnosed as benign will progress to invasive carcinoma over a 10-15 year interval.⁴ In a study by Sanders et al., low-grade DCIS progressed in 11 of 28 patients with most occurring within 10 years; 3 were diagnosed between 23 and 42 years after the initial biopsy; and 5 of 11 died of breast cancer.³

Autopsy studies suggest that a substantial number of DCIS cases may remain subclinical, although the interpretation and significance of these findings is debated.^{12,13} Papers such as these underscore the concept that some DCIS is effectively benign, but it remains evident that there is no way to prospectively determine if and when DCIS will progress to invasive disease. Moreover, the available data are not representative of the full spectrum of DCIS and largely exclude high-grade lesions. High-grade DCIS is rarely misdiagnosed pathologically and is routinely surgically excised, owing to the perceived malignant potential. This has allowed for very limited long-term observations.

In spite of the unknown, the overall prognosis for DCIS is excellent with appropriate surgical and oncologic management (approximately 98% long-term survival).¹⁴ DCIS is typically treated with wide surgical resection with or without radiation therapy; there is an evolving role for hormonal therapy.^{15,16} With a breast cancer specific mortality of less than 2%, it has proven difficult to demonstrate significant survival benefit with more advanced treatment options, such as radiation or hormonal therapy. This has led to considerable effort to stratify patients with a diagnosis of DCIS, based on the risk of local recurrences, as invasive recurrence (either local or systemic) appears to be the primary source of breast cancer specific mortality in these patients. Approximately half of patients with recurrence after breast conservation

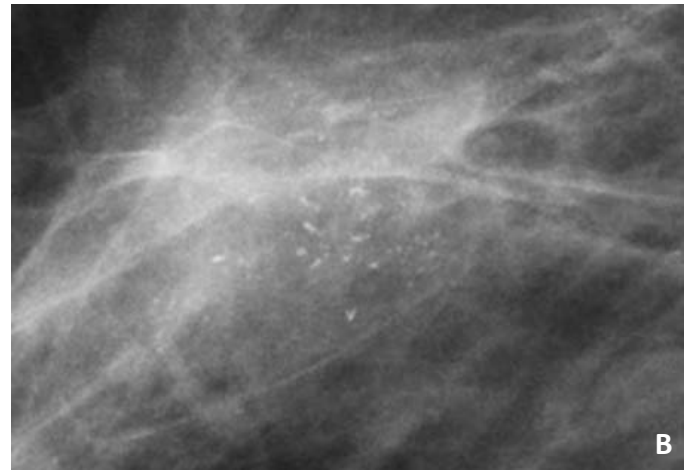
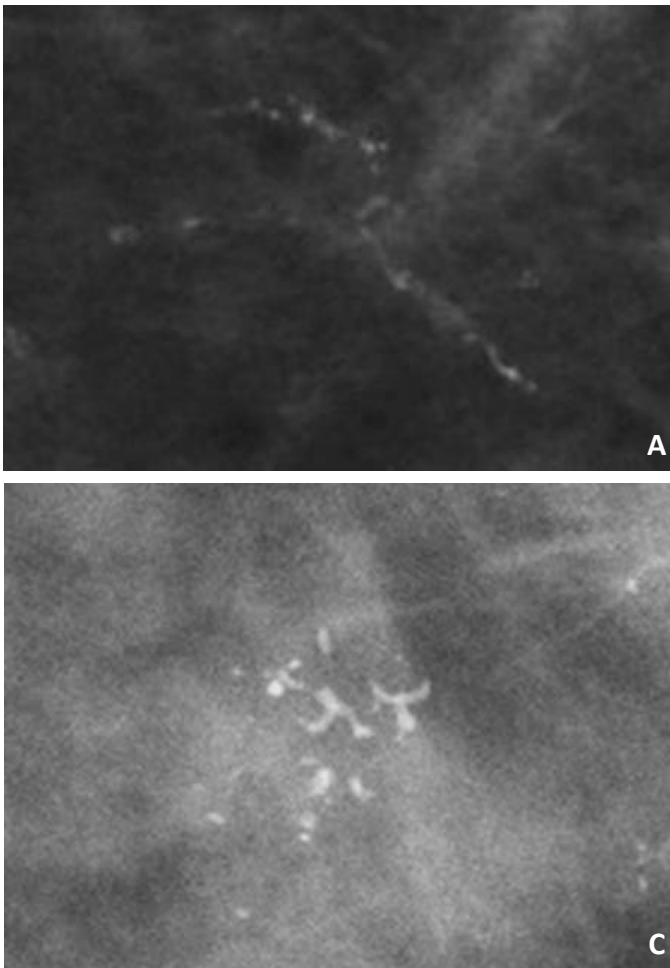


Figure 1. Examples of linear and branching calcifications in three cases of high-grade ductal carcinoma in situ. **(A)** shows classic casting type calcifications within a long ductal segment that has one major branch. **(B)** reveals a cluster of fine pleomorphic calcifications with several linear forms. **(C)** demonstrates casting calcifications forming branching shapes with additional adjacent pleomorphic calcifications.

surgery are diagnosed with invasive disease, and 12-15% of these patients ultimately die of breast cancer.^{17,18} While the overall prognosis for conservation therapy is good, the risk of recurrence or death is relatively negligible when DCIS is treated with mastectomy.^{18,19}

The pathologic evaluation of DCIS is one of the primary considerations in stratifying patients and has shifted from a purely architectural classification, which offered little prognostic information, to a focus on the nuclear grade and degree of cellular necrosis. This is reflected in the Van Nuys system which simply divides DCIS lesions into high-grade and non-high-grade; the latter group is further divided into those with or without necrosis.²⁰ Moreover, the Consensus Conference on Classification of Ductal Carcinoma In Situ (1997) recommends stratifying DCIS first by nuclear grade (high, intermediate, and low) and then determining the presence or absence of necrosis due to the potential treatment implications.¹⁶ The consensus reflects the current understanding of high-

grade DCIS as an aggressive subtype of DCIS with an overall poorer prognosis than non-high-grade disease. Analysis of the data has shown that a high nuclear grade may increase the risk of local recurrence after breast conservation therapy, shorten the time to recurrence, increase the rate of distant metastases, increase the rate of recurrence with invasion, and increase mortality with recurrent invasion.^{17,19-25} High-grade DCIS at core needle biopsy also appears to be a significant risk factor for underestimation of invasive breast cancer, a phenomena which occurs in approximately 25% of all DCIS diagnoses.²⁶

High-grade DCIS represents the majority of screening detected in situ lesions in multiple series, further emphasizing the importance of this diagnosis.²⁷⁻²⁹ Diagnosing high-grade DCIS represents a relatively frequent opportunity for radiologists to impact patient care. Thorough knowledge of the characteristic imaging features of high-grade DCIS, as well as the limitations of imaging, is imperative.

Mammography of High-Grade DCIS

Microcalcifications are found in an estimated 50-75% of all DCIS diagnosed on mammography and in approximately 90% of clinically occult DCIS.³⁰⁻³⁴ Radiologic-pathologic correlation has shown that these calcifications develop as a consequence of calcified intraluminal cellular debris secondary to a high concentration of calcium in adjacent necrotic cells and from ductal secretions, such as mucin or other calcific products.^{31,35}

Many studies have demonstrated a correlation between the type of mammographic calcification and the pathologic diagnosis, suggesting that certain calcification types are more likely to be associated with high-grade lesions at histopathology. Specifically, linear branching calcifications are generally predictive of high-grade DCIS (**Figure 1**).^{21, 36-38} These result from extensive intraluminal necrosis and calcifications which form “casts” of the ducts, yielding the characteristic linear branching pattern. A variety of mammographic descriptors have been used that with nuanced differences appear to be synonymous to linear branching calcifications, including “fine linear branching,” “casting,” and “comedo” calcification. The range of non-standardized microcalcification descriptors in the literature may indicate a measure of subjectivity in the analysis, although generally the differences can be reconciled.

While linear branching calcifications are characteristic of high-grade DCIS, the significance of this finding as a histologic predictor of disease is debated. High-grade DCIS appears to present with this finding in a majority of cases. In one study by Lee et al., 15 of 16 high-grade DCIS lesions presented with linear calcifications and showed excellent correlation.³⁶ In another study by Dinkel et al., 14 of 18 high-grade DCIS lesions showed linear calcifications. This pattern represented high-grade DCIS 56% of the time. Though this is the majority, compared with intermediate and low-grade DCIS, this was not a statistically significant result. The remaining 32% and 12% of linear calcifications represented intermediate and low-grade DCIS, respectively.³⁹ First evaluated by Tabar et al., multiple studies have provided evidence that casting calcifications import a poor prognosis when associated with small invasive cancers.^{38,40,41} Analysis shows that these casting calcifications consistently represent the presence of extensive high-grade DCIS (**Figure 2**).

Unfortunately, as the Dinkel study illustrates, there remains considerable overlap in the imaging appearance of not only different grades of DCIS but also between DCIS and benign processes, as high-grade DCIS is not confined to the linear branching pattern of calcifications. While this morphology has shown good positive predictive value for high-grade DCIS, other calcification patterns have not produced

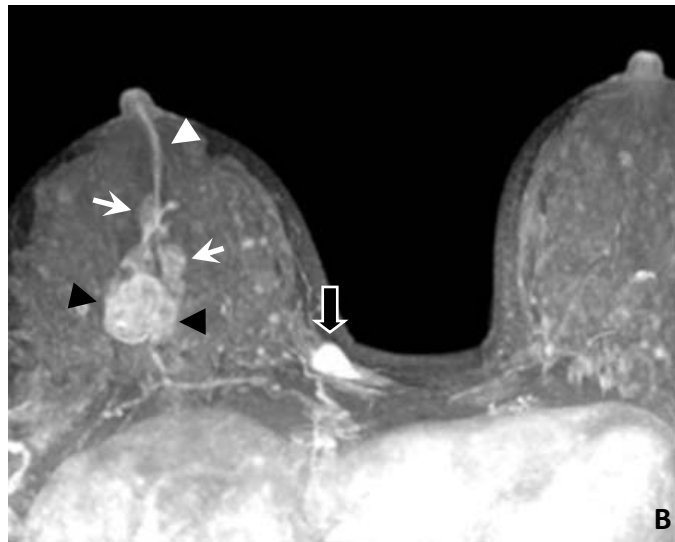
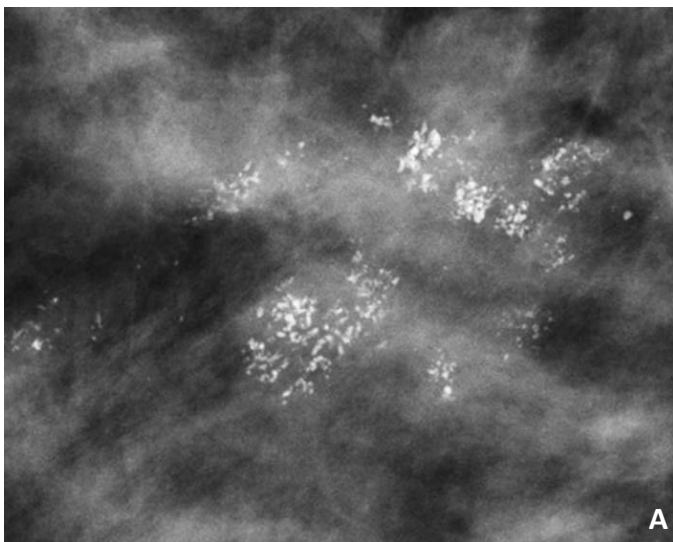


Figure 2. Ectopic Casting type calcifications. **(A)** shows casting calcifications in a segmental distribution, correspond to extensive high-grade DCIS. **(B)** MRI reveals corresponding clumped segmental non-mass-like enhancement (white arrows) in the right breast in association with a circumscribed 2 cm invasive malignancy posteriorly (black arrowheads), which was mammographically occult. This patient presented with bloody nipple discharge, corresponding to the linear ductal fluid signal (white arrowhead). A benign fibroadenoma was visualized in the medial right breast (open black arrow).

significant negative predictive values or correlation with low-grade disease that might be used to confidently reduce biopsy rates. Indeed, high-grade DCIS is seen with varying degree in all of the ACR BI-RADS suspicious calcification types, including amorphous or indistinct, coarse heterogeneous, and fine pleomorphic forms, though less frequently (**Figure 3**).^{30,36,37} The challenge for radiologists is most evident in early stages when high-grade DCIS lesions are small and more confined; the appearance of associated calcifications is often non-specific. Appropriate biopsy technique and sampling provide an opportunity to limit under-diagnosis in these situations.²⁶

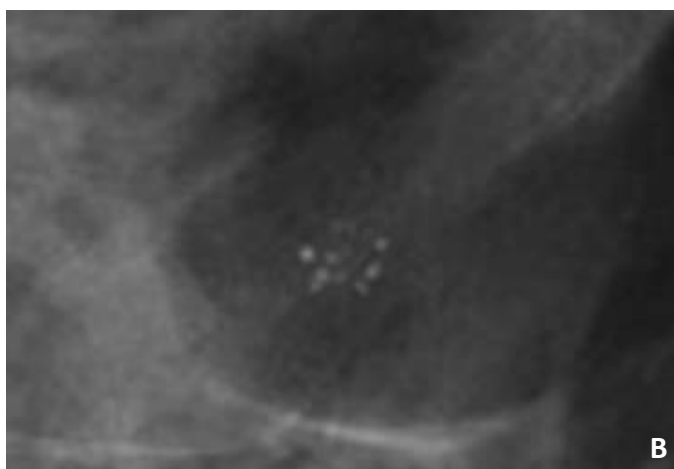
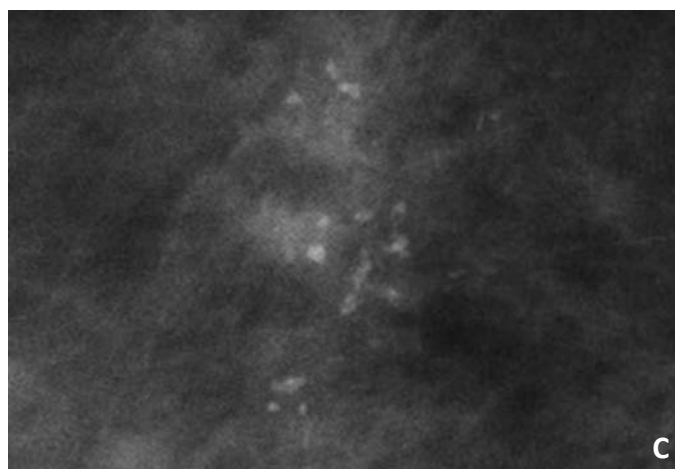
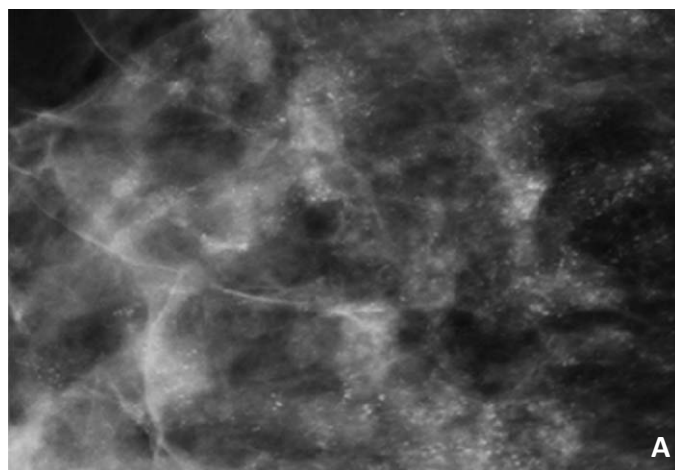
When not calcified, DCIS presents in numerous ways on mammograms, including masses, asymmetries, architectural distortion, and even as a negative exam.³² DCIS may present as a mass, either palpable or screen detected in up to 10% of cases of DCIS; this presentation is seen more commonly in low-grade lesions, rather than high-grade DCIS.^{42,43} Presentation

as a focal asymmetry may be especially challenging to radiologists when the finding is questionable, not seen with ultrasound, or difficult to localize stereotactically. Moreover, a negative mammogram may harbor DCIS, as demonstrated by occult cases identified only with the use of MRI. While such presentations are less common, it remains important to be aware that high-grade DCIS may present as a non-calcified mammographic abnormality.

Magnetic Resonance Imaging of High-Grade DCIS

The overall sensitivity of breast MRI for the detection of all grades of DCIS was previously considered to be relatively low with authors reporting various sensitivity data for DCIS as low as 77%.⁴⁴ However, with improved MRI techniques and high spatial resolution, as many as 98% of DCIS cases are now detectable by MRI with an additional 6-23% of mammographically occult DCIS lesions detectable only

Figure 3. Examples of high-grade ductal carcinoma of varying morphologies and distributions. **(A)** shows extensive amorphous calcifications in a regional distribution. **(B)** reveals a relatively innocuous looking cluster of pleomorphic calcifications with some round and punctuate forms. **(C)** demonstrates an example of fine pleomorphic and amorphous calcifications without clear linear forms.



by MRI.^{44,45} This is largely attributed to the enhancement of non-calcified DCIS which cannot be identified with a mammogram.⁴⁵

The most common MR imaging finding in DCIS falls under the category of “nonmasslike enhancement” (NMLE) and is demonstrated in 60-80% of cases.^{47,48} Though there is some variability in the literature regarding the exact descriptors, the NMLE seen with DCIS is typically in a segmental or linear distribution. Morakkabati-Spitz et al. demonstrated a positive predictive value of 34% and specificity of 96% for segmental and linear enhancement patterns.⁴⁹ The most commonly seen internal enhancement pattern among NMLE lesions associated with DCIS is clumped or heterogeneous enhancement (**Figure 4**).⁴⁸ Less commonly, purely DCIS lesions manifest as a mass (14-34%) or focal enhancement (1-12%).⁴⁴

The kinetic characteristics of pure DCIS lesions are more heterogenous and less predictive than those of invasive cancers, which are more likely to demonstrate early enhancement followed by rapid washout kinetics. The majority of pure DCIS lesions have rapid initial phase of enhancement in up to 77% of cases.^{46,48,50} The type of delayed enhancement is variably reported, but most commonly described as plateau or washout. Less often, DCIS lesions may demonstrate slow, progressive delayed enhancement (**Figure 5**). As with enhancing masses, a suspicious morphology, such as unilateral segmental or linear enhancement, will trump an associated benign appearing dynamic enhancement curve.

While one might expect that enhancement morphology and kinetics would reflect biologic behavior and by extension nuclear grade, there is no definitive evidence to suggest that either can be used to predict the presence of high-grade DCIS.^{46,48} When morphologic features of high-grade versus non-high-grade DCIS are compared, there is simply no statistical difference that would separate these categories.^{51,52} However, some potentially significant observations have been made regarding features of high-grade DCIS on MRI. High-grade DCIS appears to be more easily detected than low-grade, suggesting MRI may have a significant benefit in excluding high-grade disease with a negative exam.⁴⁹ Additionally, high-grade DCIS is significantly more likely to be detected with MRI than conventional mammography, with as many as 48% of high-grade cases detected with MRI alone.⁴⁵

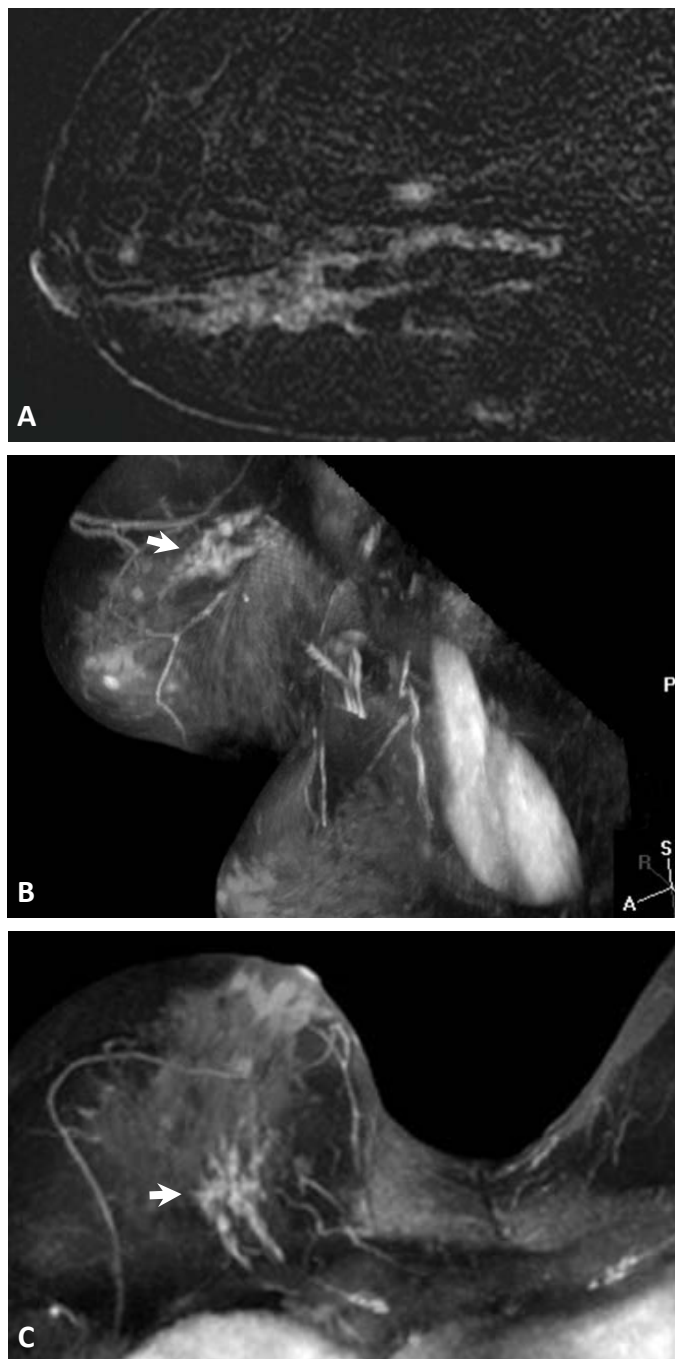


Figure 4. Clumped non-mass-like enhancement (NMLE) of high-grade DCIS. (A) Sagittal MR post-contrast subtraction image shows clumped, segmentally distributed NMLE in the mid to lower breast. (B) Craniocaudal and (C) axial post-contrast MIP images in a different patient with mammographically occult high-grade DCIS reveal asymmetric, clumped segmental enhancement (white arrows) in the upper inner breast. The orientation of the affected breast was positional, as it did not persist on the subsequent MRI guided biopsy.

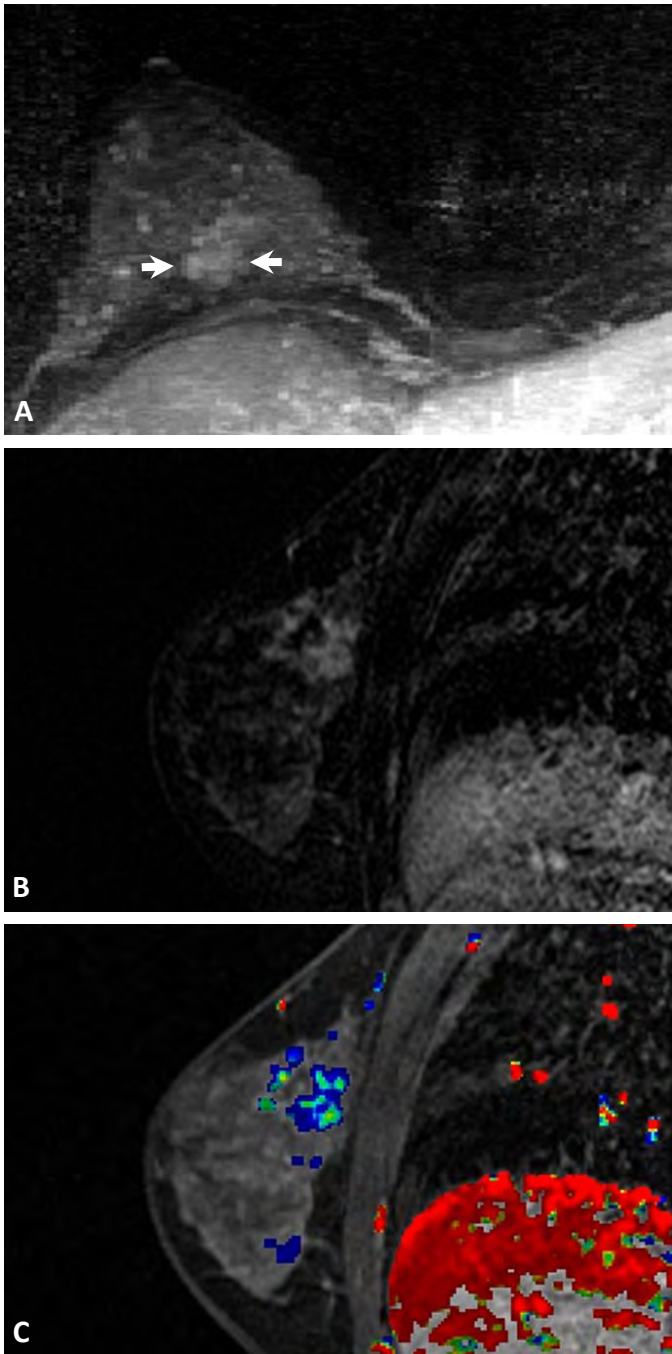


Figure 5. Variable MRI enhancement kinetics of DCIS. **(A)** axial MIP and **(B)** sagittal subtraction post-contrast images reveal clumped, segmental non-mass-like enhancement (white arrows) in the right upper inner breast. **(C)** Sagittal CAD overlay demonstrates mixed plateau and persistent delayed enhancement curves represented by the green and blue color coding, respectively.

Enhancement features of pure high-grade DCIS, including a focal branching pattern or irregular contour, may also be helpful in prospectively differentiating from pure invasive disease.⁵²

Summary

Overall, pure DCIS has an excellent prognosis; however, high-grade DCIS is an aggressive subtype with significantly greater morbidity and risk of mortality with recurrent invasive disease. Appropriate use of mammography and MRI affords radiologists an opportunity to identify this population and guide the most appropriate surgical and oncologic management based upon our current understanding of the disease. Research has extensively evaluated mammographic and MRI features of high-grade DCIS, and its appearances are well documented. Unfortunately, imaging currently shows little prospective value in cases of pure high-grade DCIS beyond the ability to make the initial diagnosis. Future research is necessary to determine the full impact of imaging patients with high-grade disease and to further define the best clinical treatment strategies.

The views expressed in this material are those of the author, and do not reflect the official policy or position of the U.S. Government, the Department of Defense, or the Department of the Air Force.

References

1. LVirnig BA, Tuttle TM, Shamliyan T, et al. Ductal Carcinoma In Situ of the Breast: A Systematic Review of Incidence, Treatment, and Outcomes. *J Natl Cancer Inst* 2010; 102: 170-178.
2. Brinton LA, Sherman ME, Carreon JD, et al. Recent Trends in Breast Cancer Among Younger Women in the United States. *J Natl Cancer Inst* 2008; 100: 1643-1648.
3. Sanders ME, Schuyler PA, Dupont WD, et al. The Natural History of Low-Grade Ductal Carcinoma in Situ of the Breast in Women Treated by Biopsy Only Revealed Over 30 Years of Long-Term Follow-Up. *Cancer* 2005; 103: 2481-4.
4. Erbas B, Provenzano E, Armes J, et al. The natural history of ductal carcinoma in situ of the breast: a review. *Breast Cancer Res Treat* 2006; 97: 135-144.
5. Espina V, Liotta LA. What is the malignant nature of human ductal carcinoma in situ? *Nat Rev Cancer* 2011; 11: 68-75.
6. Cady B, Chung MA. Preventing Invasive Breast Cancer. *Cancer* 2011 Jul 15; 117(14): 3064-8.
7. Welch GH, Woloshin S, Schwartz LM. The sea of uncertainty surrounding ductal carcinoma in situ—the price of screening mammography. *J Natl Cancer Inst* 2008; 100: 228-9.
8. Tabár L, Vitak B, Chen TH, Yen AM, et al. Swedish two-county trial: impact of mammographic screening on breast cancer mortality during 3 decades. *Radiology*. 2011 Sep; 260(3):658-63. Epub 2011 Jun 28.
9. Hellquist BN, Duffy SW, Abdsaleh S, et al. Effectiveness of population-based service screening with mammography for women ages 40 to 49 years: evaluation of the Swedish Mammography Screening in Young Women (SCRY) cohort. *Cancer*. 2011 Feb 15; 117(4): 714-22. Epub 2010 Sep 29.
10. Kopans DB, Smith RA, Duffy SW. Mammographic Screening and “Overdiagnosis”. *Radiology* 2011; 260: 616-620.
11. Jørgensen KJ, Keen JD, Gøtzsche PC. Is Mammographic Screening Justifiable Considering Its Substantial Overdiagnosis and Minor Effect on Mortality? *Radiology* 2011; 260: 621-627.
12. Welch HG, Black WC. Using Autopsy Series To Estimate the Disease “Reservoir” for Ductal Carcinoma in Situ of the Breast: How Much More Breast Cancer Can We Find? *Ann Intern Med* 1997; 127: 1023-1028.
13. Kopans DB, Rafferty E, Georgian-Smith D, et al. A Simple Model of Breast Carcinoma Growth May Provide Explanations for Observations of Apparently Complex Phenomena. *Cancer* 2003; 97: 2951-2959.
14. Ernster VL, Barclay J, Kerlikowske K, et al. Mortality Among Women With Ductal Carcinoma In Situ of the Breast in the Population-Based Surveillance, Epidemiology and End Results Program. *Arch Intern Med* 2000; 160: 953-958.
15. Zujewski JA, Harlan LC, Morrell DM, et al. Ductal carcinoma in situ: trends in treatment over time in the US. *Breast Cancer Res Treat* 2011; 127:251-257.
16. Schwartz GF, Solin LJ, Olivetto IA, et al. Consensus Conference of the Treatment of In Situ Ductal Carcinoma of the Breast, April 22-25, 1999. *Cancer* 2000; 88: 946-954.
17. Lee LA, Silverstein MJ, Chung CT, et al. Breast cancer-specific mortality after invasive local recurrence in patients with ductal carcinoma-in-situ of the breast. *Am J Surg* 2006; 192: 416-419.
18. Romero L, Klein L, Ye W, et al. Outcome after invasive recurrence in patients with ductal carcinoma in situ of the breast. *Am J Surg* 2004; 188: 371-376.
19. Silverstein MJ, Barth A, Poller DN, et al. Prognostic classification of breast DCIS; Ten-year results comparing mastectomy to excision and radiation therapy for ductal carcinoma in situ of the breast. *European Journal of Cancer* 1995; 31:1425-7.
20. Silverstein MJ, Poller DN, Waisman JR, et al. Prognostic classification of breast ductal carcinoma-in-situ. *Lancet* 1995; 345:1154-57.
21. Lagios MD, Margolin FR, Westdahl PR, et al. Mammographically detected duct carcinoma in situ. Frequency of local recurrence following tylectomy and prognostic effect of nuclear grade on local recurrence. *Cancer* 1989; 63: 619–24.
22. Bijker N, Meijnen P, Peterse JL, et al. Breast-conserving treatment with or without radiotherapy in ductal carcinoma-in-situ: ten-year results of European Organisation for Research and Treatment of Cancer randomized phase III trial 10853—a study by the EORTC Breast Cancer Cooperative Group and EORTC Radiotherapy Group. *J Clin Oncol* 2006; 24:3381-7.
23. Hetelekidis S, Collins L, Silver B, et al. Predictors of local recurrence following excision alone for ductal carcinoma in situ. *Cancer* 1999; 85(2):427-31.
24. Holmes P, Lloyd J, Chervoneval, et al. Prognostic markers and long-term outcomes in ductal carcinoma in situ of the breast treated with excision alone. *Cancer* 2011; 117: 3650-7.
25. Schnitt SJ. Local outcomes in ductal carcinoma in situ based on patient and tumor characteristics. *J Natl Cancer Inst Monogr* 2010; 2010: 158-61.
26. Brennan ME, Turner RM, Ciatto S, et al. Ductal carcinoma in situ at core-needle biopsy: meta-analysis of underestimation and predictors of invasive breast cancer. *Radiology* 2011; 260:119-28.
27. Evans AJ, Pinder SE, Ellis IO, et al. Screen detected ductal carcinoma in situ (DCIS): overdiagnosis or an obligate precursor of invasive disease? *J Med Screen* 2001; 8: 149-51.
28. Kessar P, Perry N, Vinnicombe SJ, et al. How significant is detection of ductal carcinoma in situ in a breast screening programme? *Clin Radiol* 2002; 57: 807-14.
29. Kricke A, Goumas C, Armstrong B. Ductal carcinoma in situ of the breast, a population-based study of epidemiology and pathology. *Br J Cancer* 2004; 90:1382-5.
30. Barreau B, de Mascarel I, Feuga C, et al. Mammography of ductal carcinoma in situ of the breast: review of 909 cases with radiographic-pathologic correlations. *Eur J Radiol* 2005; 54: 55-61.
31. Stomper PC, Connolly JL, Meyer JE, et al. Clinically occult ductal carcinoma in situ detected with mammography: analysis of 100 cases with radiologic-pathologic correlation. *Radiology* 1989; 172: 235-41.
32. Ikeda DM, Anderson I. Ductal Carcinoma in Situ: Atypical Mammographic Appearances. *Radiology* 1989; 172: 661-666.
33. Ciatto S, Cataliotti L, Distanti V. Nonpalpable lesions detected with mammography: review of 512 consecutive cases. *Radiology* 1987; 165: 99-102.

34. Hall FM, Storella JM, Silverstone DZ, et al. Nonpalpable breast lesions: recommendations for biopsy based on suspicion of carcinoma at mammography. *Radiology* 1988; 167: 353-8.
35. Egan RL, McSweeney MB, Sewell CW. Intramammary calcifications without an associated mass in benign and malignant diseases. *Radiology* 1980; 137: 1-7.
36. Lee KS, Han BH, Chun YK, et al. Correlation between mammographic manifestations and averaged histopathologic nuclear grade using prognosis-predict scoring system for the prognosis of ductal carcinoma in situ. *Clin Imaging* 1999; 23: 339-46.
37. Holland R, Hendriks JH. Microcalcifications associated with ductal carcinoma in situ: mammographic-pathologic correlation. *Semin Diagn Pathol* 1994; 11: 181-192.
38. Tabar L, Tony Chen HH, Amy Yen MF, et al. Mammographic tumor features can predict long-term outcomes reliably in women with 1-14-mm invasive breast carcinoma. *Cancer* 2004; 101: 1745-59.
39. Dinkel HP, Gassel AM, Tschammler A. Is the appearance of microcalcifications on mammography useful in predicting histological grade of malignancy in ductal cancer in situ? *Br J Radiol* 2000; 73: 938-44.
40. Zunzunegui RG, Chung MA, Oruwari J, et al. Casting-type calcifications with invasion and high-grade ductal carcinoma in situ: a more aggressive disease? *Arch Surg* 2003; 138: 537-40.
41. Pálka I, Ormándi K, Gaál S, et al. Casting-type calcifications on the mammogram suggest a higher probability of early relapse and death among high-risk breast cancer patients. *Acta Oncol* 2007; 46: 1178-83.
42. Evans A, Pinder S, Wilson R, et al. Ductal carcinoma in situ of the breast: correlation between mammographic and pathologic findings. *Am J Roentgenol* 1994; 162: 1307-11.
43. Yang WT, Tse GM. Sonographic, mammographic, and histopathologic correlation of symptomatic ductal carcinoma in situ. *Am J Roentgenol* 2004; 182: 101-10.
44. Yamada T, Mori N, Watanabe M, et al. Radiologic-pathologic correlation of ductal carcinoma in situ. *Radiographics* 2010; 30: 1183-98.
45. Kuhl CK, Schrading S, Bieling HB, et al. MRI for diagnosis of pure ductal carcinoma in situ: a prospective observational study. *Lancet* 2007; 370: 485-92.
46. Kim JA, Son EJ, Youk JH, et al. MRI findings of pure ductal carcinoma in situ: kinetic characteristics compared according to lesion type and histopathologic factors. *Am J Roentgenol* 2011; 196: 1450-6.
47. Rosen EL, Smith-Foley SA, DeMartini WB, et al. BI-RADS MRI enhancement characteristics of ductal carcinoma in situ. *Breast J* 2007; 13: 545-550.
48. Jansen SA, Newstead GM, Abe H, Shimauchi et al. Pure ductal carcinoma in situ: kinetic and morphologic MR characteristics compared with mammographic appearance and nuclear grade. *Radiology* 2007; 245: 684-91.
49. Morakkabati-Spitz N, Leutner C, Schild H, et al. Diagnostic usefulness of segmental and linear enhancement in dynamic breast MRI. *Eur Radiol* 2005; 15: 2010-7.
50. Neubauer H, Li M, Kuehne-Heid R, et al. High grade and non-high grade ductal carcinoma in situ on dynamic MR mammography: characteristic findings for signal increase and morphological pattern of enhancement. *Br J Radiol* 2003; 76: 3-12.
51. Viehweg P, Lampe D, Buchmann J, et al. In situ and minimally invasive breast cancer: morphologic and kinetic features on contrast-enhanced MR imaging. *MAGMA* 2000; 11: 129-37.
52. Groves AM, Warren RM, Godward S, et al. Characterization of pure high-grade DCIS on magnetic resonance imaging using the evolving breast MR lexicon terminology: can it be differentiated from pure invasive disease? *Magn Reson Imaging*. 2005 Jul; 23(6): 733-8.