

Clinical Experience With a Novel Multielectrode Basket Catheter in Right Atrial Tachycardias

Claus Schmitt, MD; Bernhard Zrenner, MD; Michael Schneider, MD; Martin Karch, MD;
Gjin Ndrepepa, MD; Isabel Deisenhofer, MD; Sonja Weyerbrock, MD;
Jürgen Schreieck, MD; Albert Schömig, MD

Background—The complexity of atrial tachycardias (ATs) makes the electroanatomic characterization of the arrhythmogenic substrate difficult with conventional mapping techniques. The aim of our study was to evaluate possible advantages of a novel multielectrode basket catheter (MBC) in patients with AT.

Methods and Results—In 31 patients with AT, an MBC composed of 64 electrodes was deployed in the right atrium (RA). The possibility of deployment, spatial relations between MBC and RA, MBC recording and pacing capabilities, mapping performance, and MBC-guided ablation were assessed. MBC deployment was possible in all 31 patients. The MBC was left in the RA for 175 ± 44 minutes. Stable bipolar electrograms were recorded in $88 \pm 4\%$ of electrodes. Pacing from bipoles was possible in $64 \pm 5\%$ of electrode pairs. The earliest activity intervals, in relation to P-wave onset, measured from the MBC and standard roving catheters were 41 ± 9 and 46 ± 6 ms, respectively ($P=0.21$). Radiofrequency ablation was successful in 15 (94%) of 16 patients in whom it was attempted, including 2 patients with polymorphic right atrial tachycardia (RAT), 2 with RAT–atrial flutter combination, 1 with macroreentrant AT, and 1 with focal origin of atrial fibrillation.

Conclusions—These data demonstrate that MBC can be used safely in patients with right atrial arrhythmias. The simultaneous multielectrode mapping aids in the rapid identification of sites of origin of the AT and facilitates radiofrequency ablation procedures. The technique is especially effective for complex atrial arrhythmias. (*Circulation*. 1999;99:2414-2422.)

Key Words: tachycardia ■ catheters ■ mapping ■ catheter ablation

Experimental high-density mapping systems^{1–3} that allow simultaneous rapid acquisition of numerous electrical signals generated by a selected surface area or volume of myocardium are not commonly available to clinical electrophysiologists. Currently available mapping techniques usually use standard electrophysiological catheters with a limited number of electrodes, which are sequentially steered to selected endocardial sites to record local electrical activity or to perform cardiac pacing. Activation sequence mapping with current techniques is time consuming, technically difficult, not reproducible, and not suitable for hemodynamically unstable patients or short-lived generated arrhythmias.^{4,5}

Recently, to overcome these setbacks in mapping methodology, several new multielectrode catheters^{6–9} and new mapping techniques^{10–13} have emerged. One type of these new catheters represents an expandable multielectrode basket catheter (MBC) that can be delivered to the endocardial surface by a standard percutaneous catheterization technique.^{10–12} MBCs are used primarily in experimental models

in animals.^{7–9,14} Clinical use of MBCs in humans is still very limited.^{15–18}

The aim of our study was to evaluate the feasibility, safety, and efficacy of the use of a novel multielectrode basket mapping catheter in patients with atrial tachycardia (AT).

Methods

Patient Population

The study population consisted of 31 patients with AT (16 men, 15 women) who were referred for electrophysiological study at Deutsches Herzzentrum München during a period of time from July 1996 until June 1998. Mean patient age was 52.8 ± 19 years (range, 19 to 78 years). The underlying heart disease was dilated cardiomyopathy in 7 patients, coronary artery disease in 5, obstructive hypertrophic cardiomyopathy in 2, myocarditis in 1, and sarcoidosis in 1. Arterial hypertension was found in 9 patients, and no clinically detectable structural heart disease was found in the remaining 6 patients. The mean duration of arrhythmia was 2.5 ± 2.2 years (range, 3 months to 10 years). All patients used 1 to 3 antiarrhythmic drugs (median, 2) to control arrhythmia before ablation. Palpitations and dyspnea were

Received August 12, 1998; revision received January 12, 1999; accepted February 16, 1999.

From Deutsches Herzzentrum München and I Medizinische Klinik, Klinikum rechts der Isar, Technische Universität München, Munich, Germany.

Presented in part at the 70th Scientific Sessions of the American Heart Association, Orlando, Fla, November 9–12, 1997, and published in abstract form (*Circulation*. 1997;96[suppl I]:I-586).

Correspondence to Claus Schmitt, MD, Deutsches Herzzentrum München, Lazarettstrasse 36, D-80636 München, Germany. E-mail schmitt@dhm.mhn.de

© 1999 American Heart Association, Inc.

Circulation is available at <http://www.circulationaha.org>

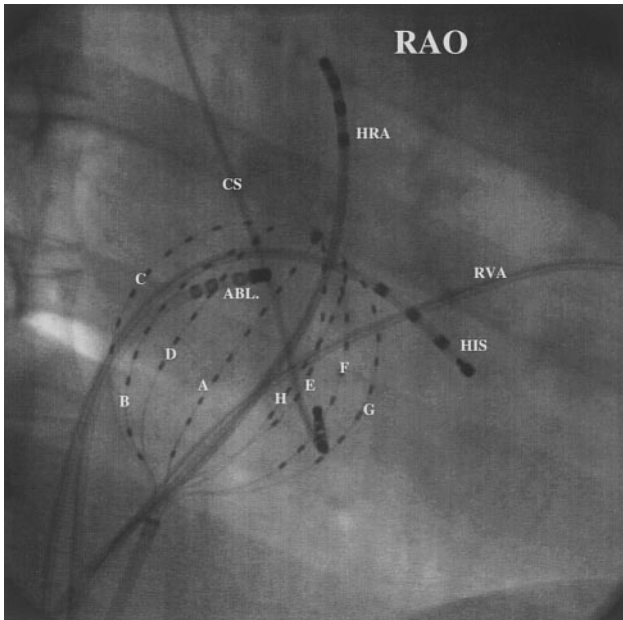


Figure 1. Fluoroscopic appearance (RAO 30°) of MBC and other standard catheters in RA. Letters A to H identify basket splines. ABL indicates ablation catheter; CS, HIS, HRA, and RVA indicate standard catheters placed in coronary sinus, His bundle region, high RA, and right ventricular apex, respectively.

the main presenting symptoms. Of the 31 patients, 20 had incessant AT. Syncopal attacks occurred in 4 patients.

All patients had ECG documentation of spontaneous episodes. All patients underwent an initial evaluation that included history, physical examination, ECG, 24-hour ECG monitoring, radiographic examination, and 2-dimensional echocardiography with color Doppler flow analysis. The definition of AT diagnosis was made on the basis of well-accepted criteria.^{19,20}

Electrophysiological Study and MBC Deployment

All patients underwent electrophysiological study in the fasting postabsorptive state after the procedure was explained to them and written consent was obtained from them. Antiarrhythmic drugs were discontinued ≥ 5 half-lives before the study. Patients were mildly sedated with midazolam (1 to 2 mg IV).

After echocardiographic estimation of RA dimensions, with the patient under local anesthesia, an 11F sheath was intravenously inserted in the right or left femoral vein and positioned at the RA via a pigtail catheter. The pigtail catheter was withdrawn, and the collapsed MBC (Constellation, EPT) was advanced past the distal end of the sheath, which was then pulled back into the inferior vena cava. The MBC (Figure 1) was composed of 64 electrodes mounted on 8 flexible, self-expanding nitinol splines (each spline carrying 8 platinum-iridium ring electrodes). The electrodes were equally spaced 4 or 5 mm apart depending on the size of the MBC used (with diameters of 48 or 60 mm, respectively). Each spline was identified by a letter (from A to H) and each electrode by a number (from 1 to 8, with electrode 1 having the cranial position on the splines). Electric-anatomic relations were determined by 1 of the following criteria: (1) fluoroscopically identifiable markers were mounted on splines A and B (1 marker on spline A and 2 on spline B in the proximal position) or (2) the recording of the His bundle on a particular spline served as a landmark for the position of the other splines. Once deployed, the MBC was not further manipulated. Final positions were documented with cinefluorograms taken in the right anterior oblique (RAO; 30°) and left anterior oblique (LAO; 40°) views. Of 64 platinum-iridium electrodes, 56 bipolar electrograms were derived (by combining electrodes 1 and 2, 2 and 3, etc, until 7 and 8 electrodes were on each spline).

After MBC deployment, the conventional catheters were introduced and positioned in standard positions inside the right heart and coronary sinus. A 5F decapolar electrode catheter (Medtronic, Inc) with an interelectrode distance of 2 mm and 10-mm spacing between electrode pairs was inserted percutaneously into the right internal jugular vein and positioned into the coronary sinus. Quadripolar catheters (BARD) with 5-mm interelectrode distance were advanced from the left femoral vein to the right ventricular apex and across the tricuspid valve for recording of His bundle potential. All intracardiac electrograms and surface leads I, II, aVF, and V_1 were simultaneously acquired (BARD LabSystem). Intracardiac electrograms were amplified, digitized at 1000 Hz, filtered (30 to 500 Hz), and recorded on an optical disk. A 12-lead surface ECG was available throughout the procedure. Anticoagulation was performed by bolus administration of 5000 IU of heparin, followed by continuous intravenous heparin infusion at an infusion rate of 1000 IU/h to maintain activated clotting time between 200 and 350 seconds. Before the MBC was removed, the sheath was readvanced over the basket to collapse it.

Spatial relations between basket splines and the right atrial endocardial contour were determined by contrast injection into the right atrium (RA) (through the sheath placed in the jugular vein) and the coronary sinus (via an Amplatz catheter). Cinefluorograms were taken in anteroposterior and lateral views.

Intracardiac Mapping

All 56 MBC electrograms or selected electrograms were displayed and combined with other electrograms depending on the stage of the study or the zone of interest. The local activity in bipolar electrograms was taken as the first rapid deflection that crossed the isoelectric line. The earliest activity interval was measured from the beginning of activity in any of the MBC recordings to the beginning of the P wave on the surface ECG. The ablation catheter was placed in the region of earliest activity, and the local electrogram was recorded from the distal poles. Beat-to-beat changes in the zone of earliest electrical activity associated with changes in right AT (RAT) activation sequences were considered diagnostic criteria for multifocal AT. Tachycardias with different but monomorphic morphologies observed or induced in the same patient were considered polymorphic. We differentiated left atrial tachycardias (LATs) by comparing local activities recorded in the coronary sinus and MBC. If atrial activity recorded in the coronary sinus preceded all atrial activities recorded on the MBC, the diagnosis of LAT was established.

The electrical stimulation (Biotronik 2000) was performed with a switch box (EPT) that allowed rapid selection of each electrode pair anywhere on the MBC. If tachycardia was not induced or was not sustained, isoproterenol was infused starting with a dose of 0.5 $\mu\text{g}/\text{min}$, with dose increases until the heart rate increased by 30% or tachycardia developed spontaneously or with electrical stimulation.

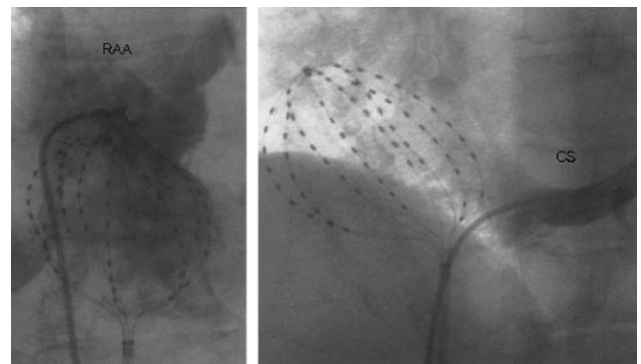


Figure 2. Left, Application of contrast dye in RA appendage (RAA; anteroposterior view) and right (LAO 40°) in coronary sinus (CS) to demonstrate the relationship of MBC with RA contour via an Amplatz catheter.

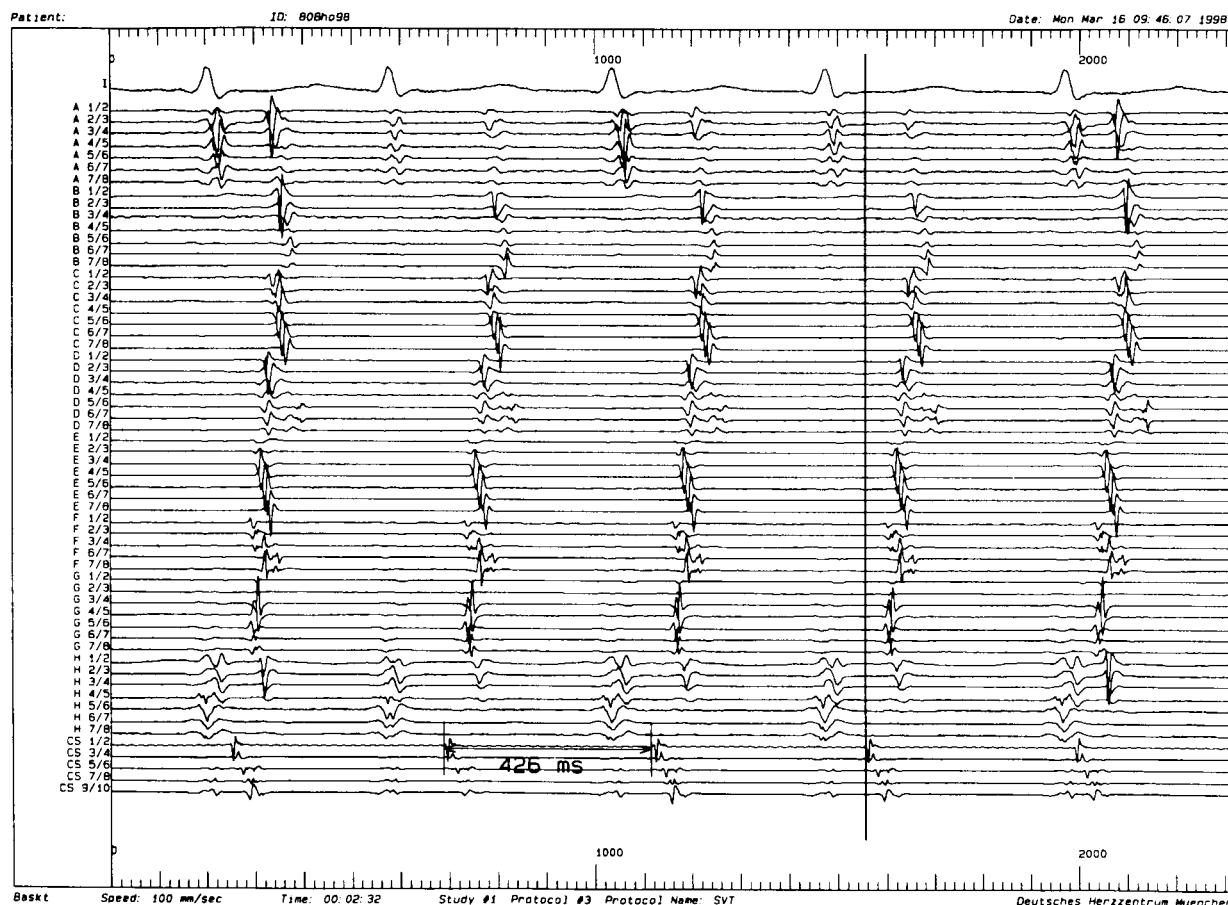


Figure 3. Simultaneous recordings of surface ECG lead I, bipolar electrograms from MBC, and 5 bipolar electrograms from coronary sinus (CS) in patient with LAT. Earliest electrical activity is recorded in coronary sinus electrograms well before electrical activity from MBC.

Radiofrequency Ablation Procedure

The mapping-ablation catheter (RF Marinr, Medtronic, Inc, or Blazer, EPT) was moved inside the RA under fluoroscopic control to the spline with the earliest atrial activity. Radiofrequency energy was delivered as an unmodulated radiofrequency current at a frequency of 550 kHz between the tip of the catheter and a skin patch placed under the left shoulder for ≤ 60 seconds at a preset temperature mode (preset temperature, 70°C).

Statistical Analysis

Data are presented as percentage, range, or mean \pm SD. The 2-tailed Student's *t* test for unpaired data was used to test for statistical difference. We performed linear regression analysis by calculating the Pearson correlation coefficient. Differences were considered significant at a *P* value < 0.05 .

Results

Feasibility and Safety of MBC Application

The MBC was inserted successfully in all 31 patients. Time needed for MBC deployment was almost identical to that needed for a standard sheath (2 to 3 minutes), with a small amount of additional time spent to advance the basket catheter through the sheath lumen. The MBC did not hinder the placement or manipulation of other mapping or ablation catheters. No electrical irritability was observed during or after insertion of the MBC. The MBC was left in the RA for 175 ± 44 minutes (range, 87 to 245 minutes).

Stability of MBC Recordings and Complications

The MBC maintained good electrical contact during the cardiorespiratory cycle. Stable electrograms could be recorded in $88 \pm 4\%$ of electrode pairs, whereas bipolar pacing (with rectangular pulses up to 10 V) was possible in $64 \pm 5\%$ of bipoles. His bundle potential was recorded in 12 patients (40%). Application of contrast dye after MBC placement revealed that the isthmus region, the atrial appendage, and, depending on how far the basket catheter was advanced, the region around the superior vena cava did not show tight wall contact with the splines (Figure 2). Patients expressed no additional sensations or complaints related to MBC deployment compared with those of a standard electrophysiological study. No complications related to MBC deployment or MBC-guided ablation occurred in the study population. Close inspection of the splines after removal revealed no thrombotic material or mechanical or ablation-related damage in any of the MBC components.

Right Atrial Tachycardias

In 21 (70%) of 31 patients with ECG-documented spontaneous ATs, the site of origin was within the RA. The locations of successfully ablated arrhythmia foci were as follows: base of RA appendage in 4 patients, lateral region in 9 patients (high, 3 patients; mid, 4 patients; and low, 2 patients), low posterolateral region in 3 patients, and low septal region (near

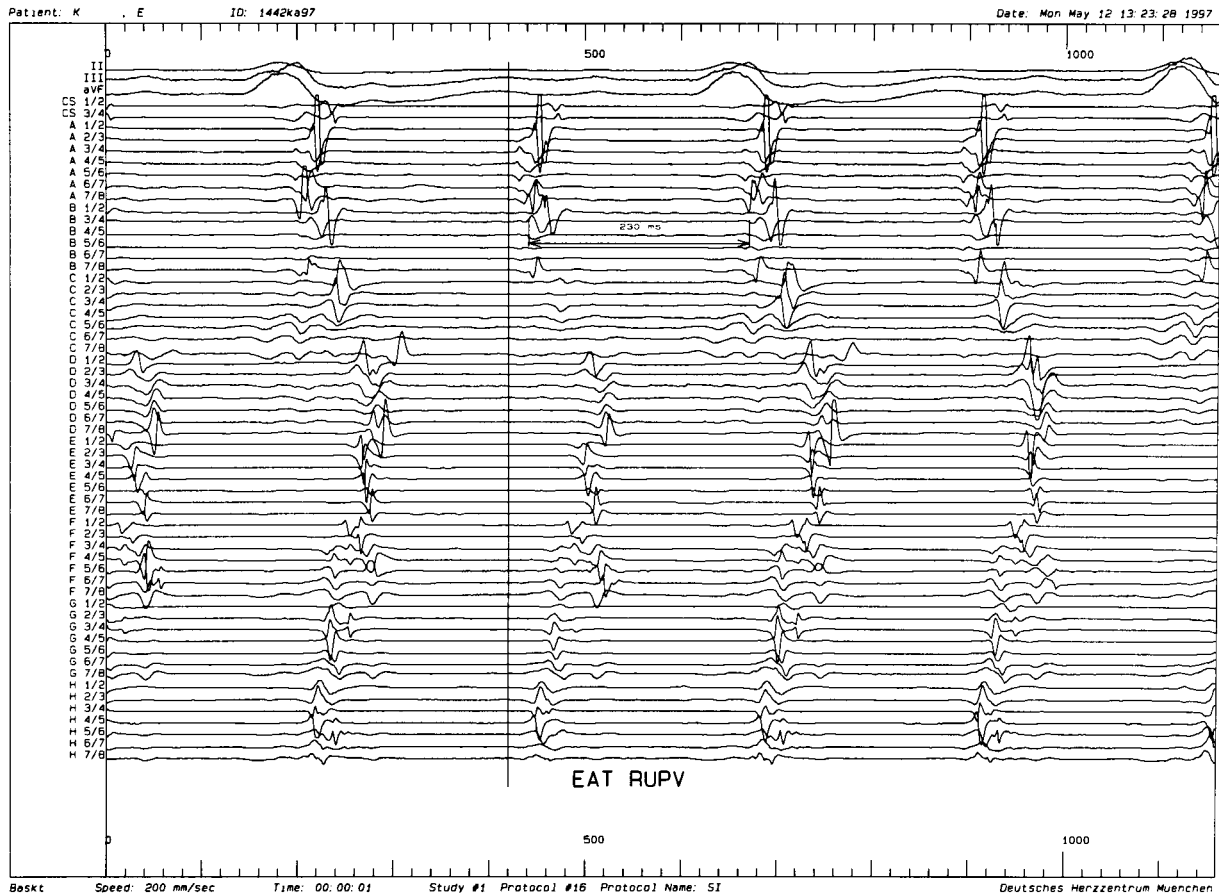


Figure 4. Ectopic atrial tachycardia (EAT) originating in right upper pulmonary vein region (RUPV). Earliest activity is recorded in spline A, which corresponds to high posteroseptal region of RA. Ablation of arrhythmia was achieved only through left-sided approach after transseptal catheter insertion. CS indicates coronary sinus electrogram.

the triangle of Koch) in 1 patient. The mean value of the earliest endocardial to beginning of P-wave interval measured from MBC recordings was 40 ± 8 ms compared with 45 ± 6 ms for the same interval measured from a standard mapping (ablation) catheter ($P=0.22$). Correlation between values of the earliest activity interval was fairly strong ($r=0.88$). In 60% of cases, no earlier activity than that reflected in MBC electrograms could be found with the roving standard catheter. In 10 patients (30%), arrhythmia originated from the left atrium. The mean cycle lengths for RATs and LATs were 387 ± 65 and 283 ± 28 ms, respectively ($P=0.005$). In ATs originating from the left atrium, the earliest atrial activity recorded in the coronary sinus preceded the earliest atrial activities recorded from the MBC (Figure 3). However, in LATs originating around the right upper pulmonary vein, the earliest electrical activity was recorded on splines covering the upper posteroseptal parts of the RA before atrial activity was recorded from any of the coronary sinus positions (Figure 4).

Mechanisms and Association With Other Atrial Arrhythmias

Response to electrical stimulation and isoproterenol showed that AT was automatic in 16 patients (6 patients with LAT) and nonautomatic in 15 patients (4 patients with

LAT). The MBC recordings showed that the earliest activity emerged from a circumvented region (focus or exit point) in 20 patients. Subsequently, the impulse was radially propagated, without evidence of its return to the site of origin (Figure 5). RAT was monomorphic in 9 patients, polymorphic in 3 (2 distinct morphologies in 2 patients, 3 morphologies in 1 patient), and multifocal in 2. In both patients with multifocal RAT, the site of earliest activity and the activation sequence manifested beat-to-beat variations (Figure 6). In 1 patient, the RA activation sequence had a clear macroreentrant pattern. The arrhythmia was repeatedly induced with premature extrastimuli from the posterior wall. The entrainment data further confirmed reentrant origin and showed that the posterior wall was within the reentry circuit (Figure 7).

In combined arrhythmias, RAT coexisted with atrial flutter (2 patients) and atrial fibrillation (4 patients). All 6 patients had previous ECG documentation of both arrhythmias. In 1 patient with persistent atrial fibrillation, a focal tachycardia took over immediately after internal defibrillation. MBC maps demonstrated that the focus was located in the antero-septal region of the RA. The site of earliest activity was successfully ablated. No drugs were prescribed, and the patient remained in sinus rhythm during 10 months of follow-up (Figure 8).

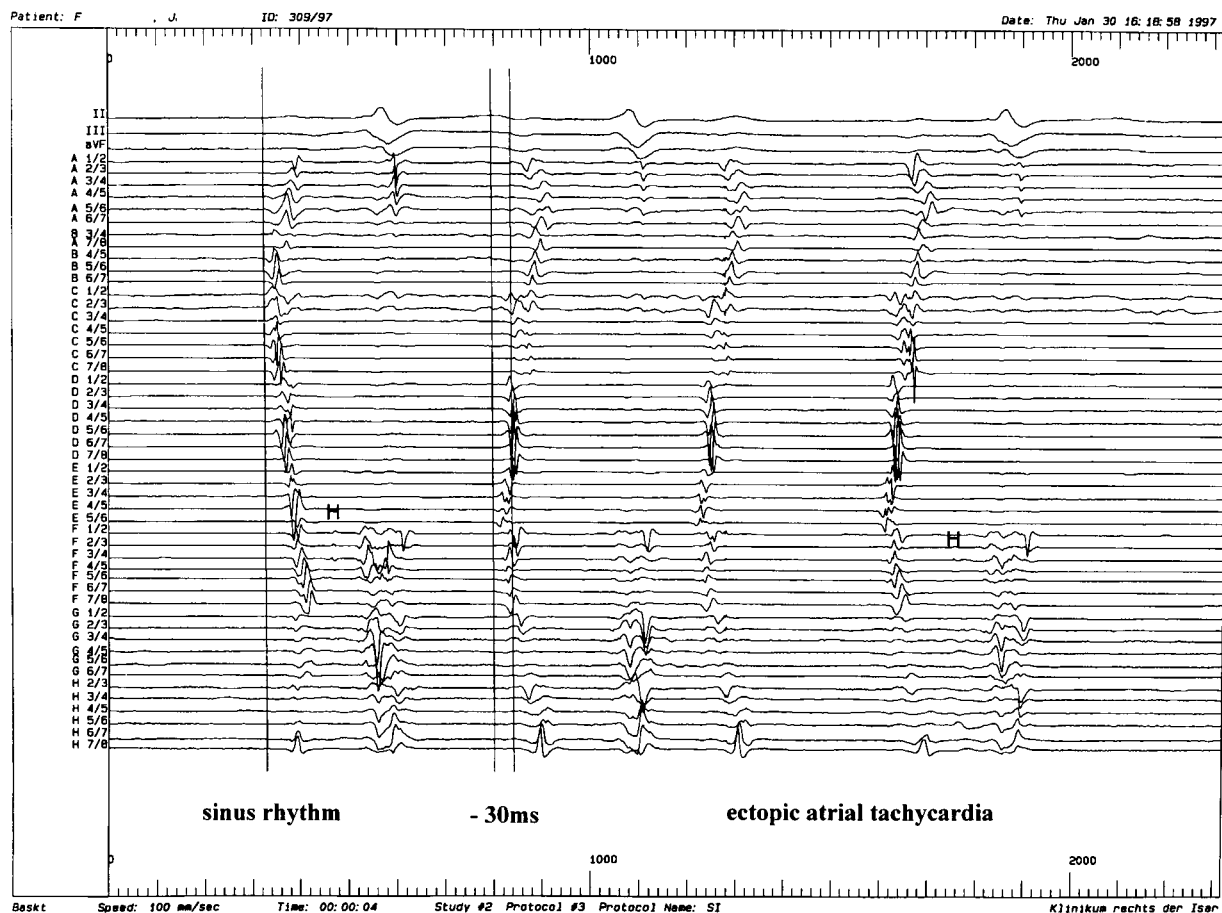


Figure 5. Initiation of short episode of RAT. Standard lead II, III, and aVF and MBC bipolar electrograms are displayed. First sinus beat is sinus; 3 consecutive beats are ectopic originating from midseptal region. P wave in inferior leads is predominantly negative with terminal positive forces. Activation sequence of RA is reversed. Earliest activity recorded from basket electrodes is 30 ms in advance of the beginning of the P wave.

Results of Ablation Procedure

Seventeen foci were successfully ablated. Ablation was successful in all patients with single foci, in 2 of 3 with polymorphic RAT, and in 2 with AT-atrial flutter combination. In 2 patients with multifocal AT and 3 in whom AT was interchangeable with atrial fibrillation, ablation was not attempted. In the patient with reentrant RAT, a linear lesion in the posterior wall terminated tachycardia that was not inducible with electrical stimulation and isoproterenol administration. A mean of 6.0 ± 5.5 radiofrequency applications were registered, with an overall x-ray exposure time of 22.8 ± 10 minutes. Patients with LAT were treated in separate procedures: 2 patients underwent successful ablation of tachycardia that originated in the right upper pulmonary vein region through the transseptal approach, and 5 patients underwent His bundle ablation and pacemaker insertion owing to coexistence of frequent episodes of atrial fibrillation. The remaining 3 patients were prescribed drugs because of their unwillingness to undergo a repeated procedure.

Discussion

ATs account for nearly 15% of supraventricular tachycardias²¹ and may occur in the presence or absence of underlying heart disease.²² They have several mechanisms²³

and multiple locations, with a clustering propensity in selected regions of the RA.^{24,25} Different mapping techniques have been proposed to locate the automatic foci or anatomic determinants of reentry circuits so that they can be effectively ablated.^{26,27}

Most of the experience with the MBC has emerged from experimental studies in animals.^{7-9,14} Jenkins et al⁷ described an MBC (Webster Laboratories) with 25 bipoles and equipped with a pull-string mechanism to optimize tissue contact that was used in endocardial atrial mapping in animals during sinus rhythm and AT. The authors suggested that MBC could help in understanding and ablation of atrial arrhythmias. In 2 recently published studies,^{8,9} Eldar et al reported their experience in using an MBC (Constellation catheter, EPT) in animal models of ventricular tachycardia in pigs. In both studies, the authors stressed the value of the technique in mapping and ablation of ventricular tachycardia. The MBCs used in their studies were the same as ours, but we recorded almost twice as many bipolar electrodes (32 were recorded in their studies). Initial morphological data on possible mechanical damage of cardiac structures by the MBC have already been reported.^{7,14} Acute postmortem animal studies revealed small superficial abrasions scattered over the superior and inferior vena cava, the RA-superior

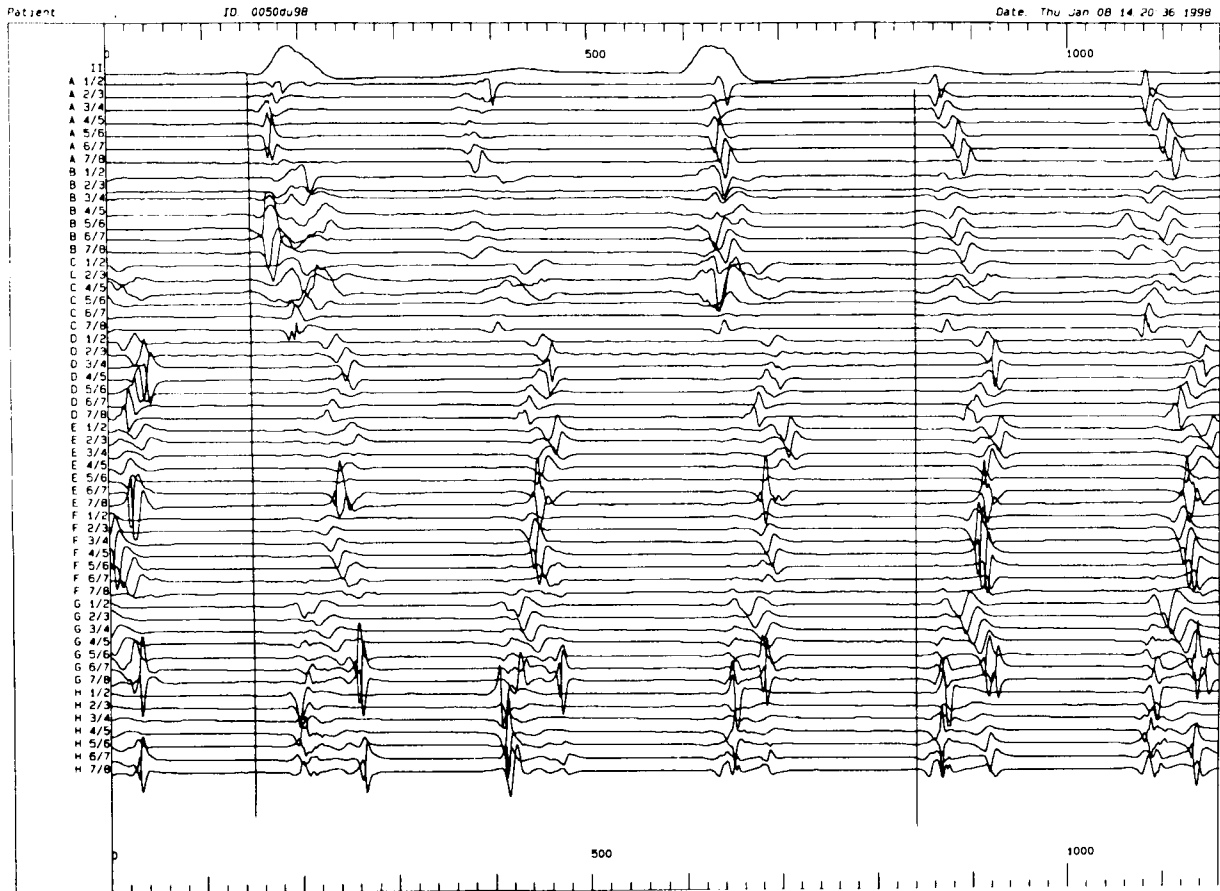


Figure 6. Multifocal RAT. Three different sites of earliest activity originating in midseptal (spline A 3/4), high anterolateral (spline C 2/3), and low posterior (spline H 7/8) regions with changes in cycle length and activation sequence visible.

vena cava junction, the base of the RA appendage, and the atrial surface of tricuspid valve leaflets.⁷ Chronic pathological data in sheep (4 to 8 weeks after MBC placement) showed focal endocardial thickenings and mild endocardial fibrosis on histology, scattered about the posterior atrial surface and at the RA–superior vena cava junction.¹⁴

Clinical experience of MBC use in humans is limited. Triedman et al¹⁵ used computer-assisted combination of bipolar electrograms recorded with an MBC and spatial locations of electrode pairs derived from digitized biplane fluoroscopic reference points to create 3-dimensional atrial activation sequence maps in patients with intra-atrial reentrant tachycardia after palliation of congenital heart disease. Greenspon et al¹⁶ presented a case report of the use of an MBC to guide radiofrequency ablation in a postmyocardial infarction patient with incessant sustained ventricular tachycardia. Recently, Schalij et al¹⁷ found that mapping with an MBC was suitable for fast and hemodynamically unstable ventricular tachycardias.

The present study demonstrates the initial clinical experience with a novel MBC in patients with AT. Our data showed that an MBC can be used safely in patients with atrial arrhythmias. The MBC deployed in the RA had a good performance in terms of recording and pacing capabilities. The MBC proved to be extremely effective in rapidly detecting the earliest activity zone in patients with focal RAT.

In patients with complex arrhythmias such as multifocal RAT, the MBC almost instantaneously identified sites of operative foci. Importantly, the recording of only a few beats was sufficient to complete the analysis of the arrhythmogenic substrate and mechanism. Thus, MBCs appear clearly advantageous for complex or short-lived arrhythmia analysis. In reentrant RAT, the MBC proved to be a valuable tool in identifying the mechanisms and differentiating RAT from other arrhythmias. The multiple recordings throughout the RA combined with the capacity of pacing from the majority of basket electrodes allowed the evaluation of activation patterns of entrained rhythms, which may help in overcoming difficulties of the current entraining technique.

The coexistence of AT with other arrhythmias is not uncommon.²⁸ The present study showed additional advantages of the current mapping system in complex or coexisting atrial arrhythmias. The presence and location of additional foci or activation patterns were instantaneously reflected in MBC maps. The technique avoids a laborious search for multiple foci in the complex 3-dimensional structure of the RA.

In the patient with macroreentrant AT, the MBC demonstrated electrical activity throughout the diastolic interval, the zone of slow conduction, and the line of block. The entrainment attempts gave a remarkable picture of the entrainment with concealed fusion, providing evidence that the current mapping system combined with entrainment techniques may

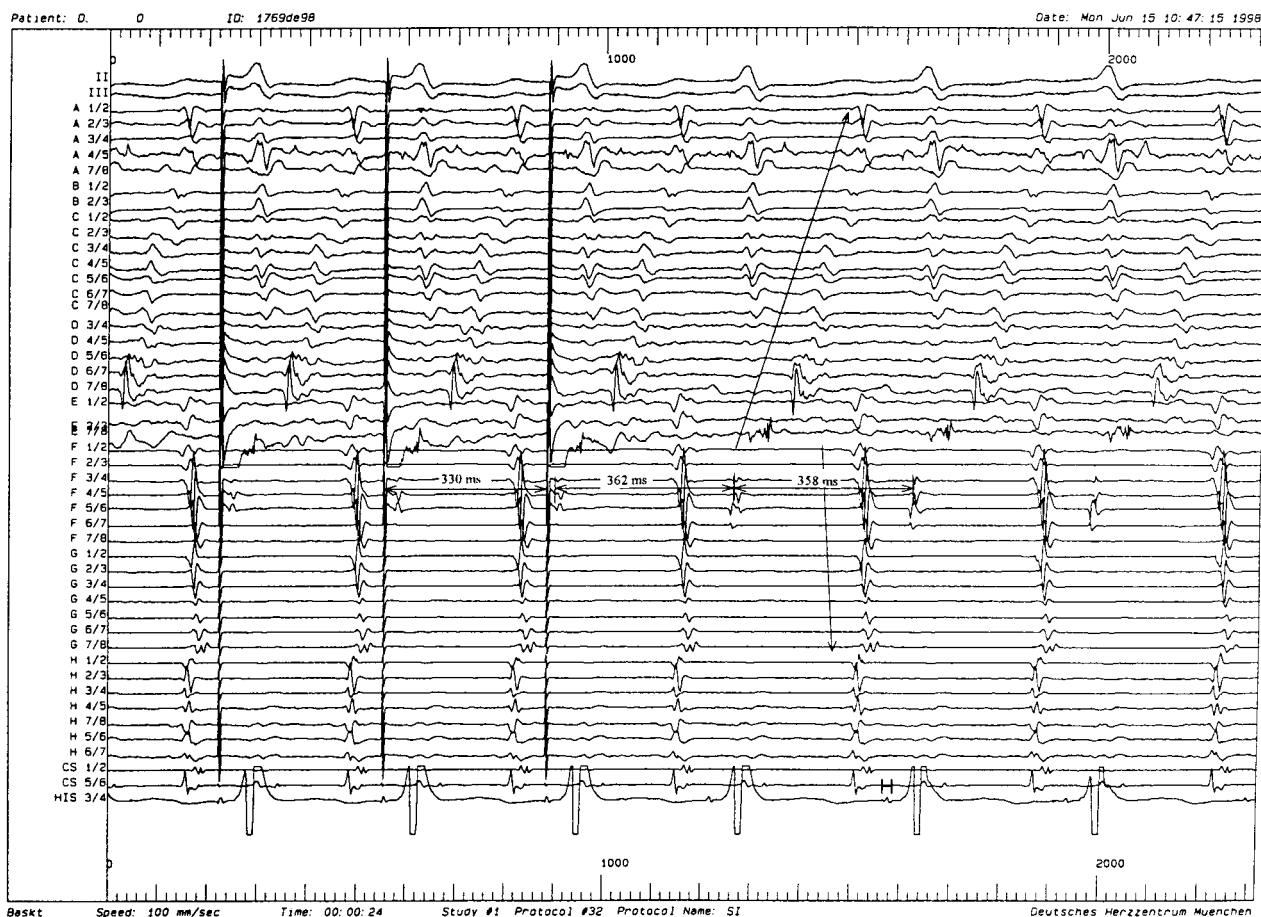


Figure 7. Reentrant RAT. Two surface ECG leads (II and III), basket catheter, His bundle (HIS), and 2 coronary sinus (CS) bipolar electrograms are presented. Double potentials are clearly demonstrated in spline F (posterior wall), and slow conduction and fragmented activity are displayed in spline D (posterolateral wall). First 3 beats are entrained by pacing from posterior (spline E) wall with cycle length of 330 ms. After last paced beat, returning circle is same as tachycardia cycle length (362 ms). In contrast to focal RAT, in reentrant RAT the MBC recordings demonstrate electrical activity throughout tachycardia cycle length. Radiofrequency current application in the posterior wall terminated tachycardia, which was not inducible after electrical stimulation and isoproterenol administration.

result in a highly sophisticated tool for the analysis of complex rhythms or activation patterns. Preliminary studies have reported that MBCs are suitable mapping tools in reentrant rhythms such as atrial flutter.^{18,29,30}

Finally, MBC-guided ablation was successful in 15 (94%) of 16 patients with RAT in whom the approach was attempted, which is comparable to reported results from other studies.^{24,26,27,31,32}

Recently, the techniques of noncontact endocardial mapping^{10,11} and electroanatomic mapping^{12,13} have been developed and introduced in clinical electrophysiology. To the best of our knowledge, no comparative studies to validate the values and advantages of these different approaches of cardiac mapping have been conducted.

Study Limitations

The most serious limitation of the use of the current mapping system in RAT is related to the specific anatomic features of the RA that do not allow complete endocardial coverage by MBC electrodes. Some important regions for location of AT foci, such as the RA appendage or the isthmus region for atrial flutter ablation, are covered incompletely by the MBC. The use of the MBC in LAT seems to be even more

problematic because of the need for transseptal catheterization, specific anatomic peculiarities of the left atrium, and possible systemic thromboembolism. Despite the advantages of the current mapping system, the procedure duration and mean x-ray exposure time reported in the present study were conditioned by the time spent for validation of the technique (pacing from all bipoles, coronary sinus catheterization, and contrast evaluation of the relations between MBC and RA endocardial contour). Despite the multitude of simultaneous recordings, the proper identification of LATs located in the right upper pulmonary vein region remains unattainable with the current mapping system. The degree of resolution of the currently available MBC is insufficient to reflect microreentrant rhythms that might be the mechanism of AT.

Conclusions

These data demonstrate that MBCs can be safely used in patients with RA arrhythmias. The simultaneous multielectrode mapping aids in the rapid identification of sites of origin and mechanisms of the ATs. The technique is especially effective for complex atrial arrhythmias. Radiofrequency ablation procedures can be guided by the MBC mapping system.

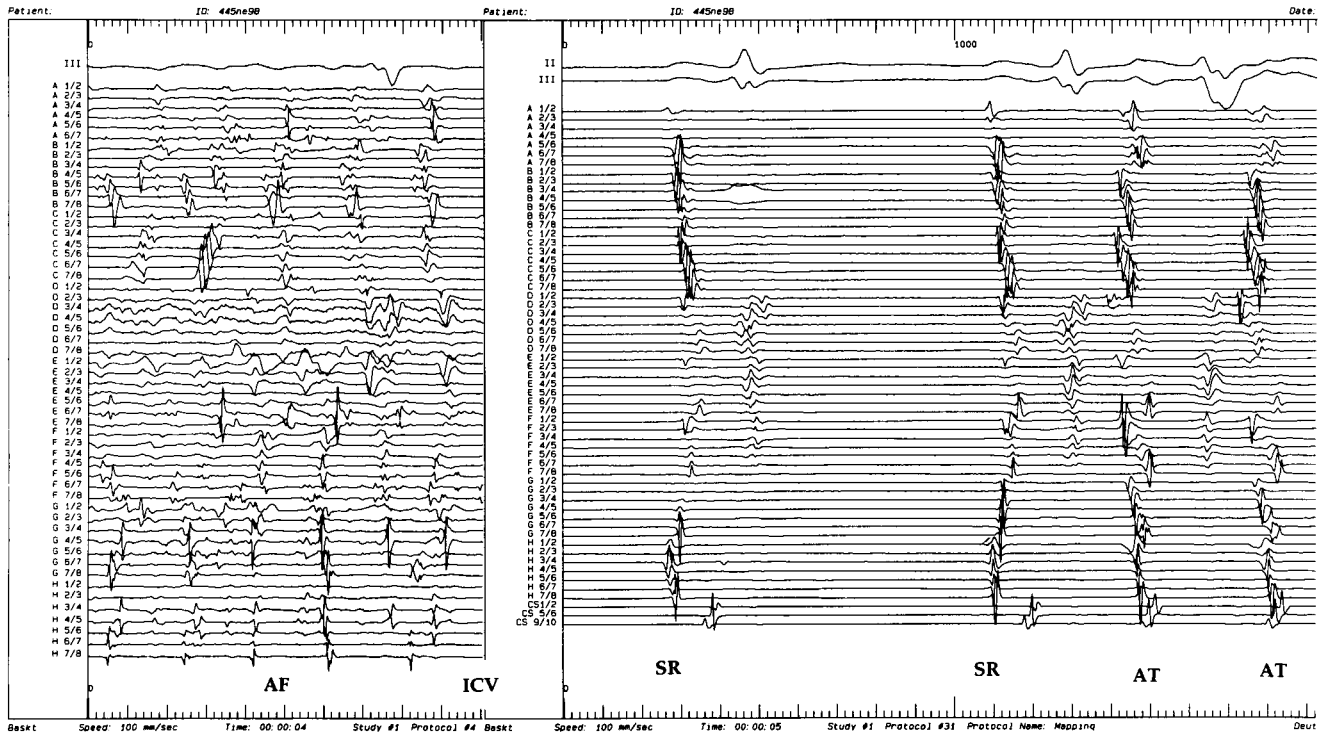


Figure 8. Focal origin of atrial fibrillation. Left, Atrial fibrillation (AF). Disorganized activity is reflected in majority of multielectrode basket splines. Right, Immediate period after internal cardioversion (ICV) with 2 J. First 2 beats are sinus beats (SR). Third beat represents first beat of RAT. Earliest activity is recorded in spline D, which is located in high anteroseptal region of RA. Radiofrequency ablation of this focus terminated tachycardia. Burst pacing and isoproterenol administration did not induce any form of atrial arrhythmia.

References

- El-Sherif N, Mehra R, Gough WB, Zeiler RH. Ventricular activation patterns of spontaneous and induced ventricular rhythms in canine one-day-old myocardial infarction: evidence for focal and reentrant mechanisms. *Circ Res*. 1982;51:152-166.
- Schoels W, Restivo M, Caref EB, Gough WB, El-Sherif N. Circus movement atrial flutter in canine sterile pericarditis model: activation patterns during entrainment and termination of single-loop reentry in vivo. *Circulation*. 1991;83:1716-1730.
- Dillon SM, Allessie MA, Ursell PC, Wit AL. Influences of anisotropic tissue structure on reentrant circuits in the epicardial border zone of subacute canine infarcts. *Circ Res*. 1988;63:182-206.
- Davis LM, Cooper M, Johnson DC, Uther JB, Richards DA, Ross DL. Simultaneous 60-electrode mapping of ventricular tachycardia using percutaneous catheters. *J Am Coll Cardiol*. 1994;24:709-719.
- Triedman JK, Saul JP, Weindling SN, Walsh EP. Radiofrequency ablation of intra-atrial reentrant tachycardia after surgical palliation of congenital heart disease. *Circulation*. 1995;91:707-714.
- Kalman JM, Olgin JE, Saxon LA, Fisher WG, Lee RJ, Lesh MD. Activation and entrainment mapping defines the tricuspid annulus as the anterior barrier in typical atrial flutter. *Circulation*. 1996;94:398-406.
- Jenkins KJ, Walsh EP, Colan SD, Bergau DM, Saul JP, Lock JE. Multipolar endocardial mapping of the RA during cardiac catheterization: description of a new technique. *J Am Coll Cardiol*. 1993;22:1105-1110.
- Eldar M, Fitzpatrick AP, Ohad D, Smith MF, Hsu S, Wayne JG, Vered Z, Rotstein Z, Kordis T, Swanson DK, Chin M, Scheinman MM, Lesh MD, Greenspon AJ. Percutaneous multielectrode endocardial mapping during ventricular tachycardia in the swine model. *Circulation*. 1996;94:1125-1130.
- Eldar M, Ohad DG, Goldberger JJ, Rotstein Z, Hsu S, Swanson DK, Greenspon AJ. Transcutaneous multielectrode basket catheter for endocardial mapping and ablation of ventricular tachycardia in the pig. *Circulation*. 1997;96:2430-2437.
- Khoury DS, Taccardi B, Lux RL, Ershler PR, Rudy Y. Reconstruction of endocardial potentials and activation sequences from intracavitary probe measurements: localization of pacing sites and effects of myocardial structure. *Circulation*. 1995;91:845-863.
- Peters N, Jackman W, Schilling R, Beatty G, Davies W. Initial experience with mapping human endocardial activation using a novel non-contact catheter mapping system. *Pacing Clin Electrophysiol*. 1996;19(pt II):600. Abstract.
- Ben-Haim SA, Gepstein L, Hayam G, Ben-David J, Josephson ME. A nonfluoroscopic electroanatomical mapping system. *Pacing Clin Electrophysiol*. 1996;19(pt II):709. Abstract.
- Gepstein L, Hayam G, Ben-Haim SA. A novel method for nonfluoroscopic catheter-based electroanatomical mapping of the heart: in vitro and in vivo accuracy results. *Circulation*. 1997;95:1611-1622.
- Triedman JK, Jenkins KJ, Colan SD, Van Praagh R, Lock JE, Walsh EP. Multipolar endocardial mapping of the right heart using a basket catheter: acute and chronic animal studies. *Pacing Clin Electrophysiol*. 1997;20:51-59.
- Triedman JK, Jenkins KJ, Colan SD, Saul JP, Walsh EP. Intra-atrial reentrant tachycardia after palliation of congenital heart disease: characterization of multiple macroreentrant circuits using fluoroscopically based three-dimensional endocardial mapping. *J Cardiovasc Electrophysiol*. 1997;8:259-270.
- Greenspon AJ, Hsu SS, Datorre S. Successful radiofrequency catheter ablation of sustained ventricular tachycardia postmyocardial infarction in man guided by a multielectrode "basket" catheter. *J Cardiovasc Electrophysiol*. 1997;8:565-570.
- Schalij MJ, van Rouge FP, Siezenga M, van der Velde E. Endocardial activation mapping of ventricular tachycardia in patients: first application of a 32-site bipolar electrode catheter. *Circulation*. 1998;98:2168-2179.
- van Ruge FP, Schalij MJ. Percutaneous endocardial mapping of atrial flutter using a multipolar basket-shaped catheter to facilitate radiofrequency catheter ablation of the atrial flutter circuit. *J Am Coll Cardiol*. 1998;31(suppl A):254. Abstract.
- Naccarelli GV, Shih HT, Jalal S. Sinus node reentry and atrial tachycardias. In: Zipes DP, Jalife J, eds. *Cardiac Electrophysiology: From Cell to Bedside*. Philadelphia, Pa: WB Saunders; 1995:607-619.
- Haines DE, DiMarco JP. Sustained intraatrial reentrant tachycardia: clinical, electrocardiographic and electrophysiologic characteristics and long-term follow-up. *J Am Coll Cardiol*. 1990;15:1345-1354.
- Josephson ME, Wellens HJ. Differential diagnosis of supraventricular tachycardia. *Cardiol Clin*. 1990;8:411-442.

22. Chen SA, Tai CT, Chiang CE, Ding YA, Chang MS. Focal atrial tachycardia: reanalysis of the clinical and electrophysiologic characteristics and prediction of successful radiofrequency ablation. *J Cardiovasc Electrophysiol.* 1998;9:355–365.
23. Chen SA, Chiang CE, Yang CJ, Cheng CC, Wu TJ, Wang SP, Chiang BN, Chang MS. Sustained atrial tachycardia in adult patients: electrophysiological characteristics, pharmacological response, possible mechanisms, and effects of radiofrequency ablation. *Circulation.* 1994;90:1262–1278.
24. Lesh MD, Van Hare GF, Epstein LM, Fitzpatrick AP, Scheinman MM, Lee RJ, Kwasman MA, Grogan HR, Griffin JC. Radiofrequency catheter ablation of atrial arrhythmias: results and mechanisms. *Circulation.* 1994;89:1074–1089.
25. Kalman JM, Olgin JE, Karch MR, Hamdan M, Lee RJ, Lesh MD. “Cristal tachycardias”: origin of right atrial tachycardias from the crista terminalis identified by intracardiac echocardiography. *J Am Coll Cardiol.* 1998;31:451–459.
26. Kay GN, Chong F, Epstein AE, Dailey SM, Plumb VJ. Radiofrequency ablation for treatment of primary atrial tachycardias. *J Am Coll Cardiol.* 1993;21:901–909.
27. Tracy CM, Swartz JF, Fletcher RD, Hoops HG, Solomon AJ, Karasik PE, Mukherjee D. Radiofrequency catheter ablation of ectopic atrial tachycardia using paced activation sequence mapping. *J Am Coll Cardiol.* 1993;21:910–917.
28. Garson A Jr, Gillette PC, Moak JP, Perry JC, Ott DA, Cooley DA. Supraventricular tachycardia due to multiple atrial ectopic foci: a relatively common problem. *J Cardiovasc Electrophysiol.* 1990;1:132–138.
29. Schmitt C, Schneider MAE, Weyerbrock S, Zrenner B. Initial clinical experience with a multipolar mapping catheter (basket) in patients with atrial flutter and atrial tachycardia. *Circulation.* 1997;96(suppl I):I-586. Abstract.
30. Zrenner B, Hofman F, Schneider MAE, Plewan A, Karch M. Three-dimensional computer-assisted animation of atrial tachyarrhythmias recorded with a 64-polar basket catheter. *J Am Coll Cardiol.* 1998;31(suppl A):511. Abstract.
31. Walsh EP, Saul JP, Hulse JE, Rhodes LA, Hordof AJ, Mayer JE, Lock JE. Transcatheter ablation of ectopic atrial tachycardia in young patients using radiofrequency current. *Circulation.* 1992;86:1138–1146.
32. Goldberger J, Kall J, Ehlert F, Deal B, Olshansky B, Benson DW, Baerman J, Kopp D, Kadish A, Wilber D. Effectiveness of radiofrequency catheter ablation for treatment of atrial tachycardia. *Am J Cardiol.* 1993;72:787–793.

Clinical Experience With a Novel Multielectrode Basket Catheter in Right Atrial Tachycardias

Claus Schmitt, Bernhard Zrenner, Michael Schneider, Martin Karch, Gjin Ndrepepa, Isabel Deisenhofer, Sonja Weyerbrock, Jürgen Schreieck and Albert Schömig

Circulation. 1999;99:2414-2422

doi: 10.1161/01.CIR.99.18.2414

Circulation is published by the American Heart Association, 7272 Greenville Avenue, Dallas, TX 75231

Copyright © 1999 American Heart Association, Inc. All rights reserved.

Print ISSN: 0009-7322. Online ISSN: 1524-4539

The online version of this article, along with updated information and services, is located on the World Wide Web at:

<http://circ.ahajournals.org/content/99/18/2414>

Permissions: Requests for permissions to reproduce figures, tables, or portions of articles originally published in *Circulation* can be obtained via RightsLink, a service of the Copyright Clearance Center, not the Editorial Office. Once the online version of the published article for which permission is being requested is located, click Request Permissions in the middle column of the Web page under Services. Further information about this process is available in the [Permissions and Rights Question and Answer](#) document.

Reprints: Information about reprints can be found online at:
<http://www.lww.com/reprints>

Subscriptions: Information about subscribing to *Circulation* is online at:
<http://circ.ahajournals.org/subscriptions/>