

Combined biopsy forceps and scissor forceps facilitate cutting the detachable loop entrapped in a large pedunculated polyp

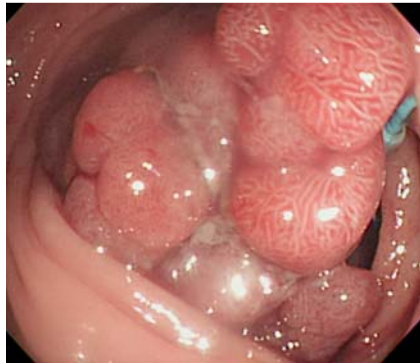


Fig. 1 Pedunculated polyp that underwent an incomplete cyanotic change, with an entrapped loop.



Fig. 2 Scissor forceps with flat blades.

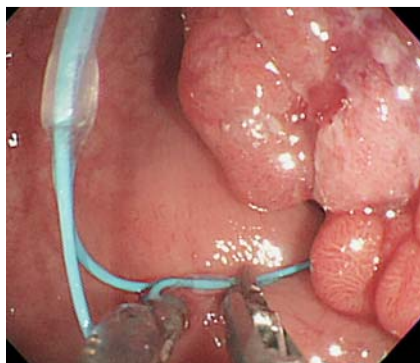

Fig. 3 Combining biopsy forceps to grasp the loop with scissor forceps to cut the loop.

A 58-year-old man was referred for resection of a pedunculated polyp, which had a head measuring 3.5×2.8cm and a stalk 1.5cm in diameter, over the sigmoid colon.

We initially applied a detachable loop over the stalk, but no total cyanotic change of the polyp head was observed. We applied a second loop, but it became entrapped in the head of the polyp without tightening (● Fig. 1). We attempted to cut the redundant loop using single-scissor forceps (FS-3L-1; Olympus, Tokyo, Japan) (● Fig. 2), but failed because the nylon loop easily slipped away from the flat blades. Therefore, we used a double-channel gastroscope (GIF-2TQ260M; Olympus) and combined biopsy forceps to grasp the loop and scissor forceps to cut the loop and remove it successfully (● Fig. 3 and ● Video 1). After ensuring effective ligation of the stalk using an additional third loop, we finally resected the polyp by cutting the stalk with a Dual-

Knife (KD-650 U; Olympus) and smoothly dragged the polyp out (● Fig. 4). Histological examination confirmed the polyp to be a tubulovillous adenoma with focal adenocarcinoma confined to the mucosal layer.

A detachable loop might occasionally stick to the ligating device, and recommendations are available for that situation [1]. In addition, events that are more common involve the ineffective loop being entrapped in the polyp and being difficult to remove with forceps only, especially when there is a large pedunculated polyp in a limited space. Using scissor forceps is another choice – either using two flat blades for cutting tissue or foreign objects within the digestive tract, or using a depressed portion of one of the blades, a so-called loop cutter. The grasping and cutting method using a double-channel scope facilitates cutting the loop using flat-blade scissor forceps. Based on our research, no such combinatory technique has been reported in relevant literature.

Video 1

Using biopsy forceps and scissor forceps to cut the loop trapped in a pedunculated polyp.

Endoscopy_UCTN_Code_TTT_1AQ_2AD

Competing interests: None

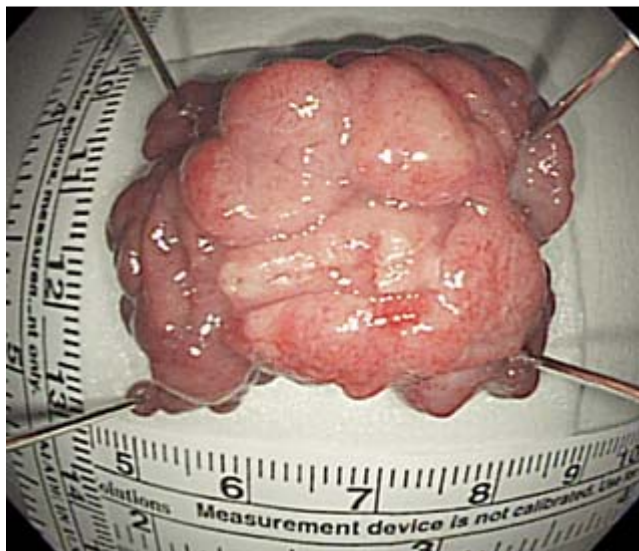

Fig. 4 The 3.5×2.8 cm pedunculated polyp which was successfully removed.

C.-W. Yang, H.-H. Yen

Department of Gastroenterology, Changhua Christian Hospital, Changhua, Taiwan

Reference

- 1 Silva RA, Dias LM, Brandão C et al. A new technique for releasing a stuck loop. *Endoscopy* 2006; 38: 437

Bibliography

DOI <http://dx.doi.org/10.1055/s-0032-1308922>
Endoscopy 2012; 44: E202–E203
© Georg Thieme Verlag KG
Stuttgart · New York
ISSN 0013-726X

Corresponding author**C.-W. Yang, MD**

Department of Gastroenterology
Changhua Christian Hospital
Changhua
Taiwan
Fax: +886-7-7228289
w96710@yahoo.com.tw