

PHILOSOPHICAL
TRANSACTIONS:

**Experiments on the Section of the
Glossopharyngeal and Hypoglossal Nerves of the
Frog, and Observations of the Alterations Produced
Thereby in the Structure of Their Primitive Fibres**

Augustus Waller

Phil. Trans. R. Soc. Lond. 1850 **140**, 423-429, published 1 January 1850

Email alerting service

Receive free email alerts when new articles cite this article - sign up in the box at the top right-hand corner of the article or click [here](#)

XX. *Experiments on the Section of the Glossopharyngeal and Hypoglossal Nerves of the Frog, and observations of the alterations produced thereby in the Structure of their Primitive Fibres.* By AUGUSTUS WALLER, M.D. Communicated by Professor OWEN, F.R.S.

Received November 22, 1849,—Read February 21, 1850.

THE object of the present observations is to describe certain alterations which take place in the elementary fibres of the nerve after they have been removed from their connection with the brain or spinal marrow.

The following is a brief summary of the opinions and researches of modern physiologists on alterations of the nerve-tubes.

BURDACH* placed a ligature on the sciatic nerve of a frog, and after the lapse of a week found no alteration of the primitive fibres either above or below the ligature.

STEINRUCK† did the same, and states that in three cases the whole nerve was more slender than on the healthy side, and ascribed it to the atrophy of the neurolema.

VALENTIN‡ denies likewise that there is any alteration of the primitive fibres in the lower portion of the nerve.

GUNTHER and SCHÖN§, whose researches are most interesting, state that the primitive fibres being examined towards the end of a week, after division of the nerve when it had lost its irritability, it was perceived that they had no longer the full round appearance of the sound ones. Here and there their contents appeared as if curdled; from eight to fourteen days after section these structural changes became still more evident, and continued to increase until the fibres appeared flat, broken up, entirely losing their transparency, their contents appearing as if disjointed.

NASSE|| states, that five months after section of the sciatic nerve of a frog, the tubes below the section were broken up into granules and small clumps; that all the nerve-tubes were strongly granulated, in some the small granules being united into oval bodies, which appeared to be surrounded by a pale cylindrical membrane, which in some was wanting, owing probably to its disorganization.

Having in a former communication to the Royal Society described the nerves of the papillæ and of the muscular fibre in the frog's tongue in their normal condition,

* Beitrag zur Mikroskopischer Anatomie der Nerven, E. BURDACH. Königsberg, 1837, p. 42.

† De Nervorum Regeneratione. Berolini, 1838, p. 72.

‡ De Functionibus Nervor Cerebral, &c. Lib. iv. 1839, p. 127.

§ MÜLLER's Archiv, 1840, Versuche und Bemerkungen über Regeneration der Nerven, p. 276.

|| Ueber die Veränderungen der Nerven-fasern nach ihrer Durchschneidung, MÜLLER, Arch. 1839, p. 409.

it is my intention at present to describe various alterations, as seen under the microscope, which take place in the structure of the same nerves after their continuity with the brain has been interrupted by section. The innervation of the frog's tongue is, as I have already shown, derived from two pairs of nerves, one arising from the brain, and traversing a foramen in the posterior part of the cranium, accompanied by the pneumogastric nerve. This pair corresponds to the glossopharyngeal in Man. In its course it descends until it reaches the hyoglossus muscle, when it is accompanied by the lingual vessels passing over part of the hyoid bone, and entering the tongue without giving off any branch to the throat. The other pair arises from the anterior part of the spinal marrow, traverses the first cervical foramen, and constitutes the first cervical pair of nerves. Following the example of BURDACH, I regard this pair as corresponding to the hypoglossal in Man, and shall apply that term to it. It takes its course towards the tongue in a similar direction to that of the former pair, giving off several branches to the muscles of the neck and throat, and when it reaches the hyoglossus muscle it is considerably smaller than the glossopharyngeal. After attaining this muscle it runs parallel to the former nerve, passing below the hyoid bone in its transit to the tongue. For a more minute description I must refer to the paper of E. BURDACH, of which a translation has appeared in the *Annales des Sciences Naturelles*.

Division of the Glossopharyngeal Nerve.

That division of these nerves produces some serious lesion is proved by the death of the animal, which generally takes place a few days after the operation. Considering the well-known tenacity of life possessed by these animals this was quite an unexpected result, for which I am unable at present to afford any satisfactory reason. We can only surmise, that besides their gustatory powers, they have others connected with respiration, in regulating the action of the tongue in closing the nares, for forcing the air into the lungs. Whatever may be the true explanation, it is impossible not to regard this result with surprise, when we consider the serious lesions which this animal is capable of undergoing at other points of the frame without loss of life. The usual time which it survives is variable, and depends greatly on the season of the year. If the examination takes place in summer, death frequently ensues on the fifth day; if in winter, not before the twentieth. For the purpose of avoiding this loss of life, I adopt the plan of dividing the glossopharyngeal on one side only of the tongue, and I find that it has the desired effect of preserving the life of the animal, while we can observe the same alterations on the corresponding side, as well as when both nerves are divided. Another advantage found in the division of a single nerve is, that on the uninjured side we have constantly at hand a means of comparison by which we can judge with certainty respecting any alterations that may be produced in the divided nerve. In cases of any doubt, it will always be found of the greatest service to examine at the same time a minute fragment from each side of the tongue.

The first effects of section of a glossopharyngeal nerve at the throat, are decreased

power of moving the tongue, diminished sensibility, generally very slight on the divided side, and symptoms indicative of some disturbance of the nutritive functions. The diminution of motor power is very slight, as is evident by the almost molecular tremor which still exists in any part irritated, and by the capability of retracting the tongue. The loss of sensation, which is also very slight, arises from the section of a few sensitive filaments which are contained in the glossopharyngeal nerve, and are distributed principally about the tubercular extremities. The lesions of nutrition and circulation on the side of the division are very variable and uncertain. Sometimes that half is œdematous, particularly towards the tubercle. Sometimes the papillæ are much injected and congested, while in other cases this side is more pale than the other. In many instances no difference can be detected between the two sides, until the organ has been slightly irritated, when on the divided side the vessels, and especially those of the fungiform papillæ, become congested and of a deeper red than on the other. Some of these differences probably arise from causes independent of the nervous lesion, as the vessels of the tongue which accompany these nerves are doubtless injured in some of the experiments.

During the first two or three days after section, no alteration in the texture and transparency of the tubes of the papillary nerves can be detected. Generally, at the end of the third and fourth day, we detect the first alteration by a slightly turbid or coagulated appearance of the medulla, which no longer appears completely to fill the tubular membrane, which does not appear to be affected. These alterations of the medulla are best seen in a fragment to which a little distilled water has been added to render it more transparent. When examined twenty-four hours after death, the difference between these and the nerves on the healthy side is still more evident. Commencing decomposition on the healthy side causes the nerve-tubes to swell considerably, so as to attain nearly double their ordinary size. On the divided side the disorganized nerve retains nearly the same size and appearance as when fresh. Caustic potash, which dissolves all the tissues except the nerves, renders the altered nerves more transparent, and consequently the morphological changes are less apparent. Nevertheless, by comparative experiments made simultaneously, we may still detect a difference between the nerves of the two sides. In some cases, in about three or four days after section, I have traced the turbid state of the nerve from the fungiform papillæ into branches containing forty or fifty tubes, where it did not appear to terminate, but where the opacity of the nerve prevented my observing it any further. About five or six days after section, the alteration of the nerve-tubes in the papillæ has become much more distinct, by a kind of coagulation or curdling of the medulla into separate particles of various sizes. Sometimes the coagulated particles have an uneven spongy appearance, as if the component parts of the medulla, *i. e.* the white substance and the axis cylinder, were mixed together. Often they appear merely like separated particles of the medulla, such as are frequently effused from the ends of a divided nerve, and present the double contour and the central nucleus cha-

racteristic of the nervous medulla. In some cases the coagulated particles are very uniform in size and appearance, averaging $\frac{1}{7000}$ th of an inch. In others, the limits between the maximum and minimum dimensions are far greater, namely, from $\frac{1}{2500}$ th to $\frac{1}{12,500}$ th of an inch. The diameter of the altered tubes, examined in the ordinary manner in water, is about a fourth smaller than that of the sound ones, and in many instances the tubular cylinders appear wanting, and the medullary particles to have escaped from the cylinder, and to be merely held together by the neurilema which surrounds the whole nerve. After the application of potash, the diameter of the altered and unaltered nerves is as nearly as possible the same. This equalization of the two is produced almost entirely by a decrease in the size of the sound tubes, which swell considerably in water, and afterwards contract by the application of the alkali. It is therefore probable that the difference of size at this stage between the altered and unaltered nerves arises from the former not absorbing so much within them as the latter. Whether this arises from a ruptured state of the membrane or from a chemical change of the medulla, is not evident. After the surrounding tissues have been removed by potash, the tubular membrane offers no signs of rupture, and the medulla appears less disorganized than before the denudation. The disjointed condition of the medulla is greatest towards the extremities. A portion of each nerve-tube is frequently so disorganized as to be carried away among the tissues dissolved by the alkali. The circular rim so frequently presented by the extremity of the tubes is absent. We often observe around the healthy nervous branches, and the papillary nerve in particular, a common sheath or neurilema fitting closely to the nerve. After disorganization has attained this degree, it appears to form a kind of loose pouch around the nerve and separated from it by an interval of $\frac{1}{5000}$ th of an inch. This pouch appears to form the sole investment of the curdled medullary particles, which, as we have stated, previous to the action of the alkali, appear void of any tubular investment. As we ascend towards the brain the disorganization appears to decrease, the coagulated medulla is more apt to assume the oval form, and at some places it presents its double contour apparently unaffected. The effect of decomposition in the unaltered and altered nerve is similar to that in the former stage. In consequence of the above changes the disorganized nerve is more opaque than the unaltered one. In the tubercles some of the ramifications of the tubes belonging to common sensation become disorganized after the section of the corresponding glossopharyngeals. These alterations take place in the same period and in the same manner as in the papillary nerves. With this exception, all the other nerves of the tongue, which comprise those of common sensation and of muscular action, remain unaltered. The muscular fibres of the papillæ are slightly altered at this period; their transverse striæ are not so distinct as on the healthy side, while their longitudinal ones are more so. The fibre itself is usually paler, narrower and more wavy in its course.

The capillaries are either much congested with dark blood, or they are completely empty and scarcely to be detected.

The epithelium and the ciliary filaments are unaltered.

On the seventh, eighth and ninth days the disorganization of the nervous structure continues to progress. In the papillæ the curdled particles of medulla become still more disconnected, and in parts are removed by absorption. The tubular sheath also is ruptured and disorganized near the extremities of the tubes. In the other ramifications of the glossopharyngeal, the medulla becomes more and more disjointed and collected into oval or circular coagulated masses.

On the tenth day and upwards we perceive another morphological state of the medulla. The coagulated particles lose their amorphous structure and assume a granulated texture. The granules, retained together by slight cohesion, are dark by transmitted light, but of a light white colour by reflexion, and average $\frac{1}{20,000}$ th of an inch.

About the twentieth day the medullary particles are completely reduced to a granular state. The condition of the papillary nerve is represented in Plate XXXI. fig. 2, where we find the presence of the nervous element merely indicated by numerous black granules, generally arranged in a row like the beads of a necklace. In their arrangement it is easy to detect the wavy direction characteristic of the nerves. They are still contained in the tubular membrane, which is but very faintly distinguished, probably from the loss of the medulla and from atrophy of its tissue. The resistance of these granular bodies to chemical agents is most remarkable, for they remain unaffected by acids, alkalies and the ethers, which have so great an influence over the nervous medulla. These granules may be detected within the papillary nerves for a considerable period of time. I have seen them apparently unaltered in the papillæ upwards of five months after division of the nerve, reunion not having taken place.

Division of the Hypoglossal Nerve.

When the hypoglossal nerves are divided at their exit from the spine, all movements of the throat and tongue are abolished, and the process of respiration entirely at an end. The tongue may be drawn from the mouth remaining completely inert, pinching or cutting causing no appearance of pain. Hence we may conclude that this nerve is of a mixed nature, containing sensorial as well as motor filaments. Another experiment, which shows this more plainly, consists in dividing one hypoglossal nerve near the spine on one side, and on the other the glossopharyngeal at its exit from the cranium. Pinching and other modes of irritation cause no pain on the side where the hypoglossal is divided, while on the other undoubted pain is caused.

After division of the hypoglossals at the throat, the motor and sensorial powers of the tongue are not entirely lost. When drawn out of the mouth, the extremity only remains fixed between the jaws, flaccid and powerless. At the inner half the fibres are still contractile, on account of their belonging to the hypoglossus, which at its lower half receives a branch from the hypoglossal nerve above the point of section. By this

means, aided also by the mylohyoid muscle, which is left unaffected for the same reason, the inner half of the tongue still enjoys contractile powers.

Respiration is hurried and laboured, and death is the invariable result of division of these nerves, whether made at the spine or at the throat. In summer, the animals died at the end of two or three days.

Division of a single hypoglossal only causes paralysis of the corresponding half of the tongue, complete when the section is near the spine, and imperfect when at the throat. The animals generally survive after the section of one nerve.

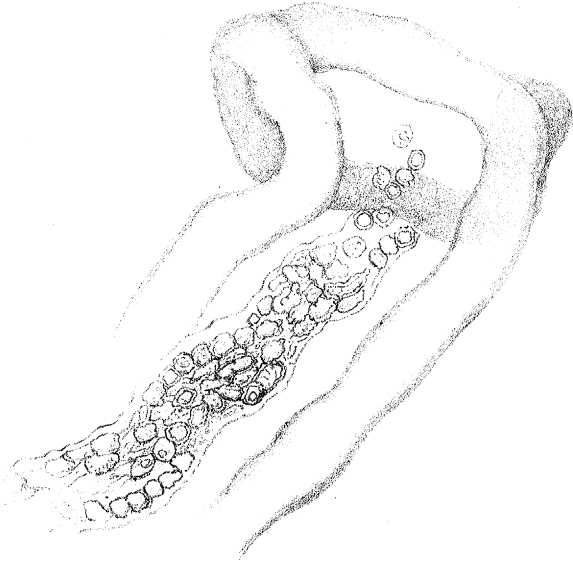
The peripheric extremities of the hypoglossal nerves are most easily found at the inferior surface of the tongue. By removing a minute fragment at this region, we can observe, without any further preparation, ramifications of nerves, which are gradually reduced to a network of single tubules on the surface, among the capillary network. At the same time, among the muscular fibres are other ramifications, either crossing them in a transverse direction or running parallel. Like the former, they are reduced to single fibres, running in all directions without forming any free ends. It is at the under surface that the alterations of the hypoglossal must be studied.

During the four first days, after section of the hypoglossal nerve, no change is observed in its structure. On the fifth day the tubes appear more varicose than usual, and the medulla more irregular. About the tenth day the medulla forms disorganized, fusiform masses at intervals, and where the white substance of SCHWANN cannot be detected. These alterations, which are most evident in the single tubules, may be found also in the branches. After twelve or fifteen days many of the single tubules have ceased to be visible, their granular medulla having been removed by absorption. The branches contain masses of amorphous medulla.

We are naturally led to inquire, whether extraneous circumstances have any influence over the removal of the tissue. We find that in the summer-time, when the renewal of the tissues must be considerably more active, in consequence of the increased respiration and activity of the animals experimented upon, that the alteration is more rapid than in winter, when they are in a state of torpor and hibernation.

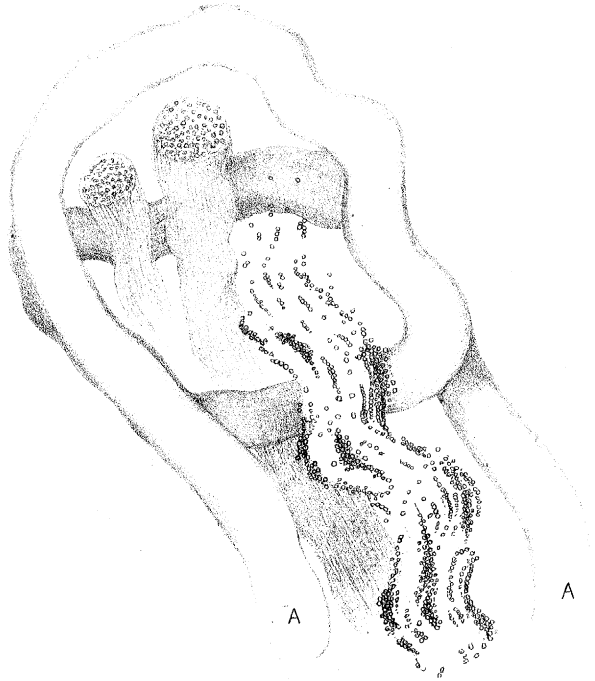
At present we have restricted our observations to the alterations which take place in the ramifications originating from two trunks, but we cannot suppose that this is a local phenomenon, and that other nerves do not participate in similar alterations, and that the brain itself, composed in great part of tubular fibres, must be excluded. Experiments on other nerves already enable me to affirm that such is not the case, and that they are to be found on other nerves, such as the sciatic, &c., and, moreover, that they are as extensive as the nervous system itself. It is impossible not to anticipate important results from the application of this inquiry to the different nerves of the animal system. But it is particularly with reference to nervous diseases that it will be most desirable to extend these researches. If one conviction impresses itself more firmly on the mind than another, it is that what we term functional diseases of

Fig. 1.



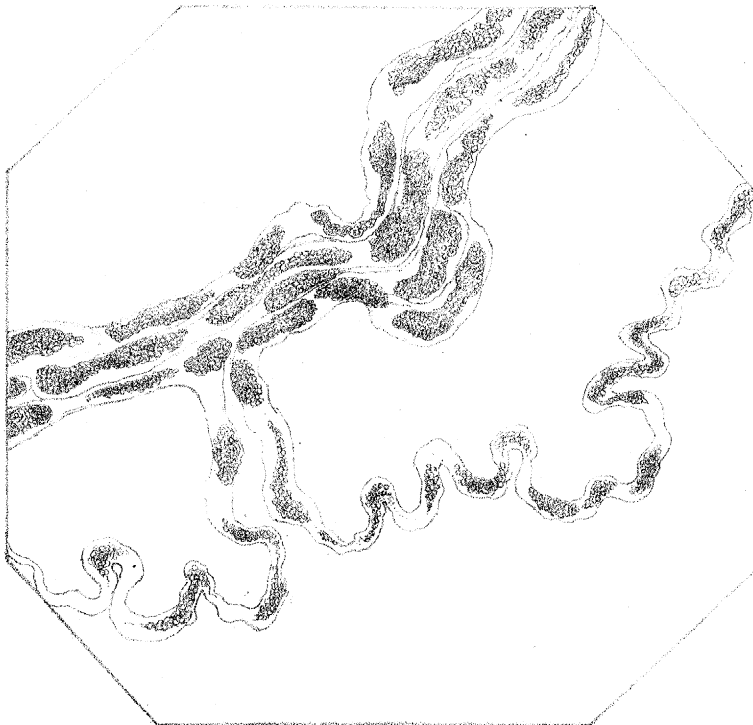
Magnified 400 diam^{rs}

Fig. 2.



Magnified 400 diam^{rs}

Fig. 3.



Mag^d 400 diam^{rs}

the nerves are in reality owing to certain organic and physical changes in the tubular fibre, which it will be the province of the microscope to ascertain. If a few days' inactivity of a nervous trunk, such as is produced by ligature or section, is sufficient to cause such disorganization of the medulla, how can we refuse to admit of its being altered in cases of prolonged paralysis?

Kensington, October 27, 1849.

DESCRIPTION OF THE PLATE.

PLATE XXXI.

- Fig. 1. Papillary nerve of frog, six days after ligature.
Fig. 2. Papillary nerve, three weeks after section, with muscular fibres in the interior of the capillary coil at the summit of the fungiform papilla.
Fig. 3. Disorganized muscular nerve, from the inferior surface of the tongue, five days after section. The muscular fibre has been omitted in this drawing.