

THE BENEFITS AND RISKS OF THE ILIZAROV TECHNIQUE FOR LIMB RECONSTRUCTION

Introduction

In the past, patients with fractures which failed to heal (non-union), or healed incorrectly (mal-union) had little treatment available to them, and patients who required surgical removal of infected bone (osteomyelitis) or cancerous bone often had no choice but to have an amputation of the affected limb. The treatment of such orthopaedic conditions was revolutionised by Dr Gavril Ilizarov, as will be explained below.

The Ilizarov frame takes its name from Dr Gavril Abramovich Ilizarov. He was born in the Soviet Union in 1921 and attended medical school in Crimea aged 18. Having graduated in 1944, his first job was as a family doctor in the Kurgan province of Northern Siberia. As this was a remote area, Ilizarov worked largely alone, and was required to perform a range of surgical procedures. As there were no experienced physicians available to guide him, he taught himself many surgical techniques from books as his only formal surgical training had been a six month course in military field surgery.

Ilizarov first became interested in orthopaedics and bone reconstruction because many of his patients were soldiers returning from the front line battles of World War 2. Many of the patients suffered severe fractures, and had to endure lengthy treatment; casts and skeletal traction being the only methods generally used (Ilizarov & Rozbruch, 2007). Ilizarov believed there must be other ways of treating fractures, and devoted his career to orthopaedics.

In 1950, Ilizarov moved to Kurgan where he worked within the general surgery department at the Kurgan regional hospital. He continued his research into improving the treatment of fractures, and developed the idea of an external fixator ring with cross wires to improve their stability.

The first patient to be treated with the new external fixator was a worker with a non-union fracture from the factory where the metal parts for the frame were made (Ilizarov & Rozbruch, 2007). Although the Ilizarov device was met with scepticism, similar devices began to emerge.

Ilizarov's methods started to become more widely accepted after he successfully treated Soviet high jumper Valery Brumel in 1968. Brumel had suffered an open fracture (one in which the bone sticks through the skin) of his tibia, which several other surgeons had attempted to treat without success. Three years after his fracture, Brumel saw Ilizarov but by this time had developed osteomyelitis and had a significant limb length discrepancy. Ilizarov treated both of these, and Brumel was able to continue his athletic career.

As well as the frame, Ilizarov developed his method which was supported by biomechanics and basic science.

As stated by Ilizarov S. and Rozbruch, Ilizarov outlined the following principles of the treatment of fractures in his dissertation:

- *'Preservation of the blood supply*
- *Preservation of the osteogenic tissue*
- *Complete anatomic reduction*
- *Stable fixation*
- *Functional activity of the muscles and joints*
- *Early patient mobilization'* (2007:p9)

He stated that by providing bone and other tissues with ideal conditions for healing and without compromising an already injured limb further we should see faster healing time and speedier recovery (Ilizarov & Rozbruch, 2007).

The ability of bone to regenerate by distraction (pulling apart) was discovered by chance when a non-union which was supposed to be treated by compression osteogenesis (pushing together bone segments to try and stimulate new bone growth) was in fact given the opposite treatment; the nuts on the frame were accidentally turned in the opposite direction, pulling the bone apart instead of pushing it together. Ilizarov observed some cloudy density on the radiograph of the patient, and believed it to be new bone formation (Ilizarov & Rozbruch, 2007).

Ilizarov continued to work to improve both his frame and his techniques. This included switching from the traditional osteotomy (making a break through the bone) to a corticotomy (cutting through only the outer layer (cortex) of the bone), which preserved the soft tissue and reduced the time needed to heal. He also developed bone transport techniques, which enabled the treatment of bone defects without the use of bone grafts.

He also discovered that other tissues such as blood vessels, nerves, and skin were able to regenerate during gradual distraction, and developed his 'Law of tension stress' which showed that under the effect of slow and gradual distraction, bone and soft tissue would regenerate.

The Ilizarov method spread to Italy after Ilizarov successfully treated Italian journalist Carlo Mauri in 1980 for an infected tibial non-union. Mauri was so impressed that he wrote an article in an Italian newspaper naming Ilizarov as the Michelangelo of Orthopaedics. This was the key factor that resulted in the spread of the Ilizarov method to the rest of the world.

In this essay, I am going to describe the biology behind the Ilizarov technique, the research which developed its use, its advantages and risks, and its applications which will be illustrated by case studies.

Biological Principles of Distraction Osteogenesis

No matter what condition or defect is being treated by the use of an Ilizarov fixator, the fixator and how it works is broadly the same. The Ilizarov apparatus is a set of external fixators consisting of rings, rods and kirschner wires, all made of stainless steel. It differs from the conventional external fixators in that it encases the limb as a cylinder and it uses wires instead of pins to fix the bone to the rings. The circular construction and tensioned wires allow early weight bearing as it provides far

greater support than monolateral (one sided) fixators. The top rings of the Ilizarov fixator allow force to be transferred through the external frame, bypassing the fracture site and transferring the force from healthy bone to healthy bone.

The purpose of the Ilizarov fixator is to stimulate bone growth, and this works by the principle of distraction osteogenesis, which is the pulling apart of bone to stimulate new bone growth. Distraction osteogenesis is a method for regenerating bone deficiencies in a number of situations, for example correcting limb length, width or misalignment. It can also be used to treat non-unions and to regenerate bone lost due to infection. A break is made in the bone, and gradual distraction of this bone results in new bone formation. Initially, the distraction gives rise to neovascularisation which is what stimulates new bone formation. Simultaneously, histogenesis of muscle, nerves and skin occurs. The bone rapidly remodels to normal structure, even in bone which is skeletally mature. The increase in local and regional blood flow were not significantly different from those measured in normal fracture healing, which suggests that the normal reparative response was neither prolonged nor enhanced by the distraction process.

The actual length of the new bone that can be produced is up to 18-20cm per limb segment (Ilizarov & Rozbruch, 2007). However it is possible to have multiple lengthening sites, so enabling more rapid lengthening. The procedure has been successful in patients at nearly every age from early childhood to middle aged adults.

The new bone that forms is usually of the same quality and cross section to the local site in the host bone from which it formed. Although bone production is usually very successful, the growth of soft tissue and the preservation of normal joint function can limit the clinical applications of the method (Paley, 1990).

Research and Experiments

Ilizarov and his team conducted a series of studies to investigate the principles of distraction osteogenesis. They mostly conducted their studies on canine tibia, and studied the effect of stability of fixation, energy of osteotomy, i.e. the degree of damage to the surrounding soft tissues, and the rate and rhythm of distraction, which are all critical factors for successful osteogenesis. (Ilizarov G. A., 1989).

In the past, the rate and rhythm of distraction were rarely considered. Italian surgeon, Alessandro Codivilla (Codivilla, 1904) stretched the whole gap in one go under general anaesthesia, while Wagner (Wagner, 1978) encouraged his patients to turn the distraction knob on the external fixator as fast as they could according to pain and neurological problems. Wagner often had to fill the distraction gap with bone grafts, but these could take years to consolidate.

Initial experiments were performed to test the hypothesis that rate and rhythm are important to distraction osteogenesis. An experiment was done where an entire distraction gap was created to see if new bone would form in 2cm gap between the cut surfaces. The result was that the gap was not bridged by new bone, so a non-union occurred (Ilizarov & Rozbruch, 2007).

Rate was further tested by comparing two groups of dogs where bone was distracted at a rate of 1 versus 2 mm per day. All the animals bridged the gap, and normal appearing bone formed, but with

the 2mm/day distraction rate, there was a significant decrease in blood flow at week three and a decrease in mineralisation of the bone at weeks four and five (Aronson, 1994).

From his experiments, Ilizarov concluded that the optimum rate of distraction is 0.25mm, four times per day. Rates exceeding 2mm per day limited angiogenesis- the growth of new blood vessels from existing ones- and cell growth, which inhibited osteogenesis, and resulted in no new bone formation in the distraction gap. Much lower rates of distraction resulted in premature consolidation of bone which prevented further distraction.

The types of external fixator were also tested. The distraction technique was controlled; Ilizarov's technique of corticotomy, latency, rate and rhythm were used. The experiments compared the standard half pin fixator as used by Wagner to the fixator modelled after Ilizarov which consisted of tensioned wires and rings (Aronson et al, 1989). The radiographic and histological appearance of the bone seemed to be identical, although use of the half pin device sometimes resulted in the bone having a slight angular deformity, which didn't happen with Ilizarov's frame (Ilizarov & Rozbruch, 2007).

The importance of stable fixation was shown when the external fixator accidentally destabilised, which could result from lack of tension in the wires, loose pins, or a flexible frame, and the gradual distraction resulted in bone that either angulated or failed to join with the docking site.

The procedure

The patient will undergo surgery to fix the Ilizarov fixator to the limb. Wires are passed percutaneously through the bone using a drill. The protruding ends of the wires are attached to metal rings which encircle the limb, and tensioned to enhance stability.

A corticotomy is then performed. This is a procedure in which the cortex of the bone is cut, leaving the periosteal (of the membrane covering the bone) and endosteal (of the membrane that lines the inner surface of bones) blood supplies intact. These are the most important elements for osteogenesis. After a delay of 5 to 10 days, distraction is begun by turning the nuts on the metal rods 0.25mm, four times per day, a total distraction of 1mm per day. Osteogenesis occurs in this gap as the distraction continues. Once the distraction is stopped, the frame remains attached to allow the new bone to harden. This time is usually one month per cm of new bone formed. After this time the frame is removed under general anaesthetic (Ilizarov & Rozbruch, 2007).

Advantages of the Ilizarov Method

The Ilizarov method carries many advantages over other methods for limb reconstruction. One of the main advantages of distraction osteogenesis is that it is effective in mature as well as young bone, which means treatment using this principle is not limited to children, but works equally as well in adults.

The Ilizarov external circular fixator is a very useful tool for many reasons:

- The modular design of the apparatus allows the frame to be custom built for each individual patient.

- The circular nature of the frame both enhances stability and evenly distributes the stress across the corticotomy and the distraction gap.
- The structure and strength of the frame allows weight bearing throughout the treatment, which is beneficial to the patient both in terms of day to day mobility and helping to build muscle strength and prevent joint stiffness (Mencio, 1992).
- When the frame is applied to the limb during surgery, only wires fix the bones to the rings, and no other skin incisions are made, which reduces the risk of bleeding, infection, and damage to the surrounding soft tissues.
- It holds fragments of bone together to allow them to unite when traditional methods of fixation are unable to give proper hold on the fracture fragments, and allows significant compression in the case of non-unions.
- It allows bone fragments to be pulled apart. This results in osteogenesis and can be used for limb lengthening or for regenerating bone which has been removed due to traumatic loss, tumour or infection, for example. (Rallis Orthopedic Hospital, 2010)

Russian studies of the Ilizarov method (Popova and Khodesechich, 1984) as cited by (Ilizarov & Rozbruch, 2007) showed that the use of this system reduced treatment time, the cost of treatment, and disability payments significantly. When used for the treatment of fractures and post traumatic non-unions, primary disability was decreased by 3-5 times, and 8 fold compared with traditional treatments in the case of open fractures. This meant that more patients were able to return to work sooner, which is advantageous for the economy of the country.

Applications of the Ilizarov Method

The Ilizarov technique can be used to correct deformities to bone. These deformities can occur for a number of reasons which include:

- As the result of a trauma. For example mal-union fractures. These can cause problems on the surrounding joints as it can result in the stress of the joint not being evenly distributed across the joint. It can also give the appearance that the limb is shorter, causing the patient to limp.
- Various conditions including Blount's Disease, Hypophosphatemic Rickets and Enchondromatosis.

-Blount's Disease is a growth disorder of the tibia in which the lower leg turns inwards, resembling a bow leg. It occurs in young children and adolescents. Although the cause is unknown, it is thought that it may be due to the effect of weight on the growth plates. The inner part of the shin bone, just below the knee, fails to develop properly. Unlike bowlegs, which tend to straighten as the child develops, Blount's disease gets progressively worse as the child gets older.

-Hypophosphatemic Rickets is a disorder in which the bones become very soft and bend easily due to low phosphate levels in the blood. This is nearly always a hereditary disorder, resulting in a kidney abnormality causing high levels of phosphate to be excreted in the urine, and not reabsorbed into the blood stream. Phosphate, along with calcium is involved in the formation of bone, and is necessary for the ossification process.

-Enchondromatosis, also known as Ollier's Disease is characterised by a number of enchondromas-benign masses of cartilage growing within bone, close to growth plate cartilage. These enchondromas can cause various defects, including skeletal deformity and limb length discrepancy, and predispose to pathologic fractures.

Other applications of the Ilizarov method include:

- Osteomyelitis and infected non-unions. In a patient with osteomyelitis, removal of the infected bone and tissue (debridement) is a necessary surgical procedure. If large sections of bone have to be removed, either a bone graft or a bone transport procedure is necessary, if the patient is to avoid the need for amputation of the limb.
- Acute trauma applications. The Ilizarov method is a very useful tool for the treatment of patients suffering from multiple fractures, or poly-trauma conditions.

The use of the Ilizarov method for treatment of angular deformity.

Angular deformity of limbs can range from small, relatively insignificant angulations, to major, crippling deformities. Often, they occur as a result of a mal-union fracture, where the bone has healed at an angle, but they also result from various conditions including Blount's disease, Hypophosphatemic rickets, and Enchondromatosis, as previously mentioned.

An external fixator is a very useful tool for correcting mal-unions, and therefore the deformity, and provided skeletal stability while the osteotomy heals. The rings of the frame can also be applied so that they exactly mimic the deformity, such that when adjusted daily until the 'home position' is reached, the bone is gradually distracted and realigned, and can then regenerate, correcting the angular deformity. As is often the case when an angular deformity is caused by a mal-union fracture, there may be a limb length discrepancy. Additional length can be obtained at the same time as the correction of the deformity, either by continuing to lengthen through the osteotomy, or for more extensive lengthening, by creating a second osteotomy elsewhere on the bone (Ilizarov & Rozbruch, 2007).

The Taylor Spatial Frame is a very useful tool for the correction severe angular deformities, and uses the classic principles of the Ilizarov method. 'A specialized feature of the frame is the virtual hinge, which allows for the simultaneous correction of multiplanar deformities and limb lengthening through one osteotomy site (Rozbruch, 2006). Unlike the traditional circular fixator, the six axis manipulator can address all components of a deformity including rotation with essentially the same frame. Due to the stability of this frame, early weight bearing can be achieved, and the optimum environment for both new bone formation and soft tissue healing is provided.

The use of the Ilizarov method and external fixation has simpler surgical goals than other methods of treating an angular deformity, which include the use of an intramedullary nail, plate fixation, physal stapling, which involves stapling the part of the bone that is pertaining to growth, and osteotomies (removal of a fragment of bone) as the surgeon has only to provide stable fixation for each segment of bone, and perform an osteotomy. The distraction and realignment is achieved after surgery, is highly accurate, and can be adjusted gradually until both the patient and surgeon are happy with the results. External fixation is also useful in cases of prior infection or poor soft tissue coverage. The drawback of the other methods mentioned above is that the shape of the bone cannot be altered after surgery. Limb alignment is determined while the patient is anaesthetised and therefore not bearing weight, which makes the functional and cosmetic results of the surgery less predictable. This may mean that additional surgeries are necessary to treat incomplete deformity corrections (Marcellin-Little, 1999). Another advantage of the Ilizarov method is that distraction osteogenesis can occur even in skeletally mature bone, so the treatment works as well in adults as it does in children.

As with any surgery, there are various complications associated with this method. Complications can be split into major or minor, major being classified as requiring further surgical treatment, prolonging the treatment, or compromising the outcome, and minor responding to non-surgical treatment, and having no lasting secondary consequence. Major complications include nerve palsy, joint contracture necessitating lengthening of the tendon, premature or delayed osseous

consolidation, and permanent stiffness of the joint. Typical minor complications include pin tract infection, oedema, and transient paresthesia (an impermanent tingling sensation in the skin) (Velazquez et al, 1993). It has been shown that there is a negative correlation between the likelihood of experiencing complications and the experience of the surgeon, and also that the longer the treatment time, the more likely the patient is to suffer complications.

Case Study

This patient is a prime example of the benefits of the Ilizarov technique for the correction of bone deformity. Following an accident several years ago, the patient suffered an open fracture to the tibia, which healed with a significant varus deformity. This is when the distal part of the leg is angled inwards, resulting in a bowlegged appearance.

The line from the middle of the hip to the ankle should pass through the centre of the knee joint, as demonstrated by the left leg. Figure 1 shows the extent of the deformity of the right tibia, as the line doesn't pass

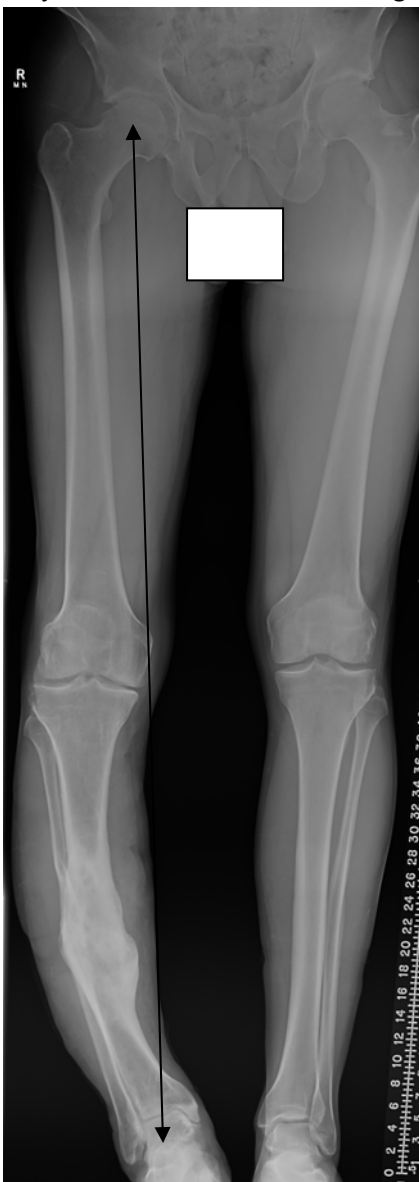


Figure 1

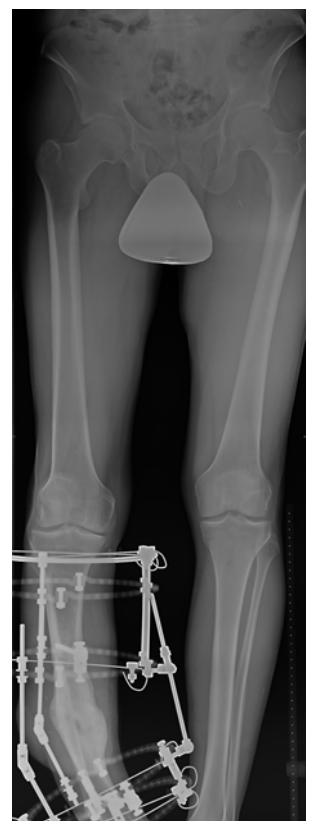


Figure 2

through the knee at all. We can also see the discrepancy in the leg lengths, with the right leg significantly shorter than the left.

One consequence of this deformity was that the patient suffered from medial knee pain due to pressure on the joint, which was made worse by some ligament instability of the knee.

The patient had also suffered from infections in the past few years which were easily controlled, but in the last year was advised that the infection in his tibia was worsening, and a below the knee amputation may be necessary. The patient had an active job and so was keen to avoid this scenario if at all possible. He was referred to a specialist bone infection team, where various surgical options were discussed. Following these discussions, he had surgery to remove the infected bone, and muscle flaps were used to address the soft tissue defect. He then went on to have further surgery to correct the bone deformity. This involved an osteotomy and an Ilizarov external fixator was applied to the limb (figure 2). It is very important to ensure that all the infected bone is removed before performing the osteotomy, or there is a risk of the infection spreading to the fracture site, causing deep bone infection. Using the Ilizarov method, the frame was adjusted and the tibia was gradually pulled apart and realigned. This also corrected the limb length discrepancy which had occurred as a result of the mal-union fracture.

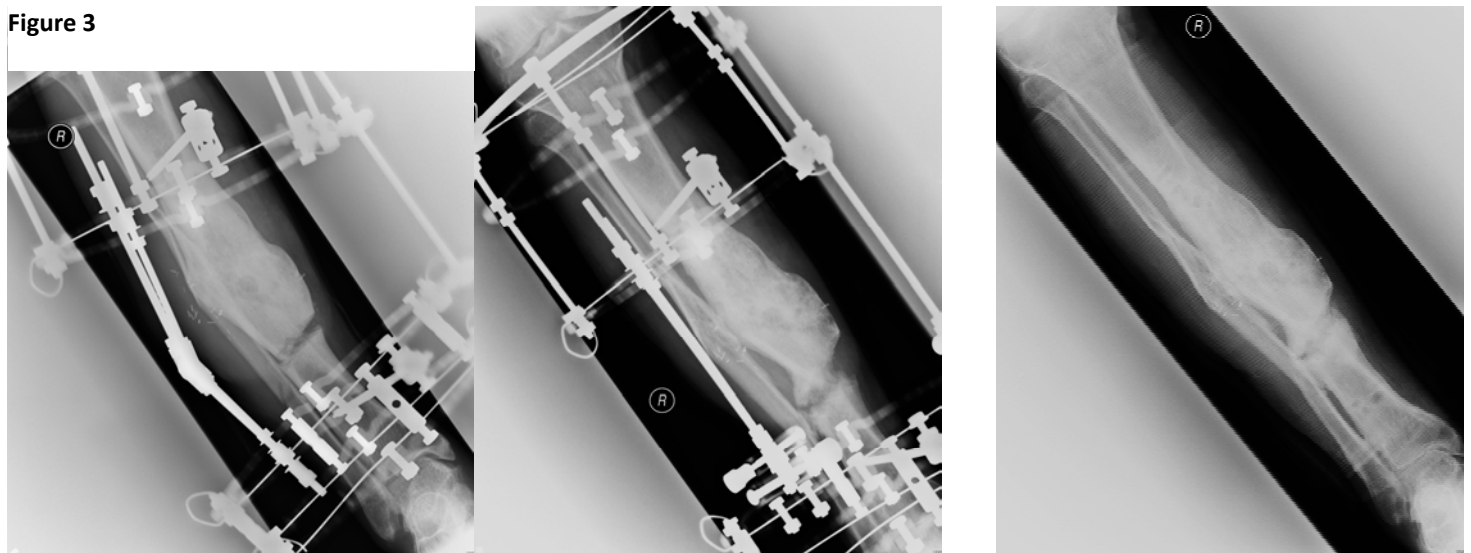


Figure 4

These two x-rays (figure 3) show the gradual distraction of the bone to correct the deformity, and we can clearly see the new bone forming in the gap that was created. In the final x-ray (figure 4) the bone is straight and the Ilizarov frame has been removed, and we can see further hardening of the bone in the distraction gap.

The use of the Ilizarov method for the treatment of osteomyelitis and infected non-unions.

Osteomyelitis describes an infection within the bone, and is usually caused by bacteria. The infection can result from injury or trauma, for example, a fractured bone, from surgery, or can be introduced by direct extension of a nearby infection, or from an infection in the bloodstream. It commonly affects the long bones of the leg, although osteomyelitis can affect any bone.

Osteomyelitis can be very difficult to treat, increasingly so due to the evolution of antibiotic resistant bacteria. If the infection is diagnosed quickly, antibiotics may be sufficient to treat the infection, but in many cases, especially in cases of chronic osteomyelitis, a surgical procedure is required to remove the dead or infected areas of bone, which is followed by prolonged use of antibiotics.

If large areas of bone are removed during surgery, bone grafting or bone transport techniques are used to fill the gap in the bone. Bone transport involves performing a corticotomy in the bone, and then gradually moving a segment of bone from A to B, where it joins with healthy bone. The bone transport method relies on Ilizarov's principles of distraction osteogenesis, and the use of an external fixator to stimulate the regeneration of the bone.

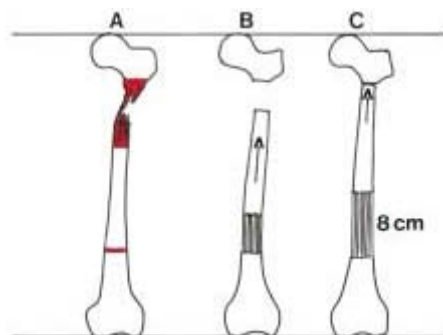


Figure 5. Preoperative scheme of the treatment by Ilizarov method. **A.** The area marked in red indicates the area of bone which will be removed. The mark in the lower part indicates the site of planned corticotomy.

B. and C. Arrows indicate the direction of the bone transport. (Barbarossa et al, 2001)

A study of 30 patients with chronic osteomyelitis and infected pseudoarthroses (false joints) of the femur showed the efficacy of the Ilizarov for treatment of such conditions, but emphasised the importance of patient compliance and involvement in order to achieve the best results. The patient must exercise the limb and joints so rigorous physiotherapy is required. Nearly all of the 30 patients involved in this study were able to stand and partially weight bear immediately after the operation, and 21 patients were able to do everyday activities whilst wearing the frame. Early and intensive physiotherapy significantly contributed to these results. (Barbarossa et al, 2001)

The use of bone transport to fill large gaps is reliable but requires the patient to have a frame for long periods of time. It also requires regular monitoring of 'bone growth, joint mobility, and any pin tract infection, loosening, or breakage' (Abdel-Aal, 2006) as well as the need for rigorous physiotherapy both while the frame is on and after its removal.

Complications of the use of the Ilizarov bone transport method include recurrence of infection, often due to inadequate debridement of the infected bone, failure of the bone segment to join to the docking site (non-union), or delayed consolidation of the bone, pin tract infections, cellulitis and oedema.

As previously mentioned, bone grafting techniques can also be used to replace infected bone. Autologous bone grafts are also used successfully in the treatment of osteomyelitis for small defects, but for larger defects they are less successful. Abdel-Aal states that:

'When the defect is large, more than one site may be used to harvest the graft, which adds to the morbidity of the patient. Allograft has its limitations (preparation and preservation) and its problems, and vascularised free fibular transfer is a demanding technique.'(2006:p.74)

Case Study

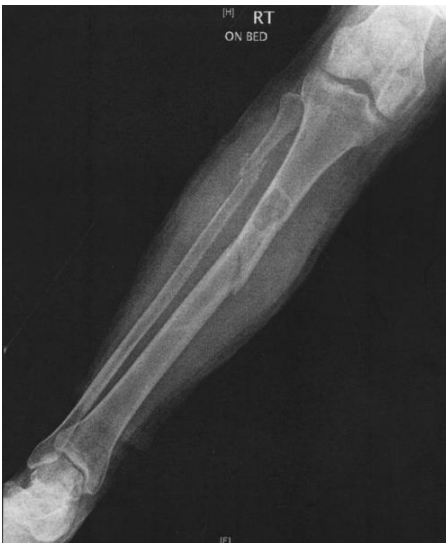

Figure 6

This 60 year old lady presented with a fracture in her right tibia and fibula caused by a benign tumour in her tibia. (Figure 6) This lady had surgery to remove the tumour, which left a large gap in both the tibia and the fibula. The bone transport technique was used to bridge the gap in her tibia, but her fibula was left as it was as it is possible to function very well without it. She was fitted with an Ilizarov circular fixator and a corticotomy was performed on the distal tibia. The bone was gradually distracted, a segment of bone being pulled up, at a rate of 0.25mm four times per day toward the docking site.

In figure 7, we can just see the bone segments beginning to be pulled apart, and we can clearly see the extent of the gap which needs bridging.

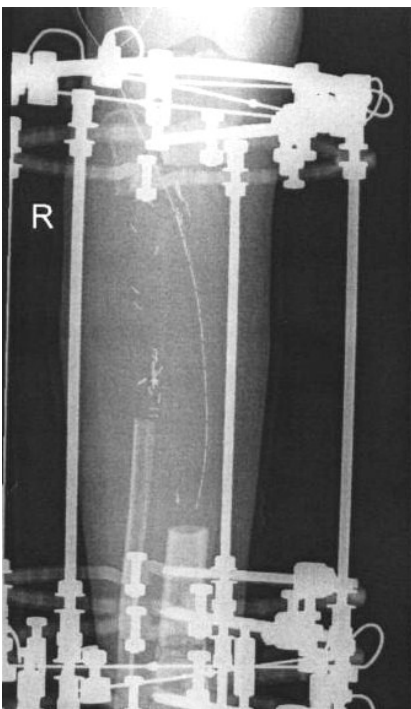


Figure 7

Figure 8 is an X-ray taken just over two months after the frame was fitted. Here we can see the bone segment has travelled about one third of the total distance, and we can begin to see bony consolidation in the distraction gap.

After five months of distraction the bone segment is nearly at the docking site, and we can see the consolidation of the bone below (figure 9).




Figure 8

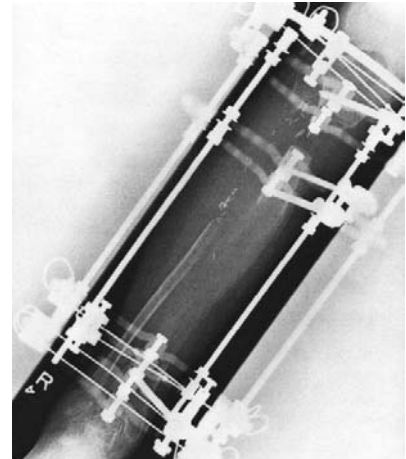


Figure 9

Acute Trauma Applications of the Ilizarov method

After the preservation of life, for patients who suffer from multiple fractures or poly-trauma conditions, the preservation of normal limb function with minimal complications is the top priority. The goal is that the patient has stable limbs of equal length and without deformation, well functioning muscles, a good range of movement through the joint, and is free of pain. Also important is that the time of disability is minimal and as few surgical procedures as possible are performed. By and large, the Ilizarov external fixation technique enables the achievement of these goals. (Ilizarov & Rozbruch, 2007)

The Ilizarov external fixator is particularly advantageous in situations when there is poor soft tissue coverage, or in the case of wound contamination. The circular ring fixator is also much more stable than a monolateral fixator so is used successfully for multiple level stabilization in the case of segmental fractures and allows early weight bearing. The circular fixator can also be used when intramedullary nailing of the bone is impossible or unsuitable, for example in the elderly due to osteoporotic bone and deficient soft tissues. (McNally & Catagni, 2002)

One of the main complications of the external fixator is pin tract infection. A superficial infection often occurs in areas where the skin is tensioned during bone transport and lengthening. Most small infections can be treated with oral antibiotics and pin site care. If the infection persists, it can be necessary to replace the half pin or wire. If left untreated, the infection can become severe and spread to the bone, causing osteomyelitis. Nerve injury is also a risk, but this should not occur if proper anatomic positioning of the wires is carried out. (Ilizarov & Rozbruch, 2007)

Conclusion

The Ilizarov technique is hugely complicated and requires a great deal of expertise to perform successfully. Extensive knowledge of human anatomy is essential, in order to reduce the risk of nerve or vascular damage. The vast amount of time it takes to acquire the necessary training means there are few surgeons suitably trained to perform this technique.

For the patient, the Ilizarov method of treatment and the external circular fixator are by no means easy; some patients are required to wear the frame for many months, and the process is slow and can be painful. Considerable physiotherapy is required to prevent permanent joint stiffness, which relies on extreme patient compliance. Pin site infection is common and so patients must be diligent in their pin site care. As we have seen, the Ilizarov method carries with it a range of possible complications, some more common or more serious than others.

Although laborious, when successful, the Ilizarov method is of dramatic benefit to the patient. For example, patients with limb length discrepancies or limb deformities can find life very difficult, both physically and psychologically, as well as it having detrimental consequences on other parts of the body, especially joints. For other patients, the Ilizarov method offers an alternative to amputation; in the past, patients with osteomyelitis where large segments of bone had to be removed would have had no option but to have an amputation, but thanks to the Ilizarov method and bone transport techniques amputation is now usually only a last resort and these patients can live normal lives without hindrance.

Works Cited

- Abdel-Aal, A. M. (2006). Ilizarov Bone Transport for Massive Tibial Bone Defects. *Orthopedics*. [Online] 29(1):70-74. Available from: <http://www.orthosupersite.com/view.aspx?rid=5170> [Accessed 11th November 2010]
- Aronson, J. e. (1989). The histology of distraction osteogenesis using different external fixators. *Clinical Orthopaedics and Related Research*. [Online] (241):106-116. Available from: <http://www.ncbi.nlm.nih.gov/pubmed/2924454> [accessed 10th November 2010]
- Aronson, J. (1994). Temporal and Spatial Increases in Blood Flow During Distraction Osteogenesis. *Clinical Orthopaedics and Related Research*. [Online] (301):124-131. Available from: http://journals.lww.com/corr/abstract/1994/04000/temporal_and_spatial_increases_in_blood_flow.20.aspx [accessed 10th November 2010]
- Barbarossa, V. e. (2001). Treatment of Osteomyelitis and Infected Non-union of the Femur by a Modified Ilizarov Technique: Follow-up Study. *Croatian Medical Journal* , 42(6):634-641.
- Codivilla, A. (1904). On the means of lengthening, in the lower limbs, the muscles and tissues which are shortened through deformity. *Am J Orthopedic Surgery* , 2:353.
- Ilizarov, G. A. (1989). The tension-stress effect on the genesis and growth of tissues: Part II. The influence of the rate and frequency of distraction. *Clinical Orthopaedics and Related Research*. [Online] (239):263-285. Available from: <http://www.ncbi.nlm.nih.gov/pubmed/2912628> [accessed 10th November 2010].
- Ilizarov, S., & Rozbruch, S. R. (2007). *Limb Lengthening and Reconstruction Surgery*. New York: Informa Healthcare USA Inc.
- Marcellin-Little, J. (1999). *Treating Bone Deformities with Circular External Fixation*. [Online] Available from: <http://www.scribd.com/doc/23752606/Treating-Bone-Deformities-With-Circular-External-Skeletal-Fixation> [Accessed 1st November 2010].
- McNally, M. A., & Catagni, M. A. (2002). Principles of Circular External Fixation in Trauma. In: C. e. Bulstrode, *Oxford Textbook of Orthopedics and Trauma. Volume 3* (pp. pp.1736-1748). Oxford: Oxford University Press.
- Mencio, G. (1992). *The Ilizarov Procedure: limb lengthening and its implications*. Retrieved November 7, 2010, from The Free Library: [http://www.thefreelibrary.com/The Ilizarov procedure: limb lengthening and its implications-a011873017](http://www.thefreelibrary.com/The+Ilizarov+procedure%3A+limb+lengthening+and+its+implications-a011873017)
- Paley, D. (1990). Problems, Obstacles and Complications of Limb Lengthening by the Ilizarov Technique. *Clinical Orthopaedics and Related Research* , (250):81-104.
- Popova, L. A. & Khodesevich, N. I. (1984) Ilizarov Method in Science and Practice: It's Economic and Social Significance. In: *Transosseous Compression-Distraction Osteosynthesis in Trauma and Orthopaedics*. Kurgan. pp 63-68
- Rallis Orthopedic Hospital. (2010). *Reconstruction and Limb Lengthning by Ilizarov* [Online] Available from: http://www.ralishospital.com/about_ilizarov.html [Accessed 10th November 2010]

Rozbruch, R. S. (2006). Correction of Tibial Deformity with Use of the Ilizarov-Taylor Spatial Frame. *The Journal of Joint and Bone Surgery*. [Online] (88):156-175. Available from: doi:10.2106/JBJS.F.00745. [Accessed 10th November 2010].

Velazquez, R. J. (1993). Complications of use of the Ilizarov technique in the correction of limb deformities in children. *The Journal of Bone and Joint Surgery* , 75 (8),1148-1156.

Wagner, H. (1978). Operative lengthening of the femur. *Clinical Orthopedics and Related Research* , 136:125.

Bibliography

Sinae Hospital. (2010) *Bone Deformities*. [Online] Available from: http://www.lifebridgehealth.org/body_rubin.cfm?id=1520 [Accessed 10th September 2010].

Farmanullah et al. (2007) Evaluation of management of tibial non-union defect with Ilizarov fixator. *Journal of Ayub Medical College, Abbottabad*. 19(3) 34-36.

O’Carrigan, T. (2010) *Limb Lengthening and Reconstruction*. [Online] Available from: <http://www.limblengthening.com.au/lengthening.html> [Accessed 11th September 2010].

Cleveland Clinic. (2010) *Limb Salvage*. [Online] Available from: http://my.clevelandclinic.org/services/limb_salvage/or_overview.aspx [Accessed 11th September 2010].

Centre for Ilizarov Techniques. (2010) *Limb Lengthening*. [Online] Available from: <http://www.ilizarov.org/ll.pdf> [Accessed 15th September 2010]

Paley, D. (2010) *Limb Lengthening Introduction*. [Online] Available from: http://www.limblengtheningdoc.org/limb_lengthening_intro.html [Accessed 9th September].

Rose, REC. (2006) Femoral Lengthening using the Ilizarov Technique. *West Indian Medical Journal*. 55(6) 420-424.

Medicine Plus. (2010) *Blount’s Disease*. [Online] Available from: <http://www.nlm.nih.gov/medlineplus/ency/article/001584.htm> [Accessed 15th September 2010].

Nuffield Orthopaedic Centre. (2007) Ilizarov fixation for the correction of Bone Deformity Limb Reconstruction and Limb Lengthening. Pre-operative patient information.

Silver, C., Juppner, H. (2005) Enchondromatosis. *Orphanet Encyclopedia*. [Online] Available from: <http://www.orpha.net/data/patho/GB/uk-Enchondromatosis.pdf> [Accessed 16th September 2010].

Brazy, P C. (2006) *Hypophosphatemic Rickets*. [Online] Available From: <http://www.merckmanuals.com/home/sec11/ch146/ch146g.html> [Accessed 16th September].

Cluett, J. (2006) *Nonunion*. [Online] Available from: <http://orthopedics.about.com/od/castsfracturetrements/g/nonunion.htm> [Accessed 1st October 2010].

American Academy of Orthopaedic Surgeons. (2007) *Nonunions* [Online] Available from: <http://orthoinfo.aaos.org/topic.cfm?topic=A00374> [Accessed 1st October 2010].

Jochen, H et al. (1996) Hypophosphataemic Rickets in Adults and Children. *Nephrology Dialysis Transplantation*. [Online] 11(9) 1918-19. Available from: <http://ndt.oxfordjournals.org/content/11/9/1918.full.pdf+html> [Accessed 19th September 2010].

REOrthopaedics, inc. (2010) *Deformity Correction/Limb Lengthening*. [Online] Available from: <http://www.osteomyelitis.com/html/deformity.html#fixation> [Accessed 23rd October 2010].

Gateley, D R. Et al. (1996) Ilizarov Bone Transport for the Treatment of Chronic Osteomyelitis: A Rare Complication. *The Journal of the Royal Society of Medicine*. [Online] 89, 348P-350P. Available from: <http://www.ncbi.nlm.nih.gov/pmc/articles/PMC1295829/pdf/jrsocmed00054-0054.pdf> [Accessed 20th October 2010].

Rose, R. Acute Trauma Applications of the Ilizarov Method. *The Internet Journal of Orthopedic Surgery* [Online] 16(1). Available from: http://www.ispub.com/journal/the_internet_journal_of_orthopedic_surgery/volume_16_number_1_2/article/acute-trauma-applications-of-the-ilizarov-method-5.html [Accessed 25th October 2010].

NHS Choices (2009). *Osteomyelitis*. [Online]. Available from: <http://www.nhs.uk/conditions/Osteomyelitis/Pages/Introduction.aspx> [Accessed 30th September 2010].

Arron, A D. (1996) Results of the Wagner and Ilizarov Methods of Limb-Lengthening. *Journal of Bone and Joint Surgery*. [Online] 78, 20-29. Available from: <http://www.ejbs.org/cgi/content/abstract/78/1/20> [Accessed 1st November 2010].

Smith, D N., Harrison. M H M. (1979) The correction of Angular Deformities of Long Bones by Osteotomy-Osteoclasia. *The Journal of Bone and Joint Surgery*. [Online] 61-B(4) Available from: <http://web.jbjs.org.uk/cgi/reprint/61-B/4/410.pdf> [Accessed 29th October 2010].