

# CASE REPORT

## Treatment of recurrent pterygium with topical administration of interferon alpha-2b: A case report

Mohammad Hossien Davari<sup>✉1</sup>, Hoda Ghitasi<sup>2</sup>, Esmat Davari<sup>3</sup>

<sup>1</sup> *Birjand Atherosclerosis and Coronary Artery Research Center, Birjand University of Medical Science, Birjand, Iran;*

<sup>2</sup> *Department of Genetic, PhD student of genetic at University of Barcelona translational research, laboratory2 Hospital Duran I Reynolds, Barcelona, Spain;*

<sup>3</sup> *Nurse, member of Research committee, Birjand University of Medical Science, Birjand, Iran.*

Received: October 24, 2015

Revised: January 10, 2016

Accepted: January 10, 2016

### Abstract

Pterygium is characterized by an elastic degeneration of the conjunctiva that extends across the limbos and invades the cornea. The recurrence rate is varied from 25-80% after primary closure to 6% with free conjunctival and limbal grafts. Several adjunctive therapies have been investigated for recurrent pte-rygium. This article presents a 52-year-old athletic man who was seen for evaluation of a recurrent lesion in his right eye and treated with topical administration of IFN- $\alpha$ -2b (Intron A, Schering Plough, Kenilworth, NJ), 1 million units/mL 4 times a day as eye drops.

**Key Words:** Recurrent pterygium; Interferon alpha-2b; Topical administration

### Introduction

Pterygium is characterized by an elastic degeneration of the conjunctiva that extends across the limbos and invades the cornea [1, 2]. The main risk factor is excessive exposure to ultraviolet (UV) radiation, dust, wind, heat, dryness, and smoke [2]. Several surgical and medical methods of treatment have been described: surgical excision with bare sclera, administration of mitomycin C, use of free autologous conjunctival and limbal grafts,  $\beta$ -irradiation, and amniotic membrane placement [3-5].

The recurrence rate is varied from 25-80% after primary closure to 6% with free conjunctival and limbal grafts [6-8]. Recurrent pterygium has predominantly fibroblastic proliferation and neovascularization, which is of highly more prominence than the elastic conjunctival

degeneration of a primary pterygium. Extensive surgical excision for recurrence or large lesions can lead to further limbal stem cell deficiency and cicatrice changes in the ocular surface.

For these reasons, many adjunctive therapies have been investigated for the treatment of recurrent pterygium [9, 10]. Interferon are glycoproteins that have been shown to have anti-proliferative and antiviral effects. While the exact mechanism of action of interferon is unknown, the recombinant form of interferon alpha-2b (IFN- $\alpha$ -2b) has been used with good results in conjunctival intraepithelial neoplasia and conjunctival papilloma [11, 12]. Because of interferon's anti proliferative effect, I decided to try using IFN- $\alpha$ -2b topically.

©2015 Journal of Surgery and Trauma

Tel: +985632443041 (5533)

Fax: +985632440488

Po Bax 97175-379

Email: jsurgery@bums.ac.ir



✉ Correspondence to:

Mohammad Hossien Davari; Assistant professor of ophthalmology, Birjand Atherosclerosis and Coronary Artery Research Center, Birjand University of Medical Science, Birjand, Iran;

Telephone Number: +989151611115

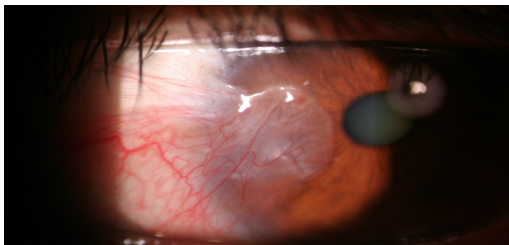
Email Address: mhd\_1337@yahoo.com

## Cases

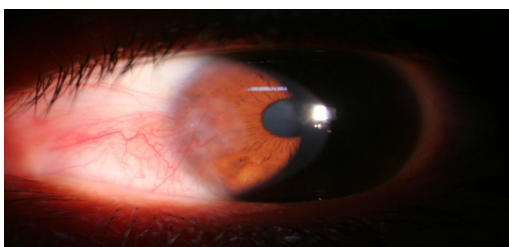
A 52-year-old athletic man was seen for evaluation of a recurrent lesion in his right eye. Three months earlier, a nasal pterygium had been exercised and a free autologous conjunctival graft placed. After 6 months he had started to note increasing eye redness, foreign body sensation and photophobia. At this examination, his best corrected visual acuity was 20/25 in the right eye and 20/20 in the left eye. The left eye had a normal appearance. The right eye showed, adjacent to the surgical scar, a vascularized, highly fibrotic lesion measuring 3.0 x 2.0 mm that had invaded the corneal limbal area 1.5 mm (Fig. 1). There were adjacent conjunctival irregularity and rose Bengal staining.

After considering all treatment options, the patient elected to try topical administration of IFN- $\alpha$ -2b (Intron A, Schering Plough, Kenilworth, NJ), 1 million units/mL 4 times a day as eye drops.

Within 4 weeks, the new vessels had regressed significantly and the lesion was visibly smaller. An asymptomatic follicular reaction of the conjunctiva was noted at the 6th-week follow-up visit, and by 3 months there was no clinical evidence of recurrence (Fig. 2). The interferon dosage was tapered to once daily for 1 more month. The follicular reaction resolved with cessation of treatment. At the time of writing, the man had remained recurrence-free for 36 months.



**Fig 1:** A vascularized, highly fibrotic lesion in the right eye



**Fig 2:** the lesion was visibly smaller 4 weeks after topical administration of IFN- $\alpha$ -2b in the right eye

## Discussion

Surgical excision of pterygium is associated with more recurrence. Therefore, several surgical and medical methods of treatment have been described, including the use of mitomycin C [3-5].

Low-dose subconjunctival mitomycin C is effective in preventing pterygium recurrence yet avoids the ocular surface toxicity associated with epithelial and bare sclera delivery of the medication. Intra-operative mitomycin and postoperative mitomycin are two of the methods of adjunctive therapy that have been most commonly reported [13]. Most of the complications of mitomycin C are associated with persistent epithelial defects and ischemic scleral necrosis. Both of these complications are secondary to side-effects produced by the direct action of mitomycin C on these tissues.

Conjunctival epithelium and sclera should be avoided not only because the epithelium and sclera are not target tissues for the mitomycin C but also because inadvertent treatment of these tissues cannot contribute to the prevention of pterygia recurrence but are rather associated with significant side effects. In our study, topical administration of IFN- $\alpha$ -2b (Intron A, Schering Plough, Kenilworth, NJ) was not seen along with these complications.

## Conclusions

Topical administration of IFN- $\alpha$ -2b is an effective treatment in recurrent pterygium, but follow up is required in the long term.

## References

1. Hirst LW. The treatment of pterygium. *Surv Ophthalmol.* 2003;48(2):145-80.
2. Pang Y, Rose T. Rapid growth of pterygium after photorefractive keratectomy. *Optometry.* 2006;77(10):499-502.
3. Sodhi PK, Verma L, Ratan SK. The treatment of pterygium. *Surv Ophthalmol.* 2004;49(5):541-2.
4. Panda A, Das GK, Tuli SW, Kumar A. Randomized trial of intraoperative mitomycin C in surgery for pterygium. *Am J Ophthalmol.* 1998;125(1):59-63.
5. Wan Norliza WM, Raihan IS, Azwa JA, Cibrabim M. Scleral melting 16 years after pterygium excision with topical Mitomycin C adjuvant therapy. *Cont Lens Anterior Eye.* 2006;29(4):165-7.
6. Figueiredo RS, Cohen EJ, Gomes JA, Rapuano CJ, Laibson PR. Conjunctival autograft for pterygium surgery: how well does it prevent recurrence? *Ophthalmic Surg Lasers.* 1997;28(2):99-104.

7. Kenyon KR, Wagoner MD, Hettinger ME. Conjunctival autograft transplantation for advanced and recurrent pterygium. *Ophthalmology*. 1985; 92(11):1461-70.
8. Lewallen S. A randomized trial of conjunctival autografting for pterygium in the tropics. *Ophthalmology*. 1989; 96(11):1612-4.
9. Frucht-pery J, Raiskup F, Ilsar M, Landau D, Orucov F, Solomon A. Conjunctival autografting combined with low-dose mitomycin C for prevention of primary pterygium recurrence. *Am J Ophthalmol*. 2006; 141(6):1044-50.
10. Gandolfi SA, Vecchi M, Braccio L. Decrease of intraocular pressure after subconjunctival injection of mitomycin in human glaucoma. *Arch Ophthalmol*. 1995;113(5):582-5.
11. Glue P, Fang JW, Rouzier-Panis R, Raffanel C, Sabo R, Gupta SK, et al. Pegylated interferon-alpha2b: pharmacokinetics, pharmacodynamics, safety, and preliminary efficacy data. Hepatitis C Intervention Therapy Group. *Clin Pharmacol Ther*. 2000;68(5):556-67.
12. Schechter BA1, Schrier A, Nagler RS, Smith EF, Velasquez GE. Regression of presumed primary conjunctival and corneal intraepithelial neoplasia with topical interferon alpha-2b. *Cornea*. 2002;21(1):6-11.
13. Raiskup F, Solomon A, Landau D, Ilsar M, Frucht-Pery J. Mitomycin -C for pterygium: long term evaluation. *Br J Ophthalmol*. 2004;88(11):1425-8.