



Dynamic compression system for the correction of pectus carinatum

Marcelo Martinez-Ferro, MD,^a Carlos Fraire, MD,^b Silvia Bernard, MD^b

From the ^aDepartment of Pediatric Surgery, Fundacion Hospitalaria's Private Children's Hospital, Buenos Aires, Argentina, and the

^bJ.P. Garrahan National Children's Hospital, Buenos Aires, Argentina.

KEYWORDS

Pectus carinatum;
 Chest wall deformity;
 Pigeon breast;
 Compression;
 Orthotic bracing;
 Nonoperative
 treatment

Between April 2001 and 2007, we treated 208 patients with pectus carinatum by using a specially designed dynamic compression system (DCS) that uses a custom-made aluminum brace. Recently, an electronic pressure measuring device was added to the brace. Results were evaluated by using a double-blinded subjective scale (1 to 10). A total of 208 patients were treated over 6 years; 154 were males (74%) and the mean age was 12.5 years (range 3 to 18 years). Mean utilization time was 7.2 hours daily for 7 months (range 3 to 20 months). A total of 28 (13.4%) patients abandoned treatment and were not evaluated for final results. Of the 180 remaining patients, 112 completed treatment. A total of 99 of 112 (88.4%) had good to excellent results scoring between 7 and 10 points, and 13 (11.6%) patients scored 1 to 6 points and were judged as poor or failed results. The "Pressure for Initial Correction" (PIC) in pounds per square inch (PSI) proved that starting treatment with less than 2.5 PSI avoids skin lesions. Patients who require pressures higher than 7.5 PSI should not be treated with this method. We found a good correlation between PIC versus treatment duration and outcome. DCS is an effective treatment for pectus carinatum with minimal morbidity. We suggest that patients with pectus carinatum have a trial of compression therapy before recommending surgical resection. The use of pressure measurement avoids complications such as skin lesions, partial or poor results, and patient noncompliance.

© 2008 Elsevier Inc. All rights reserved.

Pectus carinatum (PC) is a common pediatric condition characterized by an abnormal overgrowth of the costal cartilages, which results in protrusion of the sternum and adjacent costal cartilages (Figure 1). In our Chest Wall Deformities Clinic, consultation for PC is more frequent than for pectus excavatum, as observed in Figure 2.

PC is observed more frequently in males than in females (4:1 ratio) and may occur in association with Marfan's syndrome, scoliosis (15%), and other connective tissue disorders. The cause of PC is unknown; however, it may be

genetically linked considering its frequent occurrence in families.¹

Surgery has been the treatment of choice for PC over the last 50 years.² Most of the existing techniques are modifications of the Ravitch procedure that use resection of the deformed costal cartilages along with sternal osteotomy.^{3,4} Recently, there have been publications that propose less radical resection but still remain major surgical procedures.⁵⁻⁷ Because of the risks associated with any major surgical procedure, surgical resection has been reserved for the most severe cases, thus leaving many of the patients untreated.⁸

More recently, several authors have suggested a variety of alternative nonoperative approaches based on the fact

Address reprint requests and correspondence: Marcelo Martinez-Ferro, MD, Cramer 4601 (1429), Oficina de Cirugia, 3er piso, Ciudad Autonoma de Buenos Aires, Argentina.

E-mail: martinezferro@fibertel.com.ar.

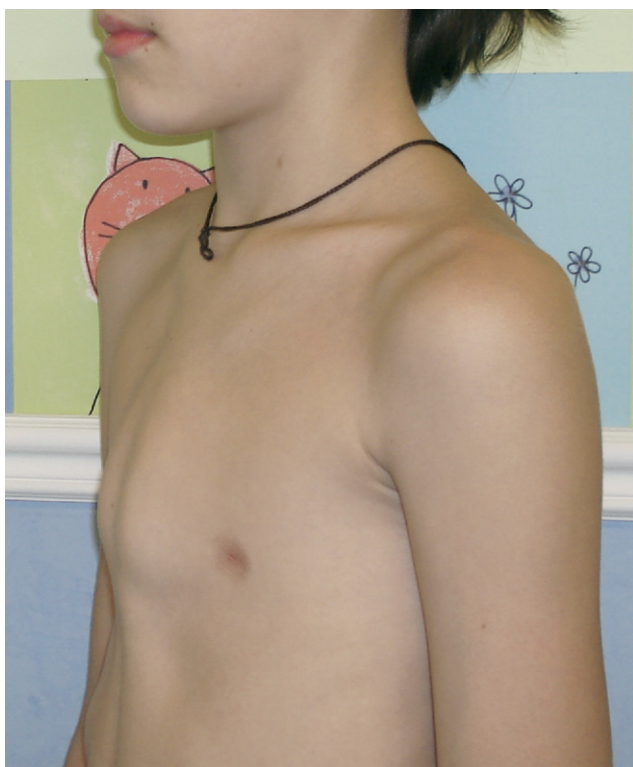

Figure 1 Patient with chondrogladiolar PC at initial consultation. (Color version of figure is available online.)

that the anterior chest wall is still compliant during puberty and permits remodeling by applying external compression.⁹⁻¹²

Since 2001, we started with a similar technique almost simultaneously with most of these authors using the same concepts, but added a quantifiable variant: the pressure for initial correction (PIC).

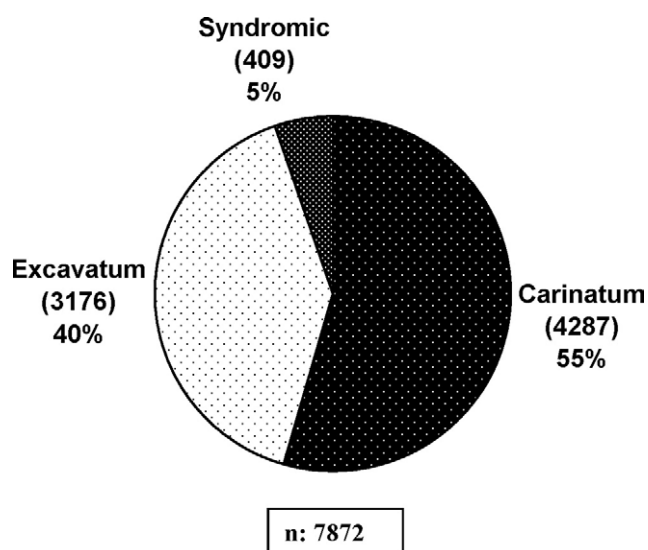


Figure 2 Diagnosis of the patients who consulted the “Thoracic Wall Deformities” clinic from April 1989 to April 2007. Patients with Poland Syndrome, Marfan, Noonan, etc., are included in the “Syndromic” group.

Table 1 Surgical approach versus non-surgical approach for treatment of PC

	Surgical (modified Ravitch; <i>n</i> = 94)	Non-surgical (DCS; <i>n</i> = 112)
Operative time (hours)	3.5	0
Hospital stay (days)	5.2	0
Deaths	0	0
Overall complications	22%	12.5%
Excellent + good results	89%	88.4%
Fair results	8%	7.1%
Poor results	3%	4.5%

Our experience before 2001 using a modified Ravitch technique is summarized in Table 1.

In these 94 surgical patients, the overall complication rate with open surgery was 22%. The most frequent complications observed were wound infection in 12 patients (12.7%), pleural effusion in 6 (6.3%), pneumothorax in 5 (5.3%), recurrence in 12 (12.7%), and hypertrophic scarring in 16 (17.0%).

The following paper summarizes our most recent 6-year experience using a nonsurgical approach by means of an external dynamic compression system (DCS) and the data observed by measuring the PIC in a group of patients with PC deformity.

Materials and methods

Dynamic compressor system

The DCS is a custom-fitted, low-profile aluminum brace that is adaptable to the sternal protrusion. The brace is assembled by using multiple light-weight aluminum curved segments to obtain a rigid belt that surrounds the thoracic wall at the level of the defect. One unique cushioned compression plate is attached to the anterior segment of the brace and placed at the level of the protrusion. By pushing the sternum backward, the continuous anterior–posterior chest compression gradually reshapes the chest into a normal position.

An adjustable lateral tension device permits gradual regulation during treatment. In addition, each curved aluminum segment can be replaced or adjusted to obtain extra widening as needed.

PIC is obtained at the time of the first consultation. A specially designed measuring device is applied over the deformity until a normal thoracic shape is obtained. PIC is measured in pounds per square inch (PSI) (Figure 3).

Following the measurements obtained at the first consultation, a DCS is assembled for each patient. Because anterior–posterior compression provokes lateral thoracic expansion, the device is designed in such a way that lateral expansion is permitted (Figure 4).

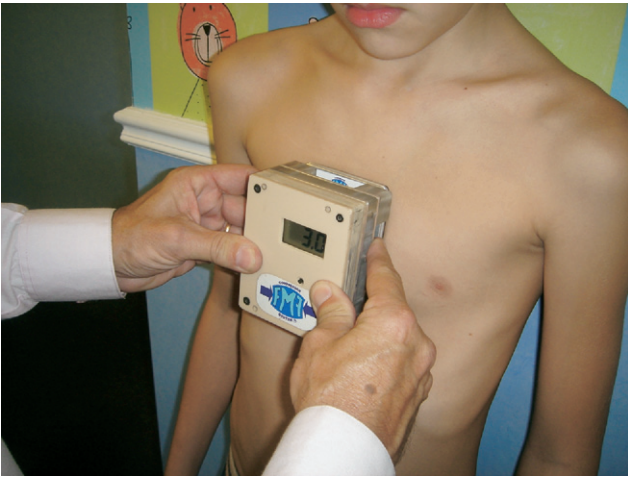


Figure 3 Same patient as in Figure 1, demonstrating measurement of the PIC in PSI. Note that this patient needs a pressure of 3 PSI for correction. (Color version of figure is available online.)

For regulation of the pressure of treatment (POT), the electronic pressure measuring device is attached to the brace by using a specially designed docking system (Figure 5). This permits one to adjust the correction pressure to the desired level and prevents one from making the pressure too high, as that will cause pressure necroses and/or noncompliance (Figure 6).

Patients are instructed to wear the brace overnight and as much as possible during the day, depending on their activities. They are only allowed to remove the compressor during sports and while having a shower.

After the initial brace fitting, patients are checked monthly until complete correction is achieved.

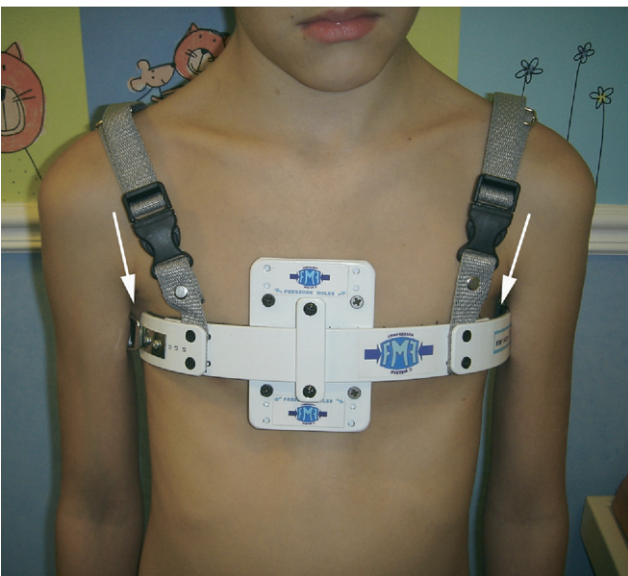


Figure 4 Dynamic compressor in place. Note the lateral space (arrows) that permit lateral thoracic expansion while breathing. The device is prepared for the attachment of a docking station for pressure determination and set up. (Color version of figure is available online.)

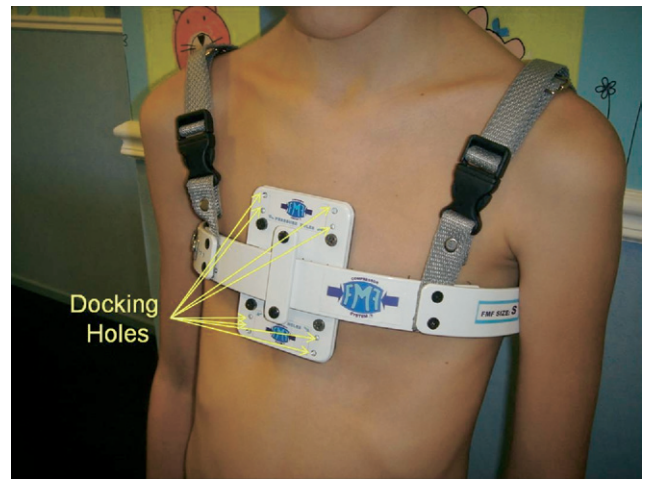


Figure 5 The POT is regulated by attaching the electronic pressure measuring device to the brace by means of a specially designed "docking system." (Color version of figure is available online.)

Patients

Between April 2001 and April 2007 we treated 232 PC patients with this new system; 154 were males (74%) and the mean age was of 12.5 years (range 3 to 18 years). A total of 24 (10.3%) patients with Marfan or Poland syndromes or those who presented with complex carinatum/excavatum malformations were excluded from this study.

Of the remaining 208 patients, 28 (13.4%) patients abandoned treatment and could not be evaluated for final results.

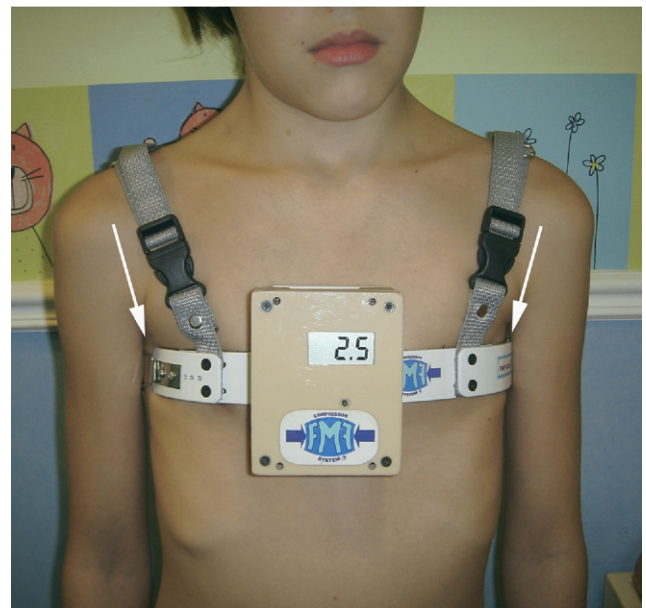


Figure 6 Docking station in place. Although the PIC is 3 PSI, the POT has been set at 2.5 PSI during maximal inspiration to avoid skin ulceration. Note that, at maximal inspiration, there is no lateral space left (arrows). (Color version of figure is available online.)

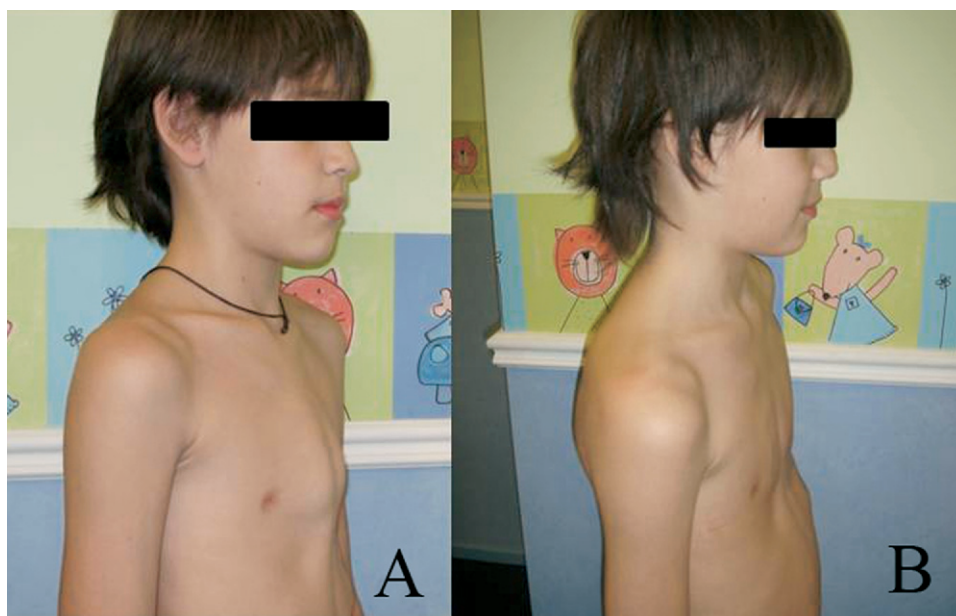


Figure 7 Same patient as Figures 1-6 with a chondrogladiolar PC before treatment (A) and after 3 months of treatment (B). (Color version of figure is available online.)

Of the 180 remaining patients, 112 have completed the treatment, and 68 are still using the device. The mean time of use per patient was 7.2 hours per day for 7 months (range 3 to 20 months). For evaluation of the results, a double-blinded (Patient–Doctor) subjective scale (1-10) was designed and applied. At the end of the treatment, at the time of the last examination, patients or parents (depending on age) were asked to judge the final outcome from 1 to 10. Each treating physician on the team also submitted an undisclosed judgment. The lowest 2 numbers were used for the final result. Historical pictures of each patient were available at any time for consultation at the physician’s desk.

Measurement of PIC in PSI was available for the last 107 patients. For this measurement, the patient is asked to stand up against a wall facing the physician. A pressure-measuring device is applied directly against the thoracic wall at the point where the protrusion is most evident. The thorax is gradually compressed until a “normal shape” is obtained. The process is repeated 3 times, and the average pressure required is considered the PIC.

Measurement of POT is achieved by attaching a docking station to the anterior segment of the DCS (Figure 6). POT was available for the last 43 cases and is measured during every consultation and DCS adjustment.

Treatment was terminated when the surgeon and patient (or parents) agreed that the deformity was corrected.

Results

Of the 24 patients who abandoned treatment, 2 declared pain and 4 reported skin intolerance as the cause of non-compliance; the other 15 claimed social discomfort, and 3 patients were lost to follow-up.

Of the 180 remaining patients, 112 have completed the treatment. Applying the previously described scale, 99/112 (88.4%) achieved a 7- to 10-point correction (excellent, very good, and good results) (Figures 7-9), and 13 (11.6%) patients achieved only 1- to 6-point corrections (poor and bad results).

Of the 107 patients in whom PIC measurement was available, the mean PIC value was 3.7 PSI (range 0.4 to 9.5 PSI).

Patients were divided into three groups depending on their PIC. Table 2 shows the correlation between the three groups versus final results and treatment duration.

Lately, as POT has been available, observational experience demonstrates that better tolerance was achieved by avoiding pressures over 2.5 PSI, thus preventing skin ulceration.

Complications were observed in 14 of the 112 patients (12.5%) who completed treatment. Complications observed were back pain ($n = 8$), hematoma ($n = 1$), and skin ulceration ($n = 5$). No other complications were observed, and although the complications caused a delay in completion of treatment in a few patients, none of them was the cause of treatment termination. Skin ulceration was mild in all cases and was treated by temporary withdrawal of the compressor and topical skin lotions.

Mean follow-up is 3.3 years (6.5 years to 6 months). During follow-up, 17 of 112 patients (15%) presented with a recurrence. Recurrence was mostly observed during periods of rapid growth and typically several months after treatment completion. All recurrences were mild, and all of them were successfully treated with dynamic compression. For this recurrent group, the same compressor was used by modifying its shape and size. All patients responded well

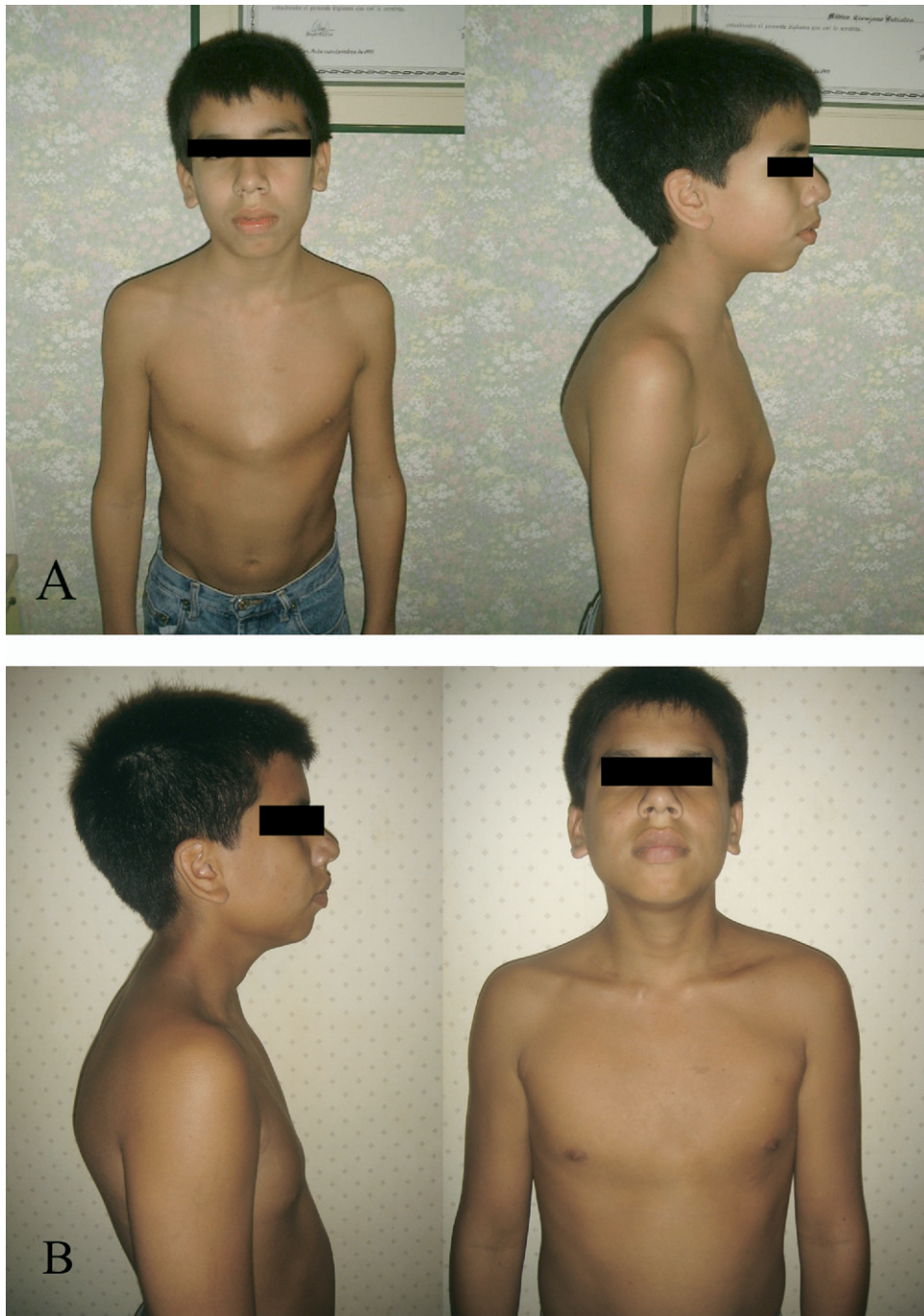

Figure 8 Patient with a symmetric chondrogladiolar PC. Before treatment (A) and after 8 months of treatment. Picture taken during long-term follow-up (2 years post-termination of treatment; B). (Color version of figure is available online.)

and were cured. Only 1 patient presented with 2 recurrences and successfully responded to both treatments.

Discussion

The Nuss procedure for pectus excavatum¹³ introduced a paradigm shift by demonstrating that the thoracic wall is a very elastic and malleable structure in children. Following this idea, early in the year 2000, we started a protocol with

the objective of treating PC patients using the same concept but with the advantage that, in these patients, there was no need for an implant as the protrusion could be compressed externally. At this time, except for the pioneer papers of Haje and coworkers,¹⁴⁻¹⁶ no other authors supported a non-operative approach for the treatment of these patients. By the beginning of 2001, the DCS design was finished and its protocol approved by our IRB.

Inspired by the same concept and starting almost simultaneously with us, several authors have suggested a variety

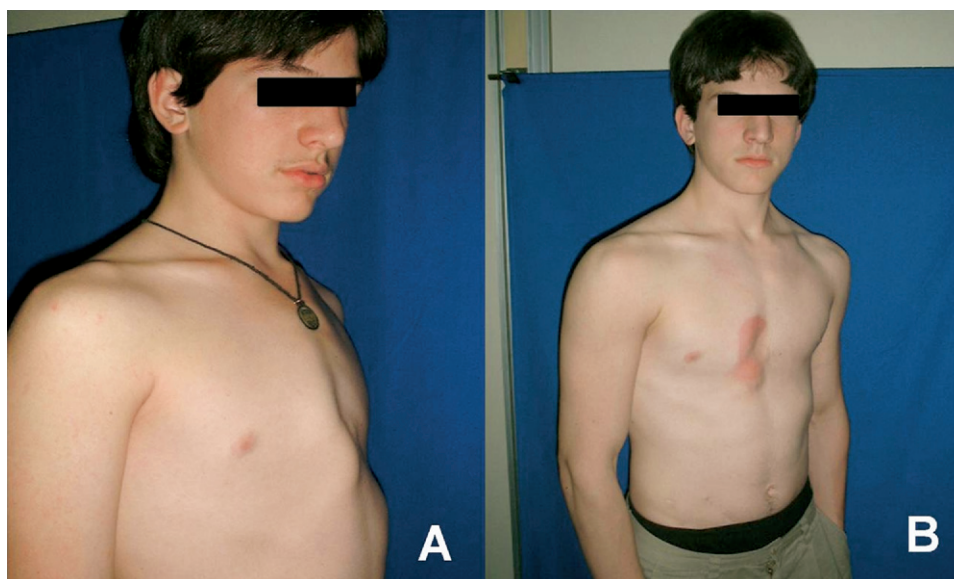

Figure 9 Patient with an asymmetrical PC. Before (A) and after 1 year of treatment (B). Picture taken at the moment of termination of treatment. Note the skin erythema over the compressed area. (Color version of figure is available online.)

of nonoperative approaches based on the same concept: that the anterior chest wall is still compliant during puberty and permits remodeling by applying external compression.⁹⁻¹²

Our results and conclusions are very similar to the above-mentioned recently published papers and help to support the nonoperative approach.

Comparing our own historical “open surgery” cases with our new “nonsurgical” approach, the benefits of the latter are obvious. Although the final cosmetic results are similar, the noninvasive treatment completely eliminates the risk of anesthesia and major surgery, decreases the complication rate, leaves no visible scar, avoids hospital admission, and dramatically reduces the cost of treatment.

When considering all of these factors and reviewing our own and other authors experience, there should be little doubt that no patient should be selected as a candidate for surgery before trying a nonoperative approach.

On the other hand, when analyzing our experience, at least two differences were established with the rest of the literature. In the first place, from the beginning, we understood that, as anterior–posterior compression is applied to the thorax, a considerable lateral thoracic widening is ob-

served. To achieve a good and effective thoracic re-shaping, the device that we had to design should permit this lateral expansion. Secondly, we noticed that, depending on the age and other factors, the pressure needed for thoracic re-shaping showed a big range between patients. At that time, we decided that measuring that pressure would be crucial for understanding and treating patients with PC.

When analyzing the pressure data, we can conclude that PIC can be used to predict treatment duration, as patients with pressures lower than 2.5 PSI were discharged twice as fast as those requiring pressures higher than 5 PSI (5 months versus 12 months). Although with less precision, PIC may predict the final outcome as group I patients had better results than those of groups II and III.

POT measurement permitted the additional observation that pressures greater than 2.5 PSI are less well tolerated, mostly because of skin ulceration. Consequently, in the last 43 patients in whom the device was available, POT was set up to be ≤ 2.5 PSI, and as a result, the DCS has been better tolerated with none of the recent patients dropping out of the treatment protocol up to this time.

We conclude that DCS is an effective tool for the treatment of patients with PC and that pressure of initial correction and pressure of treatment seem promising complementary resources.

Further experience will help to define which patients are better suited for nonoperative dynamic compression with pressure measurement.

Acknowledgments

We thank Nestor Valdetaro (Electromechanical Engineer) for the collaboration with the design and development

Table 2 Correlation between PIC versus final results and duration of treatment

	Group I (< 2.5 PSI)	Group II (2.5 - 5 PSI)	Group III (> 5 PSI)
Patients ($n = 107$)	42	51	14
Age (years)	11 (4-16)	13 (6-17)	15 (12-18)
Final results (1-10)	8.5 (7-10)	7.3 (5-8)	6 (2-9)
Duration of treatment (months)	5 (3 to 8)	7 (3-17)	12 (7 to 20)

of the DCS and the different pressure-measuring devices. We also thank Soluciones Maxilofaciales® for the unconditional support and funding.

References

1. Mégarbané A, Daou L, Mégarbané H, et al. New autosomal recessive syndrome with short stature and facio-auriculo-thoracic malformations. *Am J Med Genet A* 2004;128:414-7.
2. Welch KJ, Vos A. Surgical correction of pectus carinatum (pigeon breast). *J Pediatr Surg* 1973;8:659-67.
3. Ravitch MM. The operative correction of pectus carinatum. *Bull Soc Int Chir* 1975;34:117-20.
4. Fonkalsrud EW, Beanes S. Surgical management of pectus carinatum: 30 years' experience. *World J Surg* 2001;25:898-903.
5. Fonkalsrud EW, Anselmo DM. Less extensive techniques for repair of pectus carinatum: the undertreated chest deformity. *J Am Coll Surg* 2004;198:898-905.
6. Abramson H. A minimally invasive technique to repair pectus carinatum. Preliminary report. *Arch Bronconeumol* 2005;41:349-51.
7. Schaarschmidt K, Kolberg-Schwerdt A, Lempe M, et al. New endoscopic minimal access pectus carinatum repair using subpectoral carbon dioxide. *Ann Thorac Surg* 2006;81:1099-103.
8. Fonkalsrud EW. Pectus carinatum: the undertreated chest malformation. *Asian J Surg* 2003;26:189-92.
9. Kravarusic D, Dicken BJ, Dewar R, et al. The Calgary protocol for bracing of pectus carinatum: a preliminary report. *J Pediatr Surg* 2006;41:923-6.
10. Banever GT, Konefal SH, Gettens K, et al. Nonoperative correction of pectus carinatum with orthotic bracing. *J Laparoendosc Adv Surg Tech A* 2006;16:164-7.
11. Frey AS, Garcia VF, Brown RL, et al. Nonoperative management of pectus carinatum. *J Pediatr Surg* 2006;41:40-5; discussion 40-5.
12. Egan JC, DuBois JJ, Morphy M, et al. Compressive orthotics in the treatment of asymmetric pectus carinatum: a preliminary report with an objective radiographic marker. *J Pediatr Surg* 2000;35:1183-6.
13. Nuss D, Kelly RE Jr, Croitoru DP, et al. A 10-year review of a minimally invasive technique for the correction of pectus excavatum. *J Pediatr Surg* 1998;33:545-52.
14. Haje SA, Bowen JR, Harcke HT, Guttenberg ME, et al. Disorders in the sternum growth and pectus deformities: an experimental model and clinical correlation. *Acta Orthop Bras* 1998;6:67-75.
15. Haje SA, Bowen JR. Preliminary results of orthotic treatment of pectus deformities in children and adolescents. *J Pediatr Orthop* 1992;12:795-800.
16. Haje SA, Harcke HT, Bowen JR. Growth disturbance of the sternum and pectus deformities: imaging studies and clinical correlation. *Pediatr Radiol* 1999;29:334-41.