

Structural Brain Abnormalities in Youth With Psychosis Spectrum Symptoms

Theodore D. Satterthwaite, MD, MA; Daniel H. Wolf, MD, PhD; Monica E. Calkins, PhD; Simon N. Vandekar, BS; Guray Erus, PhD; Kosha Ruparel, MS; David R. Roalf, PhD; Kristin A. Linn, PhD; Mark A. Elliott, PhD; Tyler M. Moore, PhD; Hakon Hakonarson, MD, PhD; Russell T. Shinohara, PhD; Christos Davatzikos, PhD; Ruben C. Gur, PhD; Raquel E. Gur, MD, PhD

 Supplemental content

IMPORTANCE Structural brain abnormalities are prominent in psychotic disorders, including schizophrenia. However, it is unclear when aberrations emerge in the disease process and if such deficits are present in association with less severe psychosis spectrum (PS) symptoms in youth.

OBJECTIVE To investigate the presence of structural brain abnormalities in youth with PS symptoms.

DESIGN, SETTING, AND PARTICIPANTS The Philadelphia Neurodevelopmental Cohort is a prospectively accrued, community-based sample of 9498 youth who received a structured psychiatric evaluation. A subsample of 1601 individuals underwent neuroimaging, including structural magnetic resonance imaging, at an academic and children's hospital health care network between November 1, 2009, and November 30, 2011.

MAIN OUTCOMES AND MEASURES Measures of brain volume derived from T1-weighted structural neuroimaging at 3 T. Analyses were conducted at global, regional, and voxelwise levels. Regional volumes were estimated with an advanced multatlas regional segmentation procedure, and voxelwise volumetric analyses were conducted as well. Nonlinear developmental patterns were examined using penalized splines within a general additive model. Psychosis spectrum (PS) symptom severity was summarized using factor analysis and evaluated dimensionally.

RESULTS Following exclusions due to comorbidity and image quality assurance, the final sample included 791 participants aged youth 8 to 22 years. Fifty percent ($n = 393$) were female. After structured interviews, 391 participants were identified as having PS features (PS group) and 400 participants were identified as typically developing comparison individuals without significant psychopathology (TD group). Compared with the TD group, the PS group had diminished whole-brain gray matter volume ($P = 3.4 \times 10^{-4}$) when not accounting for intracranial volume and relatively expanded white matter volume when accounting for intracranial volume ($P = 2.2 \times 10^{-3}$). Voxelwise analyses revealed significantly lower gray matter volume in the medial temporal lobe (maximum z score = 5.2 and cluster size of 1225 for the right and maximum z score = 4.5 and cluster size of 310 for the left) as well as in frontal, temporal, and parietal cortex. Volumetric reduction in the medial temporal lobe was correlated with PS symptom severity.

CONCLUSIONS AND RELEVANCE Structural brain abnormalities that have been commonly reported in adults with psychosis are present early in life in youth with PS symptoms and are not due to medication effects. Future longitudinal studies could use the presence of such abnormalities in conjunction with clinical presentation, cognitive profile, and genomics to predict risk and aid in stratification to guide early interventions.

Author Affiliations: Department of Psychiatry, University of Pennsylvania Perelman School of Medicine, Philadelphia (Satterthwaite, Wolf, Calkins, Ruparel, Roalf, Moore, R. C. Gur, R. E. Gur); Department of Biostatistics and Clinical Epidemiology, University of Pennsylvania, Philadelphia (Vandekar, Linn, Shinohara); Department of Radiology, University of Pennsylvania, Philadelphia (Erus, Elliott, Davatzikos, R. C. Gur, R. E. Gur); Center for Applied Genomics, The Children's Hospital of Philadelphia, Philadelphia, Pennsylvania (Hakonarson).

Corresponding Author: Theodore D. Satterthwaite, MD, MA, Department of Psychiatry, University of Pennsylvania Perelman School of Medicine, 10th Floor, Gates Bldg, 34th and Spruce Street, Philadelphia, PA 19104 (sattertt@upenn.edu).

JAMA Psychiatry. 2016;73(5):515-524. doi:10.1001/jamapsychiatry.2015.3463
Published online March 16, 2016. Corrected on March 8, 2017.

Psychotic disorders have a devastating effect on the lives of patients and families, producing substantial morbidity and mortality.¹⁻³ Based on the early age at onset and convergent evidence from animal models, psychosis is increasingly conceptualized as a downstream product of abnormal neurodevelopment.⁴⁻⁷ A better understanding of the developmental antecedents of psychosis may lead to both early identification and novel targeted interventions.⁸⁻¹⁰

Adults with psychotic disorders, such as schizophrenia, have significant abnormalities of brain structure.¹¹⁻¹⁸ While initial studies examined modest samples, large meta-analyses have yielded consistent findings.^{11,13,15,16} Recently, the ENIGMA-SZ (Enhancing NeuroImaging Genetics Through Meta-Analysis-Schizophrenia) Consortium¹⁹ examined subcortical volumes from a sample totaling more than 2000 patients with schizophrenia and found reduced volume that was maximal in the hippocampus.²⁰ These results accord with a long line of research documenting structural and functional medial temporal lobe abnormalities.²¹⁻²⁷ Both meta-analyses and large-scale single-site studies examining cortical deficits have additionally provided evidence for diminished volume in frontal, temporal, and parietal brain regions.^{11,13,15,16} Subcortical and cortical volume reductions have also been reported in unaffected family members,²⁸⁻³⁰ suggesting that structural deficits are a heritable intermediate phenotype.

In contrast to large studies of adults with psychosis, studies of youth remain smaller. Most studies have examined either first-episode psychosis^{10,12,17,18,31-33} or youth at clinical high risk.^{10,12,31-33} These studies typically document attenuated patterns of gray matter volume reductions similar to those seen in adults with schizophrenia. The North American Prodrome Longitudinal Study consortium⁹ reported in 2015 that clinical high-risk youth who later convert to psychosis have accelerated gray matter loss in frontal cortex compared with non-converters and healthy comparators.³⁴ Beyond such studies of high-risk youth, it is also increasingly recognized that subtle psychosis spectrum (PS) symptoms are prevalent (5%-10%) among the general population.^{35,36} Psychosis spectrum symptoms can impact functioning,^{36,37} are associated with increased risk of conversion to a psychotic disorder,³⁸ and have been associated with neuroimaging abnormalities.³⁹⁻⁴²

Herein, we used a community-based approach to examine brain structure in a large sample of non-help-seeking youth with PS symptoms imaged as part of the Philadelphia Neurodevelopmental Cohort (PNC) of 9498 youth who received a structured psychiatric evaluation.⁴³ While such a design will likely produce lower rates of transition to frank psychosis than studying help-seeking clinical high-risk youth, understanding early subclinical psychotic symptoms may be valuable for elucidating the neurodevelopmental etiology of psychosis because it allows investigation of brain abnormalities at an earlier stage.⁴⁴⁻⁴⁷ To our knowledge, there has been only one small study⁴² of developmental structural abnormalities in community youth with PS symptoms, and it is unknown whether PS symptoms in this population demonstrate patterns of volume reduction similar to those found in clinical risk and adult psychosis samples. Similarities to adult clinical phenotypes would provide support for a dimensional view of psychotic

symptoms^{4,48,49} and support examination of these phenotypes at younger ages and milder severity levels.⁴⁴⁻⁴⁷

We hypothesized that youth with PS symptoms would demonstrate abnormalities of structural brain development. Specifically, we expected that youth with PS symptoms would show reduced gray matter volume in regions similar to those impacted in adults with frank psychosis, such as the medial temporal lobe. We used nonlinear analyses of developmental patterns to investigate structural deficits on multiple scales, including analyses of global volumes, lobar volumes, and high-resolution voxelwise analyses. As described below, this approach yielded novel evidence for structural brain abnormalities in youth with PS symptoms that show parallels to those seen in adults with clinically diagnosed psychotic disorders.

Methods

Participants

Of the 1601 participants imaged as part of the PNC, 172 were excluded due to comorbidity, including medical illness that could affect brain function ($n = 73$), incomplete data ($n = 1$), nonpsychiatric medication with potential central nervous system effects ($n = 78$), or an incidentally encountered structural abnormality that distorted normal brain anatomy ($n = 20$).⁵⁰ Of the remaining 1429, PS symptoms were present in 408 participants, as defined in prior reports^{36,37,39,40,51} using the GOASSESS interview,³⁶ which includes elements of the K-SADS (Schedule for Affective Disorders and Schizophrenia for School-Age Children), PRIME screen, and Scale of Prodromal Symptoms (eMethods in the [Supplement](#)).⁵²⁻⁵⁴ Notably, this community-based ascertainment strategy is distinct from studies of help-seeking ultra high-risk youth. A minority of the youth with PS symptoms ($n = 69$) were being treated with psychoactive medication at the time of scan (eMethods in the [Supplement](#)). Youth with PS symptoms were compared with 416 typically developing (TD) youth, who had no significant psychiatric symptoms, were not taking psychotropic medication, and had no history of psychiatric hospitalization.

Following image quality assurance, the final sample comprised 391 youth with PS features (PS group) and 400 TD youth (TD group) 8 to 22 years old. Cognition was assessed using the University of Pennsylvania computerized neurocognitive battery and summarized as a general cognitive factor as previously reported.^{52,55,56} Dimensional psychosis severity in the PS group was estimated using a previously described factor analysis of psychosis assessments.³⁷

Demographic characteristics are summarized in the [Table](#). While TD and PS samples were matched on sex ($P > .90$), they differed on age, race, and maternal education ($P < .01$). These variables were included as covariates in group-level analyses and further evaluated in supplementary analyses (see the [Supplementary Analyses](#) subsection below). All study procedures were approved by the institutional review boards of the University of Pennsylvania and The Children's Hospital of Philadelphia. Adult participants provided written informed consent. Minors provided assent, and their parent or guardian provided written informed consent.

Image Processing

All data were acquired on the same scanner using the same imaging sequences.^{43,57} To maximize sensitivity to detect effects in youth with PS, advanced structural image processing and registration procedures were used. The T1-weighted image was skull stripped using a multatlas procedure,⁵⁵ followed by multiplicative intrinsic component optimization for bias correction.⁵⁶ Multatlas regional segmentation⁵⁸ was performed, which yields regional, lobar, and tissue class volume estimates. Voxelwise analyses were conducted using regional analysis of volumes in normalized space (RAVENS maps).⁵⁹ A deformable registration (DRAMMS [Deformable Registration via Attribute Matching and Mutual-Saliency Weighting])⁶⁰ was used to register images to a study-specific template.⁶¹ RAVENS maps were downsampled to 2 mm and smoothed (8 mm full-width at half maximum) before voxelwise analyses.

Group-Level Analyses

Prior work has demonstrated that brain development is not a linear process.⁶²⁻⁶⁴ Accordingly, group-level analyses of regional and voxelwise data were flexibly modeled using penalized splines within a general additive model (GAM) (eMethods in the Supplement).^{65,66} The GAM assesses a penalty (using restricted maximum likelihood) on nonlinearity to avoid overfitting. This approach allowed us to estimate group differences and also ascertain whether the pattern of age-related changes was significantly different between groups.^{64,67} We examined group differences and group \times age interactions for global, lobar, and voxelwise volume measurements. In all models, we controlled for potentially confounding covariates, including sex, race, and maternal education. Intracranial volume (ICV) was included as a covariate in all regional and voxelwise models.^{68,69} Tissue class volumes were modeled with and without ICV.

In addition to group differences, we examined the relationship between overall dimensional psychosis symptom severity (as defined by a previously completed factor analysis of PS symptoms)³⁷ and voxelwise gray matter volume within the PS group while controlling for covariates as above (sex, race, maternal education, and spline of age). Clusters demonstrating a significant association with overall psychosis symptom severity were further evaluated versus previously defined factors corresponding to positive and negative symptoms.³⁷ To enhance interpretability, dimensional associations with symptom severity were limited to voxels where a nominal (uncorrected $P < .05$) group difference was present. Type I error for voxelwise analyses was controlled using AFNI AlphaSim⁷⁰ (cluster height z score > 2.3 , corrected cluster significance $P < .01$). Cortical projections were displayed using Caret.⁷¹ Subcortical images were projected to the Montreal Neurological Institute 1-mm template for display.

Supplementary Analyses

We conducted several supplementary analyses to ensure that potentially confounding variables did not drive the observed results. Specifically, we conducted analyses of global, lobar, and regional medial temporal lobe volumes in 3 subsamples. In the first subsample ($n = 722$), we excluded youth with PS symptoms who were taking psychoactive medication. In the second subsample ($n = 665$), as in prior work,^{39,40} we excluded youth

Table. Sample Demographics

Variable	Typically Developing ($n = 400$)	Psychosis Spectrum ($n = 391$)
Female sex, No. (%)	195 (48.8)	198 (50.6)
White race, No. (%)	221 (55.3)	121 (30.9)
Age, mean (SD), y	14.57 (4.03)	15.73 (3.11)
Maternal education, mean (SD), y	14.68 (2.56)	13.78 (2.23)
Psychosis z score, mean (SD)	-0.6 (0.7)	1.1 (0.8)
Cognitive performance, mean (SD) ^a	0.23 (0.76)	-0.18 (0.99)
Psychoactive medication use, No.	0	69
ICV, mean (SD), mm ³	1485.69 (138.55)	1436.70 (155.04)

Abbreviation: ICV, intracranial volume.

^a Cognitive performance is reported as a z score of scores from a factor analysis of the Penn Computerized Neurocognitive Battery, where a higher score denotes better performance.

with PS symptoms younger than 11 years whose status was assessed only by collateral interview. In the third subsample ($n = 478$), we used propensity score matching⁷² to create groups that were exactly matched on age, sex, race, and maternal education. Finally, to examine the specificity of PS results,⁵¹ we compared TD participants with 591 youth imaged as part of the PNC who had other psychopathology (and not PS symptoms) while controlling for covariates as above.

Results

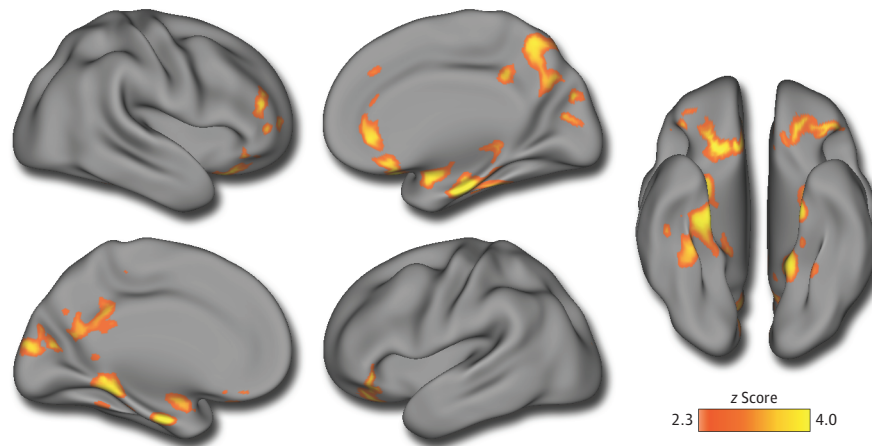
Youth With PS Symptoms Have Lower Gray Matter Volume and Greater White Matter Volume

Youth with PS symptoms had reduced ICV compared with TD youth ($P = .002$). Global gray, white, and cerebrospinal fluid volumes were thus evaluated with and without ICV correction, and ICV was included as a covariate in all other analyses. Youth with PS symptoms had reduced total gray matter volume ($P = 3.4 \times 10^{-4}$), which was present at a trend level ($P = .058$) when covarying for ICV. This difference was larger in older participants, producing a significant group \times age interaction ($P = .02$); this was not significant while covarying for ICV. When accounting for diminished ICV, youth with PS symptoms had greater white matter volume than TD comparators ($P = 2.2 \times 10^{-3}$); no age by group interaction was present. When ICV was not included in the model, PS participants demonstrated a trend towards reduced white matter volume ($P = .08$); no age by group interaction was present.

Distributed Gray Matter Volume Reduction Is Maximal in the Medial Temporal Lobe

To delineate the spatial pattern of volumetric deficits in more detail, we next conducted whole-brain voxelwise analyses. As shown in Figure 1 and summarized in eTable 1 in the Supplement, voxelwise analyses revealed significant clusters of reduced volume in youth with PS symptoms in a network of regions, including bilateral medial temporal lobe, ventromedial prefrontal cortex, orbitofrontal cortex, and posterior cingulate.

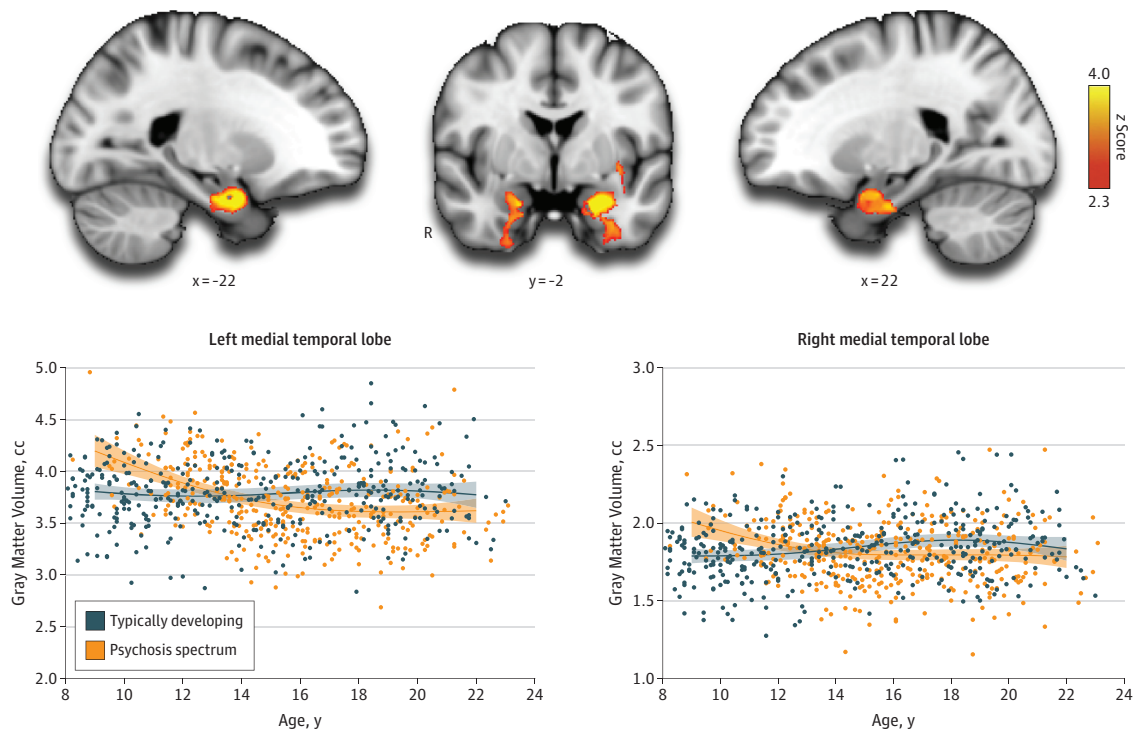
Figure 1. Multifocal Gray Matter Volume Reduction in Youth With Psychosis Spectrum Symptoms



Voxelwise between-group analysis of gray matter volume reveals that youth with psychosis spectrum symptoms have diminished gray matter volume across multiple brain regions, including the precuneus, posterior cingulate, bilateral

medial temporal lobe, frontal pole, and orbitofrontal cortex. The image was thresholded at z score > 2.3 , corrected $P < .01$. The minimum cluster size is 255 voxels. Further details are listed in eTable 1 in the [Supplement](#).

Figure 2. Reduced Medial Temporal Volume in Youth With Psychosis Spectrum Symptoms Develops in Early Adolescence



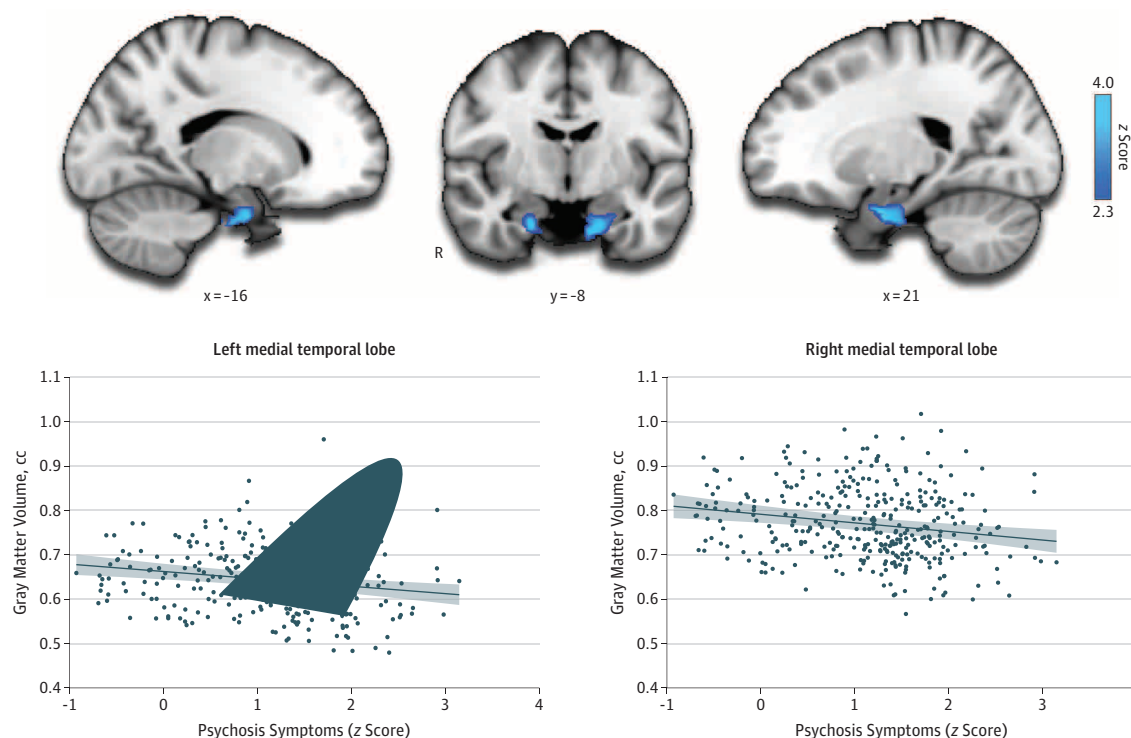
A, Voxelwise examination of nonlinear group \times age interactions reveals significant differences in the developmental pattern of bilateral medial temporal lobe. Whereas intracranial volume-adjusted medial temporal volumes are stable in typically developing youth, youth with psychosis spectrum symptoms lose medial temporal volume in late childhood and early adolescence, resulting in lower medial temporal lobe volumes bilaterally by mid-adolescence. The image

was thresholded at z score > 2.3 , corrected $P < .01$. The minimum cluster size is 255 voxels. The x and y coordinates are in MNI. B, The mean volume is plotted within these clusters vs psychosis spectrum symptom severity while adjusting for covariates. Shaded regions represent 95% CIs. Further details are listed in eTable 2 in the [Supplement](#).

Reduced volume was also seen in right dorsolateral prefrontal cortex and superior parietal cortex. Peak deficits were found in the medial temporal lobe. There was a single cluster in right in-

ferior cerebellum where the PS group had larger gray matter volume. Significant group \times age interactions were present in bilateral medial temporal lobe (Figure 2 and eTable 2 in the [Supple-](#)

Figure 3. Dimensional Severity of Psychosis Spectrum Symptoms Is Associated With Diminished Volume in Bilateral Medial Temporal Lobe



A, Voxelwise regression of dimensional psychosis spectrum symptoms within the psychosis spectrum sample reveals bilateral clusters of diminished volume in the medial temporal lobe. The image was thresholded at z score > 2.3 , corrected $P < .01$. The minimum cluster size is 150 voxels. The x and y

coordinates are in MNI. B, The mean volume is plotted within these clusters vs psychosis spectrum symptom severity while adjusting for covariates. Shaded regions represent 95% CIs. Further details are listed in eTable 3 in the [Supplement](#).

ment), where higher volume in youth with PS symptoms during childhood is followed by lower volume in adolescence. No other regions demonstrated a significant group \times age interaction.

Dimensional Psychosis Severity Is Associated With Medial Temporal Volume Loss

Having identified regions of reduced volume in youth with PS symptoms, we next evaluated whether the severity of symptoms in the PS group was related to the magnitude of structural abnormalities. Greater severity of PS symptoms was associated with volume reduction in bilateral medial temporal lobe (Figure 3 and eTable 3 in the [Supplement](#)). Follow-up analyses revealed that these medial temporal effects were driven by positive symptoms ($P < .001$) but not negative symptoms. These results suggest that lower volume in the medial temporal lobe is related to not only the presence of PS symptoms but also their severity.

Supplementary Analyses

Supplementary analyses in 3 subsamples that excluded participants taking psychoactive medication, removed individuals younger than 11 years, or used groups matched on demographic covariates demonstrated significant group differences, but only when not covarying for ICV (eTable 4 in the [Supplement](#)). The effect sizes in all samples were small (Cohen $d = 0.3$ or lower; eTable 4 in the [Supplement](#)).

Finally, PNC participants with other psychopathology did not show volumetric deficits similar to those seen in youth with PS symptoms that were observed when not covarying for ICV (eTable 5 in the [Supplement](#)).

Discussion

In a large community-based sample of youth with PS symptoms, we identified abnormalities of brain structure. Gray matter volume loss was identified globally as well as in specific regions that included the medial temporal lobe, ventromedial and orbital frontal cortex, posterior cingulate, and dorsolateral prefrontal cortex. Volume reduction was maximal in the medial temporal lobe, where deficits became apparent in mid-adolescence and were correlated with the severity of PS symptoms. Taken together, these findings delineate a pattern of abnormal structural brain development in youth with PS symptoms that in part mirrors that seen in both adults with clinically diagnosed psychotic disorders and youth at clinical risk.

Structural Brain Abnormalities in Youth With PS Symptoms

We examined gray matter volume in youth with PS symptoms at multiple scales, including tissue class, lobar, and voxelwise analyses. Throughout, we maximized sensitivity by using ad-

vanced image processing techniques: regional volumes were estimated using cutting-edge multiatlas segmentation,⁵⁸ while voxelwise analyses used a highly accurate deformable registration⁶⁰ in combination with a study-specific template. It should be noted that, as in prior meta-analyses^{15,20} of adult clinical samples, youth with PS symptoms also had significantly lower ICV. Global, lobar, and regional analyses were conducted with and without ICV included in the model. In these analyses, we only found evidence of significant gray matter reduction in PS youth when ICV was not included as a covariate. In contrast, all voxelwise analyses covaried for ICV and revealed significant areas of lower volume that were maximal in the medial temporal lobe and also present in ventromedial prefrontal cortex, orbitofrontal cortex, posterior cingulate, and dorsolateral prefrontal cortex.

Many of the regions affected are part of the default mode network, a large-scale functional network that is critical for internally directed attention, theory of mind, social cognition, and memory.^{73,74} Both functional⁷⁵⁻⁷⁷ and structural^{13,20,78} deficits of default mode regions have been widely documented in psychosis. Indeed, in a prior report³⁹ from this cohort, our group described default mode hyperconnectivity in youth with PS symptoms. The present results thus provide convergent evidence for multimodal structural and functional abnormalities of default mode regions in youth with PS symptoms.

These results show substantial concordance with other studies of psychosis and risk across the life span, including adults with chronic schizophrenia,^{13,15,16,20} childhood-onset schizophrenia,^{79,80} and first-episode psychosis.^{10,12,31-33} Our results indicate that structural abnormalities seen in clinical populations are also present in youth with PS symptoms and suggest that abnormalities of structural brain maturation may arise early in the course of development. Early loss of gray matter is consistent with prior reports of “accelerated aging” in schizophrenia.⁸¹⁻⁸³ While expansion of white matter observed herein is also consistent with premature acceleration of brain development, this finding has not typically been reported in clinical samples. It should be noted that such white matter expansion is only apparent when considering reduced ICV in PS youth; uncorrected white matter volumes did not differ significantly between groups. Thus, PS is characterized by an absolute reduction in gray matter volume and a relative expansion of white matter volume. To our knowledge, only one prior study has examined structural brain abnormalities in youth with PS symptoms. Jacobson et al⁴² documented increases in gray matter density in a small sample ($n = 11$) of children 11 to 13 years old. Differences among these results may be accounted for by the difference in dependent measure (density vs volume) and the small sample size of the prior work.

Medial Temporal Lobe Volume Deficits in Youth With PS Symptoms

Volumetric deficits in youth with PS symptoms were observed in the medial temporal lobe, including the hippocampal head, amygdala, and parahippocampal cortex. Critically, reduced volume in these regions also correlated with

symptom severity, particularly positive symptoms. These results are concordant with a large literature of both structural^{18,20,26,27,84-90} and functional^{24,91-96} medial temporal deficits in psychosis. Medial temporal volume loss has previously been documented in samples that included adults with chronic schizophrenia,^{17,18,20,24,88} first-episode psychosis,^{17,18,32,33} and youth at clinical risk for psychosis^{26,27,32,97} but has not previously been reported in association with PS symptoms in a population-based sample. While the exact mechanism of injury to the hippocampus in psychosis is as yet unknown, Schobel et al⁹⁸ recently documented hypermetabolism at baseline in hippocampus CA1 in youth at clinical high risk for psychosis, which was linked to both elevated levels of extracellular glutamate and subsequent volume loss. Such changes may potentially be linked to γ -aminobutyric acid deficits in the medial temporal lobe in psychosis.⁹⁹ In the present data, the medial temporal lobe volumes showed a marked nonlinear developmental pattern, with volumetric deficits only becoming apparent in mid-adolescence. While speculative, the nonlinear pattern of medial temporal volume reduction in the youth with PS symptoms seen in our data may be consistent with the ongoing effects of glutamate-related toxicity following a period of both higher metabolism and volume. Potentially, both structural and functional changes could be phase specific^{100,101} and represent a series of allostatic compensatory responses to an initial deficit.¹⁰⁰ Future studies using dedicated imaging techniques sensitive to hippocampal neurogenesis and injury may provide further insight.⁹¹

Opportunities and Limitations of Community-Based Research of PS Symptoms

In this study, we examined PS symptoms present in the community. In comparison with other strategies, such as studying help-seeking youth at clinical high risk, this approach comes with both advantages and disadvantages. The community-based approach allowed us to study younger participants who were largely unmedicated as well as to accrue a substantially larger sample size at a single site and scanner. However, the effect sizes of the observed effects are small (ie, Cohen $d = 0.3$ or lower), and large samples may be required to detect such effects. Furthermore, it should be noted that the correspondence with abnormalities in adult clinical samples is descriptive, and the observed abnormalities are partially, although not completely, similar to those identified in meta-analyses of schizophrenia.^{11,87,101}

In addition, the present cross-sectional analysis does not allow us to evaluate the degree to which the observed abnormalities are driven by individual participants who will later become overtly psychotic.³⁴ Given the higher prevalence of PS symptoms compared with population rates of schizophrenia, it seems likely that PS symptoms are themselves associated with structural brain abnormalities, which would support a dimensional view of the PS and accord closely with the National Institute of Mental Health Research Domain Criteria approach.^{48,49} As suggested by such a multidimensional view of psychopathology, it should be noted that individuals with PS symptoms

also have elevated levels of comorbid symptoms from other psychopathology dimensions.³⁶ While specificity analyses established that youth with other non-PS psychopathology did not have the same deficits as youth with PS symptoms, additional work will be necessary to evaluate the unique impact of PS symptoms in the context of other symptom dimensions. The necessity of further research to establish specificity is underlined by prior reports of cortical and medial temporal lobe abnormalities in both other psychiatric disorders^{102,103} and in association with cognitive deficits, such as those seen in youth with PS symptoms.⁵¹ Finally, it should be noted that, despite our efforts to control for relevant covariates, unmodeled confounding variables remain a persistent concern in psychiatric neuroimaging.¹⁰⁴

Conclusions

These results establish that community youth with PS symptoms have patterns of structural brain abnormalities similar

to those seen in clinically ascertained samples. Together with recent reports from this sample regarding cognitive deficits,^{36,37,51} reduced executive activation,⁴⁰ exaggerated amygdala threat responsivity,⁴⁰ and functional network disconnectivity in youth with PS symptoms,³⁹ these findings suggest that brain abnormalities are associated with PS symptoms at a young age before clinical high-risk symptoms are typically identified. Such deficits are not dependent on disease chronicity or the confounding influence of psychotropic medication. These brain phenotypes may become a biomarker that can be used in genomic studies, drug discovery, and clinical trials of novel therapeutics.^{34,105-108} Especially when used in combination with cognitive testing and measures of polygenic risk,¹⁰⁹⁻¹¹² imaging phenotypes may help evaluate risk and target interventions for youth with PS symptoms before frank psychosis occurs and negative outcomes accrue. Moving forward, development of data-driven analytic techniques to parse heterogeneity¹¹³ within the psychosis spectrum will accelerate translation to clinical practice.

ARTICLE INFORMATION

Submitted for Publication: October 1, 2015; final revision received October 27, 2015; accepted October 28, 2015.

Correction: This article was corrected online March 8, 2017, to fix methodologic and data errors in the Abstract, text, the original Figure 1, and the eFigure and eTables 4 and 5 in the Supplement.

Published Online: March 16, 2016.
doi:10.1001/jamapsychiatry.2015.3463

Author Contributions: Dr Satterthwaite had full access to all the data in the study and takes responsibility for the integrity of the data and the accuracy of the data analysis.

Study concept and design: Satterthwaite, Wolf, Calkins, Ruparel, Hakonarson, Davatzikos, R. C. Gur, R. E. Gur.

Acquisition, analysis, or interpretation of data: All authors.

Drafting of the manuscript: Satterthwaite.

Critical revision of the manuscript for important intellectual content: All authors.

Statistical analysis: Satterthwaite, Vandekar, Ruparel, Linn, Moore, Shinohara, Davatzikos, R. C. Gur.

Obtained funding: Satterthwaite, Hakonarson, R. C. Gur, R. E. Gur.

Administrative, technical, or material support: Satterthwaite, Calkins, Vandekar, Ruparel, Roalf, Elliott, Hakonarson, R. E. Gur.

Study supervision: Satterthwaite, Calkins, Roalf, Hakonarson, Davatzikos, R. C. Gur, R. E. Gur.

Conflict of Interest Disclosures: Dr R. C. Gur reported receiving royalties from the Brain Resource Centre and reported serving without compensation on an advisory board for Lumosity. Dr R. E. Gur reported participating in an advisory board for Otsuka Pharmaceuticals. No other disclosures were reported.

Funding/Support: This work was supported by RC2 grants MH089983 and MH089924 and P50MH096891 from the National Institute of Mental Health. Additional support was provided by grants R01MH107703 and K23MH098130 (Dr

Satterthwaite), R01MH101111 (Dr Wolf), K08MH079364 (Dr Calkins), T32MH065218 (Mr Vandekar), K01MH102609 (Dr Roalf), and R01NS085211 (Dr Shinohara) from the National Institutes of Health, as well as by the Dowshen Program for Neuroscience. Support for developing statistical analyses (Drs Satterthwaite and Shinohara) was provided by a seed grant from the Center for Biomedical Computing and Image Analysis at the University of Pennsylvania.

Role of the Funder/Sponsor: The funding sources had no role in the design and conduct of the study; collection, management, analysis, and interpretation of the data; preparation, review, or approval of the manuscript; and decision to submit the manuscript for publication.

Additional Contributions: The acquisition and recruitment team members included Karthik Prabhakaran, MS, Ryan Hopson, MS, Jeff Valdez, MS, Raphael Gerraty, BA, Marisa Riley, BA, Jack Keefe, BA, Elliott Yodh, BA, and Rosetta Chiavacci, BSN, CCRC. Harsha Battapady, MS, assisted with data processing. Tianhao Zhang, PhD, contributed discussion regarding analytics, and Chad Jackson, MSE, and Larry Macy, PhD, provided data management and systems support. None were compensated beyond their standing salary.

REFERENCES

1. Freedman R. Schizophrenia. *N Engl J Med*. 2003;349(18):1738-1749.
2. Kessler RC, Avenevoli S, Costello EJ, et al. Prevalence, persistence, and sociodemographic correlates of DSM-IV disorders in the National Comorbidity Survey Replication Adolescent Supplement. *Arch Gen Psychiatry*. 2012;69(4):372-380.
3. Kessler RC, Avenevoli S, Costello J, et al. Severity of 12-month DSM-IV disorders in the National Comorbidity Survey Replication Adolescent Supplement. *Arch Gen Psychiatry*. 2012;69(4):381-389.
4. Casey BJ, Oliveri ME, Insel T. A neurodevelopmental perspective on the Research

Domain Criteria (RDoC) framework. *Biol Psychiatry*. 2014;76(5):350-353.

5. Di Martino A, Fair DA, Kelly C, et al. Unraveling the miswired connectome: a developmental perspective. *Neuron*. 2014;83(6):1335-1353.

6. Insel TR. Rethinking schizophrenia. *Nature*. 2010;468(7321):187-193.

7. Rapoport JL, Giedd JN, Gogtay N. Neurodevelopmental model of schizophrenia: update 2012. *Mol Psychiatry*. 2012;17(12):1228-1238.

8. McGlashan TH, Johannessen JO. Early detection and intervention with schizophrenia: rationale. *Schizophr Bull*. 1996;22(2):201-222.

9. Addington J, Cadenhead KS, Cannon TD, et al; North American Prodrome Longitudinal Study. North American Prodrome Longitudinal Study: a collaborative multisite approach to prodromal schizophrenia research. *Schizophr Bull*. 2007;33(3):665-672.

10. Ruggeri M, Bonetto C, Lasalvia A, et al; GET UP Group. Feasibility and effectiveness of a multi-element psychosocial intervention for first-episode psychosis: results from the cluster-randomized controlled GET UP PIANO Trial in a catchment area of 10 million inhabitants. *Schizophr Bull*. 2015;41(5):1192-1203.

11. Bora E, Fornito A, Radua J, et al. Neuroanatomical abnormalities in schizophrenia: a multimodal voxelwise meta-analysis and meta-regression analysis. *Schizophr Res*. 2011;127(1-3):46-57.

12. Chan RC, Di X, McAlonan GM, Gong QY. Brain anatomical abnormalities in high-risk individuals, first-episode, and chronic schizophrenia: an activation likelihood estimation meta-analysis of illness progression. *Schizophr Bull*. 2011;37(1):177-188.

13. Glahn DC, Laird AR, Ellison-Wright I, et al. Meta-analysis of gray matter anomalies in schizophrenia: application of anatomic likelihood estimation and network analysis. *Biol Psychiatry*. 2008;64(9):774-781.

14. Gur RE, Maany V, Mozley PD, Swanson C, Bilker W, Gur RC. Subcortical MRI volumes in

- neuroleptic-naïve and treated patients with schizophrenia. *Am J Psychiatry*. 1998;155(12):1711-1717.
15. Haijma SV, Van Haren N, Cahn W, Koolschijn PC, Hulshoff Pol HE, Kahn RS. Brain volumes in schizophrenia: a meta-analysis in over 18 000 subjects. *Schizophr Bull*. 2013;39(5):1129-1138.
 16. Honea R, Crow TJ, Passingham D, Mackay CE. Regional deficits in brain volume in schizophrenia: a meta-analysis of voxel-based morphometry studies. *Am J Psychiatry*. 2005;162(12):2233-2245.
 17. Gur RE, Cowell P, Turetsky BI, et al. A follow-up magnetic resonance imaging study of schizophrenia: relationship of neuroanatomical changes to clinical and neurobehavioral measures. *Arch Gen Psychiatry*. 1998;55(2):145-152.
 18. Gur RE, Turetsky BI, Cowell PE, et al. Temporolimbic volume reductions in schizophrenia. *Arch Gen Psychiatry*. 2000;57(8):769-775.
 19. Thompson PM, Stein JL, Medland SE, et al; Alzheimer's Disease Neuroimaging Initiative; EPIGEN Consortium; IMAGEN Consortium; Saguenay Youth Study (SYS) Group. The ENIGMA Consortium: large-scale collaborative analyses of neuroimaging and genetic data. *Brain Imaging Behav*. 2014;8(2):153-182.
 20. van Erp TG, Hibar DP, Rasmussen JM, et al. Subcortical brain volume abnormalities in 2028 individuals with schizophrenia and 2540 healthy controls via the ENIGMA Consortium [published online June 2, 2015]. *Mol Psychiatry*. 2015.
 21. Medoff DR, Holcomb HH, Lahti AC, Tamminga CA. Probing the human hippocampus using rCBF: contrasts in schizophrenia. *Hippocampus*. 2001;11(5):543-550.
 22. Knable MB, Barci BM, Webster MJ, Meador-Woodruff J, Torrey EF; Stanley Neuropathology Consortium. Molecular abnormalities of the hippocampus in severe psychiatric illness: postmortem findings from the Stanley Neuropathology Consortium. *Mol Psychiatry*. 2004;9(6):609-620.
 23. Heckers S, Rauch SL, Goff D, et al. Impaired recruitment of the hippocampus during conscious recollection in schizophrenia. *Nat Neurosci*. 1998;1(4):318-323.
 24. Heckers S. Neuroimaging studies of the hippocampus in schizophrenia. *Hippocampus*. 2001;11(5):520-528.
 25. Gao XM, Sakai K, Roberts RC, Conley RR, Dean B, Tamminga CA. Ionotropic glutamate receptors and expression of N-methyl-D-aspartate receptor subunits in subregions of human hippocampus: effects of schizophrenia. *Am J Psychiatry*. 2000;157(7):1141-1149.
 26. Ganzola R, Maziade M, Duchesne S. Hippocampus and amygdala volumes in children and young adults at high-risk of schizophrenia: research synthesis. *Schizophr Res*. 2014;156(1):76-86.
 27. Dean DJ, Orr JM, Bernard JA, et al. Hippocampal shape abnormalities predict symptom progression in neuroleptic-free youth at ultrahigh risk for psychosis. *Schizophr Bull*. 2016;42(1):161-169.
 28. Boos HB, Aleman A, Cahn W, Hulshoff Pol H, Kahn RS. Brain volumes in relatives of patients with schizophrenia: a meta-analysis. *Arch Gen Psychiatry*. 2007;64(3):297-304.
 29. McDonald C, Dineen B, Hallahan B. Meta-analysis of brain volumes in unaffected first-degree relatives of patients with schizophrenia overemphasizes hippocampal deficits. *Arch Gen Psychiatry*. 2008;65(5):603-604.
 30. Roalf DR, Vandekar SN, Almasy L, et al. Heritability of subcortical and limbic brain volume and shape in multiplex-multigenerational families with schizophrenia. *Biol Psychiatry*. 2015;77(2):137-146.
 31. Palaniyappan L, Maayan N, Bergman H, Davenport C, Adams CE, Soares-Weiser K. Voxel-based morphometry for separation of schizophrenia from other types of psychosis in first episode psychosis. *Cochrane Database Syst Rev*. 2015;8:CD011021.
 32. Nenadic I, Dietzek M, Schönfeld N, et al. Brain structure in people at ultra-high risk of psychosis, patients with first-episode schizophrenia, and healthy controls: a VBM study. *Schizophr Res*. 2015;161(2-3):169-176.
 33. Bois C, Levita L, Ripp I, et al. Hippocampal, amygdala and nucleus accumbens volume in first-episode schizophrenia patients and individuals at high familial risk: a cross-sectional comparison. *Schizophr Res*. 2015;165(1):45-51.
 34. Cannon TD, Chung Y, He G, et al; North American Prodrome Longitudinal Study Consortium. Progressive reduction in cortical thickness as psychosis develops: a multisite longitudinal neuroimaging study of youth at elevated clinical risk. *Biol Psychiatry*. 2015;77(2):147-157.
 35. van Os J, Linscott RJ, Myin-Germeys I, Delespaul P, Krabbendam L. A systematic review and meta-analysis of the psychosis continuum: evidence for a psychosis proneness-persistence-impairment model of psychotic disorder. *Psychol Med*. 2009;39(2):179-195.
 36. Calkins ME, Moore TM, Merikangas KR, et al. The psychosis spectrum in a young U.S. community sample: findings from the Philadelphia Neurodevelopmental Cohort. *World Psychiatry*. 2014;13(3):296-305.
 37. Calkins ME, Merikangas KR, Moore TM, et al. The Philadelphia Neurodevelopmental Cohort: constructing a deep phenotyping collaborative. *J Child Psychol Psychiatry*. 2015;56(12):1356-1369.
 38. McGlashan TH, Miller TJ, Woods SW. Pre-onset detection and intervention research in schizophrenia psychoses: current estimates of benefit and risk. *Schizophr Bull*. 2001;27(4):563-570.
 39. Satterthwaite TD, Vandekar SN, Wolf DH, et al. Connectome-wide network analysis of youth with psychosis-spectrum symptoms. *Mol Psychiatry*. 2015;20(12):1508-1515.
 40. Wolf DH, Satterthwaite TD, Calkins ME, et al. Functional neuroimaging abnormalities in youth with psychosis spectrum symptoms. *JAMA Psychiatry*. 2015;72(5):456-465.
 41. O'Hanlon E, Leemans A, Kelleher I, et al. White matter differences among adolescents reporting psychotic experiences: a population-based diffusion magnetic resonance imaging study. *JAMA Psychiatry*. 2015;72(7):668-677.
 42. Jacobson S, Kelleher I, Harley M, et al. Structural and functional brain correlates of subclinical psychotic symptoms in 11-13 year old schoolchildren. *Neuroimage*. 2010;49(2):1875-1885.
 43. Satterthwaite TD, Elliott MA, Ruparel K, et al. Neuroimaging of the Philadelphia Neurodevelopmental Cohort. *Neuroimage*. 2014;86:544-553.
 44. Kelleher I, Cannon M. Psychotic-like experiences in the general population: characterizing a high-risk group for psychosis. *Psychol Med*. 2011;41(1):1-6.
 45. Kelleher I, Connor D, Clarke MC, Devlin N, Harley M, Cannon M. Prevalence of psychotic symptoms in childhood and adolescence: a systematic review and meta-analysis of population-based studies. *Psychol Med*. 2012;42(9):1857-1863.
 46. Kelleher I, Murtagh A, Molloy C, et al. Identification and characterization of prodromal risk syndromes in young adolescents in the community: a population-based clinical interview study. *Schizophr Bull*. 2012;38(2):239-246.
 47. Kelleher I, Corcoran P, Keeley H, et al. Psychotic symptoms and population risk for suicide attempt: a prospective cohort study. *JAMA Psychiatry*. 2013;70(9):940-948.
 48. Cuthbert BN. The RDoC framework: facilitating transition from ICD/DSM to dimensional approaches that integrate neuroscience and psychopathology. *World Psychiatry*. 2014;13(1):28-35.
 49. Insel T, Cuthbert B, Garvey M, et al. Research Domain Criteria (RDoC): toward a new classification framework for research on mental disorders. *Am J Psychiatry*. 2010;167(7):748-751.
 50. Gur RE, Kaltman D, Melhem ER, et al. Incidental findings in youths volunteering for brain MRI research. *AJNR Am J Neuroradiol*. 2013;34(10):2021-2025.
 51. Gur RC, Calkins ME, Satterthwaite TD, et al. Neurocognitive growth charting in psychosis spectrum youths. *JAMA Psychiatry*. 2014;71(4):366-374.
 52. Miller TJ, McGlashan TH, Rosen JL, et al. Prodromal assessment with the structured interview for prodromal syndromes and the scale of prodromal symptoms: predictive validity, interrater reliability, and training to reliability. [published correction appears in *Schizophr Bull*. 2004;30(2):217]. *Schizophr Bull*. 2003;29(4):703-715.
 53. Kobayashi H, Nemoto T, Koshikawa H, et al. A self-reported instrument for prodromal symptoms of psychosis: testing the clinical validity of the PRIME Screen-Revised (PS-R) in a Japanese population. *Schizophr Res*. 2008;106(2-3):356-362.
 54. Kaufman J, Birmaher B, Brent D, et al. Schedule for Affective Disorders and Schizophrenia for School-Age Children-Present and Lifetime Version (K-SADS-PL): initial reliability and validity data. *J Am Acad Child Adolesc Psychiatry*. 1997;36(7):980-988.
 55. Doshi J, Erus G, Ou Y, Gaonkar B, Davatzikos C. Multi-atlas skull-stripping. *Acad Radiol*. 2013;20(12):1566-1576.
 56. Li C, Gore JC, Davatzikos C. Multiplicative intrinsic component optimization (MICO) for MRI bias field estimation and tissue segmentation. *Magn Reson Imaging*. 2014;32(7):913-923.
 57. Satterthwaite TD, Connolly JJ, Ruparel K, et al. The Philadelphia Neurodevelopmental Cohort: a publicly available resource for the study of normal

and abnormal brain development in youth. *Neuroimage*. 2016;124(pt B):1115-1119.

58. Doshi J, Erus G, Ou Y, et al; Alzheimer's Neuroimaging Initiative. MUSE: MULTI-atlas region Segmentation utilizing Ensembles of registration algorithms and parameters, and locally optimal atlas selection. *Neuroimage*. 2016;127:186-195.

59. Davatzikos C, Genc A, Xu D, Resnick SM. Voxel-based morphometry using the RAVENS maps: methods and validation using simulated longitudinal atrophy. *Neuroimage*. 2001;14(6):1361-1369.

60. Ou Y, Sotiras A, Paragios N, Davatzikos C. DRAMMS: Deformable Registration via Attribute Matching and Mutual-Saliency Weighting. *Med Image Anal*. 2011;15(4):622-639.

61. Erus G, Battapady H, Satterthwaite TD, et al. Imaging patterns of brain development and their relationship to cognition. *Cereb Cortex*. 2015;25(6):1676-1684.

62. Lenroot RK, Gogtay N, Greenstein DK, et al. Sexual dimorphism of brain developmental trajectories during childhood and adolescence. *Neuroimage*. 2007;36(4):1065-1073.

63. Giedd JN, Blumenthal J, Jeffries NO, et al. Brain development during childhood and adolescence: a longitudinal MRI study. *Nat Neurosci*. 1999;2(10):861-863.

64. Vandekar SN, Shinohara RT, Raznahan A, et al. Topologically dissociable patterns of development of the human cerebral cortex. *J Neurosci*. 2015;35(2):599-609.

65. Wood SN. Stable and efficient multiple smoothing parameter estimation for generalized additive models. *J Am Stat Assoc*. 2004;99:673-686.

66. Wood SN. Fast stable restricted maximum likelihood and marginal likelihood estimation of semiparametric generalized linear models. *J R Stat Soc Series B Stat Methodol*. 2011;73(1):3-36.

67. Satterthwaite TD, Shinohara RT, Wolf DH, et al. Impact of puberty on the evolution of cerebral perfusion during adolescence. *Proc Natl Acad Sci U S A*. 2014;111(23):8643-8648.

68. Sanfilippo MP, Benedict RH, Zivadinov R, Bakshi R. Correction for intracranial volume in analysis of whole brain atrophy in multiple sclerosis: the proportion vs residual method. *Neuroimage*. 2004;22(4):1732-1743.

69. Voevodskaya O, Simmons A, Nordenskjöld R, et al; Alzheimer's Disease Neuroimaging Initiative. The effects of intracranial volume adjustment approaches on multiple regional MRI volumes in healthy aging and Alzheimer's disease. *Front Aging Neurosci*. 2014;6:264.

70. Cox RW. AFNI: software for analysis and visualization of functional magnetic resonance neuroimages. *Comput Biomed Res*. 1996;29(3):162-173.

71. Van Essen DC, Drury HA, Dickson J, Harwell J, Hanlon D, Anderson CH. An integrated software suite for surface-based analyses of cerebral cortex. *J Am Med Inform Assoc*. 2001;8(5):443-459.

72. Ho D, Imai K, King G, Stuart E. Matching as nonparametric preprocessing for reducing model dependence in parametric causal inference. *Polit Anal*. 2007;15(3):199-236. <http://gking.harvard.edu/files/abs/matchp-abs.shtml>. Accessed February 3, 2016.

73. Raichle ME, MacLeod AM, Snyder AZ, Powers WJ, Gusnard DA, Shulman GL. A default mode of brain function. *Proc Natl Acad Sci U S A*. 2001;98(2):676-682.

74. Buckner RL, Andrews-Hanna JR, Schacter DL. The brain's default network: anatomy, function, and relevance to disease. *Ann N Y Acad Sci*. 2008;1124:1-38.

75. Garrity AG, Pearlson GD, McKiernan K, Lloyd D, Kiehl KA, Calhoun VD. Aberrant "default mode" functional connectivity in schizophrenia. *Am J Psychiatry*. 2007;164(3):450-457.

76. Whitfield-Gabrieli S, Thermenos HW, Milanovic S, et al. Hyperactivity and hyperconnectivity of the default network in schizophrenia and in first-degree relatives of persons with schizophrenia. *Proc Natl Acad Sci U S A*. 2009;106(4):1279-1284.

77. Ongür D, Lundy M, Greenhouse I, et al. Default mode network abnormalities in bipolar disorder and schizophrenia. *Psychiatry Res*. 2010;183(1):59-68.

78. Salgado-Pineda P, Fakra E, Delaveau P, McKenna PJ, Pomarol-Clotet E, Blin O. Correlated structural and functional brain abnormalities in the default mode network in schizophrenia patients. *Schizophr Res*. 2011;125(2-3):101-109.

79. Giedd JN, Jeffries NO, Blumenthal J, et al. Childhood-onset schizophrenia: progressive brain changes during adolescence. *Biol Psychiatry*. 1999;46(7):892-898.

80. Rapoport JL, Gogtay N. Childhood onset schizophrenia: support for a progressive neurodevelopmental disorder. *Int J Dev Neurosci*. 2011;29(3):251-258.

81. Koutsouleris N, Davatzikos C, Borgwardt S, et al. Accelerated brain aging in schizophrenia and beyond: a neuroanatomical marker of psychiatric disorders. *Schizophr Bull*. 2014;40(5):1140-1153.

82. Thompson PM, Vidal C, Giedd JN, et al. Mapping adolescent brain change reveals dynamic wave of accelerated gray matter loss in very early-onset schizophrenia. *Proc Natl Acad Sci U S A*. 2001;98(20):11650-11655.

83. Sun D, Stuart GW, Jenkinson M, et al. Brain surface contraction mapped in first-episode schizophrenia: a longitudinal magnetic resonance imaging study. *Mol Psychiatry*. 2009;14(10):976-986.

84. Zipursky RB, Marsh L, Lim KO, et al. Volumetric MRI assessment of temporal lobe structures in schizophrenia. *Biol Psychiatry*. 1994;35(8):501-516.

85. Marsh L, Harris D, Lim KO, et al. Structural magnetic resonance imaging abnormalities in men with severe chronic schizophrenia and an early age at clinical onset. *Arch Gen Psychiatry*. 1997;54(12):1104-1112.

86. Altshuler LL, Bartzokis G, Grieder T, et al. An MRI study of temporal lobe structures in men with bipolar disorder or schizophrenia. *Biol Psychiatry*. 2000;48(2):147-162.

87. Ellison-Wright I, Glahn DC, Laird AR, Thelen SM, Bullmore E. The anatomy of first-episode and chronic schizophrenia: an anatomical likelihood estimation meta-analysis. *Am J Psychiatry*. 2008;165(8):1015-1023.

88. Meisenzahl EM, Koutsouleris N, Bottlender R, et al. Structural brain alterations at different stages of schizophrenia: a voxel-based morphometric study. *Schizophr Res*. 2008;104(1-3):44-60.

89. Meisenzahl EM, Seifert D, Bottlender R, et al. Differences in hippocampal volume between major depression and schizophrenia: a comparative neuroimaging study. *Eur Arch Psychiatry Clin Neurosci*. 2010;260(2):127-137.

90. Wheeler AL, Voineskos AN. A review of structural neuroimaging in schizophrenia: from connectivity to connectomics. *Front Hum Neurosci*. 2014;8:653.

91. Ho NF, Hooker JM, Sahay A, Holt DJ, Roffman JL. In vivo imaging of adult human hippocampal neurogenesis: progress, pitfalls and promise. *Mol Psychiatry*. 2013;18(4):404-416.

92. Holt DJ, Weiss AP, Rauch SL, et al. Sustained activation of the hippocampus in response to fearful faces in schizophrenia. *Biol Psychiatry*. 2005;57(9):1011-1019.

93. Holt DJ, Kunkel L, Weiss AP, et al. Increased medial temporal lobe activation during the passive viewing of emotional and neutral facial expressions in schizophrenia. *Schizophr Res*. 2006;82(2-3):153-162.

94. Hall J, Whalley HC, Marwick K, et al. Hippocampal function in schizophrenia and bipolar disorder. *Psychol Med*. 2010;40(5):761-770.

95. Seidman LJ, Rosso IM, Thermenos HW, et al. Medial temporal lobe default mode functioning and hippocampal structure as vulnerability indicators for schizophrenia: a MRI study of non-psychotic adolescent first-degree relatives. *Schizophr Res*. 2014;159(2-3):426-434.

96. Allen P, Seal ML, Valli I, et al. Altered prefrontal and hippocampal function during verbal encoding and recognition in people with prodromal symptoms of psychosis. *Schizophr Bull*. 2011;37(4):746-756.

97. Meisenzahl EM, Koutsouleris N, Gaser C, et al. Structural brain alterations in subjects at high-risk of psychosis: a voxel-based morphometric study. *Schizophr Res*. 2008;102(1-3):150-162.

98. Schobel SA, Chaudhury NH, Khan UA, et al. Imaging patients with psychosis and a mouse model establishes a spreading pattern of hippocampal dysfunction and implicates glutamate as a driver. *Neuron*. 2013;78(1):81-93.

99. Heckers S, Konradi C. GABAergic mechanisms of hippocampal hyperactivity in schizophrenia. *Schizophr Res*. 2015;167(1-3):4-11.

100. Krystal JH, Anticevic A. Toward illness phase-specific pharmacotherapy for schizophrenia. *Biol Psychiatry*. 2015;78(11):738-740.

101. Fornito A, Yücel M, Patti J, Wood SJ, Pantelis C. Mapping grey matter reductions in schizophrenia: an anatomical likelihood estimation analysis of voxel-based morphometry studies. *Schizophr Res*. 2009;108(1-3):104-113.

102. Sheline YI, Wang PW, Gado MH, Csernansky JG, Vannier MW. Hippocampal atrophy in recurrent major depression. *Proc Natl Acad Sci U S A*. 1996;93(9):3908-3913.

103. Mathew I, Gardin TM, Tandon N, et al. Medial temporal lobe structures and hippocampal subfields in psychotic disorders: findings from the Bipolar-Schizophrenia Network on Intermediate Phenotypes (B-SNIP) study. *JAMA Psychiatry*. 2014;71(7):769-777.

104. Weinberger DR, Radulescu E. Finding the elusive psychiatric "lesion" with 21st-century

neuroanatomy: a note of caution. *Am J Psychiatry*. 2016;173(1):27-33.

105. Anticevic A, Hu X, Xiao Y, et al. Early-course unmedicated schizophrenia patients exhibit elevated prefrontal connectivity associated with longitudinal change. *J Neurosci*. 2015;35(1):267-286.

106. Anticevic A, Tang Y, Cho YT, et al. Amygdala connectivity differs among chronic, early course, and individuals at risk for developing schizophrenia. *Schizophr Bull*. 2014;40(5):1105-1116.

107. Chung Y, Cannon TD. Brain imaging during the transition from psychosis prodrome to schizophrenia. *J Nerv Ment Dis*. 2015;203(5):336-341.

108. Cannon TD, Sun F, McEwen SJ, et al. Reliability of neuroanatomical measurements in a multisite longitudinal study of youth at risk for psychosis. *Hum Brain Mapp*. 2014;35(5):2424-2434.

109. Stein JL, Medland SE, Vasquez AA, et al; Alzheimer's Disease Neuroimaging Initiative; EPIGEN Consortium; IMAGEN Consortium; Saguenay Youth Study Group; Cohorts for Heart and Aging Research in Genomic Epidemiology Consortium; Enhancing Neuro Imaging Genetics through Meta-Analysis Consortium. Identification of common variants associated with human hippocampal and intracranial volumes. *Nat Genet*. 2012;44(5):552-561.

110. Hibar DP, Stein JL, Renteria ME, et al; Alzheimer's Disease Neuroimaging Initiative; CHARGE Consortium; EPIGEN; IMAGEN; SYS. Common genetic variants influence human subcortical brain structures. *Nature*. 2015;520(7546):224-229.

111. Ripke S, O'Dushlaine C, Chambert K, et al; Multicenter Genetic Studies of Schizophrenia

Consortium; Psychosis Endophenotypes International Consortium; Wellcome Trust Case Control Consortium 2. Genome-wide association analysis identifies 13 new risk loci for schizophrenia. *Nat Genet*. 2013;45(10):1150-1159.

112. Schizophrenia Working Group of the Psychiatric Genomics Consortium. Biological insights from 108 schizophrenia-associated genetic loci. *Nature*. 2014;511(7510):421-427.

113. Zhang T, Koutsouleris N, Meisenzahl E, Davatzikos C. Heterogeneity of structural brain changes in subtypes of schizophrenia revealed using magnetic resonance imaging pattern analysis. *Schizophr Bull*. 2015;41(1):74-84.