

Radiofrequency catheter ablation of a concealed accessory pathway of the heart in a Labrador Retriever

AGNIESZKA NOSZCZYK-NOWAK, GAVIN MCAULAY*, ARTUR FUGLEWICZ**, KRZYSZTOF NOWAK***, ADRIAN JANISZEWSKI****, PIOTR SKRZYPCZAK*****, MARCIN MICHAŁEK, ALICJA CEPIEL, URSZULA PASŁAWSKA

Department of Internal Medicine and Clinic of Diseases of Horses, Dogs and Cats, University of Environmental and Life Sciences, 47 Grunwaldzki Sq., 50-366 Wrocław

*Cardio-respiratory Referrals New Priory Vets Brighton, Veterinary Hospital, Deneway London Road, Brighton, East Sussex, BN1 8QR, United Kingdom

**J. Strus City Hospital, 3 Szajcarska Str., 61-285 Poznań

***4th Military Hospital, 5 Weigla Str., 50-981 Wrocław

****Center for Experimental Diagnostics and Biomedical Innovations, 47 Grunwaldzki Sq., 50-366 Wrocław

*****Department and Clinic of Surgery, University of Environmental and Life Sciences, 51 Grunwaldzki Sq., 50-366 Wrocław, Poland

Received 13.12.2016

Accepted 27.03.2017

Noszczyk-Nowak A., McAulay G., Fuglewicz A., Nowak K., Janiszewski A., Skrzypczak P., Michałek M., Cepiel A., Paśławska U.

Radiofrequency catheter ablation of a concealed accessory pathway of the heart in a Labrador Retriever

Summary

The presence of an accessory atrioventricular conduction pathway may provide the anatomical basis for some tachyarrhythmias. Persistent tachyarrhythmias may result in the development of systolic dysfunction or tachycardiomyopathy and eventual progression to heart failure. In this paper we report the successful ablation of an accessory pathway involved in the pathogenesis of persistent orthodromic atrioventricular reciprocating tachycardia (AVRT) and heart failure in a 3-year-old male Labrador Retriever. Electrophysiological study and radiofrequency (RF) catheter ablation were performed under general anesthesia. Electrophysiological study revealed AVRT resulting from a retrograde conduction via a right posteroseptal accessory pathway. The successful RF ablation of the accessory pathway resulted in the resolution of the tachycardia and return of normal sinus rhythm. Medical management of heart failure was withdrawn and no episodes of recurrent tachyarrhythmia were documented during a 3-month follow-up.

Keywords: atrioventricular reciprocating tachycardia, radiofrequency catheter ablation, tachycardiomyopathy

Accessory pathways (APs) are abnormal electrical conduction pathways between the atria and the ventricles that bypass the atrioventricular node. APs are typically muscular fibers that cross the fibrous rings and form an additional connection to the ventricular myocardium or conduction system (3, 14). Formation of APs is associated with incomplete embryonic development of the atrioventricular rings. APs may allow impulse conduction in either a single direction or bidirectional manner. Impulse conduction via the AV node and retrograde via an AP is described as orthodromic whilst conduction via the AP and retrograde via the AV node is described as antidromic. AVRT occurs as

a consequence of bidirectional transmission of electrical stimulus between the ventricles and the atria via two independent conduction pathways with different electrophysiological characteristics. These are classically described as an alpha pathway with slow conduction and rapid repolarization and a B pathway with fast conduction but slow repolarisation. The different conductivity and refraction periods of the physiological conduction pathway and an AP contribute to the formation and propagation of a reentry circuit. Patients with pre-excitation syndrome may be at increased risk of developing supraventricular tachycardia. In most cases conduction via an AP is faster than via the

physiological pathway through the atrioventricular node (AVN). This can result in partial premature activation of ventricular myocardium during sinus rhythm (pre-excitation), manifested as a short PR interval and slurred upstroke of the QRS or “delta wave.” Arrhythmia resulting from the involvement of an accessory pathway was reported for the first time in 1930 by John Parkinson, Paul Dudley White and Louis Wolff, and the combination of paroxysmal tachycardia and pre-excitation has been referred to as Wolff-Parkinson-White (WPW) syndrome (14, 15). In humans with WPW syndrome, in whom SVT is associated with presence of an accessory pathway, in 95% of the cases AP constitutes a retrograde arm of the reentry loop, contributing to the so-called orthodromic conduction (AVRTo), and in 5% a anterograde arm involved in antidromic conduction (AVRTa) (7). Contrary to humans, little is known about the occurrence of APs in dogs and the incidence of resultant arrhythmia, including AVRT. Although canine and feline pre-excitation syndrome was first described by Hills et al. already in 1985, only single case reports documenting incidence of AVRT and treatment thereof in veterinary patients have been published since then (1, 8, 9, 12).

We present the case of a Labrador Retriever with a concealed right posteroseptal retrograde accessory pathway, which contributed to persistent AVRT and has been successfully eliminated by means of radiofrequency catheter ablation (RFCA).

Case report

A 3-year-old male Labrador Retriever was presented with a history of lethargy, weakness, exercise intolerance and recent abdominal effusion. On clinical examination the auscultated heart rate was 250 BPM associated with poor quality femoral pulses. Echocardiography demonstrated systolic dysfunction (LVIDd 50.6 mm, FS = 16%) and left atrial dilation (LA/Ao = 1.6) (2, 6). Moderate volume ascites was evident. Thoracic radiographs were consistent with pulmonary edema. Heart failure therapy was instituted with intravenous furosemide and orally administered pimobendan (Vetmedin, 10 mg q12h PO), benazepril

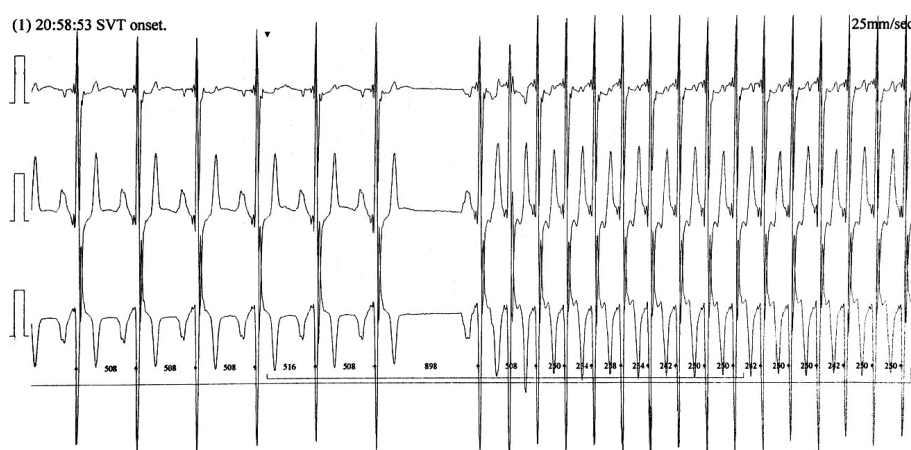


Fig. 1. Sudden onset of tachycardia on a Holter electrocardiogram

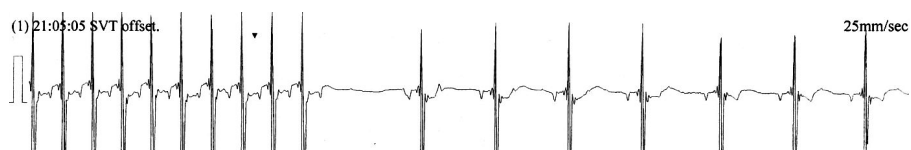

Fig. 2. Sudden end of tachycardia on a Holter electrocardiogram

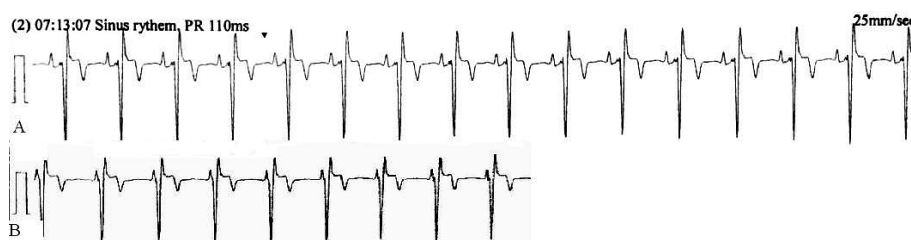


Fig. 3. A. Normal PR interval (110 ms) on a Holter electrocardiogram. B. Shortened PR interval on a Holter electrocardiogram

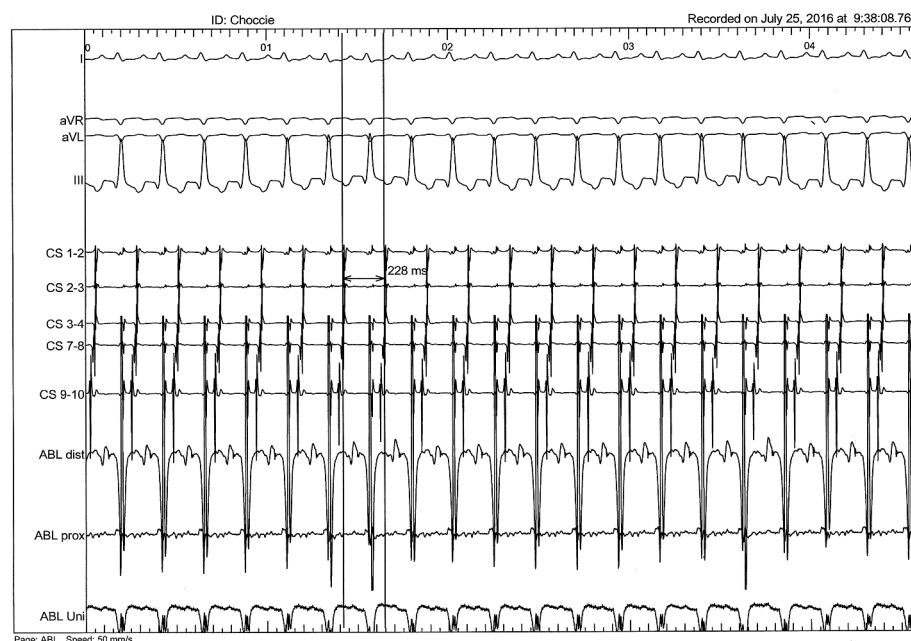


Fig. 4. Tachycardia registered during EPS. Superficial and intracardiac recording. Paper speed 50 mm/s

and spironolactone (Cardalis large, 10 mg/80 mg, once a day). Holter ECG revealed persistent supraventricular tachycardia (Fig. 1 and 2). The PQ interval varied in duration from normal to markedly shortened on resting electro-

cardiograms (Fig. 3) and subsequently on Holter recordings, probably as a manifestation of dual AVN conduction. The tachycardia was unresponsive to vagal maneuvers or IV lidocaine, and parenteral diltiazem was introduced and gradually up titrated to 60 mg q8h PO. Although continuous ECG documented reversion to predominantly sinus rhythm, after approximately 48 hours symptoms of heart failure progressed and frequent paroxysmal tachycardia persisted. Because of concern regarding the negative inotropic effects of additional diltiazem or beta blocker therapy, oral therapy with a loading dose of amiodarone was initiated (initially 250 mg, once a day). The frequency of paroxysmal tachycardia was reduced and the dog's demeanor improved, allowing discharge with torasemide (UpCard), 5 mg, once a day instead of furosemide. On reassessment 5 weeks later the dog was bright with an improved exercise tolerance.

Routine hematology biochemistry and thyroxine levels were within normal limits. Amiodarone assay was reported as 0.6 mg/l and desethylamiodarone 0.2 mg/l. After discussion regarding the potential for electrophysiological study and radio frequency ablation the owners were referred to the Cardiology Unit at the Department of Internal Medicine and Clinic of Diseases of Horses, Dogs and Cats, Faculty of Veterinary Medicine, at the University of Environmental and Life Sciences in Wrocław. Amiodarone therapy was discontinued 30 days before the planned intervention, and diltiazem was withdrawn 24 h prior to the procedure.

Blood morphology and biochemistry (WBC, RBC, PLT, Hb, Ht, urea, creatinine, ALT, AST, FA, K^+ , Na^+ , Ca^{2+}) were normal.

Electrophysiological study and ablation procedure. An electrophysiological study (EPS) was performed in July 2016. Following premedication with medetomidine (20 µg/kg) and induction of general anesthesia with intravenous propofol (4 mg/kg) anesthesia was maintained with isoflurane. The dog was placed in dorsal recumbency. Vascular access was obtained via the right external jugular vein and femoral vein, using the Seldinger technique. Under fluoroscopic and echocardiographic guidance, a 6F decapolar electrode catheter was inserted through the right external jugular vein into the coronary sinus (CS). A 7F steerable ablation catheter was inserted through the femoral vein into the high right atrium (HRA) and right ventricular apex (RVA). A permanent tachycardia with narrow QRS complexes, 230-ms cycle length (Fig. 4) and V-A sequence was observed suggestive of postero-septal origin of the local atrial signals. His-ventricular (H-V) interval during

tachycardia was 50 ms with 1 : 1 conduction. Ventricular entrainment excluded presence of ectopic atrial tachycardia (EAT). Atria were "captured" during ventricular stimulation, and a 100-ms difference between post-pacing interval (PPI) and cycle length (CL) indicated the likely presence of AVRT. Conduction mapping demonstrated the coronary sinus (CS) ostium was the first area to be activated on the atrial side of the tricuspid annulus (Fig. 5). One application of RF energy (120 s, 30 W, 65°C) resulted in a successful resolution of AVRT and the return of sinus rhythm, at a rate of 140 BPM. Subsequent stimulation of the CS, HRA and RVA did not trigger an arrhythmia, either immediately or 30 min post-application, and no signs of conduction via an AP were observed (Fig. 6). However, there remained indirect evidence of dual conduction within the atrioventricular

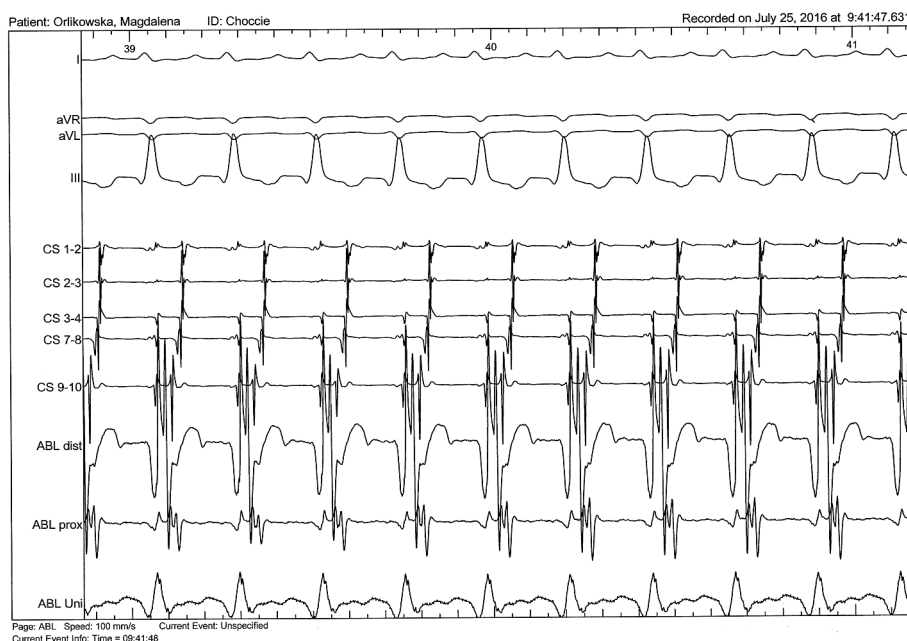

Fig. 5. The earliest local signal at coronary sinus ostium detected during mapping of the tricuspid annulus. Paper speed 100 mm/s

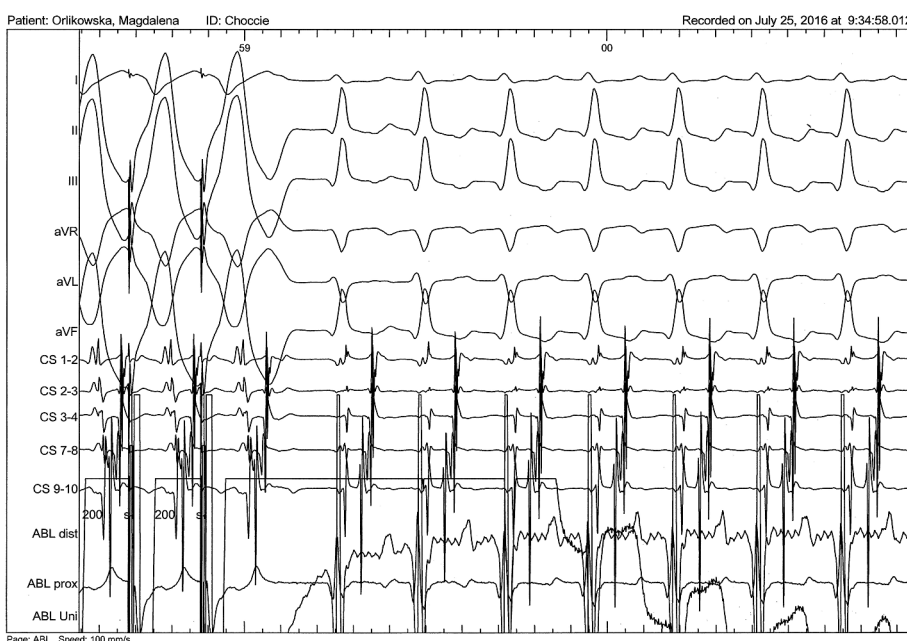


Fig. 6. Ventricular stimulation with 200-ms cycle length, with no signs of resultant arrhythmia. Paper speed 100 mm/s

junction. Recovery from the procedure was uneventful. Oral medication was continued with Pimobendan, Benazepril and Spironolactone and metoprolol prolongatum (Betalo Zoc, 1 mg/kg). No arrhythmia was documented on repeat Holter after one month and on account of this metoprolol prolongatum was discontinued. No recurrent arrhythmia was observed during a further 3-month follow-up, and both left ventricular dimension and function gradually normalized.

Discussion

Permanent or frequent tachycardia can result in the development of systolic dysfunction or "tachycardiomyopathy" (TICM) (4, 5). The development of systolic dysfunction is postulated to reflect aberrant calcium handling during high heart rates. Tachycardia is typically associated with AVRT, focal atrial tachycardias, atrial fibrillation and atroventricular nodal reentry tachycardia, though the latter has not been reported in dogs. Echocardiographically TICM appears as a dilated cardiomyopathy (DCM) phenotype. The identification and management of tachycardias in dogs with a DCM phenotype is important since tachycardiomyopathies are potentially reversible and may be associated with a more favorable prognosis in comparison to a primary cardiomyopathy.

Medical management of supraventricular tachycardia can be challenging, particularly in patients with severe systolic dysfunction. Dogs with systolic dysfunction may be intolerant of the negative inotropic effects associated with anti-arrhythmic therapy and develop iatrogenic heart failure. Injectable antiarrhythmic medications are not consistently available and attempts at rapid conversion of supraventricular arrhythmias with intravenous anti-arrhythmic medications have been associated with sudden death. For this reason this dog was managed with a combination of oral diltiazem and afterwards by amiodarone: an anti-arrhythmic possessing class I, II, III and IV properties with minimal negative inotropic effects. Amiodarone has been reported to be useful in the management of refractory supraventricular and ventricular arrhythmias but has been associated with a number of serious side effects and a loading protocol has been recommended to allow therapeutic concentration to be reached more rapidly. Because medical therapy would have required life long medication and monitoring for amiodarone toxicity and because of incomplete arrhythmia suppression an electrophysiological study was recommended.

The prevalence of accessory pathways in dogs is hard to estimate because the only source of evidence are single published case reports. Incidence of WPW syndrome in humans is estimated at 0.15-0.25% of the general population, with the majority of APs located in the left heart (9). In contrast, in most reported canine cases APs were found in the right free wall (12). In the presented case, AP was located in posteroseptal part of the tricuspid annulus, which is the second most

common location of the canine accessory pathway. Labrador Retrievers seem to be the most predisposed to this anomaly among all canine breeds (12, 12). Episodes of SVT in dogs are often associated with syncope, and may eventually lead to TICM (1), as in this case. Both in dogs and humans, APs may be found as an isolated defect or co-exist with other malformations, such as Ebstein's anomaly, atrial or ventricular septal defect, and pulmonary artery stenosis (8, 14). Although typically a single AP is identified, the presence of multiple accessory pathways has been sporadically reported (12).

Not all patients with APs present with an arrhythmia. Presence of arrhythmia or lack thereof is determined by electrophysiological properties of individual elements forming the re-entry loop. Medications and physiological maneuvers may modulate the degree of pre-excitation. Characteristic electrocardiographic abnormalities reported in humans with WPW syndrome, resulting from fusion of conduction via an AP and the physiological pathway, such as a short PR (P-delta) interval, deformed upstroke of the ventricular complex (delta wave) and QRS complex, are rarely found in dogs. The most common of these characteristics is PQ shortening, but usually the difference between PQ interval on electrocardiographic recordings with pre-excitation and without is no greater than 10-20 ms. Therefore, most dogs are diagnosed for presence of an AP when electrocardiographic abnormalities co-exist with symptomatic episodes of SVT. In some cases, despite the presence of an anterograde AP, no signs of pre-excitation are seen periodically on surface electrocardiographic recordings. This happens whenever electric stimulus delivered via the physiological pathway reaches ventricular myocardium earlier than that transmitted by an AP and has been described as concealed conduction.

The aim of electrophysiological studies is to determine the mechanisms of arrhythmia, particularly the presence of APs, their number and electrophysiological properties, as well as their contribution to arrhythmia (10). Although several electrophysiological protocols can be used to detect an AP and to determine its characteristics, many of them require ECG assessment in sinus rhythm or atrial and ventricular stimulation during sinus rhythm, which is not always possible in patients with persistent AVRT. The outcomes of electrophysiological maneuvers in this case were consistent with the presence of AVRT. Conduction mapping identified coronary sinus (CS) ostium as the first area to be activated on the atrial side of the tricuspid annulus. Ablation of this region with RFCA was successful in destroying the accessory pathway and terminating reentry. The first canine RFCA was performed in 1985 by Kathy N. Wright and colleagues from the Ohio State University (17). In Italy, the first ablation of AP was carried out by Roberto Santilli in 2006 (12), and

in Poland by a joint team including veterinary cardiologists from the Department of Internal Medicine and Clinic of Diseases of Horses, Dogs and Cats at the University of Environmental and Life Sciences in Wrocław and physicians for humans from the 4th Military Clinical Hospital in Wrocław (11). RFCAs, the treatment of choice in AP-related tachyarrhythmia, are performed at only a few veterinary centers worldwide. RFCA is a relatively safe technique, but requires an experienced electrophysiologist and therefore in many veterinary clinics this procedure is performed in cooperation with electrophysiologists for humans which may limit its more widespread adoption (11, 16). A key to successful ablation of AP is accurate identification of its topography. Following the protocol during EPS in humans, we used an ablation electrode for AP mapping, which enabled us to reduce the number of vascular access points. Ablation of right accessory pathways is typically performed on the atrial side, and involves the first area activated by electric stimulus conducted via the AP. Effectiveness of ablation is confirmed not only by the lack of tachycardia but also by a complete loss of conduction via the accessory pathway. In this case, RFCA resulted in immediate resolution of persistent orthodromic AVRT and elimination of retrograde conduction. Furthermore, no recurrent arrhythmia was observed during a 9-month follow-up, along with a gradual improvement of the left ventricular function. Overall, these findings imply that canine RFCA may be equally effective as the same procedure performed in humans.

References

1. Atkins C. E., Kanter R., Wright K., Saba Z., Baty C., Swanson C., Bai S., Keene B. W.: Orthodromic reciprocating tachycardia and heart failure in a dog with a concealed posteroseptal accessory pathway. *J. Vet. Intern. Med.* 1995, 9, 43-49.
2. Bussadori C., Amberger C., Le Bobinnec G., Lombard C. W.: Guidelines for the echocardiographic studies of suspected subaortic and pulmonic stenosis. *J. Vet. Cardiol.* 2000, 2, 15-22.
3. Butterworth J. S., Poindexter C. A.: Short P-R interval associated with a prolonged QRS complex. A clinical and experimental study. *Arch. Intern. Med.* 1942, 69, 437-445.
4. Cohn A. E., Fraser F. R.: Paroxysmal tachycardia and the effect of stimulation of the vagus nerve by pressure. *Heart* 1913, 14, 93-105.
5. Foster S. F., Hunt G. B., Thomas S. P., Ross D. L., Pearson M. R., Malik R.: Tachycardia-induced cardiomyopathy in a young Boxer dog with supraventricular tachycardia due to an accessory pathway. *Aust. Vet. J.* 2006, 84, 326-331.
6. Gugjoo M. B., Hoque M., Saxena A. C., Shamsuz Zama M. M., Dey S.: Reference values of M-mode echocardiographic parameters and indices in conscious Labrador Retriever dogs. *Iran. J. Vet. Res.* 2014, 15, 341-346.
7. Hanon S., Shapiro M., Schweitzer P.: Early history of the pre-excitation syndrome. *Europace* 2005, 7, 28-33.
8. Hills B. L., Tilley L. P.: Ventricular preexcitation in seven dogs and nine cats. *J. Am. Vet. Med. Assoc.* 1985, 187, 1026-1031.
9. Kugler J. D., Danford D. A., Houston K., Felix G.: Radiofrequency catheter ablation for paroxysmal supraventricular tachycardia in children and adolescents without structural heart disease. *Pediatric EP Society, Radiofrequency Catheter Ablation Registry. Am. J. Cardiol.* 1997, 80, 1438-1443.
10. Naccarelli G. V., Shih H. T., Jalal S.: Catheter ablation for the treatment of paroxysmal supraventricular tachycardia. *J. Cardiovasc. Electrophysiol.* 1995, 6, 951-961.
11. Noszczyk-Nowak A., Fuglewicz A., Nowak K., Skrzypczak P., Janiszewski A., Paslawska U., Nicpoń J.: Radiofrequency catheter ablation of focal atrial tachycardia as a treatment of tachycardia-induced dilated cardiomyopathy in a dog. *Bull. Vet. Inst. Puławy* 2011, 55, 267-271.
12. Santilli R. A., Spadacini G., Moretti P., Perego M., Perini A., Tarducci A., Crosara S., Salerno-Uriarte J. A.: Radiofrequency catheter ablation of concealed accessory pathways in two dogs with symptomatic atrioventricular reciprocating tachycardia. *J. Vet. Cardiol.* 2006, 8, 157-165.
13. Santilli R. A., Spadacini G., Moretti P., Perego M., Perini A., Crosara S., Tarducci A.: Anatomic distribution and electrophysiologic properties of accessory atrioventricular pathways in dogs. *J. Am. Vet. Med. Assoc.* 2007, 23, 393-398.
14. Wolferth C. C., Wood F. C.: The mechanism of production of short P-R interval and prolonged QRS complexes in patients with presumably undamaged hearts; hypothesis of an accessory pathway of auriculo-ventricular conduction (bundle of Kent). *Am. Heart J.* 1933, 8, 297-311.
15. Wolff L., Parkinson J., White P. D.: Bundle-branch with short P-R interval in healthy young people prone to paroxysmal tachycardia. *Am. Heart J.* 1930, 5, 685-704.
16. Wright K. N., Knilans T. K., Irvin H. M.: When, why, and how to perform cardiac radiofrequency catheter ablation. *J. Vet. Cardiol.* 2006, 8, 95-107.
17. Wright K. N., Mehdirad A. A., Giacobbe P., Grubb T., Maxson T.: Radiofrequency catheter ablation of atrioventricular accessory pathways in 3 dogs with subsequent resolution of tachycardia-induced cardiomyopathy. *J. Vet. Intern. Med.* 1999, 13, 361-371.

Corresponding author: dr hab. Agnieszka Noszczyk-Nowak, prof. UP, 47 Grunwaldzki Sq., 50-366 Wrocław; e-mail: anoszczynowak@gmail.com