

The Parotid Gland as a Metastatic Basin for Cutaneous Cancer

Christopher J. O'Brien, AM, MB,BS, MS, MD, FRACS

IT IS A GREAT HONOR TO HAVE BEEN invited to give the Hayes Martin Lecture at this, the 6th International Conference on Head and Neck Cancer. I am particularly grateful to Dr Jonas Johnson, president of the American Head and Neck Society, for this invitation. It is my plan to address the issue of involvement of the parotid gland and cervical lymph nodes by metastatic cutaneous squamous cell carcinoma (SCC) of the head and neck. In doing so, I hope I can speak to you on behalf of my many colleagues in Australia and New Zealand because this disease, although it is not unique to the Australasian region, occurs with such frequency in Australia and New Zealand that one may be forgiven for thinking that this form of cancer is geographically unique. Before presenting data on this issue, I would like first to mention my own relationship with the great Hayes Martin and to address some themes from some outstanding literary figures that are relevant to today's discussion.

HAYES MARTIN (1892–1977)

Dr Hayes Martin died in 1977, leaving a significant and enduring legacy. His influence and contribution live on and extend far beyond the boundaries of his alma mater, Memorial Hospital, New York, NY.¹ My own association with Dr Martin began in August 1984 when I spent 1 year working with Dr Henry Shaw, consultant otolaryngologist and head and neck surgeon, at the Royal Marsden Hospital, London, England. Henry Shaw traveled from England to New York as a young otolaryngologist to learn head and neck surgery from Dr Martin and subsequently returned to the Royal Marsden Hospital, helping to establish it as one of England's leading centers for the treatment of head and neck cancer. After my year with Dr Shaw, I worked for 18 months at the University of Alabama, Birmingham, in the United States with Dr Bill Maddox. Dr Maddox was a past president of the Society of Head and Neck Sur-

geons, and he had also worked with Hayes Martin at Memorial Hospital during the 1950s. Bill Maddox was regarded as one of the great surgeons of the South and was revered for his technical skill and his folksy Southern wisdom.

Through my association with Bill Maddox and Henry Shaw, I was able to learn, with only 1 degree of separation, something of the teachings of Hayes Martin. Dr Martin advanced our knowledge in many areas with his pioneering use of radiotherapy and fine-needle aspiration biopsy; his development of surgical techniques, particularly in the management of oral cancers and metastatic cancer in the neck; and his rigorous scientific approach to the collection and analysis of clinical data. Even in the area of parotid surgery—the principal focus of my lecture today—Hayes Martin described very clearly more than 50 years ago his approach, which has lost none of its clinical or scientific validity. He wrote, in 1952, “For the majority of parotid tumors, either benign or malignant, the ideal surgical program would be one designed to remove the tumor together with a portion of the parotid gland and to spare all or whatever branches of the [facial] nerve that are not involved.”^{2(p670)}

PARADIGMS FROM LITERATURE

The influence of Dr Hayes Martin on the specialty of head and neck surgery has been profound, and generally this influence could be regarded as being positive rather than inhibitory. The inhibitory influence of great individuals on their successors is a real phenomenon and a favorite theory of Prof Harold Bloom, Sterling Professor of Humanities at Yale University and Professor of English at New York University. Professor Bloom is recognized as one of the world's great contemporary literary critics. He has written many books, perhaps the most important of which is *The Western Canon*,³ a work that examines 26 writers deemed by Bloom to be canonical, or authoritative, in our culture. He

Author Affiliations: Sydney Head and Neck Cancer Institute, Sydney Cancer Centre, Royal Prince Alfred Hospital and University of Sydney, Sydney, Australia.
Financial Disclosure: None.

places Shakespeare at the center of his (and our) literary world and expands on his theory called “the anxiety of influence.” In short, the theory holds that writers are influenced, haunted, and even inhibited by their predecessors, sometimes never escaping their shadow. Furthermore, Bloom believes that Shakespeare remains the greatest of these influences and, in a subsequent scholarly volume, *Shakespeare: The Invention of the Human*,⁴ refers to Shakespeare as the inventor of our emotional vocabulary and center of our literary universe.

The extent to which writers, artists, composers, actors, architects, or any individuals working in creative fields are influenced by their predecessors will, of course, vary tremendously and be open to much speculation and individual interpretation. The anxiety of influence seems to be less significant in medicine, and, indeed, even in head and neck oncology our surgical egos tend to protect us from the inhibitory influences of our predecessors as we reinvent operations, call them our own, and overlook our indebtedness to the many great medical pioneers who have gone before us.

To continue the literary theme further, I would like to introduce to our discussion Leo Tolstoy. Tolstoy was born in 1828 in Russia, and his early adult life was fairly dissolute, but ultimately he married and became a dedicated family man. He is, of course, most famous for his great novels *War and Peace*, written between 1865 and 1868, and *Anna Karenina* (1874-1876). *War and Peace* is widely regarded as the greatest book ever written. It has 3 principal facets. First, it is an epic novel dealing with the lives of a variety of aristocratic individuals in 19th-century Russia. Second, it has as its background Napoleon's invasion of Russia in 1812, which led to a hollow conquest of Moscow and then to an ultimately disastrous withdrawal. Third, the novel has a recurrent and sometimes annoyingly tendentious commentary from Tolstoy that culminates in a very lengthy epilogue. In particular, the author introduces and explains his theory about why things happen. It is Tolstoy's view that the events of 1812, and in fact all events in history, should be interpreted in their wider context. Napoleon's invasion of Russia should not be seen as a result simply of a decision by one man to lead the largest army ever gathered into a foreign country but rather as the culmination of accumulated events requiring the participation and compliance, for whatever reason, of a myriad of individuals. Similarly, the First World War did not begin simply because Archduke Franz Ferdinand was assassinated in Sarajevo by the young Serb Gavrilo Princip in 1914. This event simply lit a fuse that could have been extinguished at any time in the subsequent weeks but that led to the outbreak of a brutal conflict that cost 10 million lives. In fact, the political and economic foundations were already laid, with established alliances, long-standing war plans, and hatred and mistrust based on multiple historical events.

HISTORICAL BASIS FOR AUSTRALASIA'S SKIN CANCER EPIDEMIC

How is this relevant to my central topic of discussion, which concerns metastatic cutaneous cancer? The ex-

traordinarily high incidence of cutaneous malignancy in Australia is rooted in England's 18th-century penal system and reflects the impact of history and environment on a susceptible phenotype.

Transportation was a common form of punishment in 18th-century England, and lawbreakers were transported to foreign penal colonies, particularly North America. This practice ceased with the outbreak of the American War of Independence, leading to the subsequent overcrowding of English prisons, including the hulk ships used as jails and moored in the Thames. Alternative penal destinations were sought, and the east coast of Australia, specifically the site now occupied by the city of Sydney, was chosen. Transportation of convicts began in 1788, and by 1865, more than 165 000 British and Irish convicts had been transported. Land grants attracted a further 750 000 free settlers during the same period. These free immigrants were hoping to escape the poverty and, in some cases, starvation in England and Ireland. Indeed, the Irish potato famine of 1845 to 1850 saw Ireland's population decline from 8 million to 5 million as a million people died and 2 million migrated. Many of these immigrants found their way to North America, but many also came to Australia and New Zealand.

The migration of hundreds of thousands of fair-skinned Anglo-Celtic individuals to a harsh environment characterized by long hours of intense sunshine set the scene for the current epidemic of cutaneous malignancy that exists in Australia and, to a lesser extent, New Zealand today. In Australia, the estimated incidence of nonmelanoma skin cancer is 250 to 300 per 100 000 individuals per year.⁵ However, this is not a notifiable cancer, and accurate incidence rates are not available. Melanoma affects approximately 31 to 41 per 100 000 population⁶ per year (females and males, respectively), with the incidence of melanoma increasing with proximity to the equator. With so many of these cutaneous cancers affecting the skin of the head and neck and having the capability of spreading via the lymphatics, it is not surprising that the most common parotid malignancy seen in Australia is metastatic cutaneous cancer.⁷

At the Sydney Head and Neck Cancer Institute, Royal Prince Alfred Hospital (RPAH), we perform approximately 90 parotidectomies per year. In **Table 1**, a summary of the RPAH parotidectomy experience between 1987 and 2003 is compared with that of 2 older but significant North American series from the Memorial Sloan-Kettering Cancer Center⁸ and the Mayo Clinic.⁹ At RPAH, approximately 29 parotid cancers were treated each study year. More than 75% (382/485) of the parotid cancers treated throughout the study period were metastatic. During the study period, 226 parotidectomies were performed for cutaneous SCC, representing 46% of all cancers. There were 123 parotidectomies for metastatic melanoma, all therapeutic procedures, and these also outnumbered the primary parotid malignancies.

Metastatic cutaneous SCC of the parotid gland does occur in North America, but with less frequency. **Table 2** summarizes 3 North American series that have been published previously.¹⁰⁻¹²

Table 1. Comparison of Parotidectomy at 3 Medical Centers

Variable	RPAH	MSKCC*	Mayo Clinic*
Study period, y	17	35	30
Parotidectomies			
Total No.	1107	1965	1360
No./y	65	56	45
Cancers			
Total No. (%)	485 (44)	623 (32)	228 (17)
No./y	29	18	8
Most common cancers, No. (%)	Metastatic SCC, 226 (47) Metastatic melanoma, 123 (25) Mucoepidermoid, 26 (5)	Mucoepidermoid, 272 (44) Carcinoma ex pleomorphic, 107 (17) Acinic, 75 (12)	Mucoepidermoid, 62 (27) Acinic, 34 (15) Adenoid cystic, 28 (12)

Abbreviations: MSKCC, Memorial Sloan-Kettering Cancer Center; RPAH, Royal Prince Alfred Hospital; SCC, squamous cell carcinoma.

*Metastatic cancers were not reported in these centers.

Table 2. Parotidectomy for Metastatic SCC in 3 North American Series

Institution	Parotidectomies, No.	Study Period, y	Local Control (2 y), %	Survival (5 y), %
M. D. Anderson (1981) ¹⁰	57	17	84	NA
Ann Arbor (1987) ¹¹	24	15	33	NA
University of Florida (1998) ¹²	53	28	90	72

Abbreviation: NA, not available.

Table 3. Distribution of Pathologically Positive Neck Nodes in Patients With Parotid Squamous Cell Carcinoma*

Clinical Status	Nodes, No.		Level Involved, No.				
	Total	Pathologically Positive	I	II	III	IV	V
Positive	19	16	7	16	8	8	4
Negative	37	13	3	8	4	3	1

*Reproduced with permission from O'Brien et al.¹⁵

CLINICAL BEHAVIOR OF METASTATIC SCC INVOLVING THE PAROTID

The incidence of regional metastases among patients with cutaneous SCC is estimated to be 5%, although this is based on a study of non-head and neck sites.¹³ Cancers of the frontal scalp, forehead, face, and ear can readily metastasize to lymph nodes within the parotid gland.

In an initial study from RPAH,¹⁴ 75 patients with metastatic SCC involving the parotid or neck were analyzed. The disease seemed to be biologically aggressive, and extracapsular spread was identified in at least 70% of cases. There was evidence that conservative surgery was frequently associated with positive surgical margins; however, the addition of adjuvant radiotherapy seemed to reduce the recurrence rate in the parotid bed. In that study,¹⁴ patients with involvement of the cervical nodes had a higher incidence of distant metastatic disease and a worse prognosis. Local recurrence was a significant problem and occurred in the deep parotid bed and, less frequently, in dermal lymphatic arrests in the skin. The latter finding is typical of metastatic cutaneous cancer, perhaps because dermal lymphatic invasion precedes nodal involvement.

CERVICAL NODE INVOLVEMENT

The issue of neck involvement among patients with metastatic SCC involving the parotid gland was addressed in a subsequent study.¹⁵ Of 73 patients with parotid SCC, 26% had clinically positive cervical nodes, whereas among those with clinically negative nodes who had an elective neck dissection, 36% had pathologically involved cervical nodes. Overall, therefore, more than 50% of the patients had cervical node involvement, and the conclusion from the study was that treatment of the neck is mandatory in patients with metastatic SCC involving the parotid gland. **Table 3** summarizes the incidence of nodal involvement along with the distribution of positive neck nodes in that study group.

EXTERNAL JUGULAR LYMPH NODE

The **Figure** shows a diagrammatic representation of the neck with the external jugular lymph node. This is a common site for metastatic disease from cutaneous malignancy (SCC and melanoma). The lymph node(s) is found near the anterior border of the sternomastoid muscle at the

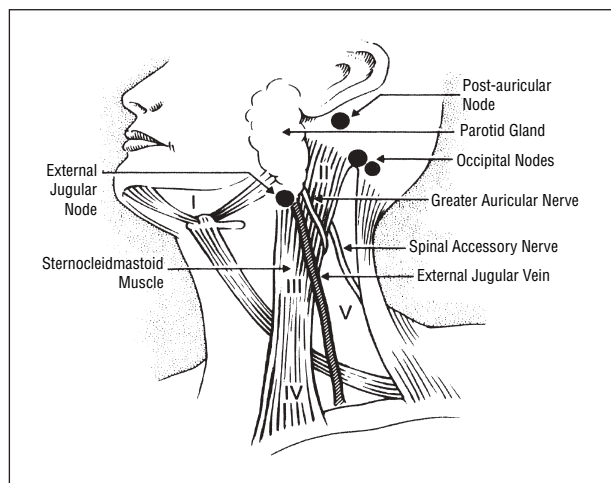


Figure. Diagrammatic representation of the neck showing the neck levels and other node groups that can be involved by metastatic skin cancer, particularly the external jugular node. Reproduced with permission from Thompson JF, Morton DL, Kroon BR, eds. *Textbook of Melanoma*. London, England: Martin Dunitz; 2004.

Table 4. Possible Revised Staging With Separation of Parotid (P) and Neck (N) Disease

P1	Single parotid lymph node ≤ 3 cm in diameter
P2	Node > 3 cm and up to 6 cm in diameter or multiple nodes
P3	Node > 6 cm in diameter or facial nerve or skull base involvement
N0	Neck disease absent
N1	Single node ≤ 3 cm in diameter
N2	Node > 3 cm in diameter or multiple nodes

lower end of, but not within, the parotid gland, where the external jugular vein crosses the sternomastoid muscle. This node must be removed in any lymphadenectomy, parotidectomy, or neck dissection for cutaneous malignancy.

TNM STAGING OF CUTANEOUS MALIGNANCY

One of the limitations of the current TNM staging system for skin cancer used by the American Joint Committee on Cancer is that all patients with regional metastatic disease are simply designated N1 irrespective of the extent of metastatic disease. This designation would include a patient with a single 2-cm parotid metastasis, a patient with a 7-cm parotid metastasis with skin ulceration and facial nerve invasion, and a patient with parotid and neck metastases.

In a previous study, O'Brien et al¹⁶ hypothesized that the current TNM staging classification, at least when applied to the head and neck, may not provide adequate prognostic discrimination. It was suggested that perhaps parotid and neck involvement may have independent prognostic significance and therefore should be separated by the introduction of a P (parotid) stage. It was further suggested that the extent of disease within the parotid and neck may also be significant and that possibly there should be subgroupings of P stage and N stage.

Table 4 gives the hypothetical revised staging system that was introduced in a previous study.¹⁶ A cohort

of 87 patients, including those previously analyzed in 2001 for cervical node involvement, was restaged using the new staging system, and clinical outcome was analyzed. The major findings were as follows:

1. Local control in the parotid bed decreased as P stage increased, with local control rates of 85%, 72%, and 50% for stages P1, P2, and P3, respectively ($P = .07$).
2. Increasing P stage did not have a statistically significant association with survival.
3. Survival did, however, vary significantly with clinical N stage, with patients staged N0 or N1 having 5-year survival of 65% to 70%, whereas those staged N2 experienced 5-year survival of slightly more than 30% ($P < .05$).
4. Survival also varied significantly with pathological N stage, with 4-year survival of 80%, 50%, and 28% for those staged N0, N1, and N2, respectively ($P < .01$).

FOLLOW-UP STUDY WITH A DIFFERENT PATIENT COHORT

Because the results of this initial study may have been sample specific, the proposed staging classification was tested on a different patient cohort, and these results, from Westmead Hospital in Sydney, have also been published.¹⁷ Of 126 patients, 81 had clinical disease in the parotid gland, and, of these, approximately 23% had pathologic involvement of neck nodes. This is less than half the incidence of pathologic node involvement identified in patients initially analyzed from RPAH. Furthermore, a high proportion of patients in the follow-up study were immunosuppressed, and some had disease only in the neck. The findings from this follow-up study can be summarized as follows:

1. Local control in the parotid bed varied significantly with increasing P stage, with those staged P1, P2, and P3 having local control rates of approximately 85%, 50%, and 25%, respectively ($P < .001$).
2. Survival also varied significantly with P stage, with 2-year survival of 88%, 62%, and 30% for stages P1, P2, and P3, respectively ($P < .001$).
3. The addition of pathologic cervical node involvement did not have a worsening effect on survival. Note that this finding contrasted with the results of the initial study of patients from RPAH in which clinical and pathologic node involvement were significant prognostic factors.
4. Patients treated with radiotherapy alone had a significantly worse outcome than those treated with surgery alone or combined surgery and radiotherapy.
5. Immunosuppressed patients had a significantly worse survival rate than those who were not immunosuppressed.

MULTICENTER STUDY

To further examine whether the current TNM staging system for cutaneous cancer as it affects the head and neck should be expanded, the study group was expanded to include patients from the 2 initial participating institutions in Australia, RPAH and Westmead Hospital, along with other patients from Australia and North America.

The details of this multicenter retrospective study are the subject of a separate study (J. L. Andrichow, MD, M. J. Veness, FRANZR, G. J. Morgan, FRACS, K. Goa, BEng,

A. Clifford, FRACS, K. Shannon, FRACS, M. Poulsen, FRANZR, L. Kenny, FRANZR, C. Palme, FRACS, P. Gullane, MD, C. Morris, MD, W. Mendenhall, MD, K. N. Patel, MD, J. Shah, MD, and C.J.O., unpublished data, 2004) that acknowledges the contributing authors and participating institutions and gives details of the methods and results. There were 325 eligible patients, 247 from 3 Australian institutions and 78 from 3 North American institutions. Of the 325 patients, 263 had clinical disease in the parotid gland, and 43 (16%) of these 263 patients also had clinical disease in the neck. A total of 124 of 220 patients with parotid disease and clinically negative neck nodes had elective lymph node dissection, and neck nodes were pathologically positive in 28 patients in this group (23%).

Overall, therefore, 27% of the patients with metastatic SCC of the parotid gland also had pathologic neck node involvement, a result similar to the patient cohort from Westmead Hospital in the follow-up study¹⁷ but approximately half the incidence reported in the original analysis of patients from RPAH.^{15,16} The results of the multicenter retrospective study are summarized as follows:

1. Five-year survival for the entire group was 72%.
2. There was no significant difference in local control rates according to P stage. This finding was at variance with the 2 previous studies, but, overall, the rate of local control was high, being approximately 88%, 82%, and 78% for P1, P2, and P3, respectively.
3. Survival did vary significantly with P stage, with patients clinically staged P2 and P3 having significantly worse survival rates than those staged P1 (68% vs 80%; $P < .05$).
4. Survival also varied significantly with clinical N stage. Patients clinically staged N0 had 5-year survival of approximately 80% compared with approximately 65% among those with clinically positive neck nodes. There was no difference in survival among those clinically staged N1 or N2 ($P < .05$).
5. Pathologic involvement of neck nodes significantly worsened survival rates for patients with metastatic SCC of the parotid gland. Patients pathologically staged N1 and N2 had identical 5-year survival of approximately 60%, significantly worse than the 80% in patients who had neck dissections but were found to have an absence of nodal involvement ($P < .05$).
6. Multivariate analysis was performed, and the factors found to have an independent effect on survival were immunosuppression, advanced clinical parotid stage (P3), and pathologic neck node involvement. Clinical neck node involvement did not reach statistical significance ($P = .06$).

CONCLUSIONS

The multicenter retrospective study described did not correct for variations in the extent of surgery, surgical margins, or radiotherapy scheduling. The evidence, however, suggests that separation of parotid (P stage) and neck (N stage) disease may be valid. Whether there is a benefit in having subgroups of P and N stages remains uncertain. It is clear, however, that patients with metastatic cutaneous SCC involving the parotid gland have a relatively high risk of also having involvement of nodes in the neck and require combined surgery and radio-

therapy to achieve the best outcome. Treatment with radiotherapy alone tends to lead to poor results. In addition, immunosuppressed patients, who should really be regarded as a separate high-risk group, potentially have a poor outcome, and every effort should be made to improve the immune status of this group.

The results of this study are not conclusive, but they highlight a deficiency in the current TNM staging system for cutaneous cancer when it is applied to metastatic SCC of the head and neck. A more comprehensive study with more patients is required before any definitive change in the staging classification can be recommended.

Finally, I must express again my gratitude to the organizers of this 6th International Conference for extending to me the great privilege of presenting this Hayes Martin Lecture. I want also to acknowledge the contribution to this work of my colleagues and collaborators.

Submitted for Publication: February 2, 2005; accepted February 19, 2005.

Correspondence: Christopher J. O'Brien, AM, MB, BS, MS, MD, FRACS, Sydney Cancer Centre, Level 6 Gloucester House, Royal Prince Alfred Hospital, Missenden Road, Camperdown 2050 New South Wales, Australia (chris.obrien@cs.nsw.gov.au).

Previous Presentation: This study was presented as the Hayes Martin Lecture at the Sixth International Conference on Head and Neck Cancer; August 10, 2004; Washington, DC.

REFERENCES

1. Helsen J. Dr Hayes Martin: surgeon, leader, teacher and founder of our society. *Am J Surg*. 1989;158:278-282.
2. Martin H. The operative removal of tumors of the parotid salivary gland. *Surgery*. 1952;31:670-682.
3. Bloom H. *The Western Canon*. New York, NY: Harcourt Brace; 1994.
4. Bloom H. *Shakespeare: The Invention of the Human*. London, England: Fourth Estate; 1999.
5. Marks R, Staples M, Giles GG. Trends in non-melanocytic skin cancer treated in Australia: the second national survey. *Int J Cancer*. 1993;53:585-590.
6. Australian Institute of Health and Welfare (AIHW) Australasian Association of Cancer Registries (AACR). *Cancer in Australia 1998*. Canberra: Australian Institute of Health and Welfare; 2001. Cancer Series No. 17.
7. Bron LP, O'Brien CJ, McNeil EB. Primary and metastatic cancer of the parotid: comparison of clinical behavior in 232 cases. *Laryngoscope*. 2003;113:1070-1075.
8. Spiro RH. Salivary neoplasms: overview of a 35-year experience with 2,807 patients. *Head Neck Surg*. 1986;8:177-184.
9. Woods JE, Chong GC, Beahrs OH. Experience with 1,360 primary parotid tumors. *Am J Surg*. 1975;130:460-462.
10. Jackson GL, Ballantyne AJ. Role of parotidectomy for skin cancer of the head and neck. *Am J Surg*. 1981;142:464-469.
11. Marks MW, Ryan RF, Litwin MS, Sonntag BV. Squamous cell carcinoma of the parotid gland. *Plast Reconstr Surg*. 1987;79:550-554.
12. delCharco JO, Mendenhall WM, Parsons JT, Stringer SP, Cassisi NJ, Mendenhall NP. Carcinoma of the skin metastatic to the parotid area lymph nodes. *Head Neck*. 1998;20:369-373.
13. Joseph MG, Zulueta WP, Kennedy PJ. Squamous cell carcinoma of the skin of the trunk and limbs: the incidence of metastases and their outcome. *Aust N Z J Surg*. 1992;62:697-701.
14. Khurana VG, Mentis DH, O'Brien CJ, Hurst TL, Stevens GN, Packham NA. Parotid and neck metastases from cutaneous squamous cell carcinoma of the head and neck. *Am J Surg*. 1995;170:446-450.
15. O'Brien CJ, McNeil EB, McMahon JD, Pathak I, Lauer CS. Incidence of cervical node involvement in metastatic cutaneous malignancy involving the parotid gland. *Head Neck*. 2001;23:744-748.
16. O'Brien CJ, McNeil EB, McMahon JD, Pathak I, Lauer CS, Jackson MA. Significance of clinical stage, extent of surgery and pathologic findings in metastatic cutaneous squamous carcinoma of the parotid gland. *Head Neck*. 2002;24:417-422.
17. Palme CE, O'Brien CJ, Veness MJ, McNeil EB, Bron LP, Morgan GJ. Extent of parotid disease influences outcome in patients with metastatic cutaneous squamous cell carcinoma. *Arch Otolaryngol Head Neck Surg*. 2003;129:750-753.