

# Tuberous Breast: Clinical Evaluation and Surgical Treatment

Giovanni Zoccali and Maurizio Giuliani  
*Department of Health Sciences, Plastic, Reconstructive and  
 Aesthetic Surgery Section, University of L'Aquila  
 Italy*

## 1. Introduction

First described in detail by Rees and Aston in 1974, tuberous breast deformity is a pathologic condition of the breast affecting teenage woman either unilaterally or bilaterally. Other names of this deformity include snooty breast, conical breast, tubular breast deformity, domed nipple, lower pole hypoplasia.

The clinical aspect of this malformation is the base absence or deficient in vertical as well as horizontal dimension.

### 1.1 Epiphenomenon

Definition of what comprises a tuberous breast have varied since the first description. Most definition have included a range of feature such us:

- A contracted skin envelop both horizontally and vertically.
- A constricted breast base.
- A reduction in the volume of the breast parenchyma.
- Abnormal elevation of inframammary fold.
- Peudoherniation of the breast parenchyma into the areola.
- Areola hypertrophy

Some (or all) of these epiphenomenon appear to be present on first inspection of the patient, see fig.1.

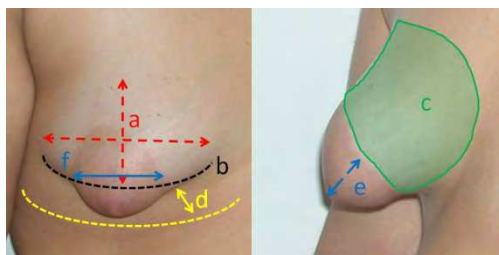


Fig. 1. Clinical epiphenomenon of tuberous breast.

## 1.2 Epidemiology

The exact incidence has not been properly investigated and remain undetermined and is probably impossible to ascertain because many woman who have mild degree of deformity may not seek help of be aware that a deformity exists. It is generally sporadic with little risk of occurrence in relatives. From a careful literature review the tuberous breast deformity has an high incidence in woman presenting with a breast asymmetry.

## 2. Pathogenesis

The etiology of tuberous breast remain still unclear. No genetic disorder are been associate to this condition and no hereditary transmission is observed. The pathogenesis of this breast deformity is linked to an aberration in thorax superficial fascia that blocks the normal expansion of glandular tissue, Fig. 2.

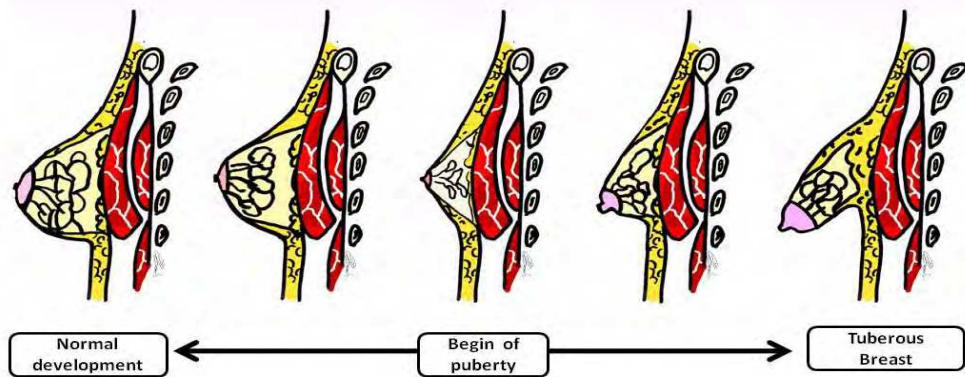


Fig. 2. Pathogenesis of tuberous breast: left side normal breast, right side malformed breast.

Normally the breast glandular tissue originate from the mammary ridge, which develops from ectoderm during the fifth week., most part of this ridge disappear, except for a small portion in the thorax region, which persists and penetrates the underlying mesenchyme around 10 to 14 weeks. The glandular development remain quiescent until puberty.

During puberty, the mammary tissue is contained in the thickness of superficial fascia. This anatomical structure is composed by two layers: the superficial one covering the outer surface of mammary parenchyma and the deeper one separate the posterior aspect of parenchyma from the muscle plane. Important is to underline that the superficial layer doesn't cover all the anterior parenchyma surface, it is absence in the area underneath the areola. With normal breast development this structure allow the peripheral breast expansion.

The onset of tuberous breast is secondary to a constricting fibrous ring at the level of periphery of the nipple- areola complex that inhibit the normal development of the breast and therefore the breast tissue cannot expand sideways and herniates through the weakest point which is the areola area because of the missing of superficial layer.

### 3. Classifications

Several classification schemes for tuberous breast have been proposed. The system described by von Heimburg has become the most commonly used. At the end of 20<sup>th</sup> century Grolleau reported a new classification. (Grolleau et al. 1999)

#### 3.1 von Heimburg classification (von Heimburg et al. 1996)

The first edition of von Heimburg classification was divided in four categories based on the degree of hypoplasia and the size of the skin envelope, fig. 3:

- Type I: hypoplasia of the lower medial quadrant.
- Type II: Hypoplasia of the lower medial and lateral quadrants, sufficient skin in the subareolar region.
- Type III: Hypoplasia of the lower medial and lateral quadrants, deficiency of skin in the subareolar region.
- Type IV: Severe breast constriction, minimal breast base.

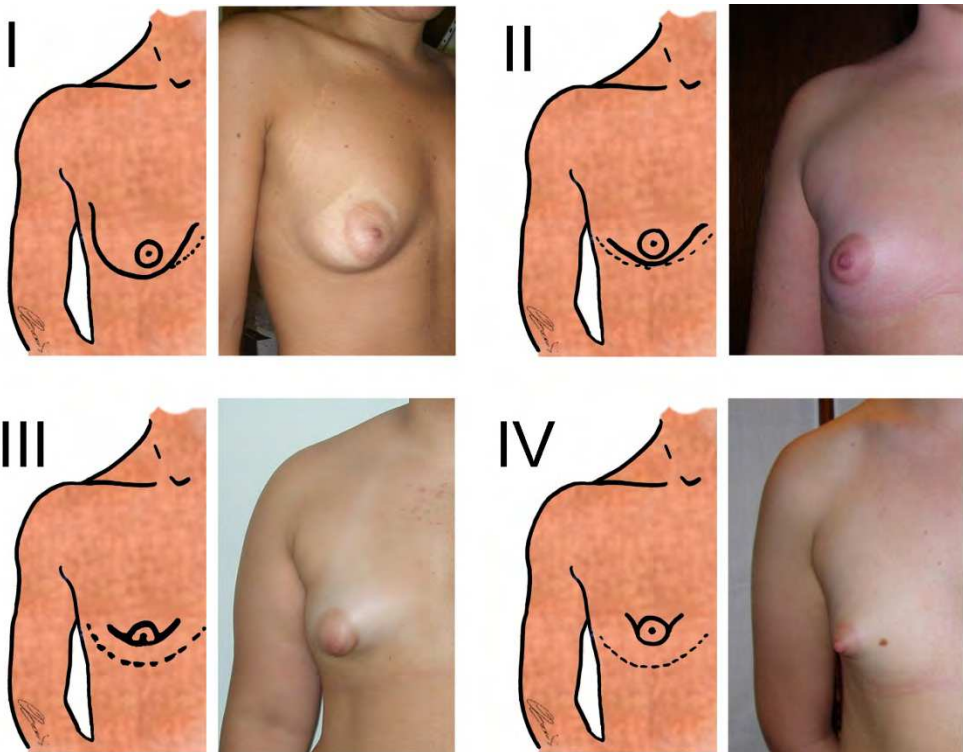


Fig. 3. Von Heimburg classification

It has been argued that type II and III are really the same because the amount of the skin envelope is simply dependent on the size of the glandular tissue itself.

### 3.2 Grolleau classification (Grolleau et al. 1999)

Following this classification system, the degree of the disorder have been reduced to three classes solely based on the degree of hypoplasia of the base of the breast, fig. 4:

- Type I: Hypoplasia of the lower medial quadrant.
- Type II: Hypoplasia of both lower quadrants.
- Type III: Hypoplasia of all four quadrants.

This classification allows a sufficient preoperative planning to choose the appropriate surgical procedure.

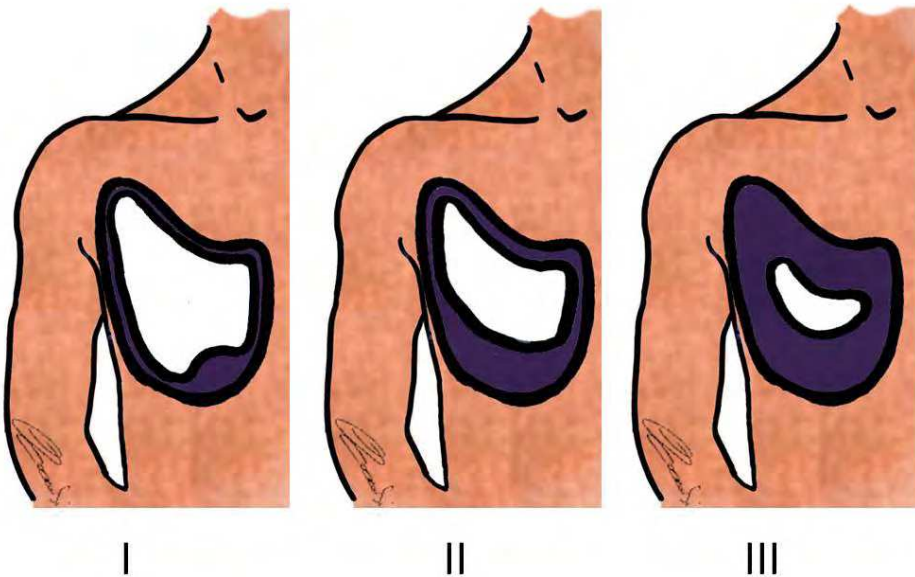


Fig. 4. Grolleau classification: in violet the theoretical breast size, in white the real amount of glandular tissue.

### 4. Differential diagnosis

In front of a wild clinical features of tuberous breast, differential diagnosis have to be done with all asymmetry condition and especially with breast ptosis, fig. 5.

The true tuberous breast has a constriction of both diameter, horizontal and vertical; tubular breast have a constriction only of horizontal one. This didactic differentiation of the same disorder is useful only in operative procedure choice. In ptotic breast the glandular parenchyma and areola have a normal structure but their position is wrong being an increase of distance between nipple-areola complex and sternal neck.

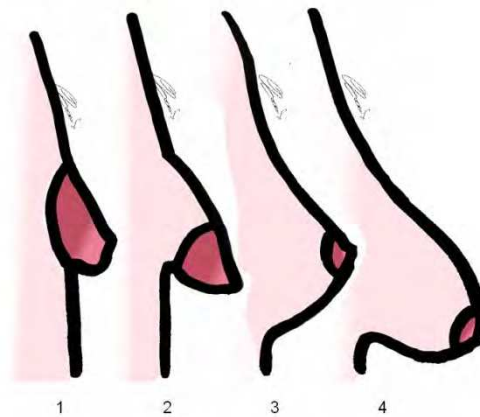


Fig. 5. Differential diagnosis: 1. Tuberous breast, 2. Tubular breast, 3. Normal breast, 4. Ptotic breast.

## 5. Treatment

Surgery is the only way to treat tuberous breast. In literature numerous techniques to correct tuberous breast deformity are reported. There has been no paradigm shift in the approach to the surgery of tuberous breast. The surgical protocol has to be planned on the patient in order to correct all malformation features.

### 5.1 Therapeutic goal

The surgical correction of tuberous breast deformity and its variants requires a comprehensive and systematic approach. Only after understanding the specific anatomic characteristics of the deformity can the surgeon plan a single stage procedure to treat each anatomic problem. The fundamental pillars to achieve a good reconstruction are:

- Reduce the areola hypertrophy.
- Increase the skin amount in the breast lower pole.
- Take down the infra mammary fold.
- Expand the glandular parenchyma.
- Increase the breast volume.

## 6. Surgical procedures

In the following part of this chapter are reported some surgical techniques to correct the tuberous breast deformity and the authors' personal experience performing Puckett technique.

### 6.1 Prosthesis implantation

The attempt to achieve a correction of tuberous deformity with prosthesis implantation is common. Often the device is located behind the glandular parenchyma through an incision

in the inframammary fold or trans-areola. This technique not always correct the parenchyma tissue imbalance and the skin envelope deficiency in the inferior breast mound. The double-bubble condition is the result of prosthetic device implantation behind the parenchyma without the expansion of breast tissue, breaking the fibrous ring. Is commonly accept that the placement of an implant as sole treatment may accentuate the appearance of the deformity, fig 6.

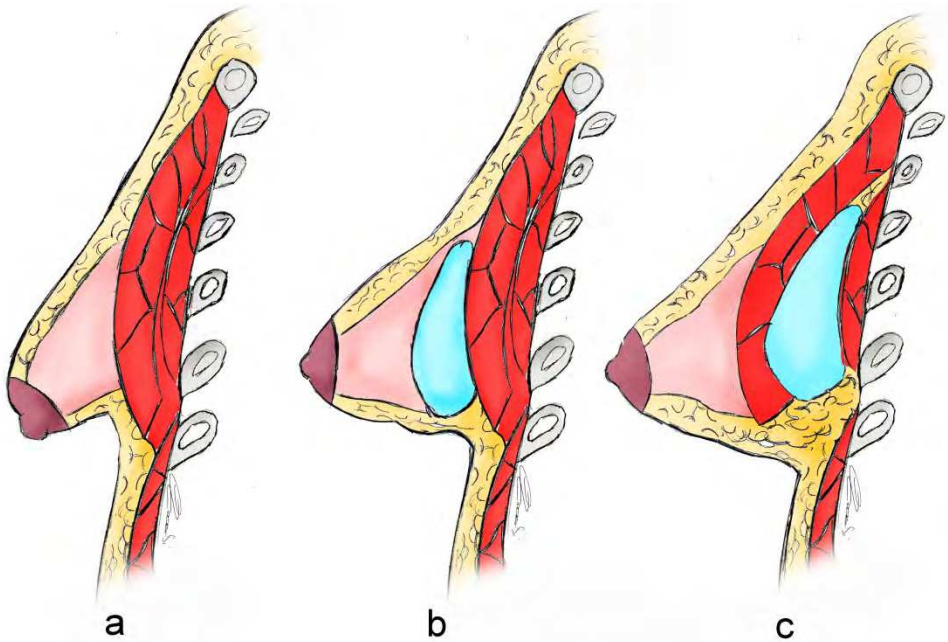


Fig. 6. Double-bubble breast after reconstruction with silicone implant. a: before surgery; b: prosthesis is inserted behind the breast tissue; c: prosthesis is located under the muscle

### 6.2 Maillard Z-Plasty (Maillard, 1986)

The target of this procedure is increase the length of nipple-inframammary fold distance.

The first step is to plan a circumareolar area in order to correct the macroareola, after peri-areola de-epithelialization, the inferior portion of the breast is extensively mobilized in the subcutaneous plane, dissection is extended inferiorly to the inframammary fold, and the glandular parenchyma is detached from the muscular fascia. The areola is moved superiorly and the breast inferior pole is reshaped performing a Z-plasty, fig 7.

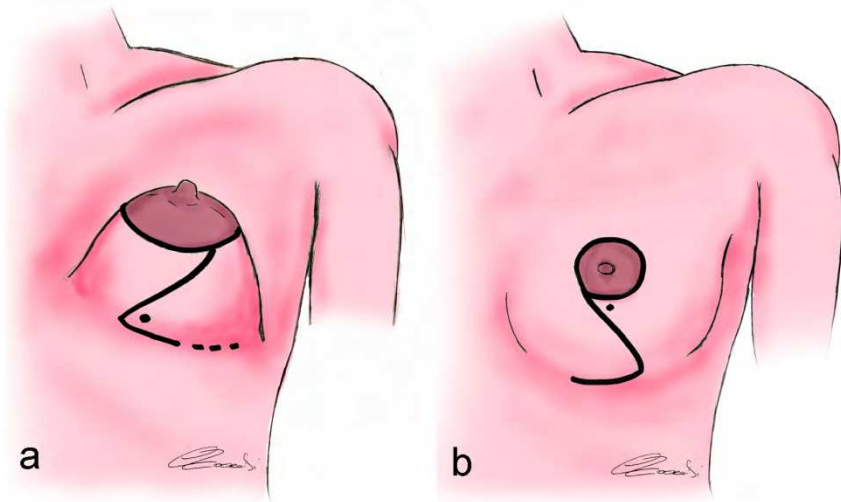


Fig. 7. Millard Z-plasty - a: preoperative planning; b: result.

### 6.3 Modified thoracoepigastric flap (Dinner & Downen, 1987)

This procedure is useful in case of deficiency of lower pole tissue especially in III type deformity. The flap is based medially with its blood supply from the lateral branches of the superior epigastric artery. The flap is dissected as thick as possible, the end of the flap is de-epithelialised and fold over itself. The folded part of the flap increase the breast volume supporting the nipple-areola complex. In front of macroareola a circular reduction can be performed, fig. 8.

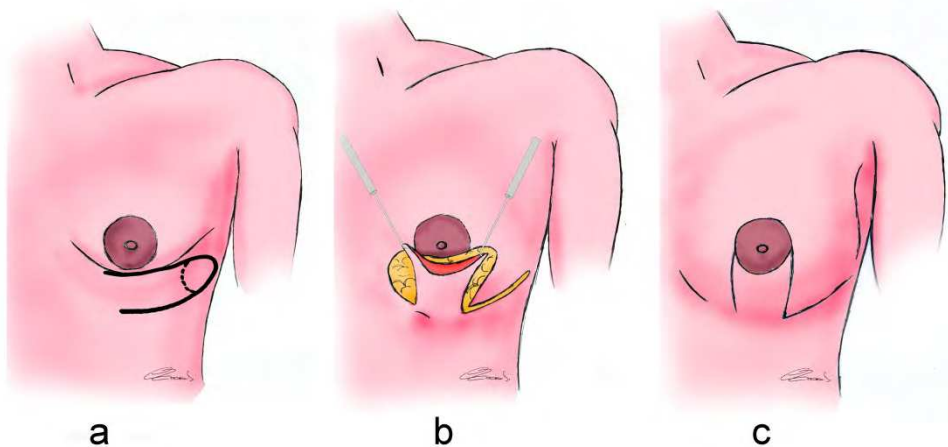


Fig. 8. Thoracoepigastric flap. a: preoperative planning, b: flap elevation, c: result.

#### 6.4 Ribeiro technique (Ribeiro, 1998)

The most significant element in the technique is crating the glandular flap and positioning it on the thoracic wall. The procedure starts with a circumareolar incision and de-epithelialization in order to reduce the areola hypertrophy. Then divide the mammary gland in half with an incision that is perpendicular to the pectoralis muscle (this disrupts the constricting fascia ring). The upper half will contain the areola; a lower pedicle flap will be created with lower half. The flap is mobilized medially and laterally and the flap is then folded over itself and fixed on the thoracic wall to give inferior pole projection.

In patient with severe hypomastia, a silicon implant can be insert in the space between the superior part of the breast and the inferior flap, fig. 9.

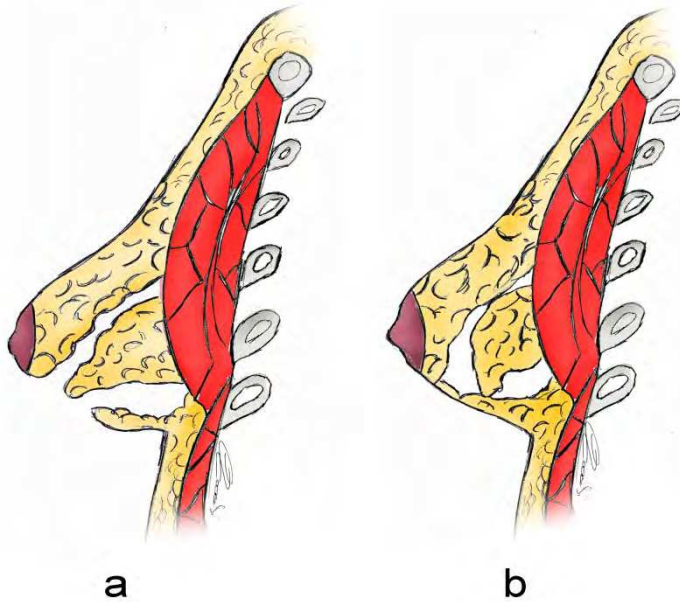


Fig. 9. Ribeiro technique - a: glandular flap elevation, b: final position of flap.

#### 6.5 Puckett technique (Puckett & Concannon, 1990)

This procedure uses the same concept of Ribeiro technique. The breast parenchyma is manipulated in order to build a glandular flap to increase the lower pole hypoplasia.

After circumareola de-epithelialization the dissection is conducted until the inframammary fold and the breast parenchyma is detached from the pectoralis fascia, a superior glandular pedicle is drawn dividing the inferior part of the breast. The flap apex is then fixed to the inframammary fold to prevent the retraction during the healing.

In case of hypoplasia a silicon implant can be placed behind the breast tissue or under the muscular plane, fig. 10.



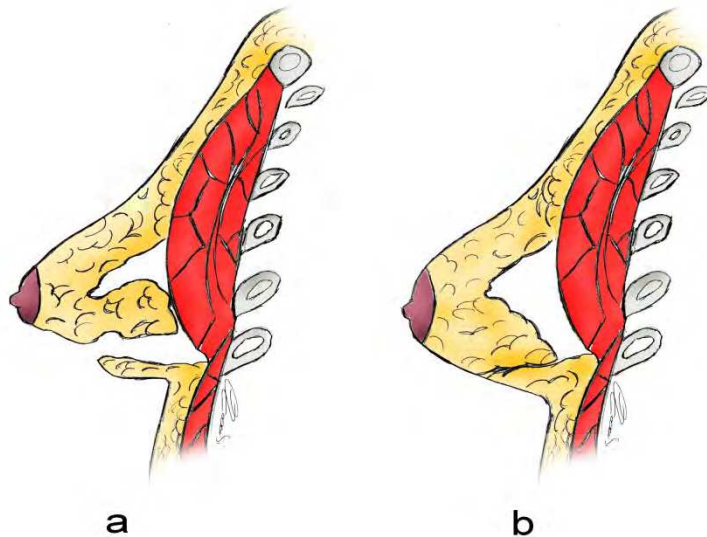


Fig. 10. Puckett technique: a: glandular flap elevation, b: final position of flap. The volume deficiency can be filled with a silicone gel prosthesis placed behind the breast parenchyma or under the pectoralis muscle.

### 6.6 Lipofilling

Lipofilling also known as fat transfer or fat graft is newer technique to treat tuberous breast. In order to improve the breast contour, the fat tissue, obtained by a liposuction and processed using Coleman protocol, is injected in tissues thickness. The fundamental limit of this technique is linked to the low amount of tissue that can be transfer: to survive the fat graft needs the contact with surrounding tissue so the injection of high quantity in the same place not allow the revascularization of fat that gradually become necrotic and absorbed. In order to reach a good result, the patient is bind to repeat several times the surgical procedure. Is Authors opinion that lipofilling may be useful to treat low grade deformity or have to be consider as a refinement procedure.

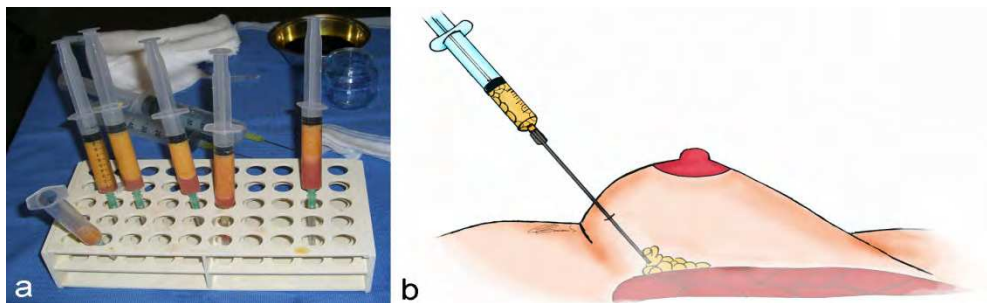


Fig. 11. Lipofilling: a) fat processing; b) Fat injection.

## 7. Personal experience with Puckett technique

In this section we describe the Puckett surgical technique in detail and our personal experience performing this procedure.

In the period from March 2009 to June 2011, 27 subjects with tuberous breast were referred to the Operative Unit of Plastic, Reconstructive and Aesthetic Surgery of L'Aquila University. Our court was composed by 27 female, with an average age of 21 years old (range 16-37); The deformity was bilateral in 25 patient and in 10 a severe asymmetry was present. Table 1.

Average age	21
Range	16 - 37
N° of patients with bilateral malformation	25 (92.5%)
N° of patients with severe asymmetry	11 (33.4%)

Table 1. Personal casuistry

A total of 52 breasts were treated and in accordance with von Heimburg classification were divided in four groups as follow:

- 7 breasts (13.46%) Type I
- 18 breasts (34.61%) Type II
- 22 breasts (42.3%) Type III
- 5 breasts (9.61%) Type IV

In order to estimate the amount of breast tissue and the contraction severity, all patient received a ecography. After surgery a antibiotic therapy was administered and a compressive dressing (post-surgery bra) was performed for all patients.

### 7.1 Surgical procedure

In order to better show the new-inframammary fold, the patient is placed in operatory room in semiseated position. To obtain vasoconstriction and hydrodissection, a solution with lidocaine and epinephrine is injected in breast parenchyma, fig. 12a. An areolotome is placed on the areola in order to determine the physiological dimension of NAC, Fig. 12b.

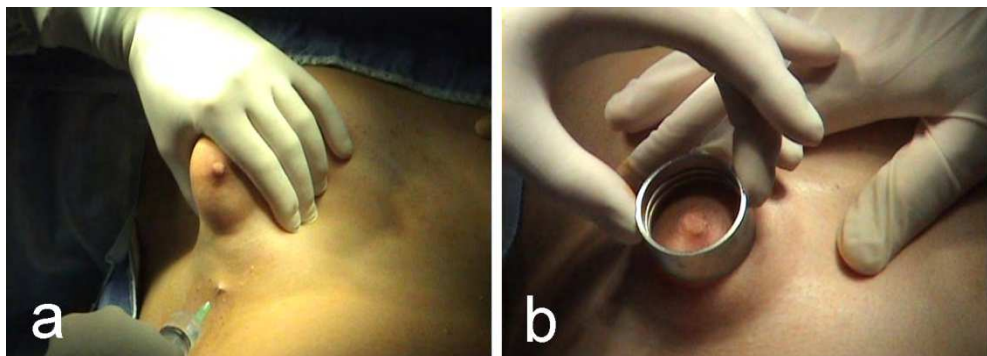


Fig. 12.

The areola outer border and neo-inframammary fold are then marked, fig. 13a.

The new areolar margin is incised by a scalpel, fig. 13b, and the superabundance of areolar tissue is then removed, fig. 14a. With cautery the deepithelialized area is incised approximately 5 mm from the margin of the skin. The incision is extended from the right side to the left following the previous incision curvature. Just the dermis is discontinued the glandular parenchyma is pulled out through the incision as a hernia, fig. 14b.

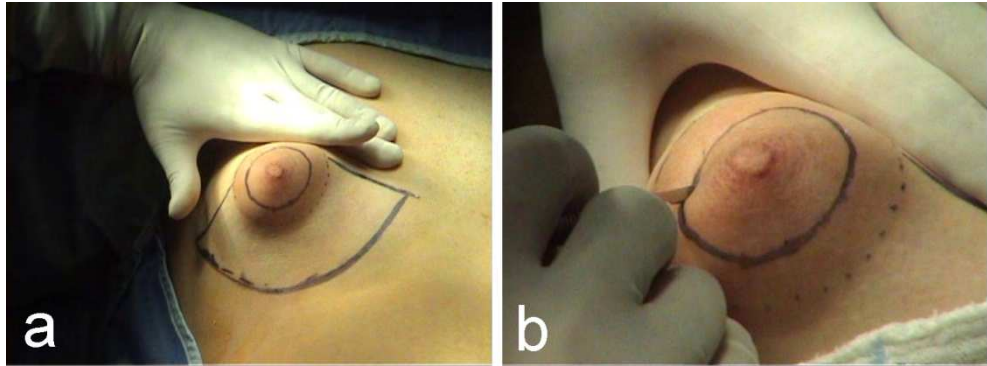


Fig. 13.

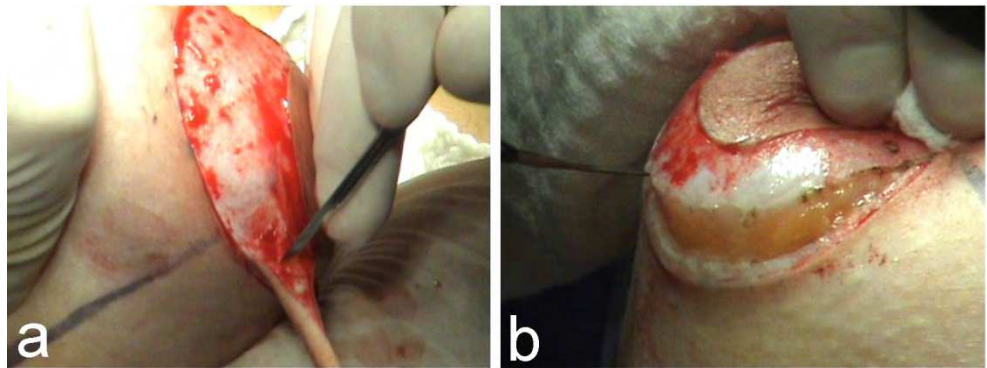


Fig. 14.

The inferior portion of the breast is completely separated from its skin covering. The dissection plain is placed 0.5-1cm from the dermis, fig. 15a. The adherence between the glandular parenchyma and pectoralis muscle fascia are discontinued, fig. 15b.

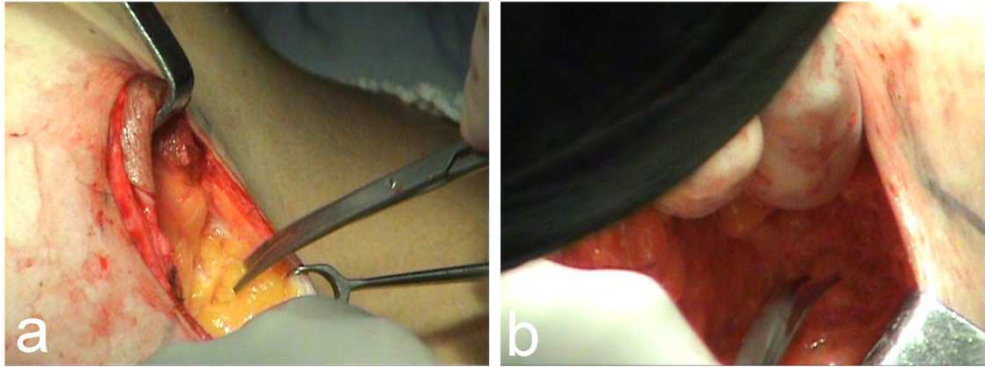


Fig. 15.

Due the delivery of all breast connection from surrounding tissue, the parenchyma can be everted, fig. 16a. Raising the superior pedicle glandular flap allow to create a sub glandular pocket in order to locate a prosthesis if a volume deficiency is present. To discontinue the fibrose ring causing the breast deformity, the glandular posterior wall is incised by the cautery, fig. 16b.

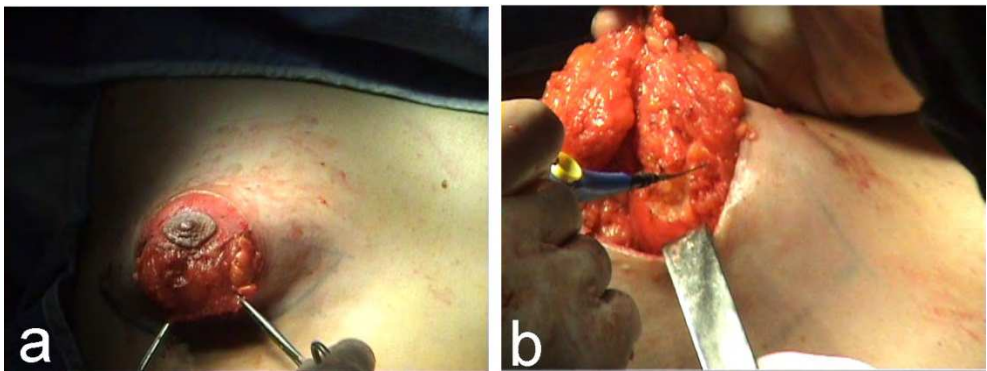


Fig. 16.

A series of incision have to be done to create a V-Y flap in order to eliminate the parenchyma tension, Fig. 17a. If necessary a silicon gel prosthesis is placed, fig. 16b. If the amount of glandular parenchyma doesn't allow to place the implant behind the breast tissue, a pocket under the muscular plane have to be done in order to better dissimulate the device presence.

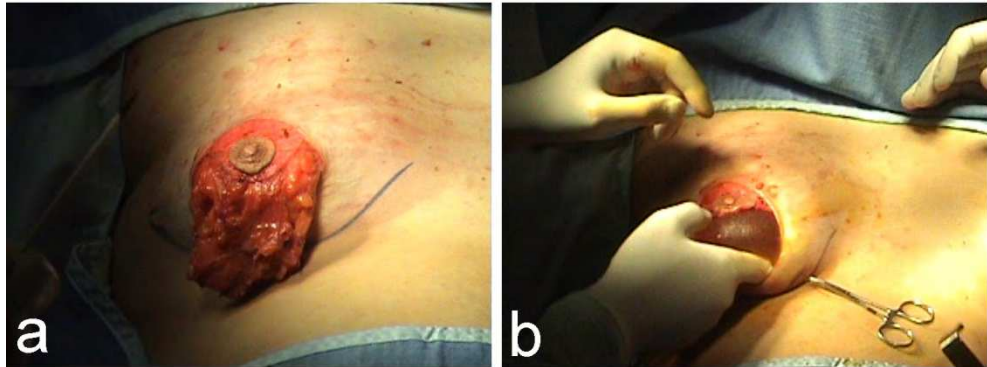


Fig. 17.

After breast tissue expansion is completed, the inferior border of glandular flap has to lie to the dermis of new-inframammary fold. To eliminate this risk, a series of suture thread go through the skin first and then through the gland, fig 18a. They are pulled by a needle that passes it from the skin surface (at the level of new inframammary fold) into the dissected subcutaneous plane, until it anchors the caudal border of expanded breast, fig 18b.

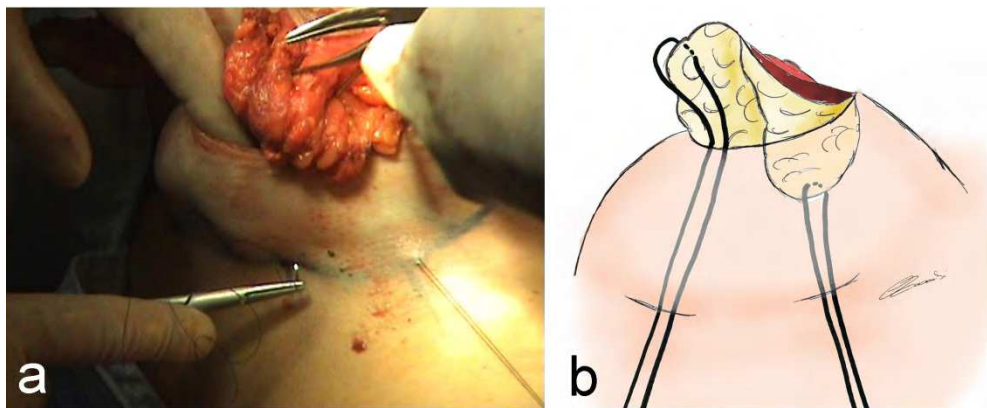


Fig. 18.

Transdermal anchorages of the gland are then tied at their ends around a soft cotton roll, fig 19, this prevent the neck decubitus and breast retraction during the healing process.

The traction system will be removed in 15 days after surgery.

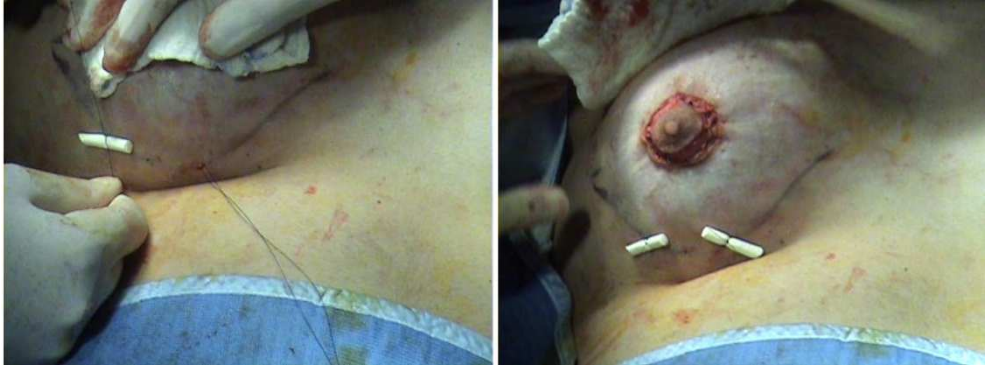

Fig. 19.

The areola is repositioned and a deep suture is performed like in round-block mastopexy and the superficial layer is closed using a continue suture with the cutaneous portion that pass through the dermis and the areolar run on the tissue surface, fig. 20a.

The aim of this suture is to further distribute the small wrinkles which inevitably form when joining two very different length margins, fig. 20b. Finally a dressing is applied.

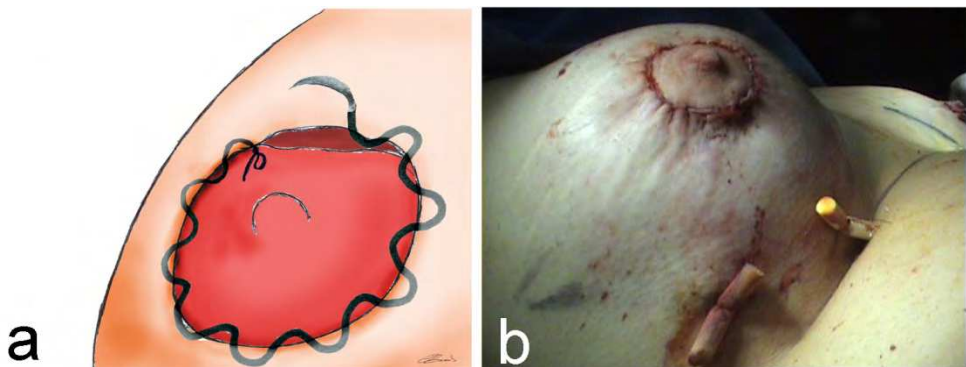


Fig. 20.

## 8. Results

With a minimum follow-up of 6 month we obtain the complete remission in all patients.

All treated breast received an implant to correct the volume deficiency.

All prosthesis have the same physical characteristics like high cohesive silicone gel, round shape and textured surface.

In four cases, type IV (7.69%), the prosthesis device was implanted under the muscular plane, a retroglandular plane for the other cases was chosen.

In one patient with severe asymmetry and suffering of hypomastia in which the few glandular tissue was completely replaced by fibrous tissue (maximum ecographic diameter of 1,5cm), in order to avoid a double bubble aspect after implant, we performed a subtotal adenectomy.

In our series the 18,5% (5 patients) of complications were been observed; the high value of adverse events is linked to the inclusion of not complete satisfy patient.

The 7,4% (2 patients) was the real percentage of clinical complications ( 1 wound infection and partial dehiscence, 1 seroma).

## 9. Case reports

### 9.1 Case report no. 1. Fig. 21.

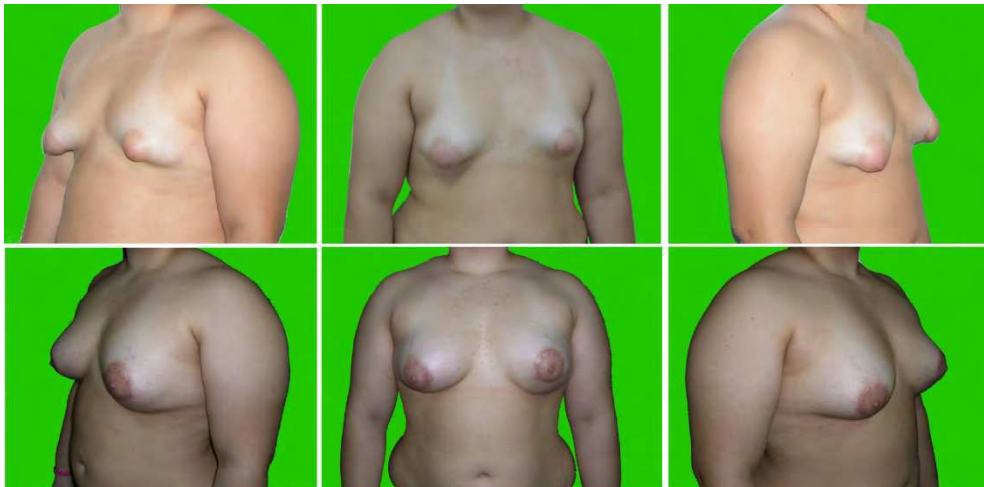

Fig. 21. C.C. - 21yars-holg girl with bilateral tuberous breast Type III, a hypoplasia is also associated. We have a reconstruction performing Puckett technique and the volume deficiency was restored with two silicone implant behind the gland (L: 200cc. R: 180cc). No complication was observed.

### 9.2 Case report no. 2. Fig. 22.

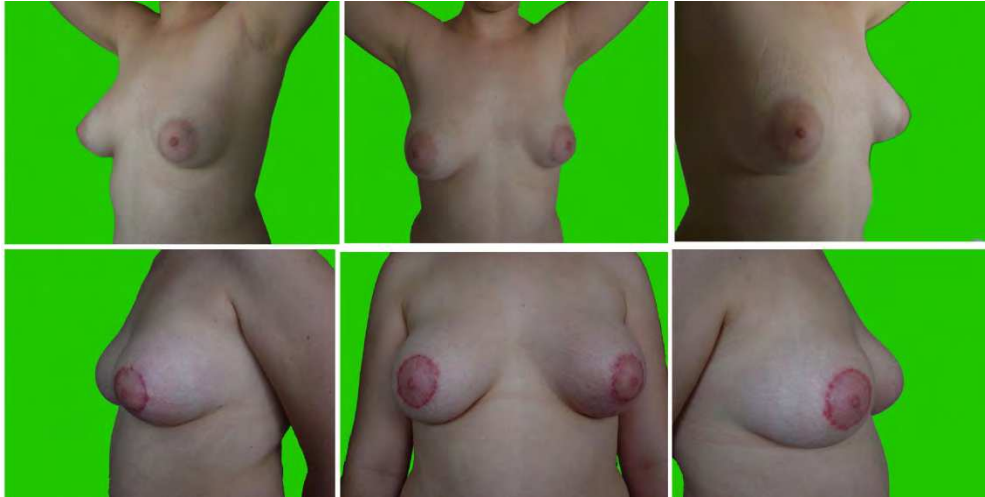


Fig. 22. G.S. - 18years-old girl with left tuberous breast type II with low asymmetry .

The deformity was correct with the Puckett technique and we insert a silicone prosthesis behind the breast parenchyma (140cc). The improve the symmetry we perform a round-block mastopexy on the right breast.

### 9.3 Case report no. 3. Fig. 23.

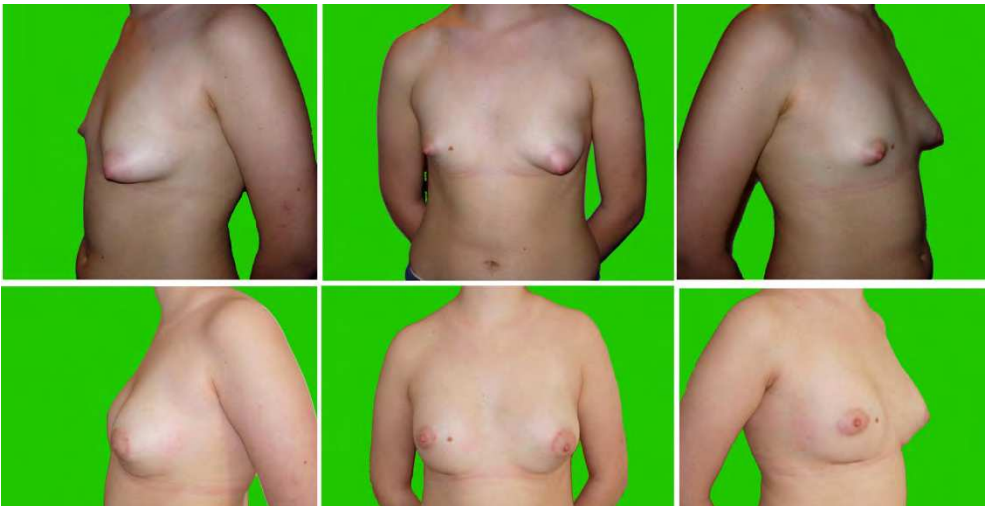


Fig. 23. M.L. 19yars-hold girl with bilateral tuberous breast Type III for left side and type IV for right, severe hypoplasia and asymmetry were The left breast was reconstructed using Puckett technique and positioning a prosthesis behind the gland (190cc). The right presenting a very



few amount of glandular parenchyma, an implant under the muscle was positioned (230cc) and in order to avoid the double-bubble effect, a partial adenectomy was performed.

#### 9.4 Case report no. 4. Fig. 24.

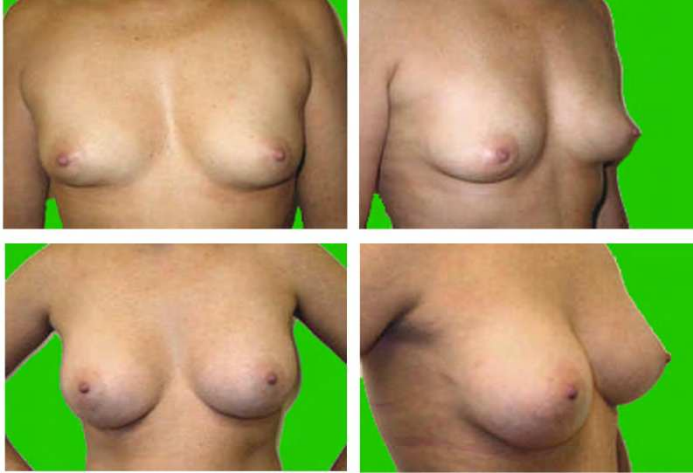

Fig. 24. T.M. - 25yars-holg girl with bilateral tuberous breast Type II. We have a reconstruction performing Puckett technique and retroglandular implant (R=L:190cc).

#### 9.5 Case report no. 5. Fig. 25.

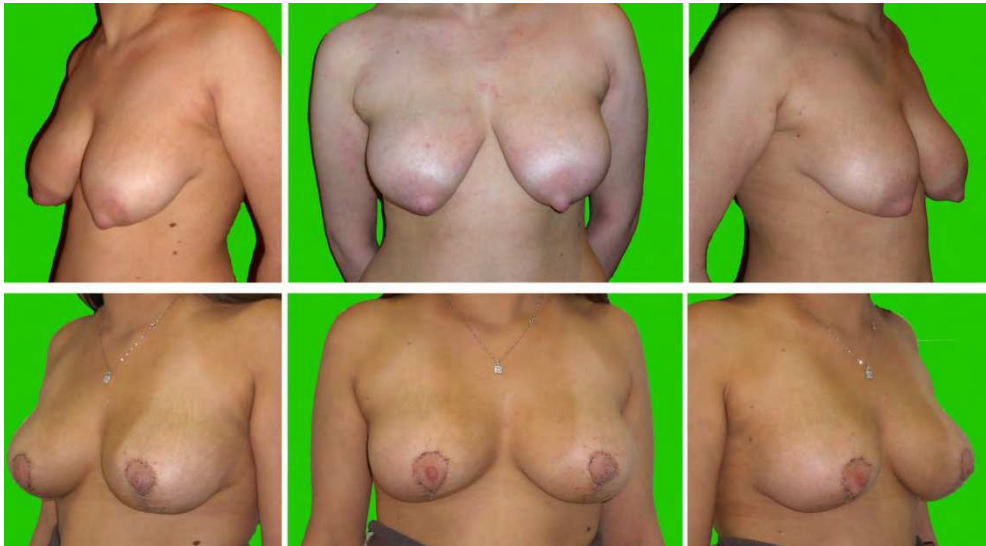


Fig. 25. A.V - 22yars-holg girl with bilateral tuberous breast Type I. hypoplasia of medial quadrant, macroareola and parenchyma hypertrophy are present in both breasts.

A modify Puckett technique was used: after glandular parenchyma expansion a skin remodeling was performed, living only a vertical scar like Lejour procedure.

No prosthesis devices were needed.

## 10. Conclusions

Tuberous breast can cause major psychological problems in the affected women presenting a surgical challenge for the plastic surgeons.

The management of the tuberous breast syndrome and its variants is best achieved by understanding the essence of the deformity.

The abundance of techniques available in literature for correcting the tuberous breast attests to the great challenge of treating this deformity. Many procedures have same steps and the little variations permit to the surgeon to have a better surgical plan to improve the patient outcome.

Is Authors opinion that Puckett technique is the better way to correct this deformity. Performing a superior pedicle flap of glandular tissue allows to the surgeon to discontinue the fibrous ring and to better expose the thoracic wall during inframammary fold reconstruction, and a good reshaping of glandular parenchyma is also permitted.

Although the results are sometimes not perfect, the psychological impact of such treatment is extremely positive with an augmentation of self-esteem and a progressive normalization of social activities.

## 11. References

- Bach, AD., Kneser, U., Beier, JP., Breuel, C., Horch, RE., & Leffler, M. (2009). Aesthetic correction of tuberous breast deformity - lessons learned with a single-stage procedure. *The Breast Journal*, Vol. 15, No. 3, (May-June 2009), pp. 279-286, ISSN 0960-9776
- De Luca-Pytell, DM., Piazza, RC., Holding, JC., Snyder, N., Hunsicker, LM., & Phillips, LG. (2005). The incidence of tuberous breast deformity in asymmetric and symmetric mammoplasty patients. *Plastic and Reconstructive Surgery*, Vol. 116, No. 7, (December 2005), pp. 1900-1901, ISSN 0032-1052
- Mandreakas, AD., & Zambacos GJ., (2010). Aesthetic reconstruction of the tuberous breast deformity: a 10-yr experience. *Aesthetic Surgery Journal*, Vol. 30, No. 5, (September 2010), pp. 680-692, ISSN 1090-820X
- Pacifico, MD., & Kang, NV.(2007) The tuberous breast revisited. *Journal of Plastic, Reconstructive & Aesthetic Surgery*. Vol. 60, No. 5., (January 2007), ISSN 1748-6815
- Rees, TD., & Aston, SJ. (1976). The tuberous breast. *Clinics in Plastic Surgery*, Vol.3, No.4, (April 1976), pp. 339-347, ISSN 0094-1298



## **Current Concepts in Plastic Surgery**

Edited by Dr. Frank Agullo

ISBN 978-953-51-0398-1

Hard cover, 264 pages

**Publisher** InTech

**Published online** 23, March, 2012

**Published in print edition** March, 2012

Plastic surgery continues to be a rapidly growing field in medicine. There have been multiple recent advancements in the field. Specifically, there has been a continuously growing interest in fat grafting, body contouring, minimally invasive surgery, and plastic surgery education. At the same time, there have been continued advances and modifications in surgical techniques, which translate into better and improved results for our patients while increasing safety and efficacy. The title of the book is Current Concepts in Plastic Surgery and, as such, it highlights some of the "hot topics" in recent years. We have invited renowned specialists from around the world to share their valued expertise and experience. Most of the chapters will expose the reader to multiple techniques for achieving desired results, with emphasis on the author's preferred methodology.

### **How to reference**

In order to correctly reference this scholarly work, feel free to copy and paste the following:

Giovanni Zoccali and Maurizio Giuliani (2012). Tuberos Breast: Clinical Evaluation and Surgical Treatment, Current Concepts in Plastic Surgery, Dr. Frank Agullo (Ed.), ISBN: 978-953-51-0398-1, InTech, Available from: <http://www.intechopen.com/books/current-concepts-in-plastic-surgery/tuberos-breast-clinical-evaluation-and-surgical-treatment>

# **INTECH**

open science | open minds

### **InTech Europe**

University Campus STeP Ri  
Slavka Krautzeka 83/A  
51000 Rijeka, Croatia  
Phone: +385 (51) 770 447  
Fax: +385 (51) 686 166  
[www.intechopen.com](http://www.intechopen.com)

### **InTech China**

Unit 405, Office Block, Hotel Equatorial Shanghai  
No.65, Yan An Road (West), Shanghai, 200040, China  
中国上海市延安西路65号上海国际贵都大饭店办公楼405单元  
Phone: +86-21-62489820  
Fax: +86-21-62489821

© 2012 The Author(s). Licensee IntechOpen. This is an open access article distributed under the terms of the [Creative Commons Attribution 3.0 License](#), which permits unrestricted use, distribution, and reproduction in any medium, provided the original work is properly cited.