



# Hyperbaric oxygen therapy as a treatment for stage-I avascular necrosis of the femoral head

N. D. Reis, O. Schwartz, D. Militianu, Y. Ramon, D. Levin, D. Norman, Y. Melamed, A. Shupak, D. Goldsher, C. Zinman

From Rambam Medical Centre, Haifa, Israel

**A**vascular necrosis (AVN) of the head of the femur is a potentially crippling disease which mainly affects young adults. Although treatment by exposure to hyperbaric oxygen (HBO) is reported as being beneficial, there has been no study of its use in treated compared with untreated patients. We selected 12 patients who suffered from Steinberg stage-I AVN of the head of the femur (four bilateral) whose lesions were 4 mm or more thick and/or 12.5 mm or more long on MRI. Daily HBO therapy was given for 100 days to each patient. All smaller stage-I lesions and more advanced stages of AVN were excluded. These size criteria were chosen in order to compare outcomes with an identical size of lesion in an untreated group described earlier. Overall, 81% of patients who received HBO therapy showed a return to normal on MRI as compared with 17% in the untreated group. We therefore conclude that hyperbaric oxygen is effective in the treatment of stage-I AVN of the head of the femur.

*J Bone Joint Surg [Br]* 2003;85-B:371-5.  
Received 6 February 2002; Accepted after revision 29 October 2002

Avascular necrosis (AVN) of the head of the femur occurs when the intraosseous microcirculation is disturbed.<sup>1</sup> Vascular insufficiency within the head causes prolonged ischaemia which leads to osteonecrosis.<sup>1</sup> Some authors<sup>2,3</sup> have presented histological evidence to indicate that the earliest

stage of AVN is preceded by bone-marrow oedema as seen on MRI. Hyperbaric oxygen (HBO) restores tissue oxygenation, reduces oedema, and induces angiogenesis. By reducing the intraosseous pressure, venous drainage is restored, and the microcirculation is improved.<sup>4</sup> It would therefore seem that HBO therapy of the head of the femur is indicated in AVN since its actions address the specific needs of the endangered bone and bone-marrow cells. This theoretical concept requires proof in clinical practice. A review of 15 earlier studies on the use of HBO in AVN of the head of the femur has shown that none had used MRI at follow-up to compare the results with those of a group of untreated patients with lesions of a similar size.<sup>5</sup>

We thus present our analysis of the results of HBO treatment in a series of patients with stage-I AVN of the femoral head. We have compared these patients with an untreated group<sup>6</sup> by using objective MRI criteria.

## Patients and Methods

In order to determine the efficacy of HBO we used the prognostic criteria established by Vande Berg et al<sup>6</sup> for subchondral MRI lesions of a specific size (4 mm or more thick and/or 12.5 mm or more long) which were present in combination with diffuse bone-marrow changes. We used their patients as an untreated, control group. From a group of 120 patients with various stages of AVN of the head of the femur, which had been treated by HBO between 1990 and 2000, we selected those with stage-I AVN (symptomatic painful hip, normal radiograph, positive bone scan, positive MRI), according to the criteria of Steinberg, Hayken and Steinberg,<sup>7</sup> in whom diffuse changes were present and the subchondral lesion was 4 mm or more thick and/or 12.5 mm or more long. The minimum follow-up was two years. Those with smaller lesions, or bone-marrow oedema alone, were excluded. There were 12 patients (16 hips) aged between 19 and 54 years (2 women and 10 men) who satisfied the criteria. The mean duration of hip pain was four months (1 to 8) before treatment. All patients underwent MRI before they began HBO therapy. The treatment comprised six daily sessions each week up to a total of 100. A session involved breathing 100% oxygen at 2 to 2.4 atmospheres absolute in a multiplace pressure chamber for 90 minutes and using a mask breathing system.

N. D. Reis, MBBS, FRCS Ed, Orthopaedic Surgeon  
O. Schwartz, MD, Orthopaedic Registrar  
D. Militianu, MD, Musculoskeletal Radiologist  
Y. Ramon, MD, Plastic Surgeon and Hyperbaric Medicine Physician  
D. Levin, MD, Orthopaedic Surgeon  
D. Norman, MD, Orthopaedic Surgeon  
D. Goldsher, MD, Director MRI Unit  
C. Zinman, MD, Head of Orthopaedic Department  
Department of Orthopaedics B, Rambam Medical Centre, Faculty of Medicine, Technion-Israel Institute of Technology, Haifa, Israel.

Y. Melamed, MD, Director Rambam Hyperbaric Unit  
Rambam Hyperbaric Unit, Elisha Hospital, Haifa, Israel.

A. Shupak, MD, Colonel  
Institute of Maritime Medicine, Israel Defence Forces, Haifa, Israel.

Correspondence should be sent to Professor N. D. Reis at Elisha Hospital, 12 Yair Katz Street, Haifa 34636, Israel.

©2003 British Editorial Society of Bone and Joint Surgery  
doi:10.1302/0301-620X.85B3.13237 \$2.00

The first MRI examination was approximately two months later and the subsequent MRI some months after the completion of HBO therapy. The endpoint of the study was either a normal MRI or the MRI after two years. No further MRI studies were routinely undertaken after a normal MRI had been obtained unless there were continuing symptoms. We used three different MRI systems, which had a 0.5 T (Gyrex; Elscint Ltd, Haifa, Israel), a 1.5 T (Phillips Ltd, Best, NT15, Netherlands), or a 2 T (Elscint) superconducting magnet, respectively, and obtained the images with a body coil. All the protocols which were used included T1 spin-echo and T2 spin-echo-weighted images of the hips. The T1-weighted images had the following parameters: TR, 500-550; TE, 15-25; a slice thickness of 5 mm with a 1 mm gap; FoV, 45 x 45 to 50 x 50 cm fields of view; a 5 mm section thickness; and a 1 mm intersection gap with a 150 x 256 matrix. The T2-weighted images had the following: TR, 2000-2500; TE, 80-90; FoV, 40 x 40 cm to 50 x 50 cm; a slice thickness of 5 mm with a 1 mm gap and a matrix of 160 x 256.

We recorded the side, thickness and length of the lesion using the scale on the MR film, the type of signal, the extent of the oedema, the site of the lesion, the size of the lesion as a percentage of the whole femoral head, the presence of fluid and the patient's age, gender and dates of the scans. Only T2-weighted images were used.

All patients were asked to use crutches in order to minimize weight-bearing during the period of treatment as did the comparative, untreated group.<sup>6</sup> A musculoskeletal radiologist (DM) carried out the MRI measurements and assessments independently. Clinical follow-up was at three-monthly intervals during the first year, then six-monthly in the second year, and yearly thereafter.

Ten patients had idiopathic AVN of the head of the femur and two were taking steroids, one for systemic lupus erythematosus, and the other for chronic renal disease.

## Results

Ten of the 12 patients who remain free from major symptoms have returned to their previous occupation. They had no limp, no wasting of the thigh muscles and a range of movement which was similar in the unilateral cases to that of the unaffected side. When pressed, the patients reported some mild discomfort in the affected hip or hips which was unrelated to exercise.

After four years the patient who suffered from lupus was still receiving steroids. The radiographic changes were consistent with stage-II AVN, but there were no degenerative changes and the joint surfaces were congruous. There was, however, persistent pain in both hips. The patient with chronic renal disease developed collapse of the femoral head and underwent total hip arthroplasty.

**MRI findings.** Each of the 12 subchondral lesions was 4 mm or more thick and 12.5 mm or more long. Nine were restored to a normal MRI appearance while one developed

collapse and two remained unchanged at stage II. The likelihood of irreversibility of this size of lesion in the untreated group was 85%<sup>6</sup> and in the treated group was 25%. The chi-squared test of association showed these results to be highly significant (likelihood ratio chi-squared = 82.86;  $p < 0.0001$ ; chi-squared = 0.60 with a high correlation between the data and the results). If we exclude the two steroid-associated patients (three femoral heads) the likelihood of irreversibility in our group is 0%.

In a further four femoral heads, the subchondral lesion was 12.5 mm or more long, but not 4 mm or more thick. In each of these the MR image returned to normal on the T2-weighted scan. Vande Berg et al<sup>6</sup> found that the likelihood of irreversibility for this size of lesion was 73%. In our series it was 0%. The numbers, however, are too small for statistical comparison.

In 13 femoral heads the MRI returned to normal after a mean of eight (3 to 24) months from the beginning of HBO treatment. Unfortunately, we experienced financial difficulties in undertaking the follow-up MRIs at planned, identical intervals. Consequently, the periods noted for the recovery time after treatment are not precise. The duration of symptoms before the start of treatment did not affect the results.

## Discussion

The quality of imaging achieved by the body coil used in our study is inferior to that of the surface coil used for the untreated group. This, however, supports the results since the relative insensitivity may have reduced the number of patients whom we considered to be suitable for inclusion in the study. The lesions would appear smaller with the less sensitive method. This point is corroborated by Vande Berg et al<sup>6</sup> in the discussion of their findings.

Stage-I AVN of the femoral head is often progressive.<sup>8</sup> Most studies of the outcome of conservative treatment indicate that once radiological changes have become apparent (stage II), the disease is progressive in most patients and leads to collapse of the femoral head and secondary osteoarthritis.<sup>9</sup> The rate of progression is not definitely known, although most studies agree that progression almost always occurs within two to three years of presentation.

All treatments for early-stage AVN attempt to conserve the sphericity of the femoral head. A simultaneous process of resorption of dead bone and replacement with living bone occurs. This raises the possibility that a form of conservative treatment may influence the rates of resorption and repair and thereby modify the loss of structural integrity and conserve the femoral head.<sup>10,11</sup>

Since AVN of the femoral head occurs most often in younger individuals, the therapeutic goal is to prevent collapse of the femoral head and to preserve the joint rather than to replace it. Unfortunately, there is currently no completely satisfactory treatment which can accomplish this. Numerous therapeutic measures have been studied including core decompression,<sup>12-15</sup> free, pedicle and microvascu-

lar fibular bone grafting and electrical stimulation.<sup>11-17</sup> There is no consensus of opinion on the efficacy of these methods.

HBO treatment involves the intermittent inhalation of 100% oxygen at greater than atmospheric pressure. It is administered in a hyperbaric chamber, which is compressed with air, while the patient breathes oxygen at the ambient pressure through a mask. The inspiration of oxygen at high pressure results in an increase in the amount of oxygen dissolved in the plasma, in direct proportion to the rise in the ambient pressure. Thus, when oxygen is inhaled at 2 to 2.4 atmospheres absolute, the plasma oxygen content increases from 0.32 volume% to 4.8 to 5.76 volume%. This considerable increase in the amount of oxygen which can be made available to the tissues is indicated when tissue oxygenation must be improved. Animal studies, clinical trials and clinical experience have shown HBO to be of benefit in radiation-induced osteonecrosis and chronic osteomyelitis.<sup>18</sup>

In AVN of the femoral head, damage to the microcirculation is an early event. It is thus clearly desirable to restore the oxygenation of the affected bone. The osteoclast has a high rate of metabolic activity and its function in removing necrotic bone is oxygen-dependent. Moreover, increasing the oxygen tension in hypoxic areas promotes synthesis of collagen, proliferation of fibroblasts and capillary angiogenesis.<sup>19</sup> A level of tissue oxygen of at least 40 mmHg is essential for these processes to take place.

Measurement of the intraosseous pressure has shown venous hypertension within, and poor venous drainage from, the affected femoral head.<sup>20</sup> By means of its vasoconstrictive effect, HBO reduces tissue oedema.<sup>4</sup> The most rapid action of HBO is the abolition of oedema, thereby lowering the intraosseous pressure, restoring venous drainage, and rapidly improving the microcirculation. In this respect HBO is similar to fenestration and core biopsy.<sup>21</sup>

Strauss and Dvorak<sup>5</sup> have reviewed 15 reports of the beneficial effects of HBO in AVN of the femoral head in a meta-analysis comparing the outcomes with those of core decompression, osteotomy, bone grafting, electrical stimulation, and pharmacological methods of treatment. They included only stages 1,2 and 3 of the Ficat, Marcus, or Steinberg classifications,<sup>7,22</sup> and concluded that 81% of patients showed long-term improvement after HBO treatment but only 66% improved after orthopaedic interventions. The total number of patients who were treated by HBO (190) was, however, too small when compared with the orthopaedic intervention group (3193) to reach statistical significance.

Since 1993, we have suggested that HBO is most likely to be effective in the earliest stages of AVN. Thus, we present an MRI follow-up of our HBO treatment protocol of patients with stage-I AVN of the femoral head. The study of Vande Berg et al<sup>6</sup> on the predictive value of MRI findings affords a means of comparing our results with an untreated group. None of the previously published reports has made

this comparison or used MRI examination at follow-up. Vande Berg et al<sup>6</sup> state that "careful assessment of subchondral changes enables confident differentiation between early irreversible lesions and transient bone marrow oedema". It has been suggested that the successfully treated femoral heads in their series had idiopathic transient osteoporosis or bone-oedema syndrome which was mistaken for AVN.

In order to assess the efficacy of HBO therapy in stage-I AVN of the femoral head, we have searched for data on the natural history of this earliest stage of the disease. Ficat's<sup>22</sup> original studies in the pre-MRI era determined that stage-I could only be diagnosed by core biopsy. Once this had been undertaken, however, the natural history of the condition could no longer be studied. There are several studies of the natural history of AVN of the femoral head which, being radiological, relate only to stage-II or more. Takatori et al<sup>23</sup> examined 17 hips with lesions seen on MRI which were of similar size to those in our series. All except four had collapsed within 3.5 years; 11 had collapsed within 18 months. All of the hips were in patients who suffered from systemic disease such as lupus erythematosus, alcoholism, leukaemia, idiopathic thrombocytic purpura, and post-renal transplantation, and hence they do not compare well with our group of patients who had mainly idiopathic AVN. The expected irreversibility of lesions above specific sizes which had been established by Vande Berg et al<sup>6</sup> afforded us a ready comparative group. Our selection of patients was strictly according to their criteria. Statistically, the comparative results of HBO therapy are highly significant. We conclude that there is strong evidence that HBO therapy is beneficial in stage-I idiopathic AVN of the femoral head. Final proof of the presence of dead bone can only be determined by histological examination which was not possible in our study since the removal of a biopsy from the subchondral lesion is in itself a form of treatment (fenestration and core biopsy). MRI can differentiate between necrotic foci and transient oedematous lesions.<sup>6</sup> In this context it is relevant to relate an additional case which was not included in our series. The patient, a physician, presented with a typical clinical bone scan and MRI findings of stage-I AVN of the femoral head. After one month of daily HBO sessions, he requested fenestration with drilling and core biopsy. This was done immediately and he went on to complete his HBO protocol of therapy. His MRI reverted to normal and histological examination confirmed osteonecrosis. This anecdotal example lends support to Vande Berg et al's<sup>6</sup> assertion that AVN can be confidently diagnosed on MRI, even in its earliest stage.

As illustrated in Figure 1, HBO therapy does not prevent the aetiological insult which causes AVN since it appeared, probably *de novo*, in the contralateral hip after treatment was begun. In our experimental work on rats we have also found that HBO does not prevent AVN.<sup>24</sup> Rather, it promoted and accelerated healing. The concealment of the subchondral AVN lesions behind a 'curtain' of bone oedema is shown by their more obvious appearance after the oedema



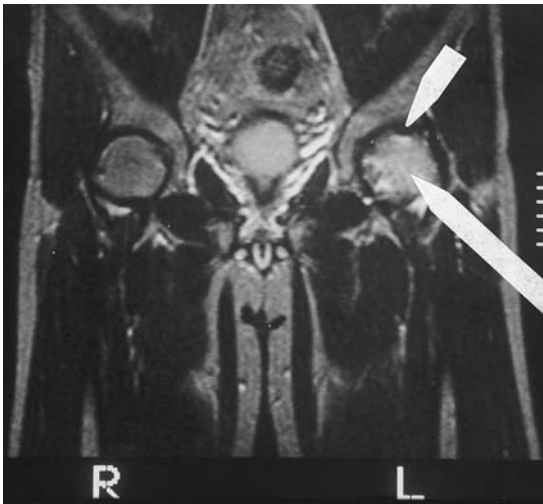


Fig. 1a

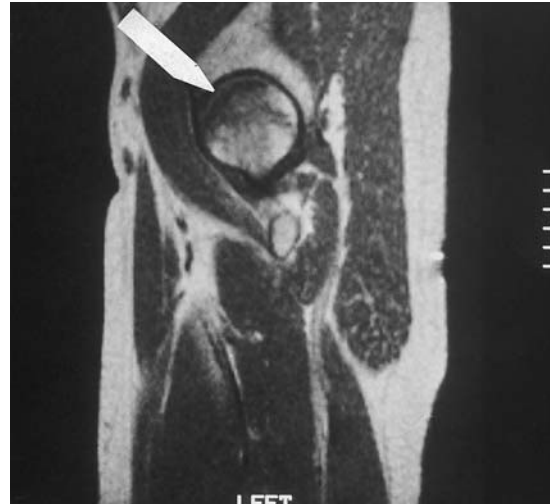


Fig. 1b

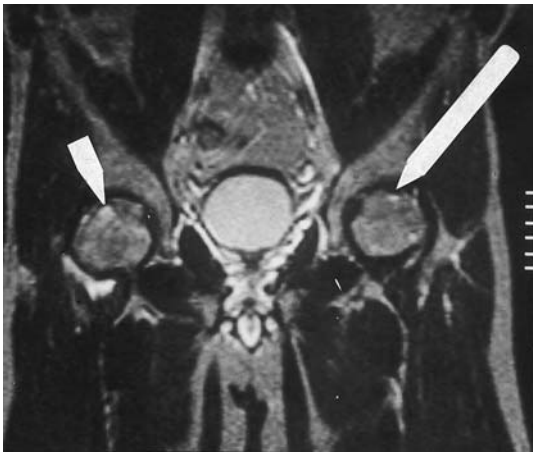


Fig. 1c

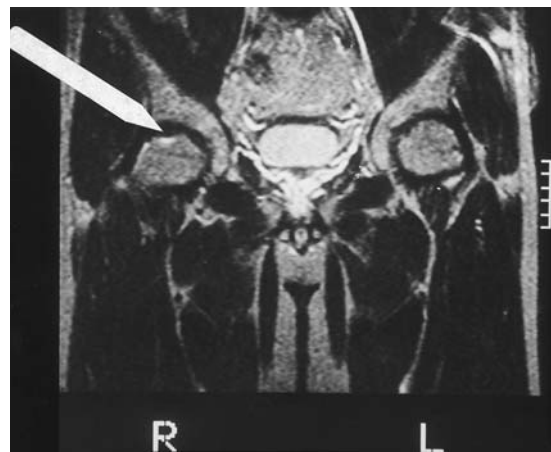

Fig. 1d

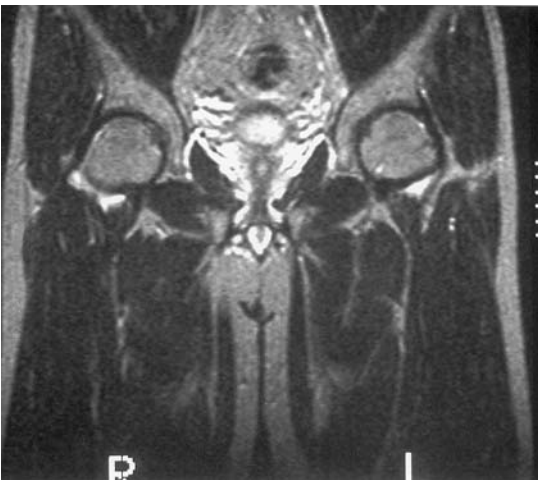

Fig. 1e

MR scans of a 34-year-old man with a ten-week history of left hip pain. Figure 1a – A coronal T2-weighted (2200/90) image showing a subchondral low signal intensity line in the superior part of the left femoral head bordered by a very thin line of high signal intensity (double line sign; short arrow), and by diffuse intramedullary oedema of high signal intensity (long arrow). Figure 1b – A sagittal T1-weighted (500/15) image showing the anterosuperior subchondral lesion of low signal intensity in the head of the femur surrounded by oedema (arrow). HBO therapy was initiated. The line is 3.5 cm long and 0.8 cm thick. Figure 1c – A coronal T2-weighted (2200/90) image obtained six weeks later showing complete resolution of the findings in the left femoral head with a residual, but smaller, double-line sign (long arrow). There is also a subchondral low intensity area (1.5 cm thick and 3.4 cm long) with a high intensity line around it within the right femoral head (short arrow). HBO therapy was continued in order to complete the full protocol of 100 daily sessions. Figure 1d – MR scan two months later showing complete resolution of the oedema with a residual small subchondral double line sign in the right femoral head (arrow). On the left the image had reverted to normal. Figure 1e – Follow-up MR scan obtained 1.75 years after the first MRI showing a normal image on both sides. (scale: the space between any two lines is equal to a distance of 1cm)

recedes. Also shown is the 'double-line sign' which does not appear initially, but takes some time to develop.

A complete course of HBO treatment costs about £6500 (US \$10 000) at the time of writing. We believe that such expense is justified if a hip is to be saved from chronic morbidity.

We thus present evidence that HBO is effective in the treatment of idiopathic stage-I AVN of the femoral head. It may be used in conjunction with core decompression, fenestration and drilling, or other forms of orthopaedic intervention. We consider it to be a primary treatment and not merely adjuvant therapy.

No benefits in any form have been received or will be received from a commercial party related directly or indirectly to the subject of this article.

## References

1. Myers M. Osteonecrosis of the femoral head: pathogenesis and long term results of treatment. *Clin Orthop* 1988;231:51-61.
2. Turner DA, Templeton AC, Selzer PM, Rosenberg AG, Petasnick JP. Femoral capital osteonecrosis: MR finding of diffuse marrow abnormalities without focal lesions. *Radiology* 1989;171:135-40.
3. Hofmann S, Schneider W, Breitensteiner M, Urban M, Plenk H. Transient osteoporosis as a special reversible form of femur head necrosis. *Orthopade* 2000;29:411-9.
4. Nylander G, Lewis D, Nordstrom H, Larsson J. Reduction of post-ischaemic edema with hyperbaric oxygen. *Plast Reconstr Surg* 1985;76:596-60.
5. Strauss M, Dvorak T. Femoral head necrosis and hyperbaric oxygen therapy. In: Kindwall EP, Whelan HT, eds. *Hyperbaric medicine practice*. Best Publishing Co. 1999;912.
6. Vande Berg BC, Malghem JJ, Lecouvet FE, Jamart J, Maldague BE. Idiopathic bone marrow edema lesions of the femoral head: predictive value of MR imaging findings. *Radiology* 1999;212:527-35.
7. Steinberg ME, Hayken GD, Steinberg DR. A quantitative system for staging avascular necrosis. *J Bone Joint Surg [Br]* 1995;77-B:34-41.
8. Ito H, Matsuno T, Kaneda K. Prognosis of early stage avascular necrosis of the femoral head. *Clin Orthop* 1999;358:149-57.
9. Merle D'Aubigne R, Postel M, Mazabraud A, Massias P, Gueguen J. Idiopathic necrosis of the femoral head in adults. *J Bone Joint Surg [Br]* 1965;47-B:612-33.
10. Glimcher MJ, Kenzora JE. The biology of osteonecrosis of the human femoral head and its clinical applications. I. Tissue biology. *Clin Orthop* 1979;138:284-309.
11. Glimcher MJ, Kenzora JE. The biology of osteonecrosis of the human femoral head and its clinical applications. II. The pathological changes in the femoral head as an organ and in the hip joint. *Clin Orthop* 1979;139:283-312.
12. Mont MA, Carbone JJ, Fairbank AC. Core decompression versus nonoperative management for osteonecrosis of the hip. *Clin Orthop* 1996;324:169-78.
13. Camp J, Colwell C. Core decompression of the femoral head for osteonecrosis. *J Bone Joint Surg [Am]* 1986;68-A:1313-9.
14. Yoon TR, Song EK, Rowe SM, Park CH. Failure after core decompression in osteonecrosis of the femoral head. *Int Orthop* 2001;24:316-8.
15. Scully SP, Aaron RK, Urbaniak JR. Survival analysis of hips treated with core decompression or vascularized fibular grafting because of avascular necrosis. *J Bone Joint Surg [Am]* 1998;80-A:1270-5.
16. Meyers M. The treatment of osteonecrosis of the hip with fresh osteochondral allografts and with muscle pedicle graft technique. *Clin Orthop* 1978;130:202-9.
17. Steinberg ES, Brighton CT, Bands RE, Hartman KM. Capacitive coupling as an adjunctive treatment for avascular necrosis. *Clin Orthop* 1990;261:11-8.
18. Behnke AR, Saltzman HA. Hyperbaric oxygenation. *N Engl J Med* 1967;276:1423-9.
19. Hunt TK, Pai MP. The effect of varying ambient oxygen tensions on wound metabolism and collagen synthesis. *Surg Gynecol Obstet* 1972;135:561-7.
20. Hungerford DS. Bone marrow pressure, venography and core decompression in ischaemic necrosis of the femoral head in the hip. *Proc Hip Society*. St Louis: CV Mosby Company 1979;218-37.
21. Ficat P, Grijalvo P. Long term results of the forage-biopsy in grade I and II osteonecrosis of the femoral head. *Rev Chir Orthop Reparatrice Appar Mot* 1984;70:253-5.
22. Ficat P. Aseptic necrosis of the femur head: importance of bone biopsies. *Acta Orthop Belg* 1981;47:285-7.
23. Takatori Y, Kokubo T, Ninomya S, et al. Avascular necrosis of the femoral head: natural history and magnetic resonance imaging. *J Bone Joint Surg [Br]* 1993;75-B:217-21.
24. Levin D, Norman D, Zinman C, et al. Treatment of experimental avascular necrosis of the femoral head with hyperbaric oxygen in rats: histological evaluation of the femoral heads during the early phase of the reparative process. *Exp Mol Pathol* 1999;67:99-108.