

Microdebrider Tonsillotomy vs Electrosurgical Tonsillectomy

A Randomized, Double-blind, Paired Control Study of Postoperative Pain

Matthew T. Lister, MD; Michael J. Cunningham, MD; Barry Benjamin, MD; Michael Williams, MD; Ann Tirrell, RN; Debra A. Schaumberg, ScD, OD, MPH; Christopher J. Hartnick, MD, MS (Epi)

Objective: To examine whether microdebrider intracapsular tonsillotomy (MT) results in less postoperative pain compared with electrosurgical extracapsular tonsillectomy (ET).

Design: Prospective, randomized, double-blind, matched pair, clinical trial.

Setting: Specialty care hospital.

Patients: Twelve male (48%) and 13 female (52%) children aged 5 to 15 years, with obstructive tonsillar hyperplasia were randomized to have one tonsil removed by MT and the other by ET.

Interventions: An angled endoscopic microdebrider was used to perform MT, and ET was performed by standard monopolar cautery technique. Parents and children were blinded to the side of MT and ET. Children rated the pain 0 to 5 by side using the Faces Pain Scale–Revised. Blinded data collection was via telephone daily for 2 weeks by a study nurse.

Main Outcome Measures: Primary: postoperative pain as recorded by Faces Pain Scale–Revised; secondary, presence or absence of otalgia and postoperative bleeding.

Results: Twenty-two children (88%) had tonsillectomy and adenoidectomy, while 3 children (12%) had tonsillectomy alone. On postoperative days 1 to 9, children reported significantly less pain on the MT side compared with the ET side (paired *t* test; *P* < .01). By postoperative days 10 to 14, the difference between sides disappeared. Twenty children (80%) reported otalgia, and it was always unilateral. For those children reporting otalgia, there was a 100% correlation between the side of otalgia and the side of ET. There was no posttonsillectomy bleeding among the 25 children.

Conclusion: Microdebrider intracapsular tonsillotomy is significantly less painful compared with electrosurgical ET in children undergoing surgical intervention for obstructive tonsillar hypertrophy.

Arch Otolaryngol Head Neck Surg. 2006;132:599-604

Author Affiliations: Department of Otolaryngology, Massachusetts Eye and Ear Infirmary (Drs Lister, Cunningham, Benjamin, Williams, and Hartnick and Ms Tirrell), and Departments of Otolaryngology and Laryngology (Drs Lister, Cunningham, Benjamin, Williams, and Hartnick and Ms Tirrell) and Medicine and Ophthalmology (Dr Schaumberg), Harvard Medical School, Boston.

TECHNIQUES FOR THE removal of tonsillar tissue have varied greatly over the long history of the procedure, ranging from blunt finger dissection to the use of various forms of electrical and radiofrequency energy to cut, coagulate, and ablate the tissue. While many of these techniques may be used to good effect in experienced hands, they all have shortcomings. These shortcomings are manifest in the varying incidence of postoperative bleeding and the varying degrees of postoperative morbidity relative to odynophagia, otalgia, return to normal diet, and resumption of baseline activity. Despite these sequelae, tonsillectomy continues to be the most commonly performed major surgical procedure in children.¹

In recent years, newer methods of tonsillectomy aimed at reducing postopera-

tive pain while still alleviating symptoms have been introduced. There is evidence to support the assertion that trauma to the surrounding pharyngeal musculature during tonsillectomy is responsible for much of the pain experienced during recovery.²⁻⁶ Depending on the instrumentation used, such trauma may be direct or indirect but is most commonly related to thermal injury.

The impact of thermal trauma is supported by studies showing that cold knife tonsillectomy results in less postoperative pain compared with electrosurgical procedures.⁷ However, the increased operative time and intraoperative blood loss associated with cold knife tonsillectomy compared with electrosurgical tonsillectomy have limited its widespread use.⁸ The idea that postoperative pain would be reduced by focusing energy delivery to tonsillar tissue and decreasing transmission

of heat energy to surrounding tissue is the basis for radiofrequency ablation in tonsillar resection. Studies suggest that radiofrequency ablation tonsillectomy reduces postoperative pain when compared with conventional electrosurgical dissection with monopolar cautery.^{2,9}

An alternative means of reducing injury to the surrounding pharyngeal musculature during tonsillar surgery is to perform a subtotal tonsillar resection, also known as a partial tonsillectomy, intracapsular tonsillotomy, or intracapsular tonsillar reduction. Koltai et al^{4,10} have popularized this approach. Partial tonsillectomy is essentially a refinement of the historical use of a tonsillotome or tonsillar guillotine.¹¹ Various methods of performing partial tonsillectomy have been shown to reduce postoperative pain while successfully alleviating obstructive symptoms. These include carbon dioxide laser excision,^{3,6} the use of an angled endoscopic microdebrider,^{4,10} and more recently, a radiofrequency loop electrode.⁵ The hypothesis is that preservation of the tonsillar capsule protects the adjacent pharyngeal musculature from injury intraoperatively and from secondary infection postoperatively, thereby reducing pain related to muscular inflammation.

Most studies assessing tonsillar removal or reduction techniques and their sequelae suffer from shortcomings relative to design. The strongest are prospective, controlled, but unblinded studies in which children and their parents may be influenced by the knowledge that the child is undergoing a “new” procedure intended to reduce postoperative pain.^{5,6} Others are retrospective case-control studies, which additionally suffer from such confounding variables as recall bias, survey bias, and information bias for lack of randomization.^{4,10} The present study was undertaken to address these design issues.

METHODS

STUDY DESIGN

A matched-pair study, in which each child acts as his or her own control, was chosen to limit confounding variables. Once enrolled, children were randomized to receive microdebrider intracapsular tonsillotomy (MT) on one side and electrosurgical extracapsular tonsillectomy (ET) on the remaining side using the SAS 8.2 random number generator (SAS Institute Inc, Cary, NC). Preoperatively, each surgeon was notified via telephone whether MT was to be performed on the right or the left. Children, parents, and the study nurse were all blinded as to which procedure was performed on either side. Following surgery, children and their parents were contacted by the study nurse daily for 14 days for data collection. Information was gathered regarding throat pain ratings on each side, the presence or absence and sidedness of otalgia, and whether there had been any bleeding. Data were entered into an encrypted, password-protected database using SAS 8.2 software (SAS Institute Inc).

RECRUITMENT

The study design, informed consent, and informed assent forms were all institutional review board approved. Children aged 5 to 15 years who presented with symptoms of obstruction including persistent snoring with or without apneic events in the setting of tonsillar or adenotonsillar hypertrophy were re-

cruited by one of the participating clinicians. Children with a history of recurrent tonsillitis or peritonsillar abscess were excluded. Parental informed consent was obtained for all children. Children 10 years or older also received an informed assent form, which they were asked to sign. Neither children nor their parents received any compensation for participation in the study. Once enrolled, each family was introduced to the study nurse who explained the study and the Faces Pain Scale-Revised (FPS-R) that would be used to rate postoperative pain. The FPS-R is a 0 to 5 scale using 6 standardized and validated facial expressions representing the spectrum of no pain to severe pain.¹² The nurse then identified a standard time each day when she could contact the family to collect data.

SURGICAL PROCEDURE

Prior to beginning the study, the surgeons involved (C.J.H., M.J.C., B.B., and M.W.) established uniform practices regarding operative technique, postoperative pain management, and perioperative corticosteroid and antibiotic administration. Intraoperatively, each child received an antibiotic (ampicillin sodium intravenously at a dose of 25 mg/kg up to a maximum of 1000 mg/kg or clindamycin intravenously, 10 mg/kg, up to a maximum of 600 mg/kg if penicillin-allergic) and dexamethasone (1 mg/kg up to a maximum of 20 mg/kg). Electrosurgical extracapsular tonsillectomy was chosen as the study standard because this was the approach and technique currently in routine use by all 4 surgeons, and it was performed using a protected, Teflon-coated spatula bovie on a coagulation setting of 20 W. Microdebrider intracapsular tonsillotomy was performed with an angled 15° endoscopic microdebrider (Gyrus ENT, Bartlett, Tenn); resection of tonsillar tissue began medially and proceeded laterally in the method previously described by Koltai et al.⁴ Monopolar suction cautery was used to spot-coagulate as needed throughout the procedure. In cases of concurrent adenoidectomy, fulguration was performed using a monopolar suction cautery or by instrumental curettage. Antibiotic therapy was continued for 5 days postoperatively. This consisted of either amoxicillin sodium, 50 mg/kg, up to a maximum of 1600 mg/kg in 3 divided doses, or azithromycin, 10 mg/kg per day on day 1 and 5 mg/kg per day on days 2 to 5 if penicillin-allergic. All children also received a prescription for an appropriate weight-based dose of pain medicine, either 5 to 10 mL of oxycodone-acetaminophen elixir (5 mg/325 mg per 5 mL) or codeine-acetaminophen elixir (12 mg/120 mg per 5 mL) to be used every 4 hours as needed.

SAMPLE SIZE CALCULATION

For purposes of the calculation, a clinical estimate was made that a difference of 2 points on the 0 to 5 scale with a standard deviation of 2 would be significant. Power was set at 0.85 and α level at .05 by convention. Using these figures, the calculation estimated that 24 children or 12 per arm would be needed to achieve statistical significance. In a paired study design, only 12 children would be required, but to assure an adequate sample, 25 were chosen.

DATA ANALYSIS

Data on throat pain, otalgia, and bleeding for each side were collected on each of 14 consecutive postoperative days as described in the “Study Design” subsection. The paired *t* test was used to examine the differences in pain scores for the throat. The correlation between the side of any reported ear pain and the procedure performed on that side was also examined. Comparison of bleeding rates was not possible because there were no episodes of posttonsillectomy hemorrhage in this study.

RESULTS

A total of 25 children were enrolled in the study; 13 were female (52%) and 12 were male (48%). Children were between 5 and 15 years of age; the mean \pm SD age was 8.08 ± 2.68 years (**Figure 1**). Three children (12%) underwent tonsillectomy alone, while the remaining 22 (88%) underwent tonsillectomy and adenoidectomy. All 25 children completed the 14-day follow-up course. There were no deviations from the planned protocol.

Individual pain scores for the MT and ET sides ranged from 0 to 4 and from 0 to 5, respectively. Mean FPS-R scores on each side ranged from 0.96 to 3.08 with standard deviations between 0 and 1.19. From days 1 to 9, MT was significantly less painful than ET, with differences between the means of 0.4 to 0.92 (paired *t* test, $P < .001$ to $.009$). Thereafter, the difference resolved. Data on both MT and ET sides show a steady decline in pain over the first 11 to 12 days and a leveling-off thereafter with only 1 child reporting no pain on either side by day 14. On the MT side, mean FPS-R scores leveled off at a score of 1 at day 9, while on the ET side, the mean dropped to a score of 1 at day 12. No children experienced an increase in mean FPS-R scores on either side from one day

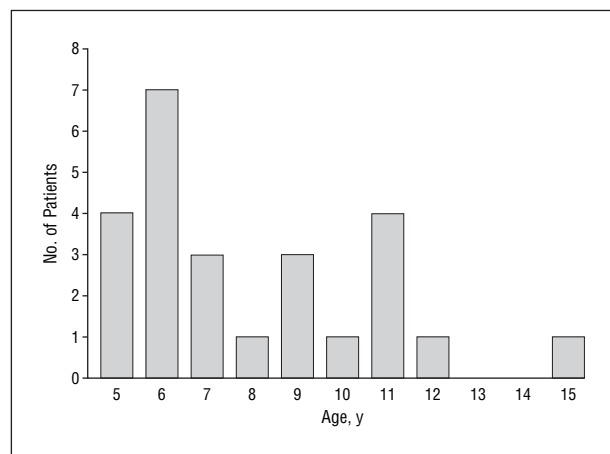


Figure 1. Age distribution of study children (mean age, 8.08 years; range, 5-15 years).

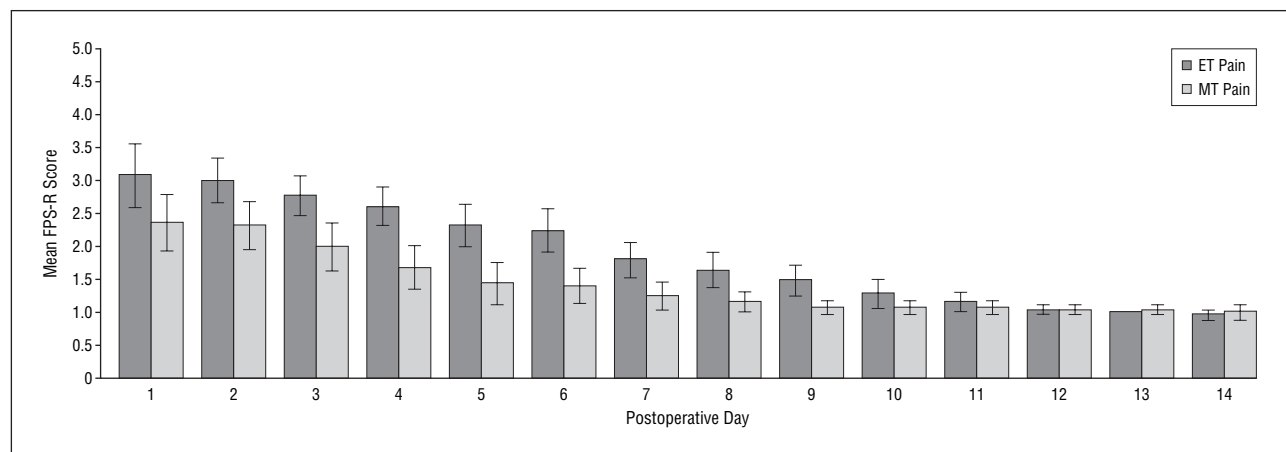


Figure 2. Mean Faces Pain Scale-Revised (FPS-R) scores by postoperative day comparing paired tonsillar procedures performed in 25 children showing a difference in pain scores until 10 days postoperatively. Error bars represent 95% confidence intervals for the paired *t* test. ET indicates electrosurgical tonsillectomy; MT, microdebrider tonsillotomy.

to the next over the course of the study. **Figure 2** and the **Table** show the mean FPS-R scores by day for both sides over the course of the study.

We compared the presence or absence and the sidedness of otalgia to the procedure performed to examine whether an association was present between it and either MT or ET. Of 25 children, 20 (80%) reported otalgia, which was always unilateral. In children reporting otalgia, we found a 100% correlation between the side of otalgia and the side of ET.

There were no recorded episodes of posttonsillectomy bleeding in any of the 25 children.

COMMENT

This prospective, randomized study demonstrates a significant decrease in postoperative pain measured on a validated pain scale when MT is performed compared with standard ET. These data are in concordance with previously published studies that also show a reduction in pain following MT vs ET.^{4,10} There are anatomic and physiologic explanations for these data that may help guide future innovations in tonsillar surgery.

The tonsillar fossa is bounded anteriorly by the palatoglossal arch (anterior pillar) and posteriorly by the palatopharyngeal arch (posterior pillar). The superior pharyngeal constrictor muscle comprises the lateral boundary. A potential space, the peritonsillar space, bridged by multiple blood vessels and loose areolar connective tissue, separates the lateral constrictor musculature from the so-called tonsillar capsule. This capsule is composed of modified pharyngobasilar fascia with several identifiable folds medially and perforating vessels entering laterally. Fingers of fibrous tissue accompany these vessels and extend deep into the tonsil.¹³ As a result the capsule is densely adherent to the tonsil, making surgical dissection between the 2 virtually impossible.

Given this anatomy, 2 options exist for tonsillar dissection: extracapsular (in the peritonsillar space) or intracapsular (removing tonsillar tissue medial to the capsule). When extracapsular dissection is performed, the lateral muscular wall of the pharynx is traumatized with

Table. Summated and FPS-R Scores for MT and ET Sides* by Postoperative Day

Day	ET Total Score	ET Mean Score†	MT Total Score	MT Mean Score†	P Value (Paired t Test)
1	77	3.08 ± 1.19 (2.59-3.57)	59	2.36 ± 1.04 (1.93-2.79)	.003
2	75	3.00 ± 0.82 (2.66-3.34)	58	2.32 ± 0.90 (1.95-2.69)	.005
3	69	2.76 ± 0.72 (2.46-3.06)	50	2.00 ± 0.87 (1.64-2.36)	.001
4	65	2.60 ± 0.71 (2.31-2.89)	42	1.68 ± 0.80 (1.35-2.01)	<.001
5	58	2.32 ± 0.81 (1.99-2.65)	36	1.44 ± 0.77 (1.12-1.76)	<.001
6	56	2.24 ± 0.83 (1.90-2.58)	35	1.40 ± 0.65 (1.13-1.67)	<.001
7	45	1.80 ± 0.65 (1.53-2.07)	31	1.24 ± 0.52 (1.02-1.46)	.004
8	41	1.64 ± 0.64 (1.38-1.90)	29	1.16 ± 0.37 (1.01-1.31)	.005
9	37	1.48 ± 0.59 (1.24-1.72)	27	1.08 ± 0.28 (0.97-1.19)	.009
10	32	1.28 ± 0.54 (1.06-1.50)	27	1.08 ± 0.28 (0.97-1.19)	.13
11	29	1.16 ± 0.37 (1.01-1.31)	27	1.08 ± 0.28 (0.97-1.19)	.43
12	26	1.04 ± 0.20 (0.96-1.12)	26	1.04 ± 0.20 (0.96-1.12)	>.99
13	25	1.00 ± 0.00 (1.00-1.00)	26	1.04 ± 0.20 (0.96-1.12)	.33
14	24	0.96 ± 0.20 (0.88-1.04)	25	1.00 ± 0.29 (0.88-1.12)	.33

Abbreviations: ET, electrosurgical tonsillectomy; FPS-R, Faces Pain Scale-Revised; MT, microdebrider tonsillotomy.

*N = 25 per side.

†Data are given as mean ± SD (95% confidence interval).

a subsequent inflammatory healing response and superinfection by oral bacterial flora. These processes are believed to contribute significantly to posttonsillectomy pain. If the tonsillar capsule is left undisturbed, it may act as a barrier to such inflammation and infection of the pharyngeal musculature, thereby reducing postoperative pain. Evidence published to date supports this contention.^{3-6,10,14,15} Although there have been no direct comparisons between methods of partial tonsillectomy, available data suggest that techniques transferring less heat energy to surrounding tissues cause less damage and are less painful.^{7,9} In light of this, it is not surprising that a method of cold partial tonsillar excision should be significantly less painful than a complete tonsillectomy using electrocautery.

Even in a well-designed study, pain scores can be confounded owing to the highly subjective nature of pain, the effects of varying doses and types of pain medicine, time-of-day effects on reported pain, emotional factors, and the presence of comorbid problems such as low fluid intake, nausea, and vomiting. When measured in separate individuals, these and many other factors may contribute to variations in pain scores and interfere with the accurate comparative assessment of the 2 procedures. A paired study design negates these effects by allowing them to equally influence each procedure in a given child. Even though the study design itself should control for such factors, we standardized our use of corticosteroids, antibiotics, and pain medicine in the perioperative period to allow easier comparison of our data with those of other studies and facilitate possible future meta-analyses. Attempts were also made to minimize intersurgeon variations in MT technique, especially relative to the amount of residual lymphoid tissue in the tonsillar fossa and the amount of monopolar electrocautery performed in the MT resection bed. All 4 surgeons practiced performing MT for several months prior to the initiation of the study. Two surgeons (C.J.H. and M.J.C.) performed over 95% of the study procedures, and they observed each other's

MT and ET procedures prior to the study to ensure they were using similar techniques. Although some degree of thermal tissue trauma occurred as a result of spot electrocautery on the MT side, the study children still reported significantly less pain on the MT side over most of the study period.

Following bilateral tonsillar procedures, there may be a tendency for the sensation of pain to be generalized to the entire oropharynx. In this situation, a paired study design would tend to decrease the difference in reported pain from one side to the other, increasing the chance of a type II error. Despite this tendency, our study was still able to show a significant reduction in pain using the MT technique. Alternatively, one might argue that a paired study design could highlight differences between the 2 sides and cause a child to focus solely on a single side as the source of their pain. Our data do not support this contention, however, as individual pain scores were consistently within 1 to 2 points of each other throughout the course of the recovery period, and only 1 child scored pain on either side as a 0 (on both sides at day 14).

Although the paired study design is particularly strong for measuring differences in pain, the inability to treat each child's overall status as a product of 1 procedure or the other makes it impossible to measure other commonly reported outcomes. Time to return to normal diet and activity, time spent in recovery, rate of admission postoperatively, the incidence of postoperative nausea, vomiting, dehydration, and pain medicine requirements cannot be assessed for each procedure using this type of study design. Many of these additional outcome measures, however, are surrogates for measuring the degree of pain experienced postoperatively. Although their correlation is useful in standard control studies, measurement of these variables is not necessary to validate our findings. Data in existing and future unpaired, randomized, controlled trials could be used to examine these outcomes. In addition, we did not measure intraoperative blood loss for

each procedure in our study because other authors have reported no significant increase in the amount of intraoperative bleeding with MT compared with ET, and we did not consider this a major morbidity of the procedure, choosing rather to focus on pain.^{4,10}

The FPS-R was chosen as the pain measuring instrument because of its ease of use by both children and their families and its validation in children 4 to 5 years and older. The FPS-R uses 5 facial expressions scored in a 0-to 5- or 0- to 10-point format; the original Faces Pain Scale had 6 faces scored on a 1- to 6-point scale. In the validation studies, the FPS-R scores correlated with linear pain measuring tools such as the visual analog scale, and a discussion with one of the scale's developers confirmed that it is a linear, equal interval scale.¹² Therefore, the paired *t* test could be used as the outcome statistic. As with any pain measuring tool, the FPS-R has limitations, especially when comparing pain scores among children of varying ages. It has been shown that younger children tend to score toward the extremes on the pain scale, but this effect is most pronounced in children younger than 5 years, an age group not included in our study.¹² The paired study design may also be advantageous in reducing the potential for error related to individual interpretations of scale expressions. Because the FPS-R had previously been validated only in children 5 years and older, we limited our study population to this age group. We recognize that a significant number of children with airway obstruction from tonsillar hypertrophy are younger than 5 years. We believe our results are generalizable to this younger population as well. In fact, the less painful MT technique may have even greater value in younger children in whom the use of postoperative narcotic pain medications may be contraindicated.

Because there is dual concern for comfort and safety in tonsillectomy procedures, we also collected data regarding bleeding in our 25 children. There were no bleeding events during the course of the study. Owing to the small sample size, no definitive statement can be made in this regard from our data. However, other studies published to date have shown either no change or a trend toward decreased postoperative bleeding in tonsillectomy patients.^{4,6,10,15} The most recently published is a large retrospective study of 870 children undergoing MT and 1121 children undergoing ET, which revealed a significantly decreased risk of primary and secondary postoperative bleeding after MT (0%-1.4%) compared with ET (3.3%).¹⁵ Future studies will help determine whether the reported decrease in posttonsillectomy bleeding after MT is a temporary phenomenon related to increased intraoperative vigilance using a novel technique or truly a long-term improvement in child safety.

We did not formally evaluate relief of tonsillar hypertrophy symptoms in our data collection. Other authors report symptomatic relief from partial tonsillectomy that is comparable to traditional tonsillectomy.^{3-6,10}

A major concern regarding partial tonsillectomy has been tonsillar regrowth or infection and/or the need for reoperation. It is important to note that these events are not mutually inclusive. Some children who have tonsillar surgery for airway obstructive symptoms may experience regrowth of tonsillar tissue. However, because of

age-related changes in upper airway dimensions subsequent to surgery, such regrowth may be insignificant from an airway obstruction standpoint. A study of 870 children at post-MT status showed an incidence of 0% to 0.9% for significant tonsillar regrowth over a mean 1.2-year follow-up.¹⁵ Perhaps a more important question concerns the potential for tonsillitis involving the partially resected tonsil and whether infection of a tonsillar remnant is more difficult to diagnose and treat if it occurs. Future studies may choose to address the efficacy of partial tonsillectomy in relieving infectious complications as well, although to our knowledge there are currently no data to support this surgical indication. Limiting tonsillectomy to those undergoing the procedure for upper airway obstructive symptoms as opposed to those who have recurrent infections may reduce potential morbidity related to infection in persistent tonsillar tissue.

One disadvantage of MT is the increased cost relative to ET, as there is a charge for the microdebrider blade. Most of the newer techniques for tonsillar surgery share the shortcoming of increased cost for instrumentation. It remains to be seen whether the reported reductions in postoperative pain and bleeding rates will translate into an overall cost savings for this technique. Another potential disadvantage is the occurrence of intraoperative bleeding during resection, necessitating control with a monopolar suction cautery. As previously described in the literature, performing the resection in a layered fashion from medial to lateral and cauterizing as needed to maintain a clear view of the operative field may minimize this problem.⁴ Although we did not collect data on total operative time with the MT technique, others have reported increased operative times of several minutes when using a microdebrider.^{4,10} These differences should diminish as surgeons become more experienced with the technique.

CONCLUSIONS

The goal of all surgery is to maximize symptomatic relief and minimize morbidity. Current trends in tonsillar surgery emphasize this fact. In cases in which airway obstruction is the indication and infection is not a significant factor, existing evidence suggests that tonsillectomy is equivalent to traditional tonsillectomy for symptom relief with a significant reduction in perioperative morbidity. We have shown in a randomized, double-blind, paired control trial that MT results in significantly less pain compared with traditional ET. The evidence suggests that any technology used to perform a partial tonsillectomy with preservation of the tonsillar capsule should yield similar results. The use of instrumentation such as the microdebrider with less heat transfer to surrounding tissues is likely to result in additional reductions in postoperative pain. Future studies will be useful in comparing instruments and techniques now available for tonsillar surgery to determine the optimal choice in terms of safety, efficacy, cost, and ease of use.

Submitted for Publication: November 18, 2005; final revision received January 30, 2006; accepted February 12, 2006.

Correspondence: Christopher J. Hartnick, MD, MS (Epi), Massachusetts Eye and Ear Infirmary/Harvard Medical School, 243 Charles St, Boston, MA 02114 (Christopher_Hartnick@meei.harvard.edu).

Author Contributions: Dr Lister had full access to all data for this study and takes responsibility for the accuracy of the data reporting and statistical analysis herein.

Financial Disclosure: None.

Funding/Support: Gyrus ENT, makers of the microdebrider technology used in this study, funded the cost of the microdebrider blades and provided salary support for the nurse responsible for data collection and entry.

Previous Presentation: This work was presented as a podium presentation at the American Society of Preventive Oncology annual meeting; May 28, 2005; Las Vegas, Nev.

Acknowledgment: We thank Stacey Manning for her data processing assistance.

REFERENCES

1. Darrow DH, Siemens C. Indications for tonsillectomy and adenoidectomy. *Laryngoscope*. 2002;112:6-10.
2. Stoker KE, Don DM, Kang DR, Haupt MS, Magit A, Madgy DN. Pediatric total tonsillectomy using coblation compared to conventional electrosurgery: a prospective, controlled single blind study. *Otolaryngol Head Neck Surg*. 2004;130:666-675.
3. Linder A, Markström A, Hultcrantz E. Using the carbon dioxide laser for tonsillectomy in children. *Int J Pediatr Otorhinolaryngol*. 1999;50:31-36.
4. Koltai PJ, Solares CA, Koempel JA, et al. Intracapsular tonsillar reduction (partial tonsillectomy): reviving a historical procedure for obstructive sleep disordered breathing in children. *Otolaryngol Head Neck Surg*. 2003;129:532-538.
5. Hultcrantz E, Ericsson E. Pediatric tonsillotomy with the radiofrequency technique: less morbidity and pain. *Laryngoscope*. 2004;114:871-877.
6. Hultcrantz E, Linder A, Markström A. Tonsillectomy or tonsillotomy? a randomized study comparing postoperative pain and long-term effects. *Int J Pediatr Otorhinolaryngol*. 1999;51:171-176.
7. Wexler DB. Recovery after tonsillectomy: electrodissection vs sharp dissection techniques. *Otolaryngol Head Neck Surg*. 1996;114:576-577.
8. Leinbach RF, Markwell SJ, Collier JA, Lin SY. Hot versus cold tonsillectomy: a systematic review of the literature. *Otolaryngol Head Neck Surg*. 2003;129:360-364.
9. Temple RH, Timms MS. Paediatric coblation tonsillectomy. *Int J Pediatr Otorhinolaryngol*. 2001;61:195-198.
10. Koltai PJ, Solares CA, Mascha EJ, Xu M. Intracapsular partial tonsillectomy for tonsillar hypertrophy in children. *Laryngoscope*. 2002;112:17-19.
11. Koempel JA. On the origin of tonsillectomy and the dissection method. *Laryngoscope*. 2002;112:1583-1586.
12. Hicks CL, von Bayer CL, Spafford PA, van Korlaar I, Goodenough B. The Faces Pain Scale-Revised: toward a common metric in pediatric pain measurement. *Pain*. 2001;93:173-183.
13. Janfaza P, Nadol JB, Galla RJ, Fabian RL, Montgomery WW. *Surgical Anatomy of the Head and Neck*. Philadelphia, Pa: Lippincott Williams & Wilkins; 2001.
14. Plant RL. Radiofrequency treatment of tonsillar hypertrophy. *Laryngoscope*. 2002;112:20-22.
15. Solares CA, Koempel JA, Hirose K, et al. Safety and efficacy of powered intracapsular tonsillectomy in children: a multi-center retrospective case series. *Int J Pediatr Otorhinolaryngol*. 2005;69:21-26.