

Evidence of Axonal Damage in the Early Stages of Multiple Sclerosis and Its Relevance to Disability

Nicola De Stefano, MD; Sridar Narayanan, MSc; Gordon S. Francis, MD; Rozie Arnaoutelis, BSc; Maria C. Tartaglia, BSc; Jack P. Antel, MD; Paul M. Matthews, MD; Douglas L. Arnold, MD

Objective: To assess axonal damage and its contribution to disability at different stages of multiple sclerosis (MS).

Background: Recent in vivo imaging and in situ pathologic studies have demonstrated that substantial axonal damage accompanies the inflammatory lesions of MS. However, the relation of axonal damage to the duration of MS and its contribution to disability at different stages of the disease remain poorly defined.

Design: We performed proton magnetic resonance spectroscopic imaging in 88 patients with a wide range of clinical disability and disease duration to measure N-acetylaspartate (NAA, an index of axonal integrity) relative to creatine (Cr) in a large central brain volume that included mostly normal-appearing white matter on magnetic resonance imaging.

Results: We observed that the NAA/Cr values were abnormally low in the early stages of MS, even before sig-

nificant disability (measured using the Expanded Disability Status Scale [EDSS]) was evident clinically, and declined more rapidly with respect to EDSS at lower than at higher EDSS scores ($P < .001$). The correlation of NAA/Cr values with EDSS score was significantly ($P < .03$) stronger in patients with mild disability (EDSS score < 5 , Spearman rank order correlation = -0.54 , $P < .001$) than in patients with more severe disability (EDSS score ≥ 5 , Spearman rank order correlation = -0.1 , $P < .9$). When similar analyses were performed in patients with MS grouped for duration of disease, the subgroup with early disease duration (< 5 years) also showed central brain NAA/Cr resonance intensity ratios significantly lower than healthy controls ($P < .001$).

Conclusion: Cerebral axonal damage begins and contributes to disability from the earliest stages of the disease.

Arch Neurol. 2001;58:65-70

From the Department of Neurology and Neurosurgery, Montreal Neurological Institute and Hospital, Montreal, Quebec (Drs De Stefano, Francis, Antel, Matthews, and Arnold; Mr Narayanan; and Mss Arnaoutelis and Tartaglia); Institute of Neurological Sciences and NMR Centre, University of Siena, Siena, Italy (Dr De Stefano); and Centre for Functional Magnetic Resonance Imaging of the Brain, Department of Clinical Neurology, University of Oxford, Oxford, England (Dr Matthews).

THE IMPORTANCE of axonal injury in multiple sclerosis (MS) is being increasingly appreciated.¹⁻⁴ Neuropathologic techniques have demonstrated that sparing of axons is only relative in MS.^{5,6} Pathologic evidence of injured or transected axons is common in active MS lesions, and chronic lesions show clear evidence of axonal injury.^{6,7} Although there is increasing agreement that axonal loss is a major factor contributing to disability in the later stages of MS,⁷⁻⁹ the relation of axonal damage to disability in the early stages of MS is less clear.

Magnetic resonance spectroscopy (MRS) is particularly useful for the study of axonal damage because it allows in vivo assessment of axonal dysfunction or loss based on the signal intensity of N-acetylaspartate (NAA), the main component of the peak dominating the normal proton spectrum, which is localized al-

most exclusively in neurons and axons in mature human brains.^{10,11} Large decreases of NAA not restricted to brain lesions were observed in the earliest proton MRS studies of patients with well-established MS¹² and have been confirmed in many subsequent reports (for review see Matthews et al²). Spectroscopic studies also have demonstrated a strong relation be-

*For editorial comment
see page 37*

tween changes in NAA and clinical disability both in acute and chronic MS.¹³⁻¹⁸ Interestingly, in these studies, it was NAA in normal-appearing white matter that correlated best with disability.

Generalization from data reported so far, however, has been limited by the small numbers of patients and the restricted disability range studied. Therefore, we performed proton magnetic resonance spec-

PATIENTS AND METHODS

STUDY POPULATION

Eighty-eight patients with clinically definite MS¹⁹ (48 women and 40 men; age range, 25-58 years) were chosen from the population followed in the Montreal Neurological Hospital MS clinic. Patients were classified according to clinical course as having either recurrent relapses (RR) with complete or partial remission (n=55; 32 women and 23 men) or secondary progressive (SP) disease with progression in the absence of discrete relapses after earlier relapsing-remitting disease (n=33; 16 women and 17 men). Patients were entered into the study only if they had been free from attacks in the previous month to study a clinically relatively stable MS population and reduce the potential confounding of reversible NAA and Cr changes occurring after acute relapses.¹³ Patients were stratified across a wide range of disability (Expanded Disability Status Scale [EDSS] score²⁰; range, 0-9) and disease duration (range, 0.5-33 years). The whole patient group could therefore be subdivided into smaller subgroups according to either their EDSS score or their disease duration (**Table**). The Montreal Neurological Hospital Ethics Committee approved the study, and informed consent was obtained from all participating subjects.

PROTON MRI AND MRSI OF BRAIN

Combined proton MRI and MRSI examinations of the brain were obtained in a single session for each examination using a scanner operating at 1.5 T (Philips Gyroscan; Philips Medical Systems, Best, the Netherlands). A transverse dual-echo, turbo spin-echo sequence (repetition time [TR], 2075 milliseconds; echo time [TE] 1, 32 milliseconds; TE2, 90 milliseconds, 256 × 256 matrix, 1 signal average, 250-mm field of view), yielding proton density-weighted and T2-weighted images with 50 contiguous 3-mm slices, was acquired parallel to the line connecting the anterior and posterior commissures. These MRIs were used to select an intracranial volume of interest (VOI) for spectroscopy measuring approximately 100 mm anteroposteriorly by 20 mm craniocaudally by 90 mm left to right (**Figure 1**). This was centered on the corpus callosum to include mostly white matter and some mesial cortex of both hemispheres. Although the VOI used in this study comprised only a limited portion of the whole brain, this included regions where axonal projections converge after traversing large brain volumes. Thus, NAA/Cr measures from this deep central brain region should reflect axonal status in a fairly large volume of brain beyond that contained within the spectroscopic VOI. Two-dimensional spectroscopic images were obtained using a 90°, 180°, 180° pulse sequence (TR, 2000 milliseconds; TE, 272 milliseconds; 250-mm field of view; 32 × 32 phase-encoding steps; 1 signal average per step) as previously described.²¹ Magnetic field homogeneity was

optimized to a line width of about 5 Hz over the VOI using the proton signal from water. Water suppression was achieved by placing frequency-selective excitation pulses at the beginning of the MRSI sequence.²² Before the water-suppressed acquisition, another MRSI was acquired without water suppression (TR, 850 milliseconds; TE, 272 milliseconds; 250-mm field of view; and 16 × 16 phase-encoding steps) to allow for B₀ homogeneity correction.

PROTON MRSI DATA ANALYSIS

Postprocessing of the raw MRSI data included zero filling the non-water-suppressed MRSI to obtain 32 × 32 profiles, followed by a mild gaussian k-space filter and an inverse 2-dimensional Fourier transformation to both the water-suppressed and unsuppressed MRSI. Artifacts present in the time domain water-suppressed signal due to static magnetic field inhomogeneities and time-varying gradients were corrected by dividing the water-suppressed MRSI signal by the non-water-suppressed signal,²³ a procedure that does not affect relative signal intensities. The residual water signal was then fitted and removed from the water-suppressed data using the Hankel singular-value decomposition procedure.²⁴ To enhance the resolution of the spectral peaks, a lorentzian-to-gaussian transformation was applied before Fourier transformation in the spectral domain. The nominal voxel size was 8 × 8 × 20 mm, giving a resolution of about 12 × 12 × 20 mm after k-space filtering. Metabolite resonance intensities of NAA and Cr were determined automatically from peak areas relative to a spline-corrected baseline. Results were expressed as the intravoxel ratio of NAA to Cr (a signal arising mainly from both Cr and phosphocreatine). In vitro MRS analysis of MS brains has demonstrated that Cr does not change in normal-appearing tissue.²⁵ In the present study, we refer to Cr in the normal-appearing white matter rather than in the lesions, because in the large central VOIs examined, lesions accounted for only about 6% of the VOI in the whole group of patients (range, 0.5%-25%; data not shown).

In our analysis, the relative NAA/Cr values of the whole brain region were obtained by averaging the NAA/Cr values for all the voxels in the spectroscopic VOI for each subject. Spectra at the edges of the VOI can be affected by chemical shift artifacts associated with selective excitation and were deleted before averaging (**Figure 1**). The average NAA/Cr values of the MS patient group were compared with those of a group of healthy adult controls (n=17; age range, 24-56 years) using the nonparametric Kruskal-Wallis test of variance. Central brain NAA/Cr values of the different patient subgroups were compared using analysis of variance followed by pairwise post hoc comparison using the Tukey honestly significant difference procedure to account for multiple comparisons. Values of NAA/Cr of the whole MS patient group and the different subgroups were then correlated with their corresponding EDSS scores using the nonparametric Spearman rank order correlation (SROC). Data were considered significant at the .05 level.

troscopic imaging (MRSI) examinations and concurrent clinical evaluations in a relatively large group of patients with MS with a wide range of clinical disability and disease duration. We then assessed the levels of NAA relative to creatine (Cr) in different patient subgroups and examined the relevance of axonal injury to disability in initial vs later stages of MS.

RESULTS

In the 88 patients with MS studied, the central brain NAA/Cr ratio was significantly lower than in healthy controls (mean ± SD NAA/Cr ratio, 2.71 ± 0.31 and 3.20 ± 0.24, respectively; *P* < .001) (**Table**) and was inversely correlated with disability (SROC = -0.55, *P* < .001). In this group

of patients with MS, age did not correlate with NAA/Cr levels (SROC=0.04, $P>.6$), and there were no differences in NAA/Cr values between men and women (mean \pm SD NAA/Cr ratio=2.71 \pm 0.33 for men with MS and 2.71 \pm 0.29 for women with MS).

Analyses of subgroups based on clinical course, disability level, and duration of disease were performed. Both the RR and SP subgroups exhibited significantly lower NAA/Cr ratios than healthy controls (mean \pm SD NAA/Cr ratio=2.77 \pm 0.33 in patients with RR MS and 2.61 \pm 0.25 in patients with SP MS; $P<.001$ for both groups). Central brain NAA/Cr ratio was significantly lower in patients with SP MS than in those with RR MS ($P=.05$). As in previous studies,^{15,16} the correlation between decreasing NAA/Cr resonance intensity ratios and increasing EDSS scores was stronger in patients with RR MS than in those with SP MS (SROC=-0.64 in RR MS patients, $P<.001$; SROC=-0.28 in SP MS patients, $P<.1$).

When a subgroup of MS patients with milder disability (EDSS score ≤ 5 , $n=50$) was considered alone, central brain NAA/Cr resonance intensity ratios were still significantly lower than healthy controls (mean \pm SD NAA/Cr ratio=2.83 \pm 0.28; $P<.001$). Further dividing this patient subgroup into smaller EDSS groups revealed that decreases in central brain NAA/Cr ratios were significant in patients with MS in the earliest stages of the disease (Table). Changes in NAA/Cr ratios as a function of EDSS were greater for patients with mild disease than for the more severely affected patients. For example, the mean decrease in NAA/Cr ratio between the patient subgroup with EDSS scores of 0 to 1 and the subgroup with EDSS scores of 4 to 5 was about 15% ($P=.001$), whereas the decrease was only 5% between the patient subgroup with EDSS scores of 4 to 5 and the subgroup with EDSS scores of 8 to 9 ($P=.1$) (**Figure 2**). The correlation between NAA/Cr ratio and EDSS score was significantly ($P<.03$) stronger in patients with mild disability (EDSS score ≤ 5 , SROC=-0.54, $P<.001$) than in the more disabled group (EDSS score ≥ 5 , $n=38$, SROC=-0.1, $P=.9$) (**Figure 3**).

When similar analyses were performed in patients with MS grouped for duration of disease, the subgroup with short disease duration (<5 years, $n=21$) also showed central brain NAA/Cr resonance intensity ratios (2.73 \pm 0.35) significantly lower than healthy controls ($P<.001$) and a close correlation between cerebral NAA/Cr ratio and EDSS score (SROC=-0.70, $P<.001$) was found (**Figure 4**). A significant correlation was not found in patients with more long-standing disease.

COMMENT

EARLY AXONAL DAMAGE IN MS

By assessing central brain NAA in a relatively large, clinically stable MS population with a wide range of disability and disease duration, we showed that diffuse cerebral axonal damage (1) begins in the early stages of MS, (2) develops more rapidly in the earlier clinical stages of the disease, and (3) correlates more strongly with disability in patients with mild disease than in patients with more severe disease.

N-Acetylaspartate-Creatine (NAA/Cr) Values Relative to the Whole Group of Patients With Multiple Sclerosis (MS) and Different Subgroups*

Patients	No.	Mean \pm SD NAA/Cr Values
Whole MS group	88	2.71 \pm 0.31†
RR	55	2.77 \pm 0.33†
SP	33	2.61 \pm 0.25†
Disease duration, y		
<5	21 (20 RR, 1 SP)	2.73 \pm 0.35†
5-10	21 (18 RR, 3 SP)	2.79 \pm 0.33†
11-15	22 (11 RR, 11 SP)	2.73 \pm 0.26†
>15	24 (6 RR, 18 SP)	2.60 \pm 0.29†
EDSS score		
0-1	17 (17 RR, 0 SP)	3.01 \pm 0.31
2-3	19 (18 RR, 1 SP)	2.84 \pm 0.20†
4-5	20 (12 RR, 8 SP)	2.58 \pm 0.28†
6-7	25 (8 RR, 17 SP)	2.59 \pm 0.23†
8-9	7 (0 RR, 7 SP)	2.45 \pm 0.28†
Healthy controls	17	3.20 \pm 0.24

*RR indicates relapsing remitting; SP, secondary progressive; and EDSS, Expanded Disability Status Scale.

† $P<.001$ compared with healthy controls.

Our results emphasize that significant axonal pathology is not confined to lesions and must occur early in the evolution of MS, ie, axonal injury and loss is not restricted to the end stages of the disease. Even complete clinical recovery from acute attacks in early MS does not mean that axonal damage has not occurred. In the initial stages of MS, in addition to functional recovery due to reversal of axonal conduction block associated with inflammation and release of soluble factors,²⁶ functional impairment due to axonal damage and dysfunction may be compensated for by mechanisms such as sodium channel redistribution^{27,28} and brain plasticity.^{29,30} In fact, the presence of early axonal damage in MS has been suggested in recent histological studies that showed that (1) axon degeneration can accompany acute demyelination,³¹ (2) milder axonal changes can occur before inflammation,³² and (3) axon degeneration can be evident in MS lesions of individuals with no history of neurologic symptoms.^{33,34} These in vitro observations lend support to our in vivo findings in suggesting that axonal damage does accumulate and is relevant to disability from the early stages of MS.

An interesting finding reported herein is that the decreases in NAA/Cr ratio were faster with respect to EDSS score in earlier stages of MS than in later stages. This should not be interpreted as evidence that axonal damage contributes less to disability later in the course of MS. In fact, with the progression of the disease, other mechanisms of axonal damage may become important and be more sensitively assessed by other magnetic resonance measures (ie, loss of brain and spinal cord parenchymal volume³⁵).³⁶⁻³⁸ The loss of spinal cord volume, for example, appears to be more evident in patients with SP MS than in those with the relapsing form of the disease.³⁷ Recent studies also have suggested that brain atrophy, although detectable in patients with RR MS,³⁹ is more prominent in the progressive phase of MS. In addition, marked brain volume changes in the later stages

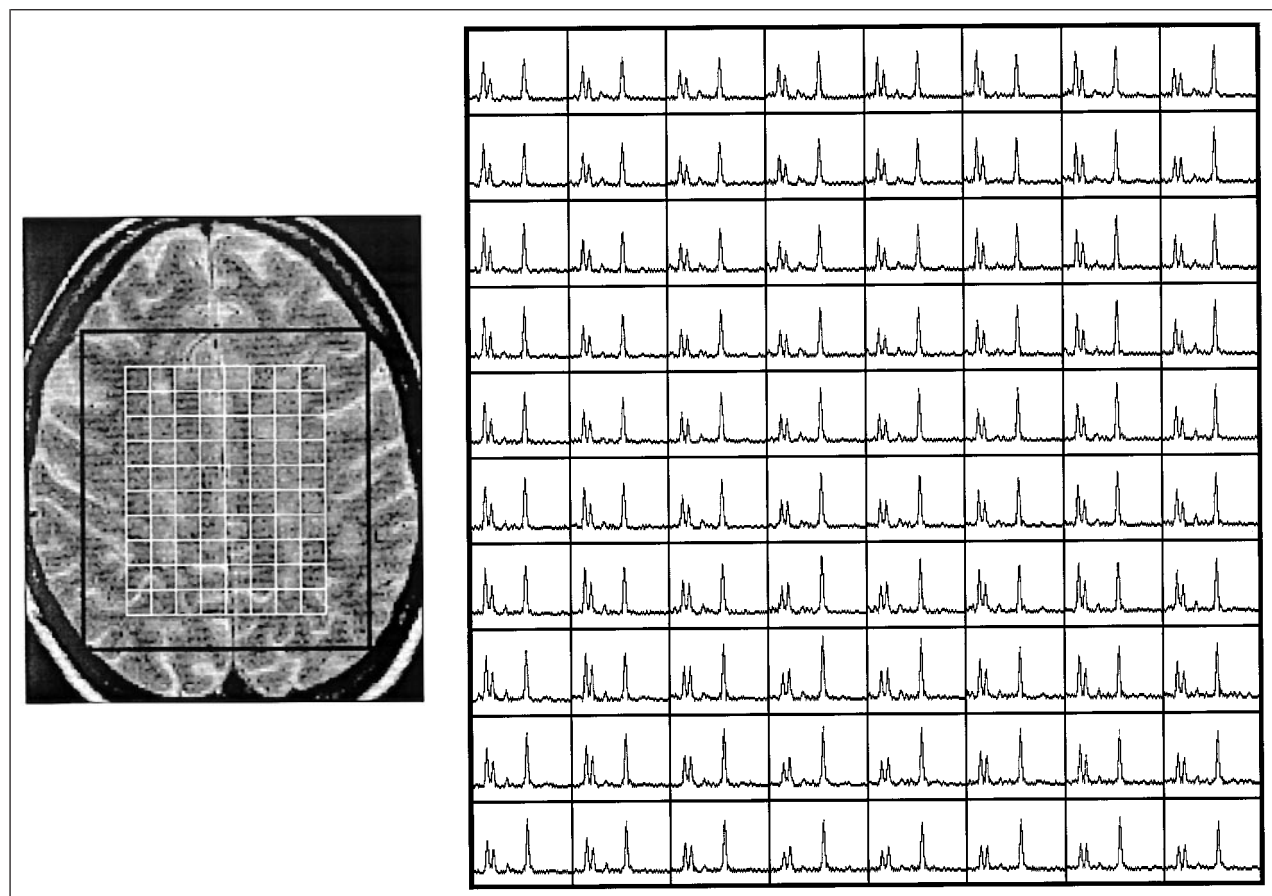


Figure 1. Conventional T2-weighted magnetic resonance imaging (MRI) scan of a patient with multiple sclerosis illustrating the volume of interest (VOI, black box inside the MRI) used for spectroscopy (left) and a set of proton spectra corresponding to the brain voxels (right). Voxels at the edges of the VOI were not used because they can show artifactual relative amplitudes. In the remaining voxels (white boxes inside the MRI), N-acetylaspartate (NAA) values were normalized to intravoxel creatine (Cr) to correct for magnetic resonance inhomogeneities through the VOI. The NAA/Cr values of the whole brain region were obtained by averaging NAA/Cr values for all the voxels in the spectroscopic VOI for each subject.

of MS might affect, to some extent, the sensitivity of NAA measurements. Thus, the presence of more pronounced brain atrophy and spinal cord pathology in late disease stages may explain, at least in part, the weaker relation between NAA/Cr ratio and EDSS score found in our study of patients with MS and severe disability.

NAA/Cr RATIO AS A MARKER OF AXONAL DAMAGE

We believe that NAA is a reliable marker of axonal integrity in the adult brain. Antibodies directed against NAA or N-acetylaspartylglutamate stain neurons strongly without staining glial cells.^{11,40} The fact that O2A progenitor cells in culture express NAA⁴¹ has raised some concerns about the specificity of NAA changes in vivo. However, O2A progenitor cells have been characterized only in culture. Related A2B5-positive cells are believed to occur in vivo but do not appear to be abundant enough to be able to contribute substantially to the total amount of NAA measured.⁴² A recent report⁴³ has demonstrated that NAA can be detected in cultured, rat-derived O2A progenitor cells and mature oligodendrocytes derived from them. However, it is not clear that these in vitro conditions are relevant to the situation in vivo. There is a need to reconcile the antibody data with these high-performance liq-

uid chromatography and nuclear magnetic resonance-based analyses. Regarding the results presented herein, oligodendrocyte density appears not to be reduced in normal-appearing white matter, which constitutes the majority of the tissue in our spectroscopic VOI. Thus, the potential for NAA expression in oligodendrocytes confounding our results appears to be minimal.⁴⁴

Proton MRSI results are expressed in this study as NAA/Cr ratios. The resonance intensity of intravoxel Cr has been widely used as internal standard in MRS studies in vivo, since it is relatively equally present in all brain cells and tends to be stable in chronic (ie, nonacute¹³) pathologic conditions. Changes in apparent brain Cr concentrations have been reported in chronic MS in recent MRS studies that attempted absolute quantitation. However, all current quantitative approaches have important limitations when applied to clinical studies and, in patients with MS, have shown discrepant results, reporting in turn increases, decreases, and absence of Cr changes in MRI lesions and in the normal-appearing white matter.^{17,45-50} We believe that the most reliable data come from a study using high-resolution in vitro proton nuclear magnetic resonance spectroscopy (which does not have the same limitations as in vivo quantitation) on postmortem MS tissue.²⁵ This study showed that Cr was decreased in MS plaques and that Cr levels were un-

changed in the normal-appearing brain. In the present study, lesions occupied, on average, about 6% of the brain VOI used for spectroscopy (see the "Patients and Methods" section), suggesting that significant changes in Cr resonance intensities are unlikely. Consistent with this, ratios of choline to Cr resonance intensities in the group of patients with MS did not differ from controls (data not shown).

CONCLUSIONS

Central brain NAA/Cr ratios reveal that axonal injury begins in the early stages of MS. The strong correlation be-

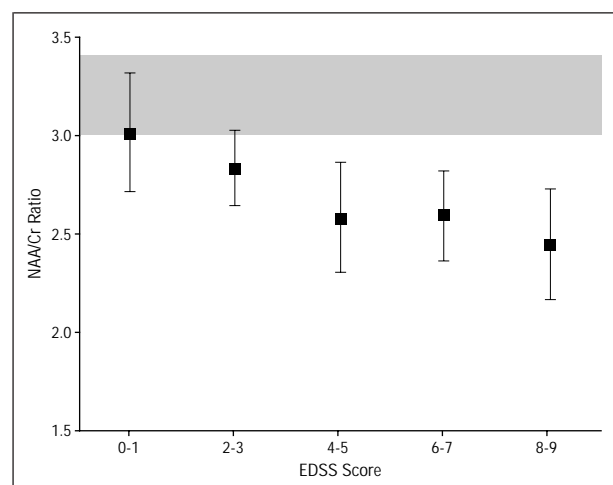


Figure 2. Mean N-acetylaspartate-creatine (NAA/Cr) ratios for patients with multiple sclerosis grouped by Expanded Disability Status Scale (EDSS) score. In the different patient subgroups, analysis of variance followed by pairwise post hoc comparison (Tukey honestly significant difference procedure) showed that changes in NAA/Cr ratio with respect to EDSS score are greater for patients with lower EDSS scores than for more disabled patients (see the "Results" section). Shaded area indicates mean \pm SD of healthy controls.

tween NAA/Cr ratio and EDSS score in patients with low disability and disease duration adds to accumulating evidence that axonal damage is a primary determinant of disability from the early stages of the disease. To better understand the contribution of axonal loss to disability through the full course of the disease, the use of new measures⁵¹ and the integration of multiple magnetic resonance modalities (ie, brain NAA, cerebral and spinal cord volumes) will be necessary. The close relation between

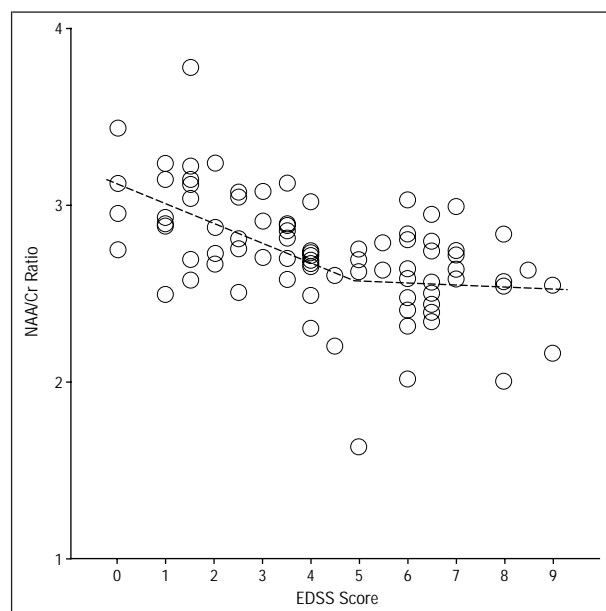


Figure 3. Data from 88 patients with multiple sclerosis illustrating the nonlinear decrease of N-acetylaspartate-creatine (NAA/Cr) ratio with respect to Expanded Disability Status Scale (EDSS) score. A significant relation can be seen in the group of patients with milder disability (EDSS score < 5 , Spearman rank order correlation = -0.54 , $P < .001$) but cannot be seen in the more disabled group (EDSS score ≥ 5 , Spearman rank order coefficient = -0.1 , $P = .9$).

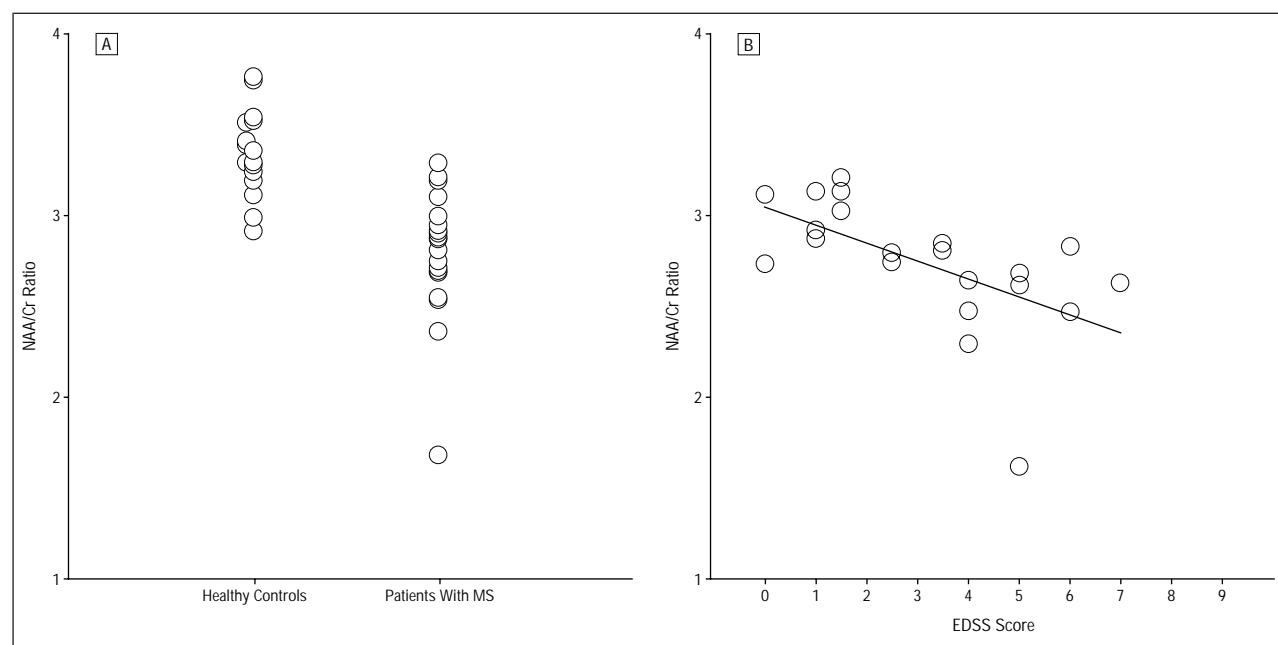


Figure 4. Data from patients with multiple sclerosis (MS) with disease duration of less than 5 years illustrating the following: (A) the significant decrease in N-acetylaspartate-creatine (NAA/Cr) ratio relative to the healthy control group ($P < .001$) and (B) a very strong correlation between NAA/Cr ratio and Expanded Disability Status Scale (EDSS) score (Spearman rank order correlation = -0.70 , $P < .001$).

axonal pathology and clinical disability in the early stages of the disease argues for the early treatment of MS with agents directed not only against inflammation but also toward axonal protection.^{3,52,53}

Accepted for publication June 13, 2000.

This study was supported by grants from the Multiple Sclerosis Society of Canada and the Medical Research Council of Canada and a pilot grant from the National Multiple Sclerosis Society. Dr De Stefano was supported in part by a grant from the Progetto Sclerosi Multipla, Istituto Superiore di Sanita', Rome, Italy. Dr Matthews acknowledges support from the Medical Research Council and the Multiple Sclerosis Society of Great Britain and Northern Ireland.

Corresponding author: Nicola De Stefano, MD, Institute of Neurological Science, Viale Bracci 2, 53100, Siena, Italy (e-mail: destefano@unisi.it).

REFERENCES

- McDonald WI. Rachele Fishman-Matthew Moore Lecture: the pathological and clinical dynamics of multiple sclerosis [review]. *J Neuropathol Exp Neurol*. 1994; 53:338-343.
- Matthews PM, De Stefano N, Narayanan S, et al. Putting magnetic resonance spectroscopy studies in context: axonal damage and disability in multiple sclerosis. *Semin Neurol*. 1998;18:327-336.
- Trapp BD, Ransohoff R, Rudick R. Axonal pathology in multiple sclerosis: relationship to neurological disability. *Curr Opin Neurol*. 1999;12:295-302.
- Waxman SG. Multiple sclerosis as a neuronal disease [editorial; comment]. *Arch Neurol*. 2000;57:22-24.
- Ferguson B, Matyszak MK, Esiri MM, Perry VH. Axonal damage in acute multiple sclerosis lesions. *Brain*. 1997;120:393-399.
- Trapp BD, Peterson J, Ransohoff RM, Rudick R, Mork S, Bo L. Axonal transection in the lesions of multiple sclerosis. *N Engl J Med*. 1998;338:278-285.
- Silber E, Sharief MK. Axonal degeneration in the pathogenesis of multiple sclerosis. *J Neurol Sci*. 1999;170:11-18.
- Barnes D, Munro PMG, Youl BD, Prineas JW, McDonald WI. The longstanding MS lesion: a quantitative MRI and electron microscopic study. *Brain*. 1991;114: 1271-1280.
- Scolding N, Franklin R. Axon loss in multiple sclerosis. *Lancet*. 1998;352:340-341.
- Birken DL, Oldendorf WH. *N*-acetyl-L-aspartic acid: a literature review of a compound prominent in ¹H-NMR spectroscopic studies of brain. *Neurosci Biobehav Rev*. 1989;13:23-31.
- Simmons ML, Frondoza CG, Coyle JT. Immunocytochemical localization of *N*-acetyl-aspartate with monoclonal antibodies. *Neuroscience*. 1991;45:37-45.
- Arnold DL, Matthews PM, Francis G, Antel J. Proton magnetic resonance spectroscopy of human brain in vivo in the evaluation of multiple sclerosis: assessment of the load of disease. *Magn Reson Med*. 1990;14:154-159.
- De Stefano N, Matthews PM, Antel JP, Preul M, Francis G, Arnold DL. Chemical pathology of acute demyelinating lesions and its correlation with disability. *Ann Neurol*. 1995;38:901-909.
- Davie CA, Barker GJ, Webb S, et al. Persistent functional deficit in multiple sclerosis and autosomal dominant cerebellar ataxia is associated with axon loss. *Brain*. 1995;118:1583-1592.
- Fu L, Matthews PM, De Stefano N, et al. Imaging axonal damage of normal-appearing white matter in multiple sclerosis. *Brain*. 1998;121:103-113.
- De Stefano N, Matthews PM, Fu L, et al. Axonal damage correlates with disability in patients with relapsing-remitting multiple sclerosis: results of a longitudinal magnetic resonance spectroscopy study. *Brain*. 1998;121:1469-1477.
- Davie CA, Silver NC, Barker GJ, et al. Does the extent of axonal loss and demyelination from chronic lesions in multiple sclerosis correlate with the clinical subgroup? *J Neurol Neurosurg Psychiatry*. 1999;67:710-715.
- Lee MA, Blamire AM, Pendlebury S, et al. Axonal injury or loss in the internal capsule and motor impairment in multiple sclerosis. *Arch Neurol*. 2000;57:65-70.
- Poser CM, Paty DW, Scheinberg L, et al. New diagnostic criteria for multiple sclerosis: guidelines for research protocols. *Ann Neurol*. 1983;13:227-231.
- Kurtzke JF. Rating neurologic impairment in multiple sclerosis: an Expanded Disability Status Scale (EDSS). *Neurology*. 1983;33:1444-1452.
- De Stefano N, Matthews PM, Arnold DL. Reversible decreases in *N*-acetyl-aspartate after acute brain injury. *Magn Reson Med*. 1995;34:721-727.
- Haase A, Frahm J, Hanicke W, Matthaei D. ¹H NMR chemical shift selective (CHESS) imaging. *Phys Med Biol*. 1985;30:341-344.
- den Hollander JA, Oosterwaal B, van Vroonhoven H, Luyten PR. Elimination of magnetic field distortions in ¹H NMR spectroscopic imaging [abstract]. *Proc Soc Magn Reson Med*. 1991;1:472.
- de Beer R, Van den Boogaart A, van Ormondt D, et al. Application of time-domain fitting in the quantification of in vivo ¹H spectroscopic imaging data sets. *NMR Biomed*. 1992;5:171-178.
- Davies SE, Newcombe J, Williams SR, McDonald WI, Clark JB. High resolution proton NMR spectroscopy of multiple sclerosis lesions. *J Neurochem*. 1995;64: 742-748.
- Smith KJ, Kapoor R, Felts PA. Demyelination: the role of reactive oxygen and nitrogen species. *Brain Pathol*. 1999;9:69-92.
- Moll C, Mourre C, Lazdunski M, Ulrich J. Increase of sodium channels in demyelinated lesions of multiple sclerosis. *Brain Res*. 1991;556:311-316.
- Black JA, Felts P, Smith KJ, Kocsis JD, Waxman SG. Distribution of sodium channels in chronically demyelinated spinal cord axons: immuno-ultrastructural localization and electrophysiological observations. *Brain Res*. 1991;544:59-70.
- Waxman SG. Molecular remodeling of neurons in multiple sclerosis: what we know, and what we must ask about brain plasticity in demyelinating diseases. *Adv Neurol*. 1997;73:109-120.
- Reddy H, Narayanan S, Matthews PM, et al. Relating axonal injury to functional recovery in MS. *Neurology*. 2000;54:236-239.
- Silver NC, Barker RA, MacManus DG, et al. Proton magnetic resonance spectroscopy in a pathologically confirmed acute demyelinating lesion [letter]. *J Neurol*. 1997;244:204-207.
- Zhu B, Moore GR, Zwimpfer TJ, et al. Axonal cytoskeleton changes in experimental optic neuritis. *Brain Res*. 1999;824:204-217.
- Mews I, Bergmann M, Bunkowski S, Gullotta F, Bruck W. Oligodendrocyte and axon pathology in clinically silent multiple sclerosis lesions. *Mult Scler*. 1998; 4:55-62.
- Trapp BD, Ransohoff RM, Fisher E, Rudick RA. Neurodegeneration in multiple sclerosis: relationship to neurological disability. *Neuroscientist*. 1999;5:48-57.
- Filippi M, Colombo B, Rovaris M, Pereira C, Martinelli V, Comi G. A longitudinal magnetic resonance imaging study of the cervical cord in multiple sclerosis. *J Neuroimaging*. 1997;7:78-80.
- Losseff NA, Miller DH. Measures of brain and spinal cord atrophy in multiple sclerosis. *J Neurol Neurosurg Psychiatry*. 1998;64(suppl 1):S102-S105.
- Stevenson VL, Leary SM, Losseff NA, et al. Spinal cord atrophy and disability in MS: a longitudinal study. *Neurology*. 1998;51:234-238.
- Nijeholt GJ, van Walderveen MA, Castelijns JA, et al. Brain and spinal cord abnormalities in multiple sclerosis: correlation between MRI parameters, clinical subtypes and symptoms. *Brain*. 1998;121:687-697.
- Simon JH, Jacobs LD, Campion MK, et al. A longitudinal study of brain atrophy in relapsing multiple sclerosis: the Multiple Sclerosis Collaborative Research Group (MSCRG). *Neurology*. 1999;53:139-148.
- Moffett JR, Nambodiri MAA, Cangro CB, Neale JH. Immunohistochemical localization of *N*-acetylaspargate in rat brain. *Neurol Rep*. 1991;2:131-134.
- Urenjak J, Williams SR, Gadian DG, Noble M. Proton nuclear magnetic resonance spectroscopy unambiguously identifies different neural cell types. *J Neurosci*. 1993;13:981-989.
- Scolding N, Franklin R, Stevens S, Heldin CH, Compston A, Newcombe J. Oligodendrocyte progenitors are present in the normal adult human CNS and in the lesions of multiple sclerosis. *Brain*. 1998;121:2221-2228.
- Bhakoo KK, Pearce D. In vitro expression of *N*-acetyl aspartate by oligodendrocytes: implications for proton magnetic resonance spectroscopy signal in vivo. *J Neurochem*. 2000;74:254-262.
- Wolswijk G. Chronic stage multiple sclerosis lesions contain a relatively quiescent population of oligodendrocyte precursor cells. *J Neurosci*. 1998;18:601-609.
- Husted CA, Goodin DS, Hugg JW, et al. Biochemical alterations in multiple sclerosis lesions and normal-appearing white matter detected by in vivo ³¹P and ¹H spectroscopic imaging. *Ann Neurol*. 1994;36:157-165.
- Pan JW, Hetherington HP, Vaughan JT, Mitchell G, Pohost GM, Whitaker JN. Evaluation of multiple sclerosis by ¹H spectroscopic imaging at 4.1 T. *Magn Reson Med*. 1996;36:72-77.
- Davie CA, Barker GJ, Thompson AJ, Tofts PS, McDonald WI, Miller DH. ¹H magnetic resonance spectroscopy of chronic cerebral white matter lesions and normal appearing white matter in multiple sclerosis. *J Neurol Neurosurg Psychiatry*. 1997;63:736-742.
- Sarchielli P, Presciutti O, Pelliccioli GP, et al. Absolute quantification of brain metabolites by proton magnetic resonance spectroscopy in normal-appearing white matter of multiple sclerosis patients. *Brain*. 1999;122:513-521.
- van Walderveen MA, Barkhof F, Pouwels PJ, van SR, Polman CH, Castelijns JA. Neuronal damage in T1-hypointense multiple sclerosis lesions demonstrated in vivo using proton magnetic resonance spectroscopy. *Ann Neurol*. 1999;46: 79-87.
- Narayana PA, Doyle TJ, Lai D, Wolinsky JS. Serial proton magnetic resonance spectroscopic imaging, contrast-enhanced magnetic resonance imaging, and quantitative lesion volumetry in multiple sclerosis. *Ann Neurol*. 1998;43:56-71.
- Gonen O, Catalaa I, Babb JS, et al. Total brain *N*-acetylaspargate: a new measure of disease load in MS. *Neurology*. 2000;54:15-19.
- Compston A. Future options for therapies to limit damage and enhance recovery. *Semin Neurol*. 1998;18:405-414.
- Demerens C, Stankoff B, Zalc B, Lubetzki C. Eliprodil stimulates CNS myelination: new prospects for multiple sclerosis? *Neurology*. 1999;52:346-350.