

## ICG fluorescence-guided sentinel node biopsy for axillary nodal staging in breast cancer

Christoph Hirche, Dawid Murawa, Zarah Mohr, Soeren Kneif, Michael Hünnerbein

► **To cite this version:**

Christoph Hirche, Dawid Murawa, Zarah Mohr, Soeren Kneif, Michael Hünnerbein. ICG fluorescence-guided sentinel node biopsy for axillary nodal staging in breast cancer. *Breast Cancer Research and Treatment*, Springer Verlag, 2010, 121 (2), pp.373-378. 10.1007/s10549-010-0760-z . hal-00535442

**HAL Id: hal-00535442**

**<https://hal.archives-ouvertes.fr/hal-00535442>**

Submitted on 11 Nov 2010

**HAL** is a multi-disciplinary open access archive for the deposit and dissemination of scientific research documents, whether they are published or not. The documents may come from teaching and research institutions in France or abroad, or from public or private research centers.

L'archive ouverte pluridisciplinaire **HAL**, est destinée au dépôt et à la diffusion de documents scientifiques de niveau recherche, publiés ou non, émanant des établissements d'enseignement et de recherche français ou étrangers, des laboratoires publics ou privés.

# ICG fluorescence-guided sentinel node biopsy for axillary nodal staging in breast cancer

Christoph Hirche · Dawid Murawa ·  
Zarah Mohr · Soeren Kneif · Michael Hünerbein

Received: 11 September 2009 / Accepted: 19 January 2010 / Published online: 7 February 2010  
© Springer Science+Business Media, LLC. 2010

**Abstract** *Background:* Sentinel lymph node (SLN) biopsy is a selective approach to axillary staging of breast cancer with reduced morbidity. Current detection methods including radioisotope and blue dye show good results but some drawbacks are remaining. Indocyanine green (ICG) fluorescence detection was evaluated as a new method for SLN biopsy in breast cancer allowing both transcutaneous visualization of lymphatic vessels and intraoperative identification of SLN. *Methods:* Forty-three women with clinically node negative breast cancer received subareolar injection of ICG for fluorescence detection of SLN. All patients underwent either planned axillary lymph node dissection (ALND) with SLN biopsy or selective SLN biopsy to determine need for ALND. Clinical feasibility, detection rate, sensitivity, and axillary recurrence after isolated SLN biopsy were analyzed. *Results:* Overall ICG fluorescence imaging identified 2.0 SLN in average in 42 of 43 patients (detection rate: 97.7%). Metastatic involvement of the SLN was found in 17 of 18 nodal positive patients by conventional histopathology (sensitivity: 94.4%). Immunohistochemistry revealed isolated tumor cells in five further cases. There was only one false-negative case in 43 patients (5.6%). In 17 of 23 overall nodal positive patients, the SLN was the only positive lymph node. After a median follow-up of 4.7 years none of the patients presented with axillary recurrence. *Conclusion:* ICG fluorescence imaging is a new method for SLN biopsy in breast cancer with acceptable sensitivity and specificity comparable to conventional methods. One advantage of this

technique is that it allows transcutaneous visualization of lymphatic vessels and intraoperative lymph node detection without radioisotope.

**Keywords** Sentinel lymph node biopsy · Breast cancer · Indocyanine green (ICG) · Fluorescence imaging · Surgery

## Abbreviations

ALND Axillary lymph node dissection  
ICG Indocyanine green  
SLN Sentinel lymph node

## Introduction

Axillary lymph node staging by sentinel lymph node (SLN) biopsy is a widely used method and an independent prognostic factor in patients with early breast cancer [1–3]. Patients who underwent SLN biopsy with a negative SLN have an improved disease-free and overall survival compared with node negative axillary lymph node dissection (ALND) patients [4, 5]. The reason for this observation is clearly the more extensive histopathologic workup of lymph nodes resulting in a more accurate axillary staging, a reduced rate of false-negative results and stage migration [6, 7]. SLN biopsy has been reported to result in an increased quality of life with reduced morbidity, but especially younger patients after isolated SLN biopsy with early breast cancer showed greater procedure-associated levels of anxiety [8].

SLN biopsy for breast cancer is usually carried out with radioactive colloids and/or blue dye [9]. Radionuclide scanning provides good accuracy allowing transcutaneous

C. Hirche · D. Murawa · Z. Mohr · S. Kneif ·  
M. Hünerbein (✉)  
Department of General Surgery and Surgical Oncology,  
Robert-Rössle-Klinik, Helios Hospital Berlin-Buch, CCB,  
13125 Berlin, Germany  
e-mail: michael.huenerbein@helios-kliniken.de

navigation to the SLN by scintigraphy and handheld gamma probe [10, 11]. However, the use of radioactive colloids involves expensive equipment, radiation protection measures and is not generally available [12]. Injection of blue dye is easy to perform and enables the surgeon to see marked lymphatic vessels and the SLN intraoperatively after skin incision. Application of blue dye alone results in a reduced detection rate [13]. Moreover, isosulfan blue (Lymphazurin<sup>TM</sup>) as the most commonly used blue dye has been associated with a significant risk of anaphylactic reactions and other adverse effects such as tattooing and skin necrosis [14–16]. Combination of both methods results in a rate of SLN identification of more than 90%, but the accuracy ranges from 65 to 98% [17, 18].

Preliminary data from toxicity and feasibility studies suggest that SLN detection guided by indocyanine green (ICG) fluorescence could emerge as a new method for SLN biopsy [19]. It has been shown that subareolar injection of ICG can be performed without allergic reactions or toxic side effects [20]. Theoretically, fluorescence imaging enables transcutaneous real-time lymphography and intraoperative lymph node detection thus combining the advantages of radiocolloid method and blue dye method.

The aim of this study was to investigate exclusively the clinical application of SLN biopsy guided by ICG fluorescence in breast cancer as an alternative to the other more established methods, i.e., radiocolloid and blue dye. The method was analyzed with regard to clinical practicability and accuracy in detecting SLN.

## Patients and methods

### Study design and patients

This study was designed to evaluate the clinical value of SLN detection with fluorescence imaging after injection of ICG. The study was approved by the Institutional Review Board (IRB) of the hospital. Preoperatively, informed consent was obtained from all patients. Inclusion criteria were histopathological diagnosis of breast cancer, image-guided tumor diameter  $\leq 3$  cm, and indication for mastectomy or breast conserving therapy without clinically positive lymph node status. Axillary lymph node status was assessed clinically and by ultrasound with a 10-MHz linear transducer (Voluson<sup>®</sup> 730 Expert, GE Healthcare, Fairfield, USA) to exclude distinct positive nodal status. Exclusion criteria comprised previous operations and/or radiation of the breast, definite lymph node metastases diagnosed by palpation or ultrasound, and age  $< 18$  years.

Altogether, this study included 43 patients with breast cancer who underwent planned mastectomy or breast conserving therapy. The mean age was 58.4 years. Most

common diagnosis was invasive ductal carcinoma (78.7%) followed by invasive lobular carcinoma (11.9%). Mastectomy or breast conserving therapy was performed in 28 and 15 patients, respectively. Indications for mastectomy were disproportion between tumor and breast size, multifocality, preoperative non-compliance to adjuvant radiation, and male gender.

Depending on tumor stage and clinical parameters all patients underwent either SLN biopsy for superstaging with planned ALND of level I/II or selective SLN biopsy. Criteria for ALND in 34 patients (79%) were preoperative tumor stage of T2 in 25 patients (58%) and a positive SLN in frozen sections in 9 patients with preoperative tumor stage T1 (21%). In case of undetectable SLN, ALND was performed. Detailed clinicopathological data and tumor characteristics are summarized in Tables 1 and 2.

Detection rate, sensitivity, and false-negative rate were calculated by comparing the results of SLN biopsy and histopathology of the resection specimen in case of ALND. Axillary recurrence after isolated SLN biopsy without axillary clearance was analyzed by scheduled follow-ups including clinical examination and ultrasound.

### SLN detection with ICG fluorescence imaging

ICG fluorescence was visualized with a fluorescence imaging system (IC-View, Pulsion Medical Systems, Munich, Germany) consisting of a digital video camera with an integrated near-infrared (NIR) light source (energy 0.16 W, wavelength 780 nm). The objective of the camera was covered with a filter (835 nm) to collect NIR radiation and reject visible light. Intraoperatively, in average 11 mg ICG solution was injected into the subareolar region of the breast. The lymphatic transport of ICG at the anterior chest wall including the supraclavicular, parasternal, and axillary regions was observed in real time with fluorescence imaging for 5–15 min after injection. The end of the lymphatic vessel was marked on the skin. SLN was excised directly in situ. Fluorescence lymphography including SLN identification and SLN biopsy was performed by two experienced surgeons.

**Table 1** Characteristics of patients and surgical procedures ( $n = 43$ )

|                                  |                |
|----------------------------------|----------------|
| Mean age and range (years)       | 58.4 (27–83)   |
| Gender female/male               | 40/3 (93/7%)   |
| Mastectomy/BCT                   | 28/15 (65/35%) |
| Axillary nodal status assessment |                |
| ALND                             | 34 (79%)       |
| Primary isolated SLNB            | 9 (21%)        |
| Secondary ALND                   | 2/9 (22%)      |

SLNB sentinel lymph node biopsy, ALND axillary lymph node dissection, BCT breast conserving therapy

**Table 2** Histopathological characteristics ( $n = 43$ )

|   |          |
|---|----------|
| Pathology   |          |
| Invasive ductal   | 34 (79%) |
| Invasive lobular  | 5 (12%)  |
| Invasive papillar   | 2 (5%)   |
| DCIS  | 1 (2%)   |
| Mixed type  | 1 (2%)   |
| Tumor staging   |          |
| pT1   | 18 (42%) |
| pT2   | 23 (54%) |
| pT3/4   | 2 (4%)   |
| Nodal staging   |          |
| pN0   | 25 (58%) |
| pN1   | 13 (30%) |
| pN2   | 3 (7%)   |
| pN3   | 2 (5%)   |
| Grading   |          |
| G1  | 12 (28%) |
| G2  | 19 (44%) |
| G3  | 12 (28%) |
| Primary tumor dissemination<br>(multifocal and multicentric spread) | 10 (23%) |
| Mean tumor diameter (mm)  | 22.3     |
| Mean number of LN excised   | 14.9     |
| Mean number of SLN excised  | 2.0      |

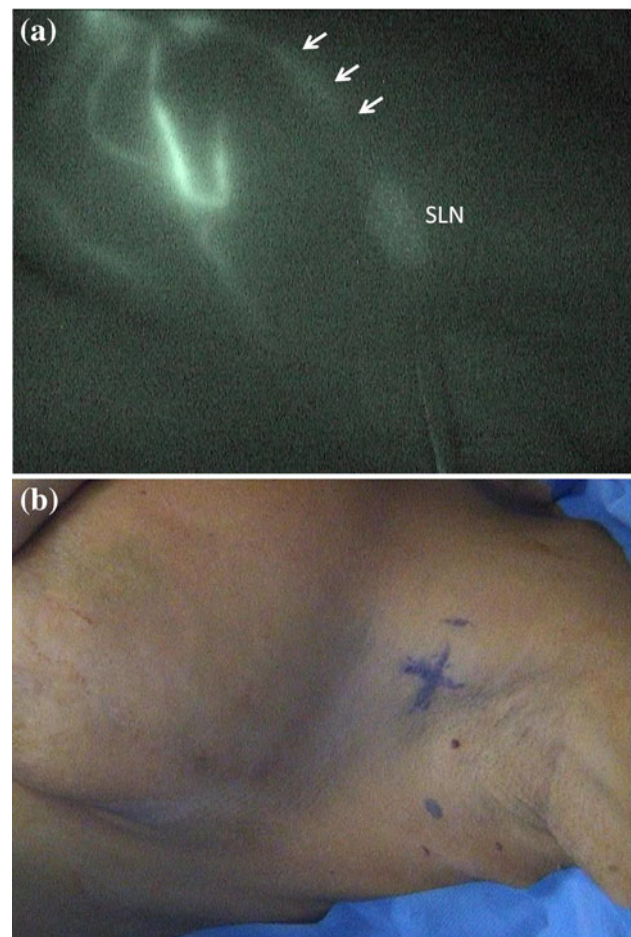
SLN sentinel lymph node, LN lymph node

### Histopathology

The mean tumor diameter in resected specimen was 22.3 mm. Intraoperatively, SLN was analyzed by frozen sections with conventional staining. All SLN negative for metastatic involvement underwent specific evaluation using a standardized protocol using immunohistochemistry. The detailed technique has been described by Meyer [21]. In brief, SLN tissue was sliced at 2 mm intervals for fixation and paraffin embedding. Microsections were prepared repeatedly at intervals of 250  $\mu$ m and examined by routine Hematoxylin-Eosin (HE)-staining. Negative SLN was re-examined by serial sectioning at intervals of 5  $\mu$ m and one microsection of each level was analyzed by HE-staining and a second by cytokeratins immunohistochemistry (MNF 116, Dako, Hamburg, Germany). After additional immunohistochemical processing, two patients (5%) with isolated immunohistochemical positive SLN received secondary ALND. All non-SLN were examined by standard pathologic measures with HE-staining. Histopathological primary tumor dissemination with multifocal and/or multicenter spread inside the breast was found in 10 of 43 patients (23%).

### Results

None of the 43 patients experienced adverse reactions or complications related to intraoperative injection of ICG. Overall ICG fluorescence imaging identified 2.0 SLN on average (range 1–3 SLN) in 42 of 43 patients (detection rate 97.7%) although none of the lymph nodes showed green staining. Identification of SLN was facilitated by transcutaneous visualization of lymphatic vessels by fluorescence (Fig. 1). The mean number of lymph nodes excised was 14.9 for ALND including SLN. Eighteen of 43 patients (42%) had metastatic lymph node involvement. ICG fluorescence imaging identified metastatic SLNs in 17 of those patients after conventional microscopic analysis (sensitivity 94.4%). There was only one undetected case resulting in a false-negative rate of 5.6%. The patient underwent ALND because of missed intraoperative SLN



**Fig. 1** ICG fluorescence imaging. **a** Transcutaneous real-time lymphography for detection of the SLN after injection of ICG (left upper site). The lymphatic vessel (arrows) and the SLN are displayed. **b** The end of the lymphatic vessels with the SLN is marked on the skin for excision

detection and showed positive nodal involvement. Immunohistochemistry revealed five additional cases with isolated tumor cells (ITC) in the SLN. The SLN was the only positive lymph node in 12 of 18 patients (67%) using conventional histopathology and in 17 of 23 (74%) with additional immunohistochemistry. Two of five patients with immunohistochemically diagnosed ITC agreed to secondary ALND and adjuvant radiotherapy. ALND of these two patients showed no metastatic disease in conventionally dissected specimen. The ratio of LN positive/SLN positive of all nodal positive patients was 3.0. After a median follow-up of 4.7 years, no patient with negative SLN by ICG presented with axillary recurrence. The detailed results are displayed in Tables 2 and 3.

## Discussion

Axillary lymph node status remains the most important prognostic factor in the treatment of breast cancer and affects the choice of systemic therapy and adjuvant radiotherapy [22, 23]. Standard techniques for sentinel node biopsy include the radiocolloid method, the blue dye method, and a combination of both [24, 25].

Recently, preliminary studies have suggested that SLN biopsy can be guided by fluorescence detection after subareolar injection of ICG. The transport of ICG through lymphatic vessels was shown to be visualized transcutaneously by fluorescence guidance and was validated for SLN biopsy in comparison to conventional technique [26, 27].

**Table 3** Sentinel lymph node status by fluorescence navigation

| Measure   | No. (%)        |
|---|----------------|
| Total no. of patients   | 43 (100%)      |
| Patients with SLN identified  | 42 of 43 (98%) |
| Patients with positive LN (conventional)  | 18 of 43 (42%) |
| Patients with positive SLN (conventional)                                       | 17 of 43 (40%) |
| Patients with positive SLN/positive LN (conventional)                           | 17 of 18 (94%) |
| Patients with isolated positive SLN after dissection of specimen (conventional) | 12 of 17 (71%) |
| Patients with positive SLN by ITC (immunohistochemical)                         | 5 of 43 (12%)  |
| Ratio positive LN/positive SLN of all nodal positive                            | 6.9/2.3 = 3    |
| Detection rate  | 42/43 (97.7%)  |
| Sensitivity   | 17/18 (94.4%)  |
| False-negative rate   | 1/18 (5.6%)    |

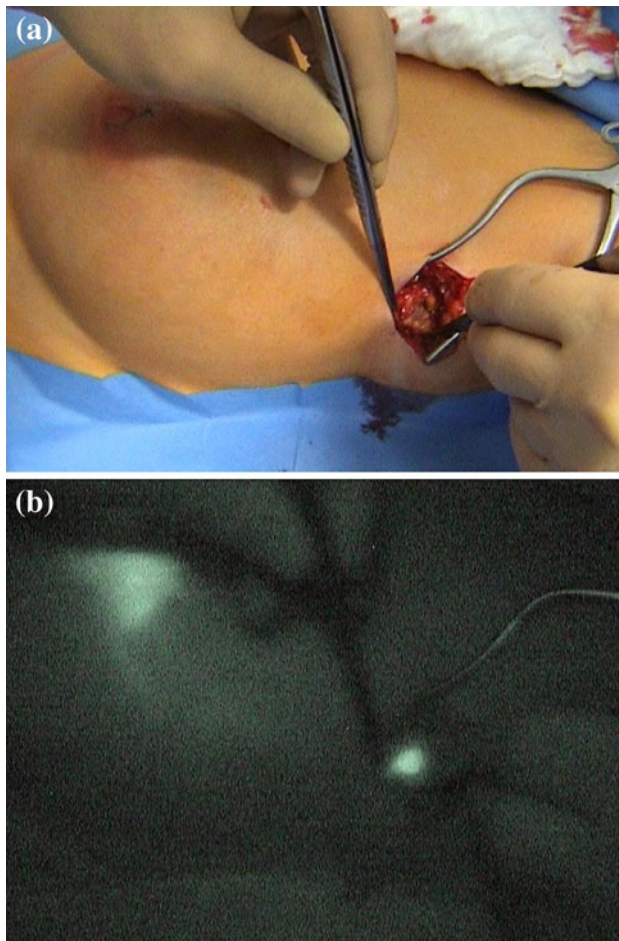
SLN sentinel lymph node, LN lymph node, NSLN non-sentinel lymph node

This study was performed to investigate the clinical feasibility and accuracy of ICG fluorescence imaging for sentinel node detection and biopsy in a series of breast cancer patients. The results confirm that the subareolar injection of ICG can be used safely for lymphatic mapping and SLN biopsy without allergic reactions or local toxicity. The detection rate of 98% for the SLN in 43 patients was comparable to that of the standard technique using a combination of radioisotope scanning and blue dye staining. Detection rate (97.7%), sensitivity (94.4%), and false-negative rate (5.6%) in this study were also similar to that reported for the combined method with a detection rate approximating 95% [3, 28].

The accuracy of ICG imaging was not due to an increased number of analyzed SLNs. In average, only 2.0 SLNs per patient were excised. In fact, it seems that the improved results with ICG must be attributed primarily to the advantages of fluorescence detection. In general, SLNs were not stained green after the injection of less than 20 mg ICG although they showed a bright fluorescence signal. Motomura et al. [29] used ICG as a dye-guided method without fluorescence detection in a large group of women with breast cancer ( $n = 172$ ) and obtained a detection rate of less than 75%.

One major advantage of fluorescence imaging is that it allows transcutaneous real-time lymphography for intraoperative identification of the SLN. In this study, lymphatic channels guiding to the SLN were successfully displayed in 38 of 43 patients (Fig. 1). Hama et al. [30] showed two-color in vivo spectral fluorescence lymphangiography to provide insight into drainage from different lymphatic basins and to influence dissection strategies. Kitai et al. [20] injected 25 mg ICG for imaging of subcutaneous lymphatic channels by fluorescence navigation in 18 women with breast cancer and achieved a detection rate of 94%. In another study involving 37 patients, one or two lymphatic pathways could be observed ICG scanning in 73% of the cases [19]. The relatively low rate of lymphatic visualization in this study may be explained by interference with blue dye that was applied together with ICG. In a feasibility study, Tagaya et al. [26] analyzed 25 patients with fluorescent and blue dye and showed detection of lymphatic vessels in all cases (Fig. 2).

In the present series, the SLN was the only positive lymph node in 12 of 23 nodal positive patients, including 7 patients with conventional positive lymph nodes and 5 patients with positive lymph node status by ITC. The remarkably high percentage of solitary positive SLNs (52%) underlines the good sensitivity of the ICG method (Fig. 2). Until now there is no evidence that there might be a specific mechanism for accumulation of ICG in metastatic lymph nodes.



**Fig. 2** SLN biopsy using ICG fluorescence detection. After skin incision at the marked area (a), fluorescence detection is used for identification of the SLN (b)

Immunohistochemical analysis of negative SLNs in 25 patients revealed ITCs in 5 additional cases (20% of conventionally negative and 12% of all patients). Two of those patients underwent secondary ALND without histopathologic evidence for lymph node metastases. None of the other three patients with ITC or negative SLN developed axillary lymph node spread after a mean follow-up of 4.7 years. Other authors identified ITC in approximately 10–15% of the patients [31, 32], but the prognostic significance and optimal management according to stage migration due to ITC remains unclear [33]. Langer et al. [34] revealed 96% of patients with ITC from SLN biopsy undergoing delayed ALND to have specimens free of macro-metastases and without benefit of ALND. SLN ITC-positive patients who did not receive ALND were shown to have a relapse rate between 0 and 3.6% [35–37].

Our experience in 43 women suggests that ICG fluorescence guiding SLN biopsy is safe and effective without need for extended tissue dissection and comparable expenses. This new method allows transcutaneous visualization of

lymphatic channels as well as intraoperative orientation during tissue dissection with a maximum duration of 30 min for SLN identification without loss of fluorescence. The data presented in this study must be interpreted with caution because of the limited number of patients. Furthermore, ICG fluorescence imaging was not compared with the more established approach (radiocolloid and blue dye). The rationale was to avoid any interference between the dyes.

One drawback of the method used here is that the light in the operating room must be dimmed to improve the sensitivity of the camera. In the meantime, there is a new system available that can be used under daylight conditions. The results of this study confirm the preliminary data from feasibility studies on lymphatic mapping and sentinel node biopsy with ICG, demonstrating the clinical practicability of the method and justify further studies with large number of patients. In future studies, ICG should be directly compared with radiocolloid and other more established dyes to find out whether there is a concordance or discordance between the methods.

**Acknowledgment** This study was supported by grants from the Charite-Universitaetsmedizin Berlin, Germany.

## References

1. Bonnema J, van de Velde CJ (2002) Sentinel lymph node biopsy in breast cancer. *Ann Oncol* 13:1531–1537
2. Zavagno G, De Salvo GL, Scalco G et al (2008) A Randomized clinical trial on sentinel lymph node biopsy versus axillary lymph node dissection in breast cancer: results of the Sentinella/GIVOM trial. *Ann Surg* 247:207–213
3. Cox CE, Pendas S, Cox JM et al (1998) Guidelines for sentinel node biopsy and lymphatic mapping of patients with breast cancer. *Ann Surg* 227:645–651
4. Langer I, Guller U, Hsu-Schmitz SF et al (2009) Sentinel lymph node biopsy is associated with improved survival compared to level I & II axillary lymph node dissection in node negative breast cancer patients. *Eur J Surg Oncol* 35(8):805–813
5. Giuliano AE, Jones RC, Brennan M, Statman R (1997) Sentinel lymphadenectomy in breast cancer. *J Clin Oncol* 15:2345–2350
6. Liberman L (2000) Pathologic analysis of sentinel lymph nodes in breast carcinoma. *Cancer* 88:971–977
7. Maaskant AJ, van de Poll-Franse LV, Voogd AC et al (2009) Stage migration due to introduction of the sentinel node procedure: a population-based study. *Breast Cancer Res Treat* 113:173–179
8. Fleissig A, Fallowfield LJ, Langridge CI et al (2006) Post-operative arm morbidity and quality of life. Results of the ALMA-NAC randomised trial comparing sentinel node biopsy with standard axillary treatment in the management of patients with early breast cancer. *Breast Cancer Res Treat* 95:279–293
9. Sardi A, Spiegler E, Colandrea J et al (2002) The benefit of using two techniques for sentinel lymph node mapping in breast cancer. *Am Surg* 68:24–28
10. Upponi SS, McIntosh SA, Wishart GC et al (2002) Sentinel lymph node biopsy in breast cancer—is lymphoscintigraphy really necessary? *Eur J Surg Oncol* 28:479–480
11. Dauphine CE, Khalkhali I, Vargas MP et al (2006) Intraoperative injection of technetium-99 m sulfur colloid is effective in the

- detection of sentinel lymph nodes in breast cancer. *Am J Surg* 192:423–426
12. Stratmann SL, McCarty TM, Kuhn JA (1999) Radiation safety with breast sentinel node biopsy. *Am J Surg* 178:454–457
  13. Rutgers EJ (2005) Guidelines to assure quality in breast cancer surgery. *Eur J Surg Oncol* 31:568–576
  14. Aydogan F, Celik V, Uras C et al (2008) A comparison of the adverse reactions associated with isosulfan blue versus methylene blue dye in sentinel lymph node biopsy for breast cancer. *Am J Surg* 195:277–278
  15. Raut CP, Hunt KK, Akins JS et al (2005) Incidence of anaphylactoid reactions to isosulfan blue dye during breast carcinoma lymphatic mapping in patients treated with preoperative prophylaxis: results of a surgical prospective clinical practice protocol. *Cancer* 104:692–699
  16. Wilke LG, McCall LM, Posther KE et al (2006) Surgical complications associated with sentinel lymph node biopsy: results from a prospective international cooperative group trial. *Ann Surg Oncol* 13:491–500
  17. Cox CE, Bass SS, Reintgen DS (1999) Techniques for lymphatic mapping in breast carcinoma. *Surg Oncol Clin North Am* 8: 447–468
  18. Sandrucci S, Casalegno PS, Percivale P et al (1999) Sentinel lymph node mapping and biopsy for breast cancer: a review of the literature relative to 4791 procedures. *Tumori* 85:425–434
  19. Ogasawara Y, Ikeda H, Takahashi M et al (2008) Evaluation of breast lymphatic pathways with indocyanine green fluorescence imaging in patients with breast cancer. *World J Surg* 32(9): 1924–1929
  20. Kitai T, Inomoto T, Miwa M, Shikayama T (2005) Fluorescence navigation with indocyanine green for detecting sentinel lymph nodes in breast cancer. *Breast Cancer* 12:211–215
  21. Meyer JS (1998) Sentinel lymph node biopsy: strategies for pathologic examination of the specimen. *J Surg Oncol* 69: 212–218
  22. Carter CL, Allen C, Henson DE (1989) Relation of tumor size, lymph node status, and survival in 24,740 breast cancer cases. *Cancer* 63:181–187
  23. Layeequr RR, Siegel E, Boneti C et al (2009) Stage migration with sentinel node biopsy in breast cancer. *Am J Surg* 197: 491–496
  24. McIntosh SA, Ravichandran D, Balan KK (2001) Sentinel lymph node biopsy in impalpable breast cancer. *Breast* 10:82–83
  25. Woznick A, Franco M, Bendick P, Benitez PR (2006) Sentinel lymph node dissection for breast cancer: how many nodes are enough and which technique is optimal? *Am J Surg* 191:330–333
  26. Tagaya N, Yamazaki R, Nakagawa A et al (2008) Intraoperative identification of sentinel lymph nodes by near-infrared fluorescence imaging in patients with breast cancer. *Am J Surg* 195: 850–853
  27. Murawa D, Hirche C, Dresel S, Hunerbein M (2009) Sentinel lymph node biopsy in breast cancer guided by indocyanine green fluorescence. *Br J Surg* 96:1289–1294
  28. Tafra L, Lannin DR, Swanson MS et al (2001) Multicenter trial of sentinel node biopsy for breast cancer using both technetium sulfur colloid and isosulfan blue dye. *Ann Surg* 233:51–59
  29. Motomura K, Inaji H, Komoike Y et al (1999) Sentinel node biopsy guided by indocyanine green dye in breast cancer patients. *Jpn J Clin Oncol* 29:604–607
  30. Hama Y, Koyama Y, Urano Y et al (2007) Simultaneous two-color spectral fluorescence lymphangiography with near infrared quantum dots to map two lymphatic flows from the breast and the upper extremity. *Breast Cancer Res Treat* 103:23–28
  31. Cserni G, Bianchi S, Vezzosi V (2008) Variations in sentinel node isolated tumour cells/micrometastasis and non-sentinel node involvement rates according to different interpretations of the TNM definitions. *Eur J Cancer* 44:2185–2191
  32. Stitzenberg KB, Calvo BF, Iacocca MV et al (2002) Cytokeratin immunohistochemical validation of the sentinel node hypothesis in patients with breast cancer. *Am J Clin Pathol* 117:729–737
  33. Patani N, Mokbel K (2009) The clinical significance of sentinel lymph node micrometastasis in breast cancer. *Breast Cancer Res Treat* 114:393–402
  34. Langer I, Guller U, Berclaz G et al (2009) Accuracy of frozen section of sentinel lymph nodes: a prospective analysis of 659 breast cancer patients of the Swiss multicenter study. *Breast Cancer Res Treat* 113:129–136
  35. Chung MA, Steinhoff MM, Cady B (2002) Clinical axillary recurrence in breast cancer patients after a negative sentinel node biopsy. *Am J Surg* 184:310–314
  36. Bergkvist L, de Boniface J, Jonsson PE et al (2008) Axillary recurrence rate after negative sentinel node biopsy in breast cancer: three-year follow-up of the Swedish Multicenter Cohort Study. *Ann Surg* 247:150–156
  37. Langer I, Marti WR, Guller U et al (2005) Axillary recurrence rate in breast cancer patients with negative sentinel lymph node (SLN) or SLN micrometastases: prospective analysis of 150 patients after SLN biopsy. *Ann Surg* 241:152–158