

Micro-incision Cataract Surgery (MICS) and MICS lenses

INSTRUCTIONAL COURSE

COURSE DIRECTOR:

Jorge L. Alió, Spain

CO-DIRECTOR:

Howard Fine, USA

COURSE PARTICIPANTS:

Amar Agarwal, India

Burkhard Dick, Germany

Thierry Amzallag, France

Mark Packer, USA

Roberto Bellucci, Italy

ESCRS, VIENNA, 2011

Course outline

1. Fundamentals and key factors in performing a successful MICS transition:
Jorge Alio
2. How to manage fluidics in MICS
Mark Packer
3. Power modulation and use of IOL through the corneal tunnel assisted technique in MICS:
Thierry Amzallag
4. MICS IOLs:
Burkhard Dick
5. Why MICS is better: Pearls of the surgical technique.
Roberto Bellucci
6. Biaxial MICS for difficult and challenging cases:
Howard Fine
7. MICS at the limit: 0.7mm MICS and MICS in special cases:
Amar Agarwal
8. Adjourn: My perspective in the evolution of modern cataract surgery
Howard Fine

1. The modern evolution of cataract surgery

Cataract surgery is one of the most frequently performed surgeries and millions of the eyes are operated each year in the entire world. The first modern cataract surgery was done by Sir Harold Ridley in 1949 with the implantation of the first PMMA intraocular lens. The incision was longer than 10 mm, the intraocular lens was not perfect, and surgery was complicated.

The spectacular progress of the cataract surgery technique led to diminish the surgical trauma and percentage of the complications connected to the manoeuvres and energy delivered into the eye in the 80 and 90 of the XX century. The technical progress made possible to think about diminishing the incision size. The idea to make the cataract surgery bimanually without phaco-tip sleeve was started in the end of the '80. This method was described by Shearing in 1985. But the idea of diversification of the liquid was the main step to develop new surgical techniques, new surgical tools and new surgical possibilities.

Better visual outcome, aggressiveness surgery, separated infusion; minimal phaco power, new surgical tools, and fluidics management evoke new idea of surgery – MICS – Micro Incision Cataract Surgery

In 2001 Jorge Alio registered the concept of Microincisional Cataract Surgery (MICS) as the surgery performed through incisions of 1.8 mm or less. Understanding this global concept implies that it is not only about achieving a smaller incision size but also about making a global transformation of the surgical procedure towards minimal aggressiveness. The name of this cataract surgery was originally given in Spain. The patent name registration concerns only the name of the surgery and does not have any commercial value in Europe.[3]

Separated fluidics high volume of the liquids and high vacuum become in the new tool. Especially in the case of the soft cataracts LOCS 1 or 2 the use of the ultrasound can be diminished or practically eliminated. The high vacuum and infusion chopper use permits the masses breaking and aspirating without US power. The phacoemulsification of the harder grade of the cataract needs to be supported by minimal doses of the US energy. Nowadays the small doses of the ultrasound power and MICS concept can eliminate the phaco-tip overheating and the thermal injury of the cornea. These ideas diminish surgical trauma and improve cataract surgery refractive result.

The complications with MICS can occur during learning curve. Transition to MICS needs to understand the principles of MICS ideas and technique. In the first time of transition the problems with fluidics, anterior chamber stability and wound integrity can occur. [1, 2]

2. Main concepts in MICS

2.1 Incision

Diminishing of incision is the most interesting and important parameter of the modern surgery. Following the minimization idea smaller incision means lower wound dimension, less eye traumatism and faster healing.

Small wound construction satisfies the principles of the self sealing incision. The wound closing is more efficient and the leakage is not observed in short period of postoperative time. The watertight construction of the wound diminishes the iris prolapses complications. Faster wound healing reduces possibility of the bacterial infection. The reduction of the SIA by the small incision becomes more important advantage in the field of cataract and refractive lens surgery.[3]

Reduction of the cataract surgery incision leads to:

- corneal tissue damage reduction
- faster recovery of the wound
- higher stability of the eye during surgery
- easier capsulorhexis, hydrodissection performance
- diminishing of the postoperative complications
 - a. wound leakage
 - b. risk of endophthalmitis
 - c. SIA
- improves optical quality of the cornea

The idea of the small incision leads to progress in the instruments adaptation, machine construction, software programming. The small incision demand new technology of the foldable lenses. In the future probably it will make the incision smaller.[2, 3, 4]

2.2 Fluidics

The fluid management is essential in MICS. The proper setup of machine with the balanced values protects the eye and helps the surgeon to pass through the all stages of the surgery without complications.

The fluid inflow should be balanced by outflow, but the balance should be corrected based on the sufficient eye ball tension. The forced pressure of the infusion should make the infusion larger than the outflow of the liquid. This difference between inflow and outflow keeps the proper anatomy of the anterior segment of the eye and become the powerful tool in the breaking of the cataract masses and this is an essential point in learning process of the MICS. High under pressure in the phaco aspiration tip and high pressure of the irrigating fluid can break the masses without using of ultrasound power during the occlusion. This excess of the irrigating fluid fluidics become powerful tool in the process of the surgery. MICS fluidics is more efficient than in the micro coaxial surgery. The gas forced infusion (GFI) support is obligatory in the MICS surgery. The continuous flow of the infusion liquid is supported by the gas which is delivered with the pressure to the infusion bottle. The GFI helps to stabilize and maintain the inflow of the liquid on the high level. This keeps the anterior chamber constant and permits to cool the tip. It equilibrates the – IOP during the whole surgery. It is very important to keep IOP stable in the case of sever retinal degenerations, PVR, neovascularizations, vascular diseases. Deregulation of the pressure can lead to AC collapse and intrasurgical hypotony of the eye like in the standard coaxial phacoemulsification.

Some of the platforms such Accurus or Millennium are supported by internal pump. Infinity platform needs to be supported by external air pump connected with the air filter.

Other fluid problem is the postocclusion time and problems connected to the high vacuum and insufficient inflow. This dangerous circumstance can happen when occluded mass is aspirated suddenly by the tip and the pressure of the AC suddenly decreases. Some phaco machines have software to prevent the surge. AMO Sovereign has virtual model of AC and in the moment of occlusion the pump decrease the vacuum. The use of the Flow Restrictors can also solve the problem. The restrictor can be connected to the aspiration tube. Small filters restrict the flow and surge does not exceed the limit values. The possibility of the AC collapse and rupture of the posterior capsule is practically eliminated. (Fig 1)[5]

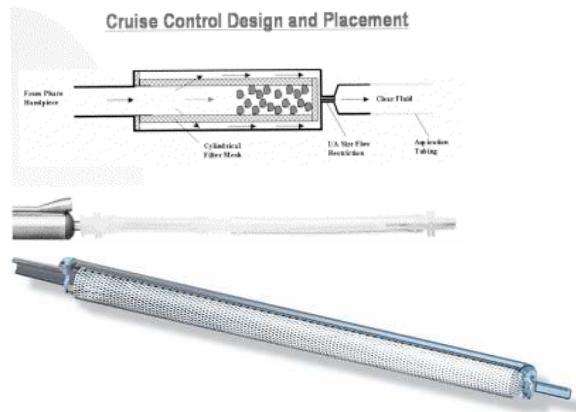


Fig. 1 Cruise Control™ System (STAAR Surgical Company Monrovia, CA USA) and Stable Chamber System (Bausch & Lomb Company Rochester, NY, USA)

2.3 Power modulation

Varying the power modulation during phacoemulsification can be save and efficient method to improve the efficacy of cataract surgery. Pulsing ultrasound can dramatically diminish energy delivered into the eye. Changing on, off - times and shortening the time of pulse you can achieve better result in cataract mass emulsification and corneal wound and endothelial cell protection. It is very important that very short power modulation like hyper pulse and ultra pulse can dramatically decrease possibility of wound burn during MICS surgery. During the on-time cycle the cornea is heating but during the off-time cycle phaco-tip and cornea are cooling. Also short pulse energy seems to be more effective because it produces more cavitation energy than continuous power. The use of torsional phaco can additionally diminish the delivered energy. With use of torsional phaco practically we can eliminate the longitudinal ultrasound power or use it only in minimal way with the hard cataract. The active use of power modulation seems to change MICS to more efficient surgery.[5, 6]

2.4 MICS instruments

MICS is bimanual procedure. Two incisions with the same diameter allow using the same instruments by the both wounds. This advantage is very helpful to clean the anterior and posterior capsule, remove cortical and nuclear fragments. The access to all regions of the anterior segment is ideal. The construction of the instrument permits to perfect manoeuvres and liquid steam direction protects the posterior capsule integrity and endothelium stability.

2.4.1 MICS 18G

To perform MICS surgery we can use two types of the instruments depending on the incision seize preferred by the surgeon. You can use tools for standard MICS (18G instruments) and micro-MICS (22G instruments)
To perform standard MICS 18G surgery we need instruments specially designed for 1.5mm incision. To make incision the calibrated knife is necessary. The Alio's MICS Knife (Katena Inc, Denville, NJ, USA) has trapezoid shape 1.25 mm / 1.4mm / 2.0mm which is necessary to make incision of the desired shape and dimensions. The other opportunity is the diamond knife with the same proportions. (Fig 2, 3)



Fig. 2 Alio's MICS Metal Knife (Katena Inc, Denville, NJ, USA)



Fig. 3 Alio's MICS Diamond Knife (Katena Inc, Denville, NJ, USA)

The shape and dimension of knives permit to make incision which is perfectly adapted to the MICS phaco tip of 0.9mm. The incision is watertight, keep the anterior chamber stable and permit perfectly the manoeuvring in the anterior chamber. The borders of the incision are perfectly adapted to close without suturing. The small amount of the fluid during hydration ascertain in incision closing.

Continuous curvilinear capsulorhexis (CCC) is essential in the each type of the phaco surgery. To make the capsulorhexis through the 1.25mm incision the micro forceps is obligatory. Alio's MICS Capsulorhexis Forceps (Katena Inc, Denville, NJ, USA) is 23G tool. This instrument is perfectly perpetrated to do tearing of the anterior

capsule by the pointed catch which is situated at the end of the forceps. The CCC is easy with this thin and delicate forceps. (Fig 4)



Fig. 4 Alio`s MICS Capsulorhexis Forceps (Katena Inc, Denville, NJ, USA)

During each capsulorhexis the maintaining of the stable anterior chamber is essentially. The disproportion between incision and tool can make conduct to the OVD leakage during the CCC and tearing the capsule outside. With the 1.25mm incision and 23G instrument practically it does not happen.

Hydrodissection and hydrodelineation is the next stage of the surgery which permit separate the lens from the capsule and divide the lens layers. This maneuver can be done by each type of the cannula preferred by surgeon but the washout of the OVD from the AC before is essential. The small incision and high density of the OVD can block the incision and lead to the increase the pressure in the anterior chamber and be dangerous for the stability of the posterior capsule.

Prechopping can facilitate the surgery. This stage of the surgery based on the mechanical division of the lens by the two prechoppers. This simply manoeuver can be done by Alio-Rosen MICS Phaco PreChopper (Katena Inc, Denville, NJ, USA) or by Alio-Scimitar MICS Prechoppers (Katena Inc, Denville, NJ, USA) (Fig 5)




Fig. 5 Alio-Rosen MICS Phaco PreChopper and Alio Scimitar Prechopper Micro Incision Cataract Surgery (Katena Inc, Denville, NJ, USA)

The shape of Scimitar Prechopper is designed to perform and facilitate the 700 microns surgery. Scimitar Prechopper has a curved tip with a blunt end and a sharp

inferior edge. The choppers are crossed by situating symmetrically opposite oneself. Now, cutting movements are being made by gently crossing prechoppers. The cut will be made from the perimeter to the centre of the nuclei. Internal edge has a sharp edge that facilitates the incisions of the lens masses. When the cut is made, two dividing hemispheres are made. The nucleus is then rotated about 90° and then for the second time prechopping is repeated as described.

Next stage of the surgery is phacoemulsification of the cataract lens. MICS permits to do surgery bimanually. One port is for the irrigating chopper and the second is for the aspiration phaco tip without the silicon sleeve. MICS gives opportunity to perform phacoemulsification from both sides, by right and left hand any time at all stage of surgery. It depends on corneal astigmatism, surgeon preferences, intraoperative conditions.

For the standard MICS surgery we use two types of the irrigating choppers: Alio`s original fingernail MICS irrigating hydromanipulator and Alio`s MICS Irrigating Stinger (Katena Inc, Denville, NJ, USA) (Fig 6,7)




Fig. 6 Alio`s original fingernail MICS irrigating hydromanipulator (Katena Inc, Denville, NJ, USA). Not in use now



Fig. 7 Alio`s MICS Irrigating Stinger (Katena Inc, Denville, NJ, USA)

First irrigating hydromanipulator fingernail helps to remove rather soft cataracts.(Fig 6) There is irrigation hole on the bottom lower side of the tool. The hole diameter is 1mm. It has also very thin walls to increase internal diameter of instrument. This irrigation canula is assuring infusion in borders 72 cc/min. A large infusion directed to the bottom assures the excellent flow of liquids and also a fast and effective chilling phacoemulsification tip. An outstanding stability of the anterior chamber is assured through the function infusion and directs the liquid to the lens masses at the bag back, independently from high vacuum sets of phacoemulsification machine. The strength of the stream permits the bag to be held in a safe distance from the phacoemulsification tip and at the same time enables convenient manipulations of tools and lens masses. Additionally, this stream can clean the back bag from remaining cortical cells. A very fertile directed stream to the back bag is provided with the preservation of cells endothelium corneas before mechanical and thermal damage. The irrigation hole can be found situated on the side of the irrigating probe or on top and this can result in the turbulences in the anterior chamber. This effect can damage the endothelium cells and stabilities of the anterior chamber.

The tool which allows the removal of harder cataracts is Alio's MICS Irrigating Stinger. (Fig 7) This tool has a 19G diameter and it is equipped with a tip at the end which is angled downwards. This tool is useful to chop off segments or dividing masses of the nucleus in the phacoemulsification tip.

For removing remains of cortical masses is serving Alio's MICS Aspiration Handpiece (Katena Inc, Denville, NJ, the USA) (Fig. 8)



Fig. 8 Alio's MICS Aspiration Handpiece (Katena Inc, Denville, NJ, USA)

There is a tool especially designed for delicate and safe manipulations within the anterior chamber. It has a diameter of 18G. The cylindrical shape allows this tool to gently manipulate within the surgical wound. At the same time the port diameter of 0.3mm assures the stability of the hydrodynamic of liquid within the anterior chamber. This handpiece allows to remove remained masses from the bag and the full comfort of polishing the bag back.[7]

2.4.2 MICS 22G

The Alio Stinger irrigating chopper Duet System (Redmond, Washington, USA) is the 22G inferior opening instrument. It has one hole on the inferior side of the cannula and provides the infusion stream directly backward, forcing cataract fragments to levitate towards the phaco tip pointed to masses and posterior capsule. This also allows maintaining anterior chamber deep and holding the capsule far from the phaco-tip. The fluid infusion with GFI is sufficient for 0.7mm MICS demand. The end of the Stinger is equipped with a pointed tip which is angled downwards. It enables to break masses with ease and provide them to aspiration hole. (Figure 9)[7]

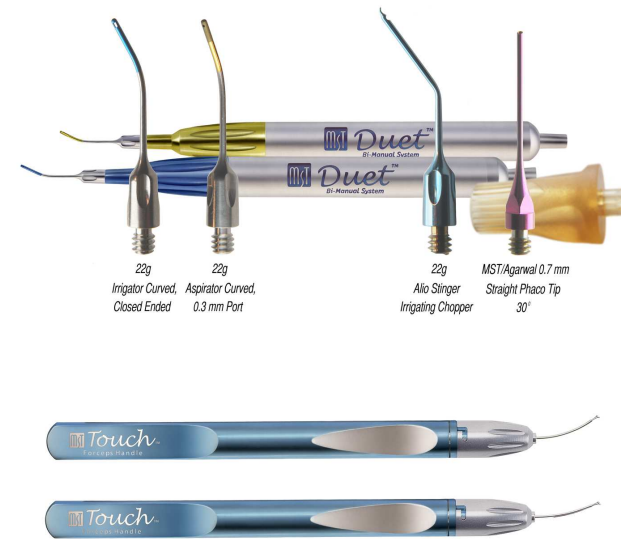


Figure 9. The 0.7mm (22G) Duet® System Alio Stinger Irrigating Chopper

2.5 MICS phacoemulsification platforms

MICS surgery can be made with the help of practically each type of the phaco platforms supported by venturi pump. This type of the pump is very powerful and effective in the vacuum construction. The surgery on venturi pump machine is the high vacuum and constant vacuum surgery. The vacuum about 550mmHg is very easy to achieve in few milliseconds in all of this types of machines. Other types of the pumps like peristaltic are not such effective.

In the case of soft cataracts having the placed under pressure on 500-550mmHg we can only use Alio's MICS hydromanipulator irrigating fingernail. This makes it possible to divide and aspirate fragment masses of the lens without using ultrasound or using ultrasound in the minimum way. The torsional phacoemulsification with the oscillatory, mechanically moving tip can be helpful. Ultrasound energy can be eliminated. The Kelman Tip and Infinity System (Alcon Laboratories, Inc.) equipped with OZil energy are preferred. In the case of hard cataracts, when total occlusion tip is not causing aspiration of masses Stinger -Alio's MICS Irrigating Chopper would be more useful. This handpiece has a narrow edge at the end which divides the masses and allows easy aspiration of the phacoemulsification tip. The fragmented elements of the hard cataracts are now easily aspirated using the high under pressure and in rare moments using of the ultrasound energy. Usually MICS is performed with up to 4% ultrasound power and fewer than 10 seconds of real phacoemulsification time.

Alcon Accurus 600

This device functions very well in MICS. Accurus device has the exerted inflow, high rate of the under pressure, advanced steering pump and fast efficiently in reacting. It cause that this system is very useful for the MICS surgery. In the table we offer settings for cataract grade 3 (LOCS 3) (Tab. 1)

Tab.1 Accurus 600 Alcon settings for 19G MICS

Quad	Phacoemulsification power	20%
	Vaccum	300 mmHg
	Irrigation	90
	Mode burst	30 ms

Alcon Infinity

This is a device with a highly efficient pump and good software which is effective in practice. The torsional phaco is the system which perfectly complement need to diminish the surgical trauma during cataract surgery. This lateral movement system of the phacoemulsification tip practically eliminates the US energy. For infinity most useful settings are shown in Table 2

Tab.2 Infinity Alcon settings for 19G MICS

Chop	Phacoemulsification power	0
	Dynamic rise	0
	Vacuum	150
	Irrigation	110
	Torsional amplitude	Limit 40
		On: 20
		Off: 40
	Aspiration rate	15
Quad	Phacoemulsification power	0
	Dynamic rise	2
	Vacuum	500
	Irrigation	110
	Torsional amplitude	Limit 80

		On: 20
		Off: 40
	Aspiration rate	30
Epi	Phacoemulsification power	0
	Vaccum	28
	Irrigation	110
	Torsional amplitude	Limit 30
		On: 20
		Off: 40
	Aspiration rate	28

Note: For 21 G MICS forced air infusion with air pump is necessary

Bausch&Lomb Millennium

Millennium is also adapted to lead the operation in the MICS mode. This highly efficient device has the software which reduces the power of ultrasound used for a surgery. It has modes: pulse, singles burst, fixed burst, multiple burst. Millennium updated by the mode pulsed, pulse lets for creating the model of cycle 250 milliseconds "on-time". It is a cut which considerable reduces the energy. In Table 3 are shown standard settings for MICS.

Tab.3 Millennium Bausch&Lomb settings for 19G MICS

Sculpture	Bottle height	100 cm
	Maximum bottle infusion	40 mmHg
	Fixed vacuum	200 mmHg
	Fixed U/S	10%
	Duration	20 ms
	Duty cycle	60%
Quadrant	Bottle height	100 cm
	Maximum bottle infusion	40 mmHg
	Fixed vacuum	470 mmHg
	Fixed U/S	10%
	Duration	20 ms

	Duty cycle	60%
I/A	Bottle height	80 cm
	Maximum bottle infusion	40 mmHg
	Maximum vacuum	550 mmHg

Note: For 21 G MICS forced air infusion with air pump is necessary

AMO Sovereign WhiteStar

The WhiteStar device is working well in mode of ultrapulse around 6 milliseconds on and 12 milliseconds off. For this device a height of the bottle is 90 cm, aspiration flow rate 26 ml/min, vacuum for nuclear emulsification 400 mmHg, and for epinucleus 200 mmHg.

2.6 MICS intraocular lenses

MICS cataract surgery develops post operative astigmatism in the minimal way. Up to 80% of MICS patients the corneal astigmatism is less than 0.5D. Only the 25% of coaxial cataract surgery patients have astigmatism less than 0.5D. MICS is the useful method to do a cataract surgery with refractive surgery. MICS caused the foldable lenses evolution and now they can be implanted through 1.5mm incision or less. (Table 4) The lenses should fulfil the high technology. Most of them are made of hydrophilic acrylic biomaterial. But only some of them can be used to MICS incision. Compression during injecting can damage the lens. The lens ruptures can occur. Decompression can also be a matter of damage of the lens. For MICS IOL, it should fulfil the following requirements. The IOL should be implantable through a sub-2.0 mm incision. After unfolding the IOL shouldn't have any structural, mechanical changes or optical alteration or deformation. Haptics of the lens should defend from decantation. The structure of the lens should protect from posterior capsule opacifications (PCO). Some of the lenses can have a problem with PCO but precise cleaning of the capsule can prevent the epithelium proliferation.[8] Lenses shouldn't induce halos, glare, night-vision phenomenon, aberrations or scattering. Microincision IOL are the following:

Table 4. Microincision IOL's

No	Name of the lens	Company
1	Zeiss - Acri.Tec MICS IOL's Family	Zeiss - Acri.Tec, Berlin, Germany
2	Akreos AO Micro Incision MI60	Bausch & Lomb, Rochester, New York, USA
3	IOLtech MICS lens	IOLtech, La Rochelle, France and Carl Zeiss Meditec, Stuttgart, Germany
4	TetraFlex KH-3500 and ZR-1000	Lenstec, St. Petersburg, Florida, USA
5	MicroSlim, Slimflex IOL	PhysIOL, Liège, Belgium
6	CareFlex IOL	W20 Medizintechnik AG, Bruchal, Germany

7	AcriFlex MICS 46CSE IOL	Acrimed GmbH, Berlin, Germany
8	Hoya Y-60H	Hoya Corporation, Tokyo, Yapan
9	Miniflex IOL	Mediphacos Ltda., Minas Gerais, Brasil

Acri.Tec MICS's lenses: You can use Acri.LISA for multifocal implantation. (Fig. 10) For toric implants, and for cases with more than 3.00 D of astigmatism, you can use the toric Acri.Tec IOL, marking the axis of the implantation at the slit-lamp prior to surgery. Acri.Smart 48S and Acri.Smart 46S are the lenses with the optical diameter 5.5 mm i 6 mm. It is biconvex, equiconvex, nonangled lenses with hydrophobic surface. They can be implanted on both sides. Acri.Smart 48S IOLs water content of 25% in its fully hydrated state Acri.Smart lenses are designed with square truncated edges. The edge thickness corresponds to standard designed IOLs and is in the range 0,25-0,27 mm. The lens is made from acrylic material, a copolymer of hydroxyethylmethacrylate and ethoxymethacrylate with an ultraviolet absorber. The optic power of this lens range from 0.00 D to 32.00 D. Acri.Smart glide system with Acri.Glide cartridge is used to implant lens. Acri.Smart 48S are the lenses can be injected through 1.5mm incision or smaller. They are very easy to apply. After injection the lens unfold very quick and with the control. It has no tendency to decentration or to tilt. The adhesion between posterior capsule and lens is perfect.[9] Wehner at al. investigation seems to confirm the stability of the Acri.Smart 46S lens. There was no decentration, rotation of this lens during 19 months observation after MICS surgery. No unwanted complications occurred.[10] Clinical results: 45 eyes with cataract grade 2, 3, 4 (LOCS III) were operated by MICS. The incision size was 1.46 mm (1.4-1.9). After 6 months after operation 98.9% of the patients had BCDVA 20/25 (0.7 decimal value) or better and 71.3% of the patients had distance UCDVA 20/32 (0.6 decimal value) or better. The safety index for distance vision of the procedure was 2.5 and the efficacy index of the procedure was 1.8. 90% of the patients had a near BCNVA of 20/25 (0.8 decimal value). 60% of the patients had a near UCNVA of 20/32 (0.6 decimal value) or better. The mean add for near was +1,5 D or less in 70% of cases and was +2,0 D in 26% of cases. The safety index for near vision of the procedure was 1.4 and the efficacy index of the procedure was 0.9. It can indicate that Acri.Smart has a pseudoaccommodative ability. In this study none of the lenses shoved any change in position, decentration, tilt, PCO. [11]



Fig. 10 Acri.LISA 366D multifocal IOL (Zeiss-Acri.Tec, Berlin, Germany)

Akreos AO MI60 Micro Incision is a hydrophilic acrylic with 26% hydration rate. Optic measures 6mm and has a 360° posterior ridge - barrier to prevent PCO. Haptics geometry consists of 4 point support system, haptics angled at about 10°. Akreos has an aspherical optic. Akreos MI-60 is an aspheric lens, reduce the aberrations and improves contrast sensitivity.

Akreos AO MI60 can be implanted with a 1.8 Viscoglide cartridge and Viscoject Lens Injection System (Medicel AG, Widnau, Switzerland). This type of lenses has no tendency to decentration or PCO. (Fig. 11)



Fig. 11 Akreos AO MI60 Micro Incision (Bausch & Lomb, Rochester, New York, USA)

IOLtech MICS lens (IOLtech, La Rochelle, France; and Carl Zeiss Meditec, Stuttgart, Germany) is biconvex. The total diameter is 12.0mm and the optic diameter is 5.5mm. The angulation is 13° between haptics and optics. This is the hydrophilic acrylic and monobloc lens. This lens has a square edge. The diopters range from +10.5D to +25.5 D. The lens can be implanted with disposable injector and micro incision cartridge. This lens shows pseudoaccommodative effect. (Figure 12)

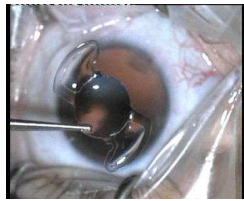

Fig 12 IOLtech MICS lens

Verges at al. (ESCRS congress, Portugal 2005, London 2006) showed data of 48 patients underwent MICS surgery and implantation of IOLtech MICS lens through 1.8 mm incision. After 1 year follow up 92% of the patients reported UCDVA 20/25 and 96% BCDVA more than 20/25. 65% of the patients achieved near visual acuity J3 with distant correction and 98% of the patients J5. Only two patients needed Nd:YAG capsulotomy.

TetraFlex KH-3500 and ZR-1000 (Lenstec, St. Petersburg, Florida, USA) is the accommodating MICS IOL-lens. It is made from hydroxyethylmethacrylate (HEMA), consist of 26% water and a material is highly flexible. The lens is 11.5mm of total length and 5.75-mm optic length with square edges. It is one-piece lens. The lens is available in powers from +5 to +36 D. The TetraFlex KH-3500 uses injector with 1.8-mm cartridge. (Figure13)



Fig 13 TetraFlex KH-3500

Chitkara at the ESCRS Winter Refractive Surgery Meeting 2004 reported the mean accommodation achieved binocularly was 3.42 D. Moreover, 89% of the patients achieved J3 or better unaided binocular near vision at 6 months, and 100% achieved J5 or better.

ZR-1000 is the new one-piece lens from Lenstec. The length of this lens is 11.0mm. The diameter of the optic is 5.5 mm and is made in square edge technology. The optic type is equiconvex and the haptic is plate. The angulation is 0°. This lens is made of 26% water content acrylic. The diopters of lens range from +10.0D to +30.0D. No clinical data is available for this lens.(Figure 14)

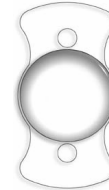

Figure 14 ZR-1000 IOL

MicroSlim and SlimFlex MICS IOL's (PhysIOL, Liège, Belgium) is a hydrophilic acrylic lens with biconvex optics. Optic diameter is 6.15mm, and overall diameter is 10.75mm. The angulation is 5°. The power of the lens range is from +10.0D to +30.0 D. This lens can be injected using Viscoject™ Injector and 1.8 Viscoglide cartridge (Medicel, Widnau, Switzerland). No clinical data is available for this lens.(Figure 15)



Figure 15 MicroSlim IOL

Vryghem at al. presented on Congress of the ESCRS 2006 his experience in SlimFlex IOL implantation through 1.5 mm incision. The group of 50 patients underwent bilateral MICS with lens implantation. After 6 weeks mean BCVA was 1.04. Less than 1 % of the patients complained about halos or glare, and 3 % of lenses resulted in small damage of the optic or haptics. No clinical data is available for this lens.

CareFlex IOL (W20 Medizintechnik AG, Bruchal, Germany) is a 26% hydrophilic acrylate, one-piece lens. Optic size is 5.8 mm, overall length is 10.5 mm and the haptic angulation is 0°. The optic design is a biconvex. The recommended anterior chamber depth is 5.1 mm. The lens is available from +10.0 to +30.0 D. No clinical data is available for this lens.

AcriFlex MICS 46CSE IOL (Acrimed GmbH, Berlin, Germany) is made of 25% acrylic hydrophilic. The superficial is hydrophobic. The lens diameter is 11.0mm and optic diameter is 6.0mm. This is a monobloc type lens with perforated haptics. The

angulation is 0°. The optic is biconvex with sharp edges. The lens is available from +15D to +27D. The clinical data is not available for this lens. (Figure 16)




Figure 16 AcriFlex MICS 46CSE IOL

Hoya Y-60H (Hoya Corporation, Tokyo, Yapan) is a quite new lens for micro surgery. This is hydrophobic foldable lens. The clinical data is not available, but Tsuneoka described possibility of implantation of this lens through 1.7mm incision. He used Hoya F-1 cartridge to inject the lens. [12] (Figure 17)



Figure 17 Hoya Y-60H MICS IOL

Miniflex IOL (Mediphacos Ltda., Minas Gerais, Brasil) is also new MICS surgery lens can be implanted through 1.8mm incision. The material is Flexacryl® Hybrid Acrylic which brings together hydrophobic and hydrophilic monomers. The optics is aberration neutral. The lens can be implanted through 1.8mm incision using a docking technique. The lens was presented on ESCRS 2008 in Berlin by Carlos Verges. (Fig 18)



Figure 18 Miniflex IOL

Finally we can conclude that MICS IOL's is not only the normal classic IOL which is adapted to MICS incision. These lenses are the other type of intraocular IOL. New technique and new idea of the construction lead to create thin and stable MICS IOL with the optical quality as good as standard intraocular IOL's. [8, 13]

MICS IOL characterizes:

- thin optic and haptic
- perfect characteristic of compression
- very good optical quality
- long term stability after implantation

3 MICS outcomes

3.1 Astigmatism Control with MICS

Among the major advantages of MICS the diminution of surgical trauma is resulting in reduction of surgically induced astigmatism (SIA), aberrations and improvement of the optical quality of the cornea after surgery.

Degraded optical quality of the cornea after incisional cataract surgery would limit the performance of the pseudophakic eye. Thus, it is important not to increase or to induce astigmatism and/or corneal aberrations after cataract surgery. Even with MICS, we could achieve reduction of the astigmatism and higher order corneal aberrations.

The optical quality of the cornea plays an important role in recovery of visual function after cataract surgery, and this is determined by combination of corneal and internal aberrations generated by the IOL and those induced by the surgery. These corneal refractive changes are attributed to the location and size of the corneal incision. The smaller incision, lower aberrations means better optical quality.

We have described the improved control on corneal surgically induced astigmatism with MICS when compared to conventional 3 mm phacoemulsification. A great advantage of MICS is the reduction of SIA and that the microincisions do not produce an increase in astigmatism. (Fig 19)

The shorter the incision, the less the corneal astigmatism, as it was estimated that the magnitude of the SIA studied by vector analysis is around 0.44 and 0.88 diopters, rising as the size of the incision increases. This is considered important because cataract surgery today is considered more and more a refractive procedure.

Also, small-incision surgery (3.5-mm incision without suture) does not systematically degrade the optical quality of the anterior corneal surface. However, it introduces changes in some aberrations, especially in no rotationally symmetric terms such as astigmatism, coma, and trefoil. Therefore, one has to expect better results and lesser changes with sub 2 mm incision (MICS). This is supported by the finding that the corneal incision of < 2 mm had no impact on corneal curvature. Going hand in hand with the modern concept of making cataract surgery a refractive procedure, by controlling and even decreasing astigmatism and HOA by using MICS, which is the state of the art. [14] We can say that MICS sub 2mm incision effectively decreases the induction or changes in corneal (HOA) during cataract surgery.




Figure 19 Comparison of MICS and Coaxial vectoral astigmatic change.

3.2 Corneal Aberration with MICS

Nowadays cataract surgery is not only a removal of a opaque lens, but also it is a part of refractive surgery. We can obtain precisely IOL power calculation, we can reduce residual astigmatism and do surgery without SIA and finally improve the corneal optical quality after cataract surgery. The final visual function is determined by the aberrations produced by the implanted intraocular lens and corneal aberrations changed by the postsurgical incisions. The smaller incision means lower aberrations and the better optical quality.[15, 16]

Authors Elkady and Alio in prospective cumulative interventional nonrandomized, noncomparative study of 25 eyes of 25 patients show that after the MICS incision smaller than 1.8mm there was no statistical difference in corneal power, corneal astigmatism before and 3 months of follow up after surgery. [17] The RMS value of the total corneal aberrations decreased slightly after MICS (mean $2.15 \pm 2.51 \mu\text{m}$ preoperatively, $1.87 \pm 1.87 \mu\text{m}$ at 1 month, and $1.96 \pm 2.01 \mu\text{m}$ at 3 months); there was no statistically significant difference between the 2 follow-up visits (both $P=1.00$, Bonferroni). Analysis of individual Zernike terms showed a mean astigmatism of $0.85 \pm 0.74 \mu\text{m}$ preoperatively, $0.65 \pm 0.44 \mu\text{m}$ at 1 month, and $0.69 \pm 0.46 \mu\text{m}$ at 3 months and a mean spherical aberration of $-0.11 \pm 0.25 \mu\text{m}$, $-0.09 \pm 0.25 \mu\text{m}$, and $-0.19 \pm 0.13 \mu\text{m}$, respectively. Coma decreased (mean $0.45 \pm 0.40 \mu\text{m}$ preoperatively, $0.39 \pm 0.36 \mu\text{m}$ at 1 month, and $0.42 \pm 0.44 \mu\text{m}$ at 3 months, respectively); there was no statistically significant difference between the 2 follow-up visits (both $P=1.00$, Bonferroni). The mean HOA was $0.47 \pm 0.26 \mu\text{m}$ preoperatively, $0.59 \pm 0.32 \mu\text{m}$ at 1 month, and $0.54 \pm 0.25 \mu\text{m}$ at 3 months; there was no statistically significant difference between the 2 follow-up visits (both $P>.47$, Bonferroni). Fig 20

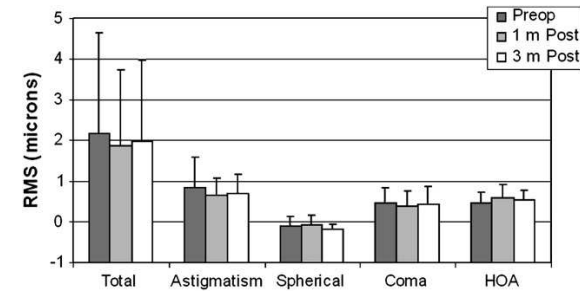


Figure 20. Corneal aberrations (Seidel coefficients) with a 6.0 mm aperture diameter over time (Preop = preoperative; m = month; HOA = higher-order astigmatism).

All aberration values except HOA decreased slightly, with no statistically significant differences between the follow-up visits. All aberration values were stable for 3 months after surgery, indicating that successful MICS depends on preventing induction of HOAs as well as a surgically neutral and stable procedure. Successful MICS gives visual quality equal to that in persons of the same age without pathology and leads to good patient satisfaction.[16, 17]

4 Clinical efficacy of MICS

Advantages of MICS in the field of the refractive result as astigmatism control and aberration neutrality are supported by many papers of the various authors as described above. But we should evaluate the other area of the MICS surgical technique. For each cataract surgeon very important is to compare available surgical techniques in the field of surgical technology and clinical efficacy. Seven years of MICS was an opportunity to evaluate this technique by many authors.

Relatively fast method to compare is evaluation of the surgical machine parameters settings. The Alio et al. comparing study of the MICS and coaxial phacoemulsification shows large difference between amounts of energy delivered into the eye. The EPT of the MICS surgery was more than 4 times lower than in the coaxial group and the astigmatism was almost 3 times lower than in the coaxial group. This means that intraocular injury connected with the phacoemulsification should be lower in the MICS group.[14] Also Kurz at al. indicate in publication important decrease of phacoemulsification time in MICS group comparing to coaxial surgery.[18] The Kahraman study shows decrease of phacoemulsification time in the MICS group comparing to coaxial group ($P=0.001$). [19] Also Tanaka study shows lower ultrasonic output in the bimanual group than in the coaxial group. Tanaka correlates it with better efficiency of nuclear treatment, including nuclear compliance, crushing, and flexor hinge in the case of bimanual procedure.[20] The other studies did not show difference in the total surgery time between MICS and coaxial phaco.[14, 21] The other study described by Crema at al. shows the total US time was lower in the coaxial phacoemulsification group than in the MICS group; the means were $0.50 \text{ minutes} \pm 0.33 \text{ (SD)}$ and $0.82 \pm 0.39 \text{ minutes}$, respectively. The mean US power was similar between groups (mean $10.1\% \pm 3.76\%$ and $10.0\% \pm 4.0\%$, respectively).[22] Nowadays we can compare also MICS and Micro-coaxial phaco. Cavallini study of

MICS shows shorter total surgery time ($P=0.04$) and lower BSS consumption ($P=0.004$) of the MICS group.[23]

The phacoemulsification process always affect on the corneal endothelial cells. Wilczynski at al. comparison study of the endothelial cell density shows that there is no difference in the MICS group and Micro Coaxial group in the lost of the endothelium.[24] Also Kahraman at al. study evaluates the endothelial cell loss in the MICS and Coaxial group but the results shows the minimal difference between both groups. There were no statistically significant differences between preoperative and postoperative anterior chamber flare or endothelial cell loss. [19] No significant differences in corneal endothelial cell loss or endothelial morphology were found between MICS and standard incision techniques in the Mencucci at al study [21] Morphology of the cells was not different in the MICS and coaxial group in the study of Mencucci or Kahraman [19, 21] The comparative study of the Crema at al. indicates lower cell lost in the coaxial group. The mean central corneal endothelial cell loss at 3 months was 4.66% +/- 6.10% in the coaxial phacoemulsification group and 4.45% +/- 5.06% in the MICS group and at 1 year, 6.00% +/- 6.72% and 8.82% +/- 7.39%, respectively. Postoperative inflammation in the anterior chamber evaluated by laser flare photometry was the same in MICS and coaxial groups in various studies [14, 18, 19] Also Wylegala et al. in the article about corneal thickness after coaxial phacoemulsification or MICS indicate the difference in the post surgery corneal oedema. Microincision cataract surgery reduces risk of corneal edema when comparing to standard coaxial phacoemulsification. [25]

The wound integrity and the self selling properties of the MICS and coaxial incisions are currently one of the most important agents in the endophthalmitis prophylaxis.

Irreversible changes may affect the cornea. Every incision of the cornea evokes the change of corneal curvature. The study of Kaufmann at al. confirms that MICS incision offers astigmatic neutrality in the cataract surgery, it supports the idea of MICS as the refractive procedure [26] In our study we proved that MICS and microphaco provided similarly good incision quality and optically neutral incisions. The MICS incision respected corneal prolateness more, with less corneal oedema in the short term and less induced corneal aberrations in the long term.[27] In the other studies, Tong at al. support the perfect MICS optical result. Cataract surgery-related changes in corneal wavefront aberrations were dependent on incision size. The MICS technique had advantages over the SICS technique in minimizing the destructive effect of the large incision size on the optical quality of the cornea.[15, 28] Denoyer at al compared MICS with conventional coaxial surgery. This study shows that MICS could improve the optical performances of the pseudophakic eye reducing in 3 months surgically induced corneal higher-order aberrations. The postoperative root mean square of 3rd to 6th was lower in MICS group $0.705 \pm 0.285 \mu\text{m}$ vs $0.956 \pm 0.236 \mu\text{m}$ in coaxial group and it was significantly different ($P<0.001$) and the root mean square for the 3rd to 6th order ocular aberration was lower in MICS $0.308 \pm 0.122 \mu\text{m}$ vs coaxial group $0.488 \pm 0.172 \mu\text{m}$ with significant difference ($P=0.002$). [29] The latest publication of Saeed et al. show the smooth but significant difference between MICS and standard coaxial phacoemulsification in terms of uncorrected visual acuity recorded 1 h and 2 weeks postoperatively. Nine eyes (18%) and one eye (2%) achieved a UCVA of C6/12 at 1 h following MICS and CAP, respectively, and this difference was statistically significant ($P = 0.02$). The authors conclude that mean UCVA at 1 h and at 2 weeks following cataract surgery was not significantly different between eyes undergoing MICS and CAP. However, a greater proportion of patients achieved a UCVA of C6/12 following

MICS when compared with CAP.[30] Astigmatic neutrality in biaxial microincision cataract surgery confirm Kaufmann et al. article. His investigation comparing keratometry of the surgical and non surgical eye shows the astigmatic neutrality of the sub 2mm cataract surgery. The difference between groups was not statistically significant.[31] Wilczynski et al. article also confirm this results.[32]

Combining MICS and Limbal Relaxing Incisions (LRI) cataract surgery can achieve superior refractive result. Ouchi et al. compares results of MICS and LRI-MICS groups. Statistically significant difference between both groups in UCVA is not surprising, but conclusion is very important. Limbal relaxing incision with bimanual MICS is an easy-to-follow combined surgery to correct pre-existing astigmatism with predictable accuracy. It confirms that MICS is SIA-neutral procedure.[33]

Quality of vision also depends on the quality of the lens implanted in the eye. Greater compression of the lens in the cartridge was a challenge for the MICS lens. But the results of comparative studies of standard lenses and MICS lenses were exceptionally good for MICS lens. There is no single method of assessing the surgical safety. We can only take into account data from the publication but also important is the opinion of surgeons. Most of them are very satisfy because of stable intraocular environment during lens removal especially in patients with high miopia, who are the greater risk of RD after lens extraction [34]. Practically MICS surgery can be performed under the stable anatomical conditions with the permanent use of the irrigating chopper.[38] We can conclude as Muller et al in the article about MICS, the advantages of MICS are less corneal astigmatism and fewer corneal surface irregularities, with favourable implications for visual quality and early rehabilitation. In the effort toward smaller incisions, special interest should be given to wound integrity, especially regarding the risk of endophthalmitis but tissue laceration can occur and smaller incisions are superior only if they cause less trauma.[35, 36] However bimanual MICS seems to be superior over the other surgical techniques because of the better refractive result, better fluidics, greater manual control and lower surgical time. [37] We have found this technique to be simple and safe.

2. Conclusion

MICS is a well established surgical technique for cataract removal. MICS offers distinctive advantages in terms of eliminating surgically induced astigmatism and reducing the changes in the aberration pattern of the cornea to the minimum. MICS is the technique that best matches the concept of premium IOLs, as the control and correction of astigmatism and corneal aberrations seems to be mandatory at this moment in modern cataract surgery. Proven evidence exists to state that MICS is the best surgical option today for cataract removal, both biaxial and coaxial sub 2 mm incision. MicroMICS (sub 1 mm surgery) is a feasible surgery, with the same standards and advantages of MICS, but IOL technology should be further developed in order to use these sub 1 mm incisions for IOL implantation, something not feasible today. Future evolution on IOL technology and new surgical tools will make MICS the gold standard of cataract surgery, as biaxial technique, separating irrigation and aspiration functions, once new energies allow the nucleus to be softened and the cataract to be aspirated injecting a lens refilling substance. Biaxiality and sub 1 mm, even punctual surgery, are pending further development in the coming years.

Tactics for Minimally Invasive Cataract Surgery: Practical tips

How to perform it, which instruments to use, and how to use the phaco pump.

By Jorge L. Alio, MD, PhD

The term *microincisional cataract surgery* (MICS) was coined and registered by me in 2001 to define lens and cataract surgery performed through incisions of 1.8 mm or less. Those who truly understand this concept realize that MICS is not only about a smaller incision size; rather, it implies a global transformation toward minimally aggressive cataract surgery.

Separated fluidics for irrigation and aspiration and high vacuum with pressurized inflow of fluid are necessary for MICS. Especially in the case of soft cataracts (grades 2 or 3), the use of ultrasound can be decreased or practically eliminated, as high vacuum and infusion permit lens material to be smashed and aspirated without ultrasound power. Removal of harder cataracts must be supported with minimal doses of ultrasound energy; however, these smaller doses reduce the risk of overheating at the phaco tip and prevent thermal injury to the cornea compared with conventional cataract surgery.

THE TRANSITION TO MICS

Because complications can occur during the learning curve, transition to MICS must begin with an understanding of its basic principles, including incision creation, fluidics, power modulation, and instrumentation.¹ Grasping these concepts will increase the surgeon's chances of maintaining anterior chamber stability and wound integrity.

Incision. The smaller incision sizes used in MICS decrease the dimensions of the wound, create less eye trauma, and promote faster healing, the latter of which reduces the risk of bacterial infection. Moreover, watertight wound construction decreases the likelihood of iris prolapse, and the absence of surgically induced astigmatism allows better control of the refractive outcome.^{2,3} Among the requirements of minimally invasive incisions are special surgical instruments and foldable IOLs, both of which are discussed in detail below.

Fluidics. Fluid management is essential in MICS, and the proper phaco pump set-up is one that helps the surgeon implement the stages of surgery without complications. Fluid inflow should be balanced by outflow, and this balance can be maintained by controlled pressurized infusion. Some MICS platforms, such as the Stellaris (Bausch + Lomb, Rochester, New York), are supported by an internal pump that creates pressurized infusion. The goal should be to maintain an infusion of fluid greater than the outflow, because this difference preserves the anatomy of the anterior segment and acts as a powerful tool to break up the cataract. During occlusion, high pressure in the aspiration tip can fracture the masses without the need for ultrasound power. Pressure dysregulation can lead to anterior chamber collapse and intraoperative hypotony, as are seen with standard coaxial phacoemulsification.

Postocclusion surge can occur when the occluded mass is aspirated suddenly, causing the pressure in the anterior chamber to drop quickly. Some of today's phaco machines include software that prevents surge, such as the Sovereign (Abbott Medical Optics Inc., Santa Ana, California), which uses a virtual anterior chamber to decrease vacuum at the

precise moment of occlusion. Another strategy is to use a flow restrictor, which is connected to the aspiration tube to control inflow, such as the Cruise Control System (STAAR Surgical, Monrovia, California) or the Stable Chamber System (Bausch + Lomb). These small filters restrict the flow so that surge does not exceed the limit values (Figure 1).⁴

Power modulation. Varying the power modulation during phacoemulsification improves the efficacy of cataract surgery.⁵ Strategies include pulsing ultrasound, which can dramatically diminish energy delivery into the eye, and varying on-off times and shortening pulse duration, which help achieve emulsification while protecting the corneal wound and endothelial cells. Very short power modulation techniques such as hyper pulse and ultra pulse dramatically decrease the potential for wound burn during MICS because heat penetrates the cornea during the on-time cycle but decreases during the off-time cycle, cooling the phaco tip and cornea. Additionally, short pulse energy may be more effective because it produces more cavitation energy than continuous power.

MICS INSTRUMENTATION

In my hands, MICS is performed with a bimanual technique. I create two incisions of equal length, allowing me to use the same instruments in either wound and providing me with complete access to the anterior chamber. Having two microincisions is helpful during anterior and posterior capsular polishing and cortical and nuclear fragment removal. Instrumentation is available for standard bimanual MICS (19 gauge) and bimanual micro-MICS (22 gauge).

MICS 19-gauge. Instrumentation for 19-gauge MICS must fit through a 1.5-mm incision. The first necessity is the appropriate calibrated knife, and I prefer the trapezoidal Alió MICS Knife (Katena Inc., Denville, New Jersey). An alternative instrument is a diamond knife with the same proportions (Figures 2 and 3).

Regardless of the phaco technique used, a continuous curvilinear capsulorrhexis (CCC) is essential. When targeting CCC creation through a 1.25-mm incision, the use of microforceps is obligatory. I use the pointed catch of the 23-gauge Alio MICS Capsulorrhexis Forceps (Katena Inc.; Figure 4) to create the tear in the anterior capsule. Following the CCC and hydrodissection and hydrodelineation, I perform prechopping with either the Alió-Rosen MICS Phaco Prechopper (Katena Inc.; Figure 5A) or the Alió-Scimitar MICS Prechopper (Katena Inc.; Figure 5B). The shape of the Scimitar Prechopper, with its curved tip, blunt end, and sharp inferior edge, is designed to facilitate 700- μ m surgery. The choppers are crossed by situating each one symmetrically opposite to the other, and cutting movements are made from the perimeter to the center of the nucleus. After creating two hemispheres, I rotate the nucleus approximately 90° and repeat the process. In the near future, femtosecond laser technology for cataract surgery will facilitate the prechopping process.

Bimanual phacoemulsification is performed with the irrigating chopper in one incision and the sleeveless phaco tip in the other, depending on the location of corneal astigmatism, surgeon preferences, and intraoperative conditions. For standard bimanual MICS in softer cataracts, I use the Alio MICS Irrigating Stinger (Katena Inc.; Figures 6 and 7). The 1-mm irrigation hole is located on the bottom lower side of the tool, but its very thin walls increase the internal diameter and achieve an infusion rate of 72 cc/min.

Infusion is directed toward the bottom of the device to assure excellent flow and to chill the phaco tip. When infusion is used to direct the liquid toward the lens masses at the back of the bag, anterior chamber stability is maintained independent of high vacuum settings. The strength of the stream keeps the capsular bag at a safe distance from the phaco tip and eases the manipulation of tools and lens masses. The remaining cortical cells are removed with the MICS Aspiration Handpiece (Katena Inc.; Figure 8).

MICS 22-gauge. The 22-gauge (0.7 mm) Alió Stinger irrigating chopper Duet System (Redmond, Washington) has one hole on the inferior side of the cannula that focuses the infusion stream posteriorly, forcing cataract fragments to levitate toward the phaco tip. This design helps to keep the anterior chamber deep and to keep the capsule far from the phaco tip. When using 0.7-mm instruments, 100 mm Hg pressurized infusion is mandatory. The pointed tip of the Stinger is angled downward (Figure 9).¹⁹

IMPROVED SURGICAL OUTCOMES

MICS improves postoperative refractive results, as surgically induced astigmatism and optical aberrations are better controlled with a smaller incision size.¹⁻⁴ Additionally, MICS techniques decrease effective phaco time and mean phaco power across all cataract grades.

Today's biggest limitation to widespread use of MICS is the small selection of IOLs that fit through microincisions (38); however, recent availability of select microincision premium IOLs has stimulated the popularity of MICS. This technique is essential for premium lenses because it allows precise control and correction of astigmatism as well as accurate manipulation of total eye aberrations.^{3,6-8}

MICS, whether biaxial or coaxial, is the best surgical option today for cataract removal. Micro-MICS (through incisions of less than 1 mm) may be feasible in the future, but for this to happen IOL technology must be further developed. The continued evolution of laser cataract surgery and IOL technology will make MICS the gold standard of cataract surgery in the immediate future.

Jorge L. Alió, MD, PhD, is a Professor and the Chairman of Ophthalmology at the Miguel Hernandez University, Alicante, Spain, and the Medical Director of Vissum Corp., Spain. Professor Alió states that he is a paid consultant to Topcon, Oculentis, and Carl Zeiss Meditec and has a royalty agreement with Hanita. He may be reached at tel: +34 96 515 00 25; e-mail: jlalio@vissum.com.

References:

1. Alió J.L., Klonowski P., Rodriguez-Prats J.L., El Kady B. Microincisional Cataract Surgery (MICS) In Garg A. et al. (eds) Mastering the Techniques of Advanced Phaco Surgery. Jaypee, 2008:121-136

2. Alió J.L., Klonowski P., El Kady B. Micro incisional lens surgery In Kohnen T., Koch D.D. (eds) Essentials in Ophthalmology. Cataract and Refractive Surgery. Springer. 2009: 11-24

3. Alió J.L., Rodriguez-Prats J.L., Galal A. Micro-incision cataract surgery. Highlights of Ophthalmology International, Miami, 2004

4. Alió J.L., Agarwal A., Klonowski P.. 0,7mm Microincision Cataract Surgery. In Alió J.L., Fine I. H. (eds) Minimizing Incisions and Maximizing Outcomes in Cataract Surgery, Springer 2010: 13-25

5. Alió J.L., Klonowski P., Rodriguez-Prats J.L., El Kady B. MICS Micro-incision Cataract Surgery. In Cavallini G. M., Perez Arteaga A., Malyugin B., Pajic B. (eds) Instant Clinical Diagnosis in Ophthalmology. Lens Diseases. Jaypee. 2008: 155-185

6. Alió J.L., Rodriguez-Prats J.L., Klonowski P., El Kady B. MICS: Cirugia de la catarata por microincision. In Lorente R., Mendicute J. (eds) Cirugia del cristalino (Tomo I). Sociedad de Española. Macline S.L. 2008: 539-544

7. Alió J.L., Klonowski P., Rodriguez Prats J.L. MICS Instrumentation. In Alió J.L., Fine I. H. (eds) Minimizing Incisions and Maximizing Outcomes in Cataract Surgery. Springer, 2010: 25-37

8. Cleary G, Spalton DJ, Hancox J, Boyce J, Marshall J. Randomized intraindividual comparison of posterior capsule opacification between a microincision intraocular lens and a conventional intraocular lens. J Cataract Refract Surg. 2009. 35: 265-72.

9. Alió J.L., El Kady B, Klonowski P. Acri.Lisa with MICS. In Goes F.J. (eds) Multifocal IOLs. Jaypee. 2009: 201-210

10. Wehner W. Microincision intraocular lens with plate haptic design. Evaluation of rotational stability and centering of a microincision intraocular lens with plate haptic design in 12-19 months of follow-up. Ophthalmologie. 2007, 104: 396-8

11. Alió JL, Rodriguez-Prats JL, Vianello A, Galal A. Visual outcome of microincision cataract surgery with implantation of an Acri.Smart lens. J Cataract Refract Surg. 2005; 31: 1549-56.

12. Tsuneoka H. Implantation of a new Hoya-IOL, Y-60H, through a 1.7mm corneal incision. In. Packer M. (eds) "Mastering the Techniques of Advanced Phaco Surgery" Jaypee LTD, New Deli. 2008, 209-13.

13. Alió J.L., Klonowski P.. MICS Intraocular Lenses. In Alió J.L., Fine I. H. (eds) Minimizing Incisions and Maximizing Outcomes in Cataract Surgery. Springer, 2010: 209-220

14. Alió JL, Rodriguez-Prats JL, Galal A, Ramzy M. Outcomes of microincision cataract surgery versus coaxial phacoemulsification. Ophthalmology. 2005; 112: 1997-2003.

15. Tong N, He JC, Lu F, Wang Q, Qu J, Zhao YE. Changes in corneal wavefront aberrations in microincision and small-incision cataract surgery. *J Cataract Refract Surg.* 2008; 34: 2085-90.
16. Nochez Y, Favard A, Majzoub S, Pisella PJ. Measurement of corneal aberrations for customization of intraocular lens asphericity: impact on quality of vision after microincision cataract surgery. *Br J Ophthalmol.* 2010;94(4):440-444.
17. Elkady B, Alió JL, Ortiz D, Montalbán R. Corneal aberrations after microincision cataract surgery. *J Cataract Refract Surg.* 2008; 34: 40-5
18. Kurz S, Krummenauer F, Gabriel P, Pfeiffer N, Dick HB. Biaxial microincision versus coaxial small-incision clear cornea cataract surgery. *Ophthalmology.* 2006; 113: 1818-26.
19. Kahraman G, Amon M, Franz C, Prinz A, Abela-Formanek C. Intraindividual comparison of surgical trauma after bimanual microincision and conventional small-incision coaxial phacoemulsification. *J Cataract Refract Surg.* 2007; 33: 618-22.
20. Tanaka T, Koshika S, Usui M. Cataract surgery using the bimanual phacoemulsification technique with an Accurus system and Mackool microphaco tip. *J Cataract Refract Surg.* 2007; 33: 1770-4.
21. Mencucci R, Ponchiotti C, Virgili G, Giansanti F, Menchini U. Corneal endothelial damage after cataract surgery: Microincision versus standard technique. *J Cataract Refract Surg.* 2006; 32: 1351-4.
22. Crema AS, Walsh A, Yamane Y, Nosé W. Comparative study of coaxial phacoemulsification and microincision cataract surgery. One-year follow-up. *J Cataract Refract Surg.* 2007; 33: 1014-8.
23. Cavallini G.M, Campi L., Masini C., Pelloni S, Pupino A, Bimanual Microphacoemulsification versus coaxial miniphacoemulsification: prospective study. *J Cataract Refract Surg.* 2007; 33: 387-92.
24. Wilczynski M, Supady E, Loba P, Synder A, Palenga-Pydyn D, Omulecki W. Comparison of early corneal endothelial cell loss after coaxial phacoemulsification through 1.8 mm microincision and bimanual phacoemulsification through 1.7 mm microincision. *J Cataract Refract Surg.* 2009; 35: 1570-4.
25. Wylegała E, Rebkowska-Juraszek M, Dobrowolski D, Woyna-Orlewicz A. Influence of 3.0 mm incision coaxial phacoemulsification and microincision cataract surgery (MICS) on corneal thickness. *Klin Oczna.* 2009;111:207-11
26. Kaufmann C, Krishnan A, Landers J, Esterman A, Thiel MA, Goggin M. Astigmatic neutrality in biaxial microincision cataract surgery. *J Cataract Refract Surg.* 2009; 35: 1555-62.
27. Elkady B, Piñero D, Alió JL. Corneal incision quality: microincision cataract surgery versus microcoaxial phacoemulsification. *J Cataract Refract Surg.* 2009; 35: 466-74.
28. Tong N, He JC, Lu F, Wang Q, Qu J, Zhao YE. Changes in corneal wavefront aberrations in microincision and small-incision cataract surgery. *J Cataract Refract Surg.* 2008; 34: 2085-90.
29. Denoyer A, Denoyer L, Marotte D, Georget M, Pisella PJ. Intraindividual comparative study of corneal and ocular wavefront aberrations after biaxial microincision versus coaxial small-incision cataract surgery. *Br J Ophthalmol.* 2008; 92: 1679-84.
30. Saeed A, O'Connor J, Cunniffe G, Stack J, Mullhern MG, Beatty S. Uncorrected visual acuity in the immediate postoperative period following uncomplicated cataract surgery: bimanual microincision cataract surgery versus standard coaxial phacoemulsification. *Int Ophthalmol.* 2009; 29: 393-400
31. Kaufmann C, Krishnan A, Landers J, Esterman A, Thiel MA, Goggin M. Astigmatic neutrality in biaxial microincision cataract surgery. *J Cataract Refract Surg.* 2009; 35: 1555-62
32. Wilczynski M, Supady E, Loba P, Synder A, Palenga-Pydyn D, Omulecki W. Comparison of surgically induced astigmatism after coaxial phacoemulsification through 1.8 mm microincision and bimanual phacoemulsification through 1.7 mm microincision. *J Cataract Refract Surg.* 2009; 35: 1563-9.
33. Ouchi M, Kinoshita S. Prospective Randomized Trial of Limbal Relaxing Incisions Combined with Microincision Cataract Surgery. *J Refract Surg.* 2009, 26:1-6
34. Fine IH, Hoffman RS, Packer M. Optimizing refractive lens exchange with bimanual microincision phacoemulsification. *J Cataract Refract Surg.* 2004; 30: 550-4.
35. Müller M, Kohlen T. Incisions for biaxial and coaxial microincision cataract surgery. *Ophthalmologie.* 2010;107:108-15
36. Weikert M.P. Update on bimanual microincisional cataract surgery. *Current Opinion in Ophthalmology.* 2006, 17: 62-67
37. Paul T, Braga-Mele R. Bimanual microincisional phacoemulsification: the future of cataract surgery?. *Curr Opin Ophthalmol.* 2005, 16:2-7
38. Osher JM, Osher RH. The transition towards smaller and smaller incisions. In: Alió JL, Fine IH, eds. *Minimizing Incisions and Maximizing Outcomes in Cataract Surgery.* New York, New York: Springer; 2010; chap 1.

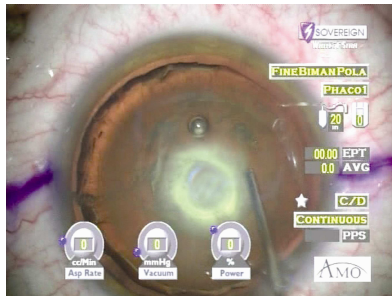
Biaxial microincision phacoemulsification for difficult and challenging cases¹

I. Howard Fine, MD, Jorge L. Alió, MD, PhD, Richard S. Hoffman, MD, Mark Packer, MD, FACS

High Myopia

In highly myopic eyes, we are able to achieve a situation in which we can maintain the anterior chamber in a completely stable configuration, never trampoline the vitreous face, by keeping the irrigating handpiece in the eye throughout the case. Chopping can take place in the usual manner, and with the completion of chopping, mobilization of segments and the epinucleus, we can keep the irrigating chopper in the eye, remove the phaco needle, infuse viscoelastic, remove residual cortex, and then infuse viscoelastic for the implantation of the intraocular lens (IOL) without ever shallowing the anterior chamber. We believe that there may, eventually, be a documented decreased incidence of retinal detachment in high myopia as a result of non-trampoline of the vitreous face during phaco, and the implantation of IOLs that fill the capsule, such as dual-optic IOLs or IOLs that arch posteriorly, as does the Crystalens.

Posterior Polar Cataract (Figure 1)

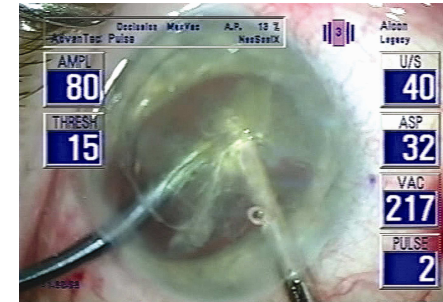


In the situation of posterior polar cataracts, 35 percent have defective posterior capsules^{ii,iii} and almost all of them have weakened capsules, so it is very important to not over-pressurize the eye and perhaps force nuclear material through the defective posterior capsule. By the same token, it is important to not shallow the chamber and have the nucleus come forward, and possibly open the defect in the posterior capsule. These cases are advantageously done with biaxial microincision phacoemulsification, because of the anterior chamber stability.^{iv}

We do hydrodelineation, without hydrodissection, and then carefully chop the endonucleus into pie-shaped segments and evacuate them from the eye. Once the endonucleus is removed, we viscodissect (Viscoat[®], Alcon Laboratories, Fort Worth, Texas) the epinucleus up from its position against the cortex without removing the irrigating chopper. In this way, we have a layer of cortex and viscoelastic under the epinucleus when we evacuate it, so should the capsule open, it is less likely that we will spill lens material into the vitreous. Once the epinucleus is gone, we leave the irrigation system in the eye, remove the phaco needle, and add Viscoat[®]. We viscodissect the cortex up into the plain of the capsulorhexis, in the same way and remove it while

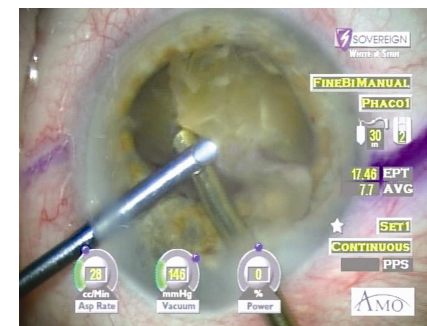
having a thick layer of viscoelastic on top of the fragile posterior capsule. We never polish the posterior segment of the capsule prior to the IOL implantation, but would rely on YAG laser if there were visually significant opacities within the visual axis, post-operatively.

Posterior Subluxed Cataracts (Figure 2):



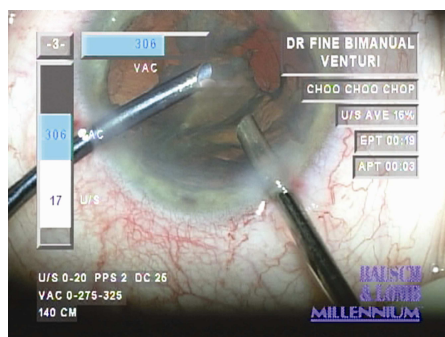
For posterior subluxed cataracts, which are hinged to a small zone of attached zonules, we will go through a pars plana incision and prolapse the lens, in its capsule, up into the anterior chamber and then add viscoelastic (Viscoat[®]) under the lens. We will then phaco the lens with biaxial microincision instrumentation utilizing an irrigating cannula in the left hand and a phaco need in the right, keeping the irrigation on top of the viscoelastic, but below the cataract. We don't try to disassemble these cataracts, but phaco them from the outside in. In general, with the irrigation under the nuclear material, we have a system in which there is fluid circulating in a circuitous pattern on top of the viscoelastic, and chips that are liberated from the mass of the nucleus tend to circulate entirely within the anterior segment and not get deposited into the vitreous. After removal of the cataract, we do a partial anterior vitrectomy and implant, through a 2.5mm incision, a foldable intraocular lens, with the haptics under the iris and the optic on top. This allows the haptics to indent the undersurface of the iris and be easily identifiable. We then suture the haptics to the iris and nudge the optic beneath the pupillary margin. We have had great success with this technique.

Mature Cataract with Zonular Dialysis (Figure 3):



In cases in which there is a dialysis of the zonular apparatus during phacoemulsification, as in a case of unrecognized pseudoexfoliation in the presence of a dense cataract, we can hold the nucleus with the phaco tip, remove the irrigating chopper, place viscoelastic under the lens, and then put the irrigating handpiece, without a chopper, under the lens and again phaco the lens entirely within the plain of the capsulorhexis. Nuclear material can be mobilized from the posterior chamber with an unsleeved phaco tip because there is no irrigation going along with the phaco tip, as in coaxial phaco, which would force the nuclear material into the vitreous cavity. This is not possible with a coaxial phaco tip. In these cases we also see chips that circulate in the fluid above the viscoelastic, which is sitting on top of the vitreous, but we do not see chips that move posteriorly. Once this has been completed, we will do a biaxial microincision partial anterior vitrectomy, or a pars plana 25 gauge transcleral microincision vitrectomy, and implant an anterior chamber lens, or a posterior chamber lens, and suture it to the iris.

Punctured Posterior Capsule (Figure 4):



In the case where the capsule is punctured during the course of phacoemulsification, we can continue the irrigation high in the anterior chamber and go back into the endolenticular space with the unsleeved phaco tip, and complete the phacoemulsification without further enlarging the puncture in the posterior capsule. Without removing the irrigator, we then remove the cortex, and then instill more viscoelastic. We then implant the lens into the capsular bag or into the ciliary sulcus. Residual viscoelastic should be removed with a vitrector to avoid the possibility of bringing vitreous to the wound. This procedure would be impossible with a coaxial phaco tip because a continuously changing fluid wave from the phaco sleeve would enlarge, or extend, the capsular tear out to the periphery of the capsule, with loss of lens material into the vitreous.

Posterior Capsule Rupture (Figures 5 and 6):

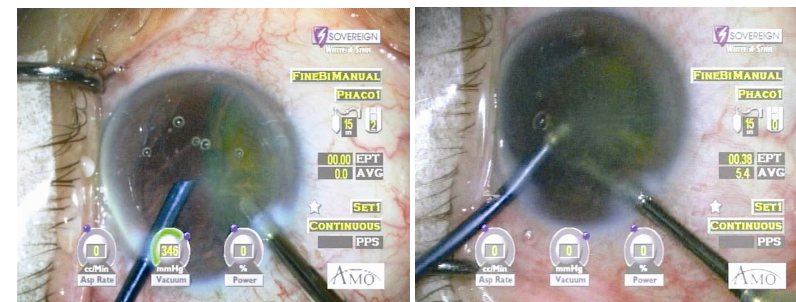
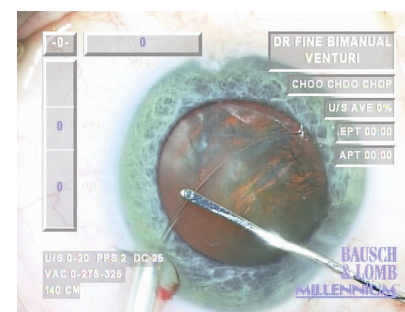


Figure 5

Figure 6

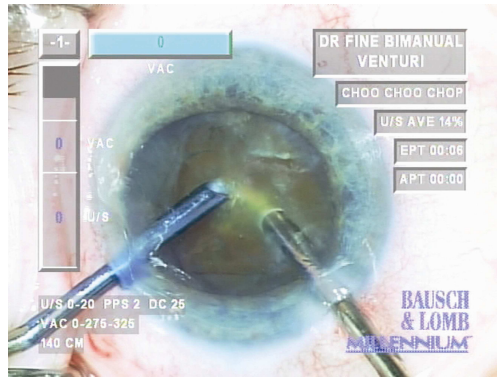
In an extensive posterior capsule rupture, we can bring the entire endonucleus up into the anterior chamber by holding it with the phaco tip. Very little fluid leaks out of the incision when we remove the irrigator, place Viscoat® under the nucleus, and replace the irrigator under the lens. We then proceed with phacoemulsification in the plain of the capsulorhexis or in the anterior chamber, with the irrigator beneath the nucleus as we carousel, or phaco, it from the outside in. We can then proceed with cortical clean-up in a similar manner, or first perform a partial anterior vitrectomy, either through the pars plana, or through side-port incisions biaxially. Once all residual cortex has been removed, we implant a posterior chamber lens into the ciliary sulcus.

Pseudoexfoliation (Figure 7):



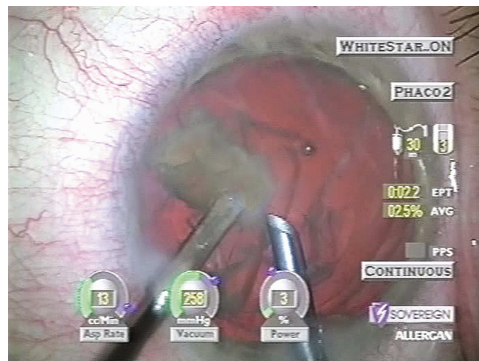
In post-filtration surgery, in the presence of pseudoexfoliation, we like to use an endocapsular tension ring that we can introduce through a side-port with an injector, following gentle cortical cleaving hydrodissection. The injector doesn't enter the incision; it is just held against the incision, and the forces on the capsule as the endocapsular tension ring is being inserted are contained by the use of a Lester hook in the opposite hand (Figure 7). We then proceed with biaxial microincision horizontal chopping of the lens so as to not add any downward force on the lens which might stress the residual zonules. Cortical clean-up is facilitated in the presence of an endocapsular tension ring, by performing gentle cortical cleaving hydrodissection prior to the implantation of the ring. The lens is then implanted into the capsular bag through an incision between the two side-port incisions, which is our routine method for IOL implantation in the presence of two 1.1mm phacoemulsification incisions.

Rock-Hard Nuclei (Figure 8):



We can phacoemulsify rock-hard nuclei with the same facility and ease with which we do softer nuclei with biaxial microincision phacoemulsification, and we usually end up with average phaco powers under ten percent with effective phaco times under ten seconds, in spite of the density of these nuclei. This is an enormous advantage in terms of corneal, endothelial protection because of the great stability of the anterior chamber. We prefer a 30 degree phacoemulsification tip used with the bevel down. This allows the achievement of vacuum once the tip touches the endonucleus. A bevel-up tip must go deeply into the nucleus before occlusion and vacuum are achieved. With a bevel-down tip, we are also sending all of the energy toward the nucleus and none toward the corneal endothelium or trabecular meshwork. Finally, one can mobilize pie-shaped segments from the level of the capsulorhexis up, rather than having to go deeply into the endolenticular space to achieve occlusion to mobilize these segments, as we would have to with a bevel-up configuration.

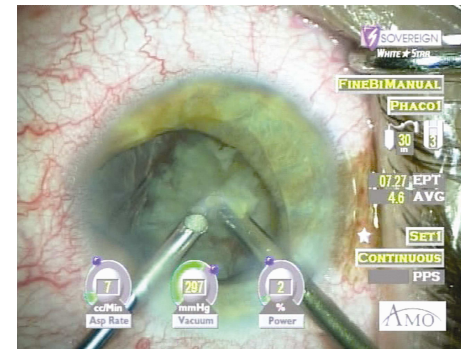
Switching Hands (Figure 9):



In cases of zonular dialysis, another advantage of biaxial microincision phacoemulsification is that we can use the phaco tip with either hand. After inserting an

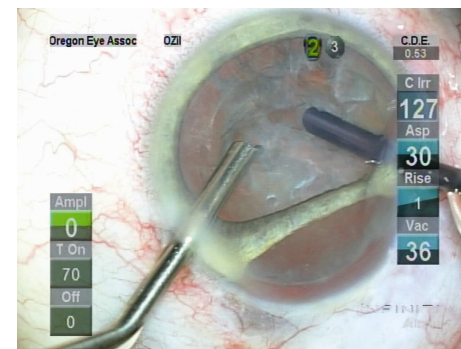
endocapsular tension ring through one of the microincisions, we would hydroexpress the lens into the plain of the capsulorhexis and then utilize the phaco tip in either the right, or left, hand, depending on the location of the zonular dialysis. For dialyses that are on the operating surgeon's right side, we would use the phaco tip in the right hand, drawing material in the anterior chamber toward the area of weakened zonules, rather than away from it, which would stress the intact zonules. For dialyses that are on the left-hand side, we can use the phaco tip in our left hand and the irrigating chopper in the right to remove the nucleus, thereby closing the zonular dialysis with the activation of flow and vacuum toward the left side.

Microcornea or Microphthalmos (Figure 10):



For very small eyes, the use of biaxial phacoemulsification is an enormous advantage because the smaller size of the instruments avoids creasing of the cornea, which compromises visualization of intraocular structures. A coaxial tip, which is much larger in size, would indent the cornea as it was manipulated and partially obscure the visualization of the intraocular structures. This has turned out to be especially advantageous in cases with a microcornea or a microphthalmic eye in the presence of an unusually large lens.

Large Iridodialysis and Zonular Defects (Figure 11):



In cases where there are large iris defects and missing zonules, we will straddle that area with our microchopper and phaco tip, fractionate the anterior chamber with Healon 5 to

keep the vitreous back and proceed in the usual manner. This has been very efficacious and has not resulted in bringing vitreous out of the posterior segment. This is exemplified in the case of a woman who had 100 degrees of ciliary body and iris, except for the pupillary margin, excised in management of a choroidal/ciliary body malignant melanoma, resulting additionally in fragile and atrophic sclera and conjunctiva at the tumor site.

In this case, we were able to perform biaxial microincision phacoemulsification through two microincisions on each side of the 100 degrees of atrophic sclera and conjunctiva, and missing ciliary body and iris. The advantage here is that with the vitreous face open to the anterior chamber, we wanted to be drawing material toward the area of missing zonules, after having sequestered the vitreous in that area with Healon 5 (Advanced Medical Optics, Santa Ana, California). Phacoemulsification performed through an incision in other locations would bring vitreous to the phaco tip and provide a much more challenging situation. The IOL was implanted nasally over the intact zonules to force the lens to push against the capsular fornix in the area of missing zonules, rather than to pull away from the area of missing zonules if it had been implanted in the temporal periphery.

Intraoperative Floppy Iris Syndrome (IFIS) (Figures 12, 13, 14, 15, and 16):

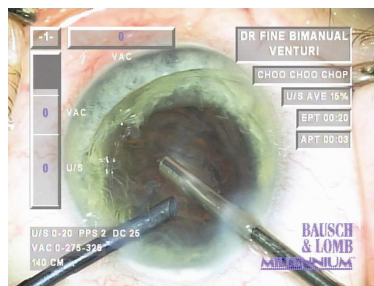


Figure 12

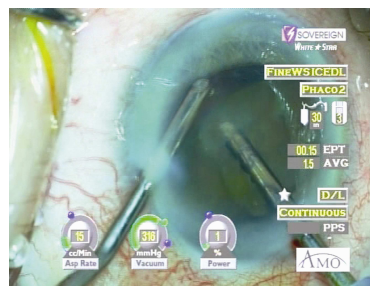


Figure 13

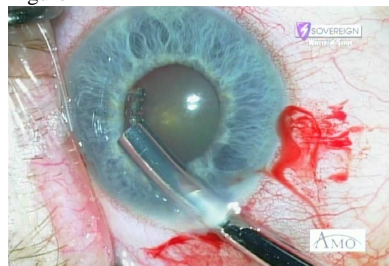


Figure 14

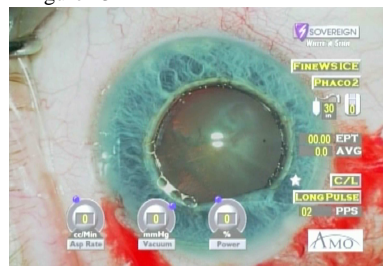


Figure 15

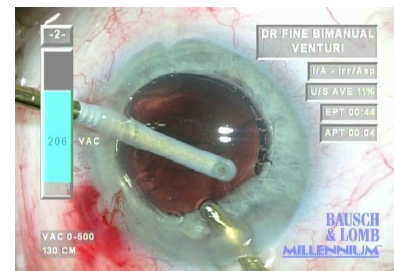


Figure 16

We find biaxial microincision phacoemulsification enormously useful in cases of intraoperative floppy iris syndrome (IFIS). If we have adequate dilation in the presence of a floppy iris, we will perform gentle cortical cleaving hydrodelineation and hydrodissection, and then hydroexpress the lens into the plain of the iris. We will then carousel the endonucleus in the plain of the capsulorhexis with the irrigating cannula held high in the anterior chamber. Holding the irrigator high in the anterior chamber allows for a tamponading of the iris by the fluid which then disallows floppiness, or billowing, of the iris. After removing the endonucleus in the plain of the capsulorhexis, we see a fully intact epinuclear shell, which had been sitting on top of the iris, helping to hold it back. This is an extremely advantageous technique for nuclei of less hard densities that can be carouselled and phacoed in the anterior chamber without threatening the corneal endothelium.

For harder cataracts, and in the presence of pupils that will not dilate well, we will dilate the pupil with Healon 5, do a rather large capsulorhexis and then do one endolenticular chop. We then keep the irrigating chopper high in the anterior chamber and with the unsleeved phaco tip, bring nuclear material up to the chopper held high in the anterior chamber for further disassembly. This allows, once again, a tamponading of the iris and prevention of billowing or floppiness. We try to keep the phaco needle occluded and in foot position two or three, but with a clearance of occlusion, we go to foot position one in order to minimize evacuation of Healon 5, which is holding the pupil open.

After the endonucleus is removed in this way, we remove the epinucleus. Since it is harder to keep the tip occluded with epinuclear trimming and flipping, there tends to be evacuation of Healon 5 and a reduction of the size of the pupil, although because of the irrigator held high in the anterior chamber, it does not billow. We then have to re-install Healon 5 to expand the bag and redilate the pupil prior to cortical clean-up. Then, once again, holding the irrigator high in the anterior chamber, we keep the aspirating microincision handpiece occluded by going circumferentially around the capsulorhexis, with the port facing the capsule fornix, removing the cortical material from only the fornix of the capsule, letting it sit as a cluster in the central portion of the capsule. After all of the cortex has been mobilized from the capsular fornix, we remove the residual cortex from the eye. In this way, we are able to keep Healon 5 in the eye and disallow miosis of the pupil until the case is complete.

In some cases, the pupil is intractably small and won't respond to Healon 5 expansion. In these cases, we may use a pupil expander ring (Morcher Pupil Expander Ring, Type 5S, FCI Ophthalmics, Marshfield Hills, MA; or a Malyugin Ring, Catalog #MAL-0001,

MicroSurgical Technology, Redmond, WA). These are implanted through a 2.5mm clear corneal incision to enlarge the pupil (Figure 14), after which biaxial phacoemulsification is then performed through the two side-port incisions and the larger incision remains sealed during the operation because of its self-sealing construction and architecture. The pupil expander rings are advantageous because the pupil can be moved away from the incisions just by pushing on the ring.

With the ring in place (Figure 15), we have found in some cases that we were unable to adequately perform hydrodissection or hydrodelineation. If we cannot perform our hydrosteps because of the tendency for the pupil to extrude, we will use a bevel-down phaco tip to bowl out the center of the cataract, and then do inside-out hydrodelineation, as described by Abhay Vasavada.^v We then chop the residual endonucleus in the usual fashion, and then remove the epinucleus as well.

In some cases, we may perform subincisional cortical removal by using a coaxial irrigation handpiece in the 2.5mm incision to hold the iris back, while going to a distal location through a microincision with a 0.2mm port aspirator to remove the subincisional cortex (Figure 16). This has been very efficacious.

Every Small Pupil Must Be Viewed as a Potential IFIS

We believe that every small pupil must be viewed as a potential floppy iris case because there have now been identified multiple other drugs and neutraceuticals that have anti-alpha-1A properties and therefore which create an intraoperative floppy iris syndrome. We no longer stretch small pupils because if they become IFIS cases we have exacerbated the floppiness by disrupting the only portion of the iris (the pupil) which retains structural integrity. The only exceptions to that are pupils that are bound down by inflammatory pupillary membranes, or that have a long history of exposure to miotic drops, and a clear absence of medications that might produce a floppy iris.

Iris Bombé (Figures 17, 18, 19, and 20):

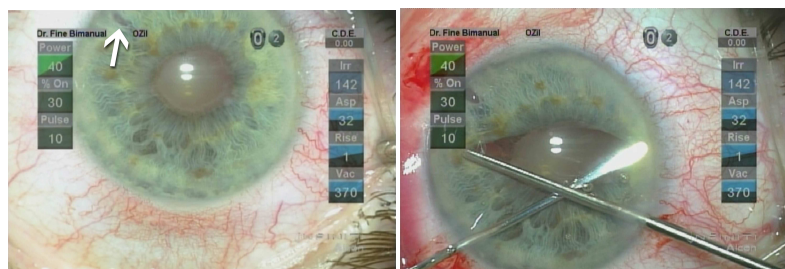


Figure 17

Figure 18

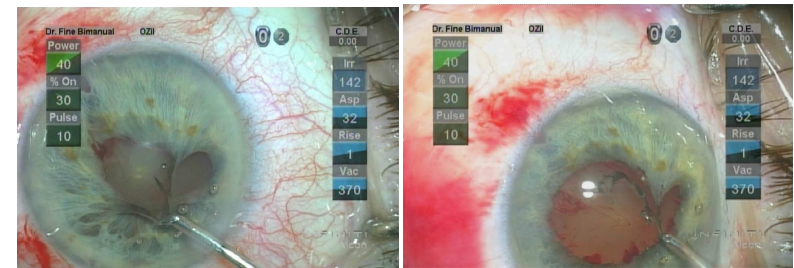
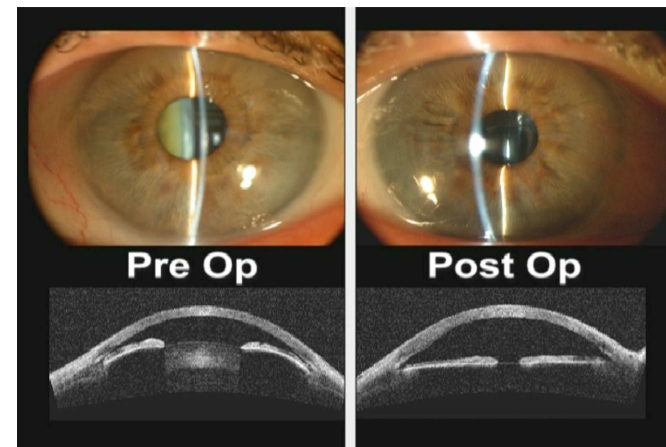


Figure 19

Figure 20

For pupils that are completely bound down by a pupillary membrane, we will use biaxial phacoemulsification. Commencing with a small iridotomy peripherally, close to one of the microincisions (Figure 17), Viscoat[®] is used to elevate the iris and its cannula to sweep the pupillary membrane from the anterior lens capsule. We then stretch the pupillary membrane in one direction and the iris just distal to the pupillary membrane in the opposite direction in the same meridian (Figure 18). This results in a lysing of the pupillary membrane for several clock hours from the pupil itself, and allows us to go back, and using tangential forces with a microincision capsulorhexis forceps, strip the pupillary membrane from the pupil (Figures 19 and 20). Following this, Healon 5 allows for maximum dilation of the pupil and we proceed in the usual manner.

Very Shallow Anterior Chambers (Figure 21):



For very shallow anterior chambers biaxial phacoemulsification is also a great advantage because the instruments are indeed smaller and fit more readily in the eye; however, if the anterior chambers are too shallow (Figure 21) we perform a 25 gauge transcleral pars plana vitrectomy, before proceeding with biaxial phacoemulsification. It is very important in using these microvitrectors to use a finger of the non-dominant hand to maintain tactile contact with the eye, so that one doesn't over-soften the eye. These vitrectors are capable of between 1,200 and 1,500 cuts per minute. In spite of

their small gauge, unless care is taken, one can overly soften the eye, retroplating the lens and creating new difficulties and challenges.

Refractive Lens Exchange (Figures 22, 23, 24, and 25):

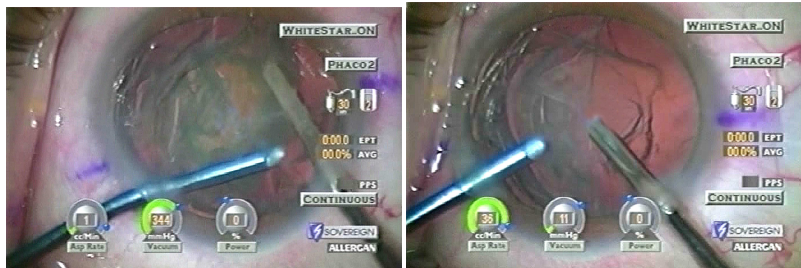

Figure 22

figure 23

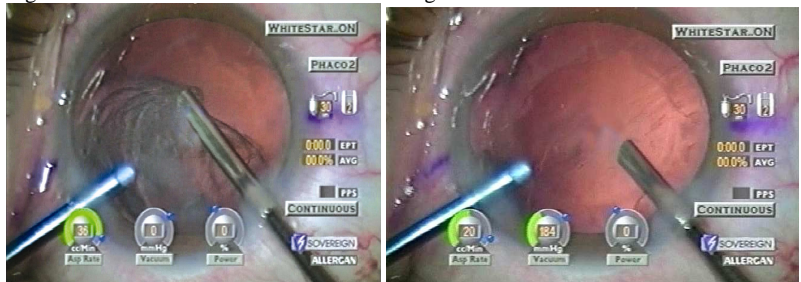
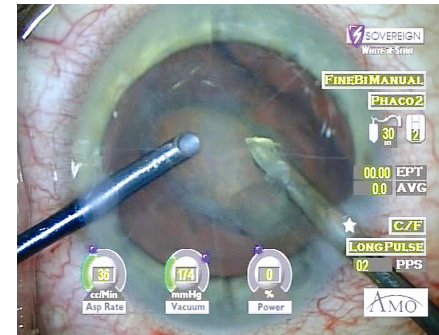


Figure 24

Figure 25

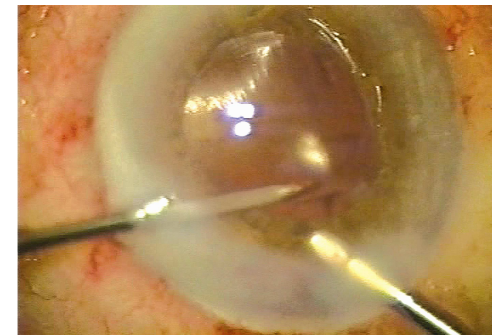
We can do refractive lens exchange very easily, and safely, with biaxial microincision phacoemulsification. We do cortical cleaving hydrodissection and no hydrodelineation. We then hydroexpress the lens into the plain of the capsulorhexis, and carousel it, without any phacoemulsification energy for soft lenses, usually encountered in refractive lens exchange (Figures 22 and 23). We do an entirely fluidic-based extraction and then, because of cortical cleaving hydrodissection, we are able to evacuate the cortex by just tilting the phaco tip back into the posterior chamber where it jumps into the phaco tip as a single piece (Figures 24 and 25).

Refractive Lens Exchange in Post Radial Keratotomy (RK) (Figure 26):



In cases where previous radial keratotomy (RK) has been performed, we can do biaxial microincision clear lens or cataract removal by going between two previously placed radials, making it much less likely that we will rupture the radial incisions during the course of the lens extraction. We then make an incision between our two microincisions for implantation of the IOL, but in the presence of previous RK, we make it through the posterior limbus for implantation of the IOL.

Intraocular Cautery (Figure 27):



We have found that we can, with biaxial microincision instruments, do intraocular cautery by using an irrigating cannula in one of the microincisions and a microincision bipolar cautery in the other. Pinching the irrigation tubing allows bleeding to take place, clearly identifying the point source because the eye softens and the bleeding points start to ooze. We cauterize them precisely with the bipolar cautery, and therefore minimize trauma to intraocular structures by avoiding more cautery than is necessary.^{vi}

Biaxial Microincision Instruments (Figures 28 and 29):

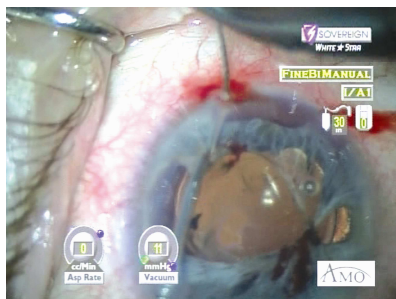


Figure 28

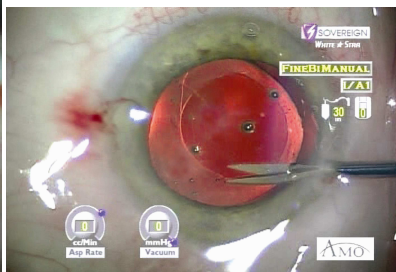


Figure 29

- control of bleeding pre-, intra- and post-operatively;
- intraocular suturing, especially following iris trauma.

There are a number of other instruments that have been developed for use through 1.1mm microincisions. Iris reconstruction is very much easier utilizing intraocular forceps that stabilize the iris for suturing. New intraocular needle holders are also usable through a 1.0mm incision. In this way, very fragile and atrophic irides can be sutured without putting excessive stress on the iris tissue. The knots are tied with a Seipser external tying mechanism,^{vii} and the knots are cut with an intraocular microincision scissors, that is also admissible through a 1.0mm incision.

For late reopening of capsular bags to recenter IOLs, we can enlarge a capsulorhexis in the late post-operative period by nicking the rhexis with a microincision intraocular scissors, and then tearing a larger opening with a microincision capsulorhexis forceps. Viscodissection of the lens,^{viii} within the capsular bag, can be accomplished through microincisions which also allow for repositioning of IOLs without the need to make larger incisions to manipulate them intraocularly. There are currently additional microincision instruments under a state of development, including microincision Colibri forceps, microincision iris graspers, and microincision intraocular lens holders and cutters.

Take Home Pearls:

We believe biaxial microincision phacoemulsification is a technique that has a very short learning curve, is highly atraumatic, and is unquestionably the technique of the future. For those who are willing to go through the short learning curve now, it represents the best and safest technique at present for the management of certain difficult and challenging cases.

- The separation of infusion from aspiration and ultrasound energy allows us to use the incoming fluid wave as a unique instrument to hold back floppy irides.
- We can sequester the anterior segment from the posterior segment in cases of ruptured capsules and zonular dialyses.
- Is especially useful in situations in which the smaller instrumentation of biaxial phacoemulsification are required, such as in high hyperopia, small eyes, and crowded anterior chambers.
- Has unique advantages in high myopia and posterior polar cataracts.
- New instrumentation facilitates
 - repositioning decentered lenses in fibrosed capsules;

Figures

Figure 1: Hydrodelineation of a posterior polar cataract.

Figure 2: Phacoemulsification of a subluxed cataract in the anterior chamber.

Figure 3: Bringing nuclear material out of the posterior chamber with an unsleeved phaco tip in the presence of zonular dialysis.

Figure 4: Completing phacoemulsification in the presence of a punctured posterior capsule.

Figure 5: Holding the Nucleus with an unsleeved phaco tip prior to removing the chopper and adding viscoelastic under the nucleus in the presence of a large posterior capsule rupture.

Figure 6: Irrigating below the cataract in the presence of a capsule rupture.

Figure 7: Injection of a capsule tension ring through a microincision controlled by a Lester hook in the right hand.

Figure 8: Chopping a rock hard nucleus.

Figure 9: Phacoemulsification in the left hand in the presence of zonular dialysis (surgeon's perspective).

Figure 10: Microinstruments phacoing a large dense nucleus in an eye with micro cornea and iris coloboma.

Figure 11: Initial chop of the cataract post 100° ciliary body excision for malignant melanoma.

Figure 12: Epinucleus holding the iris back after carouselling the endonucleus in the presence of intraoperative floppy iris syndrome (IFIS).

Figure 13: Endonuclear disassembly in the anterior chamber with the irrigator tamponading the iris.

Figure 14: A Morcher Pupil Expander Ring (Type 5S, FCI Ophthalmics, Marshfield Hills, MA) is injected through a 2.5mm clear corneal incision.

Figure 15: The Morcher Pupil Expander Ring in place.

Figure 16: The use of a coaxial irrigation handpiece with a micro aspirator to remove subincisional cortex.

Figure 17: Pre-operative image of an eye with a bound down pupillary membrane. Arrow indicates small, peripheral iridotomy.

Figure 18: Stretching the pupillary membrane in one direction and the iris just distal to the pupillary membrane in the opposite direction in the same meridian.

Figure 19: Stripping the pupillary membrane.

Figure 20: Releasing the last adhesion of the pupillary membrane.

Figure 21: Pre-operative slit-lamp and optical coherence tomography (OCT) images of a very shallow anterior chamber. The post-operative images demonstrate the increase in anterior chamber depth due to the 25 gauge transcleral pars plana vitrectomy.

Figure 22: Carouselling the nucleus in refractive lens exchange without using any phacoemulsification energy.

Figure 23: Endonucleus removal complete with only cortex remaining. No phacoemulsification energy was used to remove the endonucleus.

Figure 24: Removing cortex in refractive lens exchange by tilting the phaco tip back into the posterior chamber. (Need to get form Ryan.)

Figure 25: Cortex completely removed.

Figure 26: Bimanual microincision phacoemulsification of a cataract between RK incisions.

Figure 27: Bipolar intraocular microcauterization with easy identification of the bleeding point by pinching the infusion tubing.

Figure 28: Suturing of atrophic iris using microincision intraocular forceps.

Figure 29: Nicking the capsulorhexis with microincision scissors prior to enlarging the capsulorhexis.

References

-
- ⁱ This chapter is an update of the previously published, Fine IH, Hoffman RS, Packer M, "Use of bimanual microincision phacoemulsification for difficult and challenging cases", in Garg A, Fine IH, Alió JL, Chang DF, Weinstock RJ, Mehta KR, Bovet JJ, Tsuneoka H, Malyugin B, Pinelli R, Pajic B, Mehta CK (eds.) *Mastering the Techniques of Advanced Phaco Surgery*, Jaypee Brothers: New Delhi, India, 2008. Reprinted with permission from Jaypee Brothers: New Delhi, India.
- ⁱⁱ Osher RH, Yu BC-Y, Koch, DD. Posterior polar cataracts: a predisposition to intraoperative posterior capsule rupture. *J Cataract Refract Surg* 1990; 16:157-162.
- ⁱⁱⁱ Vasavada AR, Sing R. Phacoemulsification in posterior polar developmental cataracts. In Lu LW, Fine IH, *Phacoemulsification in Difficult and Challenging Cases*. New York, NY, Thieme, 1999; 121-128.
- ^{iv} Aravind H, Aravind S, Vadi K, Natchair G. Bimanual microphaco for posterior polar cataracts. *J Cataract Refract Surg* 2006; 32(6):914-917.
- ^v Vasavada AR, Raj SM. Inside-out delineation. *J Cataract Refract Surg* 2004; 30(6):1167-1169.
- ^{vi} Fine IH, Hoffman RS, Packer M. Bimanual bipolar diathermy for recurrent hyphema following anterior segment intraocular surgery. *J Cataract Refract Surg* 2004; 30(9):2017-2020.
- ^{vii} Seipser SB. The closed chamber slipping suture technique for iris repair. *Ann Ophthalmol*. 1994; 26(3): 71-72.
- ^{viii} Fine IH, Hoffman RS. Late reopening of fibrosed capsular bags to reposition decentered intraocular lenses. *J Cataract Refract Surg* 1997; 23:990-994.