

Wrist Arthroscopy

Stuart J. Elkowitz, M.D., and Martin A. Posner, M.D.

Compared to knee arthroscopy, wrist arthroscopy is a relatively recent operative technique that is being used with increasing frequency for the diagnosis and treatment of a wide variety of wrist problems. Wrist arthroscopy permits the visualization of the cartilage surfaces of most of the carpal bones, as well as many of the extrinsic and intrinsic ligaments of the wrist joint, including important components of the triangular fibrocartilage complex (TFCC). Wrist arthroscopy serves as a diagnostic tool, as well as a therapeutic option.

Equipment and Set-Up

The equipment necessary for wrist arthroscopy include an arthroscope, some type of traction apparatus, inflow and outflow irrigation systems, and instruments for both diagnostic and operative procedures.¹ The most commonly used arthroscopes are 1.9 mm and 2.7 mm in diameter and have 30° angled lenses. A traction apparatus stabilizes the wrist and facilitates the insertion of instruments.

At surgery, the patient is placed in a supine position on the operating table, with a hand operating table on the side to be used for the operative limb. The patient's elbow is flexed and the forearm is immobilized to the traction apparatus. Care is taken to pad areas of contact between the apparatus and arm in order to avoid any pressure irritation on the skin, particularly over bony prominences. Generally, between 10 lbs and 15 lbs of traction is applied through finger traps. Close mesh nylon finger traps are preferred

to wire traps, because nylon is a more resilient material and more evenly distributes the traction force to the skin. Traction is usually applied to two fingers, the index and middle fingers. In patients with atrophic and fragile skin, as is often seen in rheumatoid arthritis (RA), the traction is applied to 3 or all 4 fingers, in order to more evenly distribute the traction force on the skin. In addition to distraction, which facilitates visualization, an inflow irrigation system is used. The system may be gravity flow, a hand pump, large syringes, or a mechanical infusion pump. Generally, lactated Ringer's solution is used for irrigation rather than saline, because it is more physiological and is more rapidly absorbed. The surgeon must always be alert for fluid extravasation into the soft tissues of the forearm that, if severe, could possibly result in compartment syndrome. Proper instruments must be available to carry out a complete diagnostic arthroscopy, as well as to perform various operative procedures, such as debridement (torn ligamentous tissue and/or hypertrophic synovium), repair (peripheral tear of the articular disc of the TFCC), and resection of local bone (radial styloidectomy or wafer resection of the distal ulna). Instruments include probes, graspers, suction punches, small joint shavers (2.0 mm and/or 2.9 mm), power burr, and electrocautery.

Arthroscopic Portals

Several precautions must be followed when making the arthroscopic portals in order to minimize the risk of injury to underlying nerves, vessels, tendons, and ligaments, as well as to the articular surfaces of the radius and carpal bones. The superficial structures that are most vulnerable to injury are the dorsal sensory branches of the radial and ulnar nerves. The deep branch of the radial artery is also at risk for a portal near the radial styloid. Some surgeons mark key topographic anatomic landmarks before making incisions for the portals, such as identifying Lister's tubercle,

Stuart J. Elkowitz, M.D., was a Chief Resident in the NYU Hospital for Joint Diseases Department of Orthopaedic Surgery, New York, New York. Martin A. Posner, M.D., is Clinical Professor of Orthopaedic Surgery, New York University School of Medicine and Chief of Hand Service, NYU Hospital for Joint Diseases Department of Orthopaedic Surgery, New York, New York.

Correspondence: Martin A. Posner, M.D., NYU Hospital for Joint Diseases, 301 East 17th Street, New York, New York 10003.

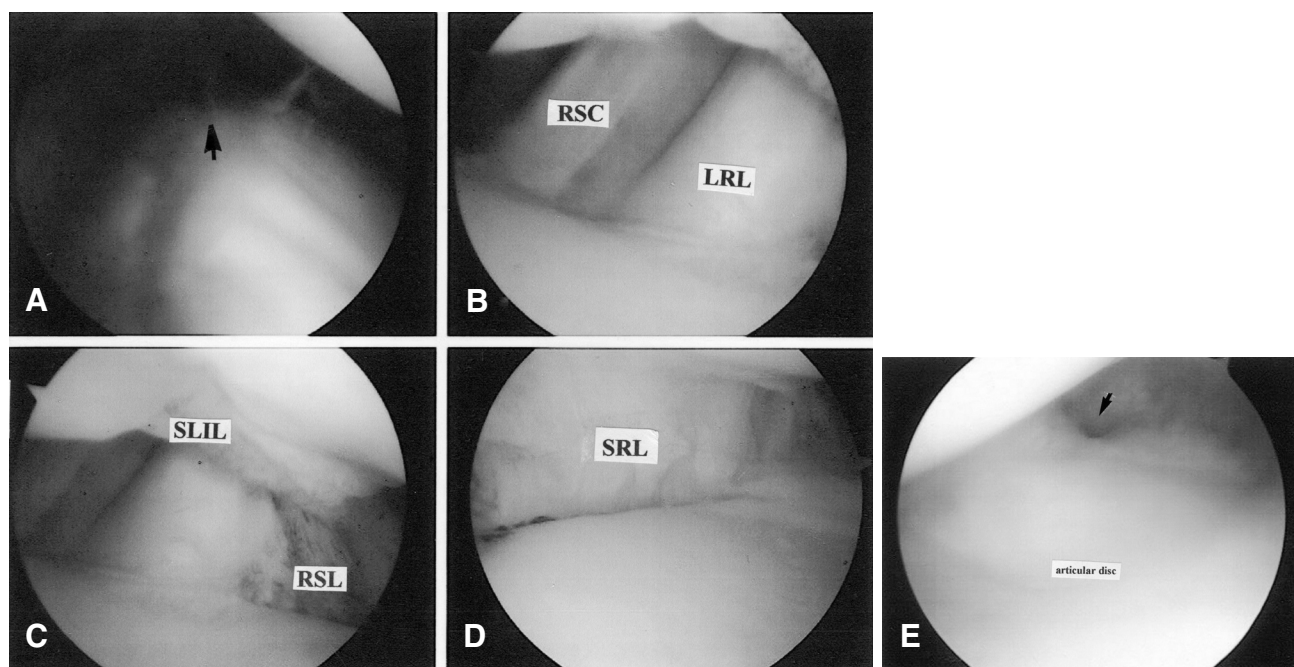


Figure 1 Four arthroscopic views of a normal radiocarpal joint, from radial to ulnar. **A**, The radial styloid (arrow). **B**, The radioscaphoidcapitate (RSC) ligament and the more superficial appearing long radiolunate (LRL) ligament, with a clear differentiation between both ligaments. **C**, The radioscapholunate (RSL) ligament or ligament of Testut. The scapholunate joint resembles a baby's bottom connected by the inferior part of the scapholunate interosseous ligament (SLIL). **D**, The short radiolunate (SRL) ligament, with the lunate fossa of the radius in the foreground. **E**, The articular disc and prestyloid recess (arrow).

the articular margins of the distal radius and distal ulna, and the anatomical course of certain tendons, the extensor pollicis longus (EPL) and extensor carpi ulnaris (ECU). Portal incisions are generally made in a longitudinal direction to avoid cutting across underlying nerves and tendons. Only the skin should be incised, and the scalpel blade should never be inserted down to the level of the joint capsule. A safe technique is to nick the skin with the pointed tip of a #11 scalpel blade that faces distally. A 0.5 cm incision is made by pulling the skin proximally against the blade. A straight or curved mosquito clamp is then used for blunt dissection down to the joint capsule, and the capsule is penetrated with a blunt trocar. Sharp trocars should not be used in order to avoid cartilage damage. Penetrating the capsule with the blunt trocar is facilitated by a combination of traction on the joint, distending the joint capsule with irrigation fluid, and "feeling" for soft spots.

There are five radiocarpal and four midcarpal portals available for wrist arthroscopy. The radiocarpal portals are named according to their relationships to the extensor tendon compartments. The most commonly used portal is the 3-4 that is located 1.0 cm distal to Lister's tubercle; it is bordered radially by the EPL and ulnarly by the extensor digitorum communis (EDC). During insertion, the blunt trocar, is tilted proximally to accommodate for the normal volar angulation of the distal articular surface of the radius. Upon entering the joint, the structure directly in line with the portal is the radioscapholunate (RSL) ligament, or

ligament of Testut. This is not a true ligament but rather a neurovascular remnant that is usually covered by fat and synovial tissue. The scapholunate interosseous ligament (SLIL) is located dorsal to the RSL ligament; to the radial and ulnar sides are the articular surfaces of the scaphoid and lunate bones, respectively. These articular surfaces should be carefully inspected for erosions or defects. Proximally, the scaphoid and lunate fossa of the distal radius, separated by a ridge, can be visualized. By rotating the arthroscope lens in a radial direction, the radial styloid and joint capsule at that site can be seen (Fig. 1). Moving the arthroscope in an ulnar direction, the radioscaphocapitate (RSC) ligament is seen, followed by the long radiolunate (LRL) ligament and then the RSL ligament. There is usually a separation between the RSC and LRL ligaments; the LRL is deeper than the RSC and appears closer to the arthroscope. The short radiolunate (SRL) ligament is immediately to the ulnar side of the RSL, and further ulnarly are components of the TFCC as well as the prestyloid recess.

The 3-4 portal is the most commonly used portal for the initial placement of the arthroscope, and the 4-5 portal is the most commonly used portal for the initial insertion of probes and instruments. The 4-5 portal is located 1.0 cm ulnar to the 3-4 portal and is bordered radially by the EDC and ulnarly by the extensor digiti quinti proprius (EDQP). Due to the normal inclination of the distal radius, the 4-5 portal is at a slightly more proximal level than the 3-4 portal.

The 6-R portal is bordered radially by the EDQP and ulnarly by the ECU. This portal provides excellent visualization of the lunotriquetral interosseous ligament (LTIL), the articular cartilage over the proximal surface of the triquetrum, the ulnolunate and ulnotriquetral ligaments of the TFCC, and the triangular fibrocartilage (TFC), or articular disc. The acronyms TFCC and TFC are frequently used interchangeably, but there is an important difference between them. TFCC refers to the entire complex of ligaments of which the TFC, or articular disc, is a component. In order to avoid confusion between TFCC and TFC, we prefer to use the term 'articular disc' rather than TFC. Occasionally, the pisiform bone can be seen through this portal when there is a normal opening just distal to the prestyloid recess.

The 6-U portal is located to the ulnar side of the ECU. Care must be taken in making this portal because of proximity of the dorsal sensory branch of the ulnar nerve. The 6-U portal can be used for instillation of fluid in order to distend the joint capsule prior to penetrating the capsule with the blunt trocar. It is also commonly used for irrigation outflow.

The 1-2 portal is bordered radially by the extensor pollicis brevis (EPB) and ulnarly by the extensor carpi radialis longus (ECRL). The portal lies in close proximity to the superficial sensory branch of the radial nerve and deep branch of the radial artery, and care must be taken to avoid injury to both structures. The risk of injury can be minimized by placing the portal no farther than 0.5 cm dorsal to the first extensor compartment and no farther than 0.5 cm distal to the radial styloid.² The 1-2 portal provides excellent visualization of the radial styloid and is a good working portal for performing an arthroscopic styloidectomy.

Arthroscopy of the wrist usually requires visualizing the midcarpal space. This space is generally tighter than the radiocarpal joint space and care must be taken in making the portals to avoid injury to the articular surfaces of the carpal bones. The most commonly used midcarpal portal is the radial one, located 1.0 cm distal to the 3-4 portal, in line with the radial border of the third metacarpal. The trocar is inserted between the scaphoid and capitate. When the arthroscope is inserted, the first structure seen is the concave surface of the capitate head. Rotating the lens proximally permits visualization of the scapholunate (SL) and lunotriquetral (LT) joints. The scaphotrapezotrapezoid (STT) joint can be seen further radially and the capitohamate joint further ulnarly.

The ulnar midcarpal portal is located 1.0 cm distal to the 4-5 portal, in line with the shaft of the fourth metacarpal. Through this portal, the SL and LT joints can also be visualized as well as the triquetrohamate (TH) joint. The other two midcarpal portals are the STT and TH portals; both are infrequently used.

In addition to five radiocarpal portals and four midcarpal portals, there is a distal radioulnar portal that can be made

to visualize the sigmoid notch of the articular surface of the radius and the articular surface of the ulna head.

Arthroscopy as a Diagnostic Tool

Wrist arthroscopy is a useful technique for the evaluation of patients with wrist pain. It should never be used as a substitute for a detailed history and careful physical examination. Wrist pain is not by itself an indication for immediate arthroscopy, particularly in patients whose pain and tenderness are diffuse and whose radiographs are negative. Treatment for these patients should be nonoperative, consisting primarily of wrist immobilization for several weeks. Oral nonsteroidal anti-inflammatory medication can also be prescribed. Frequently, the pain subsides and further treatment is unnecessary. However, in patients with localized symptoms and physical findings that persist in spite of conservative measures, arthroscopy is a useful diagnostic tool, especially when radiographs are negative.^{3,4}

Numerous studies have shown that arthroscopy is both more sensitive and more specific than arthrography.⁵⁻⁸ In one study using single injection arthrography, 33% of patients with no evidence of a TFCC tear on arthrography had tears on arthroscopic evaluation.⁵ In those patients whose arthrograms were positive, tears were confirmed by arthroscopy in every case. In another study comparing arthrography to arthroscopy in patients who eventually underwent operative arthrotomies, arthroscopy was again more accurate than arthrography for identifying the size and location of ligament and articular disc injuries.⁶ Similar results were encountered when triple-injection arthrography was substituted for the single-injection method, even though triple-injection arthrography decreases the number of false negatives that result from one-way flap tears in the articular disc. Sensitivity and specificity of arthrography compared to arthroscopy were 60% and 100%, respectively, for SLIL and articular disc lesions, and 93% and 97% respectively for LTIL lesions.⁷ A negative arthrographic examination, therefore, does not eliminate the possibility of a ligament tear(s). Magnetic resonance imaging (MRI) has been shown to be more accurate than magnetic resonance arthrography (MRA), but neither imaging study is as accurate as arthroscopy for diagnosing interosseous ligament and articular disc lesions. MRI had a sensitivity of 81% and a specificity of 75%, while MRA had a sensitivity of 97% and a specificity of 96%.⁹

Wrist Problems

Scapholunate and Lunotriquetral Instability

Wrist arthroscopy provides the surgeon with the opportunity to diagnose and treat instability of the SL and LT joints, often eliminating the need for open operative procedures (Table 1). Evaluating instability requires visualizing not only the radiocarpal joint but also the midcarpal joint, since any incongruity associated with intercarpal instability is often more effectively assessed at the midcarpal joint. The SL joint is normally open at the midcarpal joint, but without any

Table 1 Classification of SL and LT Instability

Grade I:	Loss of normal concave appearance of SLIL or LTIL ligament Ligament bulges and has a convex shape SL or LT joint remains congruent when viewed at midcarpal joint space
Grade II:	SL or LT joint no longer congruent when viewed at midcarpal joint space
Grade III:	Gap between the carpal bones at both radiocarpal and midcarpal joint spaces Dorsal portion of SL ligament may still be intact
Grade IV:	Corresponds to widening of joint space seen on AP radiograph Dorsal portion of SL ligament not intact Arthroscope can be passed between radiocarpal and midcarpal joints

articular step-off. For the LT joint, up to a 1 mm step-off is within normal limits.¹¹⁰

The initial treatment of patients with suspected tears of their SLIL or LTIL and no evidence of joint incongruity is wrist splinting for several weeks. However, if pain persists, arthroscopic debridement of the torn ligament is indicated. For debridement of the SLIL, the arthroscope is usually placed in the 4-5 portal and the shaver in the 3-4 portal. Care must be taken not to disrupt any intact dorsal portion of the SLIL ligament, because it is the strongest segment of the ligament. For debridement of the LTIL, the arthroscope is usually placed in the 3-4 portal and the shaver in the 6R portal (Fig. 2). When tears of the SLIL or LTIL are partial, excellent results have been reported with arthroscopic debridement.^{211,12} Up to 85% of patients with partial SLIL tears and 100% of patients with partial LTIL tears were symptom free or significantly improved at an average follow-up of 27 months.³¹¹ When ligament tears were complete, improvement was less successful; 66% and 78%, respectively, for the SLIL and LTIL.

Patients with incongruity of their SL or LT joint can also be treated with debridement of the torn ligament. In addition, the involved joint can be pinned.⁴¹⁰ Joint incongruity should first be corrected, and this is often accomplished by the percutaneous insertion of Kirschner wires into the carpal bones to serve as joy sticks. Once congruity is restored, two

.045 inch diameter, nonthreaded Kirschner wires are drilled across the joint. The pins are maintained for approximately 8 weeks. In a clinical study of SL instability treated by arthroscopic reduction and percutaneous pinning, patients were divided into two groups based on the chronicity of the problem and the size of the gap at the SL joint. In the first group were patients whose symptoms were less than 3 months duration and the SL gap measured less than 3 mm. In the second group were patients whose symptoms were longer than 3 months and the SL gap was greater than 3 mm. At follow-up, 83% of patients in the first group were symptom free, compared to only 53% in the second group.⁵¹³

When the dorsal portion of the SLIL is disrupted, the arthroscope can usually be passed from the midcarpal space and almost into the radiocarpal space. Patients with this severe degree of injury are best treated with an open operative repair or dorsal ligament reconstruction. With complete LTIL injuries, debridement alone has not been effective, and concomitant joint pinning has been recommended.^{611,14,15} If symptoms persist, an open lunotriquetral intercarpal fusion is sometimes necessary.

Triangular Fibrocartilage Complex Injuries

The TFCC is a complex structure that comprises the articular disk, meniscal homologue, the dorsal and palmar radioulnar

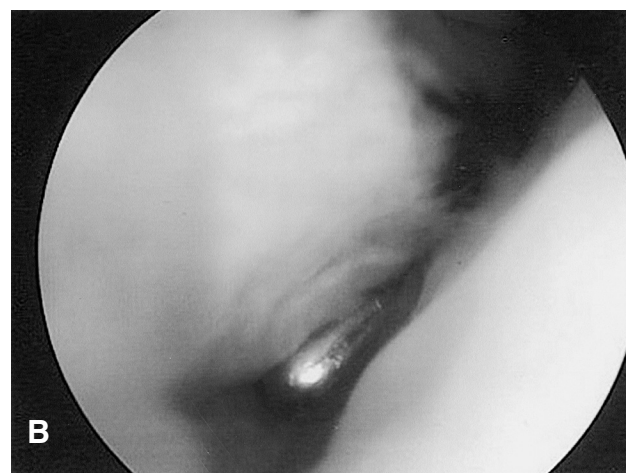
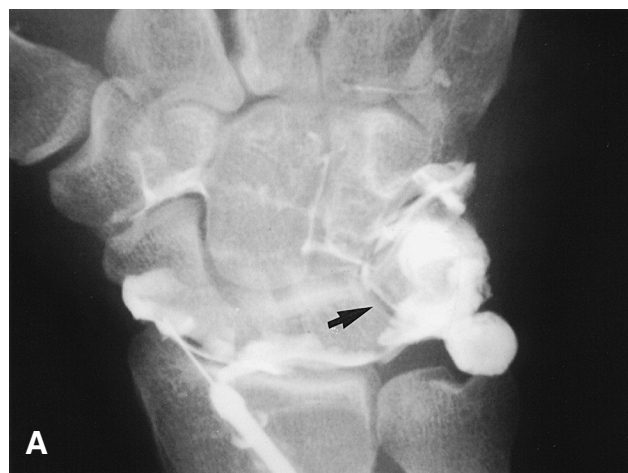

Figure 2 **A**, A 52-year-old male with chronic pain and tenderness over the lunotriquetral joint that did not respond to nonoperative treatment. An arthrogram showed leakage of dye through the lunotriquetral joint (arrow). **B**, Arthroscopic surgery confirmed the tear of the LTIL with separation of the bones.

Table 2 Class I – Traumatic Injuries

Class IA:	Tear/Perforation of central portion of articular disc
Class IB:	Avulsion of articular disc from its insertion into the ulna, with or without a fracture of the styloid
Class IC:	Peripheral tear of articular disc from lunate or triquetrum, with or without ulnocarpal instability
Class ID:	Avulsion of articular disc from its radial attachment on the radius

ligaments, the ulnolunate and ulnatriquetral ligaments, the ulnar capsule, and the sheath of the ECU tendon. The TFCC stabilizes the distal radioulnar joint (DRUJ) and ulnar side of the carpus, and also serves as a load bearing structure. Approximately 20% of the load across the wrist traverses the TFCC and is transmitted to the forearm.^{711,16} This percentage increases with positive ulnar variance. Positive ulnar variance is usually static, but it can also be dynamic and increases with forceful grip and forearm pronation.

The articular disc originates on the ulnar border of the distal articular surface of the radius and inserts into the base of the ulna styloid and the fovea of the ulna head. The ulnolunate and ulnatriquetral ligament components of the TFCC insert on the lunate, triquetrum, and hamate bones as well as on the base of the fifth metacarpal. The blood supply to the TFCC is from branches of the ulnar and anterior interosseous arteries. The blood supply to the articular disc nourishes 15% to 20% of its periphery in a U-shaped fashion.^{816,17} The radial and central aspects of the disc are avascular and consequently have poor healing potential.

In 1989, Palmer classified lesions of the TFCC and divided them into two types, class I traumatic injuries and class II degenerative lesions⁹¹⁸ (Table 2). Traumatic injuries (class I) are subtyped based on location of the lesion, and degenerative lesions (class II) are subtyped depending on the degree of chondromalacia involving the ulna head and lunate and the degree of damage to the LTIL. Palmer's classification system serves as a useful treatment guide.

Traumatic Injuries (Class I A-D)

Class IA injuries are traumatic tears of the central portion of the articular disk. Since this portion of the disc is avas-

cular, tears at this site are unlikely to heal. In patients who remain symptomatic after a trial of wrist immobilization, arthroscopic debridement is indicated. In up to 90% of patients, pain will be eliminated or substantially reduced.¹⁹⁻²² Debridement is generally performed with the arthroscope in the 3-4 portal and a power shaver and/or electrocautery in the 6R portal (Fig. 3). It is important to leave a peripheral rim of 2 mm of the disc in order to avoid injury to the ulnocarpal ligaments that could lead to DRUJ instability.

Class IB lesions are peripheral tears of the articular disc at its ulnar attachment. They are often associated with injuries to the ECU subsheath and DRUJ instability. These tears result in a decrease in tension that normally exists in an intact articular disc. This is reflected in a loss of the normal trampoline effect when the disc is pressed with a probe (Fig. 4). Since the periphery of the disc has a good supply, these lesions are amenable to surgical repair using either an inside-out or outside-in technique.

The inside-out technique was described, in 1994, by Elkmann and Poehling.²³ With the arthroscope in the 4-5 portal or 6R portal, a 20-gauge Touhy epidural needle is inserted through the 1-2 or 3-4 portal and "captures" the torn edge of the disc. The needle is pushed through the capsule and skin to emerge just distal to the ulna styloid. One end of a suture is threaded through the needle and the other end is held outside the skin. The needle is pulled back into the joint, inserted into another segment of the torn edge of the disc and pushed through the skin again. Both ends of the suture are now outside the skin, and they are then tied over a padded button on the skin surface or preferably directly over the joint capsule. The latter method reduces the likelihood of injury to the dorsal sensory branch of the ulnar nerve.

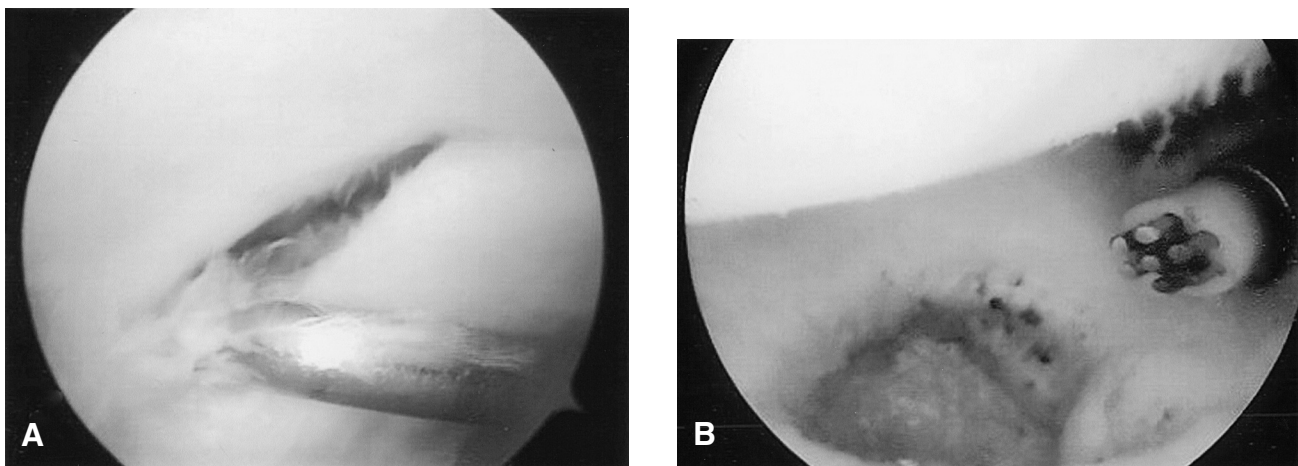


Figure 3 A, Traumatic class 1B tear of the articular disc. B, Electrocautery debridement of the tear.

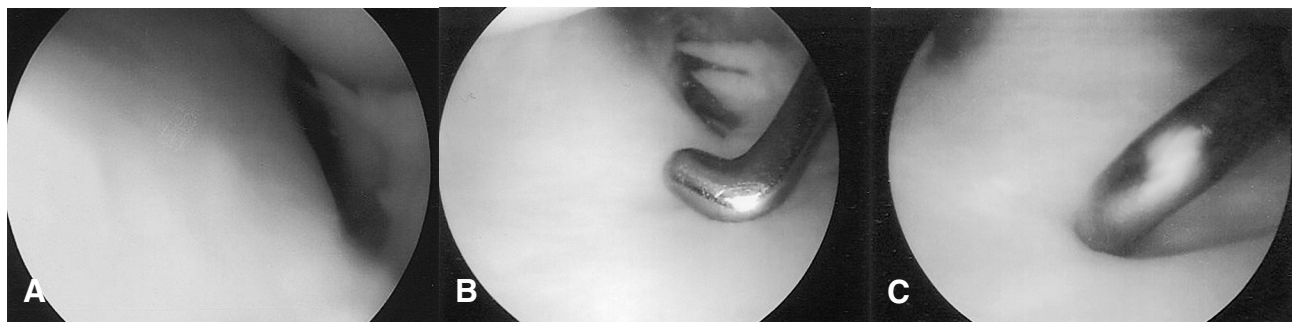

Figure 4 A, Normal articular disc with a prestyloid sulcus. B, The disc was resistant to deformation by a probe (normal trampoline effect). C, Articular disc in another patient was soft when pressed with a probe.

Tying the knot directly over the capsule is accomplished by incising the skin between the ends of the sutures and bluntly dissecting down to the capsule. If necessary, a second suture can be similarly placed in the torn edge of the disc.

The outside-in technique is a more commonly used technique and involves inserting a needle from the ulnar side of the wrist through the torn edge of the disc to emerge into the joint (Fig. 5). A second needle is similarly inserted adjacent to the first needle. Both needle tips should be clearly visualized in the joint. A suture is then threaded through one of the needles and is brought back through the other needle using a suture retriever snare. The suture is then tied over a padded button on the skin or directly over the floor of the ECU tendon sheath.²⁴ The latter method is preferred and involves making an incision in the area of the 6R portal, exposing and incising the tendon sheath and retracting the ECU tendon. The needles can also be initially inserted through the floor of the tendon sheath and the knot tied at that location.

The postoperative management is the same for both types of repairs. The wrist and forearm are immobilized for approximately six weeks, and the patient is then started on a therapy program. Results of repair of Class IB lesions have been successful, with good to excellent results reported in 85% to 90% of patients.²⁴⁻²⁷ Grip strength improved to at least 75% of the opposite hand, and postoperative wrist motions to approximately 90% of the opposite limb.

Class IC lesions are also located peripherally but on the volar edge of the articular disc. These lesions can be associated with ulnocarpal instability resulting from avulsion of the ulnocarpal ligaments from the lunate and triquetrum. Arthroscopic repair is difficult, and usually an open operative reconstruction is required.

Class ID lesions are avulsions of the articular disc from the sigmoid notch of the distal radius and are frequently as-

sociated with intra-articular fractures of the distal radius.²⁸ Due to the poor vascularity of the radial attachment of the disc, controversy exists as to the appropriate treatment, particularly when there is no associated radius fracture. When the DRUJ is stable, debridement of the tear alone will usually suffice. However, when the DRUJ is unstable, repair has been recommended. Arthroscopic repairs of class ID lesions have been described with good to excellent results in 67% of cases.²⁹ Postoperative wrist motions and grip strength were approximately 85% of the opposite limb.

Degenerative Lesions (Class IIA-E)

Degenerative lesions of the TFCC are class II lesions (Table 3). Arthroscopic debridement is usually effective when conservative measures fail and there is no ulnar positive variance. With positive variance (static or dynamic), debridement alone is usually not effective.^{30,31} In these cases, some type of ulnar shortening procedure is usually necessary in order to unload the ulnar side of the wrist. These procedures include a wafer resection of the distal ulna, a shortening osteotomy of the ulna, or resection of the head of the ulna.^{32,33} A wafer resection is the only procedure that can be performed arthroscopically. It is often effective in patients who have less than 3 mm of positive ulnar variance and whose LT joint is stable. The first part of the operation involves debriding the central portion of the degenerative articular disc, followed by burring down the distal ulna to a level 1.0 mm to 2.0 mm below the articular surface of the radius. The power burr is usually inserted through the 6R portal. Good to excellent results have been reported in approximately 90% of cases.^{33,34} Wafer resections are usually inadequate when there is LT instability. In these cases, an ulna-shortening osteotomy will more effectively unload the ulnar side of the wrist. Shortening the ulna tightens the

Table 3 Class II – Degenerative Lesions

Class IIA:	Wear of horizontal portion, no perforation
Class IIB:	Wear of horizontal portion + chondromalacia of lunate or ulna
Class IIC:	Perforation + chondromalacia of lunate or ulna
Class IID:	Perforation + chondromalacia of lunate or ulna + perforation of LT ligament
Class IIE:	Perforation + chondromalacia of lunate or ulna + perforation of LT ligament + ulnocarpal arthritis

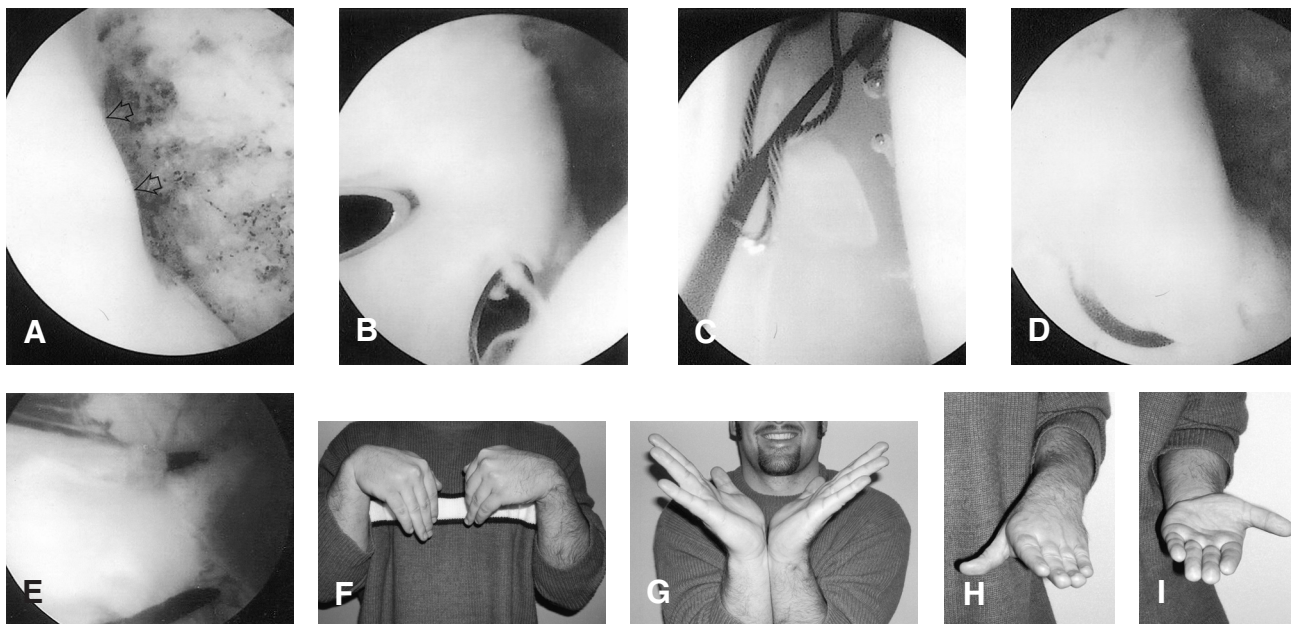


Figure 5 Outside-in technique for repair of a peripheral tear of the articular disc (class IB lesion) in a professional baseball player. Patient had painful clicking on the ulnar side of his left wrist that was disabling and did not respond to nonoperative care. **A**, Hemorrhagic capsule adjacent to peripheral tear of articular disc (arrow). **B**, Two needles were inserted through the torn edge of the disc from the ulnar side of the wrist. **C**, A suture retriever snare was passed through one needle to retrieve the suture that had been threaded into the other needle. **D**, The suture, in place, before being tightened and tied. **E**, The final repair with two sutures in place. **F-I**, The patient regained almost 100% mobility of his wrist and forearm and returned to full sports activities.

ulnocarpal ligaments, thereby restoring LT joint stability. Patients with DRUJ arthritis are not candidates for wafer resections or ulna shortenings; they require resection of the ulna head.

Excision of Dorsal Ganglions

Ganglion cysts are common in the wrist and generally occur in individuals between their 2nd to 5th decades. The majority of ganglia arise from the dorsal portion of the SLIL.³⁵ Surgical excision is usually necessary and a recurrence rate of up to 40% has been reported.^{36,37} However, that is not the experience of most hand surgeons; when the base of the lesion is excised, the recurrence rate is very low. In recent years, arthroscopic excision has been recommended as an option to the traditional open operative procedure.³⁸ The lesion is visualized through the 6R portal and a shaver, inserted through the 3-4 portal, removes that portion of the ganglion's capsule that arises from the SLIL. Although excellent results have been reported with this procedure, the stalk of the ganglion was not visualized in approximately 40% of cases. The advantages of the arthroscopic ganglionectomy as compared to the traditional open operative technique are yet to be determined.

Distal Radius Fractures

The objective of treatment for extra-articular fractures of the distal radius is to restore the normal anatomical parameters of the bone that include its length as well as

the radial inclination and volar tilt of its articular surface. With intra-articular fractures, restoration of joint congruity is of paramount importance. In the past, a 2 mm step-off and 2 mm gap in the articular surface were considered acceptable. However, Knirk and Jupiter reported that traumatic arthritis developed in approximately 90% of patients when there was any step-off of the articular surface and in 100% of patients when the gap at the fracture site was 2 mm or more.³⁹ Currently, the accepted threshold is no step-off and a gap no greater than 1 mm.^{40,41} In order to achieve these thresholds, arthroscopic-assisted reduction of intra-articular fracture fragments has been recommended. Arthroscopy has several advantages over the use of fluoroscopy. It permits the direct visualization of the articular surface of the distal radius, facilitates the detection and management of associated ligament injuries, allows for removal of tiny fracture fragments, and aids in determining when an ulna styloid fracture is associated with disruption of the ulnar attachment of the articular disc. Arthroscopy has been used for reduction and fixation of radial styloid fractures, Barton fractures, die-punch fractures, and comminuted three-part and four-part fractures.⁴²⁻⁴⁹ The ideal time for arthroscopy is generally between three and seven days after the injury. When the procedure is performed earlier than two or three days, there is a risk of increased bleeding from the fracture surfaces. When arthroscopy is performed after seven or eight days, there

is greater difficulty in mobilizing displaced fracture fragments. Arthroscopy is contraindicated in patients with compound fractures, median nerve symptoms, or clinical signs of a compartment syndrome.

Arthroscopic-assisted reduction of intra-articular distal radius fractures requires proper equipment, including fluoroscopy. Traction on the wrist can be applied with the forearm either in a vertical or horizontal position, depending on the preference of the surgeon and the ease of positioning the fluoroscopy machine. A compressive bandage is first wrapped around the forearm to help prevent fluid extravasation, which is the major risk of the procedure. The use of mechanical pumps for fluid inflow should, therefore, be avoided. When normal topographical landmarks on the surface of the wrist are difficult to identify because of soft tissue swelling, arthroscopic portals can be made using fluoroscopic guidance. As in routine arthroscopy, the 3-4 portal is used for the arthroscope, the 4-5 portal is the working portal, and the 6U portal is for fluid inflow or outflow. The initial step is to flush away the blood within the joint in order to visualize the fracture fragments. The radial styloid fragment is first reduced, because it serves as a guide for reducing the remaining portion of the articular surface.⁴² The depressed articular segments can be elevated through a small dorsal metaphyseal window proximal to the fracture site. If necessary, a cancellous autograft or allograft can be inserted through this same window. Once the fracture fragments are reduced, percutaneous wires are inserted to support the articular surface.

Clinical studies have shown the benefit of arthroscopic-assisted reduction of intra-articular fractures. In studies that evaluated the results of fluoroscopic reductions using arthroscopy, approximately one-third of reductions were unsatisfactory due to persistent articular incongruity.^{45,47,48} In a study that compared arthroscopic-assisted reduction with open operative reductions and internal fixation, postoperative wrist motions and grip strength were greater in patients treated arthroscopically.⁴⁸ Patients treated arthroscopically also had a lower incidence of later arthritis because of more accurate reduction of intra-articular fragments. However, there is no consistent association between arthritis and clinical outcome.

The incidence of ligament injuries associated with extra-articular and intra-articular distal radius fractures has been reported to range from 45% to 78% using arthrography and arthroscopy.⁵⁰⁻⁵³ Most injuries involve the articular disc, followed in frequency by injuries to the SLIL and LTIL. Studies have also shown an association between positive ulnar variance and the incidence of articular disc injuries.⁵² Following fracture stabilization, the articular disc is inspected and palpated with a probe in order to test its tension. If the disc is lax and there is an associated ulna styloid fracture (Palmer class IA lesion), the fracture should be fixed. A similar lesion without a

styloid fracture is treated by arthroscopic repair of the articular disc.

Scaphoid Fractures

Internal fixation of nondisplaced scaphoid fractures is an option to the more traditional treatment of cast immobilization, particularly in individuals who would be disabled by prolonged immobilization.^{54,55} Such individuals include surgeons as well as serious amateur and professional athletes, who are anxious to return to their sport activities. Generally, the scaphoid fracture is fixed by percutaneous insertion of a screw using fluoroscopic control. Arthroscopic-assisted internal fixation can also be used, but it is a technique that is more applicable for displaced fractures that are reducible. Currently, there are no long-term studies comparing the results of arthroscopic-assisted fixation of nondisplaced or displaced scaphoid fractures to more common percutaneous or open operative techniques.

Inflammatory Arthritis

Arthroscopic synovectomy is an effective procedure in patients with inflammatory arthritis whose joints have not yet been ravaged by the disease. The main advantage of the procedure over an open operative synovectomy is its ability to more effectively remove synovial tissue in the volar recesses of the radiocarpal and midcarpal joints.^{56,57} Arthroscopic synovectomies are contraindicated in the presence of dorsal tenosynovitis, due to the risk that the portal incisions may further damage tendons that are already at risk for rupture. Arthroscopic proximal row carpectomies have also been performed.⁵⁸ However, there appears to be little, if any, advantage of the procedure over the traditional open technique.

Conclusion

Arthroscopy facilitates the diagnosis of wrist pain in many patients and provides definitive surgical treatment for a wide array of problems. However, arthroscopy does not obviate the need for conventional imaging studies, nor does it eliminate the role for nonoperative treatment.

References

1. Whipple TL, Marotta JJ, Powell JH 3rd. Techniques of wrist arthroscopy. *Arthroscopy*. 1986;2:244-52.
2. Steinberg BD, Plancer KD, Idler RS. Percutaneous wire fixation through the snuffbox: An anatomic study. *J Hand Surg [Am]*. 1995;20:57-62.
3. Gupta R, Bozentka DJ, Osterman AL. Wrist arthroscopy: Principles and clinical applications. *J Am Acad Orthop Surg*. 2001;9:200-9.
4. Adolfsson L. Arthroscopy for the diagnosis of post-traumatic wrist pain. *J Hand Surg [Br]*. 1992;17:46-50.
5. Roth JH, Haddad RG. Radiocarpal arthroscopy and arthrography in the diagnosis of ulnar wrist pain. *Arthroscopy*. 1986;2:234-43.
6. Cooney WP. Evaluation of chronic wrist pain by arthrography,

- arthroscopy, and arthrotomy. *J Hand Surg [Am]*. 1993;18:815-22.
7. Weiss AP, Akelman E, Lambaise R. Comparison of the findings of triple-injection cinerthrography of the wrist with those of arthroscopy. *J Bone Joint Surg Am*. 1996;78:348-56.
 8. Chung KC, Zimmerman NB, Travis MT. Wrist arthrography versus arthroscopy: A comparative study of 150 cases. *J Hand Surg [Am]*. 1996;21:591-4.
 9. Scheck RJ, Romagnolo A, Hierner R, et al. The carpal ligaments in MR arthrography of the wrist: Correlation with standard MRI and wrist arthroscopy. *J Magn Reson Imaging*. 1999;9:468-74.
 10. Geissler WB, Freeland AE, Weiss AP, et al. Techniques in wrist arthroscopy. *Instr Course Lect*. 2000;49:225-37.
 11. Weiss AP, Sachar K, Glowacki KA. Arthroscopic debridement alone for intercarpal ligament tears. *J Hand Surg [Am]*. 1997;22:344-9.
 12. Ruch DS, Poehling GG. Arthroscopic management of partial scapholunate and lunotriquetral injuries of the wrist. *J Hand Surg [Am]*. 1996;21:412-7.
 13. Whipple TL. The role of arthroscopy in the treatment of scapholunate instability. *Hand Clin*. 1995;11:37-40.
 14. Westkaemper JG, Mitsionis G, Giannakopoulos PN. Wrist arthroscopy for the treatment of ligament and triangular fibrocartilage complex injuries. *Arthroscopy*. 1998;14:479-83.
 15. Osterman AL, Seidman GD. The role of arthroscopy in the treatment of lunotriquetral ligament injuries. *Hand Clin*. 1995;11:41-50.
 16. Dailey SW, Palmer AK. The role of arthroscopy in the evaluation and treatment of triangular fibrocartilage complex injuries in athletes. *Hand Clin*. 2000;16:461-76.
 17. Chidgey LK. Histologic and vascular anatomy of the triangular fibrocartilage complex. In: McGinty JB (ed): *Operative Arthroscopy*. (2nd ed). Philadelphia: Lippincott-Raven, 1996, pp. 1005-1014.
 18. Palmer AK. Triangular fibrocartilage lesions: A classification. *J Hand Surg [Am]*. 1989;14:594-606.
 19. Minami A, Ishikawa J, Suenaga N, et al. Clinical results of treatment of triangular fibrocartilage complex tears treated by arthroscopic debridement. *J Hand Surg [Am]*. 1996;21:406-11.
 20. Whipple TL, Geissler WB. Arthroscopic management of wrist triangular fibrocartilage complex injuries in the athlete. *Orthopedics*. 1993;16:1061-7.
 21. Palmer AK. Triangular fibrocartilage disorders: Injury patterns and treatment. *Arthroscopy*. 1990;6:125-32.
 22. Osterman AL. Arthroscopic debridement of triangular fibrocartilage complex tears. *Arthroscopy*. 1990;6:120-4.
 23. Ekman EF, Poehling GG. Principles of arthroscopy and wrist arthroscopy equipment. *Hand Clin*. 1994;10:557-66.
 24. Corso SJ, Savoie FH, Geissler WB, et al. Arthroscopic repair of peripheral avulsions of the triangular fibrocartilage complex of the wrist: A multicenter study. 1997 Feb;13(1):78-84.
 25. Hermansdorfer JD, Kleinman WB. Management of chronic peripheral tears of the triangular fibrocartilage complex. *J Hand Surg [Am]*. 1991;16:340-6. *Arthroscopy*. 1997;13:78-84.
 26. Bednar JM. Arthroscopic treatment of triangular fibrocartilage tears. *Hand Clin*. 1999;15:479-88.
 27. Trumble TE, Gilbert M, Vedder N. Isolated tears of the triangular fibrocartilage: Management by early arthroscopic repair. *J Hand Surg [Am]*. 1997;22:57-65.
 28. Geissler WB, Freeland AE, Savoie FH, et al. Intercarpal soft-tissue lesions associated with intra-articular fracture of the distal end of the radius. *J Bone Joint Surg Am*. 1996;78:357-65.
 29. Sagerman SD, Short W. Arthroscopic repair of radial-sided triangular fibrocartilage complex tears. *Arthroscopy*. 1996;12:339-42.
 30. Friedman SL, Palmer AK, Short WH, et al. The change in ulnar variance with grip. *J Hand Surg [Am]*. 1993;18:713-6.
 31. Tomaino MM. The importance of the pronated grip x-ray view in evaluating ulnar variance. *J Hand Surg [Am]*. 2000;25:352-7.
 32. Trumble TE, Gilbert M, Vedder N. Ulnar shortening combined with arthroscopic repairs in the delayed management of triangular fibrocartilage complex tears. *J Hand Surg [Am]*. 1997;22A:807-13.
 33. Tomaino MM, Weiser RW. Combined arthroscopic TFCC debridement and wafer resection of the distal ulna in wrists with triangular fibrocartilage complex tears and positive ulnar variance. *J Hand Surg [Am]*. 2001;26:1047-52.
 34. Feldon P, Terrono AL, Belsky MR. Wafer distal ulna resection for triangular fibrocartilage tears and/or ulna impaction syndrome. *J Hand Surg [Am]*. 1992;17:731-7.
 35. Angelides AC. Ganglions of the hand and wrist. In: Green DP, Hotchkiss RN, Peterson WC (eds): *Operative Hand Surgery*. (3rd ed). New York: Churchill-Livingstone, 1999, pp. 2172-5.
 36. McEvedy BV. Simple ganglia: A review of the modes of treatment and an explanation for the frequent failures of surgery. *Lancet*. 1965;266:135.
 37. Angelides AC, Wallace PF. The dorsal ganglion of the wrist: Its pathogenesis, gross anatomy and surgical treatment. *J Hand Surg [Am]*. 1976;1:228-35.
 38. Osterman AL, Raphael J. Arthroscopic resection of dorsal ganglion of the wrist. *Hand Clin*. 1995;11:7-12.
 39. Knirk JL, Jupiter JB. Intra-articular fractures of the distal end of the radius in young adults. *J Bone Joint Surg Am*. 1986;68:647-59.
 40. Fernandez DL, Geissler WB. Treatment of displaced articular fractures of the radius. *J Hand Surg [Am]*. 1991;16:375-84.
 41. Trumble TE, Schmitt SR, Vedder NB. Factors affecting functional outcome of displaced intra-articular distal radius fractures. *J Hand Surg [Am]*. 1994;19:325-40.
 42. Geissler WB, Freeland AE. Arthroscopic management of intra-articular distal radius fractures. *Hand Clin*. 1999;15:455-65.
 43. Trumble TE, Culp R, Hanel DP, et al. Intra-articular fractures of the distal aspect of the radius. *J Bone Joint Surg Am*. 1998;80:582-600.
 44. Whipple TE. The role of arthroscopy in the treatment of intra-articular wrist fractures. *Hand Clin*. 1995;11:13-8.
 45. Geissler WB, Freeland AE. Arthroscopically assisted reduction of intra-articular distal radius fractures. *Clin Orthop Rel Res*. 1996;(327):1125-34.
 46. Wolfe SW, Easterling KJ, Yoo HH. Arthroscopic assisted reduction of distal radius fractures. *Arthroscopy*. 1995;11:706-14.
 47. Auge WK, Velazquez PA. The application of indirect reduction techniques in the distal radius: The role of adjuvant arthros-

- copy. *Arthroscopy*. 2000;16:830-5.
48. Edwards CC, Haraszti CJ, McGillivray GR, et al. Intra-articular distal radius fractures: Arthroscopic assessment of radiographically assisted reduction. *J Hand Surg [Am]*. 2001;26:1036-41.
 49. Doi K, Hattori Y, Otsuka K, Abe Y, et al. Intra-articular fractures of the distal aspect of the radius: Arthroscopically assisted reduction compared with open reduction and internal fixation. *J Bone Joint Surg Am*. 1999;81:1093-110.
 50. Mohanti RC, Kar N. Study of triangular fibrocartilage of the wrist joint in Colles' fracture. *Injury*. 1990;11:321-4.
 51. Lindau T, Amer M, Hagberg L. Intraarticular lesions in distal fractures of the radius in young adults: A descriptive arthroscopic study in 50 patients. *J Hand Surg [Br]*. 1997;22:638-43.
 52. Richards RS, Bennett JD, Roth JH, et al. Arthroscopic diagnosis of intra-articular soft tissue injuries associated with distal radial fractures. *J Hand Surg [Am]*. 1997;22: 772-6.
 53. Hixson ML, Walker CW, Fitzrandolph RL, et al. Acute ligament tears of the wrist associated with Colles' fracture. *Orthop Trans*. 1990;14:164-5.
 54. Whipple TL. Arthroscopically assisted internal fixation of acute scaphoid fractures. *Tech Orthop*. 1992;7:19-25.
 55. Taras JS, Sweet S, Shum W, et al. Percutaneous and arthroscopic screw fixation of scaphoid fractures in the athlete. *Hand Clin*. 1999;15:467-73.
 56. Adolfsson L, Frisen M. Arthroscopic synovectomy of the rheumatoid wrist. A 3.8 year follow-up. *J Hand Surg [Br]*. 1997;22:711-3.
 57. Atik TL, Baratz ME. The role of arthroscopy in wrist arthritis. *Hand Clin*. 1999;15:489-94.
 58. Culp RW, Osterman AL, Talsania JS. Arthroscopic proximal row carpectomy. *Tech Hand Upper Extremity Surg*. 1997;1:116-9.