

# Primary Yolk Sac Tumor of the Endometrium—A Case Report and Literature Review

Huijuan Ge

Shanghai Cancer Hospital: Fudan University Shanghai Cancer Center <https://orcid.org/0000-0003-1059-4212>

Rui Bi (✉ [br\\_fdcc@163.com](mailto:br_fdcc@163.com))

fudan shanghai cancer center

---

## Case Report

**Keywords:** yolk sac tumor (YST), endometrial, SALL4, differential diagnosis, prognosis

**DOI:** <https://doi.org/10.21203/rs.3.rs-112932/v1>

**License:** © ⓘ This work is licensed under a Creative Commons Attribution 4.0 International License. [Read Full License](#)

---

# Abstract

## Background

Primary yolk sac tumor (YST) of the endometrium is extremely rare. We report a case of endometrial YST and review the literature to provide a comprehensive understanding of the diagnosis and management of primary YST of the endometrium.

## Methods

A 43-year-old woman with primary YST of the endometrium is described. We summarize the clinical characteristics, treatments and prognosis of the case reported herein and 29 cases from the literature.

## Results

In a total of 30 primary endometrial YSTs, the average patient age was 52 years (range, 24-87 y). The mean tumor size was 6.94 cm (range 1.3-19.0 cm). Increasing serum levels of AFP were observed in all but one patient. Stage I was more common (12/30, 40%), followed by stages II (5/30, 17%), III (6/30, 20%) and IV (7/30, 23%). Of all 30 patients, 17 (57%) had pure endometrial YST, and 13 (43%) had a concomitant somatic neoplasm representing between <10% and 90% of the tumor, of which endometrial adenocarcinoma was the most common. Patients with pure YST were younger than those with concomitant somatic tumors (ranging from 24-68 years, mean 44.41 years vs. range 28-87 years, mean 61.92 years,  $P=0.008$ ). Endometrial YSTs with somatic neoplasms had a poorer prognosis than pure YSTs.

## Conclusion

Primary YST of the endometrium is an extremely rare disease. Surgery combined with adjuvant chemotherapy is the most effective treatment. A late stage and combined somatic components may indicate a poor prognosis.

## Background

Yolk sac tumor (YST), also known as an endodermal sinus tumor, is the third most common form of malignant ovarian germ cell neoplasms, followed by dysgerminoma and immature teratomas[1]. It is one of the most common malignant ovarian neoplasms of childhood, adolescence, and early adulthood. Although YST usually originates from the gonads (ovary and testis), it occasionally arises from midline extragonadal regions, such as the sacrococcygeal region, mediastinum, and retroperitoneum. Approximately 20% of female patients experience extragonadal YST (EGYST)[2], and the vagina is the most common site of YST growth in infants and young children[3]. Primary YST of the endometrium is very rare[4]. The first case of primary YST of the endometrium was reported in 1980. [3] To the best of our knowledge, only 29 cases have been reported in the literature to date. We report a new case of primary endometrial YST and have a systematic review of the literature.

## Case Presentation

### Clinical history

A 43-year-old woman was admitted with abnormal vaginal bleeding for 2 months and epigastric pain for 4 months. In the local hospital, she received a transvaginal ultrasound, which showed a hyperechoic endometrial mass. A 4 cm prominent mass was observed on the left side of the uterine isthmus by hysteroscopy. A pelvic computerized tomography (CT) scan revealed a uterine mass with no obvious enlarged lymph nodes. No apparent abnormalities were observed on the abdominal and chest CT scans. A gynecological examination indicated no obvious abnormalities in the abdomen and vagina. An abnormal increasing level of AFP (1465  $\mu\text{g/ml}$ , reference level < 20  $\text{ng/ml}$ ) was observed. The serum  $\beta\text{-HCG}$ , CA125, CA199 and CEA levels were normal. The dilatation and curettage specimen was diagnosed as endometrial carcinoma. To further treatment, the dilatation and curettage specimen was subjected for a consultation diagnosis as primary YST of the endometrium in our hospital.

The patient underwent total abdominal hysterectomy with bilateral salpingectomy, bilateral ovary biopsies, bilateral pelvic lymphadenectomy, para-aortic lymphadenectomy, omentectomy and appendectomy. The intraoperative exploration revealed that the uterus was enlarged equivalent to 50 gestational days. No abnormalities were observed on the surface of the uterus, bilateral ovaries or oviducts, and no enlargement or hardening of the pelvic and abdominal para-aortic lymph nodes was observed.

The serum level of AFP decreased to 193.4  $\text{ng/ml}$  on the first day after the operation. Adjuvant chemotherapy with bleomycin, etoposide, and cisplatin (BEP) was performed for 6 cycles. The tumor response was monitored by serial determination of the serum level of AFP, which was normal before the first cycle of chemotherapy. The serum level of AFP was monitored and abdominal and pelvic MRI scans were taken every 3 months after chemotherapy. The patient remains alive and disease free 15 months after the completion of chemotherapy via a telephone follow-up.

### Pathologic findings

Grossly, the uterus measured 12.5  $\times$  9.5  $\times$  5.5 cm. An area of hemorrhage and necrosis was observed at the lower uterine segment. The residual tumor infiltrated the superficial myometrium, less than half of the myometrium. The tumor did not involve the cervix, fallopian tubes, bilateral ovaries or omentum. The tumor did not exhibit lymph node metastasis (including 12 pelvic lymph nodes and 3 para-aortic lymph nodes). The patient was classified as stage IA according to the FIGO staging system[5].

Microscopically, pure endometrial YST without any other type of germ cell tumor or somatic carcinoma components was found (Fig. 1). A reticular pattern coexisted with papillary growth. The reticulum was a labyrinth of channels lined by primitive cells expanding to form microcysts with flattened, clear atypical epithelial cells. Papillary growth displayed papillary fibrovascular structures in which a central blood vessel with tumor cells projects into the surrounding space (endodermal sinuses, Schiller–Duval bodies (S-D bodies)). Hyaline globules were observed in the cells. The stroma was hypocellular and myxoid.

The specimen was subjected to immunochemical staining on the Ventana Benchmark XT platform. AFP, SALL4, GPC-3 and AE1/AE3 were diffuse positive. PAX8 was focal positive. ER, PR, CD30, OCT4, HNF-1 $\beta$ , Napsin A, and CD117 were all negative expressed (Fig. 2).

## Results

The description of primary YST of the endometrium in the literature is limited to case reports and small series. After systematically reviewing and screening the literature, 19 citations were found. The clinicopathological features, therapies and prognosis of 30 cases (the present case and 29 cases from the literature) are summarized in Table 1.

Table 1  
summary of clinicopathologic features of primary endometrial YSTs.

case	Age	AFP level	Symptoms	Tumour size(cm)	Surgery	Associated Component	Metastasis site	Chemotherapy	Radiotherapy
1[3]	28	380	Metrorrhagia, Pelvic pain	unknow	TAH BSO	None	None	VAC	NO
2[20]	27	1580	Metrorrhagia	2.4	TAH BSO OMT	None	None	VAC	NO
3[21]	24	3600	Abdominal pain	10	SH BSO	None	ovary	VAC	YSE
4[2]	49	NA	Metrorrhagia	1.3	TAH BSO ILD	None	None	No	YES
5[22]	59	25385	Postmenopausal bleeding	Unknow	TAB BSO PLD PALD	EC	Liver	BEP EP	YES
6[10]	65	2306	Watery discharge	7	MRH BSO PLD PALD	carcinosarcoma	LN	TP	NO
7[6]	42	18530	AVB	6	TAH BSO	None	None	PVB	NO
8[18]	30	1762	AVB	6.5	TAH	None	None	BEP	NO
9[16]	29	3593.4	AVB	6.7	MRH LSO PLD PALD	None	None	BEP	NO
10[23]	28	1522	AVB	6	TAH BSO PLD OMT appendectomy, partial sigmoidectomy	EC	Peritoneum omental	PTX, ADM, DDP, CBDCA, MTX, Act-D, VP16, BLM, pingyangmycin, VCR, FUDR, oxaliplatin, CPA	NO
11[24]	31	242.3	Menorrhagia	4	None	None	None	BEP	NO
12[25]	57	31844	Abdominal pain, weight loss	10.5	TAH BSO OMT PLD PALD	None	Liver ovary lung vertebrae	BEP	NO
13[25]	44	30000	AVB, vaginal mass prolapsing	19	TAH BSO OMT PLD PALD	None	None	BEP	NO
14[26]	63	244.6(6wk postoperatively)	Postmenopausal bleeding	12	None	None	Ovary omentum	BEP	NO
15[4]	71	NA	AVB	NA	YES	SC EC	NA	NA	NA
16[4]	55	NA	AVB	NA	Yes	Complex hyperplasia	NA	Yes	YES
17[4]	59	NA	AVB, uterine mass	NA	NA	EC	NA	YES	NO
18[4]	68	NA	AVB, uterine mass	NA	YES	None	NA	YES	NO
19[4]	77	NA	AVB, uterine mass	NA	NA	EC UDC	NA	NA	NA
20[4]	64	NA	AVB	NA	YES	AC	NA	YES	YES
21[4]	87	NA	AVB	NA	YES	AC	NA	YES	NO
22[4]	61	NA	AVB	NA	YES	None	NA	YES	NO
23[4]	63	NA	AVB	NA	YES	MMMT	NA	YES	YES
24[4]	62	NA	AVB	NA	YES	SC	NA	YES	NO

AVB: abnormal vaginal bleeding; TAH: total abdominal hysterectomy; BSO: bilateral salpingo-oophorectomy; OMT: omentectomy; SH: supracervical hysterectomy; PLD: pelvic lymphadenectomy; PALD: paraaortic lymphadenectomy; MRH: modified radical hysterectomy; LSO: left salpingo-oophorectomy

EC: endometrioid adenocarcinoma; SC: serous carcinoma; UDC: undifferentiated carcinoma; AC: Adenocarcinoma; MMMT: malignant mixed Mullerian tumor;

VAC: vincristine, actinomycin D and Cyclophosphamide; BEP: bleomycin, etoposide and cisplatin; EP: etoposide and cisplatin; TP: taxol and cisplatin; PVB: bleomycin, paclitaxel; ADM: adriamycin; DDP: cisplatin; CBDCA: carboplatin; MTX: methotrexate; Act-D: actinomycin D; VP16: etoposide; BLM: bleomycin; FUDR: 5-fluoro-2-deoxy-β-uridine; CPA: cyclophosphamide;

REC: recurrence; DOD: Dead from the disease; NED: No evidence of disease; AWD: Alive with disease; LFT: Lost to follow-up; NA: Not available; AFP: α-fetoprotein

case	Age	AFP level	Symptoms	Tumour size(cm)	Surgery	Associated Component	Metastasis site	Chemotherapy	Radiotherapy
25[4]	77	NA	AVB	NA	YES	SC,CCC,UDC	NA	YES	NO
26[27]	64	15918	Abdominal distension	NA	NA	None	NA	NA	NA
27[17]	27	>800	AVB	5.4	TAH OMT PLD PALD	None	None	TC	NO
28[12]	38	normal	AVB, prolonged menstruation	NA	TAH BSO OMT PLD PALD	CCC	None	BEP	NO
29[28]	68	133.4(6days postoperatively)	AVB	3.3	TAH BSO OMT PLD PALD	None	NO	BEP	NO
30 present	43	1465	AVB, epigastric pain	4	TAH BSO PLD	None	NO	BEP	NO
AVB: abnormal vaginal bleeding; TAH: total abdominal hysterectomy; BSO: bilateral salpingo-oophorectomy; OMT: omentectomy; SH: supracervical hysterectomy; lymphadenectomy; PLD: pelvic lymphadenectomy PALD: paraaortic lymphadenectomy; MRH: modified radical hysterectomy; LSO: left salpingo-oophorectomy									
EC: endometrioid adenocarcinoma; SC: serous carcinoma; UDC: undifferentiated carcinoma; AC: Adenocarcinoma; MMMT: malignant mixed Mullerian tumor;									
VAC: vincristine, actinomycin D and Cyclophosphamide; BEP: bleomycin, etoposide and cisplatin; EP: etoposide and cisplatin; TP: taxol and cisplatin; PVB: bleomycin, cisplatin, paclitaxel; ADM: adriamycin; DDP: cisplatin; CBDCA: carboplatin; MTX: methotrexate; Act-D: actinomycin D; VP16: etoposide; BLM: bleomycin; 5-FU: 5-fluoro-2-deoxy-β-uridine; CPA: cyclophosphamide;									
REC: recurrence; DOD: Dead from the disease; NED: No evidence of disease; AWD: Alive with disease; LFT: Lost to follow-up; NA: Not available; AFP: α-fetoprotein									

Among the 30 primary endometrial YSTs, the average patient age was 52 years (range, 24–87 y). The mean tumor size was 6.94 cm (range 1.3–19.0 cm). The main clinical symptom was abnormal vaginal bleeding. Increasing serum levels of AFP were reported in 18 of 19 patients, whereas normal AFP levels were reported in only 1 patient; the serum level of AFP was not described for the other 11 patients.

Among all 16 of 25 patients who had detailed surgical resection ranges, 3/16 had bilateral adnexal resection. Unilateral and bilateral ovaries were reversed in 1 and 2 patients, respectively. The FIGO stages were as follows: I (n = 11), II (n = 5), III (n = 6), and IV (n = 7). In total, 26/30 (87%) patients underwent chemotherapy after the operation. BEP was the most common chemotherapy regimen in 11/26 patients (42%). Only 6 patients (6/30, 20%) who endured radiotherapy were not sensitive to radiotherapy.

Of all 30 patients, 17 (57%) had pure endometrial YST, and 13 (43%) had a concomitant somatic neoplasm representing < 10–90% of the tumor. The somatic neoplasms followed the histological types endometrial adenocarcinoma (n = 4), carcinosarcoma (n = 2), clear cell carcinoma (n = 1), adenocarcinoma (n = 1), serous carcinoma (n = 1), serous carcinoma and endometrial adenocarcinoma (n = 1), serous carcinoma and clear cell carcinoma (1), and endometrial complex hyperplasia (n = 1). Patients with pure YST were younger than those with a concomitant somatic tumor (ranging from 24–68 years, mean 44.5 years vs. range 28–87 years, mean 61.92 years,  $P = 0.008$ ).

Follow-up information was available in 90% (27/30) of patients, for which the mean follow-up time was 17.25 months (range 2–72 months), 48.1% (13/27) of patients had no evidence of disease during the follow-up time (the longest was more than 72 months), 8 patients died of disease (range 2.5–24 months), and 6 patients were alive with disease (range 7–30 months). The overall survival (OS) and disease-free survival (DFS) rates were 70.4% (19/27) and 48.1% (13/27), respectively.

## Discussion

The histogenesis of extragonadal YST remains speculative and controversial. There are four potential mechanisms by which a germ cell neoplasm can arise in the endometrium[6]. The first is the aberrant migration of primordial germ cells in a lateral direction during embryogenesis, which can remain in the basal layer of the endometrium for many years. The second potential mechanism is metastasis from occult ovarian YST. Residual fetal tissues remaining in the uterus because of an incomplete abortion and somatic cells that have undergone aberrant differentiation by which YST originates in unusual sites are the other two potential mechanisms.

We summarized 30 primary endometrial YSTs: the present case and 29 cases from the literature. Patients with pure YSTs were younger than those with a concomitant somatic tumor. Therefore, pure endometrial YST and endometrial YST with somatic tumors may have had different histogeneses. Pure endometrial YSTs may originate from pluripotent germ cells, while endometrial YSTs with somatic tumors may arise from malignant pluripotent somatic stem cells or possibly via “retrodifferentiation”, by which a differentiated cell transforms into a more primitive form[7]. Reports of ovarian YST arising from an endometrioid carcinoma support this hypothesis[8–10]. YSTs of the female genital tract in older adults are commonly derived from somatic epithelial neoplasms[11].

AFP, a special tumor marker elevated in the vast majority of patients with tumors containing a YST component, is essential for the diagnosis and monitoring of progressiveness. In the overwhelming most endometrial YSTs, AFP is used as a significant follow-up indicator, but only a few patients had normal serum AFP levels [12].

Since primary endometrial YST is rare, pathologists who lack experience and are not familiar with the morphology of YST may make an incorrect diagnosis, especially in biopsy specimens. Moreover, its immunohistochemical profile overlaps between that of YST and carcinoma. AE1/AE3 is positive in both carcinoma and YST, as observed in the current case, and is not a good marker for differential diagnosis[13]. Both HNF-1 $\beta$  and PAX8 can be positive in YST and thus result in an incorrect diagnosis of clear cell carcinoma[14]. However, both marker commonly are patchy positive in YSTs rather than diffuse positive in clear cell carcinoma. SALL4, as a sensitive marker for germ cell tumors, is a useful marker for diagnosis when combined with GPC-3 and AFP[15]. Hence, a panel of markers is necessary for the diagnosis of YST at rare sites.

Given the rarity of primary endometrial YSTs, there is no consensus on the treatment of this extremely rare tumor. Surgery combined with adjuvant chemotherapy is the main treatment. However, the specific resection range remains controversial, and whether ovaries are preserved still needs further study. Among the 30 patients described herein, unilateral ovary reservation was reported in only one patient[16], and bilateral ovary reservation was reported in 2 patients[17][18]. Rossi described a 30-year-old woman with stage II primary endometrial YST treated with simple total hysterectomy[18], preserving the bilateral ovary. The patient remained free of disease for more than 6 years after completion of the therapy. Tao reported a similar case, a 27-year-old woman with stage IA disease[17] who remained free of disease for 14 months after surgery. Wang described a 29-year-old woman with stage II disease who preserved her right adnexa to maintain endocrine function[16] and was alive without recurrence for 39 months. This fact revealed the possibility of treating a young patient with early-stage primary YST of the endometrium with surgery to conserve the ovary. The surgeons effectively retained the patient's ovarian endocrine function and improved her quality of life.

For germ cell tumors, including ovarian YST, the BEP regimen results in high cure rates, even for advanced-stage tumors[19]. However, the outcome for EGYST, especially in endometrial tissue, is less certain. In the literature series, 5/16 (31.3%) patients with pure YST died of disease (range 2 to 24 mo; median, 8 mo), in which 4 of 5 patients were FIGO stage IV, 1 received a regimen of vincristine, vinblastine and cyclophosphamide, 1 (6.2%) was alive with disease (follow-up, 8 mo), and 10/16 (62.5%) had no evidence of disease (range 6 to 72 mo; median follow-up 19 mo). Of the patients in whom an associated somatic tumor was reported, 3/10 (30%) died of their disease, 5/10 (50%) were alive with disease, and only 2/10 (20%) had no evidence of disease. There are too few cases to determine whether the poor prognosis is related to a somatic origin or to the fact that 6/8 (75%) of those who died of disease had FIGO stage III or IV at presentation. These findings suggest that tumor staging and somatic components are 2 important factors that influence the prognosis of patients with endometrial YST, and patients with YST of somatic origin may have a poor prognosis.

## Conclusion

Primary YST of the endometrium, a highly malignant germ cell tumor, is extremely rare. Surgery combined with postoperative chemotherapy is considered effective for the treatment of primary endometrial YST. YST combined with somatic neoplasms may have a worse prognosis. However, additional cases need to be reported to further understand these rare tumors.

## Abbreviations

YST: yolk sac tumor; EGYST: experience extragonadal YST; CT: computerized tomography ; BEP: bleomycin, etoposide, and cisplatin; S-D bodies: Schiller–Duval bodies; AVB: abnormal vaginal bleeding; TAH: total abdominal hysterectomy; BSO: bilateral salpingo-oophorectomy; OMT: omentectomy; SH: supracervical hysterectomy; ILD: iliac lymphadenectomy; PLD: pelvic lymphadenectomy PALD: paraaortic lymphadenectomy; MRH: modified radical hysterectomy; LSO: left salpingo-oophorectomy; EC: endometrioid adenocarcinoma; SC: serous carcinoma; UDC: undifferentiated carcinoma; AC: Adenocarcinoma; MMMT: malignant mixed Mullerian tumor; CCC: clear cell carcinoma; VAC: vincristine, actinomycin D and Cyclophosphamide; BEP: bleomycin, etoposide and cisplatin; EP: etoposide and cisplatin; TP: taxol and cisplatin; PVB: bleomycin, vincristine and cisplatin; PTX: paclitaxel; ADM: adriamycin; DDP: cisplatin; CBDCA: carboplatin; MTX: methotrexate; Act-D: actinomycin D; VP16: etoposide; BLM: bleomycin; VCR: vincristine; FUDR: 5-fluoro-2-deoxy- $\beta$ -uridine; CPA: cyclophosphamide; REC: recurrence; DOD: Dead from the disease; NED: No evidence of disease; AWD: Alive with disease; LFT: Lost to follow-up; NA: Not available; AFP:  $\alpha$ -fetoprotein.

## Declarations

### Acknowledgements

We gratefully acknowledge technical assistance from members of the Department of Pathology, Shanghai Cancer Center.

### Authors' contributions

Rui Bi provided the case and critically revised the manuscript. Huijuan Ge was responsible for the acquisition and interpretation of patient data and manuscript preparation. Bi and Ge performed pathological examination. All authors approved the final manuscript.

### Funding

This research was funded by National Natural Foundation Science of China, grant number NSFC 81802597.

### Availability of data and materials

Scan slides of the case can be provided if required.

### Ethics approval and consent to participate

All procedures followed were in accordance with the ethical standards of the Iwate Medical University and with the Helsinki Declaration. Substitute for informed consent (approval of the institutional review board of Iwate Medical University) was obtained from all patients for being included in the study, as below: This study was approved by the institutional review board Facility Ethical Committee (Fudan University Cancer Center Ethics Committee, China; approval No. 050432-4-121B, 13 December 2012).

### Consent for publication

Not applicable.

### Competing interests

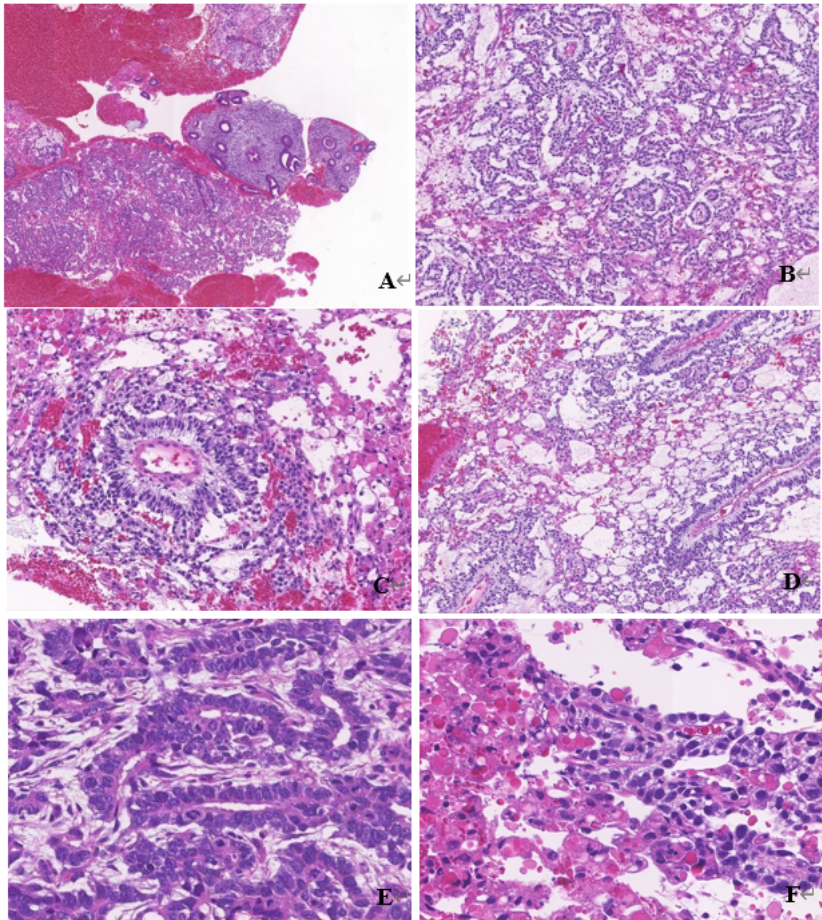
The authors declare that they have no competing interests.

## References

1. Ulbright Tm, Germ cell tumors of the gonads: a selective review emphasizing problems in differential diagnosis, newly appreciated, and controversial issues. *Modern pathology : an official journal of the United States and Canadian Academy of Pathology, Inc*, 2005. null(undefined): p. S61-79.
2. Spatz A, Bouron D, Pautier P, et al. Primary yolk sac tumor of the endometrium\_ a case report and review of the literature. *Gynecol Oncol*, 1998. 31(2): p. 285-288.
3. Pileri S, Martinelli G, Serra L, Endodermal sinus tumor arising in the endometrium. *Obstet Gynecol*, 1980. 56(3): p. 391-396.
4. Ravishankar S, Malpica A, Ramalingam P, et al, Yolk Sac Tumor in Extragonadal Pelvic Sites\_ Still a Diagnostic Challenge. *Am J Surg Pathol*, 2017. 41(1): p. 1-11.
5. Mutch DG and Prat J, 2014 FIGO staging for ovarian, fallopian tube and peritoneal cancer. *Gynecologic oncology*, 2014. 133(3): p. 401-404.
6. Joseph MG, Fellows FG, Hearn SA, Primary endodermal sinus tumor of the endometrium. A clinicopathologic, immunocytochemical, and ultrastructural study. *cancer*, 1990. 65(2): p. 297-302.
7. Nogales FF, Preda O, Nicolae A, Yolk sac tumours revisited. A review of their many faces and names. *Histopathology*, 2012. 60(7): p. 1023-1033.
8. Rutgers JL, Young RH, Scully RE, Ovarian yolk sac tumor arising from an endometrioid carcinoma. *Human pathology*, 1987. 18(12): p. 1296-1299.
9. 9.Nogales FF, Bergeron C, Carvia RE, et al., Ovarian endometrioid tumors with yolk sac tumor component, an unusual form of ovarian neoplasm. Analysis of six cases. *The American journal of surgical pathology*, 1996. 20(9): p. 1056-1066.
10. Oguri H, Sumitomo R, Maeda N, et al., Primary yolk sac tumor concomitant with carcinosarcoma originating from the endometrium: case report. *Gynecol Oncol*, 2006. 103(1): p. 368-371.
11. Mcnamee T, Damato S, McCluggage WG, Yolk sac tumours of the female genital tract in older adults derive commonly from somatic epithelial neoplasms: somatically derived yolk sac tumours. *Histopathology*, 2016. 69(5): p. 739-751.
12. Song L, Wei XX, Wang DQ, Primary yolk sac tumor originating from the endometrium- A case report and literature review. *Medicine*, 2019. 98(15).
13. Chia-Sui K, Muhammad T, Idrees Y, et al, Solid pattern yolk sac tumor: a morphologic and immunohistochemical study of 52 cases. *The American journal of surgical pathology*, 2012. 36(3): p. 360-367.
14. Rougemont AL, Tille JC, Role of HNF1beta in the differential diagnosis from other germ cell tumors. *Human pathology*, 2018.
15. Cao D, Humphrey PA, Allan RW, SALL4 is a novel sensitive and specific marker of ovarian primitive germ cell tumors and is particularly useful in distinguishing yolk sac tumor from clear cell carcinoma. *The American journal of surgical pathology*, 2009. 33(6): p. 894-904.
16. Wang C, Li G, Xi L, et al., Primary yolk sac tumor of the endometrium. *Int J Gynaecol Obstet*, 2011. 114(3): p. 291-293.
17. Lu T, Qi L, Ma Y, et al., Primary yolk sac tumor of the endometrium: a case report and review of the literatures. *Archives of gynecology and obstetrics*, 2019. 300(5): p. 1177-1187.
18. Rossi R, Stacchiotti D, Bernardini MG, et al., Primary yolk sac tumor of the endometrium: a case report and review of the literature. *Am J Obstet Gynecol*, 2011. 204(4): p. e3-4.
19. Gershenson DM, Management of ovarian germ cell tumors. *Journal of clinical oncology: official journal of the American Society of Clinical Oncology*, 2007. 25(20): p. 2938-2943.
20. Ohta M, Sakakibara K, Mizuno K, et al, Successful treatment of primary endodermal sinus tumor of the endometrium. *Gynecol Oncol*, 1988. 31(2): p. 357-364.
21. Magers MJ, Kao CS, Cole CD, et al, "Somatic-type" malignancies arising from testicular germ cell tumors: a clinicopathologic study of 124 cases with emphasis on glandular tumors supporting frequent yolk sac tumor origin. *The American journal of surgical pathology*, 2014. 38(10): p. 1396-1409.
22. Patsner B, Primary endodermal sinus tumor of the endometrium presenting as "recurrent" endometrial adenocarcinoma. *Gynecol Oncol*, 2001. 80(1): p. 93-95.
23. Ji M, Lu Y, Guo L, et al., Endometrial carcinoma with yolk sac tumor-like differentiation and elevated serum beta-hCG: a case report and literature review. *Onco Targets Ther*, 2013. 6: p. 1515-1522.
24. Abhilasha N, Bafna UD, Pallavi VR, et al., Primary yolk sac tumor of the endometrium: A rare entity. *Indian J Cancer*, 2014. 51(4): p. 446.
25. Qzler A, Dogan S, Mamedbeyli G, et al, Primary yolk sac tumor of endometrium: report of two cases and review of literature. *J Exp Ther Oncol*, 2015. 11(1): p. 5-9.

26. Damato S, Haldar K, McCluggage WG, Primary Endometrial Yolk Sac Tumor With Endodermal-Intestinal Differentiation Masquerading as Metastatic Colorectal Adenocarcinoma. *Int J Gynecol Pathol*, 2016. 35(4): p. 316-320.
27. Shokeir MO, Noel SM, Clement PB, Malignant müllerian mixed tumor of the uterus with a prominent alpha-fetoprotein-producing component of yolk sac tumor. *Modern pathology : an official journal of the United States and Canadian Academy of Pathology, Inc*, 1996. 9(6): p. 647-651.
28. Lin SW, Hsieh SW, Huang SH, et al., Yolk sac tumor of endometrium: A case report and literature review. *Taiwan J Obstet Gynecol*, 2019. 58(6): p. 846-848.

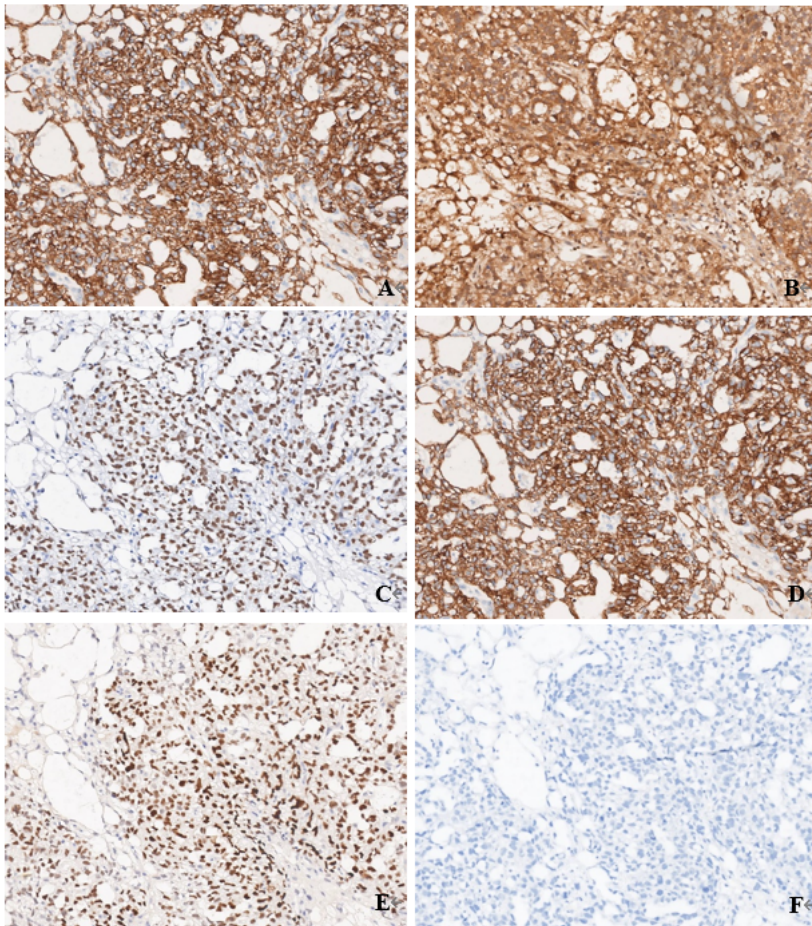
## Figures



**Figure 1**

Histological features of endometrial YST. Multiple separated tumor tissue with a small piece of normal endometrium (A), most area showing a tubulopapillary pattern (B) with classical Schiller–Duval bodies (C), a microcystic or reticular pattern (D) and focal glandular pattern (E), hyaline globules in the cytoplasm (F).





**Figure 2**

Immunocytochemical profile of endometrial YST. Diffuse positive for AFP (A), GPC-3 (B), SALL-4 (C) and AE1/AE3 (D). Focal positive for PAX8 (E) and negative for EMA (F).

## Supplementary Files

This is a list of supplementary files associated with this preprint. Click to download.

- [checklist.pdf](#)