

COMMUNICATIONS

OCULAR MANIFESTATIONS OF ICHTHYOSIS*†

BY

BARRIE JAY, R. K. BLACH, AND R. S. WELLS

Genetic Clinic, Moorfields Eye Hospital, and St. John's Hospital for Diseases of the Skin, London

DURING the past 100 years there have been numerous reports in the literature of the association between ichthyosis and ocular disorders but, because of difficulties in the descriptive classifications of ichthyosis, it has been impossible up to the present to associate any particular ocular manifestation with one form of ichthyosis, except for the occurrence of ectropion with ichthyosis congenita. The recent genetic classification of ichthyosis (Wells and Kerr, 1965) provided an opportunity for attempting to correlate ocular changes with the different genetic varieties of ichthyosis.

Ichthyosis is a condition in which, in the untreated state, there are visible, symmetrically distributed, cutaneous scales that can be removed. It is inherited in nearly all instances and in most patients the condition is apparent in the first year of life. A classification based on the mode of inheritance is given in Table I. The majority of patients with ichthyosis can be classified into one of four categories and these can be distinguished by their mode of inheritance in addition to their clinical (Wells and Kerr, 1966a) and histological characteristics (Wells and Kerr, 1966b). Ichthyosis vulgaris may be inherited as an autosomal dominant or sex-linked (X-linked) recessive trait and in this paper the former will be called ichthyosis vulgaris and the latter sex-linked ichthyosis. There are also two varieties of ichthyosiform erythrodermia: the bullous which is an autosomal dominant and the non-bullous which is an autosomal recessive trait. As with many dermatological disorders, the terminology is often confusing and it may be difficult to determine the diagnosis

TABLE I
GENETIC CLASSIFICATION OF ICHTHYOSIS

Genetic Group	Phenotype Varieties	Other Descriptive Terms
Autosomal Dominant	(a) ICHTHYOSIS VULGARIS (b) BULLOUS ICHTHYOSIFORM ERYTHRODERMIA (c) Ichthyosis hystrix gravior	Ichthyosis nitida or simplex; xerodermia Bullous ichthyosiform hyperkeratosis; epidermolytic hyperkeratosis Ichthyosis cornea
Autosomal Recessive	(a) NON-BULLOUS ICHTHYOSIFORM ERYTHRODERMIA (b) Sjögren-Larsson syndrome (c) Refsum's syndrome	Ichthyosis congenita, larvata or inversa; lamellar ichthyosis
X-linked Recessive	SEX-LINKED ICHTHYOSIS	X-linked ichthyosis; ichthyosis serpentina; ichthyosis vulgaris

* Received for publication June 20, 1967.

† Address for reprints: Genetic Clinic, Moorfields Eye Hospital, City Road, London, E.C.1.

of a patient from a case report when ophthalmological features are recorded without adequate genetic and morphological details.

The ophthalmological literature on ichthyosis has been reviewed by François (1958), Waardenburg, Franceschetti, and Klein (1961), and Duke-Elder (1964, 1965), and only papers relevant to our discussion will be quoted later.

Material and Methods

62 patients with various types of ichthyosis were seen in the Genetic Clinic of Moorfields Eye Hospital, before which they had been examined and classified by one of us (R.S.W.) on genetic, morphological, and histological grounds. They form part of a larger series of patients with ichthyosis, referred by consultant dermatologists from St. John's Hospital for Diseases of the Skin and from many other hospitals in the south of England, the dermatological features of which have been reported elsewhere (Wells and Jennings, 1967).

Each patient had a routine ophthalmological examination, including slit-lamp microscopy and ophthalmoscopy.

Results

The genetic and dermatological diagnoses of the 62 patients in this series are given in Table II.

TABLE II
ICHTHYOSIS: GENETIC AND DERMATOLOGICAL DIAGNOSES

Genetic Group	Number Examined	Phenotype Variety	Number Examined
Autosomal Dominant	25	Ichthyosis vulgaris	22
		Bullous ichthyosiform erythrodermia	3
Autosomal Recessive	11	Ichthyosiform erythrodermia	7
		Sjögren-Larsson syndrome	3
		Unclassified*	1
X-linked Recessive	26	Sex-linked ichthyosis	26

* Patient with ichthyosis of an unusual type, oligophrenia, and arachnodactyly.

Eyelids

Three disorders of the eyelids were seen: ichthyosis of the lids, scales on the lashes, and ectropion of the lower lids. The frequency of these disorders in the various types of ichthyosis is given in Table III, opposite.

When ichthyosis affected the eyelids the skin appeared dry and was covered with small scales, usually white in colour (Fig. 1, opposite). Ichthyosis of the lids occasionally occurred in the dominant and sex-linked recessive forms of the disease, but was more common in the autosomal recessive forms. Scales on the lashes, unlike those seen in blepharitis, were not associated with redness of the lid margins and did not lead to symptoms unless punctate epithelial erosions of the cornea were also present. Ectropion was only seen in the recessive non-bullous ichthyosiform erythrodermia; usually the whole lower lid was involved but in one mild case only the punctum was everted (Fig. 2, opposite).

TABLE III
 ICHTHYOSIS: DISORDERS OF EYELIDS

Variety of Ichthyosis	Number Examined	Disorder of Eyelids	Number Affected
Ichthyosis vulgaris	22	Ichthyosis of lids Scales on lashes	1 8
Bullous ichthyosiform erythrodermia	3	Scales on lashes	1
Non-bullous ichthyosiform erythrodermia	7	Ichthyosis, ectropion, and scales on lashes Ichthyosis and ectropion Ectropion Ichthyosis and scales on lashes Ichthyosis and scales on lashes	1 1 1 1 1
Sjögren-Larsson syndrome	3	Ichthyosis and scales on lashes Ichthyosis and scales on lashes	1 1
Sex-linked ichthyosis	26	Ichthyosis of lids Ichthyosis and scales on lashes Scales on lashes	2 1 10

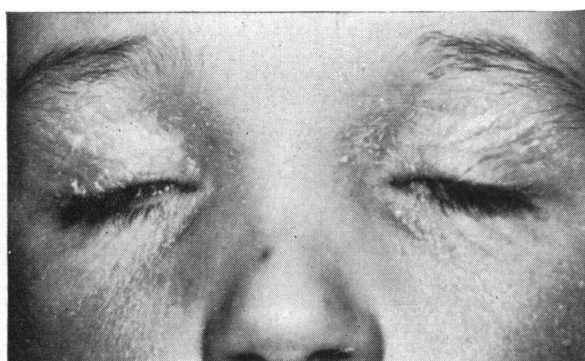
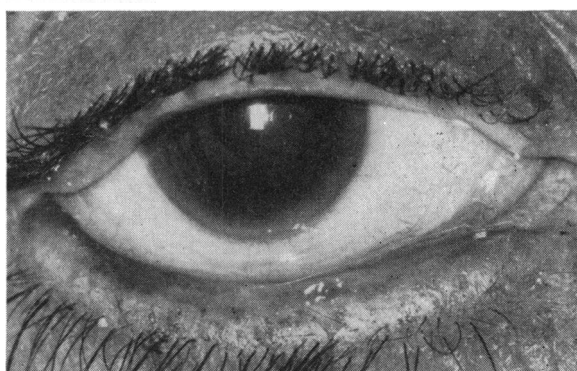
FIG. 1.—Ichthyosis of eyelids and scales on lashes.

FIG. 2.—Ectropion in non-bullous ichthyosiform erythrodermia.



Conjunctiva

This appeared normal in all but the two cases with moderate ectropion where the exposed conjunctiva was thickened and hyperaemic.

Cornea

The main ocular abnormality in ichthyosis was found in the deeper layers of the corneal stroma, but in a few patients epithelial lesions were seen (Table IV, overleaf).

TABLE IV
 ICHTHYOSIS: CORNEAL CHANGES

Variety of Ichthyosis	Number Examined	Patients with Punctate Keratitis	Patients with Stromal Changes
Ichthyosis vulgaris	22	1	3
Bullous ichthyosiform erythrodermia	3	0	0
Non-bullous ichthyosiform erythrodermia	7	1	0
Sjögren-Larsson syndrome	3	0	0
Sex-linked ichthyosis	26	1	14*

* Including one patient with subepithelial stromal keratopathy.

Three patients in this series (with ichthyosis vulgaris, non-bullous ichthyosiform erythrodermia, and sex-linked ichthyosis respectively) had punctate epithelial erosions when examined, and one of these three (with ichthyosis vulgaris) had, in addition, a history of recurrent corneal erosions. One patient with ichthyosis vulgaris, who had the characteristic deep stromal changes of ichthyosis, also had an early band-shaped keratopathy (Fig. 3).

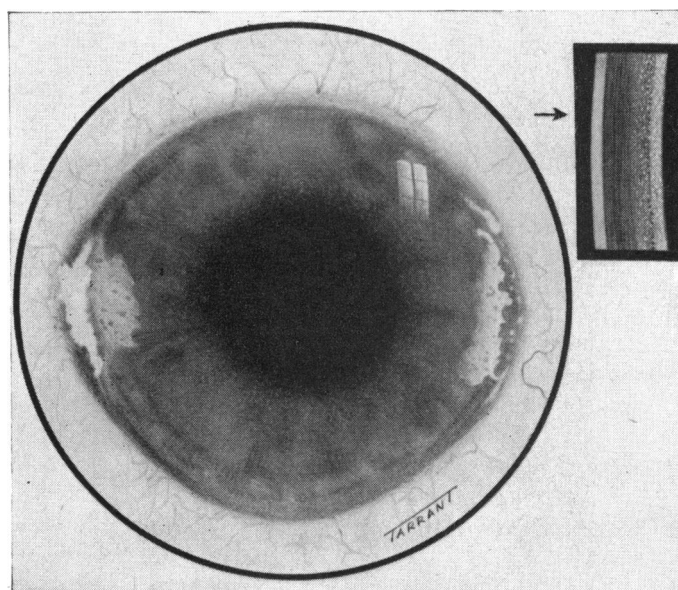


FIG. 3.—Early band-shaped keratopathy in ichthyosis vulgaris. The characteristic deep stromal keratopathy is also present.

The characteristic corneal changes of ichthyosis were found in sixteen patients, thirteen with sex-linked ichthyosis and three with ichthyosis vulgaris. These changes, which were symptomless and did not affect vision, were not seen in patients with bullous ichthyosiform erythrodermia or with autosomal recessive forms of ichthyosis. The changes consisted of multiple, deep, grey, punctate stromal opacities present over the whole extent of the cornea. In mild cases they usually lay just anterior to Descemet's membrane (Fig. 4), although in some cases Descemet's membrane itself appeared to be involved (Fig. 5). In more extensive cases the process appeared to involve the posterior half of the stroma (Fig. 6). Although these deep stromal changes were obvious in the slit-lamp beam, they were more easily seen by retro-illumination of the cornea.

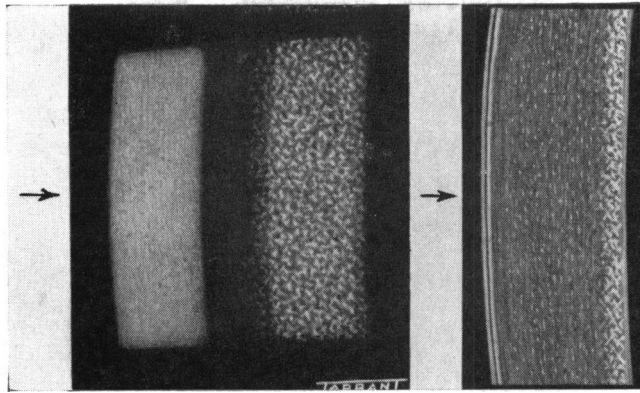


FIG. 4.—Punctate deep stromal opacities just anterior to Descemet's membrane.

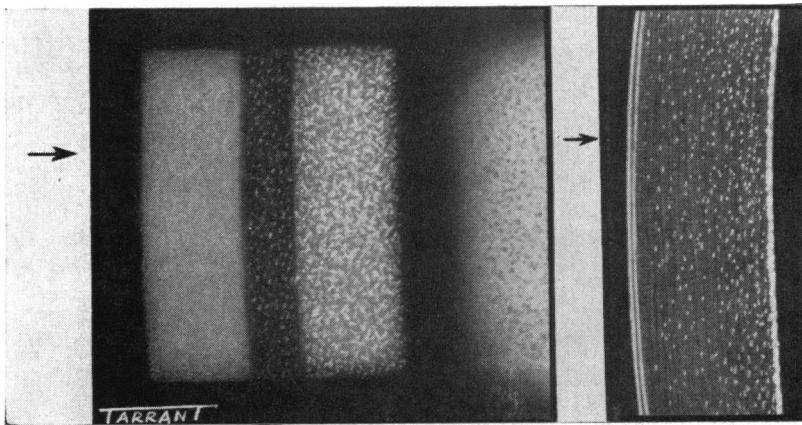


FIG. 5.—Punctate deep stromal opacities involving Descemet's membrane.

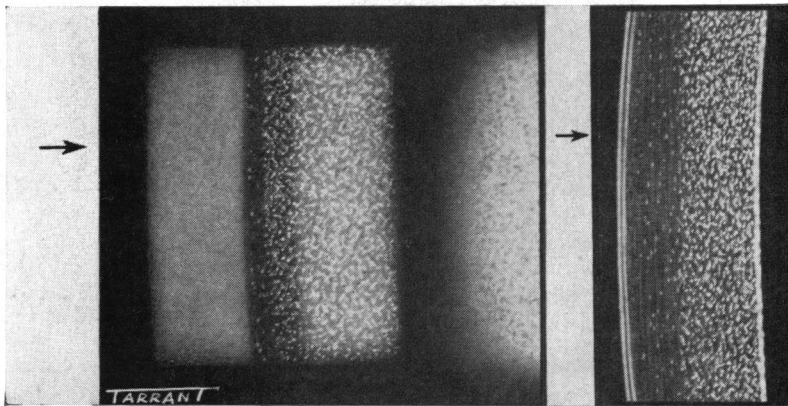


FIG. 6.—Extensive deep stromal opacities involving posterior half of cornea.

When the age of the patient was considered it was apparent that the deep stromal changes became more common with increasing age (Table V, overleaf). This was particularly evident in sex-linked ichthyosis, where these changes were found in all eight patients over the age of 25 years, but in only five out of eighteen under the age of 25 (7, 17, 18, 20, and 20 years respectively).

TABLE V
 ICHTHYOSIS: DEEP STROMAL CHANGES RELATED TO AGE

Age (yrs)	Sex-linked Ichthyosis		Ichthyosis Vulgaris	
	Number Examined	Number Affected	Number Examined	Number Affected
0-10	10	1	2	0
11-20	6	4	5	1
21-30	5	3	5	0
31-40	2	2	1	0
41-50	0	0	3	0
51-60	1	1	6	2
61-70	1	1	0	0
71-80	1	1	0	0

Although the characteristic corneal changes in ichthyosis were situated in the deeper layers of the stroma, one patient with sex-linked ichthyosis had a coarse punctate subepithelial stromal keratopathy (Fig. 7).

In all the patients in this series particular note was made of the appearance of the corneal nerves. Although in a few cases they were easily seen, in only one case were they considered unusually prominent (Fig. 7).

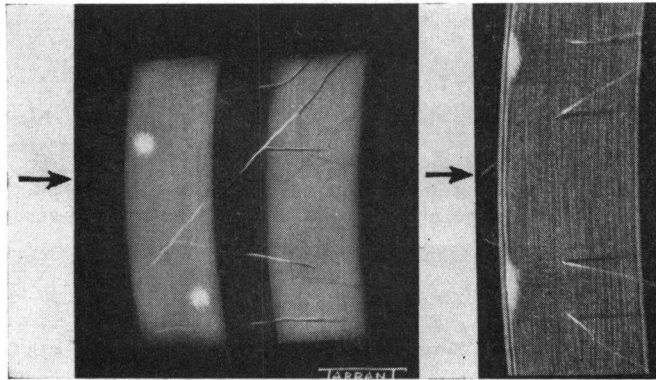


FIG. 7.—Coarse punctate subepithelial stromal keratopathy* and unusually prominent corneal nerves.

* (possibly unrelated to ichthyosis).

Lens

Four patients with ichthyosis vulgaris (all in their sixth decade) and three with sex-linked ichthyosis (aged 54, 62, and 76 years) had lenticular changes of various types. Of the patients with ichthyosis vulgaris, one had cuneiform, one nuclear, one cupuliform, and one coronary and blue-dot opacities. Of the patients with sex-linked ichthyosis, two had cuneiform and one nuclear opacities.

Fundus

The fundi of the patients in this series were essentially normal. It was our impression, however, that a granular pigmentation of the peripheral fundus (Fig. 8) was seen more often than usual. This peripheral granular pigmentation was noted in eight out of 25 patients

with dominant ichthyosis, in two of the seven with non-bullous ichthyosiform erythrodermia, in one of the three with the Sjögren-Larsson syndrome, and in ten of the 26 with sex-linked ichthyosis.

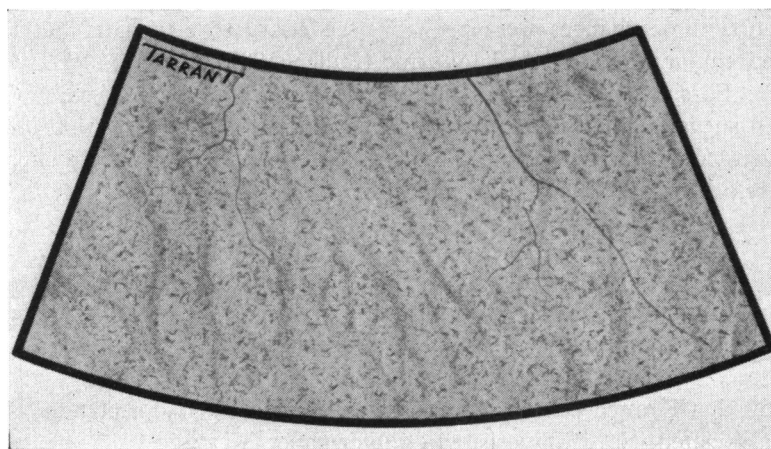


FIG. 8.—Granular pigmentation of the peripheral fundus.

The patient with an unclassified variety of autosomal recessive ichthyosis (ichthyosis of an unusual type, oligophrenia, and arachnodactyly) had myopic crescents around her optic discs and macular pigmentation.

Other Ocular Abnormalities

One patient with sex-linked ichthyosis had the Marcus Gunn lid phenomenon and buphthalmos.

Discussion

Since Arnold (1834) described a case of ichthyosis with ectropion there have been several reports in the ophthalmic literature of this association. In some reported cases a diagnosis of ichthyosiform erythrodermia (Caspary, 1886; Riecke, 1923; Sondermann, 1923; Siemens, 1928; Simizu, 1934; Sannicandro, 1936) or lamellar ichthyosis (Mortada, 1966) can be made from the clinical description. Non-bullous ichthyosiform erythrodermia affects the upper half of the face more than the lower, while the reverse is true of dominant bullous ichthyosiform erythrodermia; in ichthyosis vulgaris the forehead and cheeks are particularly involved while in sex-linked ichthyosis the sides of the face and ears are characteristically affected (Wells, 1966; Wells and Kerr, 1966a). Ectropion develops in ichthyosis because of excessive dryness of the skin and subsequent contracture, so it is in non-bullous ichthyosiform erythrodermia, which particularly involves the upper half of the face, that ectropion might be expected to occur. This is borne out in the present series, where ectropion was seen only in patients with non-bullous ichthyosiform erythrodermia, being present in three of the seven patients with this variety of ichthyosis. Ectropion can be improved by the application of an emollient to the lower eyelids.

Scales on the eyelashes are usually symptomless, but in a few cases they appear to have caused punctate epithelial erosions,

Conjunctiva

In the present series the conjunctiva was normal in all but the two patients with moderate ectropion; in these patients the changes are believed to be due to exposure secondary to the ectropion. Conjunctival changes have been reported in association with ichthyosis; in some reports these changes were probably secondary to ectropion, but the swollen hypertrophied conjunctiva described by some (Buller, 1887; Komoto, 1909; Cordes and Hogan, 1939; Forsius, 1949; Chan, 1950) was not seen in our patients. Cordes and Hogan (1939) suggested that these changes might be secondary to chronic inflammation of the conjunctiva and the absence of these changes in our patients would support a view that they were not primarily ichthyotic in nature.

Cornea

Until the advent of the slit-lamp microscope, corneal changes were described simply as "keratitis" or "secondary scarring". In many reported cases the corneal changes were secondary to an ectropion and were occasionally so severe as to result in perforation. It was not until 1920 that Kraupa described grey stromal opacities "like a plate of glass strewn with sand" associated with ichthyosis. In a later paper (Kraupa, 1923), he described the corneal nerves as being roughened and translucent with terminal filaments ending in brushes. Lejsek (1951) described deep stromal changes similar to those given by Kraupa, although it was Franceschetti and Maeder (1954) who gave the first exact description of the deep stromal changes we found in many of our patients. Friedman (1955), Savin (1956), Franceschetti and Schläppi (1957), and Amalric, Bessou, and Farenc (1965) have described patients with similar deep stromal changes. These changes have been described only in males, but only Savin (1956) and Amalric and others (1965) specified the sex-linked recessive nature of the ichthyosis in their patients. In the present series the thirteen patients with deep stromal changes associated with sex-linked ichthyosis were all males) while one of the three patients with similar stromal changes associated with (dominant, ichthyosis vulgaris was female.

The deep stromal changes described by Franceschetti and Maeder (1954) as dystrophia punctiformis profunda are peculiar to ichthyosis, and although they occasionally occur in ichthyosis vulgaris, they are chiefly seen in sex-linked ichthyosis. These changes were present in all our patients with sex-linked ichthyosis over the age of 25, as well as in some younger patients. It is possible that these changes, which do not in themselves impair vision, affect corneal metabolism in a few cases and may result in band-shaped keratopathy or recurrent corneal erosions.

The punctate appearance of these deep stromal changes may be caused by the presence of abnormal keratocytes and, if this is so, the origin of keratocytes might possibly be ectodermal to fit the known pathology of the skin in ichthyosis.

Superficial corneal changes have been reported by a number of authors. In some cases these changes were probably secondary to ectropion while in others they could well have been secondary to a chronic kerato-conjunctivitis. The small grey elevated nodules reported by Verry (1928) and Vail (1940) are more difficult to explain, as are the changes in the corneal epithelium and superficial stroma reported by Savin (1956). These may be true manifestations of ichthyosis, although similar changes were not found in any of our patients. The punctate epithelial erosions seen in three of our patients were thought to be

secondary to scales on the lashes. The coarse subepithelial opacities seen in one of our patients (Fig. 7) may be unrelated to his ichthyosis. It is remarkable that we found no primary conjunctival or corneal epithelial changes in our series analogous to the skin changes in ichthyosis.

A history of recurrent corneal erosions was given by one of our patients; a similar history was obtained by Savin (1956) and by Amalric and others (1965). All these patients had the deep stromal keratopathy characteristic of ichthyosis.

Band-shaped keratopathy was seen in one patient in the present series, a male with ichthyosis vulgaris who also had the characteristic deep stromal changes. This case is similar to that described by Franceschetti and Schläppi (1957). Hermans (1956) also described a male with band-shaped keratopathy and ichthyosis but did not mention any deep stromal changes.

Thickened corneal nerves, as described by Kraupa (1923), are an unusual accompaniment of ichthyosis. Only one of our patients had unusually prominent nerves.

Lens

There are reports in the literature of the association of ichthyosis and cataracts (Siemens, 1928; Kugelberg, 1934; Sannicandro, 1936; Jancke, 1950; Appelmans, Michiels, and Doyen, 1958; Pinkerton, 1958; Paufigue, Ravault, Moulin, and Bonnet-Géhin, 1963), but in the cases reported there is no characteristic lens change. In our series, senile lens changes were seen in six patients, and congenital coronary and blue-dot opacities in one. The association between ichthyosis and cataracts thus appears to be fortuitous.

Fundus

The increased peripheral granular pigmentation that we observed in many patients in the present series may be nothing more than a normal variation of retinal pigmentation. A similar appearance has, however, been described in a patient with Refsum's syndrome (Nordhagen and Grøndahl, 1964) and in other reports of patients with this syndrome the retinitis pigmentosa is frequently described as "atypical".

Fundus changes have been described in the Sjögren-Larsson syndrome (Sjögren and Larsson, 1957; Wallis and Kalushiner, 1960; Mereu and Careddu, 1961). The three cases of this syndrome in the present series had normal fundi.

Summary

The ocular manifestations in 62 patients with various forms of ichthyosis are described. Ectropion was present only in patients with non-bullous ichthyosiform erythrodermia. Scales on the eyelashes were commonly found; they caused symptoms only when associated with punctate epithelial erosions of the cornea. The conjunctiva was normal in all but two patients with ectropion when the thickened conjunctiva was considered secondary to exposure. A deep stromal keratopathy characteristic of ichthyosis was present in thirteen patients with sex-linked ichthyosis and in three with ichthyosis vulgaris. This keratopathy was present in all patients with sex-linked ichthyosis over the age of 25. The association between ichthyosis and cataract appears to be fortuitous.

This study could not have been carried out without the co-operation of the numerous Dermatologists who referred their cases to us; to them we tender our sincere thanks. We should like to thank Mr. T. Tarrant and other members of the Illustration Department of the Institute of Ophthalmology for preparing the illustrations.

REFERENCES

- AMALRIC, P., BESSOU, P., and FARENC, M. (1965). *Bull. Soc. Ophtal. Fr.*, **65**, 724.
- APPELMANS, M., MICHIELS, J., and DOYEN, N. (1958). *Bull. Soc. belge Ophtal.*, **118**, 391.
- ARNOLD (1834). "Med. Korresp.-Bl. d. Wuttemb. arztl. Vereins", No. 21. Cited by Duke-Elder (1964) in "System of Ophthalmology", vol. 3. Kimpton, London.
- BULLER, F. (1887). *Trans. Amer. Ophthal. Soc.*, **4**, 582.
- CASPARY, J. (1886). *Vjschr. Derm. Syph.*, **13**, 3.
- CHAN, E. (1950). *Chin. med. J.*, **68**, 378.
- CORDES, F. C., and HOGAN, M. J. (1939). *Arch. Ophthal. (Chicago)*, **22**, 590.
- DUKE-ELDER, S. (1964). "System of Ophthalmology", vol. 3, part 2, pp. 539, 882. Kimpton, London.
- (1965). *Idem.*, vol. 8, part 1, p. 548, part 2, p. 951.
- FORSIUS, H. (1949). *Acta ophthal. (Kbh.)*, **27**, 573.
- FRANCESCHETTI, A., and MAEDER, G. (1954). *Bull. Soc. franç. Ophtal.*, **67**, 146.
- and SCHLÄPPI, V. (1957). *Dermatologica (Basel)*, **115**, 217.
- FRANÇOIS, J. (1958). "L'Hérédité en Ophtalmologie", p. 742. Masson, Paris.
- FRIEDMAN, B. (1955). *Amer. J. Ophthal.*, **39**, 575.
- HERMANS, M. R. (1956). *Bull. Soc. belge Ophtal.*, No. 113, p. 316.
- JANCKE, G. (1950). *Klin. Mbl. Augenheilk.*, **117**, 286.
- KOMOTO, J. (1909). *Ibid.*, **47**(1), 259.
- KRAUPA, E. (1920). *Ibid.*, **65**, 903.
- (1923). *Ibid.*, **70**, 396.
- KUGELBERG, I. (1934). *Ibid.*, **92**, 484.
- LEISEK, J. (1951). *Čs. Oftal.*, **7**, 47.
- MEREU, T., and CAREDDU, P. (1961). *Minerva pediat. (Torino)*, **13**, 1611.
- MORTADA, A. (1966). *Ophthalmologica (Basel)*, **152**, 68.
- NORDHAGEN, E., and GRØNDAHL, J. (1964). *Acta ophthal. (Kbh.)*, **42**, 629.
- PAUFIQUE, L., RAVAUULT, M.-P., MOULIN, G., and BONNET-GÉHIN (1963). *Bull. Soc. Ophtal. Fr.*, **63**, 240.
- PINKERTON, O. D. (1958). *A.M.A. Arch. Ophthal.*, **60**, 393.
- RIECKE, E. (1923). *Münch. med. Wschr.*, **70**, 379.
- SANNICANDRO, G. (1936). *Arch. ital. Derm.*, **12**, 84.
- SAVIN, L. H. (1956). *Brit. J. Ophthal.*, **40**, 82.
- SIEMENS, H. W. (1928). *Arch. Derm. Syph. (Berl.)*, **156**, 624.
- SIMIZU, S. (1934). *Acta Soc. ophthal. jap.*, **38**, 451.
- SJÖGREN, T., and LARSSON, T. (1957). *Acta psychiat. neurol. scand.*, **32**, Suppl. 113.
- SONDERMANN, G. (1923). *Klin. Mbl. Augenheilk.*, **70**, 180.
- VAIL, D. (1940). *Arch. Ophthal. (Chicago)*, **24**, 215.
- VERRY, C. D. (1928). *Klin. Mbl. Augenheilk.*, **80**, 830.
- WAARDENBURG, P. J., FRANCESCHETTI, A., and KLEIN, D. (1961). "Genetics and Ophthalmology", pp. 291, 473, 514, 905. Blackwell, Oxford.
- WALLIS, K., and KALUSHINER, A. (1960). *Ann. paediat. (Basel)*, **194**, 115.
- WELLS, R. S. (1966). *Brit. med. J.*, **2**, 1504.
- and JENNINGS, M. C. (1967). *J. Amer. med. Ass.*, **202**, 485.
- and KERR, C. B. (1965). *Arch. Derm.*, **92**, 1.
- (1966a). *Brit. med. J.*, **1**, 947.
- (1966b). *J. invest. Derm.*, **46**, 530.