

**FOUNDATION FOR GASTROINTESTINAL SURGERY
DAVOS**



**DAVOS
COURSE**
GI SURGERY

MANUSCRIPT

FOR PRACTICAL EXERCISES

**INTERNATIONAL
GASTROINTESTINAL SURGERY WORKSHOP
at
CONGRESS CENTER DAVOS, SWITZERLAND**

www.davoscourse.ch

Preface

The Davos Postgraduate Training Course

The A.O. Davos practical postgraduate training course in orthopaedic surgery came into being in 1978. It soon became the prototype of modern practical operative training courses. Those so-called “hands-on” courses met the demands of young surgeons and became very popular indeed. Gastrointestinal surgeons greatly envied their colleagues having access to these training courses, which evolved into a perfect mode of training in the course over the following years due to the creation of artificial bones and other training models.

Tentative ideas by Professor Martin Allgöwer, one of the initiators of these AO courses, for the development of such training courses for gastrointestinal surgeons were bound to fail due to the non-availability of suitable training models. The plan for the GI-course was put aside but none the less not forgotten.

Martin Allgöwer himself took up this idea again when by chance he met Oscar Baldomero and Barry Logan, the conservators at the Royal College of Surgeons of England. Prof. M. Allgöwer saw for the first time the special specimens of intestinal organs O. Baldomero had prepared. These particular specimens were prepared in such a manner as to be ideal to handle, so that Martin Allgöwer returned from England enthusiastic about renewing the idea of the GI-course. The idea became reality. The perfect infrastructure of the Davos Congress Center recommended itself for these training courses. Oscar Baldomero was recruited and demonstrated his models at the time to a small group of surgeons, who later became the Founding Faculty of the GI-courses and Davos Course Foundation.

In addition to this great achievement, Martin Allgöwer deserves the highest respect for another extraordinary accomplishment. In the Founding Faculty of the GI-courses he managed to assemble seven different surgical schools. The criteria of his selection will forever be his secret: Rumour has it that the ability to ski played a significant role! The chiefs of Heidelberg, Freiburg, two from Munich, Mannheim, Basel and Chur, were not prepared for this and collided head on during the preparatory talks, and moreover during the first GI-course in Davos. Every single one of them had worked with and was convinced of the traditional or newly developed suture techniques in his own department. It must be pointed out that in those days suture techniques were the *brand names* of each surgical school. To successfully guide a group of renowned and autonomous surgeons into a **Unité de Doctrine** is the other outstanding achievement of Martin Allgöwer. It has to be mentioned that the extra mucosal and “one row” suture technique, which then became the **Davos Suture Technique**, was so compelling, simple, safe, that not only the personality of Martin Allgöwer, but the issue itself slowly convinced all members of the Founding Faculty, resulting eventually in the current **Unité de Doctrine**.

Thus the ***Davos Suture Courses*** were born. They grew and expanded continually, new training programmes were drawn up, automatic suture devices were included and eventually the course was extended to include the newly developing laparoscopic techniques and since some years also virtual reality training. The Davos GI-Course was very much alive and continued to adapt to new surgical developments.

For 31 years the Founding Faculty led these postgraduate courses very successfully and created the brand name of "***Davos Suture Course***". The concept was so successful and convincing that it has become an international trademark for a much sought after training model. 31 years match a generation. It is only natural that the Founding Faculty has now left the *Davos Course* and has gradually been replaced by younger faculty members of the next generation.

In the course of time, the faculty has completely renewed itself, but, as always in life the achievements of the founding generation quickly fall into oblivion. It is the duty of the contemporary witnesses to keep the memories alive.

Univ.-Prof. Dr. Dr. h.c. J. Rüdiger Siewert
Ärztlicher Direktor
Universitätsklinikum Freiburg
Hugstetter Strasse 49
D79095 Freiburg
Germany

Dear Participants of the Practical Course in Gastrointestinal Surgery

This handbook has been designed to accompany the practical exercises of the workshop. The descriptions apply to the exercises on the models and on the prepared intestinal organs. They are not intended to replace the standard descriptions in the surgical literature. A more detailed account of actual operations is given during the lectures on the course. Please feel free to seek further advice from your table instructors.

We hope you find the course instructive and enjoyable.

There is a variety of anastomoses techniques to perform. The theme of this course is to reduce these options to 5 safe basic suture techniques.

1. The extramucosal running suture technique
2. The extramucosal interrupted suture technique
3. The back wall running suture
4. The back wall interrupted mattress suture
5. The back wall suture in the so called "lift"-technique
6. The full thickness suture for oesophagus and bile duct.

The extramucosal technique picks up all the layers of the bowel including the strong collagenous layer of the submucosa, but avoids penetrating the mucosal lining itself. It is applied to those situations, where the bowel can be viewed from its serosal aspect, or where it can be rotated to achieve this view.

We recommend using the full thickness back wall suture when the bowel can not be rotated, and where, because of its fixation, it can only be viewed from its mucosal aspect.

The choice between using the interrupted and the running technique is optional. The running technique is quicker and is more certain to achieve hemostasis, but there is a risk of producing a purse string effect when used in narrow tubes. The interrupted technique is more precise, but is time-consuming. It has a special place in paediatric gastrointestinal surgery, because of the small diameter of the bowel in children.

The back wall suture in "lift"-technique is suited for all anastomoses, which are not within easy reach (low rectum, oesophagus, common bile duct). The resection margins are approached by means of prelaid sutures and adapted along the stretched threads ("lift").

The Organizing Committee

Table of Content

I. Laparoscopic Surgery	9
Practical Exercises	10
II. Conventional Surgery	19
Basics in Gastroenterological Surgery and Suture Techniques	20
Extramucosal Single-Layer Suture on Mobile GI-Segments / Interrupted Suture	23
Extramucosal Single-Layer Anastomotic Technique / Continuous Suture	24
Single-Layer Suture on Immobile GI-Segments / Interrupted Suture	26
“Cross-Section”-Gastroenterostomy	27
Gastric Resection: Billroth I / Single-Layer Running Seromuscular	
Gastroenterostomy	28
Billroth II partial gastrectomy	30
Esophago-Jejunostomy (Roux-Y) / Hand Suture	31
Esophago-Jejunostomy / Stapler Technique	32
Anterior Resection / Hand Suture	34
Anterior Resection / Stapler Technique	37
Hepatodocho-jejunosotomy / Interrupted Suture	39
Pancreatico-Jejunosotomy.....	40
Stoma placement	42
 Annexe: Suture Techniques	 43
Authors Index	46

I. Laparoscopic Surgery Practical Exercises

Edited by

**P. Vogelbach
T. Kocher
W.E.G. Thomas**

Laparoscopic Surgery Practical Exercises

R. Bumm, Alfeld, C.T. Hamel, Lörrach, T. Kocher, Baden, J. Metzger, Luzern, H.-D. Saeger, Dresden, W. E.G. Thomas, Sheffield, P. Vogelbach, Dornach

Equipment, instruments and training box (pelvitrainer)

Laparoscopic operative techniques require special equipment and instruments. All these are available at every table during the exercises. A training box is simulating the patient. The cover of the training box can be removed. The equipment consists of a laparoscope, the camera-video-monitor system and a light source. Every table is equipped with electrocoagulation units including cables and connections to the training box. The electrocoagulation will be needed during the exercise, when working with organic material.

The laparoscopic instruments are available as permanent or disposable trocars, graspers, scissors etc.

At every table 2 participants will work as a team during the exercises. They will have the following functions:

1. operator
2. assistant: camera(wo)man

These functions should be changed during the exercises. Every exercise will be explained beforehand by videos (with commentary).

Introduction of trocars

See video demonstration

Responsibilities of the team-members

See video demonstration

Laparoscopic Surgery

Practical Exercises

R. Bumm, Alfeld, C.T. Hamel, Lörrach, T. Kocher, Baden, J. Metzger, Luzern, H.-D. Saeger, Dresden, W. E. G. Thomas, Sheffield, P. Vogelbach, Dornach

Transport of matches

Instruments

1x10 mm trocar, 2x5 mm trocars, 2x grasping forceps

Material

1 match-box filled and one empty, 4 pins, 1 training-plate with hooks and eyes

Exercise

A filled and an empty match-box are fixed close to one another at the cork-plate. A training plate with hooks and eyes is fixed in a special area of the pelvitainers' base. Introduction of a 10 mm trocar and two 5 mm trocars with a distance of about 5 cm from one another. The laparoscope is introduced through the 10 mm trocar, the 2 grasping forceps through two 5 mm trocars. The matches are taken one after the other and guided for- and backwards through the eyes and finally placed into the empty match-box. Every participant should perform this exercise with at least 3 matches.

Clipping and dividing rubber bands

Instruments

1x10 mm trocar, 2x5 mm trocars, 2x grasping forceps, clip applicator, clips, scissors

Material

Plate with hooks and eyes, rubber band

Exercise

1 rubber band is fixed at the first hook, carried through the first eye, around the second and fixed at the 2nd hook. 2 clips are placed at the rubber band close to 2nd eye and a 3rd clip at a distance of around 5 mm. The rubber band is cut between the clips and the anterior part of the rubber band extracted through the trocar. The posterior part of the rubber band primarily remains at the combination of hook and eye. Finally, also this part of the rubber band can be removed and extracted through the trocar.

Chicken skin peeling

Instruments

2x10 mm trocars, 2x5 mm trocars, 2x grasping forceps, 1 dissecting spatula, hook knife

Material

1/2 chicken

Exercise

The exercise is prepared by fixing the negative electrode plate on the cork-plate with pins. Please check the correct connections of the negative electrode-cable at the inside and the outside of the training box. The chicken is placed on the negative electrode and the cork-plate. Several areas of the chickens' skin are marked and show the extent of dissection. The skin is grasped by 2 forceps and slightly elevated. The preparation starts along the outer border of the marked area with the hook knife and unipolar high-frequency coagulation.

The skin can be elevated more and more, it is dissected from the underlying muscle fascia and finally extracted through the 10 mm trocar. In every chicken you will have enough place for several marked areas, so that every member of the training crew will get his chance.

Laparoscopic Surgery

Practical Exercises

R. Bumm, Alfeld, C.T. Hamel, Lörrach, T. Kocher, Baden, J. Metzger, Luzern, H.-D. Saeger, Dresden, W.E.G. Thomas, Sheffield, P. Vogelbach, Dornach

Cutting out paper models

Instruments

2x10 mm trocars, 2x5 mm trocars, reducer, 2x grasping forceps, scissors.

Material

Paper model

Exercise

During this exercise, the cooperation of the team is particularly important. The assistant holds and moves the paper model with 2 grasping forceps, so that the operator can cut out the "gallbladder line". There are enough paper models available.

Cholangiogram - training

Instruments

2x10 mm trocars, 1x5 mm trocar, reducer, OLSEN-grasping cholangiographic cannula (optional), scissors, clip applicator, clips, 2x grasping forceps

Material

Plate with hooks and eyes, infusion tube, cholangiographic catheter, needle for catheter-introduction through the abdominal wall

Exercise

One segment of the infusion tube is applied to the hooks of the training plate. The tube should have enough tension for easier performance of the exercise. The tube ("cystic duct") is closed at the side of the gallbladder by a single clip. Incision of 1/2 of the circumference of the "cystic duct". Introduction of a metal needle laterally to the duct incision through the neoprene cover and insertion of the cholangiographic catheter through the needle. The catheter is carried inside the training box by two grasping forceps and guided into the incision of the "cystic duct". Closing of the "ligament-sided cystic duct" with one, not too strongly applied clip. In the realistic situation you would now perform the cholangiography. Afterwards the ligament-sided clip is removed with a grasping forceps and the cholangiographic catheter extracted. The ligament-sided cystic duct is then closed by 2 clips and the segment of the infusion tube is completely divided at the site of the previously performed incision.

For the tables having an OLSEN grasping cholangiographic cannula available, the cholangiographic catheter is inserted into the forceps from the back. The closed clamp then is introduced through reducer and 10 mm trocar. The tip of the clamp is guided to the incision of the infusion tube and opened. The cholangiographic catheter is then inserted by guidance of the OLSEN forceps and - if necessary - by another grasping forceps into the "cystic duct". The OLSEN forceps then is closing the "ligament-sided cystic duct". After cholangiography you open the clamp and remove the cholangiographic catheter. Close the clamp and extract it through reducer and trocar. The exercise continues as described above.

Laparoscopic Surgery

Practical Exercises

R. Bumm, Alfeld, C.T. Hamel, Lörrach, T. Kocher, Baden, J. Metzger, Luzern, H.-D. Saeger, Dresden, W.E.G. Thomas, Sheffield, P. Vogelbach, Dornach

Cholecystectomy with a pig's liver

Instruments

2x10 mm trocars, 2x5 mm trocars, reducer, 2 grasping forceps, hook knife, dissecting spatula, scissors, clip applicator, clips

Material

Pig liver with gallbladder, tin box, pins

Exercise

A tin box is fixed on the cork-plate with pins, so that it is in contact with the negative electrode. The liver is placed into the tin box with the gallbladder on top. The function of unipolar coagulation is controlled with the hook knife at a peripheral part of the liver. To avoid a bile leak from the divided distal bile duct it is closed by 1 clip.

The training box is closed by a neoprene cover. Introduction of the 4 trocars and starting with the preparation (scissors, dissecting spatula, grasping forceps) close to the cystic duct. The serosa is carefully dissected parallel to the duct structures dorsally and ventrally (Callot's triangle). Blunt dissection with the grasping forceps and the spatula. Preparation of the very fine structures of the cystic duct and the cystic artery.

After dissection of both structures over about 1-2 cm, application of a pair of clips ligament-sided and one other clip close to the gallbladder. Cut through the cystic duct between the clips. Grasp the gallbladder close to the cystic duct and pull the gallbladder cranially and ventrally. Clip and divide the cystic artery. Start now with the retrograde preparation of the gallbladder, dissecting it from the liver with scissors, dissecting spatula and hook knife. After incision of the serosa at the border of the gallbladder to the liver tissue, blunt dissection sometimes is easy to perform. If possible - avoid perforation of the gallbladder with the instruments. Before dissecting the gallbladder completely, the gallbladderbed is achieved and a thorough hemostasis is performed. Finally, the gallbladder-fundus is divided from the liver.

Extraction of the laparoscope and insertion to the 2nd 10 mm trocar. The gallbladder is handed over from the assistant to the operator inside the training box. The gallbladder finally is extracted through the neoprene cover to the outside. The extraction must be performed extremely carefully in order to avoid tearing of the gallbladder wall. In this exercise the gallbladder remains in the tin box for hygienic reasons.

Laparoscopic Surgery

Practical Exercises

R. Bumm, Alfeld, C.T. Hamel, Lörrach, Th. Kocher, Baden, J. Metzger, Luzern, H.-D. Saeger, Dresden, W.E.G. Thomas, Sheffield, P. Vogelbach, Dornach

Small bowel suture and knots

Instruments

2x10 mm trocars, 1x5 mm trocar, needle holder, grasping forceps, scissors, clip applicator, clips

Material

Small bowel segment, pins, 2 endo-sutures

Exercise

One small bowel segment of about 5 cm of length is fixed at both ends on a cork-plate without tension. Make an incision of 2 cm in the anterior bowel wall using grasping forceps and scissors. The suture then is carefully grasped just behind the needle and introduced through the 10 mm trocar. Insert the grasping forceps. The operator holds the needle holder and forceps in 2 hands and performs a running suture according to the DAVOS-technique (including the whole bowel wall together with the submucosal layer, but excluding the mucosa itself). Perform the first intra-corporeal knot. Make sure the end of the thread is rather short and lies next to the needle holder that is holding the needle. Now the running suture follows which is closed with a second intra-corporeal knot. With a second suture the lower end of the bowel incision is closed by a single stitch suture. The suture is tied instrumentally. One of the thread ends is tied to the end of the running suture internally with needle holder and forceps. Cut off the suture.

Laparoscopic closure in perforated ulcer

Instruments

3x10 mm trocars, needle holder, pickups, scissors

Material

Stomach, modul, cork-plate, pickups, scissors

Exercise

First an ulcer in the pyloric region will be created with the scissors.

Fix the esophagus and the stomach on the cork board and place in the pelvitrainer in the right upper corner. The 1st suture will be held with the needle-holder carefully behind the needle and then passed through the 10mm trocar. The ulcer will be closed with 3-4 intracorporally knotted sutures.

Tips regarding knotting technique

After suturing, the needle will be forwarded to the pickups so that the needle looks in direction of the needle-holder. The needle-holder now will be guided to the needle-end and then turned around the needle until 2 loops are created (alternatively, the pickups can be turned around the shaft of the needle-holder together with the needle). The end of the suture will be pulled through the 2 loops and the knot is performed. Afterwards, for knot safety 2 further loops will be done in opposite direction over the needle-holder. A short suture facilitates the intracorporal knotting.

Laparoscopic Surgery Practical Exercises

R. Bumm, Alfeld, C.T. Hamel, Lörrach, T. Kocher, Baden, J. Metzger, Luzern, H.-D. Saeger, Dresden, W. E.G. Thomas, Sheffield, P. Vogelbach, Dornach

Laparoscopic gastroenterostomy

Instruments

1x2 mm trocar, 2x10 mm trocars, 2x5 mm trocars, needle-holder, pickups, scissors, Endo-Stapler

Material

Stomach, small intestine segment, cork-plate, pins

Exercises

Place the stomach the same way as in the exercise "closure in perforated ulcer". Additional, a small intestine segment will be placed into the pelvitrainer. At the deepest point of the stomach a stay suture is applied between stomach and small bowel and tied. A second stay suture is placed about 7-8 cm apart in the antrum of the stomach. At the deepest point in the stomach an incision is made big enough to allow entry of a limb of the Endo-Stapler. A corresponding opening is made antimesenterially on the small intestine segment. In the next step, stomach and small intestine will be loosely fixed with 2 stay sutures in accordance to the planned gastroenterostomy. The Endo-Stapler will be passed closed through the 12 mm trocar from the right lateral side.

After opening the instrument, one of the limbs of the Endo-Stapler will be pushed into the opening of the stomach and the other limb will be passed into the opening of the small intestine. Close the Endo-Stapler carefully controlling the position of the limbs. Apply the staples by pressing the handle. Open the Endo-Stapler and remove it carefully. Close the stapler incision by a running suture. Tie the distal stay suture. The gastroenterostomy should be approximately 6 cm in length.

Laparoscopic fundoplication of Nissen-Rossetti

Instruments

3x10 mm trocars, 1x5 mm trocar, 1 Babcock-clamp, 1 needle-holder, 1 pickup, 1 scissors, 1 knot-pusher

Material

Suture material non resorbable 3-0 half circle, needle length 90 to 120 cm

Techniques of Operation

1. Open the pelvitrainer and place the cork board with the plate, fixation of stomach, esophagus and spleen inside. Adjust the of diaphragm, which is delivered separately, circumferential around the esophagus, placing some stay sutures.
2. Close the pelvitrainer.
3. Insert the first trocar in the mid-line above the umbilicus.
4. Place the further trocars under visual control.
5. Dissect the hiatus and both crura of the diaphragm. Start with the right crus. Avoid damage to the anterior and posterior vagal nerve as well as vagal fibers entering the hepatoduodenal ligament. Demonstrate both crura.

Laparoscopic Surgery

Practical Exercises

R. Bumm, Alfeld, C.T. Hamel, Lörrach, T. Kocher, Baden, J. Metzger, Luzern, H.-D. Saeger, Dresden, W.E.G. Thomas, Sheffield, P. Vogelbach, Dornach

6. Mobilize the gastric fundus by dissecting the short gastric vessels. Use the endoscissors and diathermy. In reality this would be performed with Ultracision or Ligasure. The Fundus must be mobile for tension-free retraction behind the esophagus.
7. Perform a posterior hiatoplasty by placing two extracorporarily knotted sutures behind the esophagus, involving both crura of the diaphragm. The Cameraman or assistant holds the diaphragm with laparoscopic grasping forceps to prevent the specimen from moving within the pelvitrainer.
8. Retract the fundus behind the esophagus with the Babcock clamp for formation of a short and floppy 360 degrees fundoplication. After passing behind the esophagus, the fundus should stay in place without traction.
9. Having passed the fundus behind the oesophagus, a corresponding part of the anterior wall of the stomach is held and approximated to make the fundus valve. This way a valve around the oesophagus is created using fundus and anterior stomach wall. These two parts are kept together with Babcock-clamps. Fix the valve with three to four extra-corporeally tied single knot sutures. The knots can be pushed down with the help of a knot-pusher.
10. The most distal stitch of the fundoplication should be performed as follows to prevent the plication from gliding: Anterior wall, esophagogastric junction, fundus. Perform all stitches seromuscularly The fundoplication should be made short and floppy.
11. Check the tension of the fundoplication by elevating the valve with a Babcock clamp. Discuss with your table instructor.
12. Finalize the fundoplication by fixation of the left limb of the fundoplication with one or two extracorporeal sutures in the anterior gastric wall.
13. Open the pelvitrainer and check the result of the laparoscopic fundoplication with your table instructor.

Laparoscopic Surgery

Practical Exercises

R. Bumm, Alfeld, C.T. Hamel, Lörrach, T. Kocher, Baden, J. Metzger, Luzern, H.-D. Saeger, Dresden, W.E.G. Thomas, Sheffield, P. Vogelbach, Dornach

Appendectomy

Instruments

2x10 mm trocar, 2x5 mm trocar, Endo-Stapler, 2 grasping forceps, clip applicator, clips, bipolar highfrequency forceps, scissors

Material

Small bowel segment with mesenteric root, 2 endoloops, 1 stay suture

Exercise

Fix the prepared appendectomy model with pins, grasping the appendix at the tip. Stepwise coagulate the mesentery with bipolar coagulation and then divide the coagulated mesentery. Coagulate with bipolar diathermy to the base of the appendix. Once the appendix is mobilised down to the base at the pole of the caecum, a prepared endoloop is passed through a five millimeter trocar and the open loop is passed over the appendix. By breaking the insertion rod at the end, the endoloop can be tightened right at the base of the caecum. Cut the end of this ligature and remove the knot pusher. A second endoloop is inserted and ligated 8-10 mm away from the first endoloop. Divide the appendix close to the second ligature and finally divide the second ligature. The appendix can be removed through the 10-12 mm trocar.

The trocar valve must be held open by the assistant during the extraction.

Trocar insertion

Instruments

Different trocars: 5 and 10-12 mm, single use and multiple use (steel trocars)

Material

Pelvi trainer

Exercise

Demonstration and exercising the use of different trocars. Insertion of the first trocar without direct vision, followed by second and third trocar incision under direct vision.

It is important to consider that the first trocar incision is a blind manouvre and therefore more dangerous than the following tracar insertions.

The following trocar incisions (second and third) should always be performed under direct vision and visual control.

Demonstration of the use of the insertion valve with the different trocar types. Also the use of reduction tips is demonstrated and suggested. It is very important to know the mechanism of all the instruments and prticularly the trocars to be used.

Laparoscopic Surgery

Practical Exercises

R. Bumm, Alfeld, C.T. Hamel, Lörrach, T. Kocher, Baden, J. Metzger, Luzern, H.-D. Saeger, Dresden, W.E.G. Thomas, Sheffield, P. Vogelbach, Dornach

Laparoscopic surgical knots – knot pushers

Instruments

2x10 mm trocars, 1x5 mm, needle holder, grasping forceps

Material

Plate with hooks and eyes, endoscopic sutures (120 cm)

Exercise

To perform extra-corporeal knots a long thread (about 120 cm) has to be used. Regular reef knots and surgical knots can be applied and knotted extra-corporeally. To push down the knots, knot pushers have to be used.

Different types of knot-pushers will be demonstrated and used in the exercises.

As in conventional surgery, for safety reasons a correct reef knot is very important. With practice and use of an easy knot pusher, this technique can always be used and applied.

It is very important to know how to use your specific knot pusher to apply a secure extra-corporeally knotted knot.

Part two: ESS (Endoscopic Suture System)

Exercise

A special knot pusher is demonstrated as the ESS (Endoscopic Suture System). The thread is already inserted in a special knot pusher.

The advantage of this system is that the thread cannot be lost during the process of pushing the knot down into the peritoneal cavity.

Correct reef knots and surgical knots can also be performed with this suture system.

II. Conventional Surgery

Edited by

W.E.G. Thomas

J. Metzger

T. Kocher

Basics in Gastroenterological Surgery and Suture Techniques

Instruments and Materials

Dissecting forceps	with teeth
	without teeth (long and short)
Needle holders	short for delicate work
	long for use in the pelvis
Needles	cutting
	non-cutting
Suture materials	
Inorganic	metal wire
Organic	<i>non absorbable:</i>
	- silk
	- linen thread
	<i>absorbable:</i>
	- plain catgut
	- chromic catgut
Artificial	<i>non absorbable:</i>
	- braided: mersilene
	monofilament:
	- polyamide (Nylon)
	- polypropylene (Prolene)
	- polytetrafluoroethylene (PTFE)
	<i>absorbable:</i>
	short life (braided):
	- polygalactin (Vicryl)
	- polyglyconic acid (Dexon)
	long life (monofilament):
	- polydioxanone (PDS)
	- polyglyconate (Maxon)

Knots

Requirement:	Security without strangulation
1.	Reef knot
2.	Surgeon's knot
3.	Slip knot (incorrectly applied reef knot)

Basics in Gastroenterological Surgery and Suture Techniques

Basic Techniques

Position of the surgeon

Ensure the table is at the correct height and avoid stooping. Your forearms should be parallel to the floor.

The needle holder

Hold it delicately with thumb and ring finger. Avoid using the grasp. Mount the needle near the tip of the needle holder. The needle should be placed at right angles in the needle holder a little away from its end. Handle the needle with the dissecting forceps, not with your fingers.

The dissecting forceps

Hold them lightly with a delicate apposition of the fingers on one blade and the thumb on the other blade.

The role of the assistant

Your assistant should be opposite you and should maintain display. He should avoid obscuring the field of view and should not allow his hand to get between your eye and the operating specimen.

Suturing

When suturing, ensure the needle enters the tissue at right angles to its edge. The distance from the edge should correspond to the thickness of the material. Successive throws should be placed at twice this distance.

Knotting

There are 2 types of throw:

1. using the index finger,
2. using the middle finger.

These need to alternate in order to achieve a reef knot. Choose the correct first throw. If the short end of the thread is away from you, use the index finger. If the short end is towards you, use the middle finger. Ensure your knot is secure, but do not strangulate the tissues. The reef knot is generally secure with 3 throws of braided materials. It is not so with monofilament materials. Achieve security by using at least 6 throws or by tying a surgeon's knot.

Notes:

Extramucosal Single-Layer Suture on Mobile GI-Segments

Interrupted Suture

F. Harder, Basel, J. Metzger, Luzern

Indication

Gastrointestinal anastomoses on intraperitoneal and mobile GI-Segments: for example jejunum, ileum, colon, stomach and frontwall of the rectum.

Suture material

Dissolvable 4-0

Suture technique

Stitch

Needle perforates serosa at right-angles and penetrates between mucosa and submucosa to the cut edge. On the opposite side on the cut edge the needle perforates between mucosa and submucosa and runs for 0.5-0.8 cm before exiting at serosa (**figure 1**).

Suture

1. First suture is placed at the mesenteric border and immediately tied. One end of the thread is stabilised with a hemostat.
2. The antimesenteric suture is placed and tied. Stabilized with hemostat.
3. One end of the mesenteric thread is passed behind the bowel lumen.
4. The frontwall is sutured in the above mentioned technique knotting every thread immediately (distance between the sutures 0.5-0.8cm).
5. After finishing the frontwall the bowel is turned around the mesentery. Centre of rotation is the mesenteric knot.
6. Inspect-the anastomosis from the lumen.
7. Suturing the 2nd side using the same technique from the mesentery towards the antimesenteric border.
8. Always use the same technique for end-to-end or end-to-side anastomosis.

Lumen differences in diameter (for example ileocecal) can be managed by using an antimesenteric slit on the more narrow bowel end (see **figure 2**).

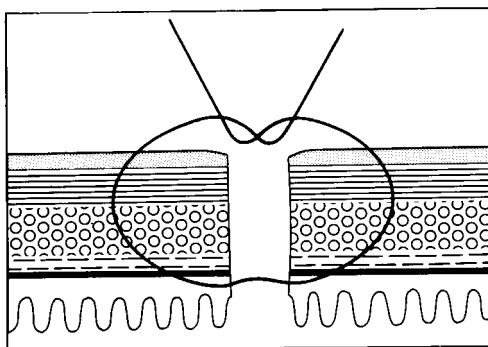


figure 1

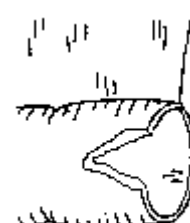

figure2

Extramucosal Single-Layer Anastomotic Technique

Continuous Suture

F. Harder, Basel, J. Metzger, Luzern

Indications

Gastrointestinal anastomoses on intraperitoneal and mobile GI-Segments: for example jejunum, ileum, colon, stomach and frontwall of the rectum.

Technique

Running single layer extramucosal, stitched from outside (extraluminal)

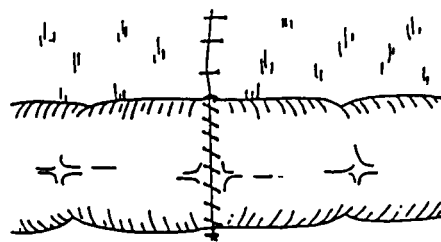
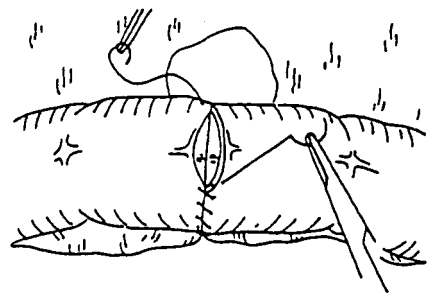
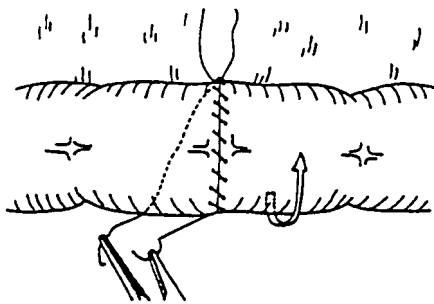
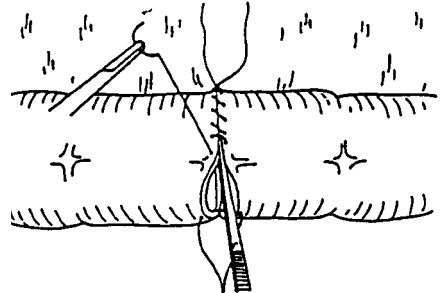
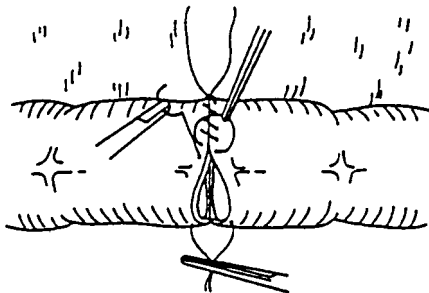
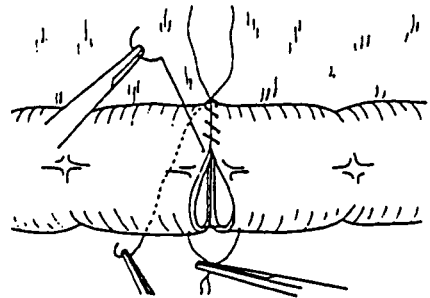
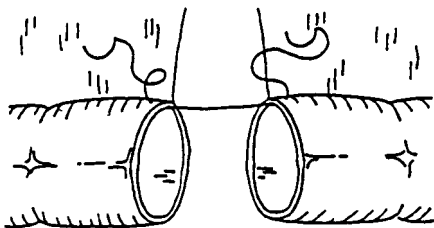
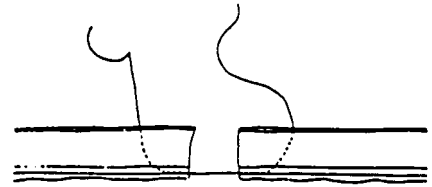
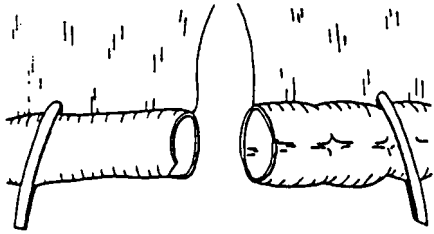
Suture material

Monofilament dissolvable double armed, size 4-0

Suture technique

1. Approximate to the bowel ends for either end-to-end or end-to-side anastomoses.
2. Insert an extramucosal stitch at the mesenteric border of the bowel using the double needle 4-0 suture material.
3. Cast 2-3 knots in the middle of the thread. Stabilise the end of the thread with a hemostat.
4. Pass the free end of the thread behind the bowel and stabilise it with the second hemostat.
5. Place an antimesenteric stay suture. Do not tie but place in a hemostat.
6. Start your running suture from the mesentery towards the antimesenteric side, the first two stitches are somewhat closer at the mesentery and slightly V-shaped. Place all sutures at right-angles to the cut edge of the bowel.
7. The assistant should maintain the correct tension on the thread and the tissues correctly approximated.
8. Position the thread with dissecting forceps ensuring the monofilament material is not grasped or damaged.
9. If necessary the bowel ends should gently be approximated with stay sutures, so as to obtain a good fit.
10. Turn the bowel round the mesentery. The back wall is now the new front wall.
11. Start again on the mesenteric border with the second end of the thread. Complete the suture on the antimesenteric side and remove the stay suture.
12. Bring the edges together without producing a stenosis.
13. After completing the suture, tie the 2 threads on the antimesenteric side with 6 knots. Danger: any purse stringing will produce strangulation or stenosis.
14. Use the same technique for end-to-end or end-to-side anastomoses. Minor variations in diameter can be accommodated using the same technique, but larger discrepancies are best managed by making an incision on the antimesenteric side of the smaller lumen.

See figure on the opposite page



Single-Layer Suture on Immobile GI-Segments Interrupted Suture

W.E.G. Thomas, Sheffield, N. Senninger, Münster, C. Rudberg, Västerås, T. Kocher, Baden,
J. Metzger, Luzern

Example

Anastomoses on immobile GI-segments (oesophagus, rectum).

Suture material

3-0 or 4-0 absorbable

Suture technique

Backwall

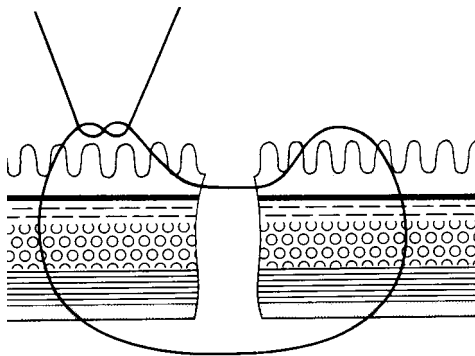
Vertical mattress suture. The needle perforating the bowel wall of the first segment from the inside, the second bowel wall from the outside. The backstitch takes a small segment of the mucosa on either side.

Frontwall

Extramucosal suture

Suture

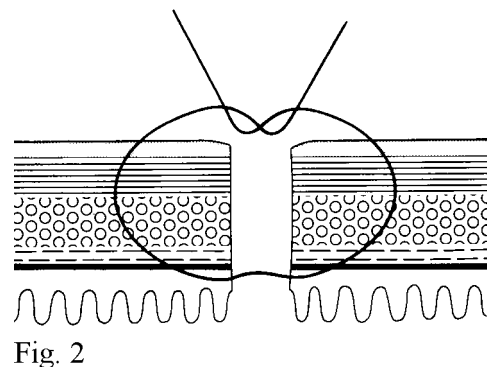
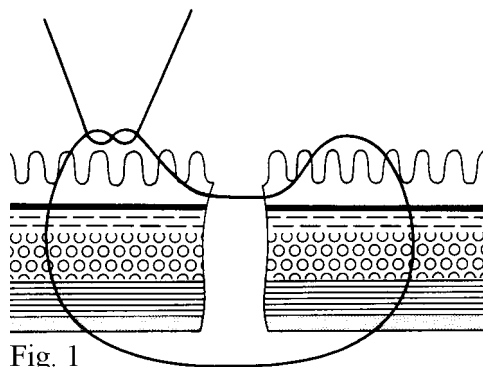
1. Starting the anastomosis with the corner stitches on either side of the backwall, the sutures are tied later.
2. Place all sutures on the backwall.
3. Place extramucosal corner stitches as first stitches of the front wall. The corner is exposed by pulling the corner stitches of the backwall to the opposite side.
4. Tie all backwall stitches.
5. Tie the extramucosal corner stitches.
6. Suture the front wall in the extramucosal technique.



“Cross-Section”-Gastroenterostomy

H.-D. Saeger, Dresden, W.E.G. Thomas, Sheffield, N. Senninger, Münster, C. Rudberg, Västerås, T. Kocher, Baden, J. Metzger, Luzern

1. The localisation of a GE is of course variable in clinical practice and depends on the localisation of the obstacle (e.g. carcinoma). In this exercise it will be placed on the anterior wall of the antrum.
2. Transverse incision of the jejunum beginning at the antimesenteric border. This incision must not reach as far as the mesentery. Leave 1 cm clearance on both sides so as to have ample room for sutures.
3. The jejunum is splayed open longitudinally and thus, the length of the gastrotomy can be defined accurately.
4. The posterior wall is sewn as a single layer of mattress sutures according to Donati (figure 1). The central suture in the middle of the posterior wall is placed first, followed by a suture in each corner. A further 2 to 3 sutures in between on each side complete the backwall. Once these sutures have been placed under good vision, they are knotted. The corner sutures are left long, all the others are cut.
5. The anterior wall of the anastomosis also consists of a single row of extramucosal sutures. These are placed (as shown in figure 2). The whole of the gastric and jejunal wall is traversed by the suture needle (from outside to inside and again from inside to outside) with the exception of the mucosa itself. Once all the sutures have been placed, they are knotted and the threads are cut.
6. To check on the correct placement of all your sutures, open the stomach and the jejunum, close to the anastomosis and inspect what you have done from the inside.



Gastric Resection: Billroth I

Single-Layer Running Seromuscular Gastroenterostomy

F. Harder, Basel, J. Metzger, Luzern

Technique

Continuous single-layer extramucosal suture

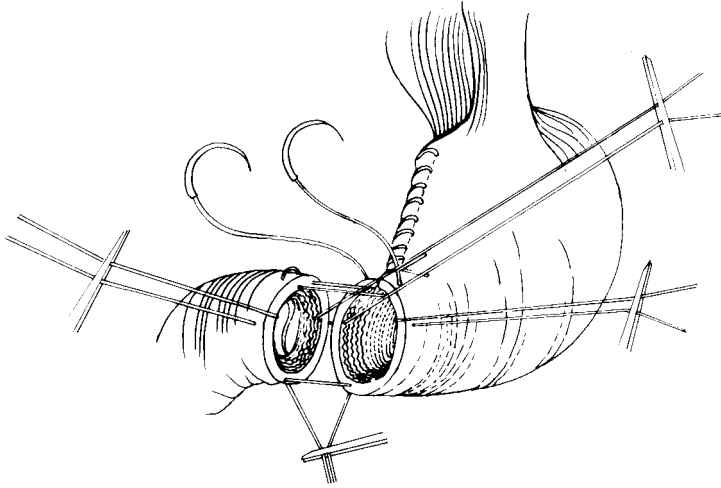
Suture material

Monofilament, dissolvable double armed

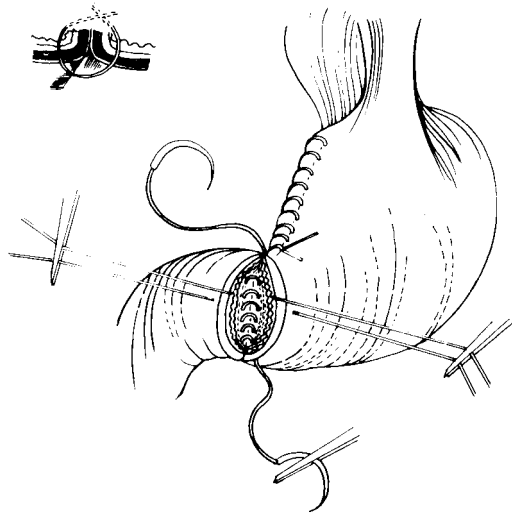
Suture technique

1. Resect the distal end of the stomach.
2. Close the stomach with an extramucosal running suture beginning high on the lesser curvature of the stomach.
3. Close the lesser curvature except for about 4-5 cm before reaching the greater curvature, tie the suture material and place in on hemostat.
4. Place a second stay suture at the greater curvature.
5. Anastomose a small bowel loop in an end-to-end fashion (duodenum).
6. Place a corner stitch at the lesser curvature, beginning at the stomach frontwall and small bowel frontwall seromuscularly using a u-fashioned stitch (see figure).
7. Tie the double armed thread with 2 or 3 knots, leaving equally long threads.
8. Place a stay suture at the greater curvature between stomach and duodenum.
9. Place a stay suture to keep the stomach frontwall out of the way and a similar stay suture at the duodenum frontwall to keep the duodenum frontwall out of the way.
10. Begin the running backwall suture, placing the first stitch at the lesser curvature through the stomach frontwall from the outside into the lumen.
11. Backwall suture (full thickness): stomach backwall inside out and duodenum outside in (full thickness).
12. Running suture from the lesser to the greater curvature.
13. Last stitch at the greater curvature from inside out on the stomach.
14. Inspect the backwall anastomosis especially at the lesser curvature.
15. Begin the running frontwall anastomosis at the lesser curvature with the second double armed thread, using an extra muscular stitch close to the corner stitch.
16. Continuous extramucosal frontwall anastomosis.
17. Tying the two threads at the greater curvature, 6-8 knots.
18. Inspection and resection of the anastomosis from inside and outside, with special regard to the corner stitch near the lesser curvature.

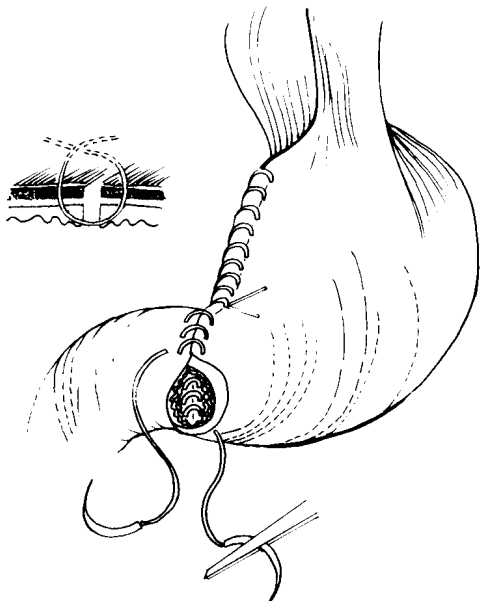
See figures on opposite page



Stitches on the backwall



Stitches on the frontwall



Billroth II partial gastrectomy

W.E.G. Thomas, Sheffield, J. Metzger, Luzern, N. Senninger, Münster, T. Kocher, Baden, C. Rudberg, Västerås

Technique

- Continuous extramucosal suture to lesser curvature
 - Posterior full thickness continuous suture for gastrojejunostomy
 - Continuous extramucosal technique for anterior wall gastrojejunostomy
1. Position the stomach as shown and excise the antrum.
 2. Close the lesser curvature of the stomach using a continuous extramucosal suture technique. Use entire lesser curvature apart from the distal 5 cm. Ligate suture.
 3. Place suture ends on hemostat.
 4. Cut off distal edge of stomach at angle as shown in the video to receive the gastrojejunum anastomosis. Approximate the jejunum and make an appropriate incision in the antimesenteric border.
 5. Insert angular “U” suture on the greater curvature end of the anastomosis from outside to inside on the stomach and then from outside to inside on the jejunum, inside to outside of the jejunum and finally inside to outside in the stomach..
 6. Now, insert the suture of the angle of sorrow using a double-armed suture from outside to inside of the posterior wall of the stomach, inside to outside on the angle of the jejunum then back from outside to inside on the anterior wall of the stomach. Ligate this angular suture (see **figure** on previous side).
 7. Insert anterior stay suture on the jejunum for ease of access.
 8. Take one of the needle of the angle of sorrow “U” suture and insert from outside to inside on the posterior aspect of the jejunal wall.
 9. Complete the posterior wall of the anastomosis using full thickness continuous suture technique.
 10. Having reached the greater curvature, exit the suture by passing from inside to outside on the stomach and secure on hemostat.
 11. Remove the angular and anterior wall stay suture.
 12. Take the other needle from the angular of sorrow “U” suture and perform a continuous extramucosal anterior wall suture technique.
 13. On reaching the greater curvature ligate with the posterior wall suture.
 14. Open the anterior wall of the jejunum to view your anastomosis.

Esophago-Jejunostomy (Roux-Y) Hand Suture

C. Herfarth, Heidelberg, N.M. Merkle, Hildesheim

Technique for single layer end-to-side-anastomosis

1. Position the esophagus in the trainer and small bowel loop just below it.
2. Close the open end of the small bowel with a continuous, single-layer-seromuscular suture (3/0).
3. Incise the small bowel on the antimesenteric border. The opening should correspond to the size of the esophageal lumen.
4. Placement of the backwall sutures: start inside-outside and go outside-inside. Begin the stitching on the small bowel taking all layers from inside to outside, continuing on the esophagus with a full thickness stitch from outside to inside; return taking a small edge of the mucosal rim of both the esophagus and small bowel. Clip the sutures.
5. Complete the back wall using the same technique with about 5 mm between stitches. Clip all the ends.
6. Frontwall corner stitches: seromuscular technique starting with the small bowel outside-in, continuing with the esophagus inside-out. Clip all the sutures.
7. Approximate the esophagus and small bowel loop whilst keeping tension on threads.
8. Control adaptation of backwall sutures; tie and cut the back wall sutures.
9. Tie the front wall corner stitches and place the two ends in hemostats.
10. Place all the frontwall sutures beginning with an all-layer small bowel stitch (from outside to inside) and end with the full thickness of the esophagus (from inside to outside). Clip the ends.
11. Tie all the frontwall sutures.
12. Inspect the frontwall of the anastomosis and cut the sutures.
13. Inspect the inside of the anastomosis by opening the small bowel.

Esophago-Jejunostomy

Stapler Technique with “Covidien instruments”

N. Senninger, Münster, T. Kocher, Baden, J. Metzger, Luzern, C. Rudberg, Västerås,
W.E.G. Thomas, Sheffield

Positioning of organs

- Oesophagus vertically from above, small bowel horizontally from below, open end of loop to the right.
- Purse-string suture at the oesophagus (4 retaining sutures, purse-string suture, three stitches per quadrant).

Preparation of DST EEA Stapler with “Tilt Top”

1. Detach the yellow plastic cap, containing the **Tilttop Anvil** and the white Trocar Tip, from the distal end of the stapler by pulling on the hollow tab.
2. The Anvil is shipped with one additional white Trocar Tip to perform a side to end anastomosis. Do not use the Tip if you perform an end to end anastomosis.
3. The DST EEA is delivered ready to use. **Do not** turn the black twist knob at the end of the instrument before introducing it into the tissue!
4. Introduce the metal Anvil (head) into the oesophagus after thorough moistening. Careful closure of purse-string suture. Be careful in tying the suture into the purse-string notch of the center rod. (Attention: the Anvil must be covered by oesophageal wall, additional tissue should be removed 5mm on each Anvil side.)
5. After moistening, introduce the stapler with sunk-in central trocar through the open end of the small bowel loop. Introduce far enough to allow a clear 3 cm to receive the anastomosis.
6. Pierce the small bowel with the tip of the trocar on the antimesenteric border by opening the stapling device, screwing in an anti-clockwise direction. Open until the orange mark is clearly seen and the metal Trocar is fully extended.
7. Grasp the Anvil only at the green grasping notch! Attach the metal Anvil, secured in the oesophagus, by pushing it on to the trocar until you hear and feel a click. The orange mark should not be visible any more.
8. To approximate the tissue between the Cartridge and the Anvil, close the stapler slowly by turning the black twist knob in clockwise direction (instruction printed on the handle of the instrument). Make sure that no tissue is under tension.
9. Close the black twist knob until it is fully tightened and you see the green bar in the tissue approximation window. The window is on the anterior side of the instrument. Ensure that both oesophagus and jejunum are placed uniformly side by side.
10. Prior to fire the instrument, unlock security lock and fire stapler by firmly and fully pressing the handle to the instrument shaft. You must hear a crunch and a click when the handle is properly closed and pushed together.
11. To remove the stapler it is necessary to open the instrument with 2 full turns of the black twist knob in an anticlockwise direction. You will hear a click when the instrument is ready to remove.

Esophago-Jejunostomy Stapler Technique

N. Senninger, Münster, T. Kocher, Baden, J. Metzger, Luzern, C. Rudberg, Västerås,
W.E.G. Thomas, Sheffield

12. Remove the instrument with careful movements. During this procedure the anastomosis should be gently held with the left hand.
13. After removal, open the stapler completely by turning the black twist knob in an anticlockwise direction.
14. Remove the metal Anvil and remove the 2 tissue rings, which demonstrate the completeness of the performed anastomosis.

Sources of error during the exercise:

- Interposition of tissue during the stapled anastomosis.
- Unequal positioning of sutures when performing the purse-string suture (only 3 stitches are recommended per quadrant). Insufficient moistening of the stapling device, the bowel or the oesophagus, respectively, before the stapler is introduced.
- Insufficient opening of the stapler before removal.
- Tissue under tension while closing the instrument.
- Make sure to push the instrument slightly towards the oesophagus while closing it. To be sure that there is not too much pulling on the oesophagus.

The open remaining end of the small bowel loop can be finally closed with a linear stapler to complete the anastomosis.

Anterior Resection Hand Suture

J. Metzger, Luzern; P. Vogelbach, Dornach

Side-to-end anastomosis (interrupted sutures)

Position: modified lithotomy position

Surgeon: right-handed surgeon stands on the patient's left side

Technique

Backwall

Use an all layer back stitch placed from within the lumen (Donati-Allgöwer stich)

Frontwall

Extramucosal

Suture material

Absorbable, size 4-0, possibly monofilament (watch knot safety)

Suture technique

1. Close the end of the colon with a running suture. Make a longitudinal incision on the antimesenteric side of the terminal colon, length according to the diameter of the rectum.
2. Place a front wall corner seromuscular sutures. First lumen (colon) outside in, second lumen inside out, secured on a hemostat. Place a second similar corner suture at the exact 180° point. Place a front wall stay suture in the middle secured on a hemostat to gently open the lumen of the rectum
3. Backwall suture: Start near the corner stitch beginning in the colon (approximately 8mm from the corner stich) inside out, full thickness, rectum full thickness outside in. Backstitch the mucosa of the rectum and mucosa of the colon using a vertical mattress suture. Secure the sutures on a hemostat
4. Mark the middle of the backwall suture line.
5. Complete the backwall sutures from right to left side, securing all sutures on hemostats which are collected on another hemostat in the correct order. The distance between stitches should be about 0,8 cm, but near the corner even less.
6. Now keeping all the sutures under tension, bring the colon towards the rectum in the small pelvis using a swab on a hemostat. Carefully control the position of the backwall of the colon and the rectum and knot all the backwall sutures. Inspect the backwall suture line and cut the sutures previously placed.
7. Tie the previously placed frontwall corner sutures.
8. Complete the front wall anastomosis using the extramucosal technique. Tie each knot as you go. Carefully suture the frontwall ensuring you do not catch the backwall.
9. Inspect the frontwall anastomosis and cut all the sutures.

Anterior Resection Hand Suture

F. Harder, Basel; J. Metzger, Luzern

Alternative: preinserted frontwall sutures on the rectum

Indication

When the anastomosis is deeply placed in a narrow pelvis and the visibility is poor (prostatic enlargement, uterus myomatosus). Staplers not available.

Position/Surgeon (see previous page)

Suture technique

Suture material

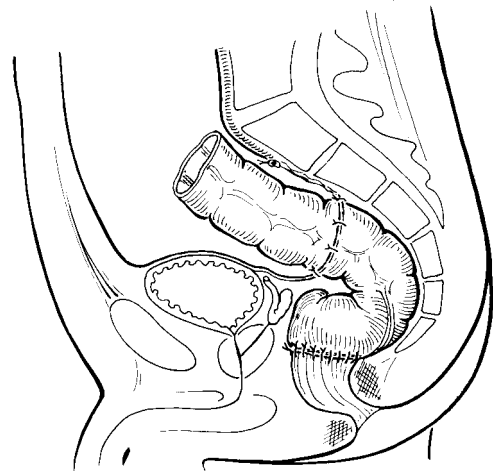
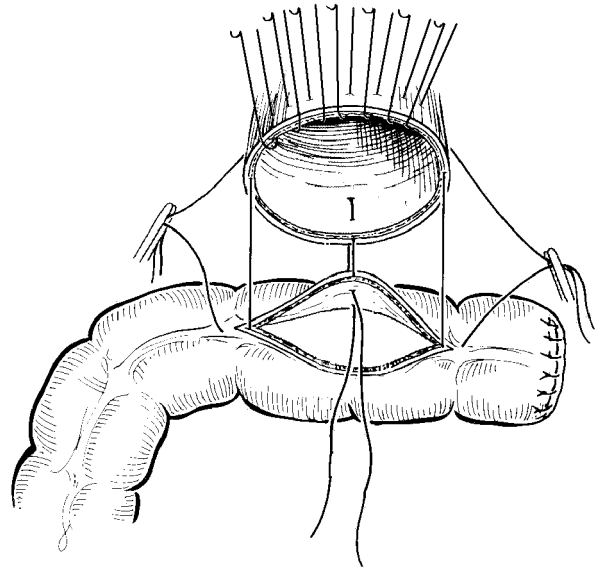
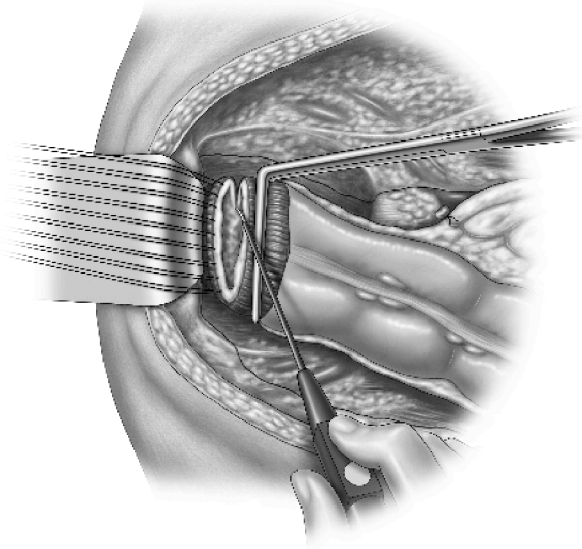
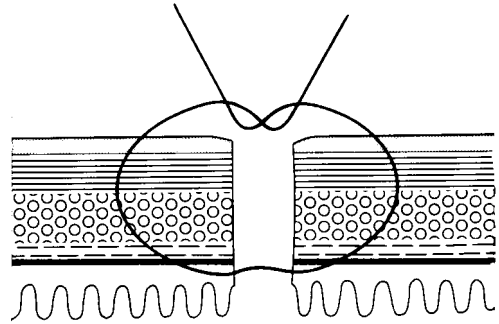
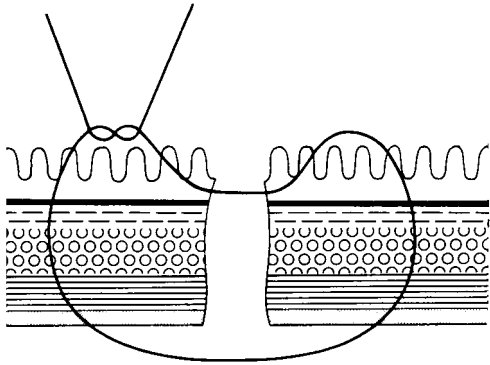
Double-armed 4-0 monofilament for the frontwall

Single-armed 4-0 monofilament for the backwall

Suture technique

1. Start by dividing the anterior wall of the rectum and insert all frontwall stitches on the rectum (frontwall from inside out) with double armed 4-0 thread. Remove one needle from external rectal side, leaving the internal colon-side needle attached.
2. Secure all the threads on hemostats and use them to keep the frontwall away which offers good visibility of the backwall. Now divide the posterior wall of the rectum.
3. Insert frontwall corner sutures between the colon and the rectum, placing extramucosal sutures and secure on hemostats.
4. After finishing the backwall anastomosis (same technique as described before). Slide colon down and tie sutures. Complete the frontwall anastomosis by suturing the colon with the second needle from the lumen inside out using the extramucosal suture technique. Tie all the threads on the frontwall immediately. Inspect the anastomosis.

See figures on next page



Anterior Resection Stapler Technique with “Covidien instruments”

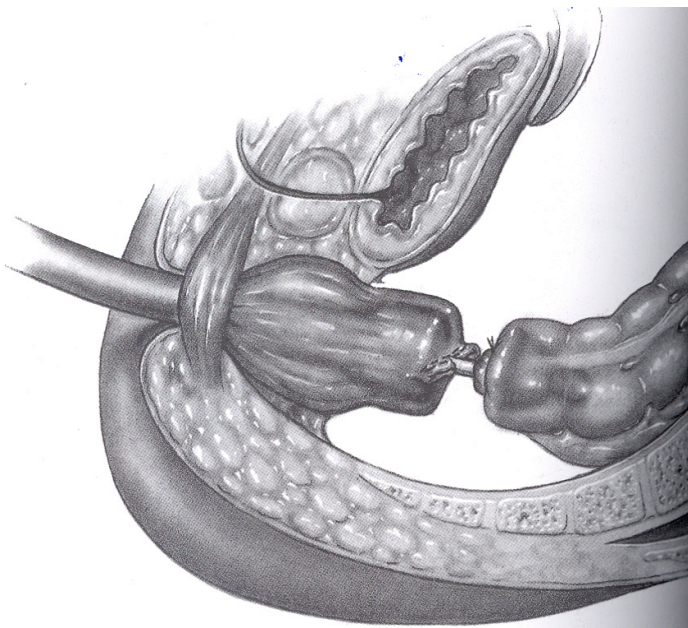
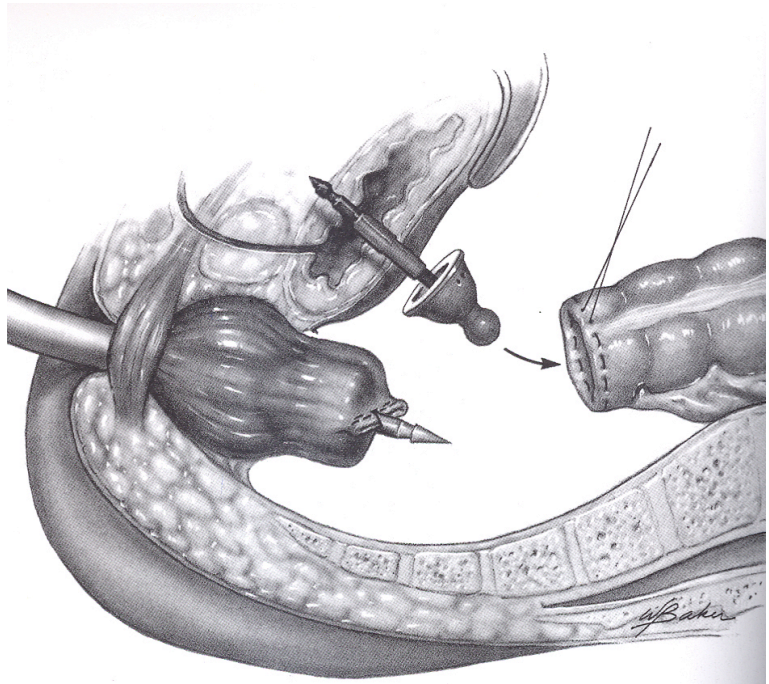
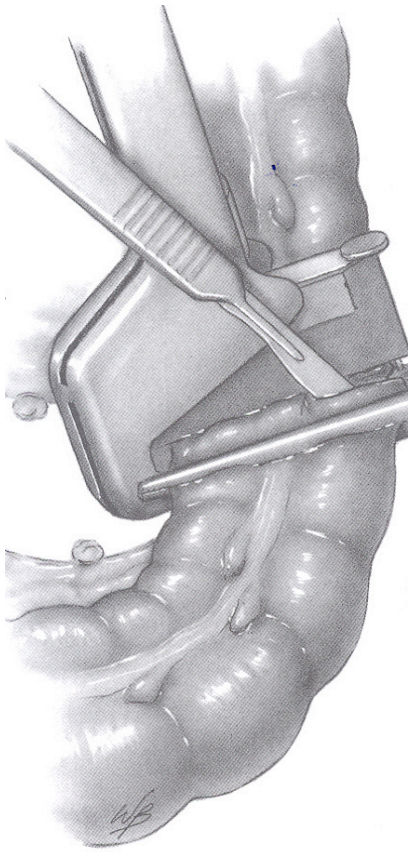
J. Metzger, Luzern; P. Vogelbach, Dornach

1. Clamp the rectum distal to the tumour with two clamps
2. Close the rectal stump with **TA 45**:

- Place the open TA 45 instrument across the rectum.
- After first stage closure (manually or automatically) of the safety pin, ensure even distribution of the rectum within the stapler.
- Complete the second stage of the closure by pressing white handles.
- Fire the device by firm closure the seconde time of the white handles.
- Transect the rectum proximal to TA 45 with knife or scissors.
- Open the device by pushing on the black release button.
- Prepare the proximal colon.
- Insert purse-string suture with monofilament suture material, taking care to include the entire circumference of the colon.

3. Preparation of DST EEA Stapler with “Tilt Top”

- Detach the yellow plastic cab, containing the **Tilt top Anvil** and the white Trocar Tip, from the distal end of the stapler by pulling on the hollow tab.
- The Anvil is shipped with the white Trocar Tip. Remove the Tip if you perform an end to end anastomosis.
- The DST EEA is delivered ready to use. **Do not** turn the black twist knob at the end of the instrument before introducing it into the tissue!
- The flat tilt top anvil is now introduced into the distal colon and the purse-string suture firmly tied. By using the purstring notch to tie the suture.
- All excess tissue must be carefully removed from the shoulders of the anvil (if using a EEA 31, the prepared area should be 1,5cm on each side of the Anvil).
- Introduce the DST EEA-Stapler transanal with fully withdrawn Trocar.
- The Trocar is extended up to the staple-line.
- In order to perforate the staple-line centrally, a small opening is made with scissors.
- Complete extension of the Trocar as far as possible and the orange mark is visible.
- The anvil is now pushed on the central rod until it latches and you hear a click. The orange mark should not be visible at this point.
- Check the correct rotation of the distal colon at this time.
- Close the EEA by slowly turning the black twist knob clockwise. Prevent any excess tissue from being caught between anvil and DST EEA.
- Close the instrument completely until the green mark becomes visible within the approximation window on the anterior side of the instrument.
- Check your anastomosis once more.
- Disengage the safety catch and firmly close the handle until you hear a crunch and the click.
- Turn the black twist knob anti-clockwise **two full turns**. After the two full turns you must hear the click. That click indicates the proper opening of the DST EEA. The instrument is then ready to be removed.
- To protect the anastomosis, gently support it with one hand, while the instrument is retracted gradually with slow movements.
- The stapler is fully opened and the two doughnuts are removed and checked for completeness.



Hepatochole-jejunostomy

Interrupted Suture

C. Rudberg, Västerås, J. Metzger, Luzern, W.E.G. Thomas, Sheffield, N. Senninger, Münster, T. Kocher, Baden

Exercise

Hepatochole-jejunostomy, end-to-side biliary-intestine anastomosis.

Suture material

4-0 dissolvable

Trainer

Bile duct

Simulated bile duct

Position the bile duct and the jejunum into the trainer

Position the jejunal loop and make an appropriate antimesenteric incision

Suture technique

Stitch technique

Backwall

Vertical all-layer-suture

Frontwall

Extramucosal suture at jejunum and all-layer suture at bile duct.

Suture

1. Place all anterior wall sutures in the bile duct from outside to inside full thickness, securing end sutures in a hemostat and keeping them in the appropriate order by loading them on to a larger clip. Do not cut the needles off.
2. Make an appropriate incision in the antimesenteric border of the jejunum.
3. Insert both corner stitches through duct and jejunum, do not tie but secure in hemostat.
4. Insert all posterior wall sutures full thickness inside to outside on the duct and outside to inside on the bowel.
5. Approximate jejunum to duct gently and not by exerting tension on the sutures as this could tear the duct.
6. Ligate all posterior wall sutures and corner sutures.
7. Cut off posterior wall sutures, but leave corner sutures in hemostats.
8. Take needles from the anterior wall sutures already placed in the duct and pass the needles from inside to outside in an extramucosal manner on the jejunum.
9. Once all anterior wall sutures have been correctly placed, ligate and cut off excess suture material.
10. At end of procedure open up and check your anastomosis.

Pancreatico-Jejunostomy

N. Senninger, Münster, W.E.G. Thomas, Sheffield, T. Kocher, Baden, C. Rudberg, Västerås,
J. Metzger, Luzern

Exercise

End to side pancreatico-jejunostomy

Suture Material

4-0 dissolvable

Suture Technique

1. Place the cut end of the simulated pancreas adjacent to a closed loop of jejunum (*figure 1*).
2. Insert angle sutures from inside to outside on the pancreas and full thickness on the jejunum. Secure in hemostat.
3. Place posterior suture from inside to outside on the pancreas and full thickness on the jejunum. Do not tie but place in hemostats (*figure 2*).
4. Approximate jejunum to pancreas with gentle pressure and not by pulling on the suture material.
5. Ligate all posterior wall sutures and cut off excess suture material.
6. Make an appropriate incision in jejunum wall corresponding to pancreatic duct (*figure 3*).
7. Place central posterior wall sutures from inside to outside from the pancreatic duct and outside to inside on the jejunum (*figure 4*).
8. Place angular sutures from outside to inside in the pancreas duct and from inside to outside on the jejunum.
9. Ligate these sutures and then cut off the suture material from the posterior wall suture.
10. Insert midline anterior wall suture from outside to inside on the pancreatic duct and then from inside to outside on the jejunum and then ligate.
11. Cut off all excess suture material from the anterior and angle sutures.
12. Roll the jejunum up over the anterior edge of the pancreas.
13. Insert anterior wall suture from outside to inside on the pancreas and full thickness on the jejunum to complete the anastomosis.
14. Cut off all excess suture material.
15. Open up jejunum to view internal aspects of the anastomosis.
16. In certain circumstances the duct anastomosis may be fashioned over a fine tube or stent.

see figures on opposite page

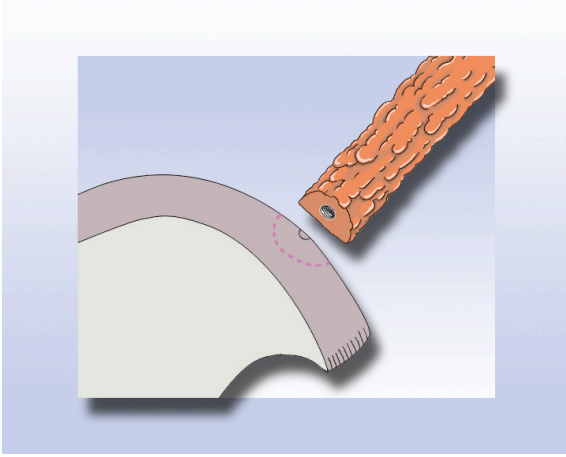


figure 1

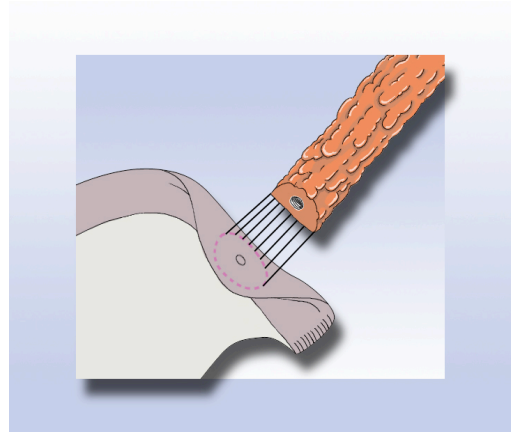


figure 2

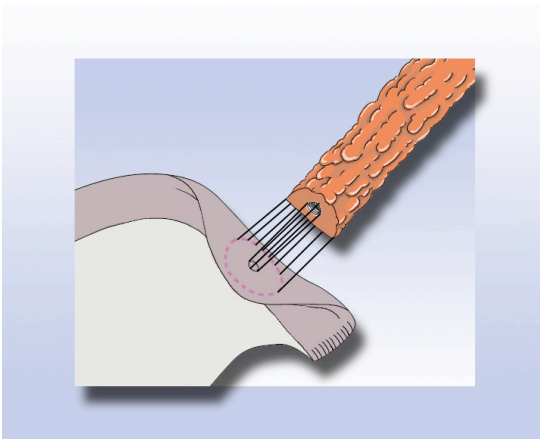


figure 3

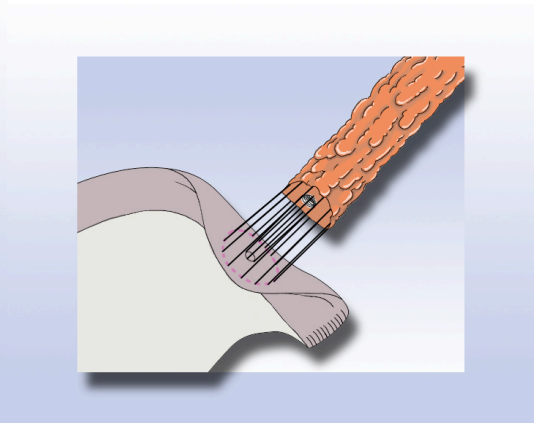


figure 4

Stoma placement

W.E.G. Thomas, Sheffield, J. Metzger, Luzern, T. Kocher, Baden

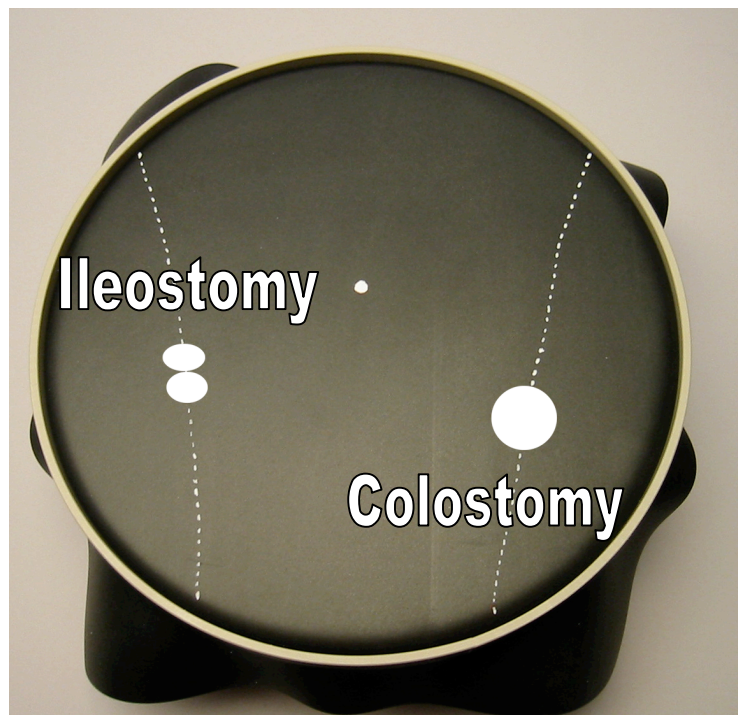
Exercise

- 1. colostomy**
- 2. loop ileostomy**

Suture Material

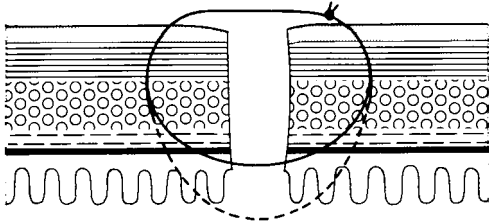
Monofilament, non-absorbable 4-0

- Make a midline incision
- Choose the appropriate position for the stoma placement (see figure)
- Excise the skin at the stoma position
- Incise the abdominal fascia
- Pull through gently the small or large bowel outside
- Suture the bowel to the skin

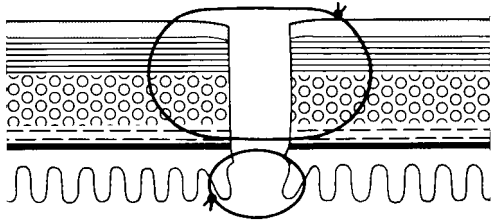


Annexe: Suture Techniques

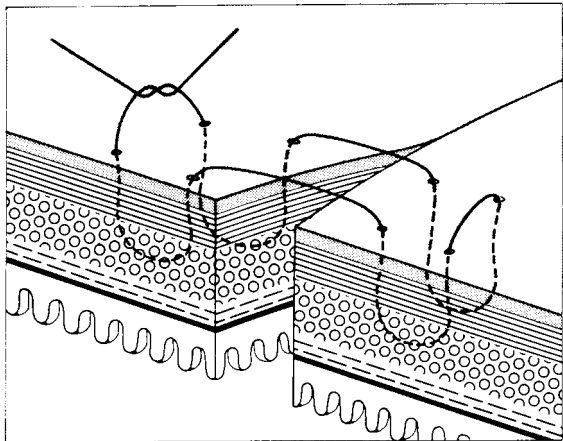
Single row



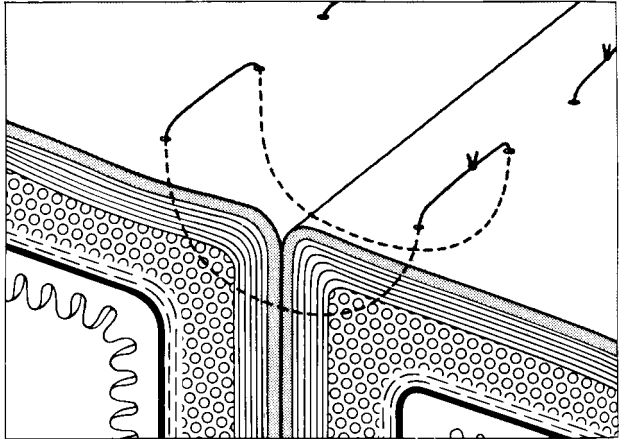
Two row



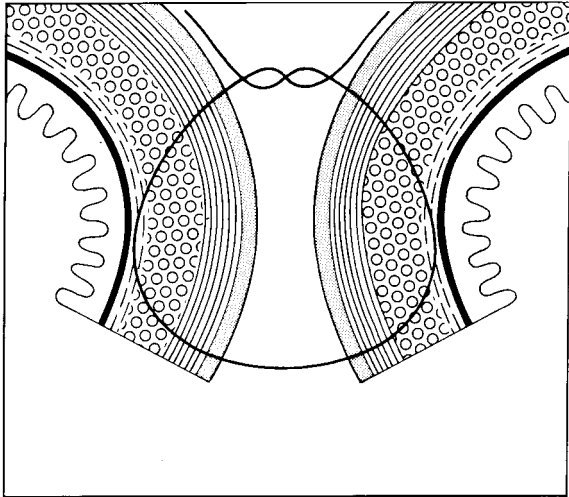
Single row inverting sutures



Halsted suture (open)



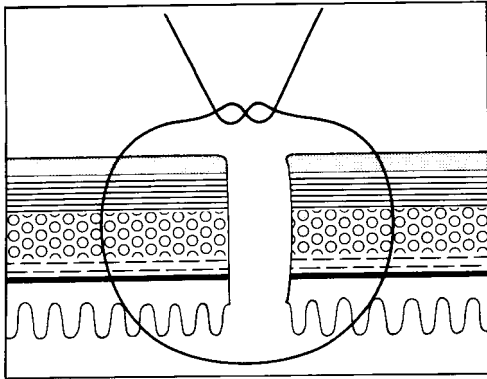
Halsted suture (knotted)



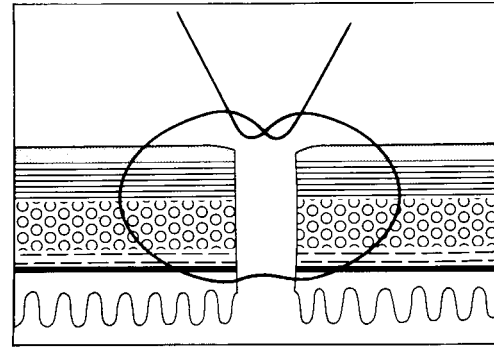
Lembert suture

Annexe: Suture Techniques

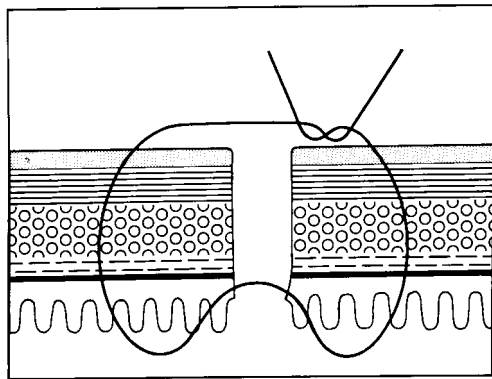
Single row sutures



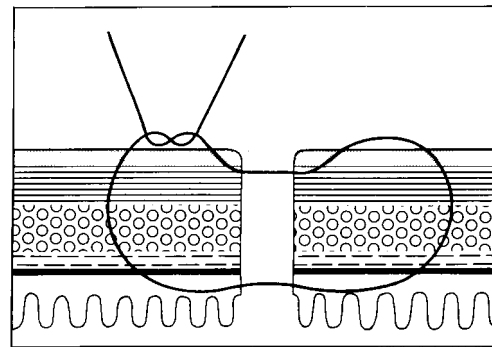
All layer suture (Albert)



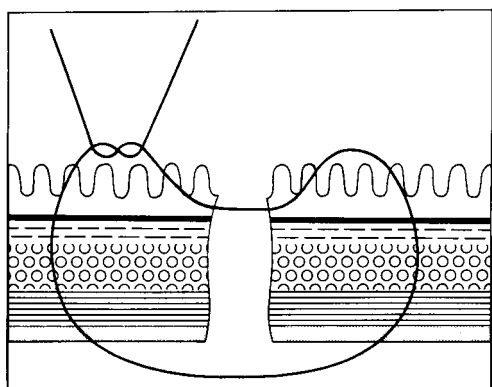
Extramucosal suture



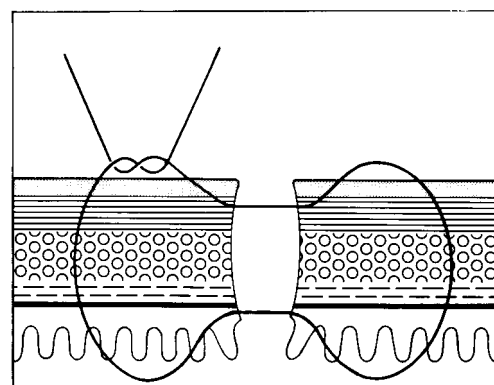
Gambee Stitch
Full thickness + mucosa backstitch



Extramucosal suture
Backstitch through serosa



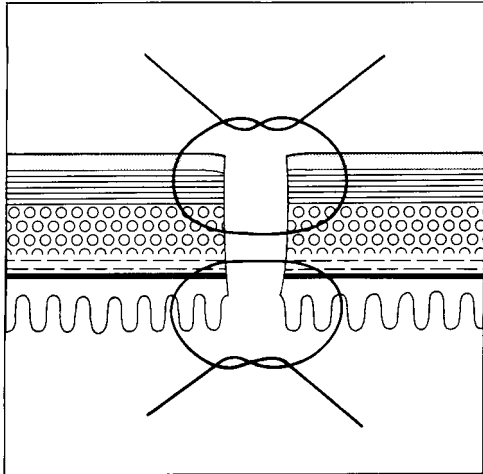
Backwall suture (Donati) - Full thickness
from inside + mucosa backstitch



Herzog Stitch
Full thickness from outside
Backstitch through mucosa and serosa

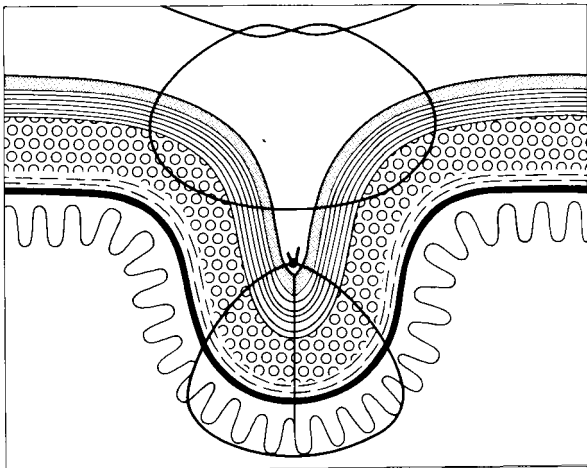
Annexe: Suture Techniques

Two row sutures

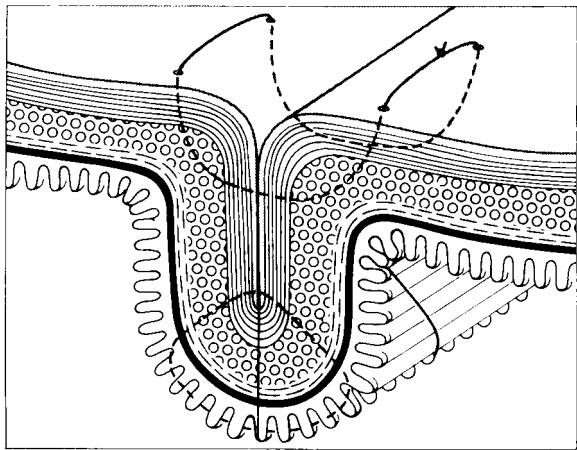


Mucosa from inside
Serosa from outside (Wolfer)

Two row inverting sutures



Albert-Lembert



Albert-Halsted

Notes:

Authors:

Prof. Dr. Rudolf Bumm

AMEOS-Klinik, Alfeld, Deutschland

PD Dr. Christian Hamel

Viszeral- Allgemein- und Unfallchirurgie, Kliniken des Landkreis Lörrach,
Lörrach, Deutschland

Prof. Dr. Felix Harder (retired)

Rittergasse 27, 4051 Basel, Schweiz

Prof. Dr. Christian Herfarth (deceased 2014)

Chirurgische Universitätsklinik Heidelberg, Heidelberg, Deutschland

Prof. Dr. Thomas Kocher

ChirurgieBaden, Langhaus 2, 5400 Baden, Schweiz

Prof. Dr. Jürg Metzger

Departement Chirurgie, Kantonsspital Luzern, Luzern, Schweiz

Prof. Dr. N.M. Merkle

Chirurgische Klinik, St. Bernward Krankenhaus, Hildesheim, Deutschland

Prof. Dr. Claes Rudberg (retired)

Kirurgiska Kliniken, Centrallasarettet, Västerås, Sweden

Prof. Dr. Hans-Detlev Saeger (retired)

Departement Chirurgie, Universitätsklinikum der TU, Dresden, Deutschland

Prof. Dr. Norbert Senninger

Allgemeinchirurgie, Universitätsklinikum, Münster, Deutschland

Mr. William E.G. Thomas, MS, FRCS

Department of Surgery, Sheffield Teaching Hospitals NHS Foundation Trust, Sheffield, UK

PD Dr. Peter Vogelbach

Departement Chirurgie, Regionalspital, Dornach, Schweiz

Responsible Editors: **Prof. Dr. Jürg Metzger**, Departement Chirurgie, Kantonsspital,
Luzern, Schweiz

PD Dr. Christian Hamel, Viszeral- Allgemein- und Unfallchirurgie,
Kliniken des Landkreis Lörrach, Lörrach, Deutschland

Co-Editors: **Prof. Dr. Thomas Kocher**, Baden, Schweiz; **Mr. William E.G. Thomas**,
FRCS, Sheffield, UK and **PD Dr. Peter Vogelbach**, Dornach, Schweiz