FEDERAL UNIVERSITY, NDUFU-ALIKE, IKWO

STUDENTS' INDUSTRIAL WORK EXPERIENCE SCHEME (SIWES)

A REPORT OF SIX (6) MONTHS STUDENTS' INDUSTRIAL WORK EXPERIENCE SCHEME

AT

JOS UNIVERSITY TEACHING HOSPITAL, (JUTH), PLATEAU STATE.

BY;

NAME: AKINOLA OLUWAPELUMI MATTHEW

REG. NO.: FUNAI/B.Sc/14/1150

DEPARTMENT: ANATOMY

COURSE TITLE: SIWES AND SEMINARS

COURSE CODE: ANA 372

In partial fulfillment for the award of a Bachelor of Science degree (B.Sc) in Anatomy

10-0CT-2017

APPROVAL

This is to certify that this Student Industrial Work Experience Scheme (SIWES) Technical Report was carried out By AKINOLA OLUWAPELUMI MATTHEW, FUNAI/B.Sc./1150 and has been read and approved as having satisfied the requirements of the Department of Anatomy, Faculty of Basic Medical Science, Federal University Ndufu-Alike,Ikwo, Abakaliki Nigeria for the award of Bachelor of Science (B.Sc.) degree in Human Anatomy

…… ……

MISS. ITORO OKU GEORGE DATE

(DEPARTMENTAL SIWES COORDINATOR)

…… ……

MR. AKUNNA G.G DATE

(DEPARTMENTAL SIWES COORDINATOR)

…… ……

Dr. EZEMAGU U.K DATE

(HEAD OF DEPARTMENT)

DEDICATION

I dedicate this work to my sister Mrs. Adegoke Olawumi and her Family and Miss. Elizabeth for their Financial and Moral support in the course of this training and also to my late industrial based supervisor Mr. Lima Muhammad. May his gentle soul rest in perfect peace.

ACKNOWLEDGEMENT

My utmost gratitude goes to almighty God who has brought me thus far from the beginning to the end of this Industrial Training (I.T).

Many thanks to all my industrial base supervisors, the internship students and the staff in Histopathology and Radiology department of Jos University Teaching Hospital for their vital support

My sincere appreciation and profound gratitude goes to my parents Pastor & Mrs. Adeniyi for their love, care, encouragement, and assistance throughout the period of this program. I deeply recognize and appreciate the exceptional sacrifices they have made to make not just this program a success, but indeed my whole life. I also want to appreciate all my siblings, Peace, for their constant support and encouragement. May God lift you up amen

In like manner my big thanks go to my department SIWES coordinator and the entire staff of the Department of Anatomy of Federal University Ndufu-Alike Ikwo, for the knowledge they have imparted in me

TABLE OF CONTENT

Tittle page

Approval…….....i

Dedication…….ii

Acknowledgement…….iii

Table of contents…….…..iv

List of figure……..……...v

List of table…….v

CHAPTER ONE

INTRODUCTION

1.1 History of Students Industrial Work Experiences Scheme (SIWES)……1

1.2 Objectives of SIWES……..……..2

1.3 Importance of SIWES ……...2

1.4 Brief History of Industrial Training Fund (ITF)……..……3

1.5 Role of ITF……...……3

1.6 Philosophy of the establishment……...4

1.7 History of JUTH…….…4

1.8 Organogram……...6

CHAPTER TWO

REPORT ON DIFFERENT SECTION OF THE ESTABLISHMENT

2.1 Department of morbid anatomy and histopathology.....7

2.1.1 Mortuary unit.....7

2.1.2 Histopathology laboratory unit.....8

2.2 Radiology department.....9

2.3 Instrumentation.....11

2.4 Relevant experience.....19

CHAPTER THREE

WORK CARRIED OUT DURING THE SIWES PROGRAM

3.1.1 Mortuary Science.....20

3.1.2 Embalmment.....21

3.1.3 Aims of embalmment.....21

3.1.4 Embalming treatment classifications.....21

3.1.5 Embalming fluids.....23

3.1.6 Embalming technique.....23

3.2 Autopsy.....26

3.2.1 Types of autopsy.....27

3.2.2 Autopsy Procedures.....27

3.3 Histopathology……..32

3.3.1 Reception……..…33

3.3.1.1 Setting of tray for fine needle aspiration cytology (FNAC)……..33

3.3.1.1 Procedure for taking FNAC……...34

3.3.1.3 Procedure for cytological sample spilling……...35

3.3.2.1 Grossing or cut-up……..…35

3.3.2.2 Tissue processing……..……36

3.3.3 Embedding ……..…41

3.3.4 Tissue sectioning……..……..43

3.3.4. Tissue staining……..45

3.4 Radiology……..……..49

3.4.1 Plain Radiography……..……49

3.4.2 Ultrasound ……..…54

3.4.3 Computer tomography……..…57

3.4.4 Magnetic resonance imaging……61

CHAPTER FOUR

4.1 Conclusion……...66

4.2 Problems Encountered During the Industrial Attachment……66

4.2 Recommendation ……..……67

LIST OF FIGURE

Fig 1 Organogram of JUTH……...6

Fig 2 Materials used in mortuary……12

Fig 3 Materials used in histopathology unit……..…..15

Fig 4 Materials used in radiology department…….……18

LIST OF TABLE

Table 1 Composition of Formal saline……...37

CHAPTER ONE:
INTRODUCTION

1.1 History of SIWES

The Student Works Experience Scheme (SIWES) was initiated by the industrial Training Fund (ITF) in 1973, as a means of blending theory and practical experience which was missing in our educational system. The scheme was therefore a skill training oriented programme designed to expose and prepare students on work which they would meet in post-graduation endeavors.

As a federal parastatal, ITF was established by Decree 47 of 1971 and charged with the responsibility of promoting and encouraging the acquisition of skills in industry and commerce with a view to generate a pool of indigenous trained manpower sufficient to meet the needs of the economy. A clause was invented by the Fund in 1978 in its policy statement No.1 dealing with the issue of practical skills among locally trained professionals. Section 15 of the policy states, The Fund will seek to work out cooperative machinery with industry whereby students will be trained in industry on commerce compatible with their area of studies. The Fund will support such mild career attachment by contributing to the allowance, etc, payable to the student. The scheme therefore was designed to provide the much needed practical experience for the students undergoing all courses that demand exposure in industrial activities and to promote the much desired technical knowledge.

1.2 OBJECTIVES OF SIWES

i. To provide means for students in tertiary institutions to acquire industrial skills and experience in their field of study.

ii. Prepare students on anticipated working situation after graduation.

iii. Expose students to work methods and techniques in handling equipment and machinery that are not available in their institution

iv. To ease the transition from school to the world or work and enable students contact for late job placement.

v. To bridge the gap between college work and actual work practice.

vi. Enlist and strengthen employer's involvement in the entire educational process of preparing students for employment.

vii. To promote industrialization in Nigeria and avenue between the word of teaching and learning, industrial work with reference to a field of studies.

IMPORTANCE OF SIWES

i. It provides students with an opportunity to apply their theoretical knowledge in real life situations.

ii. It exposes students to more practical work methods and techniques.

iii. It strengthens links between the employers, university and industrial training fund (ITF).

iv. It also prepares the students for labor market after graduation.

1.4 BRIEF HISTORY OF INDUSTRIAL TRAINING FUND (ITF)

The industrial Training Fund Act (ITFA) came into effect on 8 October 1971. The purpose of the Acts was to establish a Fund- the industrial Training fund (ITF). To be utilized to promote and encourage the acquisition of skills in industry or commerce in Nigeria with a view of generating a pool of indigenous trained manpower sufficient to meet the needs of the economy (Oyedele,2012). The ITF was the initiator of (SIWES) in the year 1973 and the programme is designed to expose students and give them opportunity to acquire knowledge as well as experience in various organizations. This programme is organized in closed relation with various Federal Government Agencies responsible for education and the institutions of higher learning such as National Universities commission (NUC), National Board of Technical Education (NBTE) and the National Commission for Colleges of Education (NCCE). The ITF then pays the allowances with fund provided by the Federal Government to students involved. The ITF also supervises the general implementation of this programme.

The programme was handed over to Nigerian University Commission (NUC) in the year 1975.

1.4.2 ROLES OF ITF

i. Organize bi-annual conference and seminars on SIWES.

ii. Provide logistic material needed to administer the scheme.

iii. Compile lists of employers and available training places for industrial attachment and forward such lists to the coordinating agencies (i.e. NUC, NBTE, and NCCE).

1.4.3 PHILOSOPHY OF JUTH

Jos University Teaching Hospital (JUTH) is an institution established by federal government of Nigeria. This establishment encompasses different sections, units and department which undertake different type of treatments.

The main mission of the establishment is to restore people's health and to training of health practitioner. Thus making lives better

1.4.4 BRIEF HISTORY OF JUTH

Jos University Teaching Hospital (JUTH) is a tertiary Health institution that provides specialize medical services, train health professionals and serve as a research center.

JUTH was established in 1975 under the leadership of then head of state Gen Yakubu Gowon but was fully commissioned by Gen Olusegun Obasanjo in 1977 with other six Federal Teaching Hospital in Maiduguri, Ilorin, Imo, Makurdi, Owerri and Abeokuta. Its first site was located along Murtala Mohammed way, Jos. By 1979, the hospital had the full complement of consultant staff and was approved for training of house officers but 1980 most of the project in the institution was abandoned. Things begin to take another awesome dimension as President Olusegun Obasanjo in 2007 commission the permanent site of the institution which is located at Lamingo, Jos north local government and was fully equipped.

In 2001, Bill and Melinda Gates Foundation found the AIDS Prevention in Nigeria Project in JUTH to establish service and research laboratory, carry out behavioral surveys in high risk

groups and commence a PMTCT program. Through this project, JUTH has developed a close and long-stand relationship with both Northwestern University and Harvard Chan School.

Fig 1 THE ORGANOGRAM OF JOS UNIVERSITY TEACHING HOSPITAL

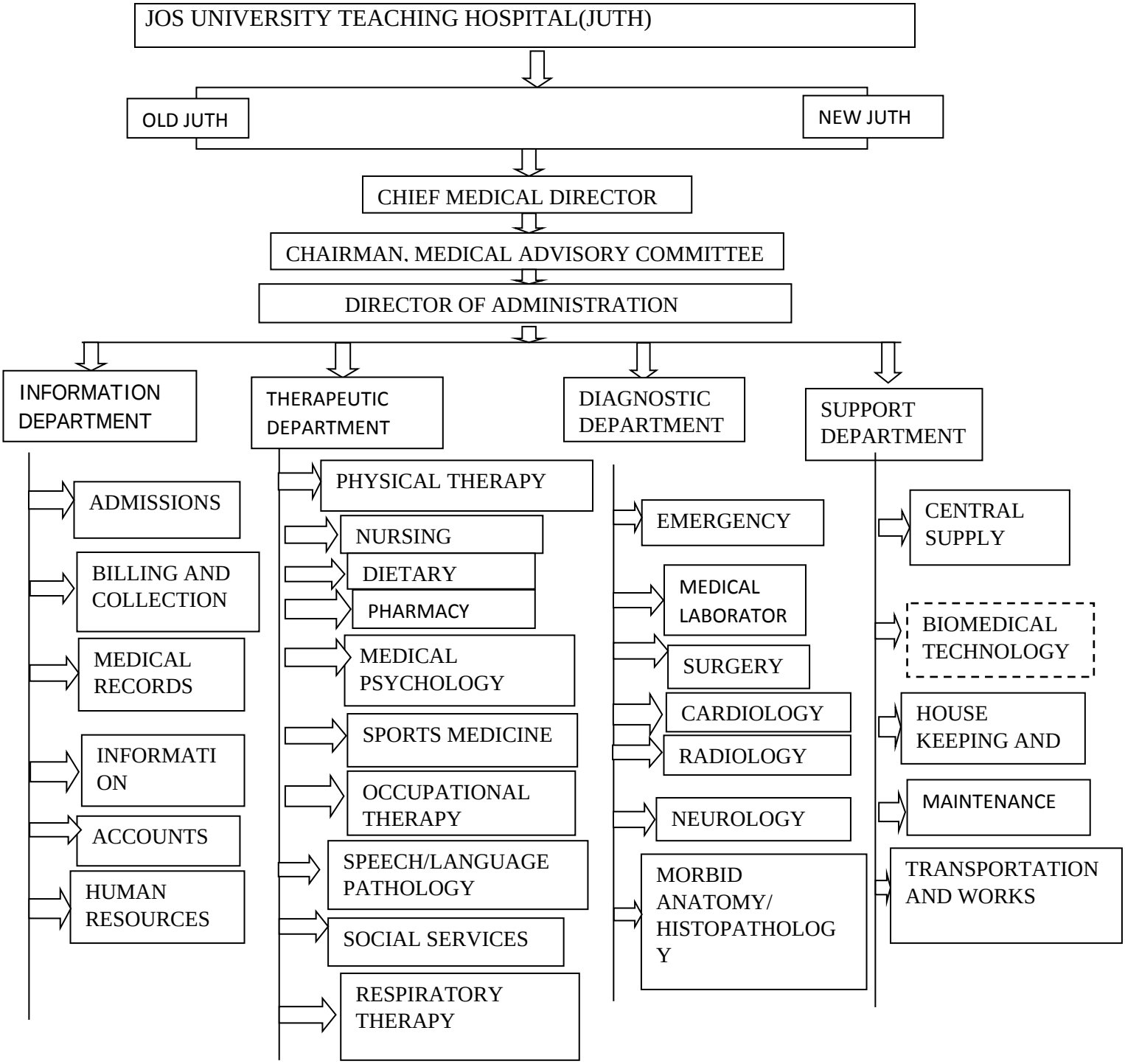

CHAPTER TWO

2.0 REPORT ON DIFFERENT SECTION OF THE ESTABLISHMENT

2.1 Department of Morbid Anatomy and Histopathology.

The department of morbid anatomy and histopathology is very important to medicine in Nigeria and most especially to Jos University Teaching Hospital. This is because of its contribution towards patient's healthy life's and also for research purposes and student training.

Tissue biopsy are carried out on patient of various pathologic complications ranging from tissue cancer, breast lump, kidney, liver, prostate and other tissues or organs in the body. Embalmment of bodys after death is also part of the services rendered by this department. In cases where the actual cause of death is unknown, autopsy on these bodies are carried out to ascertain the cause of death.

In other to conveniently perform this huge but important task, the department is divided into two (2) units. They are:-

i. Mortuary unit

ii. Histopathology unit

2.1.1. Mortuary unit

This is the section that is responsible for embalming and preserving of dead bodies waiting for burial. This unit also handle autopsy to find out the actual cause of death. This section encompasses different apartments which includes; the embalming and reception room, storage hall, dressing and autopsy hall, bathing room and last the resting room.

2.1.2. Histopathology Laboratory unit

Histopathology is the study of microscopic changes or abnormalities in tissues that are caused as a result of diseases. Histopathology lab uses both histology and cytology samples for diagnosis. This unit collects surgical sample for histological examination and Fine needle aspiration for cytological examination. These samples undergo various stages of processes and analyses in order to determine the nature of the disorder of the cells or tissues. These samples are also preserved in the process so as to retain their original shape and structure as lively as possible and also to protect tissues from autolysis and putrefaction.

The main use of histopathology is in clinical medicine where it typically involves the examination of surgically removed tissue or aspirate sample for the purpose of detailed study to further help in diagnosing, treating, and preventing future occurrences of a particular pathological complication.

The different sections under the laboratory unit include;

1. **Cytology bench**: Cytological samples (which could be serum, cerebrospinal fluid, FNAC of breast lump etc.) are being received and fixed here, prior to processing. Cytological samples received here are being fixed in alcohol and allowed for a period of 24hours before being processed. The process of collecting cytological samples used in my place of industrial training is fine needle aspiration cytology (FNAC) which involves using a syringe and needle to draw the fluid out.

2. **Cut-up bench:** Fixed tissues gotten from the surgical theater are been cut open and into smaller sizes at this bench and returned into fixative prior for processing.

3. Processing section: This is part of the job of those on cut-up bench. In this section, tissues from the cut-up room (histological sample) are being processed. This processes include, fixation, dehydration, clearing and impregnation or infiltration.

4 Embedding/Microtome bench: At this bench, tissues that are well processed are being embedded with embedding medium (paraffin wax) using a machine called **Embedding machine**. On this bench also, well embedded tissues are taking to the microtome for trimming and sectioning

5. Staining bench: Tissues on this bench are stained using any suitable and acceptable staining techniques. But the most widely used staining technique is hematoxylin and eosin (H&E) stain and Papanicolaou stain. Hematoxylin which is basic in nature stain the nucleus of a cell purple, dark blue or violet, while eosin which is acidic stains the cytoplasm pink or red.

2.2. RADIOLOGY DEPARTMENT

Clinical radiology is a specialized branch of medicine that uses ionizing, sound and spectroscopic techniques to capture images of the internal organs of the human body.

Clinical radiology uses three main kinds of imaging modalities to create internal images of the human body. These are:

- Plain radiograph and computed tomography (CT) scans, which uses ionizing radiation in the form of x-rays to image the body.
- Magnetic resonance imaging (MRI) scan this uses magnetic field, radio waves to produce detailed pictures of the inside of the body

- Ultrasound scan which uses high frequency sound waves to image the structures of the body

Other important imaging modalities include:

- Contrast study
- Doppler`s sonography
- Angiography and fluoroscopy
- Mammography
- Nuclear medical imaging

The rapid advances in clinical radiology technology and therapy have dramatically improved the diagnosis and treatment of many variety of conditions in human systems.

Clinical radiology has a range of benefits for the patient. These include:

i. It assists in making a diagnosis and further management of most body conditions.

ii. It is used to determine when a patient needs surgery.

iii. It is used to visually guide the treatment of conditions such as heart disease and stroke.

iv. It can eliminate the need for exploratory surgery.

v. Interventional radiology, which involves treatment as well as diagnosis, involves less risk, a shorter recovery time and less time in hospital than open surgery or key-hole surgery.

vi. It is used in screening for disease such as breast cancer (mammography), with early detection reducing the mortality rate.

vii. It improves cancer diagnosis and is also an effective treatment for cancer and other diseases.

2.3 INSTRUMENTATION

2.3.1 Materials used in the mortuary unit

- Trolley: Use to move the corpse from embalming place to storage place.
- Refrigerator: Use for storing corpse
- Scalpel and Blades: for making incisions
- Dissecting Forceps: for holding tissues
- Needle and Thread: for stitching tissues
- Gravity tank: for storing embalming fluid.
- Cotton wool: for closing orifice
- Face mask and eyes goggle- for protecting the face and eyes
- Rubber Tubule and Cannula: for delivery or removal of fluids
- Rain Boots: for protecting the leg and feet from biohazard
- Laboratory Coats and Aprons: for protection
- Embalming Tanks: contains embalming fluid
- Reagents: mostly embalming fluids which comprises of;
    - Formaldehyde
    - Water
    - Methylated spirit
    - Glycerin

2.3.2 INSTRUMENTS USED FOR AUTOPSY

- Saw: use for cutting the ribs other hard bones
- Autopsy bench: where the corpse will be laid before dissection.
- Suturing needle and thread: use for sewing and reconstitution of the body.
- Cotton wool: for closing of internal body
- Rib cutter: for cutting of the rib.
- Hammer: use for breaking the skull
- Chisel: for piercing hard tissues
- Surgical blade: for cutting of the body

Fig 2 Pictures of the Instruments used in the Mortuary JUTH

2.3.3. Instruments used in Histopathology unit

- Scalpel and blades→for anatomical dissections and surgery
- Surgical knives→ for anatomical dissections and surgery
- Gloves→cover and protect hands from biohazards
- Cassettes→for storing samples after grossing and during processing
- Cotton wool→for cleansing and also serves as barrier during embedding
- Surgical Cut-up board where samples are placed and cut-up or grossed
- Reagents→mostly fixatives, used to preserve the samples
- Reagent bottles→for storing reagents
- Reagent containers→ contains reagents ready for use
- Microtome→ for tissue sectioning
- Electric Water bath→for floating tissue sections
- Electric Hot plate→for heating scalpels, knives, and drying of slides
- Automatic Tissue Processor→ for processing tissues
- Wax Jar→ contains molten wax
- Syringe and Aspiration needles→for injecting into or withdrawing fluid from the body
- Staining racks→for holding slides during processing
- Slides and Cover slips-→for sample smears
- Stop watch→ for keeping time
- Coupling jar→ for fixing slides
- Refrigerator→for preserving samples

- Spatula→for lifting, mixing and spreading materials especially cassettes
- Microtome knives and Sharpener→sections tissues and sharpens microtome knives
- Conical flask→for storing reagents ready for use
- Measuring cylinder→ for measuring reagents.
- Electric Oven→ for melting wax and drying slides
- Pencil and Papers →for marking or labeling
- Electric Embedding machine →for burying tissue inside a molten wax
- Embedding mold→for shaping and molding wax block during embedding
- Embedding knives and bolts →for pressing the tissue to the surface during embedding
- Bunsen Burner and Tripod Stand→ source of heat
- Gas cylinder→supplies gas to the Bunsen burner
- Binocular Microscope→for viewing very small objects beyond human eyes, e.g. microorganisms

Fig 3 Pictures of the instruments used in Histopathology unit JUTH

CRYOSTAT



TISSUE
CASSETTE

REAGENTS

STAINING
MACHINE

STAINING MACHINE

2.3.4 Instruments used in Radiology Department

- Computed tomography machine→ used during CT scan to visualize the interior of the body and produces axial images. It is also used for PET-CT scan.
- Ultrasound machine→ used during ultrasonography and Doppler's sonography.
- Ultrasound gel→ used to reduce reflection that air-tissue against ultrasound beam
- Magnetic resonance imaging machine→used to viewsoft tissues most especially the brain.
- Mammography machine→used to image soft tissues of the breast.
- Contrast dye→ introduced into the body during contrast study.
- X-ray machine→ used during plain radiography to produce images of structures within the body
- Hand Gloves→Used to protect the hand
- Lab coat→ used to protect the body from radiation

Fig 4 Pictures of Instruments used in Radiology Department JUTH

2.4. OTHER RELEVANT EXPERIENCES

Apart from the vast practical knowledge which I have gained in the course of my training, I was also able to tap into different relevant life built experiences which I know that it would help me in my career pursuit. These include;

i. Use evident as a tool, not as a determinant of practice,
ii. Humbly accept death as an important part of life; and help people to make the best possible arrangements when death is close
iii. I have also learnt to have patient-doctor relationship, mutual-participation characteristics rather than active-passive cooperation in terms of medical decision making.
iv. To be proactively advocate for patients welfare, ready to learn from other regardless their age, role or status.
v. I have been enlightened and seen ways in which medical equipment and reagent should be handled to attain effective result.

CHAPTER THREE

3.0 WORK CARRIED OUT DURING THE SIWES PROGRAM

3.1. The Department of Morbid Anatomy/Histopathology

As mentioned earlier, the department of morbid anatomy/histopathology of JUTH has two basic unit. This unit is:

- Mortuary unit
- Histopathology unit

I was exposed to the different works that are carried out in these units.

3.1.1. MORTUARY UNIT

This section is responsible for the process of embalming and preserving of dead bodies awaiting for burial or cremation. This unit also handle autopsy to find out the actual causes of death. Mortuary is a room or building in which dead bodies are preserved and kept, for hygienic storage or for examination, until burial or cremation. Generally the mortuary performs

i. Temporary storage and preservation of bodies (embalmment)
ii. Performing post-mortem
iii. Demonstration of post-mortem findings in cases of clinical interest or teaching purposes

3.1.2 Embalmment

Is a process of chemically treating dead human body to reduce the presence and growth of microorganisms thereby preventing autolysis, putrefaction and restore an acceptable physical appearance of the body.

3.1.3 Aims of embalmment:

i. To restore the dead body to a life-like appearance
ii. To prevent growth of microorganism
iii. To avoid putrefaction and autolysis.
iv. To make the diseased person more presentable
v. To disinfect the dead body
vi.

3.1.4 Embalming treatment classifications

i. **Arterial Embalming:** This has to do with injecting of preservative solution under pressure, into the body circulatory system (**but not through the heart)** through an artery (usually through the carotid, femora, brachial arteries) while concurrently draining blood from a veins.

- Arterial embalming is also referred to as capillary embalming.85% of the body's blood is contained in the capillaries. The embalming fluid must go through the capillaries to enter the tissue spaces where it makes contact with the cells of the tissue and the body's protein thus embalming the body.

ii. **Cavity embalming:** is performed after arterial embalming. It is the direct treatment of the body's cavities which include abdominal, thoracic, and pelvic with embalming chemicals with aid of an aspirator and trocar.

- The embalmer makes a small incision just above the navel and pushes the trocar into the chest and the stomach cavities to puncture the hollow organs and aspirate their contents. He then fills the cavities with concentrated formaldehyde. The incisions is then closed with trocar button.
- The purpose of cavity embalming is to reach the hollow organs that are not penetrated by the arterial embalming solution.

iii. **Hypodermic Embalming:** is the subcuticular injection of suitable preservative chemical directly into the tissues. It is accomplished by use of a syringe and needle, or an infant or standard trocar.

- The treatment area can include finger tips, the cavity walls of an autopsied body, or a limb that won't accept arterial embalming.

iv. **Surface Embalming:** is the application of an embalming chemical directly to the surface of the tissues either by dipping the corpse directly into the embalming fluid or applied with an aerosol spray, or painted on with a brush using a liquid or gel, and can even be applied using cotton wool. Areas that are surfaced embalmed can be under the eyelids, the cavity walls in autopsied bodies, and underneath the cranial scalp when a cranial autopsy has been performed

3.1.5 Embalming fluids:

These are mixture of variety of preservatives, sanitising and disinfectant agents, and additive's used in modern embalming to temporally prevent decomposition and to restore a natural appearance for viewing a body after death.

The embalming fluids are prepared from propylene glycol which keeps the muscle moist; 10% buffered formalin used as fixative; isopropyl alcohol used as a preservative; and liquefied phenol, which is used as a mold preventive. Colouring of the blood vessels is useful in their identification with a small amount of amphyl, which is also used as a disinfectant.

3.1.6 Embalming technique

Material needed: Embalming fluids, Scalpel and blade, Forceps, Needle, Thread, Gauze, Rubber Tubule or Cannula, Long hand gloves, Face masks, Cotton wool, Light, Embalming tanks and reagent bottles.

Embalming procedure

There are three steps in embalming procedure;

1. Pre-embalming procedure
2. Main embalming procedure
3. Post-embalming procedure

Pre-embalming procedure

i. The body must be certified death by a medical doctor who is in charge of the deceased

ii. Pulsation, breathing, rigor mortis must be noted.

iii. The body must be registered and have a document pertaining the cause of death, date, in which the body arrived and will leave the mortuary and name of next of kin

iv. Then payment will be made.

Main embalming Procedure

i. After the above processes, the corpse is undressed and a wrist band containing the name of the corpse is worn onto the wrist of the body

ii. The body is wash and clean with disinfectant solution and the body is place in an anatomical position

iii. The arm, hand, legs are flexed to release rigor mortis and also the mouth and eye are closed.

iv. The embalming solution is prepared; an incision is made over the carotid artery (carotid triangle, Neck region) or most times over the femora artery (femora triangle, thigh region). The artery is located and brought above the skin with the aid of aneurysm hook.

v. Small incision is made on the artery and a cannula is inserted into the incised artery

vi. Then a suture thread is used to tie the artery with the cannula, this is done to prevent leakage during the inflow of fluid into the artery

vii. The cannula is connected to arterial tubing which is connected to a gravity embalming tank which is placed on a height. Before the embalming fluid is injected, the air is removed from the connecting tube to avoid possible airlocks produced by the vessels of the body during the injection of the fluid

viii. Then the embalming tank is turned on to allow free flow of fluid into the body. This take about 30-40 minutes depends on the pathological state of the body.

ix. During embalming, mixture of blood and formalin was seen gushing out from the eyes, nose and ears. which is an evidenced of a well embalmed body

x. After completion, cannula and tubes are removed and incision sutured. The abdominal cavity is treated by the use of a hollow tube called a trocar that is used to aspirate gasses and liquid contents under suction. An embalming chemical is introduced. Also some part of the body that did not received enough fluid where injected.

xi. While doing this, protective glasses, a mask, and gloves are worn to prevent contact to harmful chemical and bacterial

Post-embalming Procedure

i. Identification of body by the deceased family

ii. The body is washed with disinfectant solution

iii. Shaving may be done to clear the mandibular hairs.

iv. The body is dressed with cloth, hand glove, stockings and other applicable clothing material.

v. The body is then laid in a coffin ready to be transported for burial.

3.2 AUTOPSY

Autopsy also known as postmortem examination is a highly specialized surgical procedure that consist of a thorough internal and external examination of a corpse by dissection to determine the cause of and manner of death and to evaluate any disease or injury that may be present or to determine whether a particular medical or surgical treatment has been effective. Autopsy is usually performed by a specialized medical doctor called PATHOLOGIST.

In academic institutions, autopsies sometimes are also requested for teaching and research purposes.

Aim: The major aim of autopsy to know;

- The time of death
- The cause of death
- Damage to the body (including damage from disease)
- The type of death (suicide, murder, or natural causes)

Material used: Scalpel, Bone saw, Enterotome, Rib cutters, Hagedorn needle, Skull chisel, Scissors, Forceps, Hammer, vibrating saw, Autopsy table, Arterial tube, head rest, surgical gloves, Nose mask, Jacket and apron, Medical syringes, Foley catheter, Water bath, Tongue tie, Formaldehyde.

3.2.2 PROCEDURES

1. **Before Performing an Autopsy**:

- Permission for an autopsy must be given by the deceased person`s family or by the courts or by a coroner in the case of medico-legal or forensic autopsy.
- Collection and documentation of appropriate data of the person and about the events that led to the death. This includes looking at the medical records of the deceased person before commencing the autopsy.
- Photograph of the body will be taken while still dressed and after being undressed

2. **During autopsy;**

During the autopsy two main examinations are carried out on the body which include;

a8[ich incDur of autops3;

- The body length is measured from heel to crown, the body weight is measured if facilities are available; if not, it should be estimated (the weight of infant must be measured.)
- Acquired external marks e.g. birthmark may be important for identification purposes or in relation to past injuries and disease. Tattoos, circumcision, amputations, surgical scars, fracture deformities, lacerations, abrasions, bruises, burns or suicidal/homicide attempts on the wrist and throat are noted.
- Vomit, froth or blood may be present at the mouth and nostrils, and faeces and urine may have been voided, all this are taken for poison test. This can also be correlated with the degree of post-mortem decomposition.
- The genital areas are check for any signs of rape. Bruising and tearing are common in such cases.

Internal examination

Incisions

- "Y"…deep shaped incision is made behind each ear, down the neck, meet mid-sternum and continue to the groin. Or make a "T" … deep shaped incision from each shoulder, meet top of sternum (jugular notch), and continue to the groin. The incision are made using scalpel
- Spread open the skin and check to see if any rib are broken. Split the rib cage using the

b. Ghon's "En Bloc" method – Organs are removed in sections

- Examine each organ in the thorax individually. Weigh each organ, record anything notable, and take a tissue sample if further examination is needed. Many of the organs in the thorax are also dissected for thorough examination. And if a pneumothorax has been suspected beforehand, a post-mortem ra

Significance

The cause of death is stated from the record gotten during the examination. In the case of forensic autopsy the result gotten from the examination can be used to convict the murderer or used to improve medical treatment in case of clinical autopsy.

3.3 HISTOPATHOLOGY LABORATORY

Histology is the study of the cellular organization of body tissues and organs.

Pathology is the study of disease. Therefore;

Histopathology is the branch of science that deals with the gross and microscopic study of cells or tissues affected by disease. It is an important tool in clinical science because cancer and other diseases require thorough histopatholigical examination. Histopathology laboratory is responsible for the processes, microscopic examination and diagnosis of pathological sample. The tissue processing are carried out by medical lab scientist while the microscopic examination and diagnosis are carried out by histopathologist.

Due to high workload, the lab is sub divided into different sections/bench which include;

1. Reception
2. Cytology Bench
3. Grossing or Cut-up Bench/ Tissue Processing Bench
4. Embedding / Microtome bench
5. Staining Bench

3.3.1 Reception

This section/bench is responsible for the collection, setting of tray for FNAC, spilling (using centrifuge) and making of smear for cytology specimen, and documentation of samples.

STEP TO BE TAKING BEFORE COLLECTION OF SAMPLES

i. To note if the specimen is for histological examination or cytological examination.
ii. To note that the container is clearly labeled and followed by a complete request form.
iii. To note that the request form is detailed with necessary information needed and signed by a physician and stamped (for NHIS OR FHSS).
iv. Note if the tissue in the container correspond with the name of tissue writing on it request form and the label.
v. Note if the tissue or smear is fixed in appropriate fixative.

3.3.1.1 Setting of tray for Fine Needle Aspiration Cytology(FNAC);

Materials needed:

- About 6-8 microscope slides (Frosted-end slides) labelled appropriately e.g C/112/17,
- Coupling jar containing 95% alcohol.
- Syringes and needle (2, 5 and 10ml).
- Pencil for marking.
- Gloves.
- Cotton wool.
- Alcohol or Methylated spirit for swabbing the site needed for aspiration

3.3.1.2 Procedure for taking FNAC

Note: This procedure is carried out by histopathologist

- **i.** The patient is instructed to lie in a supine position on an examination couch or in a sitting position.
- **ii.** Localise the mass cleanse firmly with an alcohol swab (as used for routine injection).
- **iii.** Introduce the needle into the mass. Create negative pressure and maintain.
- **iv.** Sample area vigorously on several planes, maintaining the negative pressure.
- **v.** Release the plunger on syringe to equalize pressure and withdraw the needle from the mass.
- **vi.** Place a small drop of the aspirated sample onto a microscope glass slide.
- **vii.** Place a second glass slide on the top of the drop of aspirated material and create a smear. Avoid excessive pressure when preparing the smears to prevent cell distortion and crush artefact.
- **viii.** Fix the slides with a 95% alcohol in a Coupling jar immediately. If both breasts are being aspirated, indicate from which breast the sample was obtained on the glass slides.
- **ix.** A minimum of two samples per site is recommended.
- **x.** The sample is sent to the Laboratory immediately for processing.

3.3.1.3 Procedure for cytological sample spilling

i. Filled centrifuge container with the specimen.

ii. Insert the centrifuge bottle into the centrifuge. Ensure that at least two centrifuge bottle is present in the centrifuge for balancing.

iii. Put on the centrifuge and Spilled for 5 minute

iv. Make a smear on a well labelled 4-6 microscope slide and fixed the slide with 95%alcohol in a coupling jar immediately

v. Take the to the laboratory for processing

3.3.2.1 Grossing or cut-up/tissue processing

In grossing, tissues are examined macroscopically. This involves;

External Examination; in external examination the weight, lengths, colour, texture of the tissues and shapes are taking and documented.

Internal Examination; This involved surgical opening and observation of the internal layer of the tissues.

After the above examination the tissues site of infection are cut into small suitable size and are kept in tissue cassette which in turn are arranged in ATP tissue basket.

Note; all this procedure above are done by histopathologist.

Materials needed: A cutting board, specimen containers, 10% formal saline, forceps of various sizes, scissors of various types and size, probe, bone cutting saw or electric bone cutter, scalpel, disposable blades, long knife and ruler to measure the size of lesion and specimens, tissue cassettes, reagent container, disposable gloves, pencil/pen, eosin and tissue paper for staining and ramping tiny biopsy.

3.3.2.2 TISSUE PROCESSING

Tissue processing is a procedure that takes place between grossing and the embedding/sectioning.

It is the process of passing tissues gradually through a series of reagents mostly carried out with the aid of Automated Tissue Processor (ATP) Machine.

WHAT IS AN ATP MACHINE

An automated tissue processor is a time regulating machine designed to fixed, dehydrate, clear and impregnate or infiltrate tissues within a speculated time.

This machine is made up of 12 Jars,

First jar is filled with a fixative usually 10% formal saline,

Next four jars are filled with ascending grades of alcohol for dehydration

Next four jars are filled with a clearing agent usually xylene

The last 3 jars are filled with an impregnating agent i.e paraffin wax.

There are four (4) main steps in Tissue Processing;

- Fixation
- Dehydration
- Dealcoholisation(Clearing)
- Impregnation(Infiltration)

Fixation: It is the process of using chemicals called fixative to prevent deterioration of tissues thereby maintaining the structural integrity of a specimen so that it can be viewed microscopically.

There are many fixative that are used to fixed tissues but the most commonly used fixative is 10% formal saline, which contains water, formaldehyde and common salt. Except in brain tissue in which 20% formal saline is used.

In ATP machine, a fixative perform two functions

1. To fixed tissues
2. To delay time in which the tissue will be processed.

The most commonly used fixative is 10% formal saline-

Table 1 preparation of 1littre of 10% formal saline

40% formaldehyde	100ml
Sodium chloride	9g
Distilled water	900ml

Other fixative used are zenker's fluid, zenker formal e.t.c

Qualities of a good Fixative

- It should prevent autolysis and putrefaction
- It should permit restoration of natural colour of photomicrograph
- It should kill rapidly without distortion.
- It should be simple to prepare and economical to use
- Should impact a suitable hardness and texture to allow easy section.

- To render the tissues receptive of stains.
- Should not be toxic non corrosive and non-inflammable
- Should allow for long time storage of specimen.

Dehydration

Is the process in which the water content present in the tissue to be processed areremoved by passing the tissue through increasing concentrations of dehydrating agents.Isopropyl alcohol (IPA) is a favoured reagent because it is miscible in paraffin. The tissue must not be dehydrated rapidly because this will causedistortion of the tissue. Rather, dehydration is carried out in a slow, step-wise manner bypassing the tissue block through a series of solutions of increasing concentration of alcohol ranging from 70%, 85%, 95% and 100% allowing the tissues to spend at least 1 hour in each level of concentration depending on the numbers of tissues to be processed. In this way the water is fully leached out and replaced with alcohol.

Various dehydrating agents used are;

- Ethyl alcohol
- Acetone(but very volatile)
- Isopropyl alcohol
- Dioxane

Clearing

Clearing also known as de-alcoholisation is the process of removing absolute alcohol from tissue and replacing it with a solvent which is miscible with absolute alcohol and paraffin wax. The aim

is to increase the refractive index of the tissue. Shrinkage of tissue can occur at this stage as xylene also removes fat residues left in the samples.

The substances used for clearing are called clearing agent or antimedia. Examples of antimedia are benzene, toluene, xylene, petroleum ether, chloroform, cedar wood oil, carbon disulphate, tetrahydrofural and carbon tetrachloride. But the most widely use agent is Xylene.

Methods of Clearing

- **Rapid method:**

  Xylene I → Xylene II → Xylene III

  30minutes 30minutes 30minute

- **Routine method:**

  Xylene I → Xylene II → Xylene

  1 hour 1 hour 1 hour

Impregnation (Infiltration)

It is the process of replacing a clearing agent or ante-medium with molten paraffin wax.

Molten paraffin wax completely displaces clearing agents from the tissue and goes to fill the intra and inter cellular spaces and cavities within the cell. Paraplast Plu is normally use at this stage.

Infiltration of Molten Paraffin Wax into Tissue Can Be Carried Out In Two Ways

a. **Impregnation at normal pressure(Manual/Automatic impregnation):** This is carried out by the manual and automatic machine. In manual impregnation, hot air oven is used, maintained at a temperature of 5^0C to 10^0C above the melting point of wax to keep the wax in molten condition.

Automatic machine (ATP) has the ability to regulate its temperature ranging from 58^0C.

b. **Impregnation at reduced pressure(Vacuum impregnation):** Infiltration is faster when done at a reduced pressure in a vacuum oven. It involves rapid replacement of clearing agent with paraffin wax at a reduced pressure using vacuum oven.

Methods of impregnation

Rapid method:

Paraffin wax I → Paraffin wax II → Paraffin wax III

30minutes 30minutes 30minutes

Routine method:

Paraffin wax I → Paraffin wax II → Paraffin wax III

1hour 1hour 1hour

Manual Method

The jar containing paraffin wax I, II and III should be put in oven at a temperature of 5^0C to 10^0C above the melting point of wax to keep the wax in molten condition. After the final infiltration, the tissue cassettes are transferred to embedding bench.

Impregnations help in increasing the optical differentiation and harden the tissue which helps in easy sectioning of the tissue.

3.3.3 EMBEDDING BENCH

Embedding is the process of burying tissue inside a medium such as molten paraffin wax which when solidified will provides sufficient external supporting matrix to aid well tissue sectioning. This medium not only makes it possible for easy microtomy but also for easy preservation of tissue for future use. Tissue should be well oriented in the mould during embedding so that a complete representation of all parts of the tissue is presented in cut sections.

Materials Used; Embedding machine, metal mould, forceps, paraffin wax, Bunsen burner, gauze, cassettes containing well processed tissues

The embedding machine has a hot reservoir for melting paraffin wax, a hot and cold plates for moulding and setting of blocks and a chamber for keeping embedding metal mould.

Procedure for Embedding Tissue:

a. Pour the paraffin wax into the hot paraffin reservoir of the embedding machine and allow it to melt (this can take up to 30minutes) or better still the paraffin wax can be melted using the bunsen burner to fasten the process
b. Using forceps, pick out the metal embedding mould and placed it on the hot plate of the embedding machine.
c. Fill the mould with molten wax

d. With forceps, remove the infiltrated tissue from tissue cassette and set the best suitable face of the tissue needed for sectioning into molten wax containing mould. Ensure that the widest face of the tissue is touching the surface of the mould

e. Use a warm forceps to slightly press the tissue down to the surface of the mould.

f. Detach the main labelled part of the tissue cassette and place it on top of the tissue.

g. With the aid of warm forceps, slightly press the cassette down to the surface of the tissue and fill up the mould with molten wax.

h. Transfer the whole mould to the cold plate of the embedding machine to solidify molten wax

i. Remove the embedded tissue (remember the tissue is with a tag detached cassette) from the mould for trimming.

Trimming

A well embedded tissue undergoes two forms of trimming.

a. The first trimming is carried out to melt away wax that clings or attached to sides and edges of the detached cassette embedded with the tissue. This is done with aid of a hot plate

b. The second trimming is done on a microtome, this form of trimming is carried out to expose the face of the tissues before sectioning. Since tissue is completely surrounded by paraffin, it is useful to uncover the surface of the block to reveal the tissue. This is done on the microtome at approximately 30 microns at a time until the entire tissue surface is exposed. Tissue that was embedded improperly may not reveal the entire tissue surface and will have to be re-embedded. It is critical to have the entire flat tissue surface revealed so that the section is complete, representative, and diagnosable.

After trimming the trimmed embedded tissues are place on an ice-block or the cold plate of embedding machine to partially hydrate the tissue for easy sectioning. Soaking faced tissue blocks in a little bit of ice water sectioning much easier, especially if tissue has been overly dehydrated during processing. Tissue types that benefit the most from hydration are: bloody samples, bone, uterus, brain, liver, heart tissue, and colon biopsies. Re-hydrating tissue prevents tissue chatter or splintering, something that often occurs with bloody tissue

3.3.4 SECTIONING BENCH

Is the process of making thin slices of tissues for pathology and anatomical observation using a microscope. Sectioning is accomplished by using a cutting apparatus called MICROTOME

Microtome is a machine that is used to drive a knife called microtome knife or blade across an embedded cube shaped tissue to produce a series of thin sections of very precise thickness. There are many types of microtome but the most commonly used microtome is the rotator microtome

Materials Used: Water bath, wax blocks embedded with tissues, rotatory microtome, microtome blade, distilled water, frosted slide, flat surface rubber glycerol and egg albumen, a rubber bottle containing 20% alcohol.

Procedure for Sectioning:

i. Set the water bath to reach 48$\pm$4 degrees Celsius (2^0C-5^0C below the melting point of paraffin wax) before sectioning to heat water. This is used to float the tissue section prior to picking with a slide

ii. Put the block tissue in the block holder of the microtome.

iii. Place a very sharp fresh blade on a microtome and lock it in place and make sure blade guards are closed and also lock microtome handle while inserting the blade

iv. Adjust the block holder screws to place the block parallel to the blade or better still adjust the microtome knife holder close to the block.

v. Unlock handle and turn handle until samples starts cutting a littleblock and section the block at 3-5 microns, this gives you a nice ribbon for easy microscopy. Some tissue biopsies are sectioned at different thickness but anything above 5microns is a thick section.

vi. Gradually pick the well sections tissue with a forceps and place it on a flat surface plate containing 20% alcohol. This help to create a convention current between the sectioned tissue and water bath, this help the ribbon to lose its folding.

vii. Lower it onto a water bath.Fold in section can be removed by simply teasing it with forceps

viii. Pick the section with the plain side of a frosted slide. Sometime a mixture of glycerol and albumen at ratio of 50:50 is applied on the slide before picking the section from the water bath to enable the section stick to the slide.

ix. Using pencil, write the lab registration number of the tissue on the frosted part of the slide and allow the water to drip dry.

x. Place the slides with paraffin sections on a hot plate to melt the wax and also to bond the tissue to the glass.

xi. Arrange the slides on a staining rack for staining.

3.3.4. STAINING BENCH

Since cell organelles lack enough contrast to be easily distinguished. Therefore Staining of histological sections is needed to allow observation of features otherwise not distinguishable by the microscope. With the help of stain, the physical features and relations of the tissues and their cellular constituent can be study. Most cells have affinity for different dyes, thus no single stain can adequately provide all the information needed about a cell or group of cells. For general work, two stains of contrasting colors (stain and counterstain) are usually selected to differentiate between nucleus and cytoplasm. Others, used singly or in combination, may provide specific information concerning the chemical and structural characteristics of all organelles.

The most widely used stain is hematoxylin and eosin. Hematoxylin (basic dye) stains negatively charged structures (nucleus), a blue color. Eosin (acidic stain) imparts a red or pink color to cell cytoplasm.

Hematoxylin and Eosin Staining Technique

Material used: Staining machine, water, xylene, alcohol, 1% acid alcohol, Scott's water, hematoxylin and eosin stain.

Staining machine is a machine used to perform staining of histological specimens.

Procedure for staining paraffin sections

1. De-waxing: de-waxing is a process of removing wax from sections. This is achieved by passing the sections in three changes of xylene for 10minutes each. Because wax is not permeable to stain

2. Removal of xylene: xylene is not miscible with water and low grade alcohols. It is therefore necessary to remove it with absolute alcohol.
3. Gradual hydration with descending grades of alcohol (85% then 70% alcohol) and then rinsed thoroughly in distilled water.

   Note: staining of cytological section does not require the above procedure.
4. Stain sections in hematoxylin stain for 5minutes depending on the strength of the hematoxylin.
5. Rinse sections in water
6. Briefly differentiate sections with 1% acid alcohol.
7. Rinse with water.
8. Blue in Scotts tap water for 2minutes (this help to oxidize hematoxylin to hematin
9. Wash with water
10. Counter stain in 1% eosin.
11. Rinse with water and dehydrate with absolute alcohol.
12. Dry

Result: Blue=Nuclei.
Pink= Cytoplasm, muscle fibrils, connective tissue fibers.

Mounting of a stained section: Mounting of histological section is very important because its help to protect the stained section from physical injuries.

Procedure:

1. Clear section with xylene
2. Apply a mountant (DPX=Distyrene Plasticizer Xylene) on cover slip

3. The back of the slide is wiped with clean dry gauze.
4. The slide is quickly inverted onto the covers slip, applying a gentle pressure.
5. Excess mounting medium is wiped away with a fingernail covered with gauze dipped in xylene.
6. Finally, the slide is labelled indicating the tissue type or stain used and specimen number. Arrange the slides for viewing.

Papanicolaou Stain

A PAP stain is the most important stain utilized in the practice of cytopathology most especially, a screening procedure for cervical cancer. It is a polychromatic stain that contains five dyes in three solutions. Hematoxylin, OG6, and Eosin Azure (which is a polychrome mixture of eosin Y, light SF and Bismarck brown.

This staining techniques was discovered by George Papanikolaou

PAP smear staining procedure

1. PAP smears are normally preserved in 95% alcohol, therefore take smear from alcohol to water
2. Stain with hematoxylin for 5minutes (depending on the concentration of hematoxylin)
3. Wash in water
4. Briefly differentiate in 1% acid alcohol
5. Wash in water
6. Blue in Scotts tap water for 3 minutes
7. Wash in two changes of absolute alcohol
8. Counterstain with OG6 (orange G6) for 3 minutes
9. Wash in two changes of absolute alcohol

10. Stain with EA36 (Eosin Azure) for 3 minutes

11. Wash in two changes of absolute alcohol

12. Dry

13. Mount with coverslip and DPX (Distyrene Plasticizer and Xylene)

RESULT:

- Hematoxylin stain the cells nuclei blue
- OG6 stains keratinize squamous cell carcinoma present orange-red
- EA 36 stains
  - Eosin Y stain cytoplasm pink
  - Light green SF stains metabolically active cytoplasm (parabasal squamous cells, intermediate squamous cells and columnar cells) cells blue
  - Bismarck brown stain nothing

3.4. TEST CARRIED OUT IN THE DEPARTMENT OF RADIOLOGY

Radiology is a medical specialty that uses imaging to diagnose and treat diseases seen within the body. Being able to identify normal structures on radiographs (X-rays) makes it easier to recognize the changes caused by diseases and injuries. The acquisition of medical images is carried out by the radiographer often known as radiologic technologist while the interpretation and report filing is carried out by a radiologist. This report is then transmitted to the clinician who requested the imaging. There are different types of imaging modalities used in radiology to image. This includes;

1. Plain radiography (X-rays)
2. Ultrasound
3. Computed tomography (CT)
4. Magnetic resonance imaging.

3.4.1 PLAIN RADIOGRAPHY

Plain X-rays are the simplest medical images created through X-radiation. Is the imaging of body structures, or parts of the body, using X-rays. X-rays are a form of radiation (X-radiation) similar to visible light, radio waves and microwaves. X-radiation is special because it has a very high energy level that allows the X-ray beam to penetrate through the body and create an image or picture.

Principle

The radiation is created when an electric current is generated from a high voltage generator. This causes electrons to “boil-off” from the cathode end of an X-ray tube assembly. These electrons are emitted from a filament on the cathode and rush towards a target material known as the anode. This process is known as thermionic emission.

The electrons emitted by the cathode rush towards the anode, which holds a disc made of tungsten. When the electrons collide with the tungsten, several interactions occur at the atomic level. One of these interactions causes electrons to be expelled from the outer orbits of the atoms releasing a X-ray photon. Energy levels of the X-ray photon will vary and can be adjusted when selecting a parameter known as kVP or kilovolts peak.

These X-rays then travel through a focusing cup**,** focusing and accelerating the photons towards the area of the body to be imaged. Traditionally, radiographic film was used known as double emulsion film containing silver nitrate. With technological advancements, many institutions will be using a digital plate receptor. These receptors are placed behind the patient to capture the x-ray photons that are transmitted through the patient and ultimately form the image.A dense structure like bone absorbs a high percentage of the x-ray beam (which appears light grey on the image), while low density structures like soft tissues absorb a small percentage (which appears dark grey on the image). The body has many different structures of varying densities and this difference creates a picture or image.

Procedure

a. Before the scan:

- An X ray request form is or a referrer letter from a doctor is essentially needed before the scan.It is important that you tell your own doctor and staff at the radiology facility if there is any chance you might be pregnant.
- The patient will also be given a hospital gown to wear, as some clothing can make it difficult to see the images clearly. You might also need to remove certain items, such as watches, necklaces and some types of clothing that contain metal objects, such as zips. The patient might need to take any previous X-rays with him or her so the radiologist (specialist doctor) can compare the new X-ray with the old one and see if there have been any recent changes. And also check if the previous scan was done recently, so as to determine if the scan should be carried out or not. This is very important to prevent over exposure to radiation which might result to radiation induced cancer

b. During a plain radiograph:

- The radiographer (trained X-ray technologist) who will carry out the X-ray will explain the procedure to the patient, your position (e.g. standing, sitting or lying) depending on the part of the body being examined, It is important that the patient stay completely still when the radiographer instructs to, as any movement might create a blurred image.
- Contrast may be needed, most especially X-ray images of the gastrointestinal tract.
- Depending on the pathological organ that is to be imaged, the radiographer determines whether an anterior-posterior (AP), posterior-anterior (PA), lateral or oblique view should

be used to image the organ. But most organs, particularly organs in the chest are well represented in images gotten from posterior-anterior (PA).

c. **After a plain radiography:** A radiologist (specialist x-ray doctor) then carefully assesses the images, makes a diagnosis and produces a written report on the findings. The report is sent to the referring doctor, specialist or allied health professional that referred the patient for the test.

Interpreting an X-Ray

The interpretation of an x-ray film requires sound anatomical knowledge, and an understanding that different tissue types absorb x-rays to varying degrees:

- **High density tissue** (e.g. bone) – absorb x-rays to a greater degree, and appear white on the film.
- **Low density tissue** (e.g. the lungs) – absorb x-rays to a lesser degree, and appear black on the film.
- **Intermediate density tissue** (e.g. muscle and fat) – appears as shades of grey.

It is important to appreciate that x-rays only give a 2D superimposed view of the body part that has been imaged. Therefore, it may be necessary to take multiple views of the same area from different angle (e.g. in cases of suspected fracture), to gain a full understanding of the injury

Advantages

i. It is fast and easy, so it is particularly useful in emergency diagnosis and treatment.
ii. X-ray equipment is widely available in hospitals, X-ray clinics and other locations, making it convenient for both patients and doctors, even in remote locations

iii. It is cheap and affordable compare to CT and MRI scan

iv. X-ray imaging is useful to diagnose disease and injury, such as pneumonia, heart failure, fractures, bone infections, arthritis, cancer, blockage of the bowel, collapsed lung e.t.c

Disadvantages

As X-rays usually use low amounts of radiation, the risk to your health is very small. However, repeated exposure to radiation may damage your body's cells which can increase the risk of cancer developing in the future. This is why the dose of radiation that is used during X-rays is always kept as low as possible. The reproductive organs are particularly sensitive to radiation, and are therefore shielded whenever possible.

Image of a normal plain radiograph film

3.4.2 ULTRASOUND

Ultrasonography is a technique that visualizes superficial or deep structures in the body by the uses high frequency sound waves.It is most commonly used to evaluate soft tissues and in obstetrics.Unlike other imaging techniques, ultrasound uses no radiation. For this reason, it`s the preferred method for viewing a developing foetus during pregnancy.

The resolution attainable is higher with shorter wavelengths, with the wavelength being inversely proportional to the frequency. However, the use of high frequencies is limited by their greater attenuation (loss of signal strength) in tissue and thus shorter depth of penetration. For this reason, different ranges of frequency are used for examination of different parts of the body:

- 3–5 MHz for abdominal areas
- 5–10 MHz for small and superficial parts and
- 10–30 MHz for the skin or the eyes.

Principles

Sound waves are generated artificially by means of piezoelectric crystals. The typical transducer consists of a disk-shaped piezoelectric element that is made vibrating by applying an electrical impulse via an electrode on each side of the disc. Likewise, the echo returning to the disk makes it vibrates, creating a small electrical potential across the same two electrodes that travel outward. Conversely, when sound or pressure waves hit the crystals, they emit electrical currents that can be amplified and recorded. If ultrasound gel is applied on the body surface, the crystal is brought into direct contact with body, the emitted ultrasound waves spread through the tissues, the tissue absorbs, scatter or reflect them. Absorption and spatial resolution increase with higher frequencies

Procedure

1. **Before an ultrasound scan:** This totally depends on the area or organ that is being imaged.
   - Know the patient's problem and medical history
   - For abdominal examination, the sonographer may tell the patient to fast for 8-12 hours before the ultrasound. This is because undigested food can block the sound waves, making it difficult for the technician to get a clear picture.
   - For examination of the gallbladder, liver, pancreas, or spleen, the patient may be told to eat a fat free food the evening before the scan and then to fast until the procedure is carried out. However, the patient can continue to drink water and take any medication as instructed
   - For examination of the urinary system, the patient might be ask to drink a lot of water and to hold his/her urine so that the bladder is full and better visualised.
2. **During an ultrasound scan**: The patient changes his/her clothing into a hospital gown.
   - The ultrasound examination is usually carried out with the patient in the supine position, it is often useful to turn the patient in an oblique position or to scan from the back in a prone position, e.g. when scanning the kidneys. Ultrasound also allows examination of the patient in a sitting or standing position, which may help in certain situations to diagnose stones or fluid collection (e.g. pleural effusion).
   - The sonographer will apply the ultrasound gel to the patient`s skin. This prevents friction so that the ultrasound transducer can be rubbed easily on the skin and also to avoid artefacts caused by the presence of air between them

- The transducer is placed on the skin of the patient and constantly adjusted to produce images in different direction of the organ that is been imaged. Depending on the area being examined, a patient might need to change position so that the sonographer can have better access

3. **After an Ultrasound scan:** After the above procedure, the gels will be clean off from the patient.
   - As a rule, both a written report and pictorial documentation should be prepared for each ultrasound examination.

Note: imaging of the cervix or the uterus, oesophagus etc. might require that the transducer should be passed through the vagina or the mouth in order to have a clear picture of the required organ.

Advantages

i. Ultrasound doesn't use radiation therefore; it is the ideal imaging modality for pregnancy.
ii. Readily available.
iii. Lower cost than CT and MRI
iv. An ultrasound is also a helpful way to guide surgeons` movements during certain medical procedures, such as biopsies and fine needle aspiration
v. The machine is portable

Disadvantages

i. The resulting image can be difficult to interpret because it is operator-dependant
ii. Ultrasound waves cannot penetrate bone or air

3.4.3 COMPUTER TOMOGRAPHY

Computerized (or computed) tomography, and often formerly referred to as computerized axial tomography (CAT) scan, is an X-ray procedure that combines many X-ray images with the aid of a computer to generate cross-sectional views and, if needed, three-dimensional images of the internal organs and structures of the body.

CT scans are performed to analyze the internal structures of various parts of the body. This includes the head, where traumatic injuries, (such as blood clots or skull fractures), tumors, and infections can be identified. In the spine, the bony structure of the vertebrae can be accurately defined. In fact, CT scan methods can be used to accurately measure the density of bone in evaluating osteoporosis. CT scans can also be used in the chest to identify tumors, cysts, or infections. CT scans of the abdomen are extremely helpful in defining body organ, including visualizing the liver, gallbladder, pancreas, spleen, aorta, kidneys, uterus, and ovaries. CT scans in this area are used to verify the presence or absence of tumors, infection, abnormal anatomy, or changes of the body caused by trauma.

Principle

A large doughnut-shaped X-ray machine or scanner takes X-ray images at many different angles around the body.A beam of radiation passes through the body and hits a ring or a moving ring segment of detectors. The incoming radiation is continuously registered; the signal is digitized and fed into a data matrix taking into account the varying beam angulations. Each rotation of the scanner provides a picture of a thin slice of the part being scanned. One part of the scanning machine can tilt to take pictures from different positions. All of the pictures are saved as a group on a computer. They also can be printed

Procedure

a. **Before a CT scan:**

- A detailed medical report must be presented before the scan which most include; Presence of pregnancy, allergic to any medicines, including iodine dyes, have a heart condition, such as heart failure, have diabetes or take metformin (Glucophage) for your diabetes, have asthma, have had multiple myeloma.
- Test investigating the abdomen normally requires the patient to drink a different kind of iodinated contrast solution to outline the intestine. This would also require fasting. The patient is usually asked to drink part of the whole dose an hour prior to the scanning time and the rest of it just before entering the scanning room.
- The patient may be asked to take off any jewelry, glasses, and hearing aids. Wear comfortable, loose-fitting clothes.

b. **During the Scan:**

- The CT scanner looks like a large doughnut with a narrow table in the middle. Unlike MRI, in which the patient would be placed inside the tunnel of the scanner, when undergoing a CT scan, the patient rarely experiences claustrophobia because of the openness of the doughnut shape of the scanner
- During the test, the patient will be asked to lie on a table that is attached to the CT scanner, but for certain scans such as sinuses and middle ear, the patient would lie on their stomach and go through head first. Straps will hold your head still, but your face will not be covered.
- The table slides into the round opening of the scanner, and the scanner moves around your body. The table will move while the scanner takes pictures. The patient may

hear a click or buzz as the table and scanner move. It is very important to lie still during the test. For some studies, the patient will be asked to hold their breath for up to 20 seconds.

- During the test, you may be alone in the scanning room. But the technologist will watch you through a window. You will be able to talk to the technologist through a two-way intercom.
- If the test requires an iodine contrast injection, the radiographer will come into the room to administer it using a hand held syringe

After a well scan, the radiographer will come into the room to help the patient off the bed.

c. After the scan:

- If the patient received a contrast injection, the IV is removed from the arm before going home. In the rare circumstance that the patient received sedation, they will be sent home once they are awake and alert. However, someone will have to drive the patient home.
- The CT scan is interpreted by a radiologist, a medical doctor trained to interpret various X-ray studies. The results are forwarded to the doctor. How soon the doctor receives the report depends on the imaging center where the study is performed.

Advantage

i. CT scan can produce a 3-D image quality

Disadvantage

i. The major risks associated with radiography are the small possibilities ofdeveloping a radiation-induced cancer or cataracts some time later in life mostly if the scan is

conducted on children. In most cases this risks can be reduced or eliminated with proper shielding.

ii. There is a chance of an allergic reaction to the dye (contrast material).If you have diabetes or take met formin (Glucophage), the dye may cause problems. Your doctor will tell you when to stop taking met formin and when to start taking it again after the test so you will not have problems.

Figure 5.57 • Axial CT at level of body of pancreas (T_{12}/L_1).

1. Neck of pancreas
2. Duodenum
3. Gallbladder
4. Head of pancreas
5. Inferior vena cava
6. Right crus of diaphragm
7. Renal sinus fat
8. Right renal vein
9. Right renal artery branch
10. Stomach
11. Splenic flexure
12. Splenic vein
13. Body and tail of pancreas
14. Spleen
15. Superior mesenteric artery
16. Left renal artery
17. Aorta
18. Left kidney
19. Confluence of splenic and portal veins

CT scan Image

3.4.4. MAGNETIC RESONANCE IMAGING.

Magnetic resonance imaging (MRI) is a noninvasive medical imaging test that uses a powerful magnetic field, radio frequency pulses and a computer to produce detailed pictures of organs, bone and virtually all other internal body structures most especially soft tissues in which Physicians use to diagnose medical conditions. MRI does not use ionizing radiation.

Uses;

MRI imaging of the body is performed to evaluate:

- Organs of the Head, chest and abdomen—including the brain, heart, liver, biliary tract, kidneys, spleen, bowel, pancreas, and adrenal glands.
- Pelvic organs including the bladder and the reproductive organs such as the uterus and ovaries in females and the prostate gland in males.
- Blood vessels (including MRI Angiography).
- Lymph nodes.

Principle

As a patient lies inside a large, cylinder-shaped magnet surrounded by a circular magnet. Radio waves about 10,000 to 30,000 times stronger than the magnetic field of the earth are sent through the body. This strong magnetic field causes the alignment of particles called protons (hydrogen) which are found naturally within the body without causing any chemical changes to the tissues. Human body is mainly composed of fat and water, which makes the human body composed of about 63%hydrogen. The MRI machine applies radiofrequency (RF) pulse that is specific to hydrogen. The pulse directed to a specific area of the body causes the protons to absorb energy and spin in different direction, which is known as resonance.

Once the magnetic field is switched off, the proton (hydrogen) atoms return to their usual alignment, and emit different amounts of energy (radio wave) that vary according to the type of body tissue from which they come. The moving proton vector induces a signal in the RF antenna; the signal is picked up by a coil and sent to the computer system. The computer receives mathematical data, which is converted through the use of a Fourier transform into an image. For example, a proton found in bone will emit a very different radio wave signal when compare to a proton found in blood.

Procedure

Before an MRI Scan: MRI examinations may be performed on outpatients or inpatients.

- To ensure safety of patient during an MRI scan, the patient would be required to complete a safety questionnaire.
- The patient may be asked to wear a gown during the exam or may be allowed to wear his or her own clothing if it is loose-fitting and has no metal fasteners and since the patient will be exposed to a powerful magnetic field during MRI scan, it is important not to wear any jewelry or any metal object.
- An MRI scan is not suitable for an electrical appliances, such as ear implant, implanted pacemaker, or any surgical clips. Therefore it is important to tell the radiographer before the scan. An alternative test might be arranged for the patient.
- Some implanted devices require a short period of time after placement (usually six weeks) before being safe for MRI examinations. Examples include but are not limited to:
    - artificial heart valves
    - implanted drug infusion ports

    - artificial limbs or metallic joint prostheses
    - implanted nerve stimulators
    - metal pins, screws, plates, stents or surgical staples
- Fasting for a MRI procedure might be required in some cases.
- Some MRI examinations may require you to receive an injection of contrast material into the bloodstream. The contrast material most commonly used for an MRI exam contains a metal called gadolinium. Gadolinium can be used in patients with iodine contrast allergy. It is far less common for a patient to have an allergy to a gadolinium-based contrast agent used for MRI than the iodine-containing contrast for CT. However, even if it is known that the patient has an allergy to the gadolinium contrast, it may still be possible to use it after appropriate pre-medication
- Pregnant women should not receive injections of gadolinium contrast material except when absolutely necessary for medical treatment.

During an MRI Scan: The questionnaire would be reviewed and discussed with the patient before entering the scan room.

- The patient is asked to lie down on the scan table and given a buzzer to hold. When the patient squeeze it, an alarm sounds in the control room and the patient would be able to talk to the radiographer.
- Devices that contain coils capable of sending and receiving radio waves may be placed around or adjacent to the area of the body being studied.The MRI scanner is very noisy. It`s noisy level can damage the hearing of the patient therefore, the patient is given an earplug or headphone to reduce the noise to normal level.

- After the completion of the above steps, the scanning table is then controlled to move the patient into the magnet of the MRI unit (depending on the site needed to be scanned) and the radiologist and technologist will perform the examination while working at a computer outside of the room.
- If a contrast material is used during the examination, it will be injected into the intravenous line (IV) after an initial series of scans. Additional series of images will be taken during or following the injection.
- The patient needs to lied still and hold his/her position during the scan. The patient can breathe normally but occasionally, during some period, the patient is asked to hold his/her breathe. Because breathing and movement can make the image produced to be blurry difficult to assess the problem
- When the examination is complete, you may be asked to wait until the technologist or radiologist checks the images in case additional images are needed.

Note; Tissue with least hydrogen atoms such as bone produced dark image, while tissues with many hydrogen atoms such as fatty tissue look much brighter.

Advantages of MRI

i. MRI is a non-invasive imaging technique that does not involve exposure to ionizing radiation.
ii. It can be used safely during pregnancy and also on younger people and children.
iii. MRI produces best images of the soft-tissue structures of the body such as the brain, heart, liver and many other organs and is used to identify and accurately characterize

diseases of the soft tissue than other imaging methods. This detail makes MRI an invaluable tool in early diagnosis and evaluation of many focal lesions and tumors

iv. MRI allows physicians to assess the biliary system noninvasively and without contrast injection.

v. The contrast material used in MRI exams is less likely to produce an allergic reaction than the iodine-based contrast materials used for conventional x-rays and CT scanning.

vi. MRI can also provide information as data or graphs.

Disadvantages of MRI

i. Cannot be used if patient has certain metal or electronic implants

ii. Uncomfortable procedure (long, noisy, claustrophobic) for some patients

iii. Manufacturers of intravenous contrast indicate mothers should not breastfeed their babies for 24-48hours after contrast medium is given.

iv. A person who is very fat may not fit into the opening of certain types of MRI machines.

v. Very Expensive and may take more time to perform than other imaging modalities

vi. It’s very sensitive to breathing, breathing may cause artifacts, or image distortions, during MRIs of the chest, abdomen and pelvis.

CHAPTER FOUR

4.1 CONCLUSION

The establishment of SIWES is one the greatest thing that have ever happened to educational system as NIGERIA is concerned. Because it is like a light that has cast away darkness of practical ignorant from me and has enhance and upgrade my intelligent quotient in my area of study also in medical care.

4.2 Problems Encountered During the Industrial Attachment

The basic problems I encountered during my industrial training attachment with Jos University Teaching Hospital are;

i. I had some challenges on transportation as the venue of my IT place was far from my place of residence, I had to spend quite an amount of money on transportation.

ii. In radiology specifically, I was restricted from very important knowledge which I ought to acquire, for the reason that my course of study is not much related to some important test been carried out in the unit. Thus I wasn't able to acquire thorough knowledge of such test procedures.

iii. Due to improper maintenance and care of the hospital management, most important machines are not available, while most the machines that are available are faulty and has been abandoned. Therefore some procedures are performed manually, skipped or manoeuvred. This requires much labour, it's time consuming and also affect our end result.

4.3 RECOMMENDATION

The creation of SIWES is a wonderful effort which has successfully developed undergraduates, training them to fit into the industries before they graduate from their institution.

The following are recommendations and suggestions that will further help strengthen

SIWES in Federal University Ndufu-Alike, Ikwo.

i. There is need for various departments to organize orientations for their students apart from the one organized by ITF. This departmental orientation should outline what is expected by the students before going for the IT.
ii. Also for JUTH, they should try to adjust their policy. I.T is meant for student to gain and to have experience in all aspect of their course of study, they should stop their monopolistic attitude, that anatomist are meant to work only in the mortuary.
iii. For I.T.F, There should be regular disbursement or payment of the students' allowances to enable most students participates effectively and also they should try to increase the payment.