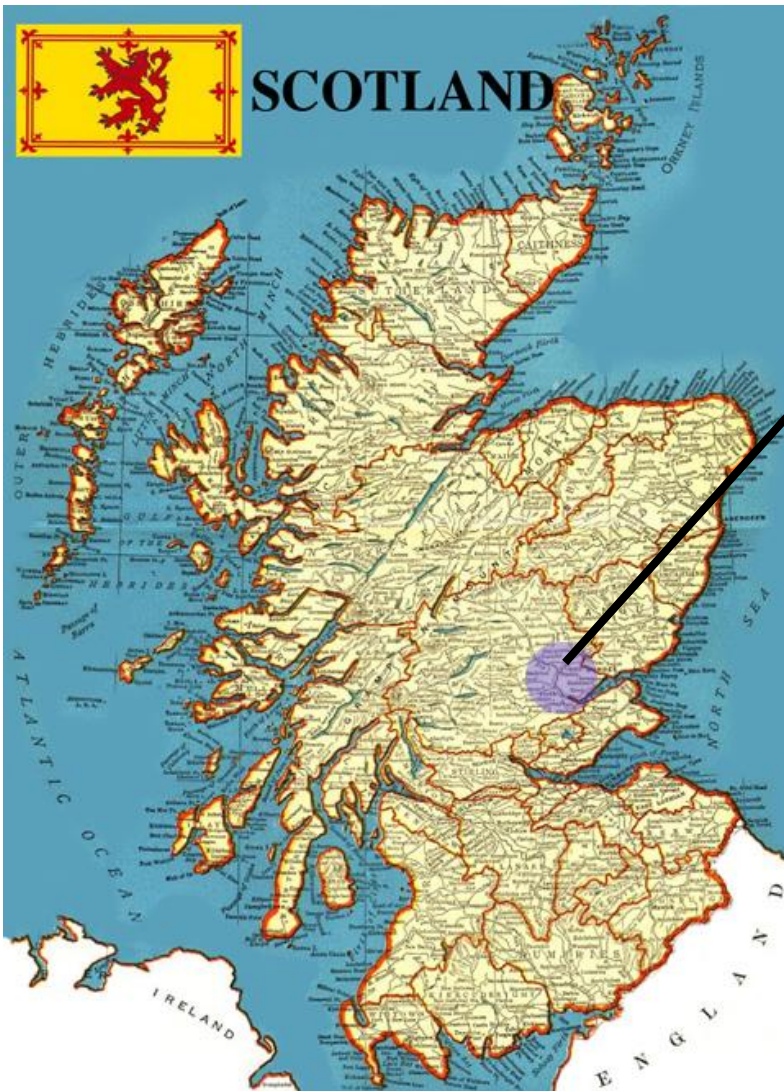


SCOTTISH FOLD



The first known Scottish Fold was discovered in 1961 by William Ross at a farm near Coupar Angus in the Tayside Region of Scotland.



William & Mary Ross



SCOTTISH FOLD

Updated June 2018

Bruce Russell, Breed Council Secretary

SCOTTISH FOLD

Over the decades the Scottish Fold has developed a look all its own. The Scottish Fold is a medium sized cat with a rounded, well-padded body and a short or medium long coat. It has large, round broadly spaced eyes full of sweetness, well-rounded whisker pads and a short nose with a gentle curve in profile. Ears should be folded forward and downward, set in a cap like fashion.

SCOTTISH FOLD

EARS - 25 pts

TAIL - 20 pts

HEAD - 15 pts

EYES - 15 pts

BODY - 10 pts

COAT - 10 pts

COLOR - 5 pts

SCOTTISH FOLD

Long Hair



Short Hair



SCOTTISH FOLD

Head - 55 Points

Head is well rounded, with firm chin and jaw. While cheeks should be prominent, males will have a jowly appearance. Head should blend into a short neck.

Ears 25 Points

Head 15 Points (shape, muzzle, neck, chin, profile)


Eyes 15 Points

SCOTTISH FOLD

Key word in describing a Scottish Fold head – ROUND




Round



Triangular

SCOTTISH FOLD



Round



Triangular

SCOTTISH FOLD



Expression should have pleasing symmetrical appearance.




Brow ridge (penalize) gives a scowling look - Nose break visible or palpable is a disqualification

SCOTTISH FOLD



Pleasing and Symmetrical



Visible Nose Break

SCOTTISH FOLD



Pleasing and Symmetrical



Pleasing and Symmetrical

SCOTTISH FOLD

Profile should be moderate with a short nose and a gentle curve.



SCOTTISH FOLD



SCOTTISH FOLD

The expression of the Scottish Fold should be one of wide-open sweet astonishment of the world. The eyes should be round and separated by a broad nose. Slightly slanted, almond shaped eyes are not preferred. Smaller, squinty eyes do not create a round, wide-open look.



SCOTTISH FOLD



Round and Open Eyes



Almond Shaped Eyes

SCOTTISH FOLD

When checking the head, the cat should be facing the audience and it is best to look down onto the muzzle. You are looking for smooth underlying boning and gently rounded padded muzzle.

This can be done without pulling the head back which will cause a strain on the neck muscles.

SCOTTISH FOLD

Ears - 25 points

- Folded down and forward.
- Placement - set in a cap-like fashion to create and compliment a rounded cranium.
- Smaller, tightly folded ear preferred over a loose fold or larger ear.
- Ear tips are gently rounded.

SCOTTISH FOLD

Ears placed high on head are undesirable as it causes ears to appear as “horns”, distorting the cap-like roundness and symmetry.



SCOTTISH FOLD



High Ear Placement

SCOTTISH FOLD

Although a smaller, more tightly folded ear is preferred, a looser, slightly larger ear can be pleasing if it complements the rounded cranium.

The ears on a Fold are fully flexible and Folds can swivel and move their ears with ease. Proper set of ears can best be viewed when the cat's attention is attracted down and to the center. A cat whose attention is elsewhere may pull their ears back making them difficult to evaluate. If you place a hand behind the cat's head it will cause them to relax their ears so they can be judged properly.

SCOTTISH FOLD

Body - 40 Points

Body description again stresses roundness. The Fold should have a medium boned, well-padded body which is even from shoulder to hip. Overall appearance to be a hardy, sturdy cat.

Note: There must be no lack of mobility or agility.

Body Structure 10 Points (Torso, legs & paws)

Tail 20 Points

Coat 10 Points

SCOTTISH FOLD


Tail - 20 Points

Tail should be medium to long in proportion to the body.

You will look for a flexible tapering tail which can end in a round tip.

A tail that demonstrates abnormally thick vertebrae, is kinked, inflexible or shows sign of being foreshortened is a disqualification.

SCOTTISH FOLD



Note length of tail

SCOTTISH FOLD



SCOTTISH FOLD

The best way to judge a Fold's tail is to start at the base of the tail. Place your fingers under the tail with the thumb resting lightly on the top of the tail. Gently lift the tail and roll it through your fingers. If done correctly, you can detect any stiffness, kinks or abnormal vertebrae in the tail. Each vertebrae should move independent of each other.

The tail is an extension of the spinal column, and it should be remembered that aggressive manipulation can be understandably painful and uncomfortable.


SCOTTISH FOLD

Coat - Shorthair

- The coat for the shorthaired cat should be short to medium, dense, plush and even in length, standing away from the body.
- It should be soft in texture and full of life.
- It should not be flat or close lying.

SCOTTISH FOLD

Shorthair




SCOTTISH FOLD

Coat - Longhair

- The coat for the longhaired cat should be medium to long. Shorthair is permissible on the face and legs, but a full body coat is desirable. Britches, tail plume, toe tufts and ear furnishings should be clearly visible with a ruff desirable.
- Seriously penalize cottony coat, except in kittens.
- A coat which is very thick and very long over the body, such as found on a Persian, would not be considered a proper Scottish Fold longhair coat.

SCOTTISH FOLD

Longhair



SCOTTISH FOLD

Penalize – Brow ridge

Disqualify:

- Kinked tail
- Tail that is foreshortened
- Tail that is lacking in flexibility due to abnormally thick vertebrae
- Splayed or incorrect number of toes
- Palpable nose break
- Any evidence of illness or poor health

SCOTTISH FOLD

Handling

- Generally, most Scottish Folds will play for the judge and enjoy showing themselves off to the audience. Judges are encouraged to play with this breed, as playing will afford a better view of the head. Again, the best view of the head is when the cat's attention is attracted down and to the center.
- It is encouraged that judges NOT check the flexibility of the tail until all four feet are placed on the table. When checking the tail, gently manipulate each vertebrae for signs of inflexibility. Fused bones will not move independently of each other. Problems with fusion, stiffness or kinks can happen throughout the entirety of the tail, so gently evaluate from the base of the tail to the tip.

SCOTTISH FOLD



Thank you for your attention!

OSTEOCHONDRODYSPLASIA

Osteochondrodysplasia

The Scottish Fold breed has cats with both straight and folded ear phenotypes. The fold type results from a mutation in a single gene. The mutation is dominant and a single copy of the mutation affects cartilage development and produces the fold phenotype. Other impacts of the mutation are variable but most consistently present as smaller feet resulting from misshapen toes, thickened and inflexible tails and accelerated progressive osteoarthritis. Age of onset and progression of secondary effects are highly variable but ear folding is a consistent feature. Kittens with two copies are prone to more extreme health problems affecting cartilage and bone. – Dr. Leslie Lyons

Take home lessons

1. This is one gene, and it is identical all over the world.
2. Even if bred “correctly”, this gene causes secondary issues with variable severity.
3. Folding of the ears is consistent, so if you do not have the gene, your phenotype is “straight ear”.

Autosomal Dominance and the Punnett Square

	F	f
F	FF	Ff
f	Ff	ff

	F	f
f	Ff	ff
f	Ff	ff

FF = Folded ear phenotype

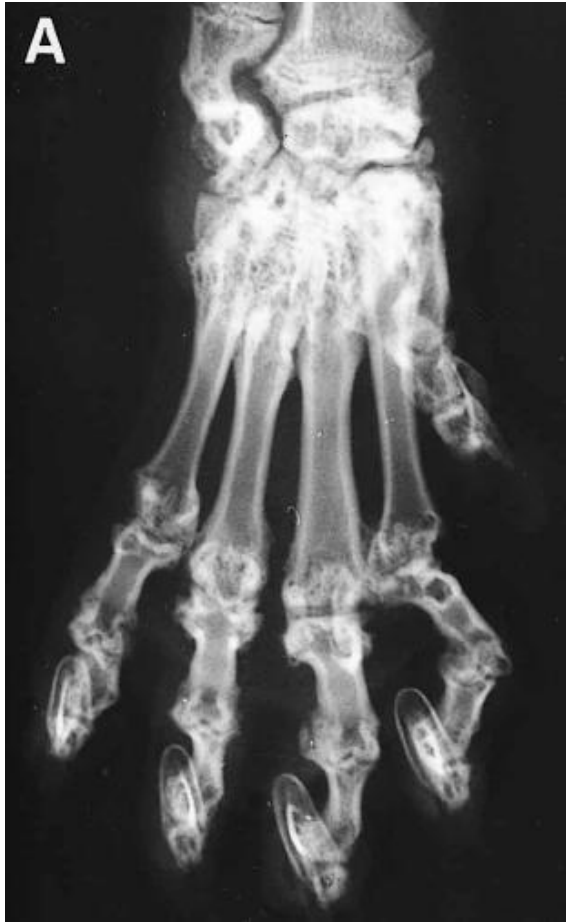Ff = Folded ear phenotype

ff = straight ear phenotype

Osteochondrodysplasia

- “Osteochondrodysplasia is not seen in homozygote cats alone. Varying degrees of primary developmental deformities are also observed in heterozygote cats”--Hereditary Osteochondrodysplasia in Scottish fold Cats 2015 Aydin, et al
- “Scottish Fold: There is no intention to recognize this breed because the gene which produces the folded ears also causes skeletal abnormalities, producing stiffness of the limbs and tail which increases with age. This is especially true when two fold-eared cats are bred together but it has been shown that cats with only one gene for folded ears also suffer from abnormal stiffness. Under these circumstances it has never been recognized and we strongly advise members of the public not to try to acquire cats of this breed.”--GCCF (Governing Council of the Cat Fancy-UK)
- “In all nine cases where pedigree information was available, affected cats allegedly originated from the mating of a Scottish Fold to a cat with normal ears. The severity and time of onset of physical signs, and rate of progression and extent of radiographic abnormalities, varied from case to case.”--Osteochondrodysplasia in Scottish Fold Cats 1999 Malik, et al.

Osteochondrodysplasia



Osteochondrodysplasia

[Osteoarthritis Cartilage](#). 2016 Aug;24(8):1441-50. doi: 10.1016/j.joca.2016.03.019. Epub 2016 Apr 6.

A dominant TRPV4 variant underlies osteochondrodysplasia in Scottish fold cats.

[Gandolfi B](#)¹, [Alamri S](#)², [Darby WG](#)³, [Adhikari B](#)⁴, [Lattimer JC](#)⁵, [Malik R](#)⁶, [Wade CM](#)⁷, [Lyons LA](#)⁸, [Cheng J](#)⁹, [Bateman JF](#)¹⁰, [McIntyre P](#)¹¹, [Lamandé SR](#)¹², [Haase B](#)¹³.

- **OBJECTIVE:** Scottish fold cats, named for their unique ear shape, have a dominantly inherited osteochondrodysplasia involving malformation in the distal forelimbs, distal hindlimbs and tail, and progressive joint destruction. This study aimed to identify the gene and the underlying variant responsible for the osteochondrodysplasia.
- **DESIGN:** DNA samples from 44 Scottish fold and 54 control cats were genotyped using a feline DNA array and a case-control genome-wide association analysis conducted. The gene encoding a calcium permeable ion channel, transient receptor potential cation channel, subfamily V, member 4 (TRPV4) was identified as a candidate within the associated region and sequenced. Stably transfected HEK293 cells were used to compare wild-type and mutant TRPV4 expression, cell surface localisation and responses to activation with a synthetic agonist GSK1016709A, hypo-osmolarity, and protease-activated receptor 2 stimulation.
- **RESULTS:** The dominantly inherited folded ear and osteochondrodysplasia in Scottish fold cats is associated with a p.V342F substitution (c.1024G>T) in TRPV4. The change was not found in 648 unaffected cats. Functional analysis in HEK293 cells showed V342F mutant TRPV4 was poorly expressed at the cell surface compared to wild-type TRPV4 and as a consequence the maximum response to a synthetic agonist was reduced. Mutant TRPV4 channels had a higher basal activity and an increased response to hypotonic conditions.
- **CONCLUSIONS:** Access to a naturally-occurring TRPV4 mutation in the Scottish fold cat will allow further functional studies to identify how and why the mutations affect cartilage and bone development.

Osteochondrodysplasia

Nat Genet. 2011 Oct 2;43(11):1142-6. doi: 10.1038/ng.945.

Mutations in TRPV4 cause an inherited arthropathy of hands and feet.

Lamandé SR1, Yuan Y, Gresshoff IL, Rowley L, Belluoccio D, Kaluarachchi K, Little CB, Botzenhart E, Zerres K, Amor DJ, Cole WG, Savarirayan R, McIntyre P, Bateman JF.

Murdoch Childrens Research Institute, Royal Children's Hospital, Melbourne, Australia.
shireen.lamande@mcri.edu.au

Familial digital arthropathy-brachydactyly (FDAB) is a dominantly inherited condition that is characterized by aggressive osteoarthropathy of the fingers and toes and consequent shortening of the middle and distal phalanges. Here we show in three unrelated families that FDAB is caused by mutations encoding p.Gly270Val, p.Arg271Pro and p.Phe273Leu substitutions in the intracellular ankyrin-repeat domain of the cation channel TRPV4. Functional testing of mutant TRPV4 in HEK-293 cells showed that the mutant proteins have poor cell-surface localization. Calcium influx in response to the synthetic TRPV4 agonists GSK1016790A and 4 α PDD was significantly reduced, and mutant channels did not respond to hypotonic stress. Others have shown that gain-of-function TRPV4 mutations cause skeletal dysplasias and peripheral neuropathies. Our data indicate that TRPV4 mutations that reduce channel activity cause a third phenotype, inherited osteoarthropathy, and show the importance of TRPV4 activity in articular cartilage homeostasis. Our data raise the possibility that TRPV4 may also have a role in age- or injury-related osteoarthritis.

PMID: 21964574 DOI: 10.1038/ng.945

Osteochondrodysplasia

